

# We are IntechOpen, the world's leading publisher of Open Access books Built by scientists, for scientists

6,900

Open access books available

186,000

International authors and editors

200M

Downloads

Our authors are among the

154

Countries delivered to

TOP 1%

most cited scientists

12.2%

Contributors from top 500 universities



WEB OF SCIENCE™

Selection of our books indexed in the Book Citation Index  
in Web of Science™ Core Collection (BKCI)

Interested in publishing with us?  
Contact [book.department@intechopen.com](mailto:book.department@intechopen.com)

Numbers displayed above are based on latest data collected.  
For more information visit [www.intechopen.com](http://www.intechopen.com)



---

## **Early Treatment of Anterior Crossbite Relating to Functional Class III**

---

Sanaa Alami, Hakima Aghoutan, Farid El Quars,  
Samir Diouny and Farid Bourzgui

Additional information is available at the end of the chapter

<http://dx.doi.org/10.5772/59251>

---

### **1. Introduction**

Anterior crossbite is one of the most common orthodontic problems observed in children's growth, in both skeletal and functional Class III malocclusion. The latter presents an apparent imbalance in jaw size, considered to be essentially the result of a mesial thrust of the mandible. Its origins are multiple, ranging from abnormal eruption of deciduous or definitive incisors to lingual dysfunction (low position of the tongue) [1].

Functional Class III has long-term effects on the growth and development of the teeth. This widely justifies the need for early treatment to normalize the occlusion and create conditions for normal jaws development. An accurate diagnosis is required for successful treatment and stability.

Orthodontists must distinguish pseudo Class III crossbites from skeletal Class III. Thorough clinical assessment and accurate diagnosis must be performed in order to plan proper treatment strategies and appliance design during the early stages of dental development. In this respect, various modes of treatment have been suggested for anterior crossbite correction [2, 3, 4, 5]; early interceptive treatment is one mode of treatment, which has been suggested because of its diverse benefits.

This chapter aims (1) to define functional mandibular prognathism and its etiopathogeny, (2) to highlight the needs to manage earlier anterior crossbites, and finally (3) to illustrate the impact of interceptive approach with the use of a simple fixed appliance.

## 2. Functional mandibular prognathism

The functional mandibular prognathism referred as mandibular pseudo-prognathism, or pseudo-Class III, is a mandibular abnormal function belonging to the class III malocclusion according to the terminology of Angle [1, 6]. The aforementioned is an anomaly of occlusal origin, which develops into a skeletal anomaly (true Class III). Indeed, the functional disorder translates into a normal closure until the premature contact [7].

Anterior crossbite is defined as a situation in which one or more permanent mandibular incisors occlude labially to their antagonists [4], which can be associated or not to a mandibular lateral-deviation [7].

### 2.1. Etiopathogeny

Pseudo-Class III malocclusion is identified as an anterior crossbite as a result of mandibular displacement. The reported prevalence of anterior crossbites varies between 2.2% and 12%, depending on children's age and their ethnicity [2, 8, 9, 10].

Moyers suggested that pseudo-Class III malocclusion was a positional relationship related to an acquired neuromuscular reflex. The anterior crossbite that results is established in the mixed dentition. Different etiological factors are involved; they can be classified in dental, functional and skeletal factors [4, 8, 9].

#### Dental factors:

- Palatal eruption of the maxillary central incisors,
- Proclination of the lower incisors due to low thrust lingual or supernumerary anterior teeth in mandible,
- Premature loss of the the primary upper incisors following a dental trauma,
- Over-retained primary maxillary incisors due to odontomas,
- Crowding in the incisor region, and inadequate arch length

#### Functional factors:

- Tongue position anomalies
- Nasorespiratory problems

#### Skeletal factors:

- Minor transverse maxillary discrepancy.

Premature contact between the maxillary and mandibular incisors results in a forward displacement of the mandible to permit a comfortably occlusion [4, 9, 11].

## 2.2. Prognosis

Functional mandibular prognathism in the early mixed dentition can have long-term effects on the growth and development of the teeth and jaws (McNamara, 2002). Anterior crossbite may lead to abnormal enamel abrasion or proclination of the mandibular incisors, which, in turn, leads to gingival recession. Abnormal mandibular shift caused by lack of incisal guide may have adverse effects on the temporo-mandibular joints and masticatory system [4, 12].

What is most to be feared is that a functional anomaly becomes a skeletal prognathism. Indeed, spontaneous correction of such malocclusion has been reported to be too low to justify non-intervention. Therefore, interceptive treatment is often advised to normalize the occlusion and create conditions for normal occlusal development [4].

## 3. Diagnostic approach

Class III malocclusion has been divided into two subtypes: Skeletal and pseudo-Class III [5]. The early management of the pseudo-class III presents no real difficulties. Timing and modalities of treatment depend on the differential diagnosis which aims to determine whether the crossbite is dental or skeletal in nature. An essential aspect of the differential diagnosis in Class III malocclusion is the assessment of dental compensations and the presence of functional slide via a thorough clinical and radiographic analysis [13].

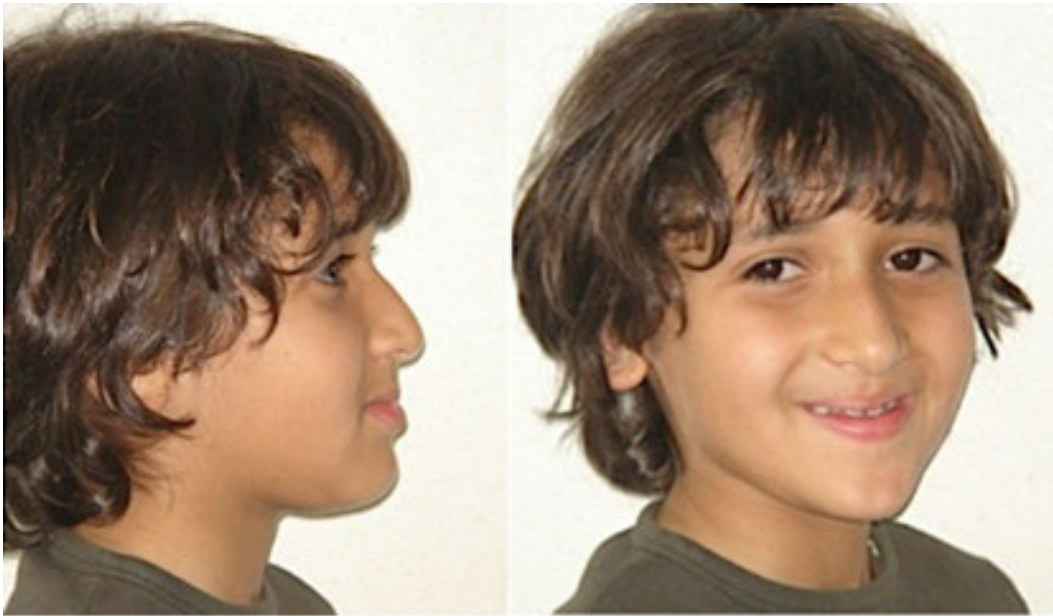### 3.1. Clinical analysis

#### 3.1.1. Exobuccal evaluation

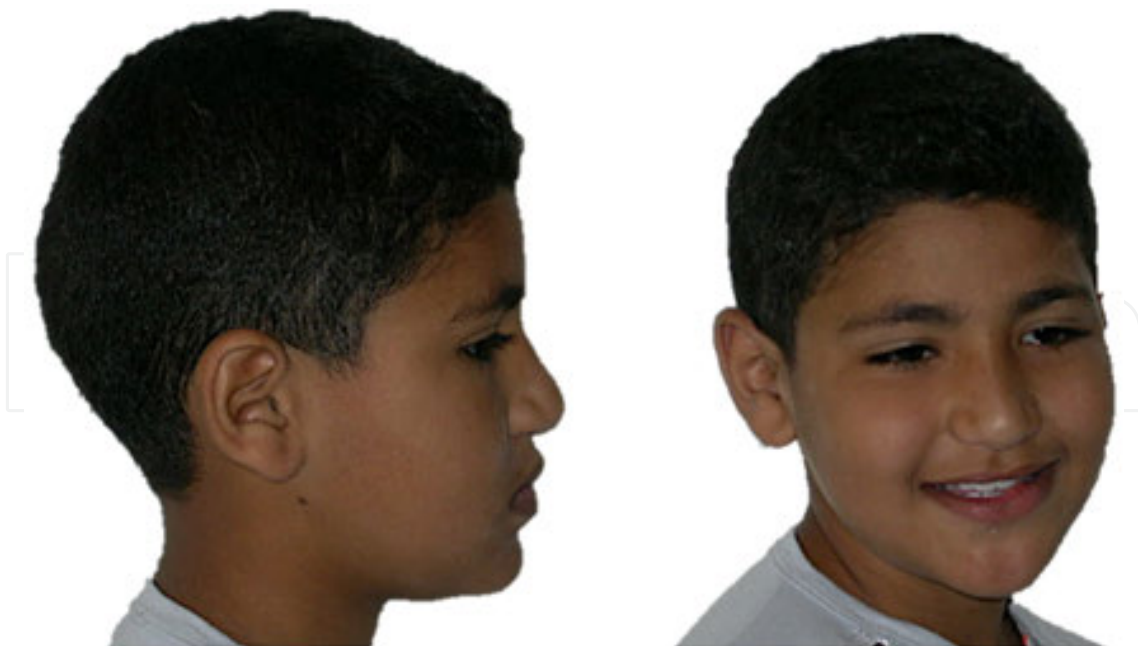
Exobuccal signs are practically the same for both types of dysmorphia (skeletal and functional Class III) which are, most of the time, misleading. There is usually a concave profile, characterized by an inversion of the labial relationship as well as a projection at the front of the mandible (Figure 1). Usually, soft tissues tend to camouflage skeletal discrepancy so that the patient's profile appears normal or slightly concave in centric occlusion (Figure 2) [10].

It is important to note that although skeletal Class III is mandibular or maxillary, there is some degree of maxillary deficiency. Skeletal Class III, therefore, differs by a retrusive nasomaxillary area, and an important protrusive lower face and lip (Figure 3) [14].

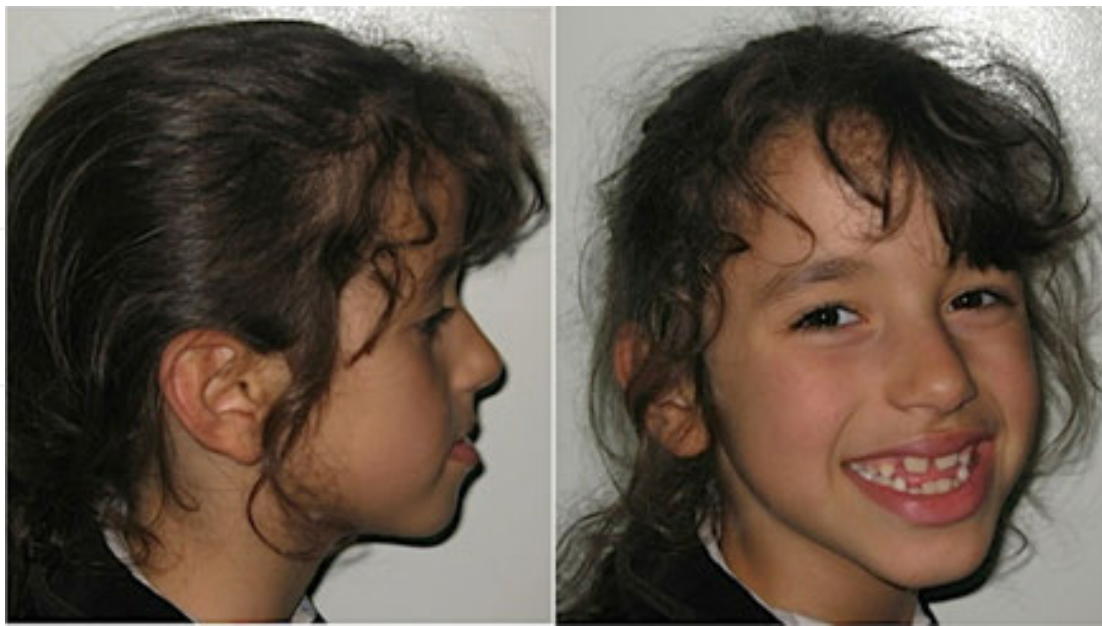The clinical assessment of profile changes from postural rest position to habitual occlusion is an additional criterion to be evaluated. The skeletal Class III profile remains concave in both positions, whereas the pseudo-class III profile is usually straight, but becomes concave as the mandible shifts forward into habitual occlusion position [9]. As many signs, which could mislead to a true Class III diagnosis.



**Figure 1.** A patient, aged 8, presents pseudo-Class III malocclusion characterized by retrusion of the upper lip relative to the lower lip; smile betrays an anterior crossbite



**Figure 2.** A patient, aged 9, presents pseudo-Class III malocclusion and a convex soft-tissue profile; labial relationships appear normal. Anterior cross-bite is revealed only on the views of smiling face and  $\frac{3}{4}$ .

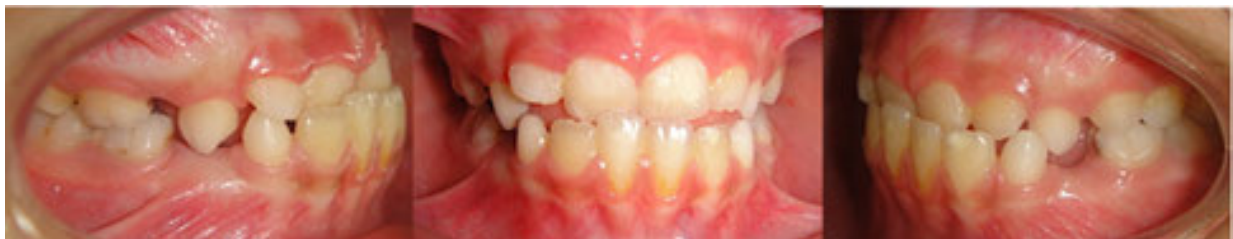

**Figure 3.** A patient, aged 8, presents skeletal Class III malocclusion characterized by concave profile and retrusive nasomaxillary area.

### 3.1.2. Endobuccal evaluation

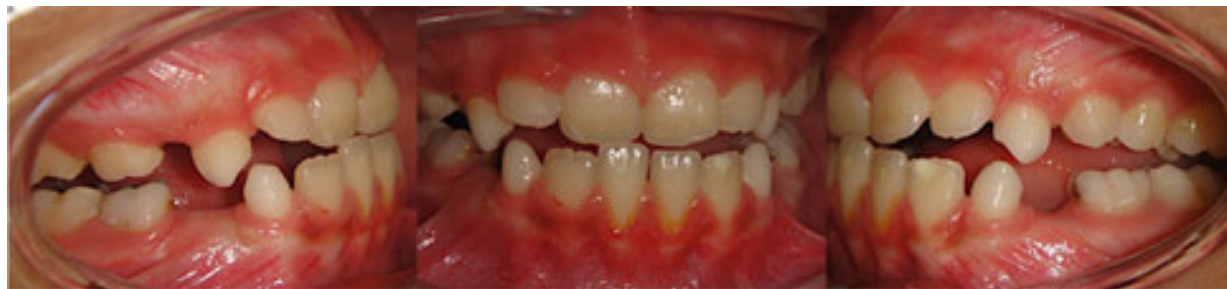Endobuccal exam allows the practitioner to identify his patient as a class I case. In skeletal Class III, dento-alveolar components compensations occur in the form of proclined maxillary incisors and retroclined mandibular incisors [9]. This is in contrast with pseudo-Class III cases, where anterior crossbite occlusion and Angle's Class III molars and canines are associated with dental compensations of class II malocclusion (Figure 4).

The assessment of dental relations must always be done with the mandible in centric relation. (Figure 5) It is important at this stage to proceed to the unique gesture, which allows making the differential diagnosis: It is the De Nevreze procedure, which consists in obtaining a more retrusive position of the mandible to minimize the dental relations in pseudo-prognathism cases. Conversely, in true mesiocclusion, the maneuver does not succeed. The mandible cannot be retruded, and there is no modification of the dental reports [1, 15].



**Figure 4.** Pre-treatment intra-oral photographs in habitual occlusion showing characteristics of Angle's Class III molars and canines, vertical axis of the maxillary incisors, and the presence of anterior crossbite occlusion.

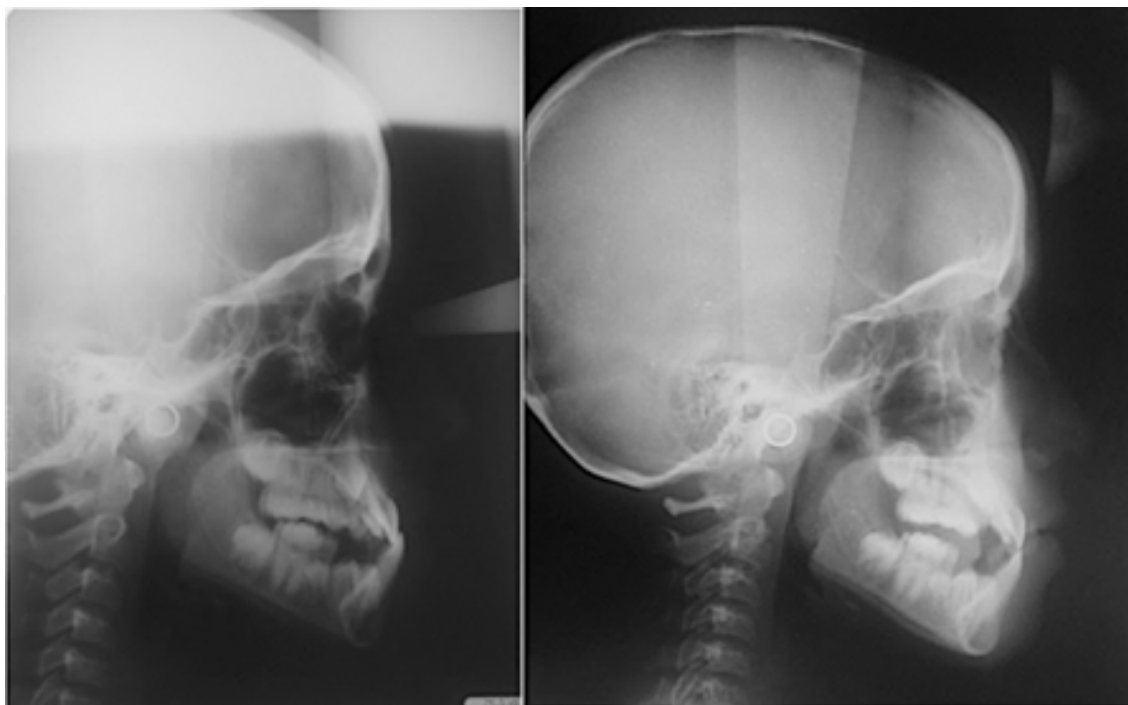
When the anterior crossbite exhibit a functional shift; that is, interincisal contact is possible in centric relationship, implying a pseudo Class III malocclusion with no inherent skeletal Class III discrepancy [8]. We find Characteristics of Angle's Class I molars and canines (Figure 5).



**Figure 5.** Pre-treatment intra-oral photographs in centric occlusion showing edge-to-edge occlusion and Angle's Class I molars and canines relationship.

### 3.2. Radiographic analysis

Lateral cephalogram largely contributes to establishing the diagnostic of a skeletal Class I. To evaluate the amount of mandibular shift, two lateral cephalograms, one at maximum intercuspation and one at the point of initial contact, are compared. (Figures 6)



**Figure 6.** Pretreatment lateral cephalogram in maximum intercuspation position (AOBO=-7mm) and in position of initial contact with anterior edge to edge (AOBO=-4mm), showing that cephalometric values are in favor of a middle Class I.

In true Class III, the skeletal components are characterized by an underdeveloped maxilla, overdeveloped mandible or a combination of both. Dento-alveolar compensations are revealed by cephalometric values for proclined maxillary incisors and retroclined mandibular incisors.

Tweed defined a pseudo Class III malocclusion as having a conventionally shaped mandible. The sagittal jaw relation's show a Class I or a mild Class III pattern in centric relation. The upper incisors are often retroclined, whereas lower incisors are normally inclined or proclined [9].

## **4. Interceptive treatment**

### **4.1. Timing**

Optimum treatment timing for orthodontic problems continues to be one of the most controversial topics in orthodontics; this is especially true for the correction of Class III malocclusion [16].

However, spontaneous worsening during transition from deciduous to permanent dentition has been reported. For this reason, pseudo Class III malocclusion should be treated as early as possible to reduce the functional shift of the mandible and increase maxillary arch length [3, 5].

Several clinicians believe that early intervention has many advantages; they have suggested a number of reasons for early correction of anterior crossbite even in the deciduous dentition. The optimum period suggested for treatment is between 6 years and 9 years; intervention at this period permits normal growth [10].

### **4.2. Objectives**

Generally, interceptive orthodontic treatment during mixed dentition is more effective to improve malocclusions than no treatment. Early intervention is, therefore, recommended preventing adverse effects on growth and development of the jaws and disturbance of temporal and masseter muscle activity, which would increase the risk of craniomandibular disorders during adolescence. A pseudo Class III malocclusion should be treated as early as possible to reduce the functional shift of the mandible and increase maxillary arch length [2, 3, 5].

In addition to its effectiveness and efficiency, early orthodontic treatment may have positive effects on the quality of life for both children and their families (self-esteem, social acceptance) [3].

The management of a pseudo-class III malocclusion via the proclination of upper incisors and/or retroclination of lower incisors aims to correct anterior crossbite and eliminate mandibular displacement. Obtaining a front stop to lock the occlusion allows creating conditions for normal occlusal development [4, 9].

4.3. Modalities of treatment

Various appliances have been devised for early treatment of a pseudo Class III ; these include removable plates, fixed or removable inclined planes, functional appliances, face mask, and simple fixed appliances. Each device has its specific indication, its advantages and disadvantages [6, 10, 15].

4.3.1. Removable appliances

Hawley appliance with auxiliary springs is one of the earliest appliances introduced to produce proclination of upper incisors. The plate stabilization is provided by Adams clasp and the heightening of occlusion is strongly required to resolve an anterior crossbite (Figure 7 and 8).

A modified Hawley appliance with inverted labial bow is a simple way to manage pseudo Class III. The appliance is easy to construct and require transferring the bite by guiding the mandible distally in an edge to edge (Figure 9) [15].

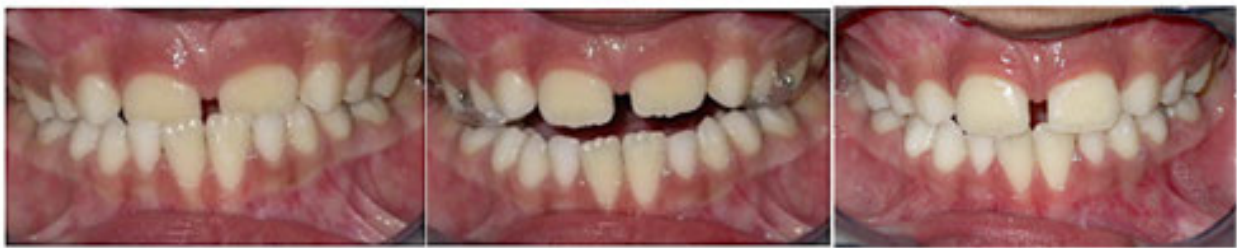

Figure 7. Correction of anterior crossbite by Hawley appliance with auxiliary springs

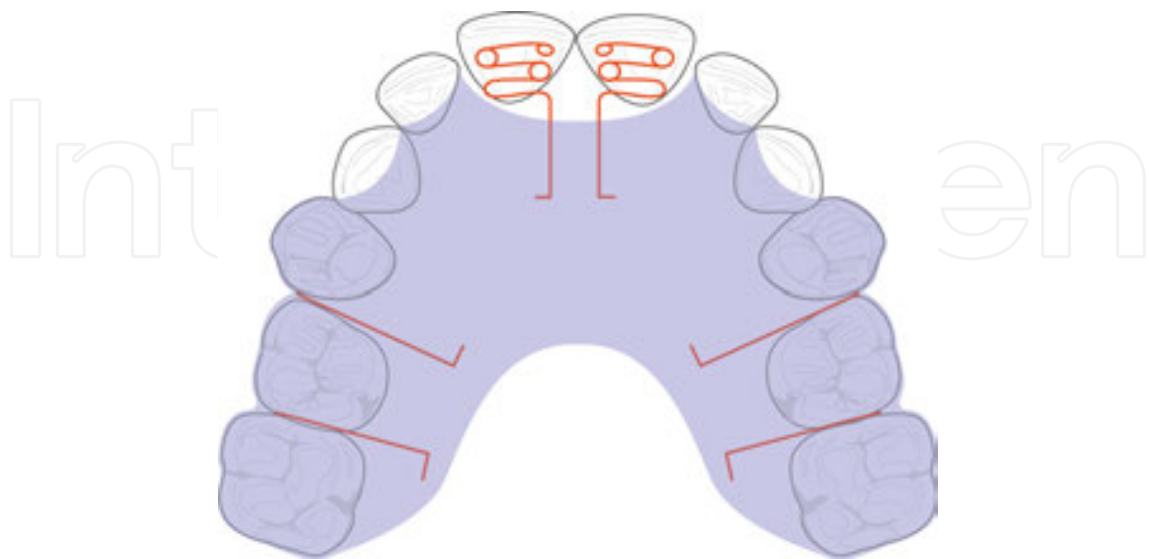
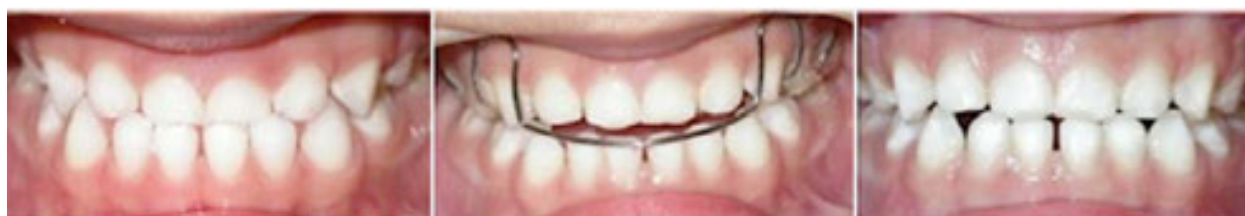

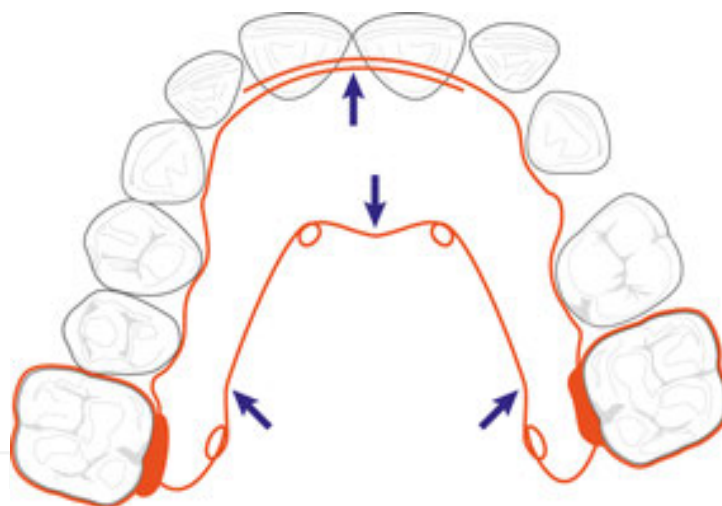
Figure 8. illustrating components of Hawley appliance with springs.



**Figure 9.** Correction of anterior crossbite, in deciduous dentition, by Hawley appliance with inverted labial bow

#### 4.3.2. *A modified quad helix appliance*

This is one of the earliest appliances introduced for posterior expansion, it is made of 0.036 Blue Elgiloy and soldered to the bands on the first permanent maxillary molars. It can be modified by addition of an anterior extension arm. The appliance is expanded and cemented. The occlusion must be relieved by posterior bite-blocks to permit crossbite correction [9]. The gradual activation of both arms allows proclination maxillary incisors. The major indication of such device is the combination of anterior and posterior crossbites (Figure 10).

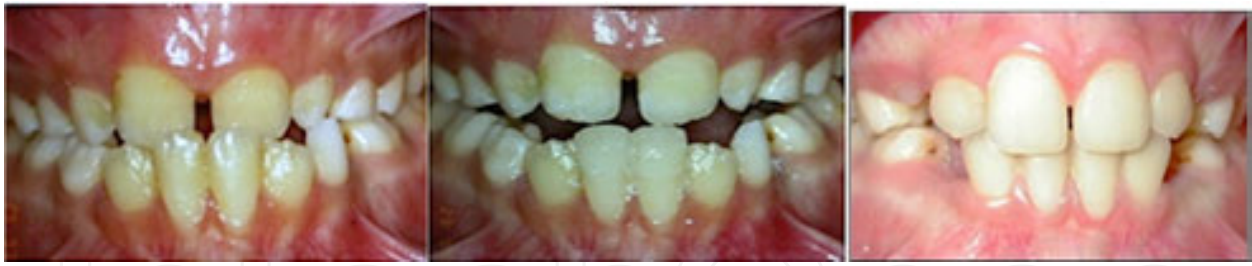

**Figure 10.** Illustrating activation of modified quad helix

#### 4.3.3. *Inclined plane*

Some modalities for anterior crossbite correction include fixed or removable acrylic inclined planes (Croll, 1984), bonded resin-composite slopes (Bayrak and Tunc, 2008) [4, 12].

These are simple functional appliances placed on the lower arch; they allow quicker results. One of the identified advantages of removable appliance is that it can also be used as retention appliance after active treatment as well as it is possible to add acrylic teeth if necessary (Figure 11) [12].



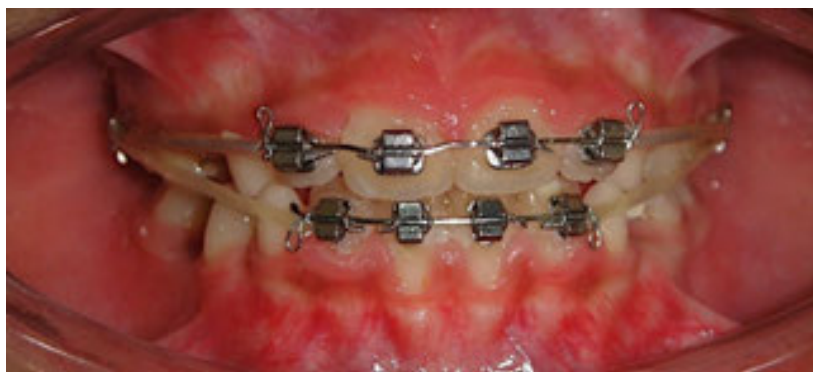**Figure 11.** Correction of anterior crossbite by bonded resin-composite plane on mandibular incisors. The ramps should be progressively reduced.

#### 4.3.4. Fixed appliance

The earlier treatment of pseudo-prognathism was feasible from a simple fixed appliance (partial bonding of brackets) simultaneously with elastics.

The most common pattern is to bond the brackets on the labial surfaces of the lower incisors and the palatal surfaces of the upper incisors. Intermaxillary elastics are then used to create an earlier proclination maxillary incisors and retroclination mandibular incisors.

This can also be composed of bands or tubes on the first permanent maxillary molars, brackets on the maxillary, and a wire with open coil springs. Brackets are also bonded on the mandibular incisors and the anterior cross-bite is simultaneously managed with Class III elastics (Figure 12) [17].



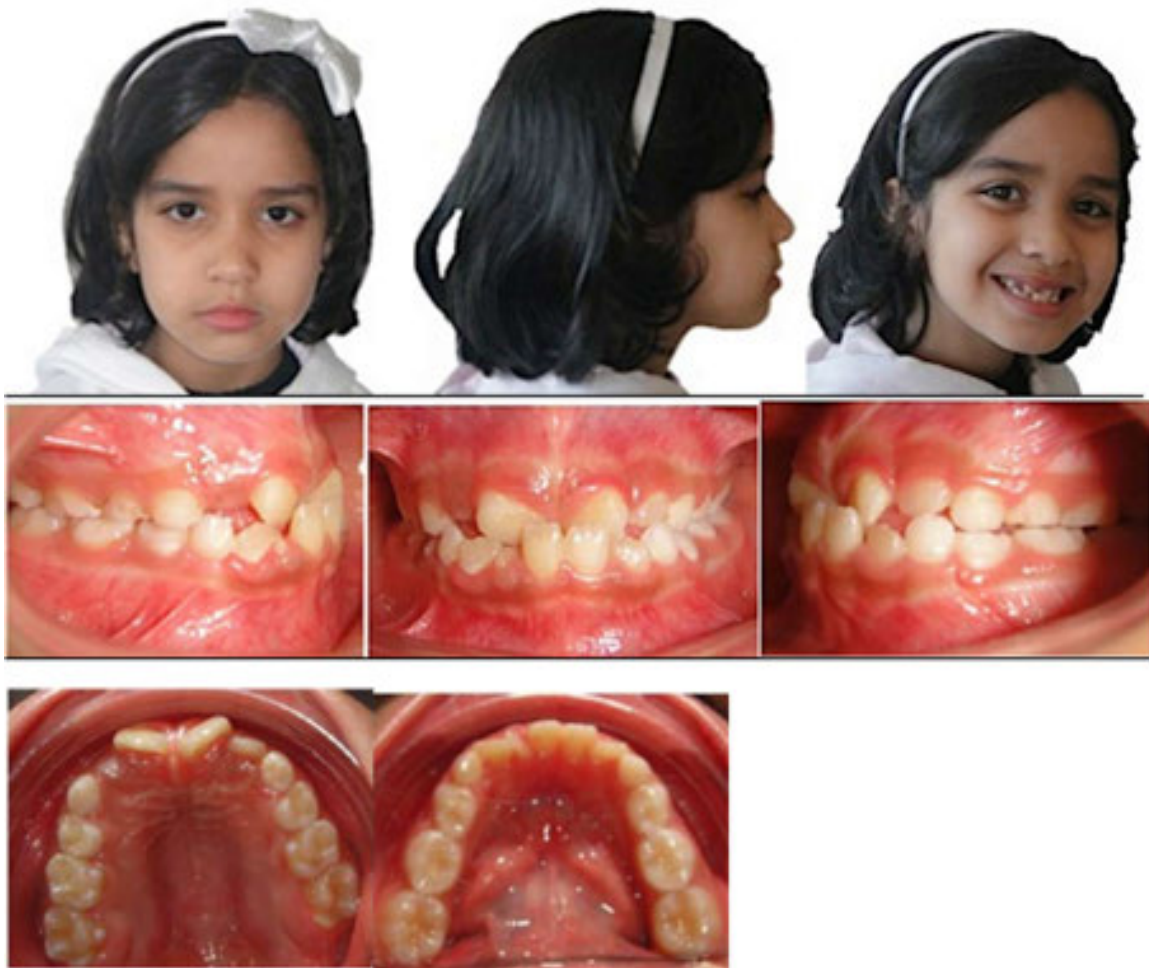**Figure 12.** The components of standard edgewise appliance to resolve an anterior crossbite.

## 5. Case reports

### 5.1. Case N° 1

A 8 year-old girl was referred by her pediatric dentist for an orthodontic consultation regarding her anterior bite. Extra orally, she had a balanced face, *a slight retrusion of the upper lip while*

*excessive mandibular anterior displacement is revealed to smile view. She presented in the early mixed dentition stage with Class III left molar relationships. The anterior crossbite was expressed as a result of functional shift of the mandible in the sagittal plane due to lingually-inclined maxillary incisors and supernumerary anterior teeth in mandible. (Figure 13) When the mandible is manipulated into a terminal hinge-axis position, the incisors come into edge-to-edge contact, requiring the patient to move the mandible forward to achieve posterior occlusion. The panoramic radiograph showed presumptive signs of crowding in the maxilla. The cephalometric values confirmed retroclined maxillary incisors, proclined mandibular incisors, and normal vertical development. (Figure 14)*



**Figure 13.** Pre-treatment extraoral and intraoral photographs.

The treatment aims to reduce the functional shift of the mandible and increase maxillary arch length, thus permitting eruption of the permanent canines and premolars into a Class I relationship. Bonding brackets to the two maxillary permanent central incisors in combination with banding the two maxillary permanent first molars was used. The device consists, in the first stage, of a round stainless steel arch wire to achieve alignment of upper incisors; an elevation of the occlusion was provided by resin-composite bite plane bonded to lingual side

of the lower incisors. Then, an open-coil spring was compressed against the molar tube to push the incisors labially. So, the supernumerary incisor was extracted for the recovery of the lower incisor. (Figure 15)

The total active treatment period was about 6 months and follow-up appointments were scheduled every 4 weeks. Upon completion of treatment, the anterior crossbite was corrected, the molar relationships were restored to Class I. Advancing the maxillary incisors labially normalized the overjet and allow the mandible to close into a Class I without the anterior shift. Finally the treatment improved maxillary lip posture and facial appearance (Figure 16) Both skeletal and dento-alveolar effects of interceptive treatment are illustrated in Figure 15; the wits appraisal is a leading indicator of re-equilibration of maxillomandibular relationship (AOBO=0mm). (Figure 17)

The case was followed up out of retention 6 months later. Stable anterior and posterior relationships were evident, and continued spontaneous alignment of the mandibular incisors was noticed. (Figure 18)

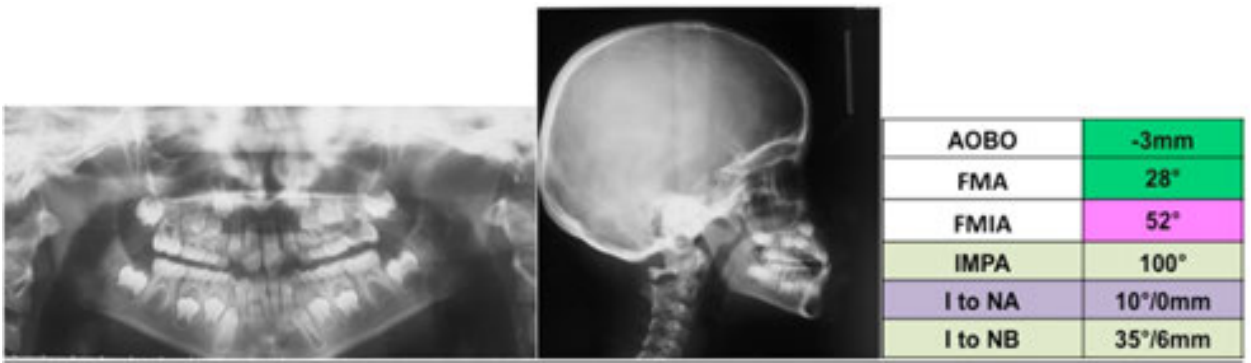

Figure 14. Pre-treatment radiographs.

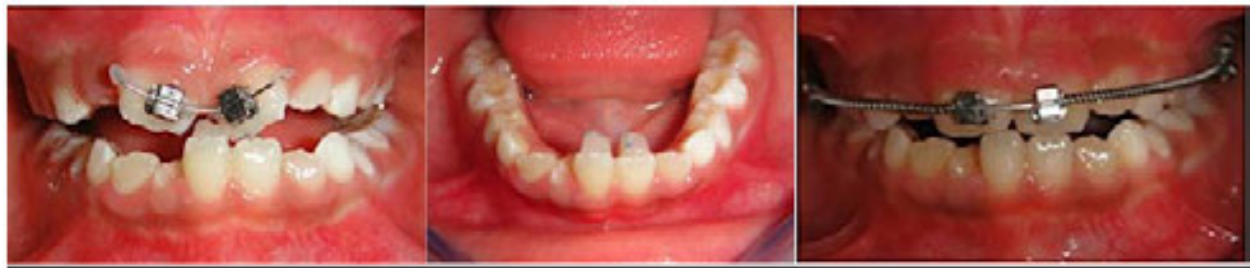

Figure 15. Treatment progress.

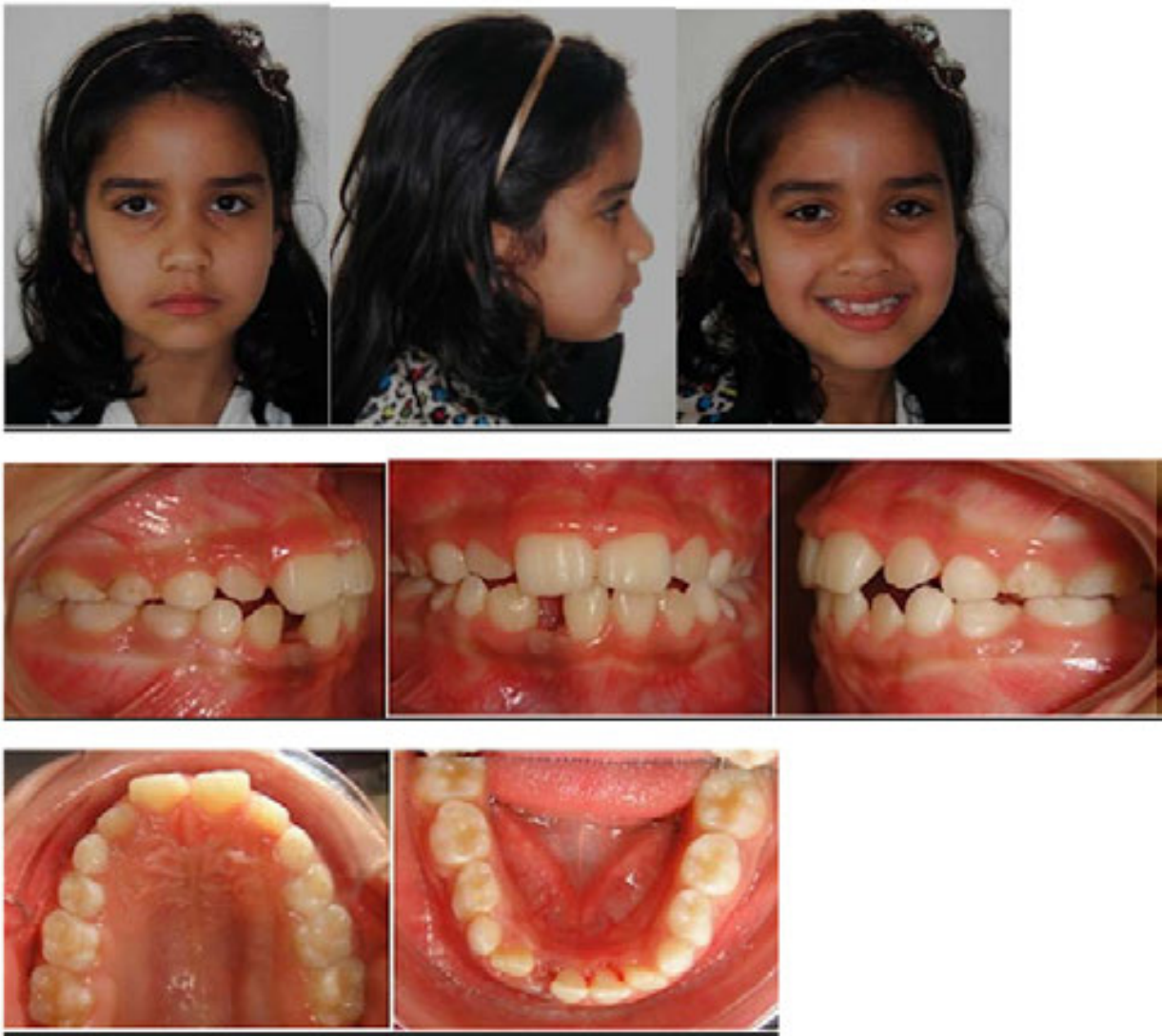

Figure 16. Extraoral and intraoral photographs after anterior crossbite correction.

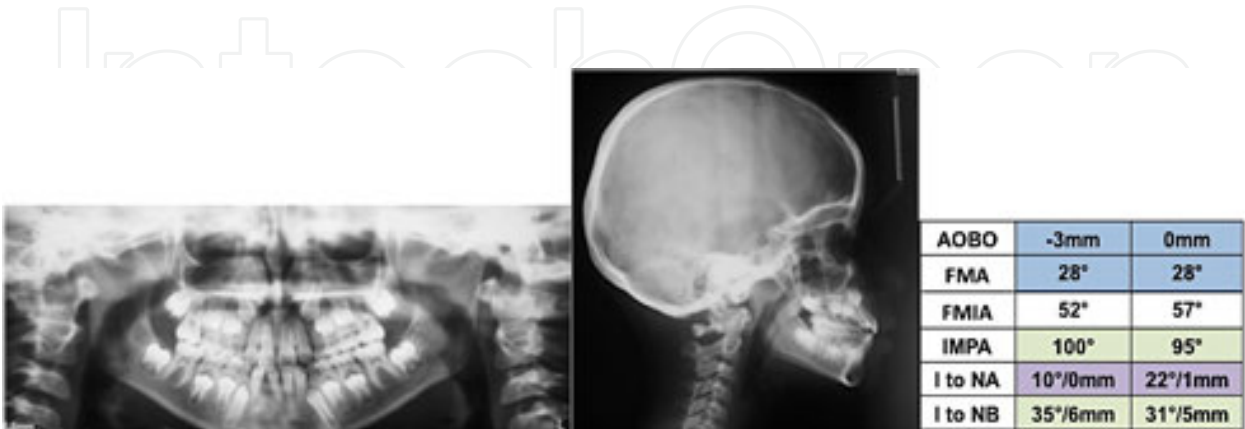
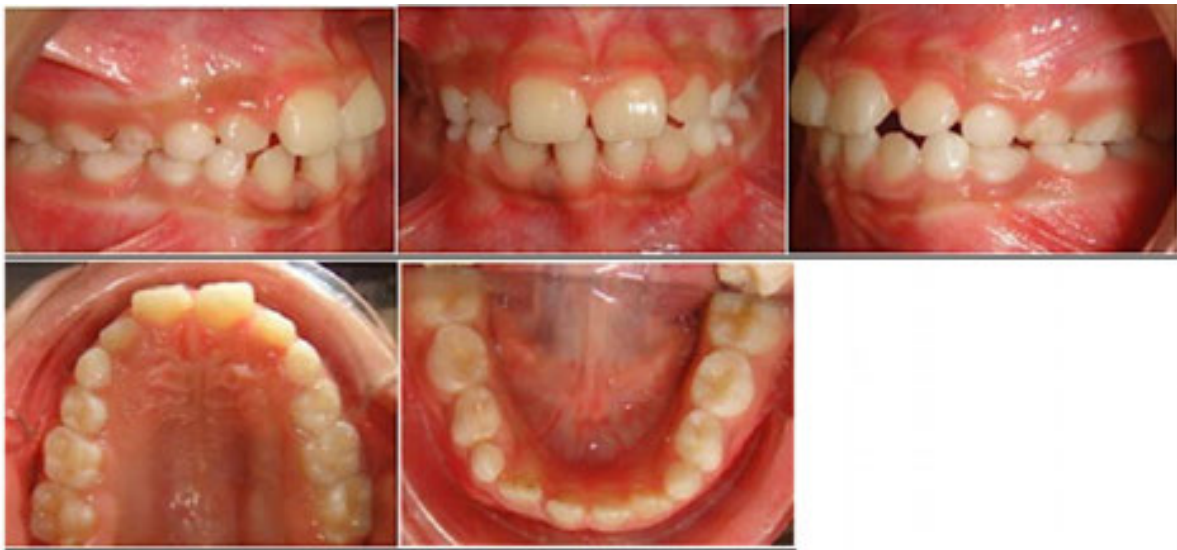

Figure 17. post-treatment radiographs.



**Figure 18.** Six months post-treatment intraoral photographs.

## 5.2. Case N° 2

A 9-year-old boy consulted regarding his anterior bite that causes a concern for his parents. On extraoral examination, a slight retrusion of the upper lip was noticed, and smile betrays the anterior reversed occlusion. Intraoral examination revealed a mixed dentition stage, with erupted upper and lower permanent incisors and first molars. All maxillary incisors were in crossbite with the mandibular incisors. The molar relation on both sides was developing class III malocclusion (Figure 19). There was no family history of class III malocclusion. On assessment guidance of the mandible on closure, a functional shift of the mandible was seen. An occlusal prematurity in relation to erupting 41 and retroclination of maxillary incisors appeared to be responsible for the present functional shift [Figure 20]. Based on the above findings, a diagnosis of pseudo class III malocclusion was made and the treatment aimed at eliminating the anterior interlock. It was expected to position the mandible backward and promote maxillary growth with standard edgewise appliance.

Bite opening and bracket and tube bonding to the four maxillary incisors and the two maxillary permanent first molars (2 \* 4 fixed appliance) were used to resolve an anterior crossbite in combination with open coil spring and Class III elastics (Figure 21). After leveling and alignment stage, crossbite was corrected in 4 months. After six months of treatment, significant improvement in the patient's profile and smile was noted. An increase in upper incisor inclination was obtained, and reduction in lower incisor inclination resulted in normalized overbite and overjet. So, for more security, we opted for a bonded maxillary retainer (Figure 22). The effects observed were attributed to the correction of interlocking and also to the guidance of the mandible in a normal backward position. The intraoral examination after a 1-year follow-up revealed a normal overjet and overbite relation [Figure 23].

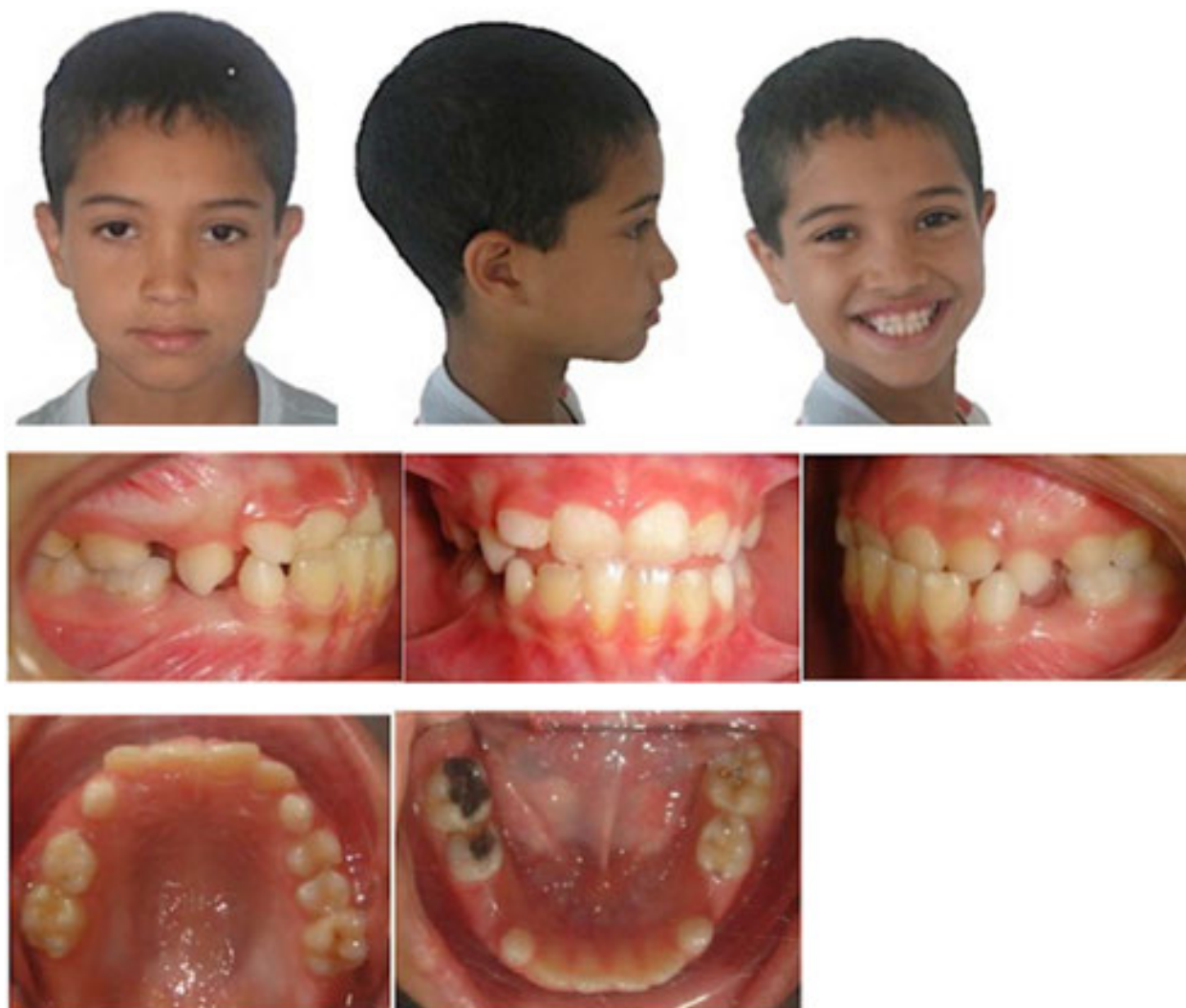

Figure 19. Pre-treatment extraoral and intraoral photographs.

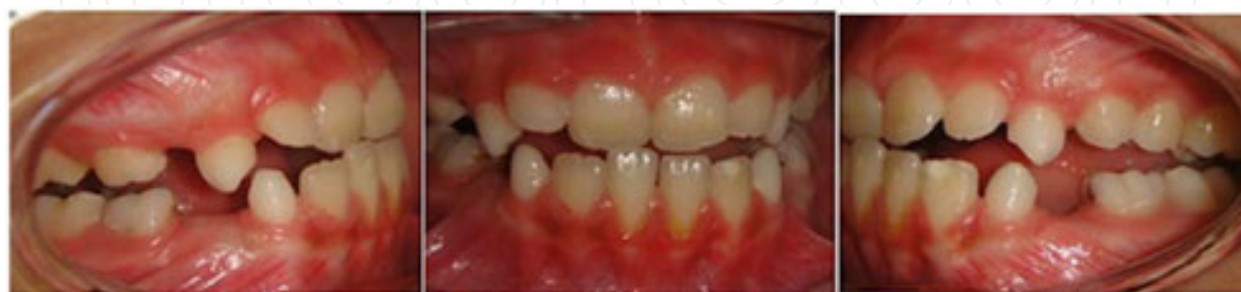
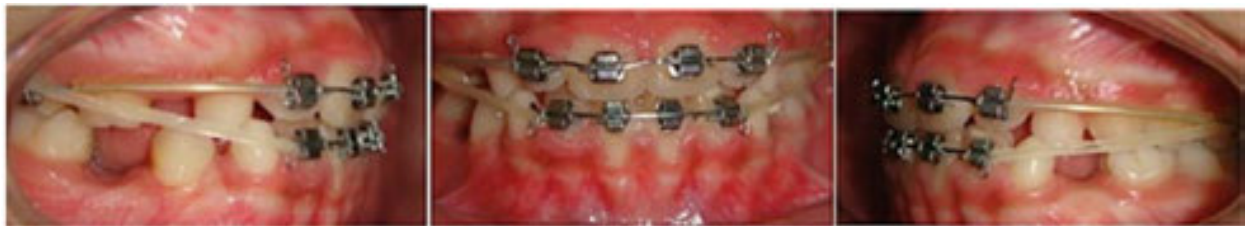
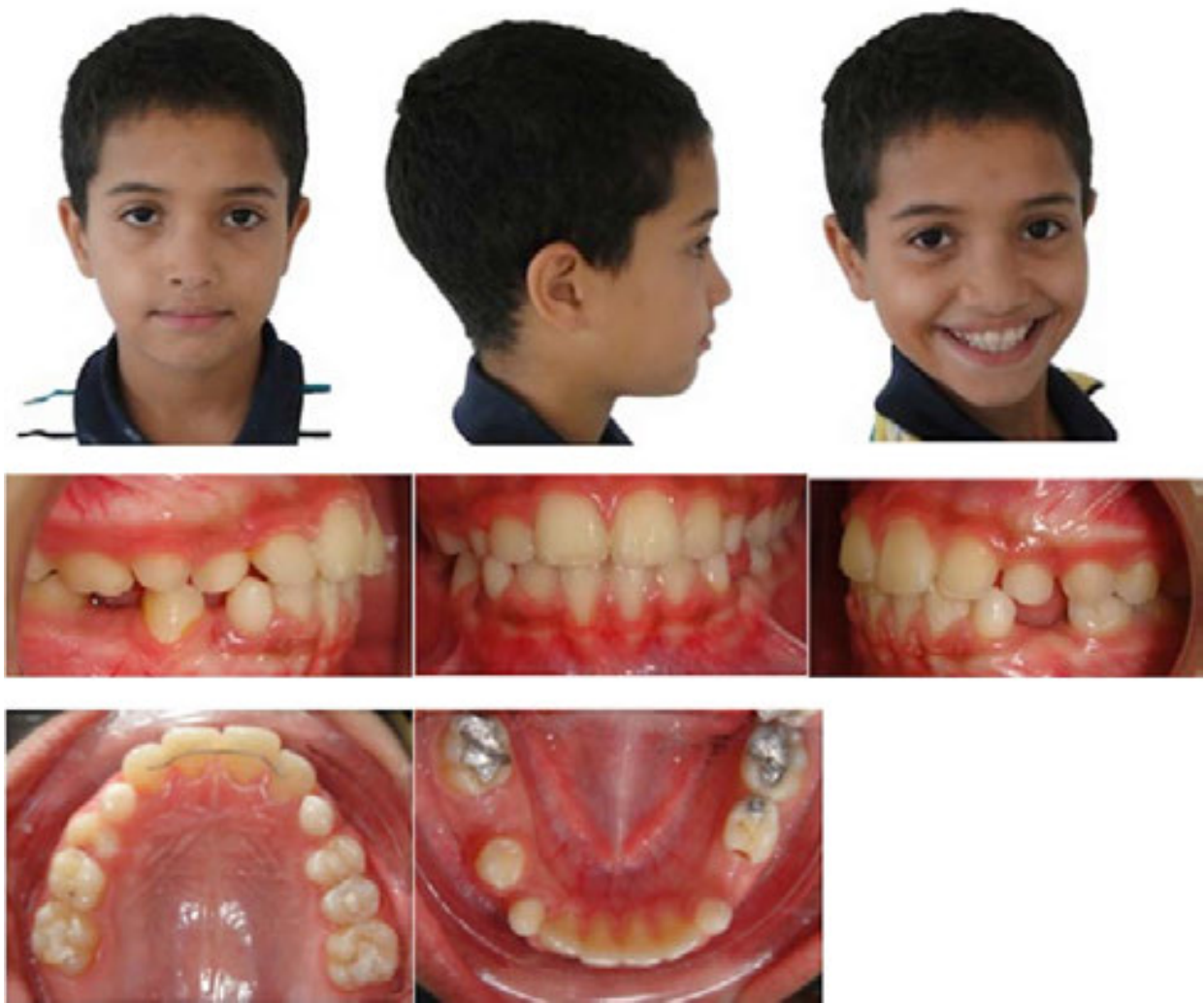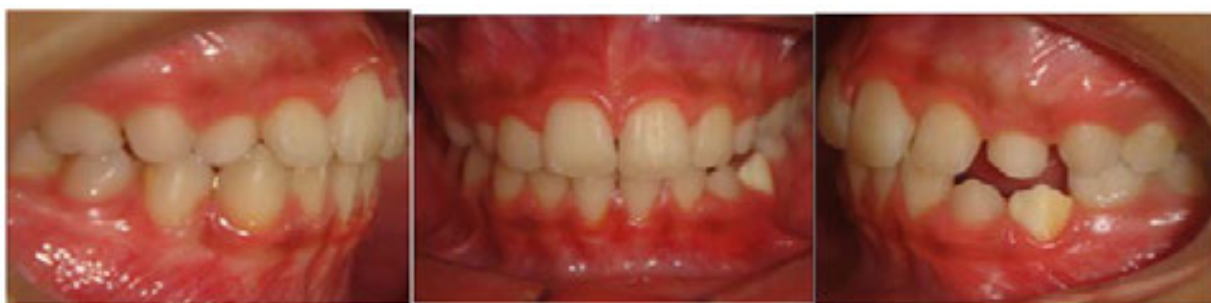Figure 20. Pre-treatment intra-oral photographs in centric occlusion.



**Figure 21.** Upper and lower 2\*4 appliances in combination with Class III elastics, used for advancing maxillary incisors into desired overjet.



**Figure 22.** Extraoral and intraoral photographs after anterior crossbite correction.



**Figure 23.** Year-follow-up

## 6. Discussion

Anterior crossbite is a major concern for both parents and clinicians. It requires early intervention to achieve a normal occlusion that is morphologically stable in the long term and functionally and esthetically acceptable. However the fundamental goal of interceptive approach is to improve the growth.

The pseudo-Class III malocclusion involves both permanent teeth and deciduous dentition. Some practitioners prefer to wait for the permanent maxillary incisors to erupt before initiating therapy due to the natural tendency of teeth to erupt in a lingual position during dental arch development. And the possible spontaneous correction of functional deciduous anterior crossbites occasionally corrects themselves spontaneously. However, the optimum period for successful treatment suggested being between the ages 6–9 years [10].

Interceptive orthodontic procedures must be relatively simple and inexpensive treatment approaches that target developing malocclusions during the mixed dentition. In cases of pseudo-Class III malocclusion, early intervention has a highly favorable cost-benefit ratio, and treatment usually takes less time [18]. So, it was suggested that early management of anterior crossbite in these kind of case be successful in 100% of treated young patients [17].

The various treatments suggested in the literature for correction of anterior crossbite include different appliances, both fixed and/or removable with heavy intermittent forces (inclined bite plane, tongue blade) or light-continuous forces (removable appliance with auxiliary springs). A recent systematic review disclosed a wide variety of treatment modalities, more than 12 methods, in use for anterior crossbite correction [19]. However, strong evidence in support of any treatment technique is lacking [8].

Removable appliances have been shown to be effective in the correction of anterior crossbite and elimination of mandibular displacement. Nonetheless, the major inconvenience of these tools is the necessity of an absolute cooperation on the part of the patient due to a high risk of loss or repetitive fractures.

A modified quad helix appliance has proved to be an economical alternative, which is easy to fabricate and causes minimal patient discomfort [9].

Other alternative therapies that may correct skeletal problems in young patients have been shown to be effective in functional Class III, with significant changes in the craniofacial complex, including the use of protraction headgear, chin cup, and Frankel III [10, 15].

The face mask should be advised during the deciduous dentition phase in cases of minor skeletal component. This produces protrusive forces to the maxilla and maxillary dentition.

The literature demonstrates that functional appliances are effective in anterior crossbite correction. This approach prevents unfavourable growth especially mandibular protrusion, and eliminates traumatic occlusion. Giancotti suggested the therapeutic use of a Balters' Bionator appliance. The patients wore the bionator approximately 15 hours daily for a period of 60-90 days. However, the cooperation of the patient is essential for the success of this approach [10].

Bonding brackets to the four maxillary incisors in combination with banding or bonding the two maxillary permanent first molars is one of the methods used for the correction of anterior crossbite with fixed appliances. It has been reported to effectively manage anterior crossbite in the mixed dentition [20]. For some authors, the main reason for using the fixed appliance treatment seems to be misalignment, [17] For others, this method has the advantages of requiring little or no patient compliance or alteration of speech [4].

One of the benefits claimed for early treatment with fixed appliance is that space is provided for the eruption of the canines and premolars in the upper arch, allowing the erupting dentition to be guided into a Class I relationship in centric relation [17].

There is disagreement about the need for a second phase of treatment during adolescence, A retrospective cohort study of interceptive orthodontic treatment indicate that interceptive orthodontic treatment is effective for improving malocclusion, but does not produce finished-quality results without a second phase of treatment in the permanent dentition [3]. Several studies have suggested that systematically planned interceptive treatment in the mixed dentition might contribute to a significant reduction in treatment need between the ages of 8 and 12 years, In a Finnish study, the need was reduced significantly from 8 to 12. However, Only 25% of these patients required a second stage of treatment after eruption of the remaining permanent teeth [21].

With respect to stability of such approach, it was reported, in follow-up study, that in young patients diagnosed with pseudo Class III malocclusion and treated early with a fixed appliance, the overjet was corrected, and the treatment result was maintained in the long term (for more than 5 years after active treatment) [17]. So, it was suggested that either fixed or removable appliances with similar long-term stability could successfully correct anterior crossbite [22].

A systematic review of early correction of anterior crossbite has highlighted the lack of high quality evidence, and concludes that despite the low level of evidence, there is similarity in the length of time it took to successfully treat anterior crossbites using similar treatment modalities [19].

The therapeutic use of a fixed appliance is suggested in two case reports of subjects with anterior crossbite in mixed dentition. Careful clinical evaluation of Class III malocclusion

checked anterior and posterior dental relationships with the mandible in centric relation. The prognosis was favorable for the treatment and post-retention results to be stable in the future. The two patients achieved a positive and often slightly overcorrected overjet during the active treatment after six months of treatment.

As early correction of anterior crossbite was undertaken in the growing child, it is important to evaluate post-treatment changes. The overjet remained stable because the corrected upper incisors were kept in place by normalizing the overjet and overbite.

## 7. Conclusion

Interceptive orthodontic treatment aims to recognize and eliminate potential irregularities and malpositions in the developing dento-facial complex. Early treatment of Class III malocclusion is one of the most challenging problems confronting orthodontists. The treatment should be carried out as early as possible with the aim of permitting normal growth, and improving facial attractiveness and psychosocial well being of children.

In spite of its weak prevalence, functional Class III must be prematurely detected and treated to prevent a functional anomaly from becoming a skeletal anomaly. A well-conducted clinical and radiographic examination, highlighting skeletal Class I, allows judicious and appropriate therapeutic choices.

The optimum treatment timing and the treatment modalities influence therapy. It is believed to have many benefits, including a better use of the patient's growth potential, a lower risk of progression to a true Class III malocclusion, and more stable results.

## Author details

Sanaa Alami<sup>1\*</sup>, Hakima Aghoutan<sup>1</sup>, Farid El Quars<sup>1</sup>, Samir Diouny<sup>2</sup> and Farid Bourzgui<sup>1</sup>

\*Address all correspondence to: [alamisana89@gmail.com](mailto:alamisana89@gmail.com)

1 Department of Dento-facial Orthopedic, Faculty of Dental Medicine, Hassan II University of Casablanca, Morocco

2 Chouaib Doukkali University, Faculty of Letters & Human Sciences, El Jadida, Morocco

## References

- [1] Le Gall M, Philip C, Bandon D. The functional mandibular prognathism. Archives de pédiatrie. 2009; 16; 77–83.

- [2] Keski-Nisula K, Lehto R, Lusa V, Keski-Nisula L, Varrela J. Occurrence of malocclusion and need of orthodontic treatment in early mixed dentition. *Am J Orthod Dentofacial Orthop.* 2003; 124:631-8.
- [3] King GJ, Brudvik P. Effectiveness of interceptive orthodontic treatment in reducing malocclusions. *Am J Orthod Dentofacial Orthop.* 2010;137;18-25.
- [4] Bindayel NA. Simple removable appliances to correct anterior and posterior crossbite in mixed dentition: Case report. *The Saudi Dental Journal.* 2012; 24, 105–13.
- [5] Kumar A, Tandon P, Singh GP. Management of pseudo Class III malocclusion-synergistic approach with fixed and functional appliance. *Int J Orthod Milwaukee.* 2013; 24 (2) 41-4.
- [6] Randrianarimanarivo HM, Rasoanirina MO, Andriambololo-Nivo RD, Ralison G, Rakotavao JD. Interception de la pseudo-prognathie mandibulaire: comparaison de la plaque en “V” et du plan incliné antéro-inférieur. *Revue d’odontostomatologie malgache en ligne.* 2011; 3; 29-38.
- [7] Langlade M. *Diagnostic orthodontique*, Paris : Maloine ;1981.
- [8] Wiedel AP, Bondemark L. Stability of anterior crossbite correction: A randomized controlled trial with a 2-year follow-up. *Angle Orthod.* 2014.
- [9] Kumar A, SA, Shetty KS, Prakash AT. Pseudo-Class III: Diagnosis and Simplistic Treatment. *J Ind Orthod Soc.* 2011; 45 (4) 198-201.
- [10] Giancotti A, Maselli A, Mampieri G, Spanò E. Pseudo-Class III malocclusion treatment with Balters’ Bionator. *Journal of Orthodontics.* 2003; 30; 203–15.
- [11] Ngan P1, Hu AM, Fields HW Jr. Treatment of Class III problems begins with differential diagnosis of anterior crossbites. *Pediatr Dent.* 1997 Sep-Oct;19(6):386-95.
- [12] Jirgensone I, Liepa A, Abeltins A. Anterior crossbite correction in primary and mixed dentition with removable inclined plane (Bruckl appliance). *Stomatologija.* 2008;10 (4):140-4.
- [13] Park JH. Orthodontic correction of Class III malocclusion in a young patient with the use of a simple fixed appliance. *Int J Orthod Milwaukee.* 2012 ; 23 (3 43-8.
- [14] Arman A, Ufuk Toygar T, Abuhijleh E. Profile Changes Associated with Different Orthopedic Treatment Approaches in Class III Malocclusions *Angle Orthodontist.* 2004; 74 (6) 733-40.
- [15] Negi KS, Sharma KR. Treatment of pseudo Class III malocclusion by modified Hawleys appliance with inverted labial bow. *Journal of Indian Society of Pedodontics and Preventive Dentistry.* 2011; 29 (1) 57-61.
- [16] Le Gall M, Philip C, Salvadori A. Early treatment of Class III malocclusion. *Orthod Fr.* 2011;82 (3) 241-52.

- [17] Hägg U, DDS, Tse A, Bendeus M, Rabie ABM. A Follow-up Study of Early Treatment of Pseudo Class III Malocclusion. *Angle Orthodontist*, Vol 74, No 4, 2004.
- [18] Bowman SJ. A Quick Fix for Pseudo-Class III Correction. *J. clin Ortho*. 2008; 42(10) 1-7.
- [19] Borrie F1, Bearn D. Early correction of anterior crossbites: a systematic review. *J Orthod*. 2011; 38(3) 175-84.
- [20] Dowsing P1, Sandler PJ. How to effectively use a 2 x 4 appliance. *J Orthod*. 2004; 31(3) 248-58.
- [21] Gu, Y.; Rabie, A.B.; and Hägg, U. Treatment effects of simple fixed appliance and reverse headgear in correction of anterior crossbites, *Am. J. Orthod*. 2000.117:691-99,
- [22] Wiedel AP, Bondemark L. Stability of anterior crossbite correction: A randomized controlled trial with a 2-year follow-up. *Angle Orthodontist*. 2014.

