

# We are IntechOpen, the world's leading publisher of Open Access books Built by scientists, for scientists

6,900

Open access books available

186,000

International authors and editors

200M

Downloads

Our authors are among the

154

Countries delivered to

TOP 1%

most cited scientists

12.2%

Contributors from top 500 universities



WEB OF SCIENCE™

Selection of our books indexed in the Book Citation Index  
in Web of Science™ Core Collection (BKCI)

Interested in publishing with us?  
Contact [book.department@intechopen.com](mailto:book.department@intechopen.com)

Numbers displayed above are based on latest data collected.  
For more information visit [www.intechopen.com](http://www.intechopen.com)



---

# Vascular Access and New Trends

---

Eirini Grapsa and Konstantinos Pantelias

Additional information is available at the end of the chapter

<http://dx.doi.org/10.5772/59464>

---

## 1. Introduction

Patients suffering from end-stage renal disease (ESRD) treated with renal replacement therapy is a continuously growing population [1–3]. Hemodialysis is the most preferable modality among them [4], making a suitable permanent vascular access (VA) vital for their treatment. The ultimate purpose is the successful creation of a well-functioning, long-lasting VA, capable of delivering adequate dialysis to the patient with the minimum of complications under its appropriate management. In the last years in this field of nephrology, very few changes have taken place. Three types of permanent VA are in use, arteriovenous fistula (AVF), arteriovenous grafts (AVGs), and cuffed central venous catheters (CVCs). Long-lasting survival, adequate blood flow, and low complications rate are necessary characteristics of them. Native forearm AVF best fulfills this criteria and is the first choice of VA, the first native arteriovenous fistula (AVF) described in 1966 by Brescia and Chimino [5]. The second choice is upper arm AVF, followed by AVG and last one cuffed CVC [6–8]. Vascular access dysfunction is responsible for 20% of dialysis patients' hospitalizations in the USA [9], making it one of the most important causes of morbidity [10], while the annual cost of VA creation and maintenance is over 1 billion dollars yearly [11], with arteriovenous graft (AVG) cost be more than fivefold higher than AVF [12]. Thus, VA is called the “Achilles’ heel” of hemodialysis [13].

## 2. History of vascular access

In 1924, Haas [14] carried out the first hemodialysis treatment in humans using glass needles in radial and cubital vein. In 1943, Kolff used venipuncture needles in the femoral artery and vein [15, 16]. Kolff's [17] twin-coil kidney made regular hemodialysis treatments possible in 1950s, making the need of a safe, reliable, long-lasting VA more imperative.

Aubaniac [18], in 1952, described the puncture of subclavian vein as a VA, while, in the 1960s, Dillard, Quinton, and Scribner [19], based on Alwall's experience, developed arteriovenous Teflon shunt inserted into radial artery and cephalic vein. Flexible silicon rubber replaced later Teflon. Based on Seldinger's technique, Shaldon inserted catheters into femoral artery and vein for dialysis sessions in 1961 [20, 21]. Vessels in different sites were used, over time, including the subclavian, jugular, and femoral vein.

Cimino and Brescia [22] described, in 1962, a "simple venipuncture for hemodialysis." Fogarty et al. [23] invented, in 1963, a special designed catheter for thrombectomy and embolectomy with an inflatable balloon at its distal tip. In 1965, the first AVF was created, and 14 more in 1966 when Brescia, Cimino, Appel, and Hurwich published their paper [24]. Sperling [25], in 1967, created an end-to-end anastomosis in the forearm, between radial artery and cephalic vein, in 15 patients, whereas Appell did side-to-side anastomosis. End-to-end anastomosis usually is not the first choice of AVF due to high risk of steal syndrome in aging, diabetic patients of dialysis, but it remains a useful option in revision procedures, although it is correlated with higher mortality risk from infections [26].

Nowadays, artery side-to-vein anastomosis seems to be a standard procedure [27], which began from Rohl et al. [28] in 1968. Girardet et al. [29] and Brittinger et al. [30] in 1970 described their experience with AVG between femoral vein and artery and subcutaneously fixed superficial femoral artery for chronic HD. Brittinger et al. [31] were the first to implant a plastic valve as a vascular access in an animal model, but unfortunately, their efforts did not proceed to a human one. In the early 1970s, Buselmeier et al. [32] developed a U-shaped silastic prosthetic AV shunt with either one or two Teflon plugged outlets, which communicated to the outside of the body. The U-shaped portion could be totally or partially implanted subcutaneously. Subsequently, pediatric hemodialysis patients were extremely favored by this procedure. In 1976, Baker [33] presented expanded PTFE grafts in 72 hemodialysis patients. In the subsequent years, several publications indicated the benefits and the shortcomings of the prosthetic material in question, remaining the primary choice of graft for hemodialysis VA to date. The same year, two authors, Mindich and Dardik, had worked with a new graft material: the human umbilical cord vein [34, 35]. Regrettably so, this material did not succeed in becoming a revolutionary graft material due to its inadequate resistance against the trauma of repeated cannulations and their complications (aneurysm and infection). After the subclavian route for hemodialysis access was firstly introduced by Shaldon in 1961, it was further processed in 1969 by Josef Erben, using the intraclavicular route [36]. In the next 20 years or so, the subclavian vein was the preferred access for temporary vascular access by central venous catheterization. Today, due to phlebographic studies revealing a 50% stenosis or occlusion rate at the cannulation site, subclavian route has been discarded. Subclavian stenosis and occlusion predispose to edema of the arm, especially after creation of an AV fistula [37].

The first angioplasty described by Dotter et al. [38], who introduced a type of balloon, was immensely conducive to the resolution of one of the most significant predicaments in vascular surgery and vascular access surgery.

In 1977, Gracz et al. [39] created the "proximal forearm fistula for maintenance hemodialysis," a variant of an AV anastomosis. An adjustment of this AVF became quite significant in the old,

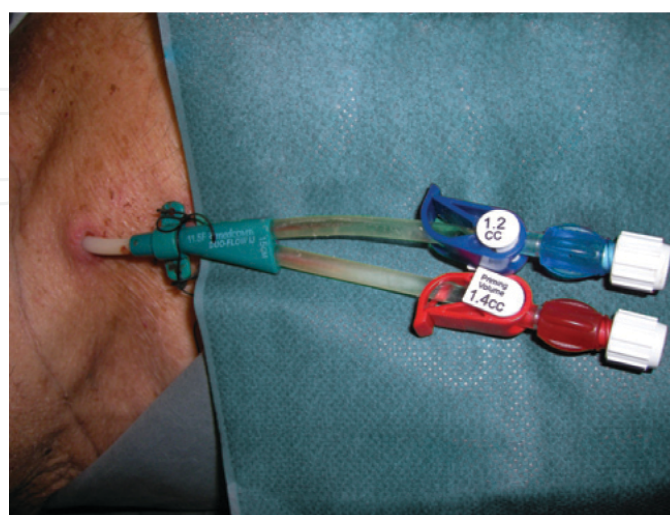
hypertensive, and diabetic patients on the grounds that it allows a proximal anastomosis with a low risk of hyper circulation [40]. In 1979, Golding et al. [41] developed a “carbon transcutaneous hemodialysis access device” (CATD), commonly known as “button,” as a blood access not requiring needle puncture. As a procedure of the third choice, these devices were expensive and never gained widespread acceptance. Shapiro et al. [42] described another type of “button,” a device similar to that developed by Golding.

### 3. Classification of vascular access

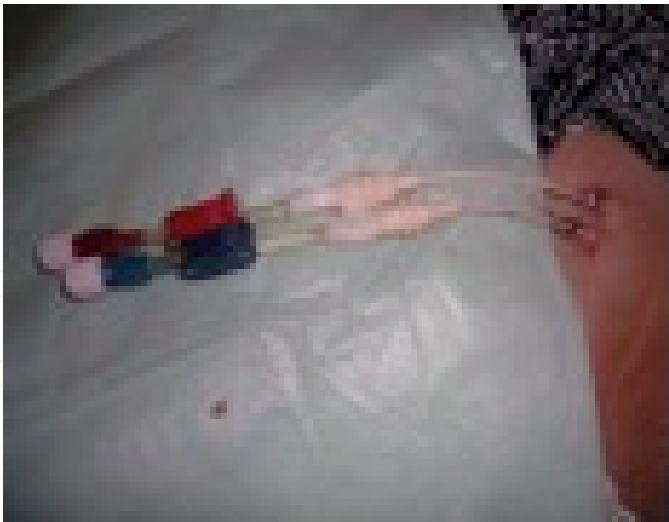Nowadays, and thanks to all above efforts, nephrologists have the ability to choose the most suitable VA for their patients depending on special needs of each one. Based on expected half-life, the first demarcation is of permanent and temporary VAs [43]. Long-term or permanent VAs are called the ones with an expected half-life of more than 3 years, and mainly include AVF [13] and PTFE AVG. VAs with expected half-life of less than 90 days are called temporary VAs and basically are noncuffed double lumen catheters and arteriovenous shunts. The VAs with half-life between the above categories (90 days to 3 years) are the mid-term VA containing tunneled cuffed catheters, port devices and external and internal shunts.

#### 3.1. Acute hemodialysis vascular access

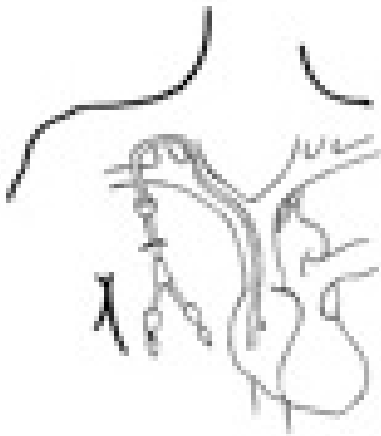Acute hemodialysis is a lifesaving treatment, which needs a VA in order to be carried out. When a permanent VA is not available, the preferred and currently available VA for acute hemodialysis is cuffed tunneled and noncuffed nontunneled hemodialysis catheters (Figures 1–5). The reason is that they can be used immediately and placed relatively easily. For catheter insertion, a modified Seldinger guide wire technique is used, preferably with ultrasound guided assistance for minimizing acute placement complications [44, 45].



**Figure 1.** Noncuffed in jugular double lumen catheter.



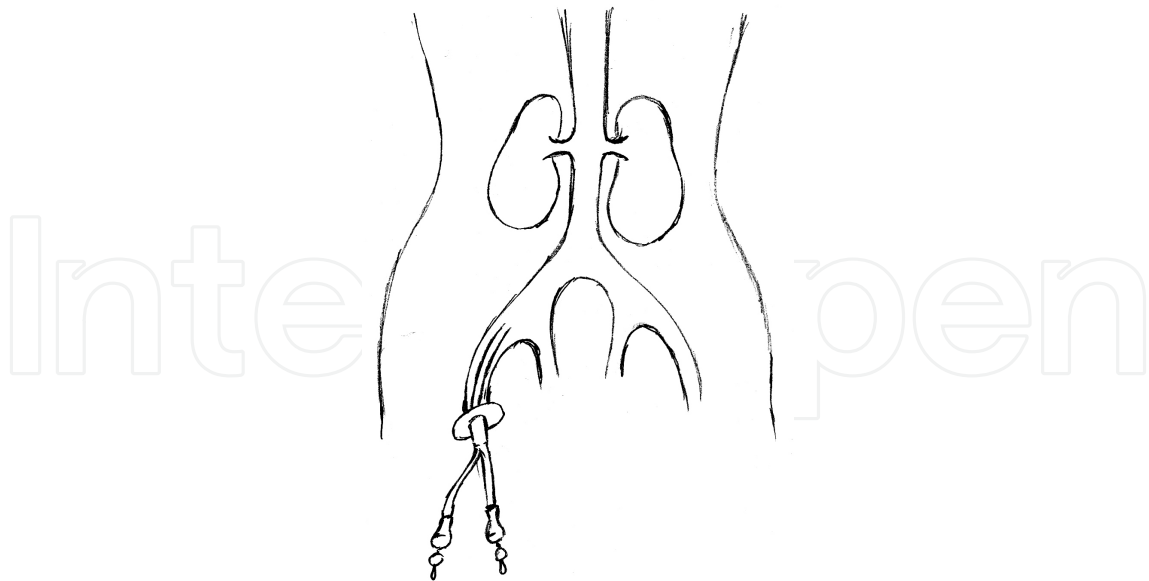
**Figure 2.** Cuffed tunneled in jugular double lumen catheter.



**Figure 3.** Permanent cuffed jugular catheter.



**Figure 4.** Acute noncuffed jugular catheter.



**Figure 5.** Femoral noncuffed catheter.

The most used and feasible are the noncuffed nontunneled catheters with easy insertion and availability for immediate use. They have some specific technical characteristics; they are made of polymers inelastic at room temperature, facilitating the insertion, but unstiffening at inner body temperature in order to be atraumatic for the vessels. The distance between the inflow and the outflow tip of the catheter must be at least 2 cm to lessen recirculation [46].

Central veins such as jugular or femoral can be used as insertion routes of these catheters [47]. Subclavian typically is an option, but due to its higher incidence of complications, such as lung injury, it is used when the others insertion sites are not feasible.

The National Kidney Foundation Dialysis Outcomes Quality Initiative (K/DOQI) 2006 guidelines recommend the radiographical identification of tip placement and any potential complications before catheter use or anticoagulation treatment [48]. Subclavian vein should be avoided for catheter insertion due to high frequency of stenosis and thrombosis.

There are restrictions concerning the use of these catheters such as the blood flow with a maximum pump speed of 300 ml/min, although actual blood flow tops at 250 ml/min, catheters for insertion in femoral vein should be no less of 18 to 25 cm long to minimize recirculation [49, 50]. Their insertion site determines their life use, with the ones in internal jugular vein be suitable for use for about 2 to 3 weeks, while in femoral vein are used for 3 to 7 days in bedridden patients and for a single treatment in ambulatory patients [51]. Nevertheless, according to KDOQI guidelines, the life use of noncuffed, nontunneled catheters must be of a week or less; when hemodialysis treatment will be required for a longer period, the placement of cuffed, tunneled catheters is suggested [48]. Especially in hospitalized patients, triple lumen catheters are placed, using the third lumen for intravenous drugs and fluid administration and for blood drawing. It seems that two and three lumen catheters have similar blood flow and inflections incidence [52]. The leader cause for catheter removal is infectious complications.



### 3.2. Permanent vascular access

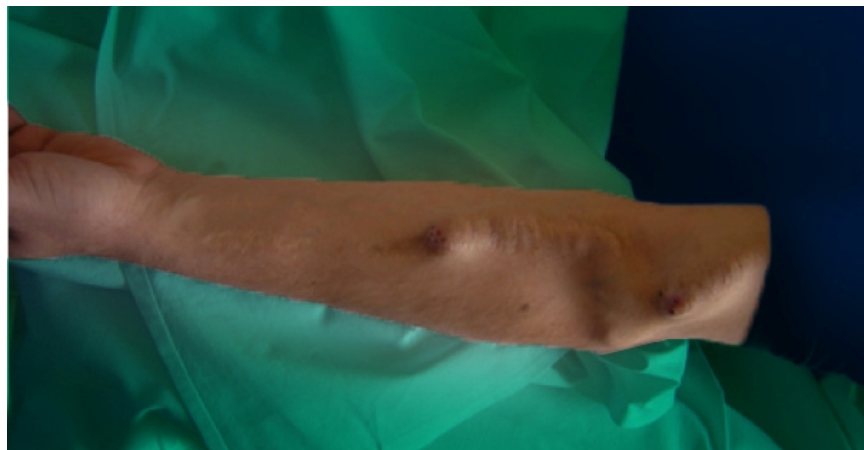
Taking patient-dependent factors into consideration, such as life expectancy, comorbidities, the status of the venous and arterial vascular system, is very important in order to prescribe the appropriate access. Each type of access, such as arteriovenous fistula (AVF), arteriovenous graft (AVG) or TC, has a different effect on circulatory system, and this should be taken into consideration. Also, the duration of their functionality and the risk for infection and thrombosis are important factors to consider. Each type of surgical anastomosis has advantages and disadvantages [53]. Also, it seems that the advantages of an AVF attempt strategy lessened considerably among older patients, particularly women with diabetes, reflecting the effect of lower AVF success rate and lower life expectancy, suggesting that vascular access-related outcomes may be optimized by considering individual patient characteristics [54]. The American Association for Vascular Surgery and the Society for Vascular Surgery, in 2002, for better consultation and understanding between physicians and registration of VA set VA reporting standards in which three components should be listed, structure (autogenous, prosthetic), position and alignment (loop, direct, etc.) [55]. Risk factors such as female gender, age, diabetic nephropathy, dialysis initiation via CVC and inability of VA maturation before HD initiation are responsible for the majority of VA failure. Repetitive VA failures are risk factor for mortality [56]. It seems that early referral to nephrologist and patient's education leads to initiation of dialysis with permanent VA, better metabolic and clinical situation, lower long-term morbidity and higher 2-year survival [57–61]. It is of benefit to the patient to begin hemodialysis treatment via a functional AVF than with a TC [62–64]; however, grafts are a better alternative to TCs, when AVF is not feasible [65]. Patients with bilateral central vein stenosis often require more than one vascular access modality to achieve a “personal access solution.” Native long saphenous vein loops provided the best long-term patency. Expedited renal transplantation with priority local allocation of cadaveric organs to patients with precarious vascular access provides a potential solution [66]. Patients who received either femoral AVG or HeRO VA device experience poor access patency. ESRD patients who receive either of these procedures appear to be at the end stage of available access options [67].

#### 3.2.1. Arteriovenous fistula

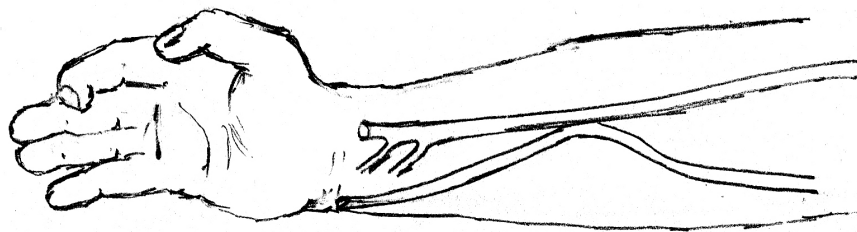
The first choice of VA is AVF, for its longevity and low morbidity and mortality rates [68, 69], low complication incidence for infection (one-tenth of AVGs) and thrombosis (one-sixth of AVGs) [70, 71]. AVFs' primary patency rates at 1 year vary considerably between USA and Europe, with reports from the USA that include diabetic patients be as low as 40–43% [72, 73]. From the study of 748 AVFs in diabetic patients over 5 years, Konner et al. showed a primary patency rate of 69–81% [74], while Chemla et al. had a rate of 80% at 22 months in 552 radiocephalic AVFs in 153 patients over a 4-year period [75]. Hemodialysis patients with AVF have lower mortality and that seems to be attributed not only to decreased incidence of infections and VA dysfunctions but also to other factors, such as LVEF increase and blood pressure and arterial stiffness reduction, as Korsheed et al. [76] showed.

Based on the way of their creation, three types of AVFs can be identified. The first type belongs to the AVFs where an artery and a vein are connected in their natural position, with a side-to-

side or side-artery-to-vein-end anastomosis. In the second type, a vein is connected to an artery in end-to-side form, after its metathesis, to connect a further distance or surface the vein to facilitate cannulation; a tunnel creation is required for vein's new positioning. When a vein is connected to an artery end-to-end after it is removed from its anatomical location, we have the third type of AVF [77] (Figures 6–9). The end-to-end technique is abandoned nowadays since it leads to advanced risk for ischemia and thrombosis. Vein end to artery side anastomosis is the most common technique. The first option for the primary AVF is the radial-cephalic. Distal forearm ulnar-basilic has similar secondary patency rate to it and is the best alternative when the first one is not feasible [78]. Stenosis due to technical problems like false surgical cut of vein leads to dysfunctional VA. Complications such as heart failure or steal syndrome may result from a more proximal, big arterial anastomosis [77]. Local anesthesia is usually effective for AVF creation, and the morbidity of the procedure is low. AVF requires time after its creation for maturation before cannulation for at least 14 days according to DOPPS (Data from the Dialysis Outcomes and Practice Patterns Study). During the period of maturation, the blood flow and the vessel size increase over time in 8–12 weeks, and the initial blood flow is in a range of 200–300 ml/min [64].




**Figure 6.** Forearm AVF.



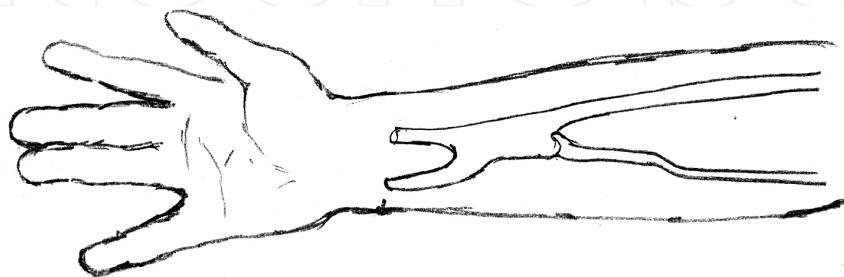
**Figure 7.** Side-to-side forearm AVF.

The placement of AVFs should be initiated when the patient reaches CKD stage 4, or within 1 year of the anticipated start of dialysis. In their recent study, Hod et al. [79] suggested that





**Figure 8.** End-to-end forearm AVF.



**Figure 9.** Side-to-end forearm AVF.

creating AVF more than 6 to 9 months before initiating dialysis in elderly may not associate with better AVF success rate. In order to increase the possibilities of a well-functioning AVF's creation and to minimize the complication, a physical examination must be done prior to procedure to identify any differences in blood pressure between the upper extremities [80] and the presence or lack of a well-developed palmar arch to avoid steal syndrome in case of using the dominant artery for AVF creation [81].

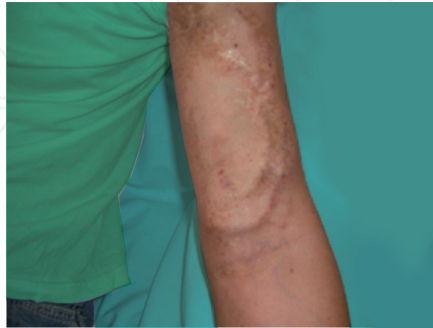Additional information before the creation of AVF can be given with ultrasound of the vessels; their diameter is closely correlated with surgery success with a size of 2 mm and more leads with fruitful maturation [80], in contrast of a size of 1.6 mm and less, which predispose to failure [82]. The upper extremity AVF is the preferred access for hemodialysis, the duplex ultrasound identifies suitable arteries and veins for its successful creation, while early detection and intervention can save the fistula when complications occur [83]. Uzun et al. [84] showed that autologous saphenous vein can be preferably chosen as a prosthetic hemodialysis access graft due to its higher primary and secondary patency and lower complication rate and cost when compared with PTFE grafts. According to the vascular access guidelines of KDOQI, a well-functioning AVF has blood flow over 600 ml/min, with a diameter greater than 6 mm, and is lying less than 6 mm from the surface in a depth between 5 and 10 mm. When an AVF's maturation progresses successfully, then rapidly after surgery blood flow increases from baseline values of 30 to 50 ml/min, reaching 200 to 800 ml/min within 1 week; after 8 weeks, blood flow is over 480 ml/min [85, 86]. The AVFs must be evaluated 4–6 weeks after placement; experienced examiners (e.g., dialysis nurses) can identify nonmaturing fistulas with 80% accuracy [87]. Patients with newly placed AVF are advised for hand squeezing exercises to increase the rate of fistula maturation, such as squeezing a ball, bicep curls, and finger tips

touches resulting to fistulae dilation [88, 89]. Far Infrared therapy, which is a form of heat therapy, has been implicated in improvement of endothelial function and hemodynamics in coronary arteries, probably through up-regulating endothelial nitric oxide synthase (eNOS) expression in arterial endothelium, leading to improved cardiac function in patients with chronic heart diseases. Repeated leg hyperthermia using FIR has been shown to reduce oxidative stress in bed-ridden type II diabetics and may positively influence the complex process of AVF maturation, improving both primary and secondary patency rates [90, 91]. Jennings et al. [92] published a trial, which showed that Venous Window Needle Guide, a subcutaneously placed hemodialysis cannulation device, is safe and effective in facilitating AVF cannulation for patients with an otherwise mature but noncannulatable access. Strozecki et al. described a case report of a 65-year-old female patient who had several hemodialysis sessions by cannulation of dilated collateral abdominal veins with dialysis needles, as an unconventional vascular access for HD in case of central vein occlusion [93]. Humerobasilic and radiocephalic AVF are the two VA types with the most functioning longevity, although in radiocephalic AVF, there is high initial failure rate [94]. It is the preferable VA due to its longevity, low incidence of complications, and easy cannulation [95–97]. In case of failure of radiocephalic AVF creation, the second most preferable VA is brachiocephalic AVF, which comes first in diabetic patients, in whom the inadequacy of vessels for radiocephalic AVF is usually found [98] with a reported 4-year patency of 80% [99]. According to a study of Rondriguez et al., brachiocephalic AVF has a lower survival than radiocephalic. Four years after its creation, just over 50% of the patients have patent AVF and about 30% after 8 years. Failure at first VA increases the risk for following failure, while successful development of the first VA, at about 60% of patients, does not lead to subsequent failure. Diabetes and female gender seem to be risk factors to VA failure [94].

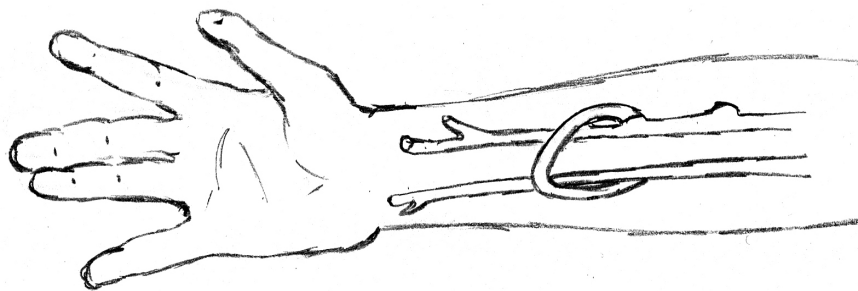
### 3.2.2. Arteriovenous graft

In the USA, AVGs (Figures 10–12) are the most common type of VA that is used for hemodialysis [100]. However, they last less than AVFs and have more complications such as infections and thromboses [70]. Recent technological advances using tissue-engineered AVGs have shown promise for patients receiving hemodialysis and their potential to provide an attractive, viable option for vascular access [101]. Grafts present a second choice of VA when AVF is not possible to be performed because of vascular problems [102]. AVGs have lower risk of nonmaturation in lower time [103]. They can be placed in the forearm, the upper arm and the thigh, when upper-extremity options are exhausted [104] and they can have a straight, curved or loop configuration. Axillary loop arm graft yields acceptable early patency rates in specific patients with vascular problems [105]. Another advantage is that AVGs may offer a large surface for cannulation. Some types of AVGs such as PTFE AVGs can be cannulated immediately after their placement, according to some studies, although it is preferable to wait for about 2 to 3 weeks for the first cannulation [106, 107]. However, the usual time for a functional graft is 2 to 3 weeks in order to reduce the post surgical edema and the perigraft hematoma and seroma [108]. Karatepe et al. [109] presented a novel polycarbonate urethane nanofabric graft, produced by electrospinning technology, which had self-healing features that avoid seroma formation and allow puncturing within 48 hours. It had good 12-month primary

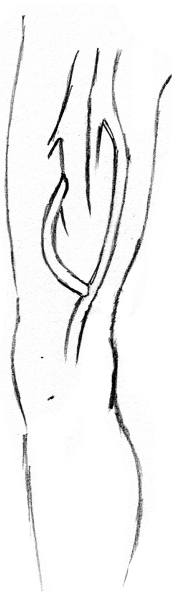
and secondary patency rates and substantially lowers infection rates. Early experience with GORE Acuseal is encouraging with patency and bacteremia rates at least comparable to standard polytetrafluoroethylene grafts, permitting cannulation within 24 hours of insertions and line avoidance in the majority of patients [110].



**Figure 10.** Upper arm AVG.



**Figure 11.** Looped forearm AVG.



**Figure 12.** Straight femoral AVG.

### 3.2.3. *Tunneled hemodialysis catheter*

TCs (Figures 2 and 3) have higher mortality risk than AVFs or AVGs; thus, they are used when the creation of the latter is not feasible [111]. There are several reasons that lead to the inability for AVF or AVG creation, such as multiple vascular surgeries, which lead to vascular thrombosis, or when patients have severe peripheral vascular disease or very low cardiac output. TCs are more frequently encountered in pediatric and very old patients. They can also be used as a bridge until AVF or AVG maturation [111]. Their use remains very high during the first year of HD care and is associated with high mechanical and infection rates [112]. The incidence of AVFs has been effectively increased since the “fistula first” has been developed [113], although it is accompanied with an increase in TCs, especially those used as a bridge until the maturation of an AVF [100]. Nonetheless, DOPPS shows an increasing use of TCs for the period 1996 to 2006 in many countries [114], which is in accordance with our data of 2011, which showed increased prevalence of TCs in female hemodialysis patients [115]. It is also signified that it is more likely for a patient to have permanent VA (AVF or AVG) than TC if he is at a center with experienced vascular surgery department successfully creating permanent VA in diabetic, older women and early AVF cannulation practice (within 4 weeks from its formation) [114].

They do not last as much as the others types of VA, and they have higher complication rates such as infections. There are studies revealing that CVCs are colonized within the first 10 days of placement; however, the catheter’s lumen colonization does not equal to positive blood cultures or clinical signs of bacteremia [116]. The guide-wire change or the complete removal of catheter does not affect the outcome of the infection treatment [117]. Power et al. [118] with their study of 759 TCs showed that the appropriate management of catheters can give functional and complication results similar to AVGs. In their study, survival rates were 85%, 72%, and 48% at 1, 2, and 5 years, respectively, while the infection rate was 0.34 per 1000 catheter-days. Although earlier studies showed a lower risk of catheter-related bloodstream infections with internal jugular TCs compared to femoral, recent studies show no difference between the three sites [119, 120].

Transhepatic hemodialysis catheters seem to be a viable alternative option with low morbidity rates [121]. Another safe and effective long-term access is translumbar inferior vena cava [122]. Retrograde femoral vein catheter insertion is a newly applied lifesaving HD vascular access approach for selected ESRD patients with no available HD vascular access at the ordinary sites with accepted HD adequacy, but it needs more evaluation and studies [123].

## 4. Children’s hemodialysis vascular access

Renal replacement treatment in children varies. According to North American Pediatric Renal Trials and Collaborative Studies (NAPRTCS) registry of patients reaching ESRD in pediatric centers, 25% submitted preemptive renal transplantation, 50% joined in peritoneal dialysis, and 25% started hemodialysis [124, 125]. The preferable therapy is transplantation and in perspective of a rather short time on HD, children receive maintenance HD through an

indwelling CVC [126]. In the USA, no more than 800 pediatric patients receive maintenance HD therapy, while the majority of smaller patients, less than 10 kg or 2 years old, receive peritoneal dialysis [127–129].

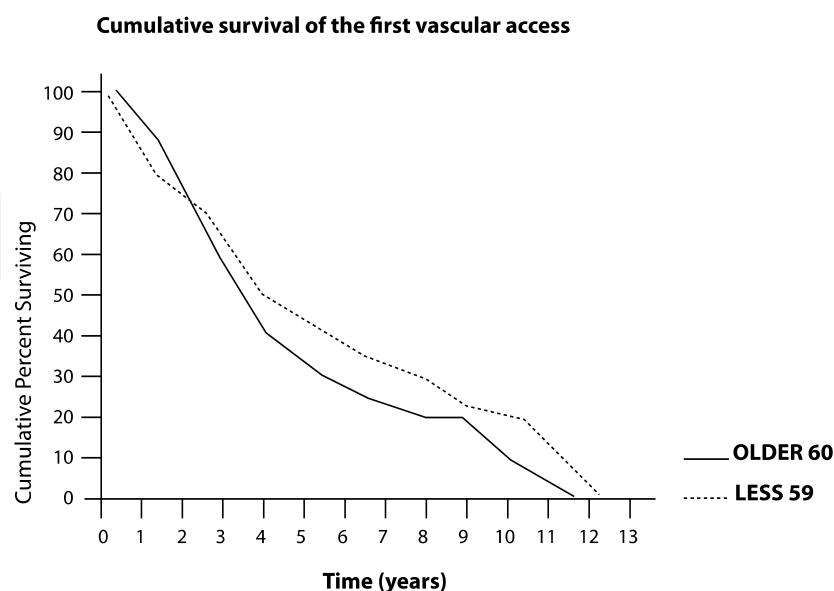
However, hemodialysis can be performed successfully in infants and very young children, as well [130]. An evaluation of the vasculature of children who will undergo hemodialysis will indicate the appropriate vascular access. Because of the size of their vessels, there is limited use of AVF in children, although there is an effort to make nephrology society to consider AVF as the best access in pediatric HD patients [131]. According to a 2008 pediatric registry (NAPRTCS) annual report, vascular access for hemodialysis included external percutaneous catheter in 78% of patients, internal AV fistula in 12%, and internal and external AV shunt in 7.3 and 0.7%, respectively [125]. K/DOQI has encouraged greater use of AV fistulas in larger children receiving hemodialysis who are not likely to receive a transplant within 12 months, with a goal of achieving more effective dialysis with fewer complications than the ones occurring with catheters. Patient's size determines catheter size. An 8-F dual lumen catheter is well tolerated in 4- to 5-kg children, and as the child's size increases, a vascular access of larger volume can be placed [132]. Blood flow in pediatric patients varies due to the catheter size, which depends on the child's size. In most of the patients, a recommended blood flow of 3 to 5 ml/kg/min is acceptable [133], providing adequate dialysis with Kt/V equal or greater than 1.2. A recent study by Fadel et al. found a significant correlation between serum soluble vascular cell adhesion molecule 1 and ESA doses in thrombosed AVF, and this could have clinical significance after further investigation [134].

## 5. Vascular access morbidity and mortality

Studies have shown a mortality risk dependent on access type, with the highest risk associated with central venous dialysis catheters, followed by AVGs and then AVFs [135–137]. Recently Hicks et al. [137] stated that this benefit of AVG over TCs may not apply to younger (18–48 years) or older (over 89 years) age-groups. Additionally, patients who had a catheter as the first VA had more complications and higher mortality [138]. The same results have been presented by Ng et al. [139], who examined hospitalization burden related to VA type among 2635 incident patients. The risk for vascular access complications is increased in intensive HD, with overall reported rates being lower in patients with AVF [140]. The CHOICE study examined mortality based on access type in 616 hemodialysis patients for up to 3 years of follow-up. Increased mortality was observed in CVCs and AVGs compared to AVFs in a rate of 50% and 26%, respectively, with greater prevalence in male and elderly patients [141, 142]. Despite these findings and the KDOQI recommendations, dialysis access data from 2002 to 2003 showed that only 33% of prevalent hemodialysis patients in the USA were being dialyzed via AVFs. On the contrary, in Europe and Canada, the majority of the patients (74% and 53%, respectively) were being dialyzed via AVFs [143], but a decreasing trend in the use of AVF seems to take place accompanied by an increasing trend in the use of TCs at the start and after the start of HD [144].



Vascular access admissions continue to fall, with more procedures now performed in an outpatient setting, and are 45% below than in 1993. Among African American patients, the relative risk of an all-cause hospitalization or one related to infection is almost equal to that of Caucasians; the risk of a vascular access hospitalization, however, is 24% higher [145]. Thrombotic occlusion remains a major event, leading to permanent failure in 10% of AVFs and 20% of grafts each year. Interventional (percutaneous transluminal angioplasty and/or stent implantation) or surgical revision of thrombosed accesses has similar outcomes with a high rate of reinterventions. Diabetic elderly patients suffering from peripheral arteriosclerotic obstructive disease are particularly prone to angioaccess-induced hand ischemia [146]. Patients with TCs and AVGs have higher chronic inflammation levels than those with AVFs and increased requirements in epoetin [147]. In our previous work with 149 hemodialysis patients with 202 vascular access procedures (177 Cimino-Brescia AVFs and 25 PTFE AVGs), Cimino-Brescia fistula was used in all patients as the first choice vascular access, except for one patient in the elderly group. Fifteen patients in the elderly group and 7 younger than 65 years old had PTFE AVGs as the third or second choice of VA, respectively. Vascular thrombosis was the only reason of technique failure in both groups. Other complications were aneurysms (10/48 and 14/101), infections (0/48 and 2/101) and edema (0/48 and 6/101) (Table 1). AVF had a 5-year technique survival in two groups of 35% and 45%, respectively (Figure 13). According to our findings, there was no difference in VA complications across age-groups and the first AVF survival was independent of age [6]. Swindlehurst et al. [148] have published similar results, according to which the creation of AVF in the elderly is not only possible but also proved to have a short hospital stay, high patency rates, and an acceptable rate of further intervention. The outcome of AVF benefits more from acknowledging individual vascular conditions rather than age of the patient and therefore AVF creation should not be denied to elderly patients [149]. Among patients over 80 years of age, the AVF as vascular access for HD at the time of dialysis initiation was among the factors that benefit their survival [150].



**Figure 13.** Cumulative survival of first VA according to the patients' age.



	Group A (age>60)	Group B(age<60)	P
Thrombosis	14/48	39/101	N.S.
Aneurysm	10/48	14/101	N.S.
Edema	0/48	6/101	N.S.
Infection	0/48	2/101	N.S.

**Table 1.** Complications of vascular access

According to the 2010 USRDS Annual Data Report, in 2008, hospitalizations increased, to a point of 46% over 1993. Women on hemodialysis were 16% more likely to be hospitalized than men, overall, in 2007–2008. Also, they had a greater risk than men of cardiovascular, infectious and vascular access hospitalizations 11%, 14%, and 29%, respectively. Recently, in a retrospective single-center analysis, our data varies to those we published in 1998. In 145 patients on HD, we found that female had more possibilities to start HD with double lumen catheter than male and also patients with heart failure independent of gender [115]. Patibandla et al. [151] in their logistic regression model found that increasing age, female sex, black race, lower body mass index, urban location, certain comorbidities and shorter pre-end-stage renal disease nephrology care are all associated with a significantly lower likelihood of AVF placement as initial access predialysis. Additionally, there are geographic disparities in AVF creation with decreased rates of AVF placement as the first access in metropolitan, but not rural, populations compared with micropolitan communities [152]. Improvement in standardization of care according to practice guidelines is necessary. AVF rate could be increased by improving access to surgical resources and patients education [153]. Enhancing patient self-care abilities and working together with patients on proper vascular access care can prolong vascular access site viability [154]. Intraoperative blood flow measurements greater than 120 ml/min in AVF and less than 320 ml/min in AVGs may be predictive factors of early failure and fistulography is essential to access patency [155]. In addition to the clinical examination, there are numerous radiological assessments of vascular access pre- and postoperative that enrich our diagnostic armamentarium [156]. Recently, Remuzzi and Manini [157] presented a numerical model that in the clinical setting should allow to reduce the incidence of AVF nonmaturation as well as incidence of VA complications. Cannulation of VA is a crucial part of its management in HD patients and the proper use of the rotating site technique might still be the best approach to cannulation [158]. Evidence do not support the preferential use of buttonhole over rope-ladder cannulation [159]. However, according to systematic review of Muir et al. [160], buttonhole cannulation is associated with higher rates of infectious events, staff support requirements and no reduction in surgical AVF interventions compared with rope ladder in home HD patients.

## 6. Nontunneled double lumen catheters complications

The nontunneled double lumen catheters’ complications concern the early ones during the insertion and the late ones such as infection and thrombosis of the vessels.

The severity of acute complications varies with the site of insertion. The lowest rate is in the femoral position. A significant complication is perforation of the femoral artery. Bleeding usually resolves within minutes of direct compression and large femoral or retroperitoneal hematomas occur occasionally [161]. Subclavian insertion complications are more serious. The overinsertion of guide wire can occasionally lead to atrial or ventricular arrhythmias, but they are frequently transient [162]. The penetration or cannulation of the subclavian artery can lead to hemothorax, which may require a thoracotomy tube. The incidence of pneumothorax varies from less than 1% to more than 10% of insertions, depending on the skill and experience of the physician. Pericardial rupture and tamponade also have been described [163, 164]. There is less likelihood of arterial puncture or pneumothorax in ultrasound-guided catheter insertion [165]. Subclavian insertion from the left has an increased risk of pneumothorax and atrial perforation, which can be presented with acute hemopericardium upon initiation of dialysis. Internal jugular vein is the preferred site of insertion because of subclavian stenosis and loss of the ipsilateral arm for future hemodialysis access. This complication appears to occur more often with subclavian (40–50%) than with internal jugular insertions (up to 10%) [166, 167]. At internal jugular insertions, a carotid artery penetration may occur, but there is also a lower risk of pneumothorax (0.1%). Post procedural chest X-ray is taken for confirmation of position of catheter tip and to detect early complications, but delayed complications can occur after catheterization. Thus, the patient should be monitored carefully and managed appropriately according to the presenting signs and symptoms [168].

Prevention and treatment of catheter thrombosis are important clinical issues. To prevent formation of thrombus, both lumens of the double lumen catheter are instilled with heparin following hemodialysis [46]. Lytic agents such as urokinase and alteplase are effective in treatment of catheter thrombosis. Alteplase has effectiveness rates in thrombosis treatment comparable to the ones observed with urokinase [169]. Central vein catheters are associated with the development of central vein stenosis [170]. The K/DOQI guidelines therefore recommend avoiding placement in the subclavian vein, unless no other options are available. If central venous thrombosis is detected early, it responds well to directly applied thrombolytic therapy [170] or to percutaneous transluminal angioplasty when the fibrotic stenosis can be crossed with a guide wire [171]. The infection risks associated with temporary double lumen catheters include local exit site infection and systemic bacteremia, both of which require prompt removal of the catheter and appropriate intravenous antibiotic therapy [48, 172, 173]. Bacteremia generally results from either contamination of the catheter lumen or migration of bacteria from the skin through the entry site, down the hemodialysis catheter into the blood stream [174–176]. It seems that prevention strategies should target the first 6 months after access placement or a remedial access-related procedure as over time the risk decline [177]. Skin flora, *Staphylococcus* and *Streptococcus* species, are responsible for the majority of infections. It has been reported that surface modification with bismuth film reduces bacterial colonization of nontunneled HD catheters [178]. Guidelines have been proposed by working group with O'Grady et al. [179], with major areas of emphasis such as educating and training healthcare personnel, who insert and maintain catheters, maximal sterile barrier precautions during CVC insertion, using >0.5% chlorhexidine. The use of prophylactic gentamicin/citrate lock seems to be associated with a substantial reduction in catheter-related bloodstream than

heparin [180]. Nurse is also a key figure in the preventions of such infections with the adoption of standard precautions such as washing hands, managing HD rooms and other medical devices, managing vascular access, and providing educational support to patient [181].

There is conflicting evidence concerning the risk of infection based on the site of insertion [172, 182, 183]. Coagulase-negative staphylococci, *Staphylococcus aureus*, aerobic gram-negative bacilli, and *Candida albicans* most commonly cause catheter-related bloodstream infection. In most cases of nontunneled CVC-related bacteremia and fungemia, the CVC should be removed. The decision should be based on the severity of the patient's illness, documentation that the vascular-access device is infected, assessment of the specific pathogen involved and presence of complications, such as endocarditis, septic thrombosis, tunnel infection, or metastatic seeding [184].

Overall, compared with the subclavian vein, the internal jugular vein remains the preferred access site in ambulatory patients. In the intensive care unit, either femoral or internal jugular vein placement is satisfactory, with the use of ultrasound making internal jugular vein placement safer.

The best solution is to prevent the infection by proper placement technique, optimal exit site care and management of the catheter within the HD facility [46, 185]. It is generally believed that CVC can adversely affect permanent VA ipsilateral placement outcomes due to central vein stenosis that they cause, but it seems that the primary failure rate of AVF and AVG is not affected by the presence of an ipsilateral catheter, but cumulative access survival is inferior [186].

## 7. Arteriovenous fistulas complications

Early causes include inflow problems due to small or atherosclerotic arteries, or juxta-anastomotic stenosis, so a preoperative evaluation for suitable access sites has to be performed [187]. Selective use of duplex ultrasonography appears to enhance AVF success rate, although agreed vessels criteria are needed [188]. It seems that the type of anesthesia plays a role in the fistula surgery, with regional anesthesia having a beneficial sympathectomy like effect that causes vasodilation with increased blood flow during surgery and in the AVF postoperatively that may prevent early thrombosis and potentially improve outcome [189], but more evidence are expected to establish this [190].

The etiology of this acquired lesion is not entirely clear but may be related to manipulating the free end of the vein, torsion, poor angulation or loss of the vasa vasorum during anatomic dissection. More often than not, this lesion can be effectively managed with angioplasty [191, 192] or surgical revision [193].

Accessory veins that divert blood flow from the intended superficial vessels to deeper conduits or central venous stenoses due to prior TCs placements may cause outflow problems. Vessels, smaller than one-fourth of the fistula diameter, are usually not hemodynamically relevant. Juxta-anastomotic stenosis and accessory veins are the most common causes for early failure

AVFs when preoperative evaluations for suitable access sites have been performed [187]. In elderly population, there is an association of older age, female gender, black race, diabetes, cardiac failure and shorter pre-ESRD nephrology care with predialysis AVF failure [194].

A rather rare complication secondary to bleeding from a catheter-related puncture of an AVF is an acute forearm compartment syndrome [195].

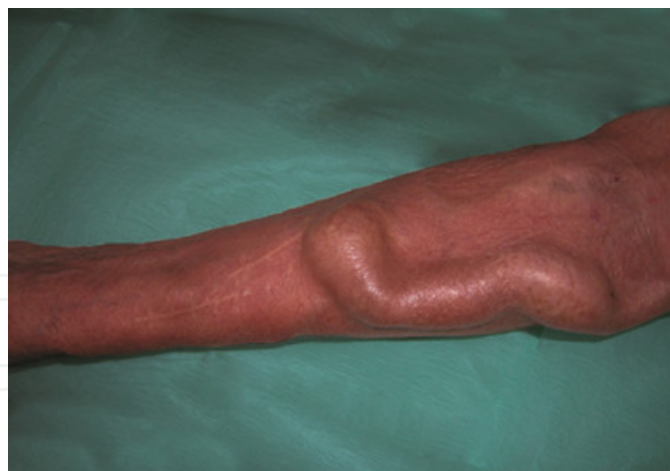Venous stenosis, thrombosis and attained arterial lesions like aneurysms or stenoses constitute late causes of AVFs' failure.

As blood flow decreases due to venous stenosis, weekly Kt/V ([dialyzer clearance time]/body volume) decreases and/or recirculation increases, constituting great clinical signs of VA dysfunction. AVF salvage surgery is of paramount importance in order to increase the patency rate, which prolongs survival and increases the patient's quality of life [196]. Balloon angioplasty followed with stenting maintains the vessel lumen shape over time, as the stent is likely to reduce the risk of restenosis that can otherwise occur after balloon angioplasty because of the viscoelastic recoil of the vessel [197]. According to Aftab et al. [198], for AVF stenosis resistant to conventional percutaneous transluminal angioplasty (PTA), cutting balloon angioplasty may be a better second line treatment given its superior patency rates. It seems that the deficiency of circulating endothelial progenitor cells is associated with early and frequent restenosis after angioplasty of HD VA [199].

Native fistulas will not typically thrombose until flow is severely diminished. The thrombectomy of fistulas, although technically more challenging than in AVGs, is often successful and if flow is reestablished, primary patency is longer than in grafts [200]. Antiplatelet treatment protects fistula from thrombosis or loss of patency but has little or no effect on graft patency and uncertain effects on vascular access maturation for dialysis and major bleeding [201]. Elective repair of subclinical stenosis in AVFs with blood flow >500 ml/min cost-effectively reduces the risk of thrombosis and access loss [202]. Reconstructing the AVF by surgically removing venous neointimal hyperplasia is an effective technique for late hemodialysis access failure which preserves patients' vessels [203].

As AVF's size increases over time with increased blood flow, aneurysms may be formed, constituting rather a cosmetic than functional concern, unless stenotic lesions accompany them. If the overlying skin is atrophic or blanching, or there are signs of ulceration or bleeding, a surgical evaluation must be performed urgently [204]. Also, if there is a high association of venous outflow stenosis and AVF aneurysms, comprehensive therapy should encompass treatment of any venous outflow stenosis before open AVF aneurysm repair. A two-stage repair may decrease tunneled HD catheter use in patients with multiple aneurysms [205]. In order to maintain an autogenous access while conserving future dialysis sites, partial aneurysmectomy is recommended as a first-line choice for managing aneurysm associated complications [206]. Also, autologous surgical reconstruction is feasible in the majority of AVF aneurysms. It preserves fistula function and keeps the advantages of an autogenous access [207]. The rupture of such aneurysms in high-flow fistulas can lead to exsanguination and death (Figure 14).





**Figure 14.** Aneurysm in forearm AVF.

Infections of AVFs are rare but must be treated properly due to patients' impaired immunologic status. Very rare infections of the AV anastomosis require surgery with resection of the infected tissue. More often, infections occur at cannulation sites and then the arm should be rested and cannulation cease [208]. In all cases of AVF infection, antibiotic therapy is initiated with broad-spectrum vancomycin plus an aminoglycoside and converting to appropriate one based on results of culture and sensitivities. Infections of primary AVFs should be treated for a total of 6 weeks, analogous to subacute bacterial endocarditis [209].

## 8. Arteriovenous graft complications

AVGs have a functional life much shorter than AVFs. Neointimal hyperplasia causes venous stenosis, which leads to thrombosis, and this is the natural course of AVGs. The principal cause of thrombosis is the increased production of smooth muscle cells, myofibroblasts and vascularization within the neointima. Around the graft, there is also angiogenesis and numerous macrophages in the tissue [210, 211]. Growth factors (GF) such as VEGF (vascular endothelial), PDGF (platelet derived) and basic FGF (fibroblast) are present within the neointimal lesion [211]. The presence of shear stress regulates vascular endothelium [212, 213] and that flow within AVGs is likely to be different from native veins. Understanding the pathophysiology of neointimal hyperplasia could lead to targeted therapy. Current studies are evaluating the role of radiation [214], decoy peptides against transcription factors [215, 216] and local delivery of drugs with cell-cycle inhibitory effects (e.g., paclitaxel [217] and sirolimus). Cell-based strategies seek to take advantage of endothelial progenitor cells that release endogenous inhibitors of proliferation and thrombosis, such as nitric oxide (NO) and prostacyclin [218]. Venous stenosis in AVGs leads to decreased blood flow and thrombosis, at a rate of 1–1.5 times/patient/year [70]. Thrombosis is associated with anatomical stenosis, in most cases, which is located in the venous anastomosis (60%), followed by the peripheral vein (37%) and within the graft (38%) [219]. Stenosis and closure by venous anastomoses are the most frequent causes of failure of AVG for hemodialysis. AVG closure can be addressed surgically and endovasc-

ularly (amenable to thrombectomy by radiological or surgical means) [220]. Percutaneous angioplasty is safe and effective in treating venous stenosis [221], with a success rate of 80% to 94% and primary patency around 60% at 6 months and 40% at 1 year. The placement of self-expanding nitinol stents at the venous anastomosis appears to prolong patency in cases where focal lesions are resistant to repeated angioplasty and recur and improve PTFE grafts longevity in selected cases of older grafts [222]. Central stenosis is technically more difficult to treat, and stenotic lesions often recur within 6 months [77]. Recently, a modular anastomotic valve device (MAVD) has been in preliminary use in order to isolate the graft from the circulation between dialysis sessions, decreasing the flow disturbances this way and as a result the intimal hyperplasia [223]. During the last decades, percutaneous techniques became increasingly important for the treatment of AVG failure [224]. Cutting balloon angioplasty is a safe and effective treatment of graft to vein anastomotic stenosis, with significantly higher patency than that of conventional balloon angioplasty [225]. From the point of view of Troisi et al. [226], the combined simultaneous hybrid (open and endovascular) approach in urgency maximizes the use of different available techniques, improving overall success rate to save a thrombosed graft.

As described above, AVGs' thromboses are usually the result of multiple factors; such as stenosis, hypotension and excessive compression for hemostasis. Hemodialysis nurses have to be careful in order to avoid these factors. Thrombosis risk increases as blood flow (BF) decreases, as May et al. [227] showed in their study. AVG thrombosis can be managed in an outpatients' basis endovascularly. Angiography for venous stenosis is always required and is often accompanied by an angioplasty.

Prompt pharmaceutical thrombolysis or mechanical removal of the thrombus with a Fogarty catheter and thromboaspiration or thrombectomy with a mechanical device [228] may avoid a new catheter placement.

Infections of AVGs are severe complications and the second cause of vascular access loss. Hemodialysis-related bacteraemia is 10-fold more often in AVGs than AVFs: 2.5 incidents every 1000 HD sessions versus 0.2 [229]. It seems that the most significant modifiable risk factor is patients' hygiene [230].

A referral to surgeon of pseudoaneurysms for resection is imposed when they are increasing rapidly in size, their width is more than 2-fold bigger than the graft, or the overlying skin seems under duress (thin, bleeding, blanching) [231].

Ischemia, as a result of access placement, is more common for AVGs than AVFs: vascular steal syndrome and ischemic monomelic neuropathy are two important clinical entities to distinguish.

"Physiological" steal phenomenon occurs in 73% of AVFs and 90% of AVGs. Thus, in a radiocephalic fistula, arterial blood from the palmar arch may also deliver blood into the fistula. Unless there is the capacity for collateralization, this can lead to ischemia in the hand, ranging from complaints about cold hands to necrotic fingertips. Most of these complaints improve over time, but 1% of AVFs and up to 4% of AVGs require surgical revision [232]. Doppler ultrasonography is a useful adjunctive tool to determine the etiology of chronic hemodialysis access-induced distal ischemia (HAIDI). Conservative measures combined with close follow-up can be used as the first step in the management of chronic HAIDI patients with mild symptoms [233]. Ischemic monomelic neuropathy is characterized by warm hands with



a good pulse, but the hands are tender and swollen, usually immediately after surgery, and there is muscle weakness [234]. The cause is likely ischemia of the nerves, and rapid surgical reevaluation is needed. Wound and skin complications and greater incidence of thrombosis of VA associated with recombinant human erythropoietin have been reported (rHuEPO) [235].

## 9. Tunneled catheter complications

Early or late catheter dysfunctions are the functional complications of TCs. Kinking and unsuitable positioning of the catheter tip may be the cause of early dysfunction and can be managed under fluoroscopic guidance. Around or at the catheter tip, fibrin sheaths and thrombi can be formed constituting late causes of failure. Balloon angioplasty can disrupt fibrinous sheaths, improving flow through a new catheter in the same location. Valliant et al. [236] have demonstrated in their study that there is no significant increase in bacteraemia and subsequent catheter dysfunction rates after fibrin sheath disruption by balloon procedure compared to simple over the wire exchange. Symptomatic occlusions of the central veins usually require the removal of the catheter and system anticoagulation and must be weighed in the context of a continued need for dialysis and other available access options. Yoon et al. recently referred a novel two-stage hemodialysis reliable outflow (HeRO) graft implantation technique that avoids the use of a femoral bridging hemodialysis catheter in internal jugular vein (IJV) catheter-dependent patients with contralateral central venous occlusion and thus lowering the risk of infection related to a femoral catheter [237]. The use of catheter is related to a higher incidence of infection and could compromise dialysis adequacy [238, 239]. Catheter-related infections (CRI) are linked with increased all cause morbidity and mortality. The 8–10% of MRSA bacteraemia in the UK occurs in patients receiving long-term hemodialysis. It appears that the catheter locking with appropriate antimicrobial lock solutions (ALS) decrease the infections' incidence in HD patients [180, 240, 241]. It seems that prophylaxis with gentamicin of the catheter lumens reduces bacterial infection morbidity and mortality-related bacteremia of catheter without obvious bacterial resistance, making such use advisable [242]. Even taurolidine–citrate–heparin catheter lock solution reduces staphylococcal bacteraemia rates in HD patients [243] and improves the inflammatory profile in HD patients with TCs [244]. Del Pozo et al. [245] in their prospective study showed that an evaluation of tunneled catheters with intracatheter leukocyte culture helps in the early colonization of HD catheters, giving the possibility to eradicate biofilm without the removal of catheter. Recent studies have demonstrated that the “shower and no-dressing” technique appears to be a safe TC option that improves quality of life [246, 247], although there is skepticism and uncertainty about the appropriate dressing [248].

## 10. Final conclusions and remarks

Unfortunately, there are no revolutionary changes in the field of vascular access for hemodialysis in the last years. According to the guidelines, AVFs are still the best choice. Luckily, AVGs' survival has been increased, but still TCs are used in a great portion of ESRD patients.

As a result, humerobasilic and radiocephalic AVFs are the two VA types with the most functioning longevity. However, AVFs' primary patency rates at 1 year vary considerably between USA and Europe. Hemodialysis patients with AVF seem to have lower mortality.

The incidence of AVFs has been effectively increased since the "fistula first" has been developed, although it is accompanied with an increase in TCs.

AVGs as a second choice remain a good solution for patients without the possibility of AVF and the survival of grafts has been improved.

TCs seem to be a new reality in most American and European dialysis units because of the increase of number of elderly patients and with heart failure. Early referral to nephrologists and patient's education has an important role for a successful VA.

Additionally, the cannulation of VA is a crucial part of its management in HD patients and the proper use may improve the survival of VA.

Summarized from the international literature and our experience, when there are suitable vessels, the creation of AVF is of top priority. When this is not feasible or there is an AVF failure, AVGs or TCs are the first choice alternative or the second best, respectively. Female and old patients are more likely to initiate HD treatments via TC. A well-matured and functioning permanent vascular access is of great importance for its longevity and thus early referral to a nephrologist is mandatory.

## Author details

Eirini Grapsa<sup>1\*</sup> and Konstantinos Pantelias<sup>2</sup>

\*Address all correspondence to: [grapse@otenet.gr](mailto:grapse@otenet.gr)

1 National and Kapodistrian University of Athens, Aretaieio, University Hospital, Athens, Greece

2 Protipo Nefrologiko Kentro Athinon, Athens, Greece

## References

- [1] Gilbertson DT, Liu J, Xue JL, Louis TA, Solid CA, Ebben JP, et al. Projecting the number of patients with end-stage renal disease in the United States to the year 2015. *J Am Soc Nephrol*. 2005;16(12):3736–41.
- [2] Schieppati A, Remuzzi G. Chronic renal diseases as a public health problem: epidemiology, social, and economic implications. *Kidney Int Suppl*. 2005(98):S7–S10.

- [3] Eggers PW. Has the incidence of end-stage renal disease in the USA and other countries stabilized? *Curr Opin Nephrol Hypertens*. 2011.
- [4] Grassmann A, Gioberge S, Moeller S, Brown G. ESRD patients in 2004: global overview of patient numbers, treatment modalities and associated trends. *Nephrol Dial Transplant*. 2005;20(12):2587–93.
- [5] Santoro A, Canova C, Freyrie A, Mancini E. Vascular access for hemodialysis. *J Nephrol*. 2006;19(3):259–64.
- [6] Grapsa EJ, Paraskevopoulos AP, Moutafis SP, Vourliotou AJ, Papadoyannakis NJ, Digenis GE, et al. Complications of vascular access in hemodialysis (HD)—aged vs adult patients. *Geriatr Nephrol Urol*. 1998;8(1):21–4.
- [7] III. NKF-K/DOQI Clinical Practice Guidelines for Vascular Access: update 2000. *Am J Kidney Dis*. 2001;37(1 Suppl 1):S137–81.
- [8] Schwab SJ, Oliver MJ, Suhocki P, McCann R. Hemodialysis arteriovenous access: detection of stenosis and response to treatment by vascular access blood flow. *Kidney Int*. 2001;59(1):358–62.
- [9] Feldman HI, Kobrin S, Wasserstein A. Hemodialysis vascular access morbidity. *J Am Soc Nephrol*. 1996;7(4):523–35.
- [10] System USRD. 2002 Annual Data Report. Bethesda, National Institutes of Health, National Institute of Diabetes and Digestive Diseases. 2002.
- [11] Roy-Chaudhury P, Duncan H, Barrett W, Elson H, Narayana A, Foley J, et al. Vascular brachytherapy for hemodialysis vascular access dysfunction: exploring an unmet clinical need. *J Invasive Cardiol*. 2003;15 (Suppl A):25A–30A.
- [12] Lee H, Manns B, Taub K, Ghali WA, Dean S, Johnson D, et al. Cost analysis of ongoing care of patients with end-stage renal disease: the impact of dialysis modality and dialysis access. *Am J Kidney Dis*. 2002;40(3):611–22.
- [13] Allon M. Implementing a vascular access program: improved outcomes with multidisciplinary approaches. In: Gray RJ, Sands JJ, editors. *Dialysis Access: A Multidisciplinary Approach*. Philadelphia: Lippincott Williams & Wilkins; 2002. pp. 6–9.
- [14] Haas G. Versuche der Blutauswaschung am Lebenden mit Hilfe der Dialyse. *Klin Wochenschr*. 1925;4:13–4.
- [15] Kolff WJ. The artificial kidney. *J Mt Sinai Hosp N Y*. 1947;14(2):71–9.
- [16] Vienken J. 'Bioengineering for life': a tribute to Willem Johan Kolff. *Nephrol Dial Transplant*. 2009;24(8):2299–301.
- [17] Kolff WJ. First clinical experience with the artificial kidney. *Ann Intern Med*. 1965;62:608–19.

- [18] Aubaniac R. A new route for venous injection or puncture: the subclavicular route, subclavian vein, brachiocephalic trunk. *Sem Hop.* 1952;28(85):3445–7.
- [19] Quinton W, Dillard D, Scribner BH. Cannulation of blood vessels for prolonged hemodialysis. *Trans Am Soc Artif Intern Organs.* 1960;6:104–13.
- [20] Seldinger SI. Catheter replacement of the needle in percutaneous arteriography; a new technique. *Acta Radiol.* 1953;39(5):368–76.
- [21] Shaldon S, Chiandussi L, Higgs B. Hemodialysis by percutaneous catheterisation of the femoral artery and vein with regional heparinization. *Lancet.* 1961. 278(7207):857–9.
- [22] Cimino JE, Brescia MJ. Simple venipuncture for hemodialysis. *N Engl J Med.* 1962;267:608–9.
- [23] Fogarty TJ, Cranley JJ, Krause RJ, Strasser ES, Hafner CD. A method for extraction of arterial emboli and thrombi. *Surg Gynecol Obstet.* 1963;116:241–4.
- [24] Brescia MJ, Cimino JE, Appel K, Hurwich BJ. Chronic hemodialysis using venipuncture and a surgically created arteriovenous fistula. *N Engl J Med.* 1966;275(20):1089–92.
- [25] Sperling M, Kleinschmidt W, Wilhelm A, Heidland A, Klutsch K. [Subcutaneous arteriovenous shunt for intermittent hemodialysis treatment]. *Dtsch Med Wochenschr.* 1967;92(10):425–6.
- [26] Stolic RV, Trajkovic GZ, Krstic NJ, Stolic DZ, Subaric-Gorgieva G. Correlation of mortality and location of arteriovenous fistula in hemodialysis patients. *Int J Artif Organs.* 2011;34(1):26–33.
- [27] Konner K, Nonnast-Daniel B, Ritz E. The arteriovenous fistula. *J Am Soc Nephrol.* 2003;14(6):1669–80.
- [28] Rohl L, Franz HE, Mohring K, Ritz E, Schuler HW, Uhse HG, et al. Direct arteriovenous fistula for hemodialysis. *Scand J Urol Nephrol.* 1968;2(3):191–5.
- [29] Girardet RE, Hackett RE, Goodwin NJ, Friedman EA. Thirteen months experience with the saphenous vein graft arteriovenous fistula for maintenance hemodialysis. *Trans Am Soc Artif Intern Organs.* 1970;16:285–91.
- [30] Brittinger WD SM, Huber W et al. 16 months experience with the subcutaneously fixed superficial femoral artery for chronic haemodialysis. *Proc EDTA.* 1970;7:408–12.
- [31] Brittinger W-D vHG, Twittenhoff W-D et al. Implantation of a plastic valve into the superficialised femoral artery. *Proc EDTA.* 1971;8:521–5.
- [32] Buselmeier TJ, Kjellstrand CM, Simmons RL, Duncan DA, von Hartitzsch B, Rattazzi LC, et al. A totally new subcutaneous prosthetic arterio-venous shunt. *Trans Am Soc Artif Intern Organs.* 1973;19:25–32.

- [33] Baker LD, Jr., Johnson JM, Goldfarb D. Expanded polytetrafluoroethylene (PTFE) subcutaneous arteriovenous conduit: an improved vascular access for chronic hemodialysis. *Trans Am Soc Artif Intern Organs*. 1976;22:382–7.
- [34] Mindich BP, Silverman MJ, Elguezabal A, Levowitz BS. Umbilical cord vein fistula for vascular access in hemodialysis. *Trans Am Soc Artif Intern Organs*. 1975;21:273–80.
- [35] Dardik H, Ibrahim IM, Dardik I. Arteriovenous fistulas constructed with modified human umbilical cord vein graft. *Arch Surg*. 1976;111(1):60–2.
- [36] Erben J KJ, Bastecky J, Vortel V. Experience with routine use of subclavian vein cannulation in haemodialysis. *Proc EDTA*. 1969;6:59–64.
- [37] Schillinger F, Schillinger D, Montagnac R, Milcent T. Post catheterisation vein stenosis in haemodialysis: comparative angiographic study of 50 subclavian and 50 internal jugular accesses. *Nephrol Dial Transplant*. 1991;6(10):722–4.
- [38] Dotter CT, Judkins MP, Rosch J. Nonoperative treatment of arterial occlusive disease: a radiologically facilitated technique. *Radiol Clin North Am*. 1967;5(3):531–42.
- [39] Gracz KC, Ing TS, Soung LS, Armbruster KF, Seim SK, Merkel FK. Proximal forearm fistula for maintenance hemodialysis. *Kidney Int*. 1977;11(1):71–5.
- [40] Konner K. Primary vascular access in diabetic patients: an audit. *Nephrol Dial Transplant*. 2000;15(9):1317–25.
- [41] Golding AL, Nissenson AR, Raible D. Carbon transcatheter access device (CTAD). *Proc Clin Dial Transplant Forum*. 1979;9:242–7.
- [42] Shapiro FL, Keshaviah PR, Carlson LD, Ilstrup KM, Collins AJ, Andersen RC, et al. Blood access without percutaneous punctures. *Proc Clin Dial Transplant Forum*. 1980;10:130–7.
- [43] Canaud B. DS. Vascular access for hemodialysis. In: Horl HW, Lindsay BR, Ronco C, Winchester FJ, editors. *Replacement of Renal Function by Dialysis*. Kluwer Academic Publishers; 2004. pp. 203–30.
- [44] Randolph AG, Cook DJ, Gonzales CA, Pribble CG. Ultrasound guidance for placement of central venous catheters: a meta-analysis of the literature. *Crit Care Med*. 1996;24(12):2053–8.
- [45] Work J. Vascular access for renal replacement therapy. In: Murray PT, Hall JB, editors. *Intensive Care in Nephrology*. Taylor & Francis; 2006. pp. 157–64.
- [46] Schwab SJ, Beathard G. The hemodialysis catheter conundrum: hate living with them, but can't live without them. *Kidney Int*. 1999;56(1):1–17.
- [47] Fan PY, Schwab SJ. Vascular access: concepts for the 1990s. *J Am Soc Nephrol*. 1992;3(1):1–11.



- [48] Clinical practice guidelines for hemodialysis adequacy, update 2006. *Am J Kidney Dis.* 2006;48 (Suppl 1):S2–90.
- [49] Oliver MJ, Edwards LJ, Treleaven DJ, Lambert K, Margetts PJ. Randomized study of temporary hemodialysis catheters. *Int J Artif Organs.* 2002;25(1):40–4.
- [50] Little MA, Conlon PJ, Walshe JJ. Access recirculation in temporary hemodialysis catheters as measured by the saline dilution technique. *Am J Kidney Dis.* 2000;36(6):1135–9.
- [51] Cheesbrough JS, Finch RG, Burden RP. A prospective study of the mechanisms of infection associated with hemodialysis catheters. *J Infect Dis.* 1986;154(4):579–89.
- [52] Contreras G, Liu PY, Elzinga L, Anger MS, Lee J, Robert N, et al. A multicenter, prospective, randomized, comparative evaluation of dual- versus triple-lumen catheters for hemodialysis and apheresis in 485 patients. *Am J Kidney Dis.* 2003;42(2):315–24.
- [53] Konner K. The initial creation of native arteriovenous fistulas: surgical aspects and their impact on the practice of nephrology. *Semin Dial.* 2003;16(4):291–8.
- [54] Drew DA, Lok CE, Cohen JT, Wagner M, Tangri N, Weiner DE. Vascular access choice in incident hemodialysis patients: a decision analysis. *J Am Soc Nephrol.* 2014.
- [55] Sidawy AN, Gray R, Besarab A, Henry M, Ascher E, Silva M, Jr., et al. Recommended standards for reports dealing with arteriovenous hemodialysis accesses. *J Vasc Surg.* 2002;35(3):603–10.
- [56] de Almeida E, Dias L, de Sousa FT, Mil-Homens MC, Pataca I, Prata MM. Survival in haemodialysis: is there a role for vascular access? *Nephrol Dial Transplant.* 1997;12(4):852.
- [57] Stehman-Breen CO, Sherrard DJ, Gillen D, Caps M. Determinants of type and timing of initial permanent hemodialysis vascular access. *Kidney Int.* 2000;57(2):639–45.
- [58] Sesso R, Yoshihiro MM. Time of diagnosis of chronic renal failure and assessment of quality of life in haemodialysis patients. *Nephrol Dial Transplant.* 1997;12(10):2111–6.
- [59] Arora P, Obrador GT, Ruthazer R, Kausz AT, Meyer KB, Jenuleson CS, et al. Prevalence, predictors, and consequences of late nephrology referral at a tertiary care center. *J Am Soc Nephrol.* 1999;10(6):1281–6.
- [60] Roubicek C, Brunet P, Huiart L, Thirion X, Leonetti F, Dussol B, et al. Timing of nephrology referral: influence on mortality and morbidity. *Am J Kidney Dis.* 2000;36(1):35–41.
- [61] Pena JM, Logrono JM, Pernaute R, Laviades C, Virto R, Vicente de Vera C. Late nephrology referral influences on morbidity and mortality of hemodialysis patients. A provincial study. *Nefrologia.* 2006;26(1):84–97.



- [62] Pisoni RL, Young EW, Dykstra DM, Greenwood RN, Hecking E, Gillespie B, et al. Vascular access use in Europe and the United States: results from the DOPPS. *Kidney Int.* 2002;61(1):305–16.
- [63] Ravani P, Brunori G, Mandolfo S, Cancarini G, Imbasciati E, Marcelli D, et al. Cardiovascular comorbidity and late referral impact arteriovenous fistula survival: a prospective multicenter study. *J Am Soc Nephrol.* 2004;15(1):204–9.
- [64] Rayner HC, Pisoni RL, Gillespie BW, Goodkin DA, Akiba T, Akizawa T, et al. Creation, cannulation and survival of arteriovenous fistulae: data from the Dialysis Outcomes and Practice Patterns Study. *Kidney Int.* 2003;63(1):323–30.
- [65] Ethier J, Mendelssohn DC, Elder SJ, Hasegawa T, Akizawa T, Akiba T, et al. Vascular access use and outcomes: an international perspective from the Dialysis Outcomes and Practice Patterns Study. *Nephrol Dial Transplant.* 2008;23(10):3219–26.
- [66] Aitken E, Jackson AJ, Kasthuri R, Kingsmore DB. Bilateral central vein stenosis: options for dialysis access and renal replacement therapy when all upper extremity access possibilities have been lost. *J Vasc Access.* 2014;0(0):0.
- [67] Kudlaty EA, Pan J, Allemang MT, Kendrick DE, Kashyap VS, Wong VL. The end stage of dialysis access: femoral graft or HeRO vascular access device. *Ann Vasc Surg.* 2014.
- [68] Santoro D, Benedetto F, Mondello P, Pipito N, Barilla D, Spinelli F, et al. Vascular access for hemodialysis: current perspectives. *Int J Nephrol Renovasc Dis.* 2014;7:281–94.
- [69] Ganie FA, Lone H, Dar AM, Lone GN, Wani ML. Native arterio-venous fistula is the vascular access of choice for hemodialysis in end stage renal disease. *Int Cardiovasc Res J.* 2013;7(2):67–70.
- [70] Lameire N, Mehta RL. *Complications of Dialysis.* New York: M. Dekker; 2000. xiv, 877 p. p.
- [71] Sommer G, Bruce HM. *Vascular Access for Hemodialysis II.* 1991. pp. 145–57.
- [72] Leapman SB, Boyle M, Pescovitz MD, Milgrom ML, Jindal RM, Filo RS. The arteriovenous fistula for hemodialysis access: gold standard or archaic relic? *Am Surg.* 1996;62(8):652–6; discussion 6-7.
- [73] Hodges TC, Fillinger MF, Zwolak RM, Walsh DB, Bech F, Cronenwett JL. Longitudinal comparison of dialysis access methods: risk factors for failure. *J Vasc Surg.* 1997;26(6):1009–19.
- [74] Konner K, Hulbert-Shearon TE, Roys EC, Port FK. Tailoring the initial vascular access for dialysis patients. *Kidney Int.* 2002;62(1):329–38.

- [75] Fassiadis N, Morsy M, Siva M, Marsh JE, Makanjuola AD, Chemla ES. Does the surgeon's experience impact on radiocephalic fistula patency rates? *Semin Dial.* 2007;20(5):455–7.
- [76] Korsheed S, Eldehni MT, John SG, Fluck RJ, McIntyre CW. Effects of arteriovenous fistula formation on arterial stiffness and cardiovascular performance and function. *Nephrol Dial Transplant.* 2011.
- [77] Hentschel MD. Vascular access for hemodialysis. *Nephrology Rounds.* 2008;6(1).
- [78] Shintaku S, Kawanishi H, Moriishi M, Bansyodani M, Tsuchiya S. Distal ulnar-basilic fistula as the first hemodialysis access. *J Vasc Access.* 2014;15(2):83–7.
- [79] Hod T, Patibandla BK, Vin Y, Brown RS, Goldfarb-Rumyantsev AS. Arteriovenous fistula placement in the elderly: when is the optimal time? *J Am Soc Nephrol.* 2014.
- [80] Silva MB, Jr., Hobson RW, 2nd, Pappas PJ, Jamil Z, Araki CT, Goldberg MC, et al. A strategy for increasing use of autogenous hemodialysis access procedures: impact of preoperative noninvasive evaluation. *J Vasc Surg.* 1998;27(2):302–7; discussion 7-8.
- [81] Beathard GB. A Practitioner's Resource Guide to Hemodialysis Arteriovenous Fistulas. ESRD Network of Texas; 2003.
- [82] Wong V, Ward R, Taylor J, Selvakumar S, How TV, Bakran A. Factors associated with early failure of arteriovenous fistulae for haemodialysis access. *Eur J Vasc Endovasc Surg.* 1996;12(2):207–13.
- [83] Lew SQ, Nguyen BN, Ing TS. Hemodialysis vascular access construction in the upper extremity: a review. *J Vasc Access.* 2014;0(0):0.
- [84] Uzun A, Diken AI, Yalcinkaya A, Hanedan O, Cicek OF, Lafci G, et al. Long-term patency of autogenous saphenous veins vs. PTFE interposition graft for prosthetic hemodialysis access. *Anadolu Kardiyol Der.* 2014;14(6):542–6.
- [85] Yerdel MA, Kesenci M, Yazicioglu KM, Doseyen Z, Turkcapar AG, Anadol E. Effect of haemodynamic variables on surgically created arteriovenous fistula flow. *Nephrol Dial Transplant.* 1997;12(8):1684–8.
- [86] Malovrh M. Non-invasive evaluation of vessels by duplex sonography prior to construction of arteriovenous fistulas for haemodialysis. *Nephrol Dial Transplant.* 1998;13(1):125–9.
- [87] Robbin ML, Chamberlain NE, Lockhart ME, Gallichio MH, Young CJ, Deierhoi MH, et al. Hemodialysis arteriovenous fistula maturity: US evaluation. *Radiology.* 2002;225(1):59–64.
- [88] Oder TF, Teodorescu V, Uribarri J. Effect of exercise on the diameter of arteriovenous fistulae in hemodialysis patients. *ASAIO J.* 2003;49(5):554–5.

- [89] Rus RR, Ponikvar R, Kenda RB, Buturovic-Ponikvar J. Effect of local physical training on the forearm arteries and veins in patients with end-stage renal disease. *Blood Purif.* 2003;21(6):389–94.
- [90] Bashar K, Healy D, Browne LD, Kheirelseid EA, Walsh MT, Moloney MC, et al. Role of far infra-red therapy in dialysis arterio-venous fistula maturation and survival: systematic review and meta-analysis. *PLoS One.* 2014;9(8):e104931.
- [91] Lin CC, Yang WC, Chen MC, Liu WS, Yang CY, Lee PC. Effect of far infrared therapy on arteriovenous fistula maturation: an open-label randomized controlled trial. *Am J Kidney Dis.* 2013;62(2):304–11.
- [92] Jennings WC, Galt SW, Shenoy S, Wang S, Ladenheim ED, Glickman MH, et al. The Venous Window Needle Guide, a hemodialysis cannulation device for salvage of uncannulatable arteriovenous fistulas. *J Vasc Surg.* 2014.
- [93] Strozecki P, Flisinski M, Serafin Z, Wiechecka-Korenkiewicz J, Manitius J. Abdominal collateral vein as an unconventional vascular access for hemodialysis in patient with central vein occlusion. *Semin Dial.* 2014;27(4):E48–50.
- [94] Rodriguez JA, Armadans L, Ferrer E, Olmos A, Codina S, Bartolome J, et al. The function of permanent vascular access. *Nephrol Dial Transplant.* 2000;15(3):402–8.
- [95] Kinnaert P, Vereerstraeten P, Toussaint C, Van Geertruyden J. Nine years' experience with internal arteriovenous fistulas for haemodialysis: a study of some factors influencing the results. *Br J Surg.* 1977;64(4):242–6.
- [96] Reilly DT, Wood RF, Bell PR. Prospective study of dialysis fistulas: problem patients and their treatment. *Br J Surg.* 1982;69(9):549–53.
- [97] Windus DW. Permanent vascular access: a nephrologist's view. *Am J Kidney Dis.* 1993;21(5):457–71.
- [98] Hakaim AG, Nalbandian M, Scott T. Superior maturation and patency of primary brachiocephalic and transposed basilic vein arteriovenous fistulae in patients with diabetes. *J Vasc Surg.* 1998;27(1):154–7.
- [99] Bender MH, Bruyninckx CM, Gerlag PG. The brachiocephalic elbow fistula: a useful alternative angioaccess for permanent hemodialysis. *J Vasc Surg.* 1994;20(5):808–13.
- [100] USRDS. 2007 Annual Data Report. 2007.
- [101] Dukkupati R, Peck M, Dhamija R, Hentschel DM, Reynolds T, Tammewar G, et al. Biological grafts for hemodialysis access: historical lessons, state-of-the-art and future directions. *Semin Dial.* 2013;26(2):233–9.
- [102] Gowda A, Pavan M, Babu K. Vascular access profile in maintenance hemodialysis patients. *Iran J Kidney Dis.* 2014;8(3):218–24.
- [103] Disbrow DE, Cull DL, Carsten CG, 3rd, Yang SK, Johnson BL, Keahey GP. Comparison of arteriovenous fistulas and arteriovenous grafts in patients with favorable vas-

cular anatomy and equivalent access to health care: is a reappraisal of the Fistula First Initiative indicated? *J Am Coll Surg*. 2013;216(4):679–85; discussion 85-6.

- [104] Ong S, Barker-Finkel J, Allon M. Long-term outcomes of arteriovenous thigh grafts in hemodialysis patients: a comparison with tunneled dialysis catheters. *Clin J Am Soc Nephrol*. 2013;8(5):804–9.
- [105] Hunter JP, Nicholson ML. Midterm experience of ipsilateral axillary–axillary arteriovenous loop graft as tertiary access for haemodialysis. *J Transplant*. 2014;2014:908738.
- [106] Schild AF, Schuman ES, Noicely K, Kaufman J, Gillaspie E, Fuller J, et al. Early cannulation prosthetic graft (Flixene™) for arteriovenous access. *J Vasc Access*. 2011.
- [107] Hakaim AG, Scott TE. Durability of early prosthetic dialysis graft cannulation: results of a prospective, nonrandomized clinical trial. *J Vasc Surg*. 1997;25(6):1002–5; discussion 5-6.
- [108] Quinn B, Cull LD, Carsten G. Hemodialysis access: placement and management of complications. In: *Comprehensive Vascular and Endovascular Surgery*, 2nd ed. [Internet]. Mosby ELSEVIER; 2009. pp. 429–62].
- [109] Karatepe C, Aitinay L, Yetim TD, Dagli C, Dursun S. A novel electrospun nano-fabric graft allows early cannulation access and reduces exposure to central venous catheters. *J Vasc Access*. 2013;14(3):273–80.
- [110] Aitken EL, Jackson AJ, Kingsmore DB. Early cannulation prosthetic graft (Acuseal) for arteriovenous access: a useful option to provide a personal vascular access solution. *J Vasc Access*. 2014;0(0):0.
- [111] Donati G, Cianciolo G, Mauro R, Rucci P, Scrivo A, Marchetti A, et al. PTFE grafts versus tunneled cuffed catheters for hemodialysis: which is the second choice when arteriovenous fistula is not feasible? *Artificial Organs*. 2014.
- [112] Xue H, Ix JH, Wang W, Brunelli SM, Lazarus M, Hakim R, et al. Hemodialysis access usage patterns in the incident dialysis year and associated catheter-related complications. *Am J Kidney Dis*. 2013;61(1):123–30.
- [113] Beasley C, Rowland J, Spergel L. Fistula first: an update for renal providers. *Nephrol News Issues*. 2004;18(11):88, 90.
- [114] Rayner HC, Pisoni RL. The increasing use of hemodialysis catheters: evidence from the DOPPS on its significance and ways to reverse it. *Semin Dial*. 2010;23(1):6–10.
- [115] Grapsa E, Pantelias K, Vourliotou A, Tseke P, Pipili C, Deda E, et al. Patients with cardiac failure and female gender are most likely to start hemodialysis using a double lumen catheter. *Minerva Urol Nefrol*. 2014.

- [116] Raad I, Costerton W, Sabharwal U, Sacilowski M, Anaissie E, Bodey GP. Ultrastructural analysis of indwelling vascular catheters: a quantitative relationship between luminal colonization and duration of placement. *J Infect Dis.* 1993;168(2):400–7.
- [117] Troidle L, Finkelstein FO. Catheter-related bacteremia in hemodialysis patients: the role of the central venous catheter in prevention and therapy. *Int J Artif Organs.* 2008;31(9):827–33.
- [118] Power A, Singh SK, Ashby D, Cairns T, Taube D, Duncan N. Long-term Tesio catheter access for hemodialysis can deliver high dialysis adequacy with low complication rates. *J Vasc Interv Radiol.* 2011.
- [119] Marik PE, Flemmer M, Harrison W. The risk of catheter-related bloodstream infection with femoral venous catheters as compared to subclavian and internal jugular venous catheters: a systematic review of the literature and meta-analysis. *Crit Care Med.* 2012;40(8):2479–85.
- [120] Timsit JF, Bouadma L, Mimoz O, Parienti JJ, Garrouste-Orgeas M, Alfandari S, et al. Jugular versus femoral short-term catheterization and risk of infection in intensive care unit patients. Causal analysis of two randomized trials. *Am J Respir Crit Care Med.* 2013;188(10):1232–9.
- [121] Younes HK, Pettigrew CD, Anaya-Ayala JE, Soltes G, Saad WE, Davies MG, et al. Transhepatic hemodialysis catheters: functional outcome and comparison between early and late failure. *J Vasc Interv Radiol.* 2011;22(2):183–91.
- [122] Power A, Singh S, Ashby D, Hamady M, Moser S, Gedroyc W, et al. Translumbar central venous catheters for long-term haemodialysis. *Nephrol Dial Transplant.* 2010;25(5):1588–95.
- [123] Gouda Z. Retrograde femoral vein catheter insertion. A new approach for challenging hemodialysis vascular access. *J Vasc Access.* 2014;0(0):0.
- [124] Seikaly M, Ho PL, Emmett L, Tejani A. The 12th Annual Report of the North American Pediatric Renal Transplant Cooperative Study: renal transplantation from 1987 through 1998. *Pediatr Transplant.* 2001;5(3):215–31.
- [125] NAPRTCS. NAPRTCS: 2008 Annual Report 2008. Available from: <https://web.emmes.com/study/ped/announce.htm>.
- [126] USRDS: the United States Renal Data System. *Am J Kidney Dis.* 2003;42(6 Suppl 5):1–230.
- [127] Verrina E, Cappelli V, Perfumo F. Selection of modalities, prescription, and technical issues in children on peritoneal dialysis. *Pediatr Nephrol.* 2009;24(8):1453–64.
- [128] Fischbach M, Edefonti A, Schroder C, Watson A. Hemodialysis in children: general practical guidelines. *Pediatr Nephrol.* 2005;20(8):1054–66.
- [129] Carey WA, Talley LI, Sehring SA, Jaskula JM, Mathias RS. Outcomes of dialysis initiated during the neonatal period for treatment of end-stage renal disease: a North



American Pediatric Renal Trials and Collaborative Studies special analysis. *Pediatrics*. 2007;119(2):e468–73.

- [130] Sadowski RH, Harmon WE, Jabs K. Acute hemodialysis of infants weighing less than five kilograms. *Kidney Int*. 1994;45(3):903–6.
- [131] Chand DH, Geary D, Patel H, Greenbaum LA, Nailescu C, Brier ME, et al. Barriers, biases, and beliefs about arteriovenous fistula placement in children: a survey of the International Pediatric Fistula First Initiative (IPFFI) within the Midwest Pediatric Nephrology Consortium (MWPNC). *International Symposium on Home Hemodialysis*. 2014.
- [132] Goldstein SL JK. Pediatric hemodialysis. In: Avner ED, Niaudet P, editors. *Pediatric Nephrology*, 5th ed. Lippincott Williams & Wilkins; 2003. pp. 1395–410.
- [133] Donckerwolcke RA, Bunchman TE. Hemodialysis in infants and small children. *Pediatr Nephrol*. 1994;8(1):103–6.
- [134] Fadel FI, Elshamaa MF, Nabhan MM, Essam RG, Kantoush N, El Sonbaty MM, et al. Soluble adhesion molecules as markers of native arteriovenous fistula thrombosis in children on uremia. *Blood Coagul Fibrinolysis*. 2014;25(7):675–82.
- [135] Pastan S, Soucie JM, McClellan WM. Vascular access and increased risk of death among hemodialysis patients. *Kidney Int*. 2002;62(2):620–6.
- [136] Xue JL, Dahl D, Ebben JP, Collins AJ. The association of initial hemodialysis access type with mortality outcomes in elderly Medicare ESRD patients. *Am J Kidney Dis*. 2003;42(5):1013–9.
- [137] Hicks CW, Canner JK, Arhuidese I, Zarkowsky DS, Qazi U, Reifsnnyder T, et al. Mortality benefits of different hemodialysis access types are age dependent. *J Vasc Surg*. 2014.
- [138] El Minshawy O, Abd El Aziz T, Abd El Ghani H. Evaluation of vascular access complications in acute and chronic hemodialysis. *J Vasc Access*. 2004;5(2):76–82.
- [139] Ng LJ, Chen F, Pisoni RL, Krishnan M, Mapes D, Keen M, et al. Hospitalization risks related to vascular access type among incident US hemodialysis patients. *Nephrol Dial Transplant*. 2011.
- [140] Cornelis T, Usvyat LA, Tordoir JH, Wang Y, Wong M, Leunissen KM, et al. Vascular access vulnerability in intensive hemodialysis: a significant Achilles' heel? *Blood Purif*. 2014;37(3):222–8.
- [141] Astor BC, Eustace JA, Powe NR, Klag MJ, Fink NE, Coresh J. Type of vascular access and survival among incident hemodialysis patients: the Choices for Healthy Outcomes in Caring for ESRD (CHOICE) Study. *J Am Soc Nephrol*. 2005;16(5):1449–55.



- [142] Ocak G, Halbesma N, le Cessie S, Hoogeveen EK, van Dijk S, Kooman J, et al. Haemodialysis catheters increase mortality as compared to arteriovenous accesses especially in elderly patients. *Nephrol Dial Transplant*. 2011.
- [143] Mendelssohn DC, Ethier J, Elder SJ, Saran R, Port FK, Pisoni RL. Haemodialysis vascular access problems in Canada: results from the Dialysis Outcomes and Practice Patterns Study (DOPPS II). *Nephrol Dial Transplant*. 2006;21(3):721–8.
- [144] Noordzij M, Jager KJ, van der Veer SN, Kramar R, Collart F, Heaf JG, et al. Use of vascular access for haemodialysis in Europe: a report from the ERA-EDTA Registry. *Nephrol Dial Transplant*. 2014.
- [145] System USRD. 2010 Annual Data Report. Bethesda, National Institutes of Health, National Institute of Diabetes and Digestive Diseases. 2010.
- [146] Tordoir JH, Van Der Sande FM, De Haan MW. Current topics on vascular access for hemodialysis. *Minerva Urol Nefrol*. 2004;56(3):223–35.
- [147] Movilli E, Brunori G, Camerini C, Vizzardi V, Gaggia P, Cassamali S, et al. The kind of vascular access influences the baseline inflammatory status and epoetin response in chronic hemodialysis patients. *Blood Purif*. 2006;24(4):387–93.
- [148] Swindlehurst N, Swindlehurst A, Lumgair H, Rebollo Mesa I, Mamode N, Cacciola R, et al. Vascular access for hemodialysis in the elderly. *J Vasc Surg*. 2011;53(4):1039–43.
- [149] Watorek E, Golebiowski T, Kuształ M, Letachowicz K, Letachowicz W, Augustyniak Bartosik H, et al. Creation of arteriovenous fistulae for hemodialysis in octogenarians. *Hemodial Int*. 2014;18(1):113–7.
- [150] Sladoje-Martinovic B, Mikolasevic I, Bubic I, Racki S, Orlic L. Survival of chronic hemodialysis patients over 80 years of age. *Clin Interv Aging*. 2014;9:689–96.
- [151] Patibandla BK, Narra A, Desilva R, Chawla V, Vin Y, Brown RS, et al. Disparities in arteriovenous fistula placement in older hemodialysis patients. *Hemodial Int*. 2014;18(1):118–26.
- [152] Goldfarb-Rumyantzev AS, Syed W, Patibandla BK, Narra A, Desilva R, Chawla V, et al. Geographic disparities in arteriovenous fistula placement in patients approaching hemodialysis in the United States. *Hemodial Int*. 2014;18(3):686–94.
- [153] Trepanier P, Quach C, Gonzales M, Fortin E, Kaouache M, Desmeules S, et al. Survey of infection control practices in hemodialysis units: preventing vascular access-associated bloodstream infections. *Infect Control Hosp Epidemiol*. 2014;35(7):833–8.
- [154] Bai YL, Hung SY, Chiou CP. Vascular access management and education for hemodialysis patients. *Hu Li Za Zhi*. 2014;61(1):93–8.
- [155] Saucy F, Deglise S, Holzer T, Salomon L, Engelberger S, Corpataux JM. Intraoperative assessment of vascular access. *J Vasc Access*. 2014;15 (Suppl 7):S6–9.

- [156] Kamper L, Frahnert M, Grebe SO, Haage P. Radiological assessment of vascular access in haemodialysis patients. *J Vasc Access*. 2014;15 (Suppl 7):S33–7.
- [157] Remuzzi A, Manini S. Computational model for prediction of fistula outcome. *J Vasc Access*. 2014;15 (Suppl 7):S64–9.
- [158] Gallieni M, Brenna I, Brunini F, Mezzina N, Pasho S, Fornasieri A. Which cannulation technique for which patient. *J Vasc Access*. 2014;15 (Suppl 7):S85–90.
- [159] Wong B, Muneer M, Wiebe N, Storie D, Shurraw S, Pannu N, et al. Buttonhole versus rope-ladder cannulation of arteriovenous fistulas for hemodialysis: a systematic review. *Am J Kidney Dis*. 2014.
- [160] Muir CA, Kotwal SS, Hawley CM, Polkinghorne K, Gallagher MP, Snelling P, et al. Buttonhole cannulation and clinical outcomes in a home hemodialysis cohort and systematic review. *Clin J Am Soc Nephrol*. 2014;9(1):110–9.
- [161] Raja RM, Fernandes M, Kramer MS, Barber K, Rosenbaum JL. Comparison of subclavian vein with femoral vein catheterization for hemodialysis. *Am J Kidney Dis*. 1983;2(4):474–6.
- [162] Fan PY. Acute vascular access: new advances. *Adv Ren Replace Ther*. 1994;1(2):90–8.
- [163] Vanholder R, Lameire N, Verbanck J, van Rattinthe R, Kunnen M, Ringoir S. Complications of subclavian catheter hemodialysis: a 5 year prospective study in 257 consecutive patients. *Int J Artif Organs*. 1982;5(5):297–303.
- [164] Edwards H, King TC. Cardiac tamponade from central venous catheters. *Arch Surg*. 1982;117(7):965–7.
- [165] Geddes CC, Walbaum D, Fox JG, Mactier RA. Insertion of internal jugular temporary hemodialysis cannulae by direct ultrasound guidance—a prospective comparison of experienced and inexperienced operators. *Clin Nephrol*. 1998;50(5):320–5.
- [166] Hernandez D, Diaz F, Rufino M, Lorenzo V, Perez T, Rodriguez A, et al. Subclavian vascular access stenosis in dialysis patients: natural history and risk factors. *J Am Soc Nephrol*. 1998;9(8):1507–10.
- [167] Cimochoowski GE, Worley E, Rutherford WE, Sartain J, Blondin J, Harter H. Superiority of the internal jugular over the subclavian access for temporary dialysis. *Nephron*. 1990;54(2):154–61.
- [168] Zadeh MK, Shirvani A. The role of routine chest radiography for detecting complications after central venous catheter insertion. *Saudi J Kidney Dis Transpl*. 2014;25(5):1011–6.
- [169] Daeihagh P, Jordan J, Chen J, Rocco M. Efficacy of tissue plasminogen activator administration on patency of hemodialysis access catheters. *Am J Kidney Dis*. 2000;36(1):75–9.

- [170] Schwab SJ, Quarles LD, Middleton JP, Cohan RH, Saeed M, Dennis VW. Hemodialysis-associated subclavian vein stenosis. *Kidney Int.* 1988;33(6):1156–9.
- [171] Newman GE, Saeed M, Himmelstein S, Cohan RH, Schwab SJ. Total central vein obstruction: resolution with angioplasty and fibrinolysis. *Kidney Int.* 1991;39(4):761–4.
- [172] Oliver MJ, Callery SM, Thorpe KE, Schwab SJ, Churchill DN. Risk of bacteremia from temporary hemodialysis catheters by site of insertion and duration of use: a prospective study. *Kidney Int.* 2000;58(6):2543–5.
- [173] Ishani A, Collins AJ, Herzog CA, Foley RN. Septicemia, access and cardiovascular disease in dialysis patients: the USRDS Wave 2 study. *Kidney Int.* 2005;68(1):311–8.
- [174] Dahlberg PJ, Yutuc WR, Newcomer KL. Subclavian hemodialysis catheter infections. *Am J Kidney Dis.* 1986;7(5):421–7.
- [175] Nielsen J, Kolmos HJ, Espersen F. *Staphylococcus aureus* bacteraemia among patients undergoing dialysis—focus on dialysis catheter-related cases. *Nephrol Dial Transplant.* 1998;13(1):139–45.
- [176] Nielsen J, Ladefoged SD, Kolmos HJ. Dialysis catheter-related septicaemia—focus on *Staphylococcus aureus* septicaemia. *Nephrol Dial Transplant.* 1998;13(11):2847–52.
- [177] Ravani P, Gillespie BW, Quinn RR, MacRae J, Manns B, Mendelssohn D, et al. Temporal risk profile for infectious and noninfectious complications of hemodialysis access. *J Am Soc Nephrol.* 2013;24(10):1668–77.
- [178] Schindler R, Heemann U, Haug U, Stoelck B, Karatas A, Pohle C, et al. Bismuth coating of non-tunneled haemodialysis catheters reduces bacterial colonization: a randomized controlled trial. *Nephrol Dial Transplant.* 2010;25(8):2651–6.
- [179] O’Grady NP, Alexander M, Burns LA, Dellinger EP, Garland J, Heard SO, et al. Summary of recommendations: Guidelines for the Prevention of Intravascular Catheter-related Infections. *Clin Infect Dis.* 2011;52(9):1087–99.
- [180] Moore CL, Besarab A, Ajluni M, Soi V, Peterson EL, Johnson LE, et al. Comparative effectiveness of two catheter locking solutions to reduce catheter-related bloodstream infection in hemodialysis patients. *Clin J Am Soc Nephrol.* 2014;9(7):1232–9.
- [181] Grimaldi R. The centrality of the nurse in the prevention of the infections in hemodialysis. *G Ital Nefrol.* 2014;31(3).
- [182] Parienti JJ, Thirion M, Megarbane B, Souweine B, Ouchikhe A, Polito A, et al. Femoral vs jugular venous catheterization and risk of nosocomial events in adults requiring acute renal replacement therapy: a randomized controlled trial. *JAMA.* 2008;299(20):2413–22.
- [183] Kairaitis LK, Gottlieb T. Outcome and complications of temporary haemodialysis catheters. *Nephrol Dial Transplant.* 1999;14(7):1710–4.

- [184] Mermel LA, Farr BM, Sherertz RJ, Raad, II, O'Grady N, Harris JS, et al. Guidelines for the management of intravascular catheter-related infections. *J Intraven Nurs.* 2001;24(3):180–205.
- [185] George A, Tokars JL, Clutterbuck EJ, Bamford KB, Pusey C, Holmes AH. Reducing dialysis associated bacteraemia, and recommendations for surveillance in the United Kingdom: prospective study. *BMJ.* 2006;332(7555):1435.
- [186] Shingarev R, Barker-Finkel J, Allon M. Association of hemodialysis central venous catheter use with ipsilateral arteriovenous vascular access survival. *Am J Kidney Dis.* 2012;60(6):983–9.
- [187] Beathard GA. Strategy for maximizing the use of arteriovenous fistulae. *Semin Dial.* 2000;13(5):291–6.
- [188] Bashar K, Clarke-Moloney M, Walsh SR. Pre-operative ultrasonography and arteriovenous fistulae maturation. *J Vasc Access.* 2014;15 (Suppl 7):S60–3.
- [189] Shemesh D, Raikhinstein Y, Orkin D, Goldin I, Olsha O. Anesthesia for vascular access surgery. *J Vasc Access.* 2014;15 (Suppl 7):S38–44.
- [190] Macfarlane AJ, Kearns RJ, Aitken E, Kinsella J, Clancy MJ. Does regional compared to local anaesthesia influence outcome after arteriovenous fistula creation? *Trials.* 2013;14:263.
- [191] Beathard GA, Settle SM, Shields MW. Salvage of the nonfunctioning arteriovenous fistula. *Am J Kidney Dis.* 1999;33(5):910–6.
- [192] Beathard GA, Arnold P, Jackson J, Litchfield T. Aggressive treatment of early fistula failure. *Kidney Int.* 2003;64(4):1487–94.
- [193] Romero A, Polo JR, Garcia Morato E, Garcia Sabrido JL, Quintans A, Ferreiroa JP. Salvage of angioaccess after late thrombosis of radiocephalic fistulas for hemodialysis. *Int Surg.* 1986;71(2):122–4.
- [194] Hod T, Desilva RN, Patibandla BK, Vin Y, Brown RS, Goldfarb-Rumyantzev AS. Factors predicting failure of AV “fistula first” policy in the elderly. *Hemodial Int.* 2014;18(2):507–15.
- [195] Lin CT, Dai NT, Chen SG, Chang SC. Acute forearm compartment syndrome following haemodialysis access fistula puncture in uraemia. *ANZ J Surg.* 2014.
- [196] Belli S, Yabanoglu H, Aydogan C, Parlakgumus A, Yildirim S, Haberal M. Surgical interventions for late complications of arteriovenous fistulas. *Int Surg.* 2014;99(4):467–74.
- [197] Decorato I, Kharboutly Z, Legallais C, Salsac AV. Comparison of two endovascular treatments of a stenosed arteriovenous fistula: balloon-angioplasty with and without stenting. *Int J Artif Organs.* 2014;0(0):0.

- [198] Aftab SA, Tay KH, Irani FG, Gong Lo RH, Gogna A, Haaland B, et al. Randomized clinical trial of cutting balloon angioplasty versus high-pressure balloon angioplasty in hemodialysis arteriovenous fistula stenoses resistant to conventional balloon angioplasty. *J Vasc Interv Radiol*. 2014;25(2):190–8.
- [199] Wu CC, Huang PH, Lai CL, Leu HB, Chen JW, Lin SJ. The impact of endothelial progenitor cells on restenosis after percutaneous angioplasty of hemodialysis vascular access. *PLoS One*. 2014;9(6):e101058.
- [200] Turmel-Rodrigues L, Pengloan J, Baudin S, Testou D, Abaza M, Dahdah G, et al. Treatment of stenosis and thrombosis in haemodialysis fistulas and grafts by interventional radiology. *Nephrol Dial Transplant*. 2000;15(12):2029–36.
- [201] Palmer SC, Di Micco L, Razavian M, Craig JC, Ravani P, Perkovic V, et al. Antiplatelet therapy to prevent hemodialysis vascular access failure: systematic review and meta-analysis. *Am J Kidney Dis*. 2013;61(1):112–22.
- [202] Tessitore N, Bedogna V, Poli A, Lipari G, Pertile P, Baggio E, et al. Should current criteria for detecting and repairing arteriovenous fistula stenosis be reconsidered? Interim analysis of a randomized controlled trial. *Nephrol Dial Transplant*. 2014;29(1):179–87.
- [203] Lu FP, Liu LP, Lu ZX. One-year patency rate of native arteriovenous fistulas reconstructed by vascular stripping in hemodialysis patients with venous neointimal hyperplasia. *J Vasc Surg*. 2014.
- [204] Beathard GA. Physical examination: the forgotten tool. In: Gray RJ, Sands JJ, editors. *Dialysis Access: A Multidisciplinary Approach*. Lippincott Williams & Wilkins; 2002. pp. 111–228.
- [205] Patel MS, Street T, Davies MG, Peden EK, Naoum JJ. Evaluating and treating venous outflow stenoses is necessary for the successful open surgical treatment of arteriovenous fistula aneurysms. *J Vasc Surg*. 2014.
- [206] Hossny A. Partial aneurysmectomy for salvage of autogenous arteriovenous fistula with complicated venous aneurysms. *J Vasc Surg*. 2014;59(4):1073–7.
- [207] Sigala F, Kontis E, Sassen R, Mickley V. Autologous surgical reconstruction for true venous hemodialysis access aneurysms-techniques and results. *J Vasc Access*. 2014;0(0):0.
- [208] KDOQI. Guideline 5. Treatment of Fistula Complications. 2006.
- [209] Stevenson KB. Management of hemodialysis vascular access infection. In: Gray RJ, Sands JJ, editors. *Dialysis Access: A Multidisciplinary Approach* Philadelphia, PA: Lippincott Williams & Wilkins; 2002. pp. 98–106.
- [210] Swedberg SH, Brown BG, Sigley R, Wight TN, Gordon D, Nicholls SC. Intimal fibromuscular hyperplasia at the venous anastomosis of PTFE grafts in hemodialysis pa-



tients. Clinical, immunocytochemical, light and electron microscopic assessment. *Circulation*. 1989;80(6):1726–36.

- [211] Roy-Chaudhury P, Kelly BS, Miller MA, Reaves A, Armstrong J, Nanayakkara N, et al. Venous neointimal hyperplasia in polytetrafluoroethylene dialysis grafts. *Kidney Int*. 2001;59(6):2325–34.
- [212] Paszkowiak JJ, Dardik A. Arterial wall shear stress: observations from the bench to the bedside. *Vasc Endovascular Surg*. 2003;37(1):47–57.
- [213] Corpataux JM, Haesler E, Silacci P, Ris HB, Hayoz D. Low-pressure environment and remodelling of the forearm vein in Brescia–Cimino haemodialysis access. *Nephrol Dial Transplant*. 2002;17(6):1057–62.
- [214] Misra S, Bonan R, Pflederer T, Roy-Chaudhury P. BRAVO I: a pilot study of vascular brachytherapy in polytetrafluoroethylene dialysis access grafts. *Kidney Int*. 2006;70(11):2006–13.
- [215] Cai X, Freedman NJ. New therapeutic possibilities for vein graft disease in the post-edifoligide era. *Future Cardiol*. 2006;2(4):493–501.
- [216] Conte MS, Bandyk DF, Clowes AW, Moneta GL, Seely L, Lorenz TJ, et al. Results of PREVENT III: a multicenter, randomized trial of edifoligide for the prevention of vein graft failure in lower extremity bypass surgery. *J Vasc Surg*. 2006;43(4):742–51; discussion 51.
- [217] Melhem M, Kelly B, Zhang J, Kasting G, Li J, Davis H, et al. Development of a local perivascular paclitaxel delivery system for hemodialysis vascular access dysfunction: polymer preparation and in vitro activity. *Blood Purif*. 2006;24(3):289–98.
- [218] Rotmans JJ, Heyligers JM, Verhagen HJ, Velema E, Nagtegaal MM, de Kleijn DP, et al. In vivo cell seeding with anti-CD34 antibodies successfully accelerates endothelialization but stimulates intimal hyperplasia in porcine arteriovenous expanded polytetrafluoroethylene grafts. *Circulation*. 2005;112(1):12–8.
- [219] Beathard GA. Angioplasty for arteriovenous grafts and fistulae. *Semin Nephrol*. 2002;22(3):202–10.
- [220] Bachleda P, Utikal P, Kocher M, Cerna M, Fialova J, Kalinova L. Arteriovenous graft for hemodialysis, graft venous anastomosis closure—current state of knowledge. Minireview. *Biomedical papers of the Medical Faculty of the University Palacky, Olomouc, Czechoslovakia*. 2014.
- [221] Vesely TM. Endovascular intervention for the failing vascular access. *Adv Ren Replace Ther*. 2002;9(2):99–108.
- [222] Sreenarasimhaiah VP, Margassery SK, Martin KJ, Bander SJ. Salvage of thrombosed dialysis access grafts with venous anastomosis stents. *Kidney Int*. 2005;67(2):678–84.

- [223] McNally A, Akingba AG, Robinson EA, Sucosky P. Novel modular anastomotic valve device for hemodialysis vascular access: preliminary computational hemodynamic assessment. *J Vasc Access*. 2014;0(0):0.
- [224] Planken RN, van Kesteren F, Reekers JA. Treatment of hemodialysis vascular access arteriovenous graft failure by percutaneous intervention. *J Vasc Access*. 2014;15 (Suppl 7):S114–9.
- [225] Saleh HM, Gabr AK, Tawfik MM, Abouellail H. Prospective, randomized study of cutting balloon angioplasty versus conventional balloon angioplasty for the treatment of hemodialysis access stenoses. *J Vasc Surg*. 2014;60(3):735–40.
- [226] Troisi N, Chisci E, Frosini P, Romano E, Setti M, Mingardi G, et al. Hybrid simultaneous treatment of thrombosed prosthetic grafts for hemodialysis. *J Vasc Access*. 2014;0(0):0.
- [227] May RE, Himmelfarb J, Yenicesu M, Knights S, Ikizler TA, Schulman G, et al. Predictive measures of vascular access thrombosis: a prospective study. *Kidney Int*. 1997;52(6):1656–62.
- [228] Vesely TM. Mechanical thrombectomy devices to treat thrombosed hemodialysis grafts. *Tech Vasc Interv Radiol*. 2003;6(1):35–41.
- [229] Taylor G, Gravel D, Johnston L, Embil J, Holton D, Paton S. Prospective surveillance for primary bloodstream infections occurring in Canadian hemodialysis units. *Infect Control Hosp Epidemiol*. 2002;23(12):716–20.
- [230] Kaplowitz LG, Comstock JA, Landwehr DM, Dalton HP, Mayhall CG. Prospective study of microbial colonization of the nose and skin and infection of the vascular access site in hemodialysis patients. *J Clin Microbiol*. 1988;26(7):1257–62.
- [231] KDOQI. Guideline 27: Treatment of pseudoaneurysm of dialysis AV grafts.
- [232] Schanzer H, Schwartz M, Harrington E, Haimov M. Treatment of ischemia due to “steal” by arteriovenous fistula with distal artery ligation and revascularization. *J Vasc Surg*. 1988;7(6):770–3.
- [233] Modaghegh MH, Kazemzadeh G, Pezeshki Rad M, Ravari H, Hafezi S, El-Husheimi A, et al. Chronic hemodialysis access-induced distal ischemia (HAIDI): distinctive form of a major complication. *J Vasc Access*. 2014;0(0):0.
- [234] Hye RJ, Wolf YG. Ischemic monomelic neuropathy: an under-recognized complication of hemodialysis access. *Ann Vasc Surg*. 1994;8(6):578–82.
- [235] Grapsa Irene OD. Dialysis in the elderly. In: Horl HW, Lindsay BR, Ronco C, Winchester FJ, editors. *Replacement of Renal Function by Dialysis*. 5th ed. Kluwer Academic Publishers; 2004.

- [236] Valliant AM, Chaudhry MK, Yevzlin AS, Astor B, Chan MR. Tunneled dialysis catheter exchange with fibrin sheath disruption is not associated with increased rate of bacteremia. *J Vasc Access*. 2014;0(0):0.
- [237] Yoon WJ, Lorelli DR. Two-stage hemodialysis reliable outflow (HeRO) graft implantation technique that avoids the use of a femoral bridging dialysis catheter. *J Vasc Access*. 2014;0(0):0.
- [238] Hoen B, Kessler M, Hestin D, Mayeux D. Risk factors for bacterial infections in chronic haemodialysis adult patients: a multicentre prospective survey. *Nephrol Dial Transplant*. 1995;10(3):377–81.
- [239] Combe C, Pisoni RL, Port FK, Young EW, Canaud B, Mapes DL, et al. Dialysis outcomes and practice patterns study: data on the use of central venous catheters in chronic hemodialysis. *Nephrologie*. 2001;22(8):379–84.
- [240] Jaffer Y, Selby NM, Taal MW, Fluck RJ, McIntyre CW. A meta-analysis of hemodialysis catheter locking solutions in the prevention of catheter-related infection. *Am J Kidney Dis*. 2008;51(2):233–41.
- [241] Zhao Y, Li Z, Zhang L, Yang J, Yang Y, Tang Y, et al. Citrate versus heparin lock for hemodialysis catheters: a systematic review and meta-analysis of randomized controlled trials. *Am J Kidney Dis*. 2014;63(3):479–90.
- [242] Fdez-Gallego J, Martin M, Gutierrez E, Cobelo C, Frias P, Jironda C, et al. Prophylaxis with gentamicin reduces bacterial infection morbidity and mortality related to permanent tunneled central venous catheter and does not cause bacterial resistance. *Nefrologia*. 2011.
- [243] Murray EC, Deighan C, Geddes C, Thomson PC. Taurolidine-citrate-heparin catheter lock solution reduces staphylococcal bacteraemia rates in haemodialysis patients. *QJM*. 2014;107(12):995–1000.
- [244] Fontseré N, Cardozo C, Donat J, Soriano A, Muros M, Pons M, et al. Tunneled catheters with taurolidine–citrate–heparin lock solution significantly improve the inflammatory profile of hemodialysis patients. *Antimicrob Agents Chemother*. 2014;58(7):4180–4.
- [245] Del Pozo JL, Aguinaga A, Garcia-Fernandez N, Hernaez S, Serrera A, Alonso M, et al. Intra-catheter leukocyte culture to monitor hemodialysis catheter colonization. A prospective study to prevent catheter-related bloodstream infections. *Int J Artif Organs*. 2008;31(9):820–6.
- [246] Lawrence JA, Seiler S, Wilson B, Harwood L. Shower and no-dressing technique for tunneled central venous hemodialysis catheters: a quality improvement initiative. *Nephrol Nurs J*. 2014;41(1):67–72; quiz 3.

- [247] Evans EC, Hain D, Kear TM, Dork LA, Schrauf C. Hemodialysis catheter outcomes pilot study: no dressing coverage with prescribed showering. *Nephrol Nurs J.* 2014;41(1):53–64; 72; quiz 65.
- [248] Gillies D, O’Riordan L, Carr D, Frost J, Gunning R, O’Brien I. Gauze and tape and transparent polyurethane dressings for central venous catheters. *Cochrane Database Syst Rev.* 2003(4):CD003827.