

# We are IntechOpen, the world's leading publisher of Open Access books Built by scientists, for scientists

6,900

Open access books available

185,000

International authors and editors

200M

Downloads

Our authors are among the

154

Countries delivered to

TOP 1%

most cited scientists

12.2%

Contributors from top 500 universities



WEB OF SCIENCE™

Selection of our books indexed in the Book Citation Index  
in Web of Science™ Core Collection (BKCI)

Interested in publishing with us?  
Contact [book.department@intechopen.com](mailto:book.department@intechopen.com)

Numbers displayed above are based on latest data collected.  
For more information visit [www.intechopen.com](http://www.intechopen.com)



---

# **Haemosuccus Pancreaticus in Chronic Pancreatitis — Diagnosis and Treatment**

---

Hiroataka Okamoto and Hideki Fujii

Additional information is available at the end of the chapter

<http://dx.doi.org/10.5772/58952>

---

## **1. Introduction**

Obscure gastrointestinal bleeding (OGBI) has been defined as persistent or recurrent bleeding from the gastrointestinal tract, even though initial gastrointestinal- and colon-endoscopy or small bowel radiological imaging were performed for initial evaluation [1].

In 10-20% of cases of patients who present with gastrointestinal bleeding, the underlying etiology may not be evident on initial evaluation. About half of these patients were observed in recurrent or persistent bleeding and had to need the further challenge to both diagnosis and management. The underlying etiology often remains difficult to define, despite extensive examinations. This fact results in recurrent hospitalization and multiple blood transfusions [2, 3].

Hemosuccus Pancreaticus is known to be a cause of OGIB. Lower and Farrel first reported that blood was expelled into the duodenum via the main pancreatic duct [4]. The term 'hemosuccus pancreaticus' was coined by Sandblom in 1970 [5]. Hemoductal pancreaticus was proposed by Longmire and Rose in 1973 [6]. These terms describe the emission of red blood cells along pancreatic ducts through the papilla.

Diagnosis of hemosuccus pancreaticus is often difficult because the condition involves intermittent gastrointestinal bleeding. In this paper, we describe two rare cases of hemosuccus pancreaticus from our clinical experience and discuss the diagnosis and pathogenesis of this disease with a review of the literature.

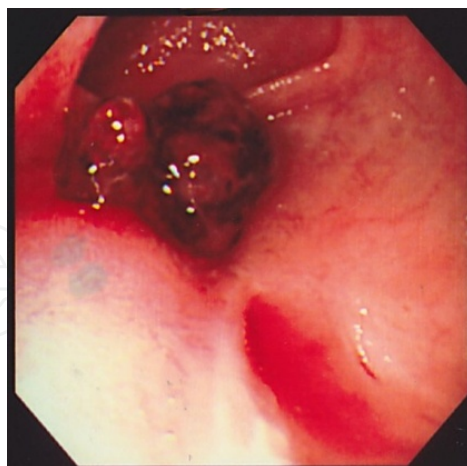
## 2. Case reports

### 2.1. Case report 1

A 47-year-old Japanese male had a past history of peritoneal drainage for acute necrotizing pancreatitis at 23 years of age and a lateral pancreaticojejunostomy (Puestow procedure) for chronic pancreatitis at age 31. The patient experienced several episodes of tarry stools following the Puestow operation. Physical examination on admission revealed severe conjunctiva pallor and tarry stools.

Emergent gastrointestinal fiberscopy was performed, and no abnormal lesions were found in the stomach or duodenum. Hemorrhagic scintigraphy and abdominal computed tomography (CT) were also carried out, but no hemorrhagic lesions were found. After blood transfusion, total colonoscopy was performed via insertion up to the terminal ileum, which also revealed no abnormal lesions. Although interventional radiology was considered as a treatment option, hemostasis seemed possible through conservative therapy alone. The bleeding point was assumed to be in the upper jejunum, including the reconstructed jejunum.

Two week later, more tarry stools occurred, the patient went into hemodynamic shock and subsequently underwent laparotomy without delay. After inspection of the whole abdomen, the intestine was found to contain coagulated blood in the upper jejunum. Intra-operative endoscopy through an incision in the reconstructed jejunal loop at the close proximal end revealed massive bleeding. After suction of the bleeding and coagulation clots, an active bleeding site from the side-to-side anastomotic pancreatic duct became clear (Fig. A). Longitudinal jejunotomy was performed, and the bleeding point was sutured and ligated [7].



**Figure 1.** Active bleeding from side-to-side pancreaticojejunostomy

### 2.2. Case report 2

A 45-year-old Japanese male had been treated by medication for chronic pancreatitis and gastroduodenal peptic ulcer. The patient had a complaint of hematemesis and emergent

gastrointestinal endoscopy revealed massive duodenal bleeding. Emergent distal gastrectomy was performed. After discharge, he had epigastric pain and was re-admitted with a diagnosis of chronic pancreatitis. Abdominal CT revealed splenomegaly and a pancreatic cyst in the pancreatic tail. Angiography revealed aneurysm of the distal pancreatic artery. Distal pancreatectomy and splenectomy were performed. The resected specimen included was a pseudocyst filled with a blood clot in the pancreatic tail, and it communicated with the main pancreatic duct. Furthermore, the splenic artery had ruptured into the pseudocyst [8].

### 3. Diagnosis

#### 3.1. Symptoms

The usual presentation of hemosuccus pancreaticus is the development of symptoms of upper or lower gastrointestinal bleeding, such as hematemesis, vomiting of bloody contents, melena, tarry stool, hematochezia, or fresh rectal bleeding. The feature of gastrointestinal bleeding is that it is intermittent, waxing and waning. The bleeding source is not determined by standard endoscopic technique as usual. The symptoms of this condition are categorized as a cause of obscure overt gastrointestinal hemorrhage. Obscure gastrointestinal bleeding (OGIB) has been defined as persistent or recurrent gastrointestinal bleeding, after negative initial examinations.

More than one half patients with hemosuccus pancreaticus also have symptoms as abdominal pain, usually located in the epigastric lesion or upper part of the abdomen. The characteristics of the pain is like being crescendo-decrescendo in nature, meaning that it slowly increases and decreases in intensity with time. This symptom is thought to be due to transient blockage and increasing pressure of the pancreatic duct from the source of bleeding or clots [9].

Upper abdominal pain	intermittent crescendo-decrescendo
Upper gastrointestinal bleeding	hematemesis vomiting of bloody contents
Lower gastrointestinal bleeding	melena tarry stool hematochezia fresh rectal bleeding

Table 1. Symptom of Hemosuccus Pancreaticus

#### 3.2. OGIB: Obscure Gastrointestinal Bleeding

Obscure gastrointestinal bleeding (OGIB) has been defined as persistent or recurrent gastrointestinal bleeding after negative initial evaluation by pan-endoscope and radiological small intestinal imaging [9]. On initial endoscopic evaluation with standard endoscopy, such as esophago-gastroduodenoscopy and colonoscopy, as well as the limited capacity of endos-

copy to examine the small bowel the main challenges related to the evaluation of OGBI include the high miss rate for lesions. Therefore, the management of these patients has traditionally required invasive procedures such as intra-operative enteroscopy and exploratory laparotomy. The technological advances such as the introduction of video capsule endoscopy, single and double balloon enteroscopy, spiral enteroscopy, CT enterography can overcome the limitation of old diagnostic modalities.

3.3. Diagnostic features

Hemosuccus pancreaticus is known to be a cause of OGIB. It is often difficult to diagnose hemosuccus pancreaticus because the bleeding is usually intermittent. Endoscopy represents the first diagnostic step in patients with upper gastrointestinal bleeding. Although it is essential to rule out other causes of bleeding such as peptic ulcers, esophageal, and gastric varices, endoscopy rarely identifies blood in the ampulla of Vater. Pancreatic pseudocysts or aneurysms of peripancreatic arteries can be visualize by ultrasonography. Doppler ultrasound and dynamic ultrasound have been also reported to be useful diagnostic modalities [10, 11]. And contrast-enhanced CT is an further excellent modality for demonstrating the feature of chronic pancreatitis, pseudocysts and pseudoaneurysm [12, 13]. Selective angiography of the celiac axis and the superior mesenteric artery provides formal proof of hemosuccus pancreaticus by opacifying the main pancreatic duct, the presence of an aneurysm or pseudo-aneurysm with a high sensitivity [14].(Table 2) Diagnosis of hemosuccus pancreaticus accomplished by advanced technologies such as video capsule endoscopy, single-and double-balloon enteroscopy, spiral enteroscopy, and computed tomography enterography has not been reported until now. These advanced technologies provide vital information for the diagnosis of hemosuccus pancreaticus.

---

Esophago-gastro-duodenoscopy
Side-viewing upper gastrointestinal endoscopy
Doppler or dynamic ultrasound
Contrast-enhanced CT
Angiography

---

Table 2. Diagnostic Modalities of Hemosuccus Pancreaticus

4. Pathogenesis and etiology

Hemosuccus pancreaticus complicates an underlying pancreatic disease in 80% of cases and vascular anomaly in 20% of cases [15]. Chronic pancreatitis is the cause of about 90% of pancreatic diseases [15, 16]. Several mechanisms are thought to be involved. A pseudocyst is thought to be one of causes of hemosuccus pancreaticus, because of hemorrhagic pseudocyst or communication of cyst to pericystic artery. Arterial aneurysm and pseudo-aneurysm are

also known to be a cause of hemosuccus pancreaticus. These aneurysms are frequent in about 10 % in chronic pancreatitis. Vascular ulceration by pancreatic intraductal stone is also thought to be a cause of hemosuccus pancreaticus [10, 18]. Although aneurysm and chronic pancreatitis are often associated, there is no clear causal relationship. Other causes of hemosuccus pancreaticus are rare: neuroendocrine tumor [15], intraductal papillary-mucinous carcinoma [19], ectopic pancreas [20], pancreas divisum [21], and Puestow procedure [7]. Finally, hemosuccus pancreaticus can result from a post ERCP (endoscopic retrograde cholangiopancreatography) complication. As for acute pancreatitis, hemosuccus pancreaticus can occur after necrosis of the adjacent arterial wall such as gastroduodenal artery, splenic artery, pancreaticoduodenal arcade. The pathogenesis and etiology are summarized in Table 3.

Chronic pancreatitis
Acute pancreatitis
Pancreatic cysts
Pancreatic tumor
Ectopic pancreas
Pancreas divisum
Arterial aneurysm or pseudoaneuysm
Iatrogenic, (ERCP, operation)

**Table 3.** Pathogenesis and Etiology of Hemosuccus Pancreaticus

**5. Management and treatment**

The management for hemosuccus pancreaticus should be aimed at completely eradicating the source of bleeding. Three therapeutic options are considered for this disorder: endoscopic treatment, angiographic embolization, and surgery have been documented. Endoscopic treatment was used in a rare case in which hemosuccus pancreaticus caused by post ERCP pancreatitis was treated by endoscopic stent tree tamponade [22]. Interventional radiographic methods are chosen for initial treatment when the hemodynamic situations is under control. The treatment response rate was 67% to 100% of cases [23-25]. Most hemosuccus pancreaticus cases can receive angiography. If the source of hemorrhage is found by angiography, interventional radiological therapy should be done following this examination. Interventional radiological therapy by implantation of an uncoated metal Palmaz stent across the aneurysmal segment of splenic artery is also reported [26]. Transcatheter arterial embolization was reported to be effective for hemosuccus pancreaticus treatment [27-29]. However, ischemia also can develop in the tissue supplied by the artery if the collateral circulation is not sufficient, and other complications of aneurysm infection and splenic infarction may arise. Sources bleeding from a pseudoaneurysm were reported to arise from the splenic artery in most cases but also the gastroduodenal artery, from the branch of the superior pancreaticoduodenal



artery, from the branch of the inferior pancreaticoduodenal artery, from the superior mesenteric artery or vein, and from an unnamed intracystic artery [30]. Some authors documented that recurrent bleeding rates were about 30% [12]. Thus, arterial embolization is recommended as the initial therapeutic method, either to stabilize the patient to perform elective surgery or as a definitive treatment where possible [31, 32].

Surgical treatment is indicated in uncontrolled hemorrhage, persistent shock, where embolization is not feasible or when embolization fails. Ligation of the pancreatic duct is one of the surgical approaches, but results are unsatisfactory because the causal lesion remains intact. Ligation of the causal artery is more effective but does not remove the risk of recurrence. Pancreatic resection such as distal pancreatectomy, central pancreatectomy, or pancreaticoduodenectomy treats both the pancreatic and the arterial diseases. Distal pancreatectomy is indicative for bleeding pseudoaneurysms in the body or tail of the pancreas. When the location of the pseudoaneurysm is the head of the pancreas, pancreaticoduodenectomy is chosen. However, increased mortality and morbidity have been reported, and consequently angioembolization alone has been proposed as the recommended treatment modality [25, 26, 31, 32]. Bleeding from the pancreaticoduodenal artery has a higher mortality rate than bleeding from the splenic or gastroduodenal artery [31, 32]. Most patients suffer from chronic pancreatitis so the potential perioperative complications and postoperative pancreatic insufficiency should be noted. Most surgical series have documented success rates of 70% to 85% with mortality rates of 20% to 25% and rebleeding rates of 0% to 5% [31-34]. The treatment options are summarized in Table 4.

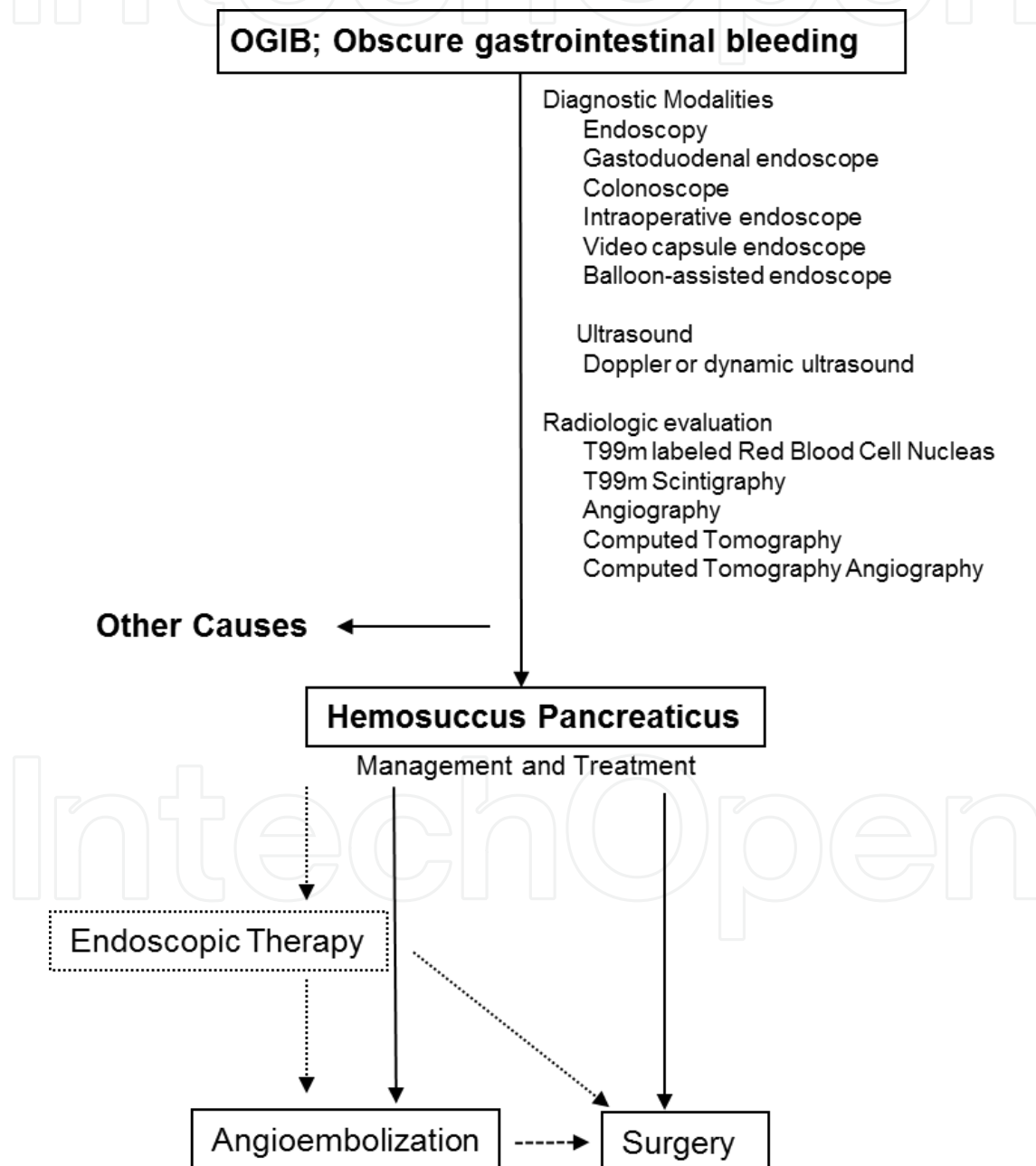
Endoscopic therapy
Stent tamponade
Angioembolization
Surgery
Ligation of bleeding vessel
Pancreaticoduodenectomy
Central pancreatectomy
Distal pancreatectomy

Table 4. Treatment of Hemosuccus Pancreaticus

6. Conclusion

A flow chart for management of hemosuccus pancreaticus is shown in Figure 1. Hemosuccus pancreaticus is a rare and potentially life threatening clinical entity. It is the least frequent cause of upper gastrointestinal bleeding and is most often caused by chronic pancreatitis. Its diagnosis is difficult because of its rarity and its anatomical location as well as its intermitted

bleeding. During the intermitted phase, it cannot be diagnosed by the upper gastrointestinal endoscope. The timely diagnosis is often delayed because of the intermitted nature of bleeding. Therapeutic options consist of embolization, stenting, endoscopic stenting, and surgery. Endovascular therapy by embolization is effective in most patients, although to achieve a complete cure there is no consensus on the need for surgery. Embolization can control unstable haemodynamics. Emergent surgery is required in patients with recurrent bleeding or failed first-line therapies such as embolization or stenting.



**Figure 2.** Flowchart for the management of hemosuccus pancreaticus



## Author details

Hiroataka Okamoto<sup>1,2\*</sup> and Hideki Fujii<sup>2</sup>

\*Address all correspondence to: [hirotaka@yamanashi.ac.jp](mailto:hirotaka@yamanashi.ac.jp)

<sup>1</sup> Department of Surgery, Tsuru Municipal Hospital, Japan

<sup>2</sup> Department of Gastrointestinal, Breast & Endocrine Surgery, Faculty of Medicine, University of Yamanashi, Japan

## References

- [1] Raju GS, Gerson L, Das A, Lewis B. American Gastroenterological Association (AGA) Institute technical review on obscure gastrointestinal bleeding. *Gastroenterology*. 2007;133:1697-1717.
- [2] Thompson JN, Salem RR, Hemingway AP, Rees HC, Hodgson HJ, et al. Specialist investigation of obscure gastrointestinal bleeding. *Gut*. 1987;28:47-51.
- [3] Lin S, Rockey DC. Obscure gastrointestinal bleeding. *Gastroenterol Clin North Am*. 2005;34:679-698.
- [4] Lower WE, Farred JJ: Aneurysm of the splenic artery. Report of a case and review of literature. *Arch Surg*. 1931;23:182-190.
- [5] Sandblom P: Gastrointestinal hemorrhage through the pancreatic duct. *Ann Surg*. 1970;171:61-66.
- [6] Longmire WP, Rose AS. Hemoductal pancreatitis. *Surg Gynecol Obstet*. 1973;136:246-250.
- [7] Okamoto H, Miura K, Fujii H. Hemosuccus pancreaticus following a Puestow procedure in a patient with chronic pancreatitis. *Case Rep Gastroenterol*. 2011;5:452-456.
- [8] Iino H, Shirasu T, Karikome K, et al. A case of chronic pancreatitis with hemosuccus pancreaticus and left-sided portal hypertension. *Jpn J Gastroenterol Surg*. 1994;27:2461-2465.
- [9] Clay R, Farnell M, Lancaster J, Weiland L, Gostout C. Hemosuccus pancreaticus. An usual cause of upper gastrointestinal bleeding. *Ann Surg* 1985;202:75-79
- [10] Risti B, Marineck B, Jost R, et al. Hemosuccus pancreaticus as a source of obscure upper gastrointestinal bleeding: three cases and literature of review. *Am J Gastroenterol*. 1995; 90:1878-1880.

- [11] Benz CA, Jakob P, Jakobs R, et al. Hemosuccus pancreaticus-a rare cause of gastrointestinal bleeding: diagnosis and interventional radiological therapy. *Endoscopy*. 2000;32:428-431.
- [12] de Perrot M, Berney T, Buhler L, et al. Management of bleeding pseudoaneurysms in patients with pancreatitis. *Br J Surg*. 1999;86:29-32.
- [13] Koizumi J, Inoue S, Yonekawa H e al. Hemosuccus pancreaticus: diagnosis with CT and MRI and treatment with transcatheter embolization. *Abdom Imaging*. 2002;27:77-81.
- [14] Bergert H, Hinterseher I, Kersting S, et al. Management and outcome of hemorrhage due to arterial pseudoaneurysms in pancreatitis. *Surgery*. 2005;137:323-328.
- [15] Peroux JL, Arput JP, Saint-Paul MC, et al. Wirsungorragie compliquant une pancréatite chronique associée á une neuroendocrine du pancréas. *Gastroenterol Clin Biol*. 1994;18:1142-1145.
- [16] Emilie E, Regenet N, Tuech JJ, Pessaux P, Meurette G, et al. Diagnosis and treatment of hemosuccus pamcreaticus. *Pancreas* 2007;34:229-232.
- [17] Arnaud JP, Bergamashi RR, Serra-Maudet V, et al. Pancreatoduodenectomy for hemosuccus pancreaticus in silent chronic pancreatitis. *Arch Surg*. 1994;129:333-334.
- [18] el Hamel A, Parc R, Adda G, et al. Bleeding pseudocysts and pseudoaneurysms in chronic pancreatitis. *Br J Surg*. 1991;78:1059-1063.
- [19] Kuruma S, Kamisawa T, Tu Y, et al. Hemosuccus pancreaticus due to intraductal papillary-mucinous carcinoma of the pancreas. *Clin J Gastroenterol*. 2009;2:27-29.
- [20] Meneu JA, Fernandes-Cebrian JM, Alvarez-Baleriola I, et al. Hemosuccus pancreaticus in a heterotopic jejuna pancreas. *Hepatogastroenterology*. 1999;46:177-179.
- [21] Vasquez-Iglesias JL, durana JA, Yanez J et al. Santorinrrhage: hemosuccus pancreaticus in pancreas divisum. *Am J Gastroenterol*. 1988;83:876-878.
- [22] Gutkin E, Kim SH. A novel endoscopic treatment of hemosuccus pancreaticus: A stent tree tamponade. *JOP. J Pancreas* 2012;13:312-313.
- [23] Stabile BE, Wilson SE, Debas HT. Reduced mortality from bleeding pseudocysts and pseudoaneurysms caused by pancreatitis. *Arch Surg*. 1983;118:45-51.
- [24] Kahn LA, Kamen C, McNamara MP Jr. Variable color Doppler appearance of pseudoaneurysm in pancreatitis. *AJR Am J Roentgenol*. 1994;162:187-188.
- [25] Gambiez LP, Emst OJ, Merlier OA, et al. Arterial embolization for bleeding pseudocysts complicating chronic pancreatitis. *Arch Surg*. 1997;132:1016-1021.
- [26] Akpınar H, Dicle O, Ellidokuz, et al. Hemosuccus pancreaticus treated by transvascular selective arterial embolization. *Endoscopy*. 1999;31:213-214.

- [27] Sugiki T, Hatori T, Imaizumi T, Harada N, Fukuda A, et al. Two cases of hemosuccus pancreaticus in which hemostasis was achieved by transcatheter arterial embolization. *J Hepatobiliary Pancreat Surg*. 2003;10:450-454.
- [28] Naitoh I, Ando T, Shimohira M, Nakazawa T, Hayashi K, et al. Hemosuccus pancreaticus associated with segmental arterial mediolysis successfully treated by transarterial embolization. *JOP. J Pancreas* 2010;11:625-29.
- [29] Ray S, Das K, Ray S, Khamrui S, Ahammed M, et al. Hemosuccus pancreaticus associated with severe acute pancreatitis and pseudoaneurysms: A report of two cases. *JOP. J Pancreas* 2011;12:469-472.
- [30] Rammohan A, Palaniappan R, Ramaswami S, Perumal SK, Lakshmanan A, et al. Hemosuccus pancreaticus: 15-year experience from a territory care GI bleed centre. *ISRN Radiology* 2013, ID 191794, 1-6.
- [31] Bender JS, Bouwman DL, Levison MA, et al. Pseudocysts and pseudoaneurysms: Surgical strategy. *Pancreas* 1995;10:143-147.
- [32] Heath DI, Reid AW, Murray WR. Bleeding pseudocysts and pseudoaneurysms in chronic pancreatitis. *Br J Surg*. 1992;79:281.
- [33] Udd M, Leppaniemi AK, Bidel S, et al. Treatment of bleeding pseudoaneurysms in patients with chronic pancreatitis. *World J of Surg*. 2007;31:504-510.
- [34] Waltman AC, Luers PR, Athanasoulis, et al. Complementary roles of surgery and transcatheter occlusive techniques. *Arch Surg*. 1986;121:439-443.