

# We are IntechOpen, the world's leading publisher of Open Access books Built by scientists, for scientists

6,900

Open access books available

186,000

International authors and editors

200M

Downloads

Our authors are among the

154

Countries delivered to

TOP 1%

most cited scientists

12.2%

Contributors from top 500 universities



WEB OF SCIENCE™

Selection of our books indexed in the Book Citation Index  
in Web of Science™ Core Collection (BKCI)

Interested in publishing with us?  
Contact [book.department@intechopen.com](mailto:book.department@intechopen.com)

Numbers displayed above are based on latest data collected.  
For more information visit [www.intechopen.com](http://www.intechopen.com)



---

# **Spinal Anaesthesia in Spinal Surgery**

---

Nicola Nicassio and Irfan Malik

Additional information is available at the end of the chapter

<http://dx.doi.org/10.5772/58749>

---

## **1. Introduction**

Surgery for lumbar disc prolapse is one of the most common spinal procedures. Lumbar microdiscectomy is usually performed under general anaesthesia despite recent publications showed that these procedures can be performed safely also under spinal anaesthesia. Indeed, some authors have previously highlighted the possibility of using spinal anaesthesia for decompressive laminectomy and microdiscectomy, so avoiding the risks related to the general anaesthesia and allowing to reduce the length of the inpatient stay and the overall costs. In this chapter we will also expose different surgical procedures performed with local and general anaesthesia as well and we will give the possibility to the reader to realize the mean important differences with the use of the spinal anaesthesia.

## **2. Body**

Spinal surgery is one of the more highly widespread disciplines in the world and it involves many different procedures, ranging from the easiest to the most complex ones.

In 1934 Mixter and Barr were the first authors to treat a lumbar disc herniation surgically by performing an open laminectomy and discectomy. With the introduction of the microscope, Caspar and Yasargil refined the original laminectomy into an open microdiscectomy.

Currently lumbar laminectomy and microdiscectomy, performed as open procedures by a posterior approach, are the most widespread procedure for surgical decompression.

Despite results are essentially related to the right indication for surgery and not to the anaesthetic or surgical techniques chosen, some complications are more correlated to the surgical approach and to the anaesthesiologist methods used.

For this reason in the last decades the technologies and the spinal surgeon's efforts have been addressed toward the use of the most minimally invasive procedures that can preserve as much as possible the anatomy in order to reduce the short-term and the long-term (post-operative fibrosis) surgical complications.

This is particularly true for the easiest spinal procedures as discectomy and central canal and foraminal decompression and all the new technical procedures, which have been developed, have allowed reaching two different aims:

- a. To preserve as much as possible the anatomy of the whole spine (paravertebral muscles and ligaments included). With this objective in mind, minimally invasive and percutaneous approaches have been developed in order to reduce the damage to the anatomical structures and at the same time the intraoperative bleeding, the post-operative pain (and consequently the need of post-operative analgesia and related side effects), the incidence of post-operative infections and, eventually, the long-term post-operative fibrosis.
- b. To lower the use of general anaesthesia and consequently all the risks related to its use. Indeed, the increase of the average age of the population has created a new class of patients that are more at risks of systemic (cardiovascular and pulmonary) complications.

Thus, in the last years, research and technology have pointed towards these two objectives, sometimes aiming for one in particular and, more rarely, achieving both of them. Particularly in the latter case, the result allows to manage the entire situation in the best way with clear consequences on the post-operative recovery period, which is often so fast to allow discharging the patient the same day of the operation. Evident implications arise on the economic benefits, as well.

Despite a detailed description of every surgical procedure falls outside the purpose of this chapter, we consider it useful to touch on the procedures that, in particular in the last period, have started to spread among the spinal surgeons. This will allow a clear understanding of the advantages and drawbacks as well as indications and contraindications of each procedure and to compare each other and all against the use of regional anaesthesia in spinal surgery.

Among the procedures that aimed for the goals in point a), a particular mention has to be done to the spinal endoscopy.

Spinal endoscopy was born as acting as a counterpart to the open spinal surgery and, since its introduction, has been applied for disc prolapse and stenosis of the entire spine, from the cervical to the lumbar segment [1].

Spinal endoscopy uses the “keyhole” rule, which is a specific entrance point where it is possible to insert progressive dilator tubes in order to create a way in which, at the end, it is possible to insert the endoscope.

Then, the endoscope allows having a wide view of the field (generally a 25° optic is used) and, makes it possible to insert and to work with surgical instruments, generally the same ones used for the open procedures. On the cervical spine, currently the authors prefer to perform the endoscopic procedure with the patient under general anaesthesia and an anterior (like the

anterior approach for the ACDF), or a posterior approach is used. Compared with the anterior approach [2], the posterior one is preferred because it is considered safer and less laden with major complications as injuries of the nervous-vascular bundle (ICA, internal jugular vein and vagus nerve) or of the esophagus [2, 3].

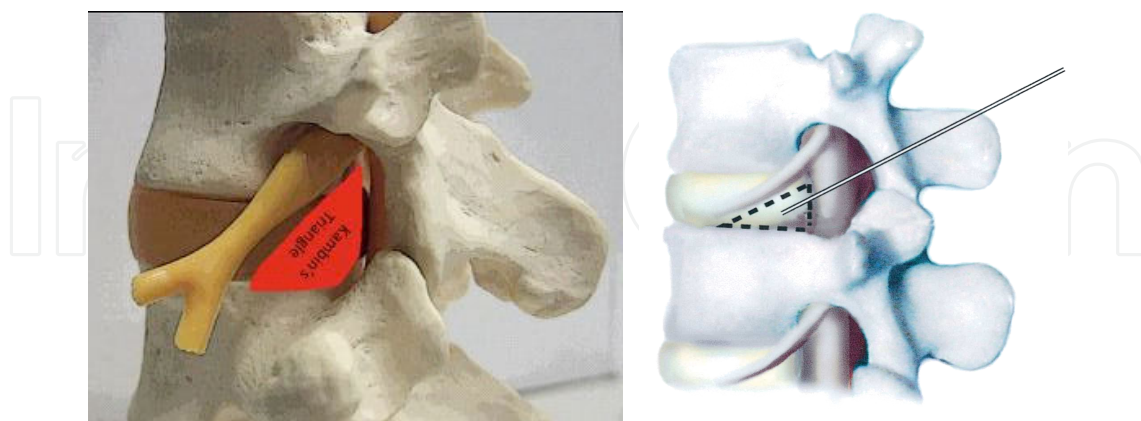
In addition, the corridor created, despite narrow, allows the surgeon to reach the disc and to remove it in small fragments without making any dangerous compression on the spinal cord.

Endoscopic techniques for the lumbar spine have been developed following different schools of thought which distinguish each other mainly: 1) on the endoscope's entry point (midline, postero-lateral and far-lateral) and 2) on the preferred anaesthesiologist techniques (local anaesthesia+mild sedation or general anaesthesia).

Of course, the decision about these variables depends on the pathology to face with (disc prolapse or central canal stenosis), the exact level of the disease (L5-S1 is considered a level for which some approach are not suitable) and the positioning of the pathology (midline, paramedian, foraminal, far lateral). Moreover, it is fundamental the surgeon's experience (who generally tends to use always the same approach) as the patient's condition, his past medical history and his ability to cooperate with the surgeon during the awake procedures.

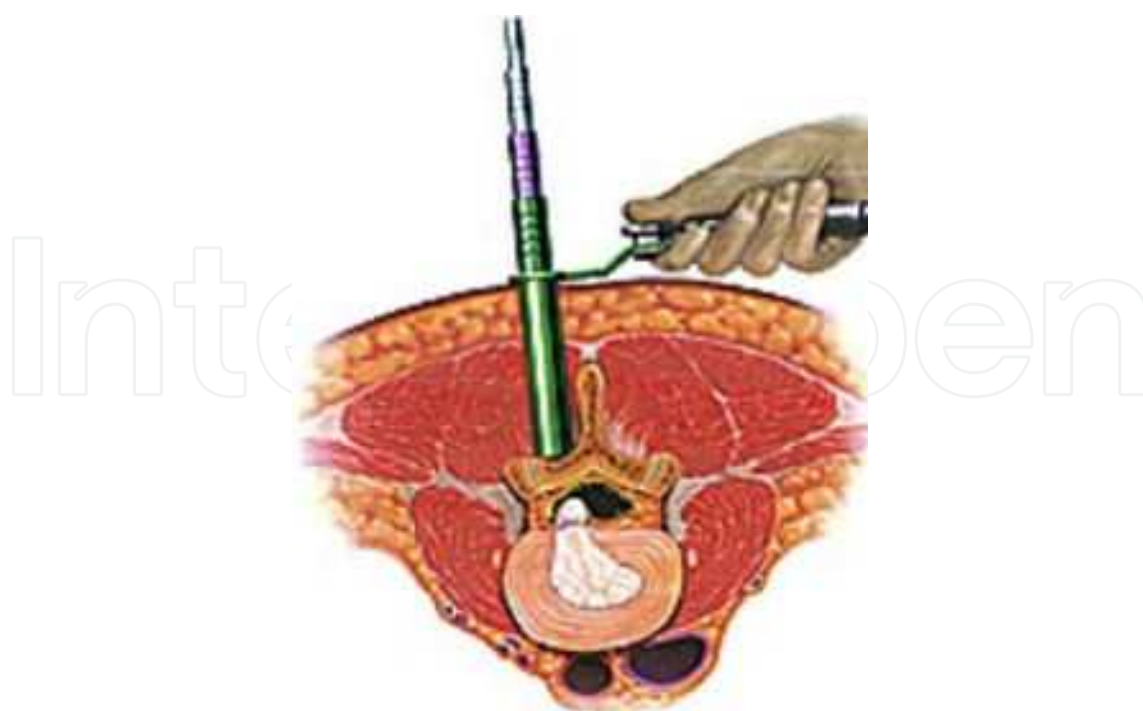
The patient is in a prone or a lateral decubitus and this essentially depends on the approach used (the prone position usually requires the patient under general anaesthesia).

The postero-lateral and the far-lateral approaches allow reaching the pathology (generally a disc prolapse) passing through the foramen (transforaminal approach), with the endoscope which is located in the caudal half of the foramen (triangle safe zone) and the nerve root laying in the rostral half (Fig.1 and Fig 3).



**Figure 1.** Triangle safe zone for the endoscopic transforaminal approach

The midline approach, on the contrary, is performed introducing the endoscope almost on the midline (roughly 2-3 mm laterally to avoid injury to the supraspinous ligament or to the interspinous ligament).



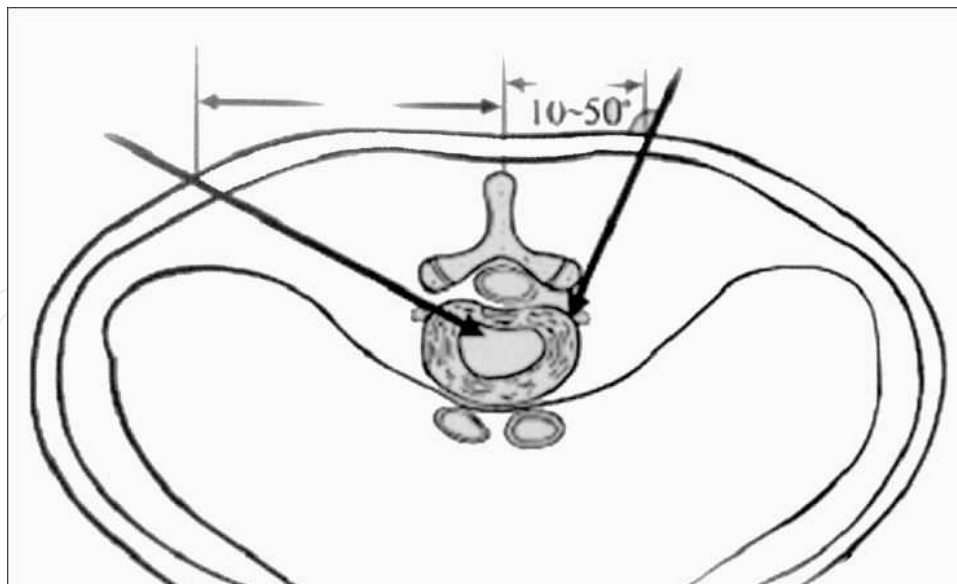
**Figure 2.** Midline endoscopic approach

With this approach, of course, it is necessary to remove some of the flavum ligament and part of the upper lamina and to dislodge medially the dural sac to reach the disc. The other approaches, on the contrary, allow reaching the disc without disrupting the flavum ligament and so reducing a lot the possibility of dura mater injury.

The transforaminal approach, generally with the patient on the lateral decubitus, can be performed under local anaesthesia and mild sedation or under general anaesthesia. The different choice is relevant in the positioning of the endoscope (this step of the procedure is done under fluoroscopic guide) and is dictated by some factors which are also related to the surgeon's personal experience and to the patient. The possibility to monitor the safe transit of the endoscope through the foramen by asking to the patient about the onset of any radicular pain is a tool that some surgeons are keen to use and for which, of course, the patient needs to be alert and completely collaborative (during this phase of the procedure the sedation needs to be stopped). This method can help to avoid damage to the nerve root during the position of the foramen [1, 5, 6].

Other surgeons prefer to ground only on the information given by the fluoroscopy and by a direct endoscopic vision of the nerve root and, for this reason, it is not necessary to work with an awake patient.

The midline approach is generally performed with the patient in the prone position and under general anaesthesia. The risk of a nerve root damage is quite small if compared with the transforaminal approach but the possibility of a dural tear and a consecutive dural fistula is more frequent.



**Figure 3.** Different endoscope's direction in the transforaminal approach

The most suitable approach also depends on the axial position of the disc prolapse. Indeed, in case of a far lateral disc prolapse, a transforaminal approach is the most suitable to remove the compression while a foraminal disc herniation with a dislodgment of the nerve root caudally makes the transforaminal approach impossible to use or at least very dangerous.

About the sagittal position of the disc prolapsed, a migrated fragment behind the vertebral body is considered by some authors an absolute contraindication in performing endoscopic discectomy.

The surgeon's personal experience is another factor that should be considered, as some surgeons prefer to use always the same approach, not modifying it on the base of the level of the pathology or its axial position, while others prefer to change the approach according to the lumbar level interested in or the axial position of the compression. Thus, some surgeons face with the midline disc prolapse using a transforaminal approach while others prefer to use a midline approach.

The L5-S1 space is considered, by the majority of the authors a contraindication for the transforaminal approach because of the hindrance created by the iliac crest in conjunction with the inclination of this space. Despite these factors, some authors are keen to use the transforaminal approach and, relying on their great experience, in many cases are able to reach the L5-S1 space through this approach with the patient on the lateral decubitus and under local anaesthesia and mild sedation. Of course a high position of the iliac crest is an absolute contraindication to the transforaminal approach and, if this approach has been tempted, the surgeon needs to change in order to be able to perform the operation. Anyway, as we mentioned, the majority of the surgeons prefer to reach the L5-S1 disc space by a direct midline approach and the patient under general anaesthesia.



The most important advantage of the endoscopic spinal surgery is represented by a minimally invasive approach with a minimal disruption of the normal anatomy. Also the transforaminal approach keeps the post-operative fibrosis on a minimum and make a re-do surgery easiest and less dangerous.

Among the risk and drawbacks of the transforaminal approach we must remind the damage to the nerve root, while, for the midline approach, the major risk is represented by a dural tear (the rate is similar to that one of the classical procedure). Common to all the endoscopic spinal procedures is a long and hard learning curve and consequently a long training period that can be frustrating [4]. Particularly at the beginning a simple operation can last considerably longer if compared with the same procedure done in a classical way (under general anaesthesia and with the operating microscope) and, if performed under local anaesthesia and mild sedation, can become stressful for the patient.

Eventually it is important to remind the cost related to the entire instrumentation.

Table 1 summarizes advantages and drawbacks of lumbar endoscopic discectomy

Advantages	Drawbacks
Good preservation of the normal anatomy	Nerve damage in the transforaminal approach and dural tear in the midline approach
Reduction in post-operative pain	Long and difficult learning curve
Reduction in post-operative fibrosis	Cost of the equipment
Reduced period of hospitalization	

**Table 1.** Advantages and drawbacks of lumbar endoscopic discectomy

The increase of the age of the population and consequently the increase of the co-morbidity with sometimes unacceptable risks for the general anaesthesia has pushed all the health personnel to find alternatives to the latter, in particular in performing spinal procedures for the most simple pathologies (disc prolapse and stenosis).

In the past many publications have stressed the possibility and opportunity to use local and regional anaesthesia for some easiest procedures, e.g. lumbar microdiscectomy and decompressive laminectomy [7, 8, 10, 11, 12]. Despite this, in the vast majority of centers these procedures are still carried out under general anaesthesia, with the patient in a prone or genu-pectoral position.

General anaesthesia has got a widespread consent and it is used routinely. It is the preferred option for anaesthesiologists because it allows an easier monitoring of vital parameters in a prone position; it is supported by surgeons because it allows extra time for surgery without problems (also useful for teaching purposes). Last but not least, patients prefer general anaesthesia since they can avoid the anxiety linked to the awareness of undergoing a surgical operation and the fear of pain [10, 12]. Nevertheless, the advantages of general anaesthesia have often outweighed its drawbacks. On this regard, we have to keep in mind potential

pulmonary complications, injuries from nervous compression during the patient positioning, post-operative nausea and vomiting and extension of the operative time related to patient awaking and recovery.

In the past different publications have shown the results coming from the use of local anaesthesia for laminectomy surgery and in many occasions these publications have established that, on a particular class of selected patients (generally elderly patients with an important pre-morbid history), this procedure can be suitable and can offer a valid alternative to the general anaesthesia [7, 8].

The practice of the local anaesthesia for spinal surgery is not new. Traditionally, cervical osteotomies in patients with severe ankylosing spondylitis were managed in this way, mainly because they were difficult to intubate.

The use of local anaesthesia has also been previously reported in fit and healthy patients undergoing cervical laminectomy. The technique was advocated in these patients, in part, to allow neuro-monitoring during surgery. Later, other authors presented a serie of patients, with significant premorbid pathology, undergoing cervical, thoracic or lumbar decompressive laminectomy under local anaesthesia. The authors arrived to the conclusion that local anaesthesia can be very successful with minimal complications. Unfortunately the most important side effect was the pain experienced by the patient in particular during the stripping of the paravertebral muscles (a consistent finding in many patients, very difficult to manage) and not a satisfactory solution to this problem was found, except great care handling of the tissues and a well targeted infiltration of the local anaesthetic [7]. Clearly such drawback happens when the procedure is performed in the classical way that envisages the stripping of the paravertebral muscles bilaterally. It is also important to underline that this technique is only appropriate if performed by a skilled surgeon, as the patients became uniformly restless if required to lie still for, on average, more than 90 min [7].

For the reasons just mentioned, the only use of the local anaesthesia is generally not accepted and, if not contraindicated, some intravenous sedation is also administered.

As the patient is ready, the operation can also be carried out, according to the surgeon's experience, by percutaneous techniques or by endoscopic techniques whose skin incisions are often less than 1 cm long (the classical techniques generally require skin incisions 4-6 cm long). In this sense, it is evident that the percutaneous and endoscopic techniques carried out under local anaesthesia and mild sedation are able to combine all the aims that we have mentioned at the beginning of this chapter.

Indications for the use of the local anaesthesia with mild sedation can be summarized as follow:

- 1) Patient ability to cope with a "stressful situation".
- 2) Severe premorbid conditions (cardio-vascular and pulmonary diseases) which may represent a significant risk for general anaesthesia.
- 3) No allergy toward local anaesthetics.
- 4) A skilled surgeon.

Table 2 summarizes indications, advantages and drawbacks of local anaesthesia for decompressive laminectomy.



Indications	Advantages	Drawbacks
Severe pre-morbid conditions (cardiovascular and pulmonary diseases)	None of risks related to the general anaesthesia	Pain related to the handling of the paravertebral muscles
Patient able to cope with a stressful situation	Possibility to discharge the patient the same day of the operation	Need of a skilled surgeon

**Table 2.** Indications, advantages and drawbacks of local anaesthesia for decompressive laminectomy

A valid alternative to the local anaesthesia, generally more effective in the pain control, is the injection of anaesthetic agents to create a regional block.

Under this prospective two different techniques have been developed: spinal anaesthesia and epidural anaesthesia. These techniques are erroneously considered both as the same technique and sometimes the terms are used as synonymous. Actually these two techniques are very different and currently the epidural anaesthesia is the most used.

Unlike the epidural anaesthesia, spinal anaesthesia can be used only for lumbar cases. Indeed, while epidural anaesthesia virtually can be also used for the cervical and thoracic spine, spinal anaesthesia (in consideration of the injection of anaesthetic agents in the subarachnoid space) has got the evident limit to its application to the lumbar segment in order to avoid a depression of the respiratory muscles and a dangerous bradycardia related to a sympathetic block.

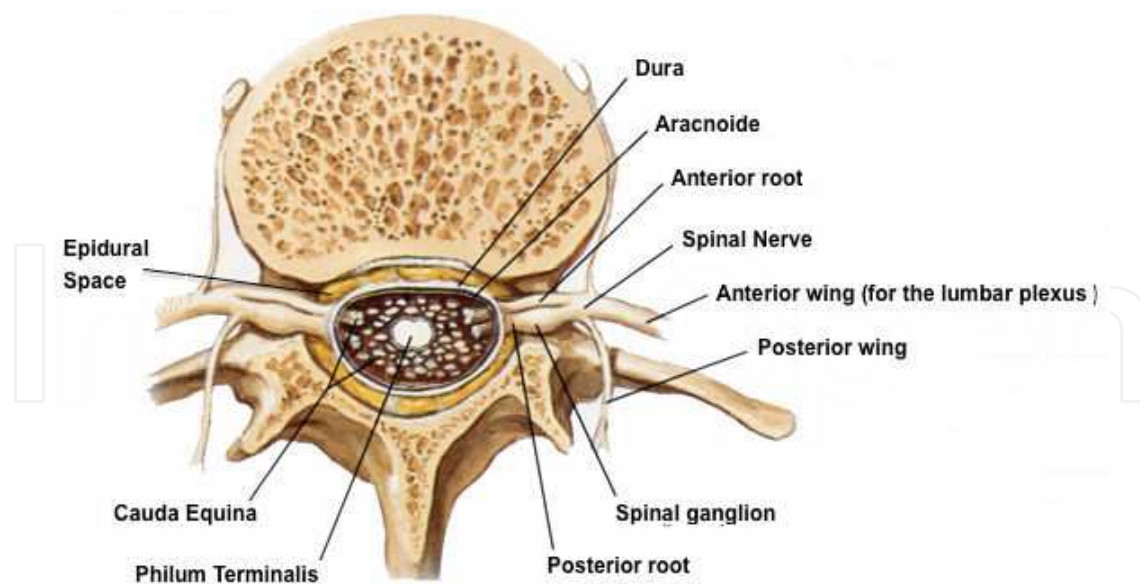
To understand better the difference between these two methods it is useful to make some brief outline on the anatomy of the spine (Fig 4).

The epidural space is that potential space included between the dura and the periosteum lining the vertebral canal and it extends from the foramen magnum to the sacral hiatus. The nerve roots in their dural covering pass across this potential space to reach the intervertebral foramen where they form the segmental nerves. Anteriorly, the epidural space is bordered by the posterior longitudinal ligament covering the vertebral bodies and the intervertebral discs. Laterally, it is bordered by the periosteum of the vertebral pedicles and the intervertebral foraminae and posteriorly is bordered by the periosteum of the anterior surface of the laminae and articular processes, the periosteum of the root of the spines and the interlaminar spaces filled by the ligamentum flavum. The epidural space contains venous plexuses and fatty tissue.

The subarachnoid space is the space containing the anterior and posterior nerve roots and the CSF which is in continuity with the CSF contained in the ventricles and in the cerebral cisterns. Below the level between L1 and L2 the spinal cord ends and all the nerve roots take a configuration that resembles an cauda equina. All these nerve roots are responsible for the motility and sensation of the lower limbs and for the sphincters' control.

Before describing in details both the procedures, the indications, the contraindications (related to the selection of the appropriate patient) and the risks are outlined.

As for the local anaesthesia, for the spinal anaesthesia and epidural anaesthesia some criteria also need to be fulfilled in the patient selection. These criteria can be summarized in the following points: consented and cooperative patient; no coagulopathy or therapeutic antico-



**Figure 4.** Axial view of the lumbar canal

agulation; no anatomical abnormalities of the spine; no allergy to anaesthetic medications; no skin infection at injection site; no hypovolaemia or fixed cardiac output states (additive risks with sympathetic block); no intracranial hypertension (risks of brain stem herniation in particular with the spinal anaesthesia) [9, 10].

Both these procedures must be performed in a work area that is equipped for airway management and resuscitation. Indeed, serious complications may occur with epidural anaesthesia and facilities for resuscitation should always be available whenever epidural or spinal anaesthesia are performed [9].

Starting with the description of the epidural anaesthesia, some standardized steps are followed: while monitoring cardiac parameters (EKG, hearth rate, blood pressure) and respiratory parameters (respiratory rate, pulse oximetry), some sedation is administered intravenously (generally 3 mg of midazolam) [10]. With the patient in a sitting or a lateral position, an intervertebral space is identified, generally two spaces above the space interested in surgery. The skin is prepared with alcohol or iodine-containing solutions and draped in a sterile fashion (the operator should take full sterile precautions, including gown, mask and gloves). Modern epidural kits are usually disposable and packed in a sterile fashion. In this sterile kit an epidural needle (17 Ga.x3-7/8"TW) is included as well as an epidural catheter that is designed to pass through the lumen of the epidural needle. A filter is also used to prevent the inadvertent injection of particulate matter into the epidural space, and as a bacterial filter. After injecting some local anaesthesia (5 mL of 2% lidocaine), the epidural needle is introduced on the midline and the epidural space is identified. To identify this space, different techniques have been developed over the years, but currently most practitioners use a syringe to identify a loss of resistance when pressure is applied to the plunger [9]. Some authors use saline in the syringe while others use air. These two methods are broadly similar, with some mild differences in the way the syringe is advanced and the epidural space entered.

Other techniques to identify the epidural space have been used in the past, e.g. the “hanging drop technique”. With this technique, a drop of saline is placed at the hub of the needle and the needle (without syringe) is advanced. The epidural space is identified when the drop is “sucked” into the needle by the negative pressure characteristic of the epidural space.

When in the epidural space the local anaesthetics can be administered.

Single shot epidurals, without the use of a catheter, is still widely used in various settings, and is effective in providing intraoperative anaesthesia and analgesia in the immediate postoperative period. The major disadvantages of single shot epidurals are: 1) The duration of postoperative analgesia is limited to the duration of action of the drug given and cannot be topped up, and 2) The risks involved in injecting a full anaesthetic dose of local anaesthetics into the epidural space without a test dose and without the ability to give slow increments. This means that the risks of inadvertent high block, total spinal block and local anaesthetic toxicity are much greater. For this reason many authors prefer to avoid the single shot techniques.

The choice of drugs administered epidurally depends on the indication for the epidural.

Surgical anaesthesia requires heavy sensory block and usually moderate to heavy motor block. To achieve this, concentrated local anaesthetic preparations are required. The most commonly used local anaesthetics in this setting are 10-20ml of 2% lignocaine (with or without adrenaline 1:200000) or 10-20 mL of 0.5% bupivacaine. The latter has a longer duration of action, but a slower onset time, compared with lignocaine. Other authors prefer 8-10 ml (depending on patients' BMI) of 0.75% Ropivacaine. After the injection the patient is maintained in the sitting position for a further 30 minutes [10].

In the past the addition of opioids to local anaesthetic solutions gained popularity in particular because the opioids have a synergistic effect by acting directly on opioid receptors in the spinal cord. The combination of low-concentration local anaesthetic and low-concentration mixtures of opioids, administered by slow infusion rather than as intermittent boluses, has, in particular, been shown to be very effective in the management of postoperative pain.

The amount of opioid should be reduced where there is an increased risk of respiratory depression, i.e. the elderly or in patients with significant chronic obstructive airway disease.

Caution should be exercised when morphine is administered epidurally, as it is associated with delayed respiratory depression. This is thought to be as a result of its low lipid solubility, which means that instead of binding to opioid receptors in the spinal cord, some of the drug remains in solution in the CSF, and the circulation of CSF transports the remaining drug to the brainstem where it acts on the respiratory centre. This may occur many hours (up to 24 hours) after morphine has been administered epidurally.

Among the major risks and complications of epidural anaesthesia we must remind hypotension, a high spinal block, local anaesthesia toxicity and the total spinal block [9-12].

Hypotension is the commonest side effect of successful therapeutic blockade for procedures above the umbilicus. Vasodilatation of resistance and capacitance vessels occurs, causing relative hypovolaemia and tachycardia, with a resultant drop in blood pressure. This is

exacerbated by blockade of the sympathetic nerve to the adrenal glands, so preventing the release of catecholamines. If blockade is as high as T2, sympathetic supply to the heart (T2-5) is also interrupted and may lead to bradycardia. The overall result may be inadequate perfusion of vital organs and measures are required to restore the blood pressure and cardiac output, such as fluid administration and the use of vasoconstrictors. Sympathetic system arises from T1 to L2 and blockade of nerve roots below L2 is less likely to cause significant sympathetic blockade, compared with procedures requiring blockade above the umbilicus.

The inadvertent high epidural block is generally due to an excessively large dose of local anaesthetic in the epidural space. It may present with hypotension, nausea, sensory loss or paraesthesia of high thoracic or even cervical nerve roots (arms), and difficulty in breathing due to blockade of nerve supply to the intercostal muscles. These symptoms in the most severe cases may require intubation of the patient to secure the airway, while treating hypotension. If the patient has a clear airway and is breathing adequately they should be reassured and any hypotension immediately treated. Difficulty in talking (small tidal volumes due to phrenic block) and drowsiness are signs that the block is becoming excessively high and should be managed as an emergency.

Local anaesthetic toxicity can also occur as a result of an excessive dose of local anaesthetic agents in the epidural space. Even a moderate dose of local anaesthetic, if injected directly into a blood vessel, can cause toxicity. This is especially possible when an epidural catheter is inadvertently advanced into one of the many epidural veins. It is therefore vital to aspirate from the epidural catheter prior to injecting local anaesthetic. Symptoms usually follow a sequence of light-headedness, tinnitus, circumoral tingling or numbness and a feeling of anxiety or "impending doom", followed by confusion, tremor, convulsions, coma and cardio-respiratory arrest. It is important to recognize these symptoms early, and discontinue the further administration of local anaesthetic drugs. Treatment should be supportive, with the use of sedative/anticonvulsants (thiopentone, diazepam) where necessary, and cardiopulmonary resuscitation if required.

Total spinal block is a rare complication occurring when the epidural needle, or epidural catheter, is inadvertently advanced into the subarachnoid space and an "epidural dose" e.g. 10-20 mL of local anaesthetic is injected directly into the CSF. The result is a profound hypotension, apnoea, unconsciousness and dilated pupils as a result of the action of local anaesthetic on the brainstem. The use of a test dose helps in preventing most cases of total spinal block despite some cases have been described where the epidural initially appeared to be correctly sited, but subsequent top-up doses caused the symptoms of total spinal block. This has been ascribed to the migration of the epidural catheter into the subarachnoid space, although the exact mechanism is still uncertain.

Acute management of the total spinal block is based on: 1) Secure airway and administer of 100% oxygen; 2) Ventilate by facemask and intubate; 3) Treat with intravenous fluids and vasopressors; 4) Continue to ventilate until the block wears off (2-4 hours); 5) As the block recedes, the patient will begin recovering consciousness followed by breathing and then movement of the arms and finally legs.



The accidental dural puncture is usually easily recognized by the immediate loss of CSF through the epidural needle. This complication occurs in 1-2% of epidural blocks and is more related to the experience of the practitioner. It leads to a high incidence of post dural puncture headache, which is severe and associated with a number of characteristic features. The headache is typically frontal, exacerbated by movement or sitting upright, associated with photophobia, nausea and vomiting, and relieved when lying flat. The headache is thought to be due to the leakage of CSF through the puncture site. Basic measures, such as simple analgesics, caffeine, bed rest, fluid rehydration and reassurance are indicated in the first instance, and are often sufficient to treat the headache. Where the headache is severe, or unresponsive to conservative measures, an epidural blood patch may be used to treat the headache. This procedure is effective in treating approximately 90% of post dural puncture headaches. If unsuccessful, the blood patch may be repeated, and the success rate increases to 96% on the second attempt. The blood injected into the epidural space is thought to seal the hole in the dura.

Epidural haematoma is a rare but potentially catastrophic complication of epidural anaesthesia. The epidural space is filled with a rich network of venous plexuses, and puncture of these veins, with bleeding into the confined epidural space, may lead to the rapid development of a haematoma which may lead to compression of the spinal cord, and can have disastrous consequences for the patient including paraplegia and the onset of a cauda equina syndrome. For this reason, coagulopathy or therapeutic anticoagulation with heparin or oral anticoagulants is considered an absolute contraindication to epidural blockade.

Infection is another rare but potentially serious complication. Pathogenic organisms can be introduced into the epidural space if strict asepsis is not observed during the performance of the block. The commonest pathogens are *Staphylococcus aureus* and *Streptococci*. Meningitis has been described, as has epidural abscess. In addition to the symptoms of spinal cord compression described above, the patient may exhibit signs of infection such as pyrexia and a raised white cell count.

Failure of block can occur as a result of many factors, the most important being the experience of the operator. False loss of resistance during performance of the block may lead to insertion of the epidural catheter into a different area than the epidural space. Segmental sparing occurs occasionally for reasons that are unclear, but are assumed to be the result of anatomic variations of the epidural space, so that local anaesthetic fails to spread evenly throughout the space. The result is that some nerve roots are inadequately soaked with local anaesthetic, leaving the dermatomes of these nerve roots poorly anaesthetized. Unilateral blockade occurs occasionally, and this is thought to be the result of a septated epidural space, with failure of the local anaesthetic solution to spread to one half of the epidural space. Positioning the patient on his side with the unblocked side down is sometimes successful in allowing spread of the local anaesthetic to the dependent side, giving bilateral anaesthesia.

Spinal anaesthesia is the other technique that can be used; despite currently the epidural anaesthesia is the preferred one. These two techniques have relevant differences in indications, in execution and in the related risks.



Spinal anaesthesia, as we have explained before, is used only for surgery in the caudal part of the body (genital, urinary tract, or lower body procedures)

The spinal anaesthesia involves injecting a small volume of local anaesthetics (1-3.5 mL) into the spinal space below the level at which the spinal cord ends, unlike the epidural anaesthesia that involves injecting a larger volume of local anaesthetics into the space that surrounds the spinal canal and so it may be performed in any region of the back.

The local anaesthetic agents that are used provide surgical anaesthesia for 1-3 hours. For this reason, a spinal anaesthesia can only be used when the operation will take less time.

The anesthesia is performed using a needle that is thinner than that one used in the epidural anaesthesia and the needle is advanced until the subarachnoid space is reached (the discharge of CSF is the test bench. The effect starts few minutes (5-10 minutes) after the injection while with the epidural anaesthesia it can need more than 20 minutes. Another relevant difference between the two methods is the length of the effect, between 1 and 3 hours with the spinal anaesthesia and between 3 and 5 hours with the epidural anaesthesia. Also, the spinal anaesthesia is administered as a single shot and it cannot be repeated while the epidural anaesthesia can be prolonged provided that an indwelling catheter is kept in the epidural space.

Table 3 compares epidural and spinal anaesthesia and summarizes the main differences.

The major risks related to spinal anaesthesia are represented by: spinal shock, cauda equina injury, cardiac arrest, hypothermia, epidural clot, infection (meningitis, epidural abscess), severe headache, nausea, vomiting, itching, hypotension, urinary retention [9].

	Epidural anaesthesia	Spinal anaesthesia
Use	All the spine	Only the lumbar level
Quantity of anaesthetic agent injected (mL)	1 – 3.5	10 - 20
Onset of effect (min)	5 - 10	" / > 20
Duration of the effect (hours)	1 - 3	3 - 5
Possibility to recall	yes	No (single shot)

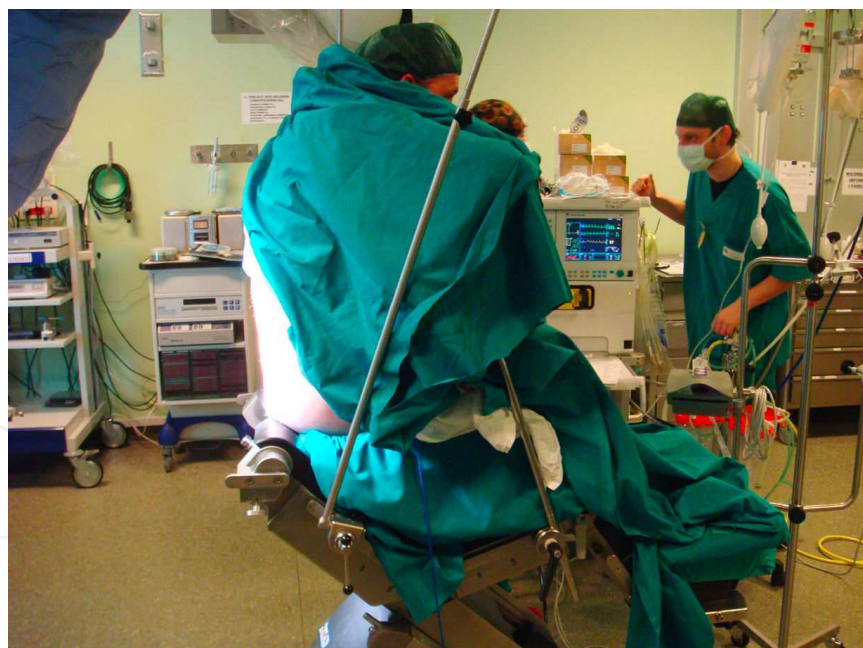
**Table 3.** Comparison between epidural anaesthesia and spinal anaesthesia

In particular with reference to the epidural anesthesia, many publications [10-18] in the past have showed that this technique is as safe and effective as general anesthesia and at the same time it allows the reduction of surgical and anaesthetic timing and the risks related to the general anaesthesia. Reduction of anaesthesia time, evidently, is linked to the elimination of the patient awaking phase, as it occurs after general anaesthesia and of the patient's recovery (post-op monitoring period).

Reduction of surgical time seems mainly related to an easier positioning of the patient and to a reduction of the intra-operative bleeding. Generally the position used during the spinal anaesthesia is the lateral decubitus (or in some occasions the sitting position), while, when a general anaesthesia is used, a prone position is preferred.

The lateral or the sitting position [10], compared to the prone one, shows benefits and drawbacks. As for the benefits we include a better comfort for the patient and the possibility to simulate the “real-life” orthostatic posture during the sitting position, often considered responsible for the onset or worsening of symptoms (this way it is possible to reveal some borderline situations, where nerve root impingement takes place only in the upright posture) (Fig. 5).

Also among the advantages of the lateral and the sitting position we must remind a “cleaner” operative field, since gravity will keep it “blood-free”. This latter effect, essentially, is the result of multiple determinants: first of all, the sympatholytic effects of anaesthetic drugs used for epidural anaesthesia that are responsible for a vasodilation and a light hypotension. In addition, we must also consider the lack of increase of intrathoracic pressure, opposite to what happens for patients under general anesthesia. The lack of an upsurge of intrathoracic pressure, furthermore reinforced by not using the prone position, leads to a decreased tension in the prevertebral epidural venous plexus [15].



**Figure 5.** Patient in a sitting position on a dedicated chair

All of these mechanisms are responsible for a reduction of intraoperative bleeding, which, by speeding up the surgical procedure, allows altogether the reduction of the surgical time.

Drawbacks of the lateral and the sitting position are first of all some discomfort for the surgeon who has to work with outstretched arms (even though seated) and with the operative micro-

scope set in a position quite similar as used for the posterior fossa surgery. This disadvantage, however, is mitigated by the shorter operating time. Surely, the most worrying drawback of the sitting position, that at the same time could be source of dangerous complications, is the possibility of a dural tear leading to CSF leak. Obviously, where a small dural tear can have no effects, a larger one could cause an important and sudden CSF leak, with a consequent risk of intracranial subdural hematomas or brain herniation syndromes. This is the reason why it is important to select the patients, by avoiding those with some risk factors (e.g.: previous surgery on the involved disc space, presence of scar tissue involving the dura, radiation therapy on the lumbar spine, etc) that could be responsible for a dural weakening [10].

In the assessment on the validity of epidural anaesthesia, some authors reported a satisfactory analgesia level reached in almost 90% of the patients undergone to epidural anaesthesia and often the only pain sensation the patient reported was a “feeling of pressing” [10].

Under this perspective, two more factors need to be considered: the urinary retention and the pain-free period after surgery. In the past, urinary retention was typically considered a side effect of spinal anaesthesia as compared to general anaesthesia but, in the last publications, this complication has not been showed. As observed by some authors, it is possible that at present this different trend has to be correlated to the “no use” of opioids during the induction of the epidural anaesthesia [15, 19].

The pain-free time extension after epidural anaesthesia [14,15] is harder to explain. It is likely that protopathic nervous fibers ( $A\delta$  and C), responsible for pain transmission, are more susceptible to medication used for spinal anaesthesia and resume their function more slowly than motor and epicritic sensation fibers.

Generally, the incidence of post-operative nausea or vomiting in patients who undergo spinal anaesthesia is considerably lower if compared with patients who undergo general anaesthesia, where these side effects can last for over 24 hours (leading to a longer hospital stay).

Some authors reported a slight difficulty in the placement of the muscle retractor related to the lack of a proper muscle relaxation. This led the surgeons to increase mildly (roughly 1 cm) the length of the skin incision.

In conclusion, in the current medical environment, where high medical standards have to meet lower costs, the trend is to go for surgical procedures that allow the surgeons to reach the same results with minimally invasive techniques and reducing the hospitalization time.

Under this perspective, spinal and epidural anaesthesia have gained a significant role, by allowing a reduction in anesthetic and surgical timing, in anaesthetic complications and consequently in hospital length of stay.

Despite, as usual, the right selection of the patient remains a fundamental factor to reach an optimal result, we believe that, in a near future, there will be the possibility to use these techniques to perform this type of surgery to a such an extent that they will supersede the classical techniques and will allow to manage the patient on a day-surgery basis.

## Author details

Nicola Nicassio\* and Irfan Malik

\*Address all correspondence to: nicknave@yahoo.it

Neurosurgery Department, King's College Hospital, London, UK

## References

- [1] Nellensteijn J, Ostelo R, BartelsR, Peul W, Van Royen B, Van Tulder M. Transforaminal endoscopic surgery for symptomatic lumbar disc herniations: a systematic review of the literature. *Eur Spine J.* 2010;19:181-204.
- [2] Tzaan WC Anterior percutaneous endoscopic cervical discectomy for cervical intervertebral disc herniation: outcome, complications, and technique. *J Spina Disord Tech.* 2011 Oct; 24(7): 421-431.
- [3] Yao N, Wang C, Wang W, Wang L. Full-endoscopic technique for anterior cervical discectomy and interbody fusion: 5-year follow-up results of 67 cases. *Eur Spine J.* 2011 Jun;20(6):899-904.
- [4] Wang H, Huang B, Li C, Zhang Z, Wang J, Zheng W, Zhou Y. Learning curve for percutaneous endoscopic lumbar discectomy depending on the surgeon's training level of minimally invasive spine surgery. *Clin Neurol Neurosurg.* 2013 Oct;115(10): 1987-91.
- [5] Choi I, Ahn JO, So WS, Lee SJ, Choi IJ, Kim H Exiting root injury in transforaminal endoscopic discectomy: preoperative image considerations for safety. *Eur Spine J.* 2013 Jun 11.
- [6] Chen ZG, Fu Q Percutaneous transforaminal endoscopic discectomy through different approaches for lumbar disc herniation. *Zhongguo Gu Shang.* 2012 Dec;25(12): 1057-60. Review. Chinese
- [7] Ames.W.A., Songhurst L., Gullan R.W. Local anaesthesia for laminectomy surgery. *British Journal of Neurosurgery* 1999;13(6):598± 600
- [8] Nygaard OP, Romner B, Thoner J, Due-Tonnessen B. Local anesthesia in posterior cervical surgery. *Anesthesiology* 1997; 86:242± 3
- [9] Dr Leon Visser Epidural Anaesthesia-Update in Anesthesia Issue 13 (2001) Article 11: page 1-4

- [10] Nicassio N, Bobicchio P, Umari M, Tacconi L Lumbar microdiscectomy under epidural anaesthesia with the patient in a sitting position: A prospective study J Clin Neurosci. 2010 Dec;17(12):1537-40.
- [11] Sadrolsadat SH, Mahdavi AR, Moharari RS, et al. A prospective randomized trial comparing the technique of spinal and general anesthesia for lumbar disk surgery: a study of 100 cases. Surg Neurol 2009;71:60–5
- [12] Smrcka M, Baudysová O, Jurán V, et al. Lumbar disc surgery in regional anaesthesia—40 years of experience. Acta Neurochir (Wien) 2001;143:377–81
- [13] Papadopoulos EC, Girardi FP, Sama A, et al. Lumbar microdiscectomy under epidural anesthesia: a comparison study. Spine J 2006;6:561–4.
- [14] McLain RF, Kalfas I, Bell GR, et al. Comparison of spinal and general anesthesia in lumbar laminectomy surgery: a case-controlled analysis of 400 patients. J Neurosurg Spine 2005;2:17–22.
- [15] McLain RF, Tetzlaff JE, Bell GR, et al. Microdiscectomy: spinal anesthesia offers optimal results in general patient population. J Surg Orthop Adv 2007;16:5–11
- [16] Demirel CB, Kalayci M, Ozkocak I, et al. A prospective randomized study comparing perioperative outcome variables after epidural or general anesthesia for lumbar disc surgery. J Neurosurg Anesthesiol 2003;15:185–92
- [17] Zou J, Yang H, Miyazaki M, et al. Dynamic bulging of intervertebral discs in the degenerative lumbar spine. Spine 2009;34:2545–50
- [18] McLain RF, Bell GR, Kalfas I, et al. Complications associated with lumbar laminectomy: a comparison of spinal versus general anesthesia. Spine 2004;29:2542–7
- [19] Koebbe CJ, Maroon JC, Abila A, et al. Lumbar microdiscectomy: a historical perspective and current technical considerations. Neurosurg Focus 2002;13:1–6.



