

We are IntechOpen, the world's leading publisher of Open Access books Built by scientists, for scientists

6,900

Open access books available

185,000

International authors and editors

200M

Downloads

Our authors are among the

154

Countries delivered to

TOP 1%

most cited scientists

12.2%

Contributors from top 500 universities



WEB OF SCIENCE™

Selection of our books indexed in the Book Citation Index
in Web of Science™ Core Collection (BKCI)

Interested in publishing with us?
Contact book.department@intechopen.com

Numbers displayed above are based on latest data collected.
For more information visit www.intechopen.com



Dry eye — An Insight into Meibomian Gland Dysfunction

Vikas Tah, Kamran Saha, James Myerscough, Muhammad Ahad, Jason Ho, Pranev Sharma, Fariyah Tariq and Stephen Tuft

Additional information is available at the end of the chapter

<http://dx.doi.org/10.5772/58566>

1. Introduction

The term 'Dry Eyes' was first coined in 1950 by the Ophthalmologist Andrew De Roeth (1893–1981): a dacryologist who introduced the term dry eye. For decades it was thought dry eyes was limited to a reduction in the aqueous phase of the tear film. It was as recent as 1995 that dry eyes was eventually recognised as a multifaceted ocular pathology which was due to decreased tear production and increased tear evaporation [1]. In this chapter we will focus on the latter, specifically looking at meibomian gland dysfunction.

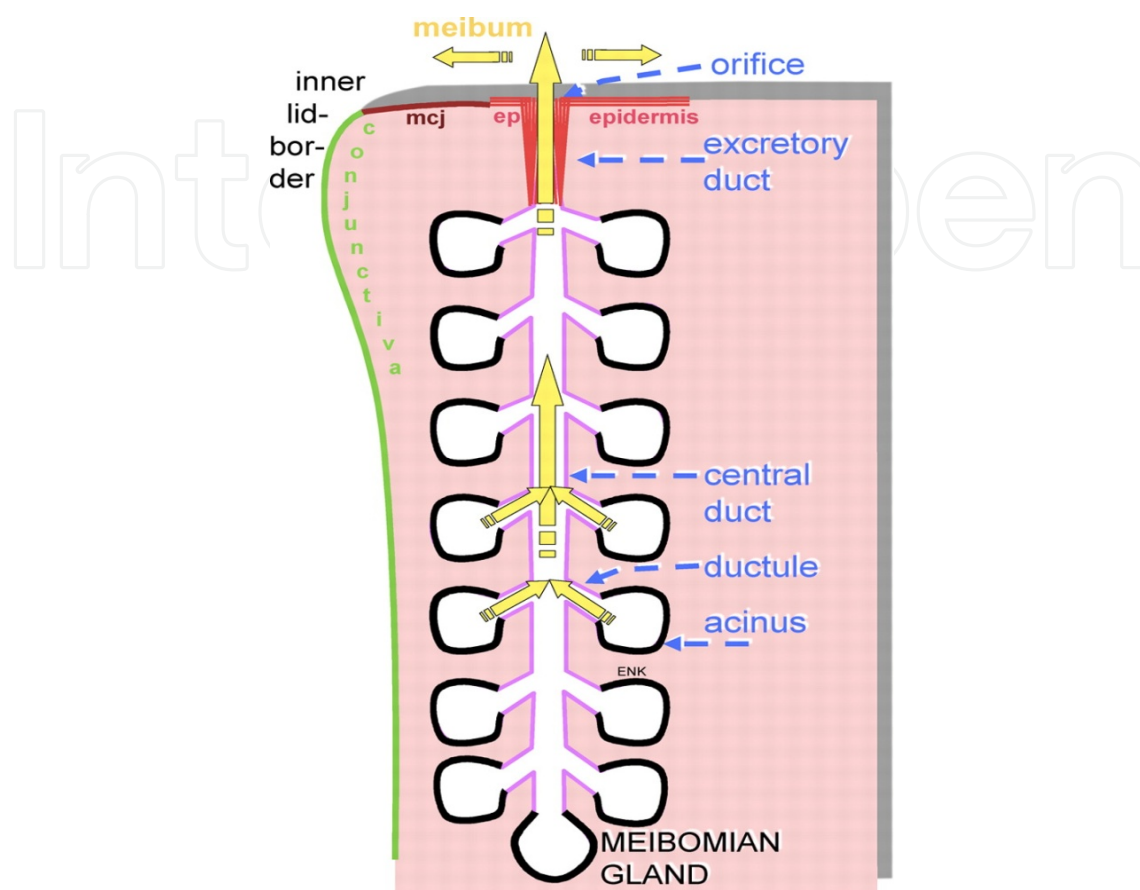
An estimate of the prevalence of dry eyes is difficult given that many sufferers may be asymptomatic or dismissive of subjective questionnaires of their symptoms if mild. Various studies estimate the prevalence as between 7.4% to 33.7% [2-3]. The epidemiology of dry eye depends on the mode of diagnosis, population surveyed and study cited.

Large American epidemiological studies estimate symptomatic dry eyes to affect 7% of women and 4% of men over the age of 50 years in the United States [4]. Similar data is seen in Australian studies [3]. The far eastern studies report the largest proportion of dry eye sufferers with Taiwan having the highest at 33.7% [5] followed by Japan and Indonesia [6].

2. Meibomian gland dysfunction

The meibomian glands, named after the German physician Meibom in 1666, are specialised sebaceous glands within the eyelids. They number 20-5 on the lower lids and up to 50 on the upper lid. Meibomian glands are responsible for secretion of a lipid rich mixture call meibum onto the tear surface through small openings found on the lid margin. A single gland consists of a central duct linked to multiple acini via ductules. Meibum is loaded into acini and released

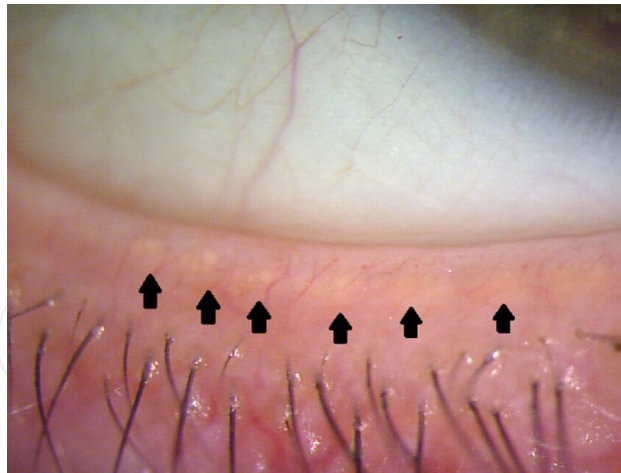
into the central duct where it moves to the openings on the lid margin and ocular surface. The glands undergo constant renewal and are delicate owing to their holocrine nature.



Scheme 1. Diagram courtesy of International Workshop on Meibomian Gland Dysfunction

It is widely thought that reduced meibum quality and quantity in addition to hyperkeratinisation of the ductal epithelium are the main reasons for meibomian gland dysfunction (MGD). Hyperkeratinised ducts and thicker meibum secretions lead to obstruction of the ducts. A progressive increase in pressure from continuous meibum secretion causes widening of the duct, acinar atrophy with cornification of duct epithelia. Ultimately there is reduced meibum secretion and gland drop out causing an unstable tear film. [7]

The tear film lubricates the ocular surface, which is vital to its maintaining its function and well being. It also forms a vital role in light refraction in the air-tear-cornea interface. Tear film is structured into 3 primary layers: The inner layer comprises mucin and a layer of glycocalyx that is synthesised by the conjunctiva and epithelial cells. The lacrimal gland primarily secretes the middle aqueous layer. The outermost lipid layer is secreted by the meibomian gland. This superficial layer stabilises the tear film by preventing its evaporation. Meibomian gland dysfunction is the most common cause of evaporative dry eye. Left untreated dry eye initially causes irritating ocular surface symptoms and signs that can threaten visual impairment, cause corneal perforation and blindness.[8]



(courtesy of Stoke Mandeville Hospital)

Figure 1. Lower lid meibomian glands

Broadly meibomian gland dysfunction can be defined as *a chronic, diffuse abnormality of the meibomian glands commonly characterized by terminal duct obstruction and/or qualitative/quantitative changes in the glandular secretion. It may result in alteration of the tear film, symptoms of eye irritation, clinically apparent inflammation, and ocular surface disease*[9-10].

3. Aetiology

Meibomian gland dysfunction can affect many different groups.

Age is a major risk factor for the development of MGD. It is more common in the elderly. Studies in humans seem to mirror the effects in animals [9]. Decreased acinar proliferation, atrophy and altered localisation of the lipogenesis factor PPAR γ (regulates meibomian differentiation and secretion) are seen in mice. Elderly patients have been noted to have a higher rate of meibomian gland dropout [10-11] with half as many functioning glands between 20 to 80 years of age. Human cadaveric studies show gland orifice metaplasia and narrowing [12-13] with hyperkeratinisation and lipogranulomatous inflammatory changes. Additionally meibum composition changes with age yielding a reduced volume and increased viscosity [10-14].

Androgens are known to be integrally involved in differentiation of sebaceous glands all over the body and have been shown to promote genes essential for meibomian function [13-14]. Furthermore, complete androgen insensitivity syndrome has been shown to have altered meibomian glands and composition of lipid secretions that resulted in clinically apparent signs and symptoms of MGD [15-16].

Confusingly, chronic blepharitis has been suggested as a cause for MGD. Whilst MGD itself is a cause of chronic blepharitis, there is considerable overlap with other causes of chronic blepharitis that may accentuate MGD. One study showed 74% (42 of 57) chronic blepharitis

sufferers had evidence of meibomian gland loss on meibography whereas 20% (4) of matched normal patients had any dropout. More detailed understanding is needed regarding the overlap of MGD with chronic blepharitis [18-19].

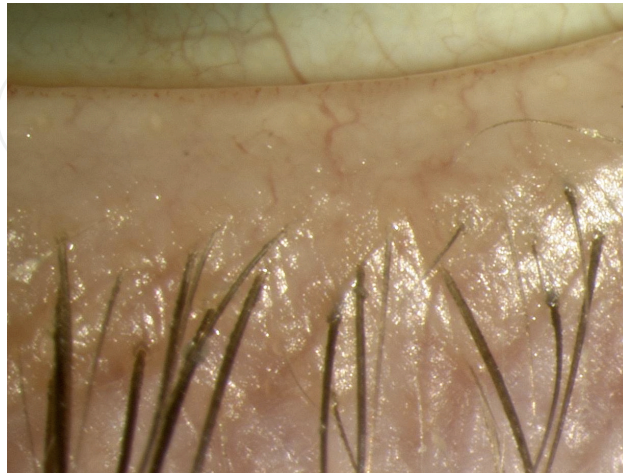


Figure 2. Lower lid meibomian glands and dropout in an elderly patient (courtesy of S Tuft)

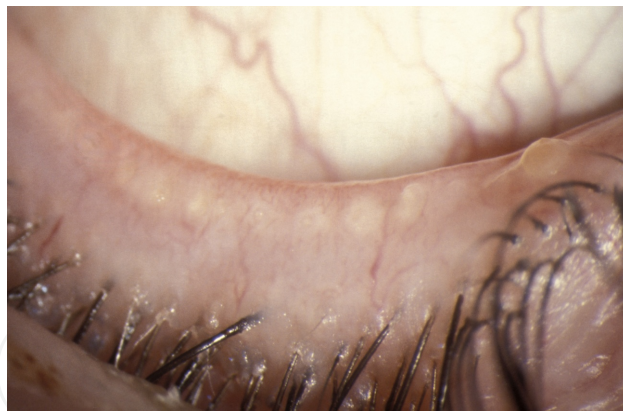


Figure 3. Meibum secretions of elderly patient showing increased plugging and viscosity (courtesy of S Tuft)

Demodex mites are the most common ectoparasites found in human skin. Of this species *D.brevis* is thought to be the most pertinent in MGD [20]. Current thinking is that the mite burrows deep into sebaceous and meibomian glands to feed on sebum and meibum respectively, as this forms as its main food source. Its chitinous exoskeleton causes a granulomatous reaction which ultimately leads to a mechanical blockage of the gland. *D.brevis* has been found in the centre of granulomatous meibomian glands surrounded by histocytes, epithelioid cells,

fibroblasts and plasma cells which may thus offer a potential explanation for refractory and recurrent chalazia in some patients. [21]

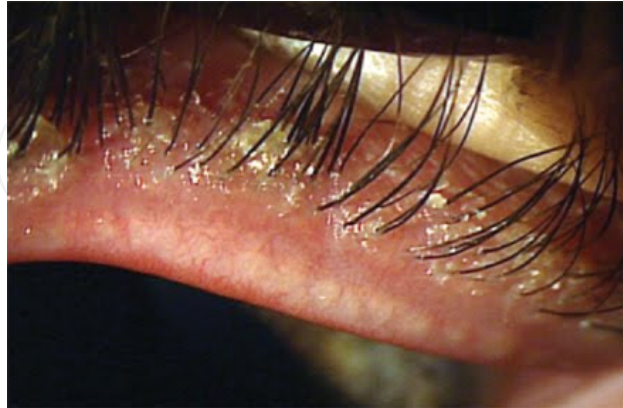

Figure 4. Desmodex infested lashes with meibomian gland dysfunction

Contact lens wear can increase the risk of MGD. Studies utilising meibography have shown that contact lenses alter meibomian gland morphology with greater rates of dropout than non-contact lens wearers. The duration and type of contact lens was weakly associated with this. By inserting and removing contact lenses, desquamated epithelial cells have been shown to obstruct the duct orifice leading to stagnation and atrophy [22-23]. While some studies show a statistically significant increase in MGD in contact lens wearers [22-24] others did not show significant differences [25-26]. It is important however to bear in mind these studies defined meibomian gland dysfunction differently. Damage to stem cells at the limbus is likely to be different based on duration on contact lens wear and may help account for the differences.

Environment may play a role in MGD. It is likely that factors such as temperature, humidity and visual undertaking have an accentuating impact rather than develop MGD. For example, concentrated computer use may be associated with reduced blink rate, exacerbating symptoms of MGD. One study of 70 patients found 74% of video display terminal users had MGD [27]. Decreased conjunctival temperature has been suggested to cause obstructive MGD through increased meibum viscosity [28-29].

Various medical conditions have been associated with MGD. Polycystic ovary syndrome (PCOS), where there is often insulin resistance and hyperinsulinaemia can result in increased androgen synthesis. Androgen receptors have been found in meibomian glands with a possible effect on function [30-33]. Twenty two (22)% of PCOS patients had MGD compared to 13% of normals in one study [34].

Dyslipidaemia appears to be associated with MGD. Patients with moderate to severe MGD have a higher incidence of dyslipidemia with respect to elevated total cholesterol than the general population [35-36]. Higher meibomian cholesterol ester levels are associated with MGD in humans [37].

Sjorgen's syndrome has been shown to have a higher incidence of MGD. One study found a higher incidence of MGD in MGD related dry eye to other causes of dry eye. The actual association, whether causative or a consequence of dry eye is not established and further study is needed [38-39]

Multiple medications have been implicated as possible risk factors for MGD. Studies looking at the acne treatment isotretinoin, 13-cis retinoic acid, have found that this resulted in altered meibum secretion, atrophy of the gland, reduced tear break up time and dry eye symptoms [40-41]. Other studies have looked at medication under the umbrella category of dry eye, not specially MGD. There may however be some overlap with MGD. Included in this category are antihistamines. One study has shown that treatment of allergic conjunctivitis with once daily loratidine resulted in signs of ocular dryness [42-43].

Post-menopausal hormone therapy has been associated with MGD [44-47] although the pathophysiology is not fully understood. Whilst established that sex hormone levels change from pre-to post-menopause, it is presumed that PMH results in changes to meibum gland secretions that can lead to MGD. Higher estrogen levels post-menopausally have been implicated in reduced tear function [45]. The largest of the studies, looking at 3500 patients from the Blue Mountain Study has shown a statistically significant 60% higher prevalence of dry eye in PMH users. A longer duration of use has been associated with longer symptoms [44].

Anitidepressant use has been associated with a higher risk of evaporative dry eye symptoms. Often many such medications simply have visual blurring only as a side effect without any mention of dry eye disease [48-51].

Omega 3 oils have been shown to have a beneficial effect on MGD whilst omega 6 oils have an opposite effect. Both are essential for growth and development. The omega 3 oils are found naturally in Mediterranean diets, flaxseed and cod liver oil [52]. Omega 6 oils are found typically in Northern European diets containing high red meat and less of the above [52]. The most detailed study to date showed a reduction in meibum thickness, dry eye signs and tear break up time in those with a high omega 3 to omega 6 ratio [53], agreeing with previous findings [52, 54, 55]. These oils compete for an enzyme involved in the inflammatory pathway therefore it is the ratio of omega 3 and 6 that is crucial. The ideal omega 6:3 ratio is 4:1 but typical Northern European and American diets are in the realm of 14:1 A higher omega 6 to 3 ratio results in overproduction of pro-inflammatory PGE2 from omega 6 and underproduction of anti-inflammatory PGE1 and PGE3 via omega 3 that induces MGD [53].

4. Presentation

Meibomian gland dysfunction is the leading cause of evaporative dry eye. As such patients will present with dry eye symptoms.

Most patients with MGD are likely to be asymptomatic. The vast majority will not experience any symptoms unless it is moderate in nature or exacerbated by other causes of evaporative dry eye. Burning, irritation, redness, watering or intermittent visual blur are frequently

described. It is important to ask what time of day this occurs to try to distinguish from other causes of dry eye. Blepharitis is typically worse in the morning with redness, crusting, puffiness, itchy lids or a 'gritty sensation' within the eyes.

5. Clinical assessment

There are different ways to assess meibomian gland dysfunction. Whilst a slit lamp is certainly beneficial and the commonest form of assessment, one can simply use a direct ophthalmoscope for those in primary care settings. Though it does not give as detailed a view the principles are the same as for slit lamp examination. The key is to observe the meibomian glands and ocular surface. With the ophthalmoscope one needs to place on high magnification to view the state of the meibomian glands which are located posterior to the greyline. Often orifices can be seen to be plugged, or pouting. Surrounding tissue can be erythematous with telangiectatic vessels. Misdirected eyelashes can also be a sign of eyelid inflammatory changes. A good clinical examination will also include eversion of the eyelids which will often show white, hard deposits called concretions on the tarsal conjunctiva, follicles or granulomatous changes from previous chalazia. The ocular surface should also be assessed. Important to evaporative dry eyes is assessment of the tear film break up (TFBUT). This is done by instilling fluorescein sodium 2% (although 0.25% is an acceptable alternative) and asking the patient to blink a few times. The patient should then be asked to keep their eyes open and careful note of the time taken for vacuoles to appear in the tear film. A normal time frame is 10-15 seconds. The ocular surface should also be noted for punctate epithelial erosions which can be wide-spread or mainly inferior. In severe cases mucous filaments have been noted on the cornea. Abrasions can also be seen in those with associated in-turned eyelashes. The conjunctiva can be injected to varying degrees. As MGD is almost always bilateral, a unilateral presentation must alert the clinician of the possibility of basal cell carcinoma or meibomian cell carcinoma.

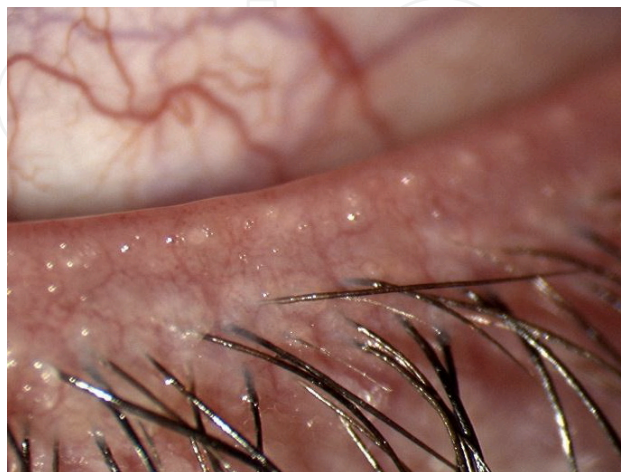


Figure 5. Thickened meibomian secretions i

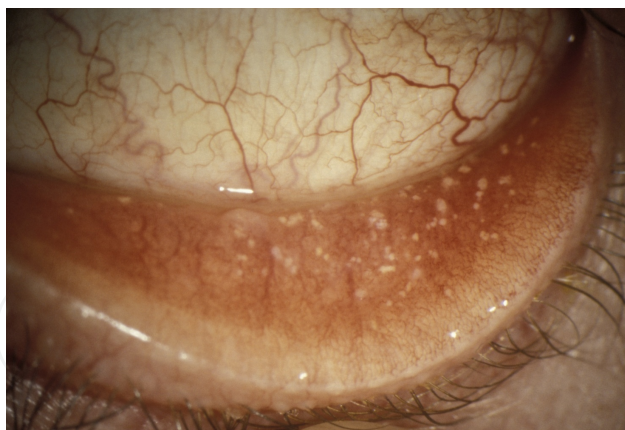


Figure 6. Concretions on the lower lid (courtesy of S Tuft)

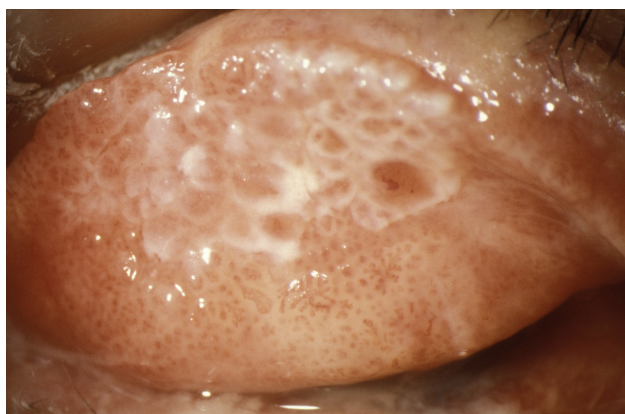


Figure 7. Follicles and sebaceous material (courtesy of S Tuft)

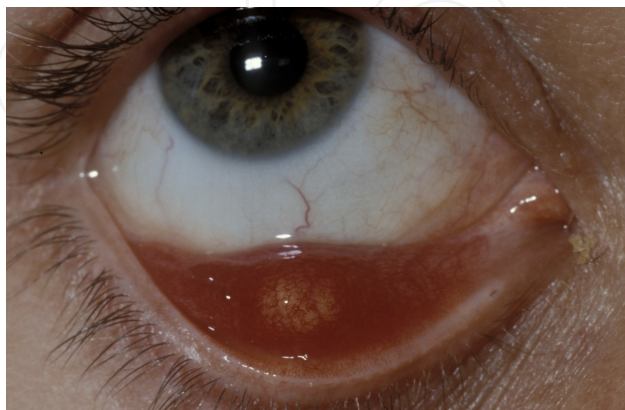


Figure 8. Chalazion on lower lid (courtesy of S Tuft)

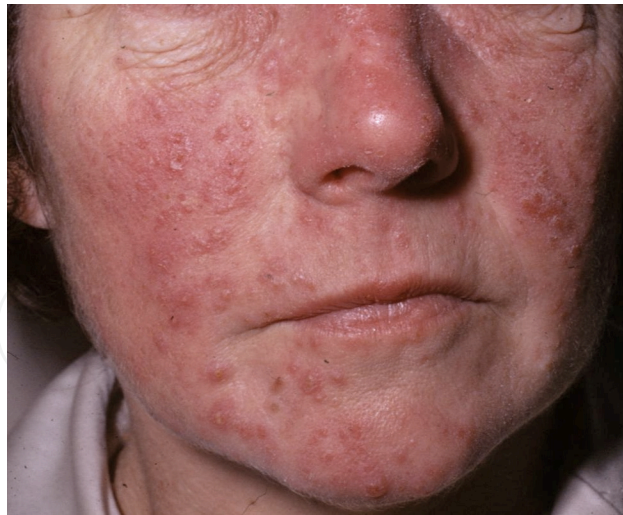

Figure 9. Rosacea above is associated with meibomian gland dysfunction (courtesy of S Tuft)

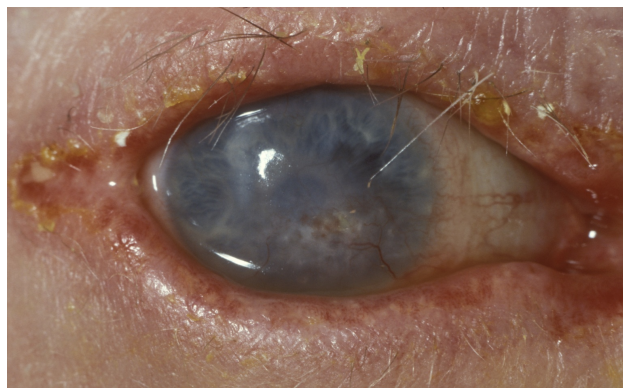


Figure 10. Trichiatric lashes resulting in corneal damage (courtesy of S Tuft)

There is no universal classification system of MGD. Different approaches have been used. The International Workshop Meibomian Gland subcommittee have recommended categorisation into 4 subtypes, although this is not universally applied.

1. MGD alone Asymptomatic Symptomatic (noncicatricial, cicatricial)
2. MGD with associated with ocular surface damage
3. MGD-related evaporative dry eye
4. MGD associated with other ocular disorders.

Alternatively, clinical measurement has been described. This is based on lid signs and meibum quality. Meibum can be graded on the Oxford score scale 0-3 (0=clear, 1=cloudy, 2=cloudy/particulate and 3=toothpaste like) [107].

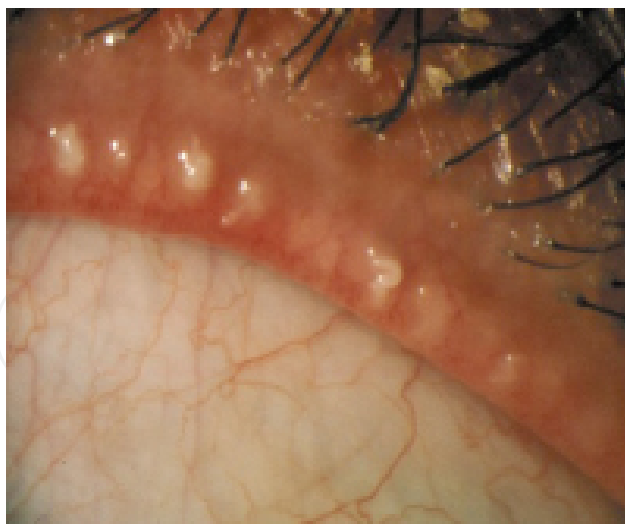


Figure 11. cloudy and particulate meibum: Oxford scale 2

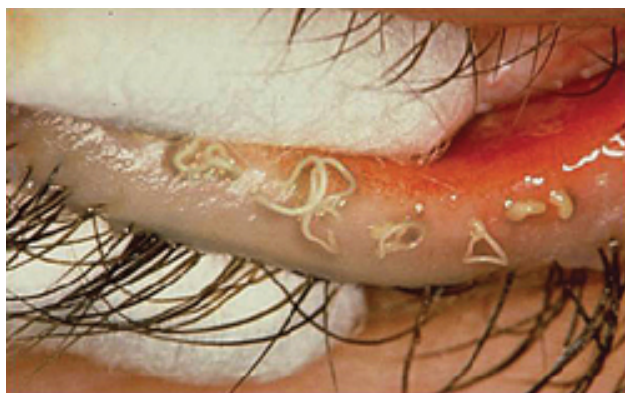

Figure 12. Toothpaste like meibum: Oxford score 3

5.1. Differential

A common misnomer is that MGD and posterior blepharitis are interchangeable terms [56-58]. Some previous literature has used the terms as such. MGD though, is one cause of posterior blepharitis (inflammation of the lid margins) and must be distinguished from other causes based on the anatomical structures of the posterior lid. Other causes include conjunctivitis (allergic or infective) and dermatological (acne rosacea or seborrheic dermatitis).

Anterior blepharitis is another differential. This refers to inflammation anterior to the gray line, particularly around the lashes. The gray line anatomically subdivides the anterior and posterior lamellae of the lid. Anterior blepharitis can result in scurf on lashes, collarettes at the lash base and vascular changes of the eyelids.

5.2. Treatment principles

Typically treatment is predominantly based on the general term 'lid hygiene', ocular lubricants and antibiotics. There are more recent advances in the field and these are described further below.

Lid hygiene as a method varies across different centres [59]. Currently there is no standardised method. Commonly patients are told to either to place a warm compress over the lids at least twice daily or massage the lids for 10 minutes during each session. Compresses alone have been shown to cause transient visual blurring [60-61]. Active massage is encouraged. MGD secretions have been shown to have higher melting (35 C) points relative to normal (32C) [62-63]. The warmth melts the pathological meibum within the glands and active massage helps to unblock the glands. The authors feel that cotton wool whilst more gentle on the eye is often not firm enough to dislodge meibum that a flannel or towel is able to do. Lid hygiene is made more efficient by encouraging active massage just under the lashes themselves so the patient can directly affect the glands themselves. This needs to be demonstrated to patients directly. By pressing the lateral canthus firmly, traction can be provided and using a flannel the pulp of the finger swept gently over the inner aspect of the upper and lower lids. This needs to be balanced against any possible damage to the ocular and careful explanation and assessment of patient technique needs to be balanced against this [64-65]. The use of mild baby shampoo over the lids has also been advocated as part of lid hygiene. Ultimately patients need to be educated that lid hygiene is the basis upon which MGD will be controlled and that compliance is crucial in not only reducing symptoms but preventing recurrence.

Physical expression of the meibomian glands has been described [66-67]. Methods vary from gentle lid palpation to forceful squeezing of the lids. Use of a finger on the outer lid and a rigid object on the inner aspect like a metal paddle have been reported [68]. Often considerable force is needed to express pathological meibum and transient visual blurring owing to corneal distortion has been reported [60-61]. We believe that the risks involved and potential discomfort from this outweigh any benefit and do not recommend this.

Ocular lubricants are helpful to provide symptomatic relief. They help to alleviate symptoms experienced secondary to evaporative dry eye and do not treat the MGD itself. It is important for patients to realise that they are not a cure but give temporary respite. Ocular lubricants are helpful in bolstering the tear film volume, spreading of tears [69] and providing a layer over the cornea that reduced the possibility of corneal erosion from friction of the lid moving over the cornea by blinking [70-71]. The ocular lubricants may also help wash away pro-inflammatory molecules and dilute the concentration of inflammatory cytokines in tears. This has not been tested and remains a speculative theory presently.

Much research has been based around the contents of ocular lubricants. Preservatives can cause discomfort and toxicity to the corneal epithelium. Frequently used preservatives like benzylalkonium chloride and polyquaternium have been shown to decrease goblet cell density and thus affect tear film stability [72-77]. There is no evidence nor consensus on frequency of usage. It should be based on an individual level. Preservative free drops are recommended in severe dry eye where high frequency drops are required. More recently so called vanishing preser-

vatives such as sodium perborate or sodium chlorite have been incorporated into artificial tears. There is a lack of data to date to suggest whether these have the intended less preservative toxicity than the traditional preservatives mentioned.

Lipid supplemented tears have been shown of benefit in MGD [79-84]. Patients have reported reduced symptoms with an increased tear break up time and thicker lipid layer of the tear film. Castor oil drops have been shown to reduce tear break up time in a randomised control trial [84]. Temporary visual blurring has been reported in older studies that used ointments but more recent formulations have not been shown to have this problem [84]

Leading from this is the viscosity of the ocular lubricant. The greater the viscosities the more benefit in bulking tear film thickness and volume in dry eyes [85-87] as well as increased transit time on the eye. This needs to be counterbalanced against visual blurring and inconvenience.

Antibiotics are often used in MGD. The exact pathogenesis of bacteria remains not entirely understood. However the presence of bacterial flora on the lid surface, notably staphylococcus epidermidis, staph aureus, propion acnes amongst others is known. It may be the case that the keratinisation of the meibum and abnormal lipids provide prime conditions for normal bacterial flora to produce enzymes such as lipases and exotoxins resulting in proinflammatory changes. Thus an antibiotic would need to be effective against common flora.

Macrolides are commonly used. Studies have shown that they exert many anti-inflammatory effects. Neutrophil activity is affected by downregulating adhesion protein expression [88]. Phagocytosis and chemotaxis are affected through this. A reduction in proinflammatory cytokines has been demonstrated [89-90].

Tetracyclines have multiple helpful anti-inflammatory properties, including influencing neutrophil chemotaxis and proliferation of lymphocytes [91-92]. Matrix metalloproteinases and inflammatory cytokines like IL1 are suppressed as are anti-angiogenesis properties [93-94]. Collagenase 2 (matrix metalloproteinase P8) is directly suppressed by doxycycline specifically. They have been established for treatment of acne rosacea. Lipase production of the typical bacterial flora such as S epidermidis is suppressed. The lipases are responsible for production of pro-inflammatory free fatty acids that can destabilise the tear film and directly alter meibum composition. The tetracyclines as a group have varying lipophilicity that alters individual drug pharmacokinetics. The international workshop on meibomian gland dysfunction recommend the use of doxycycline and minocycline [96]. These have been shown to be clinically effective at lower doses relative to tetracycline, which is poorly lipophilic and has been found at lower relative concentrations in tears after 5 days [97-100]. Typically doxycycline or minocycline are given at 100mg dosage for 2 months.

Dietary modification have been popular treatments amongst patients. Omega 3 rich foods as can be found in flax seed or cod-liver oil have been shown to have improved meibum scores, tear break up time and surface signs [100-102]. Omega 6 rich foods such as red meat have a counter effect and should be discouraged [101].

Surgical management is reserved for complications from MGD. Typically this would occur where the MGD is severe. Chalazia can be treated with incision and curettage where they are

inflamed and affecting vision. Eyelid cicatrisation may cause trichiatic lashes that can commonly undergo epilation or electrolysis. Lid laxity, ectropion or entropion may be treated surgically.

Recently, devices have been created to be worn by patients to help with lid hygiene. These include blepharitis goggles, which aim to provide heat and moisture via steam to unclog blocked meibomian glands [103-104]. LipiFlow® Thermal Pulsation System is similar but provides heat therapy and physical pressure to express the meibomian glands [105]. These variables can be adjusted accordingly, and seems to offer more favourable outcomes over 12 months than typical lid hygiene and lubricating drops [105]. The evidence base for such devices is currently limited further studies on outcomes and potential side effects are needed.

5.3. Primary care setting

It is understandably difficult to make an unambiguous diagnosis of meibomian gland dysfunction without a slit lamp in primary care or on the ward.

However through careful history of symptoms and possible risk factors mentioned earlier, along with a direct ophthalmoscope on high magnification, an informed judgment can be made. Use of the direct ophthalmoscope does require practice to look at anterior surface structures in detail. Most hand held ophthalmoscopes have a cobalt blue mode, meaning that with available fluroscein drops an evaluation of the tear break up time and state of the corneal surface can be undertaken.

Where MGD is suspected, we would recommend starting lid hygiene, taking care to assess whether the patient is capable of performing this safely without damage to anterior structures. If there is suspicion of anterior surface structure damage from unsafe hygiene measures or possible other causes we recommend referral without starting lid hygiene. Prescribing suitable preservative free lubricating eye drops is recommended before ophthalmic referral.

6. Conclusion

Meibomian gland dysfunction is the most common ocular sign encountered in patients and cause of evaporative dry eye. Whilst awareness of the condition improves and research continues to be undertaken, a universal consensus on the definition, pathophysiology, signs and management is still being awaited. This is needed to allow for earlier detection and optimal structured treatment for MGD. Further questions do need to be answered regarding meibomian gland dysfunction too. Owing to a lack in consensus over definition and clinical tests performed in studies there is difficulty comparing results in different studies. The International Workshop for Meibomian Gland Dysfunction have suggested future research aim to prioritise a specific validated questionnaire for symptoms, a standard grading system of signs and validated outcomes for MGD [106]. It is hoped this will provide greater clarity in diagnosing, understanding the extent and severity of disease. Ultimately this would allow the most suitable treatment to be started improving the level of patient care in meibomian gland dysfunction.

Author details

Vikas Tah^{1,2*}, Kamran Saha², James Myerscough³, Muhammad Ahad¹, Jason Ho², Pranev Sharma⁴, Fariyah Tariq⁵ and Stephen Tuft²

1 Stoke Mandeville Hospital, UK

2 Moorfields Eye Hospital London, UK

3 Colchester University Hospital NHS Foundation Trust, UK

4 Chelsea and Westminster Hospital, UK

5 Raigmore Hospital Inverness, UK

References

- [1] CLAO J. 1995 Oct;21(4):221-32. Report of the National Eye Institute/Industry workshop on Clinical Trials in Dry Eyes. Lemp MA.
- [2] Ophthalmology. 2003 Jun;110(6):1096-101. Prevalence of dry eye among an elderly Chinese population in Taiwan: the Shihpai Eye Study. Lin PY, Tsai SY, Cheng CY, Liu JH, Chou P, Hsu WM.
- [3] Ophthalmology. 1998 Jun;105(6):1114-9. The epidemiology of dry eye in Melbourne, Australia. McCarty CA, Bansal AK, Livingston PM, Stanislavsky YL, Taylor HR.
- [4] Am J Ophthalmol. 2003 Aug;136(2):318-26. Prevalence of dry eye syndrome among US women. Schaumberg DA, Sullivan DA, Buring JE, Dana MR.
- [5] Results of a population-based questionnaire on the symptoms and lifestyles associated with dry eye. Shimmura S, Shimazaki J, Tsubota K. Br J Ophthalmol. 2002 Dec; 86(12):1347-51.
- [6] Prevalence and risk factors associated with dry eye symptoms: a population based study in Indonesia. Lee AJ, Lee J, Saw SM, Gazzard G, Koh D, Widjaja D, Tan DT.
- [7] The international workshop on meibomian gland dysfunction: report of the subcommittee on anatomy, physiology, and pathophysiology of the meibomian gland. Knop E, Knop N, Millar T, Obata H, Sullivan DA. Invest Ophthalmol Vis Sci. 2011 Mar 30;52(4):1938-78. doi: 10.1167/iovs.10-6997c. Print 2011 Mar. Review. No abstract available.
- [8] Research in dry eye: report of the Research Subcommittee of the International Dry Eye WorkShop(2007). [No authors listed] Ocul Surf. 2007 Apr;5(2):179-93. Review. PMID:17508121

- [9] Aging and dry eye disease. Ding J, Sullivan DA. *Exp Gerontol.* 2012 Jul;47(7):483-90. doi: 10.1016/j.exger.2012.03.020. Epub 2012 Apr 28. Review. PMID:22569356
- [10] Norn, M., 1987. Expressibility of meibomian secretion. Relation to age, lipid precorneal film, scales, foam, hair and pigmentation. *Acta Ophthalmol.* 65, 137–142.
- [11] Arita, R., Itoh, K., Inoue, K., Amano, S., 2008. Noncontact infrared meibography to document age-related changes of the meibomian glands in a normal population. *Ophthalmology* 115, 911–915
- [12] Hykin, P.G., Bron, A.J., 1992. Age-related morphological changes in lid margin and meibomian gland anatomy. *Cornea* 11, 334–342
- [13] Sullivan, B.D., Evans, J.E., Dana, M.R., Sullivan, D.A., 2006. Influence of aging on the polar and neutral lipid profiles in human meibomian gland secretions. *Arch. Ophthalmol.* 124, 1286–1292.
- [14] Schirra, F., Richards, S.M., Liu, M., Suzuki, T., Yamagami, H., Sullivan, D.A., 2006. Androgen regulation of lipogenic pathways in the mouse meibomian gland. *Exp. Eye Res.*
- [15] Krenzer, K.L., Dana, M.R., Ullman, M.D., Cermak, J.M., Tolls, D.B., Evans, J.E., Sullivan, D.A., 2000. Effect of androgen deficiency on the human meibomian gland and ocular surface. *J. Clin. Endocrinol. Metab.* 85, 4874–4882
- [16] Sullivan, B.D., Evans, J.E., Cermak, J.M., Krenzer, K.L., Dana, M.R., Sullivan, D.A., 2002a. Complete androgen insensitivity syndrome: effect on human meibomian gland secretions. *Arch. Ophthalmol.* 120, 1689–1699.
- [17] Sullivan, B.D., Evans, J.E., Dana, M.R., Sullivan, D.A., 2002b. Impact of androgen deficiency on the lipid profiles
- [18] Mathers WD, Shields WJ, Sachdev MS, Petroll WM, Jester JV. Meibomian gland dysfunction in chronic blepharitis. *Cornea.* 1991;10:277–285
- [19] The international workshop on meibomian gland dysfunction: report of the subcommittee on the epidemiology of, and associated risk factors for, MGD. Schaumberg DA, Nichols JJ, Papas EB, Tong L, Uchino M, Nichols KK. *Invest Ophthalmol Vis Sci.* 2011 Mar 30;52(4):1994-2005. doi: 10.1167/iovs.10-6997e. Print 2011 Mar. Review. No abstract available.
- [20] Corneal manifestations of ocular demodex infestation. Clinical treatment of ocular demodocosis by lid scrub with tea tree oil. Gao YY, Di Pascuale MA, Elizondo A, Tseng SC *Cornea.* 2007 Feb; 26(2):136-43.
- [21] *Am J Ophthalmol.* 1985 Sep 15;100(3):482-3.Desmodectic mites and chalazion. English FP, Cohn D, Groeneveld ER.
- [22] Korb DR, Henriquez AS. Meibomian gland dysfunction and contact lens intolerance. *J Am Optom Assoc.* 1980;51:243–251

- [23] Henriquez AS, Korb DR. Meibomian glands and contact lens wear. *Br J Ophthalmol*. 1981;65:108–111
- [24] Ong BL, Larke JR. Meibomian gland dysfunction: some clinical, biochemical and physical observations. *Ophthalmic Physiol Opt*. 1990;10:144–148
- [25] Prevalence of Meibomian gland dysfunction. Hom MM, Martinson JR, Knapp LL, Paugh JR *Optom Vis Sci*. 1990 Sep; 67(9):710-2.
- [26] Relation between contact lens wear and Meibomian gland dysfunction. Ong BL *Optom Vis Sci*. 1996 Mar; 73(3):208-10.
- [27] Meibomian gland dysfunction and ocular discomfort in video display terminal workers.
- [28] Fenga C, Aragona P, Cacciola A, Spinella R, Di Nola C, Ferreri F, Rania L *Eye (Lond)*. 2008 Jan; 22(1):91-5.
- [29] Nagymiha'lyi A, Dikstein S, Tiffany JM. The influence of eyelid temperature on the delivery of meibomian oil. *Exp Eye Res*. 2004;78(3):367-370
- [30] Baudouin C. The pathology of dry eye. *Surv Ophthalmol*. 2001;45:211–220.
- [31] McCulley JP, Shine WE. The lipid layer of tears: Dependent on meibomian gland function. *Exp Eye Res*. 2004;78:361–365.
- [32] Sutphin JE, Chodosh J, Dana MR, et al. Normal physiology of the ocular surface. In: Liesegang TJ, Skuta GL, Cantor LB, eds. *Basic and Clinical Science Course External Disease and Cornea*. San Francisco: American Academy of Ophthalmology; 2005: 47–52.
- [33] Sullivan DA, Sullivan BD, Ullman MD, et al. Androgen influence on the meibomian gland. *Invest Ophthalmol Vis Sci*. 2000;41:3732–3742.
- [34] *Curr Eye Res*. 2008 Feb;33(2):133-8. Meibomian gland alterations in polycystic ovary syndrome. Yavas GF, Ozturk F, Kusbeci T, Ermis SS, Yilmazer M, Cevrioglu S, Aktepe F, Kose S.
- [35] Association of dyslipidemia in moderate to severe meibomian gland dysfunction. Dao AH, Spindle JD, Harp BA, Jacob A, Chuang AZ, Yee RW. *Am J Ophthalmol*. 2010 Sep;150(3):371-375.e1. doi: 10.1016/j.ajo.2010.04.016
- [36] *Ophthalmol Plast Reconstr Surg*. 2013 Mar-Apr;29(2):101-3. doi: 10.1097/IOP.0b013e31827a007d. Associations between the grade of meibomian gland dysfunction and dyslipidemia. Bukhari AA.
- [37] Shine WE, McCulley JP. The role of cholesterol in chronic blepharitis. *Invest Ophthalmol Vis Sci* 1991;32: 2272–2280.
- [38] Meibomian gland dysfunction in patients with Sjögren syndrome. Shimazaki J, Goto E, Ono M, Shimmura S, Tsubota K *Ophthalmology*. 1998 Aug; 105(8):1485-8.

- [39] Tear evaporation rates in Sjögren syndrome and non-Sjögren dry eye patients. Goto E, Matsumoto Y, Kamoi M, Endo K, Ishida R, Dogru M, Kaido M, Kojima T, Tsubota K *Am J Ophthalmol*. 2007 Jul; 144(1):81-85
- [40] Ocular side effects associated with 13-cis-retinoic acid therapy for acne vulgaris: clinical features, alterations of tearfilm and conjunctival flora. Egger SF, Huber-Spitzy V, Böhler K, Raff M, Scholda C, Barisani T, Vecsei VP. *Acta Ophthalmol Scand*. 1995 Aug; 73(4):355-7.
- [41] Ocular side effects of isotretinoin therapy. [J Am Optom Assoc. 1988] Caffery BE, Josephson JE *J Am Optom Assoc*. 1988 Mar; 59(3):221-4.
- [42] Prevalence of and risk factors for dry eye syndrome. [Arch Ophthalmol. 2000] Moss SE, Klein R, Klein BE *Arch Ophthalmol*. 2000 Sep; 118(9):1264-8.
- [43] An open-label, investigator-masked, crossover study of the ocular drying effects of two antihistamines, topical epinastine and systemic loratadine, in adult volunteers with seasonal allergic conjunctivitis. Ousler GW 3rd, Workman DA, Torkildsen GL. *Clin Ther*. 2007 Apr; 29(4):611-6.
- [44] Dry eye in post-menopausal women using hormone replacement therapy. [Maturitas. 2007] Erdem U, Ozdegirmenci O, Sobaci E, Sobaci G, Göktolga U, Dagli S *Maturitas*. 2007 Mar 20; 56(3):257-62.
- [45] W.D. Mathers, D. Strovall, J.A. Lane, M.B. Zimmerman Menopause and tear function: the influence of prolactin and sex hormones on human tear production *Cornea*, 17 (4) (1998), pp. 353–358
- [46] B.E. Klein, R. Klein, L.L. Ritter Is there evidence of estrogen effect on age-related lens opacities? The Beaver Dam Eye Study *Arch Ophthalmol*, 112 (1994), pp. 85–91
- [47] Chia EM, Mitchell P, Rochtchina E, Lee AJ, Maroun R, Wang JJ. Prevalence and associations of dry eye syndrome in an older population: The Blue Mountains Eye Study. *Clin Exp Ophthalmol*. 2003;31:229–232
- [48] Schaumberg DA, Dana R, Buring JE, Sullivan DA. Prevalence of dry eye disease among US men: estimates from the Physicians' Health Studies. *Arch Ophthalmol*. 2009;127:763–768
- [49] Long-term incidence of dry eye in an older population. Moss SE, Klein R, Klein BE *Optom Vis Sci*. 2008 Aug; 85(8):668-74.
- [50] Wilkes S Bupropion. *Drugs Today (Barc)* 2006;42 (10) 671-681 PubMed
- [51] Hudson JI Perahia DG Gilaberte I Wang F Watkin JG Detke MJ Duloxetine in the treatment of major depressive disorder: an open-label study. *BMC Psychiatry* 2007;743 PubMed
- [52] Omega-3 Dietary Supplementation in Dry Eye and Blepharitis *Trans Am Ophthalmol Soc / Vol 106 / 2008* 338

- [53] Calder PC. N-3 Polyunsaturated fatty acids and inflammation: from molecular biology to the clinic. *Lipids* 2003;38:343-352
- [54] Simopoulos AP. The Mediterranean diets: what is so special about the diet of Greece? The scientific evidence. *J Nutr* 2001;131:3065-3073S.
- [55] *Am J Clin Nutr.* 2005 Oct;82(4):887-93. Relation between dietary n-3 and n-6 fatty acids and clinically diagnosed dry eye syndrome in women. Miljanović B, Trivedi KA, Dana MR, Gilbard JP, Buring JE, Schaumberg DA.
- [56] Meibomian keratoconjunctivitis. McCulley JP, Sciallis GF *Am J Ophthalmol.* 1977 Dec; 84(6):788-93.
- [57] McCulley JP, Dougherty JM, Deneau DG. Classification of chronic blepharitis. *Ophthalmology.* 1982;89:1173-1180
- [58] Luchs J. Efficacy of topical azithromycin ophthalmic solution 1% in the treatment of posterior blepharitis. *Adv Ther.* 2008;25:858-870
- [59] The international workshop on meibomian gland dysfunction: report of the subcommittee on management and treatment of meibomian gland dysfunction. Geerling G, Tauber J, Baudouin C, Goto E, Matsumoto Y, O'Brien T, Rolando M, Tsubota K, Nichols KK. *Invest Ophthalmol Vis Sci.* 2011 Mar 30;52(4):2050-64. doi: 10.1167/iovs.10-6997g. Review
- [60] Warm compress induced visual degradation and Fischer-Schweitzer polygonal reflex. Solomon JD, Case CL, Greiner JV, Blackie CA, Herman JP, Korb DR *Optom Vis Sci.* 2007 Jul; 84(7):580-7.
- [61] Goto E, Monden Y, Takano Y, et al. Treatment of non-inflamed obstructive meibomian gland dysfunction by an infrared warm compression device. *Br J Ophthalmol.* 2002;86:1403-1407
- [62] Assessment of meibomian gland function in dry eye using meibometry. Yokoi N, Mossa F, Tiffany JM, Bron AJ. *Arch Ophthalmol.* 1999 Jun; 117(6):723-9
- [63] Review Meibomian secretions in chronic blepharitis. McCulley JP, Shine WE *Adv Exp Med Biol.* 1998; 438():319-26.
- [64] Smith GT, Dart J. External eye disease. In: Jackson TL, editor. ed. *Moorfields Manual of Ophthalmology.* Philadelphia: Mosby Elsevier; Chap 4:2008
- [65] Ehler J, Shah ChP. *Wills Eye Manual.* Philadelphia: Lippincott Williams & Wilkins; 2008
- [66] Krenzer, K.L., Dana, M.R., Ullman, M.D., Cermak, J.M., Tolls, D.B., Evans, J.E., Sullivan, D.A., 2000. Effect of androgen deficiency on the human meibomian gland and ocular surface. *J. Clin. Endocrinol. Metab.* 85, 4874-4882

- [67] Sullivan, B.D., Evans, J.E., Cermak, J.M., Krenzer, K.L., Dana, M.R., Sullivan, D.A., 2002a. Complete androgen insensitivity syndrome: effect on human meibomian gland secretions. *Arch. Ophthalmol.* 120, 1689–1699.
- [68] Mastrotta K. The meibomian Mastrotta paddle. Rosenberg, TX: Cynacon/Ocusoft, Inc., 2006. Available at <http://www.ocusoft.com/for-eye-care-professionals/surgical/misc-surgical-instruments/mastrotta-meibomian-paddle.html> Accessed: July 16, 2010
- [69] Rheology of tear film lipid layer spread in normal and aqueous tear-deficient dry eyes. Yokoi N, Yamada H, Mizukusa Y, Bron AJ, Tiffany JM, Kato T, Kinoshita S *Invest Ophthalmol Vis Sci.* 2008 Dec; 49(12):5319-24
- [70] Lid-wiper epitheliopathy and dry-eye symptoms in contact lens wearers. Korb DR, Greiner JV, Herman JP, Hebert E, Finnemore VM, Exford JM, Glonek T, Olson MC *CLAO J.* 2002 Oct; 28(4):211-6.
- [71] Prevalence of lid wiper epitheliopathy in subjects with dry eye signs and symptoms. Korb DR, Herman JP, Blackie CA, Scaffidi RC, Greiner JV, Exford JM, Finnemore VM *Cornea.* 2010 Apr; 29(4):377-83
- [72] Labbe A, Pauly A, Liang H, et al. Comparison of toxicological profiles of benzalkonium chloride and polyquaternium-1: an experimental study. *J Ocul Pharmacol Ther.* 2006;22:267–278
- [73] Fraunfelder FW. Corneal toxicity from topical ocular and systemic medications. *Cornea.* 2006;25:1133–1138. [PubMed]
- [74] Debbasch C, Brignole F, Pisella PJ, Warnet JM, Rat P, Baudouin C. Quaternary ammoniums and other preservatives' contribution in oxidative stress and apoptosis on Chang conjunctival cells. *Invest Ophthalmol Vis Sci.* 2001;42:642–652. [PubMed]
- [75] Furrer P, Mayer JM, Plazonnet B, Gurny R. Ocular tolerance of preservatives on the murine cornea. *Eur J Pharm Biopharm.* 1999;47:105–112. [PubMed]
- [76] Palmer RM, Kaufman HE. Tear film, pharmacology of eye drops, and toxicity. *Curr Opin Ophthalmol.* 1995;6:11–16. [PubMed]
- [77] Lapalus P, Ettaiche M, Fredj-Reygrobelle D, Jambou D, Elena PP. Cytotoxicity studies in ophthalmology. *Lens Eye Toxic Res.* 1990;7:231–242. [PubMed]
- [78] Burstein NL. Corneal cytotoxicity of topically applied drugs, vehicles and preservatives. *Surv Ophthalmol.* 1980;25:15–30
- [79] Low-concentration homogenized castor oil eye drops for noninflamed obstructive meibomian gland dysfunction. Goto E, Shimazaki J, Monden Y, Takano Y, Yagi Y, Shimmura S, Tsubota K *Ophthalmology.* 2002 Nov; 109(11):2030-5.
- [80] Topical omega-3 and omega-6 fatty acids for treatment of dry eye. Rashid S, Jin Y, Ecoiffier T, Barabino S, Schaumberg DA, Dana MR *Arch Ophthalmol.* 2008 Feb; 126(2):219-25.

- [81] Rieger G. Lipid-containing eye drops: a step closer to natural tears. *Ophthalmologica*. 1990;201:206–212. [PubMed]
- [82] Tiffany JM. Lipid-containing eye drops. *Ophthalmologica*. 1991;203:47–49. [PubMed]
- [83] Korb DR, Scaffidi RC, Greiner JV, et al. The effect of two novel lubricant eye drops on tear film lipid layer thickness in subjects with dry eye symptoms. *Optom Vis Sci*. 2005;82:594–601. [PubMed]
- [84] Craig JP, Purslow C, Murphy PJ, Wolffsohn JS. Effect of a liposomal spray on the pre-ocular tear film. *Cont Lens Anterior Eye*. 2010;33:83–87
- [85] Dynamic distribution of artificial tears on the ocular surface. Wang J, Simmons P, Aquavella J, Vehige J, Palakuru J, Chung S, Feng C *Arch Ophthalmol*. 2008 May; 126(5):619–25.
- [86] Simmons PA, Vehige JG. Clinical performance of a mid-viscosity artificial tear for dry eye treatment. *Cornea*. 2007;26:294–302
- [87] Khanal S, Tomlinson A, Pearce EI, Simmons PA. Effect of an oil-in-water emulsion on the tear physiology of patients with mild to moderate dry eye. *Cornea*. 2007;26:175–181.
- [88] Sanz MJ, Nabah YN, Cerda-Nicolas M, et al. Erythromycin exerts in vivo anti-inflammatory activity downregulating cell adhesion molecule expression. *Br J Pharmacol*. 2005;144:190–201.
- [89] Bosnar M, Bosnjak B, Cuzic S, et al. Azithromycin and clarithromycin inhibit lipopolysaccharide-induced murine pulmonary neutrophilia mainly through effects on macrophage-derived granulocyte-macrophage colony-stimulating factor and interleukin-1beta. *J Pharmacol Exp Ther*. 2009;331:104–113.
- [90] Yamaryo T, Oishi K, Yoshimine H, Tsuchihashi Y, Matsushima K, Nagatake T. Fourteen-member macrolides promote the phosphatidylserine receptor-dependent phagocytosis of apoptotic neutrophils by alveolar macrophages. *Antimicrob Agents Chemother*. 2003;47:48–53.
- [91] Sanchez J, Somolinos AL, Almodovar PI, Webster G, Bradshaw M, Powala C. A randomized, double-blind, placebo-controlled trial of the combined effect of doxycycline hyclate 20-mg tablets and metronidazole 0.75% topical lotion in the treatment of rosacea. *J Am Acad Dermatol*. 2005;53:791–797.
- [92] Sneddon IB. A clinical trial of tetracycline in rosacea. *Br J Dermatol*. 1966;7
- [93] Li DQ, Lokeshwar BL, Solomon A, Monroy D, Ji Z, Pflugfelder SC. Regulation of MMP-9 production by human corneal epithelial cells. *Exp Eye Res*. 2001;73:449–459.8:649–652.

- [94] Sobrin L, Liu Z, Monroy DC, et al. Regulation of MMP-9 activity in human tear fluid and corneal epithelial culture supernatant. *Invest Ophthalmol Vis Sci.* 2000;41:1703–1709.
- [95] Beardsley RM, De Paiva CS, Power DF, Pflugfelder SC. Desiccating stress decreases apical corneal epithelial cell size—modulation by the metalloproteinase inhibitor doxycycline. *Cornea.* 2008;27: 935–940.
- [96] The international workshop on meibomian gland dysfunction: report of the subcommittee on management and treatment of meibomian gland dysfunction. Geerling G, Tauber J, Baudouin C, Goto E, Matsumoto Y, O'Brien T, Rolando M, Tsubota K, Nichols KK. *Invest Ophthalmol Vis Sci.* 2011 Mar 30;52(4):2050–64.
- [97] Ta CN, Shine WE, McCulley JP, Pandya A, Trattler W, Norbury JW. Effects of minocycline on the ocular flora of patients with acne rosacea or seborrheic blepharitis. *Cornea.* 2003;22:545–548.
- [98] Aronowicz JD, Shine WE, Oral D, Vargas JM, McCulley JP. Short term oral minocycline treatment of meibomianitis. *Br J Ophthalmol.* 2006;90:856–860.
- [99] Hoeprich PD, Warshauer DM. Entry of four tetracyclines into saliva and tears. *Antimicrob Agents Chemother.* 1974;5:330–
- [100] Pinna A, Piccinini P, Carta F. Effect of oral linoleic and gammalinolenic acid on meibomian gland dysfunction. *Cornea.* 2007; 26:260–264
- [101] Miljanovic B, Trivedi KA, Dana MR, Gilbard JP, Buring JE, Schaumberg DA. Relation between dietary n-3 and n-6 fatty acids and clinically diagnosed dry eye syndrome in women. *Am J Clin Nutr.* 2005;82:887–893.
- [102] Macsai MS. The role of omega-3 dietary supplementation in blepharitis and meibomian gland dysfunction (an AOS thesis). *Trans Am Ophthalmol Soc.* 2008;106:336–356.
- [103] <http://www.spectrum-thea.co.uk/apps/content/html/ViewContent.aspx?fid=31>
- [104] <http://www.butterflies-eyecare.co.uk/Blephasteam-Blephasteam.html>
- [105] *Current Eye Research*, 37(4), 272–278, 2012A Single LipiFlow® Thermal Pulsation System Treatment Improves Meibomian Gland Function and Reduces Dry Eye Symptoms for 9 Months Jack V. Greiner DO, PhD1,2
- [106] *Invest Ophthalmol Vis Sci.* 2011 Mar 30;52(4):1922–9. doi: 10.1167/iovs.10-6997a. The international workshop on meibomian gland dysfunction: executive summary. Nichols KK, Foulks GN, Bron AJ, Glasgow BJ, Dogru M, Tsubota K, Lemp MA, Sullivan DA.
- [107] Meibomian gland disease. Classification and grading of lid changes. Bron AJ, Benjamin L, Snibson GR. *Eye (Lond).* 1991;5 (Pt 4):395–411. Review.

