

We are IntechOpen, the world's leading publisher of Open Access books Built by scientists, for scientists

6,900

Open access books available

186,000

International authors and editors

200M

Downloads

Our authors are among the

154

Countries delivered to

TOP 1%

most cited scientists

12.2%

Contributors from top 500 universities



WEB OF SCIENCE™

Selection of our books indexed in the Book Citation Index
in Web of Science™ Core Collection (BKCI)

Interested in publishing with us?
Contact book.department@intechopen.com

Numbers displayed above are based on latest data collected.
For more information visit www.intechopen.com



Fabry Disease – Ocular Manifestations and Visual Symptoms

Pinakin Gunvant Davey

Additional information is available at the end of the chapter

<http://dx.doi.org/10.5772/58677>

1. Introduction

Fabry disease is a rare lysosomal disorder that has a prevalence of 1 in 40,000 males.[1] This disease follows x-linked inheritance and the individuals affected with the disease show multi system disorders that are present at birth and signs and symptoms worsen with time. The *GLA* gene mutation leads to the deficiency of an enzyme alpha galactidose A which leads to the progressive accumulation of globotriacylceramide (GB3) deposits in a variety of cells including those in kidneys, and the autonomic the cardiovascular systems.[2-4]

The ocular manifestations of Fabry disease includes a cornea verticillata which is a “vortex whorl” like corneal opacity. It is the most common finding and is seen in all hemizygotes and majority (up to 70%) of hetrozygotes.[5] The cornea verticillata is the outcome of the deposit of GB3 in the basal layer of the corneal epithelium. The cornea verticillata is visible using a slitlamp biomicroscope and in-vivo confocal microscopic studies have shown that even when the cornea verticillata may not be visible using a slitlamp there are intracellular inclusion bodies in the basal epithelial cells.[6] To a lesser degree and fewer Fabry disease patients have subtle lenticular deposits which is the Fabry cataract.[7] The Fabry cataract tends to be off axis dendritic or subcapsular opacities along the posterior suture lines. It is believed that patients with cornea verticillata will not have any visual symptoms due to the deposits. [7-9]

The role of the cornea and the crystalline lens is to provide the eye with necessary refractive power and unhindered path to the light rays that pass through them. To this accord the corneal physiology is finely tuned and causes the least amount of scatter of light rays in ocular healthy individuals. It can be hypothesized that individuals with Fabry disease could have problems with visual function given that both the cornea and the crystalline lens have deposits of GB3 and opacities. It can further be hypothesized that the vision problems would be present and

will be worst at night time when compared to the day time, with patients with Fabry disease having additional problems of glare, blurry vision or dim vision (contrast sensitivity issues).

The patients with Fabry disease also experience anhydrosis or hypohydrosis as one of the symptom. This is due to the neurological manifestations of the disease. Prior reports have suggested that patients with Fabry disease may have deposits of GB3 in the ganglia or the lacrimal gland itself.[10-12] It can be hypothesized that patients with Fabry disease could also have symptoms of dry eyes.

The present study utilized an ocular symptom survey instrument to evaluate for the symptoms of general ocular problems like itching, tearing, dryness, burning sensation, sensation of foreign body or difficulty in vision or asthenopic symptoms in patients with Fabry disease and compared the findings to healthy controls.

2. Materials and methods

2.1. Study participants

A total of 95 individuals (75 patients with Fabry disease and 20 healthy controls) completed the survey. The mean age and standard deviation (SD) of the patients in the Fabry group and the control group was 32.5 and SD 19.1 years and 42.6 SD 14.7 years respectively. Ninety six percent of the participants completed all the survey questions, with 4 individuals not answering the question about "soreness and fatigue" of eyes.

The survey was administered live at the conferences for lysosomal disease storage which was conducted by the Fabry Support and Information Group in San Diego California, USA and the National Fabry Disease Foundation in Greensboro, North Carolina, USA. These events were attended by individuals that had a confirmed case of Fabry disease or by a family member who were tested and confirmed of being healthy and did not have Fabry disease or healthy spouse. The participants were instructed to answer the survey questions with regards to their self-perceived ocular and vision status when they were wearing optimal refractive correction. Data was collated and analyzed in a masked fashion with the data entry performed by a separate individual and the statistical analysis performed by the author.

2.2. Survey instrument

A modified survey instrument that was utilized by Lee et al [13] to investigate the ocular and visual symptoms in glaucoma patients was utilized in the present study. The survey instrument proposed by Lee et al[13] was called the Glaucoma Symptom Scale (GSS) and is a simple 10 question survey that was developed by modifying the survey used in the Ocular Hypertension Treatment Study. The GSS was tested and validated on a group of glaucoma patients in four tertiary care glaucoma centers. This survey instrument was administered to both patients with Fabry disease and their healthy family members (controls).

The survey administered in the present study is shown in Figure 1. The major difference between the GSS and the survey administered in the present study is the scale of the symptoms.

The GSS graded the symptoms in 4 point scale whereas the present study utilized a 6 point scale. The larger scale in the present survey allowed evaluating a wide range of symptom level as it was likely that the ocular symptoms in patients with the ocular manifestations of Fabry disease could be mild or minimal. The GSS survey instrument mainly evaluated for dryness and tear film and ocular surface issues in questions 1 to 4 and 7, whereas question 4 is designed to evaluate for general fatigue or asthenopic symptoms. The survey instruments question number 6, 8-10 were designed to evaluate vision related problems primarily the difficulty in contrast sensitivity issues, day time night time vision and glare respectively.

		<u>Almost Never</u>			<u>Almost Always</u>		
1	Burning /stinging	1	2	3	4	5	6
2	Tearing	1	2	3	4	5	6
3	Dryness	1	2	3	4	5	6
4	Itching	1	2	3	4	5	6
5	Soreness/tiredness	1	2	3	4	5	6
6	Blurry/Dim vision	1	2	3	4	5	6
7	Feeling of something in your eyes	1	2	3	4	5	6
8	Hard to see in daylight; I need to wear sunglasses	1	2	3	4	5	6
9	Hard to see in dark places	1	2	3	4	5	6
10	Halos around light	1	2	3	4	5	6

Figure 1. Survey instrument administered to the study participants; Survey instrument used in the study was developed by Lee et al [13]. The only modification made to the survey was the scale. The present study used a 6 point scale where as the survey instrument used by Lee et al had a 4 point scale.

2.3. Statistical analysis

The difference in the mean age between the groups was analyzed using a one-way analysis of variance (ANOVA). The severity for each variable was graded in an ordinal scale with 1 being “almost never” and 6 as “almost always”. A Mann-Whitney test was performed to evaluate the median difference between the Fabry group and the healthy control for each symptom survey question. A p-value of <0.05 was considered to be significant.

3. Results

The mean age of the control group was greater than the mean age of the Fabry group (ANOVA F=4.75; p=0.03). The table-1 provides the mean symptom severity score for the Fabry group and the control group and the p-value obtained using the Mann-Whitney test.

Symptom		Mean Severity Score		p-value
		Fabry group	Control group	
1	Burning /stinging	1.9	1.5	0.06
2	Tearing	2.0	1.9	0.2
3	Dryness	2.3	1.5	0.02
4	Itching	2.0	1.8	0.3
5	Soreness/tiredness	2.4	1.7	0.009
6	Blurry/Dim vision	2.2	1.6	0.02
7	Feeling of something in your eyes	2.0	1.5	0.07
8	Hard to see in daylight; I need to wear sunglasses	2.4	1.7	0.15
9	Hard to see in dark places	2.6	1.6	0.01
10	Halos around light	2.4	1.7	0.01

p-value in bold are significant at $p<0.05$ and in bold and italics are significant $p <0.01$

Table 1. Symptoms surveys and the median severity of groups and statistical significance

Of the survey instruments items, it was found that patients in the Fabry group had more complaints of “dryness” of eyes ($p=0.02$). The Fabry group also showed significantly greater symptom severity score and complained of “Blurry/Dim vision”, “hard to see in dark places” and “halos around light” ($p=0.02$, 0.01 and 0.01 respectively). The Fabry group also had a mean severity score for “soreness/tiredness” significantly higher than the control group ($p=0.009$). The tally of number of participants with symptoms and without symptoms is given in Table 2

4. Discussion

The survey instrument (GSS) utilized in this study was designed by Lee et al [13] to study the ocular and vision issues in glaucoma patients with the purpose of surveying daytime and night time vision, contrast sensitivity, glare, dryness and tear film related problems. The present study utilized the GSS survey instrument to identify ocular and visual symptoms in the Fabry disease and ocular healthy controls. The study results indicate that compared to healthy controls, the patients with Fabry disease had greater ocular symptom severity score in particularly areas related to night vision, contrast sensitivity and glare. Further they also have greater symptom severity score and complaint of soreness/tiredness and dry eyes.

Prior reports have indicated that patients with Fabry disease do not have any visual problems due to the cornea verticillata. [7-9] This is perhaps true to the point that the cornea verticillata may not cause a decline in Snellen visual acuity charts that uses 100% contrast optotypes (black letters on white background) as long as the patients wear appropriate refractive error correction. The findings of this study indicate that the symptoms of “dim vision”, “hard to see in dark places” perhaps indicates decrease in contrast sensitivity or difficulty in identifying targets in day to day life that are in shades of grey not of 100% contrast.. The Fabry group also

had a symptom severity score significantly higher for the survey item seeing “Halo around lights” which is perhaps a result due to the scatter or glare problems that patients experience. This problem may perhaps be further exaggerated at night time.

Symptoms		Problem	No Problem
Burning and stinging	Disease	38	37
	No disease	5	15
Tearing	Disease	44	31
	No disease	11	9
Dryness*	Disease	44	31
	No disease	7	13
Itching	Disease	44	31
	No disease	9	11
Soreness tiredness*	Disease	52	23
	No disease	6	14
Blurry, Dim vision*	Disease	48	27
	No disease	7	13
Feeling something in your eyes	Disease	40	35
	No disease	6	14
Hard to see in daylight, I need sunglasses	Disease	39	36
	No disease	7	13
Hard to see in dark places*	Disease	45	30
	No disease	7	13
Halos around light*	Disease	44	31
	No disease	6	14

* indicates symptoms that was statistically significant greater severity score between the groups

Table 2. The tally of study participants that reported experiencing symptoms in the Fabry group and the control group

The vision problems related to scotopic (night) vision, contrast sensitivity and glare are most likely due to the deposits of GB3 in corneal epithelium and lens which causes increased scatter of light rays and decreased transmittance of light (See figures 2 A-C). The confocal microscopic studies have revealed that even when there is no clinically visible cornea verticillata the basal layer of the epithelium show hyper reflectivity due to the intracellular inclusion bodies. Thus although one can expect the symptom severity score to be related to the amount of corneal deposits visible, the patients that do not have visible deposits or cornea verticillata may still have some visual problems given that have the intracellular inclusion bodies in the corneal epithelial cells.

The Fabry group also had greater complaints of “dryness” compared to the control group. This could be due to the fact that GB3 gets deposited both in the ganglia and the lacrimal gland. [10-12] Prior researchers have also suggested that patients with Fabry disease can have a dry

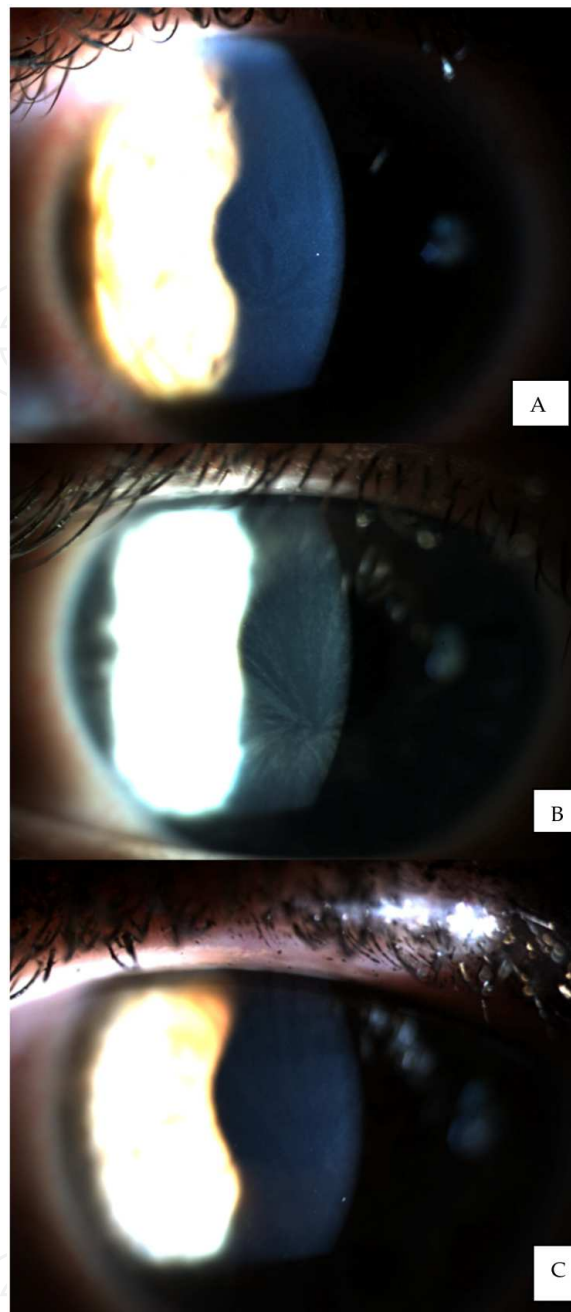


Figure 2. Cornea verticillata in patients with Fabry disease A: Top panel: Cornea verticillata giving a even spread of smear of deposits throughout the cornea. B: Middle panel: A vortex like deposits. C: Bottom panel: A subtle verticillata in a patient with Fabry disease

eye syndrome.[9] The report of this survey quantifies that patients may have a subtle yet clinically significant dry eye.

The patients with Fabry disease also complain of lack of energy or chronic fatigue. [14] It is intriguing to note that symptom survey score for “soreness/tiredness of eyes was significantly greater than the control group. This could have multiple reasons. The simplest explanation is they experience chronic fatigue of their body and thus also experience “soreness/tiredness”

with eyes. Although it is possible that dry eye, dim vision may contribute to some of these asthenopic problems. It will be interesting to see if this symptom severity score would decrease if appropriate therapy using glare filters, contrast enhancing filters or treatment for dry eyes was administered.

The cornea verticillata in patients with Fabry disease can vary significantly; they can be absent, subtle, or dramatic in appearance. The figures 2 A-C provide slit lamp photographs of cornea verticillata in patients with known Fabry disease. The figures 3 A B provide images of of conjunctival vascular findings in patients with Fabry disease. It should be noted that the cornea verticillata is not limited to Fabry disease and patients on medication like amiodorone or aminoquinolones on chronic use can have similar corneal appearance.[7] It can be postulated that any person with cornea verticillata can have vision problems pertaining to night time, contrast discrimination and glare.

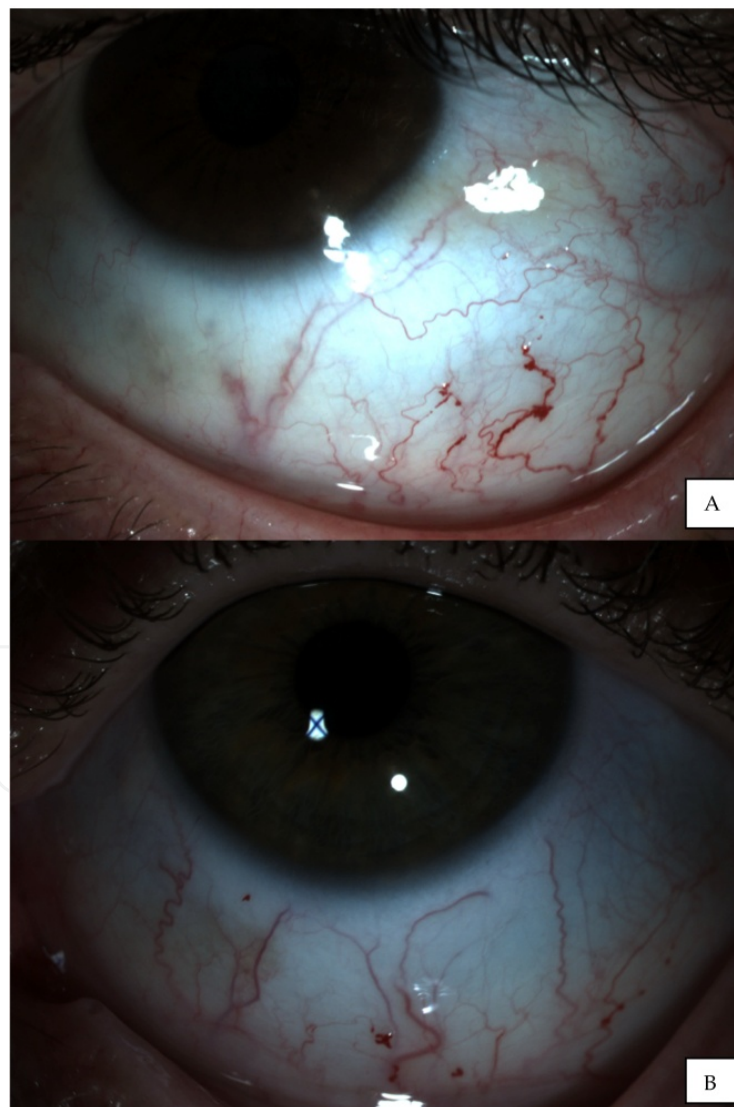


Figure 3. Conjunctival tortuosity with aneurysms like out pouching (A: Top and B: Bottom panel)

This is first report to my knowledge that has evaluated the ocular symptom severity survey in patients with Fabry disease. Future studies are needed and should look at quantifying the problems and symptoms with contrast sensitivity function testing, glare testing and investigate tear function tests to evaluate the vision related difficulty and dry eye problems.

Acknowledgements

I would like to thank Mr. Jerry Walter Founder and President National Fabry Disease Foundation (NFDF) and Mr. Jack Johnson Executive Director Fabry Support & Information Group for their kind help in administering the survey to Fabry patients I would like to thank Mr. Nate Klingensmith of Haag Striet USA for his assistance in ocular imaging of Fabry group and Mr. Jack Greenan for the data entry related to the study. A special thank you to Dr. Rebecca Kammer for interesting discussion on ocular survey instruments and all the study participants for their time and efforts in completing the survey.

Author details

Pinakin Gunvant Davey

Western University of Health Sciences, College of Optometry, Pomona CA, USA

References

- [1] Meikle PJ, Hopwood JJ, Clague AE, et al. Prevalence of lysosomal storage disorders. *JAMA* 1999;281:249-54.
- [2] MacDermot KD, Holmes A, Miners AH. Anderson's Fabry disease: clinical manifestations and impact of disease in a cohort of 98 hemizygous males. *J Med Genet* 2001;38:750-60.
- [3] MacDermot KD, Holmes A, Miners AH. Anderson's Fabry disease: clinical manifestations and impact of disease in a cohort of 60 obligate carrier females. *J Med Genet* 2001;38:769-75
- [4] Branton MH, Schiffmann R, Sabnis SG, et al. Natural history of Fabry renal disease: influence of α -galactosidase A activity and genetic mutations on clinical course. *Medicine* 2002;81:122-38
- [5] Desnick RJ, Brady RO. Fabry disease in childhood. *J Pediatr* 2004;144:20-26.

- [6] Wasielica-Poslednik J, Pfeiffer N, Reinke J, Pitz S Confocal laser-scanning microscopy allows differentiation between Fabry disease and amiodarone-induced keratopathy Graefes Arch Clin Exp Ophthalmol (2011) 249:1689–1696
- [7] Samiy N: Ocular Features of Fabry Disease: Diagnosis of a Treatable Life-threatening Disorder Surv Ophthalmol 53:416–423, 2008.
- [8] Sodi A, Ioannidis A, Pitz S. Ophthalmological manifestations of Fabry disease. In: Metha A, Beck M, Sunder-Plassmann G, eds. Fabry disease. Perspectives from 5 years of FOS. Oxford, UK: Oxford Pharmagenesis Ltd, 2006:249-61.
- [9] Sivley MD Fabry Disease: A Review of Ophthalmic and Systemic Manifestations Optom Vis Sci 2013;90:e63-e78
- [10] Cable WJ, Kolodny EH, Adams RD. Fabry disease: impaired autonomic function. Neurology 1982;32:498-502.
- [11] Hilz MJ. Evaluation of peripheral and autonomic nerve function in Fabry disease. Acta Paediatr Suppl 2002;91:38-42.
- [12] Kolodny EH, Pastores GM. Anderson-Fabry disease: extrarenal, neurologic manifestations. J Am Soc Nephrol 2002;13(Suppl. 2):S150-3.
- [13] Lee BL, Gutierrez P, Gordon M, Wilson MR, Cioffi GA, Ritch R, Sherwood M, Mangione CM The Glaucoma Symptom Scale. A brief index of glaucoma-specific symptoms. Arch Ophthalmol. 1998 Jul;116(7):861-6
- [14] Zarate YA, Hopkin RJ Fabry's disease. Lancet. 2008 Oct 18;372(9647):1427-35

