

We are IntechOpen, the world's leading publisher of Open Access books Built by scientists, for scientists

6,900

Open access books available

186,000

International authors and editors

200M

Downloads

Our authors are among the

154

Countries delivered to

TOP 1%

most cited scientists

12.2%

Contributors from top 500 universities



WEB OF SCIENCE™

Selection of our books indexed in the Book Citation Index
in Web of Science™ Core Collection (BKCI)

Interested in publishing with us?
Contact book.department@intechopen.com

Numbers displayed above are based on latest data collected.
For more information visit www.intechopen.com



Strangulated Inguinal Hernia

Evangelos P. Misiakos, George Bagias,
Nickolaos Zavras, Panagiotis Tzanetis,
Paul Patapis and Anastasios Machairas

Additional information is available at the end of the chapter

1. Introduction

An inguinal hernia is an abnormal protrusion of intra-abdominal tissue through a fascial defect in the groin. When a part of bowel which is inside the hernia sac becomes obstructed, there may initially be no interference with blood supply. This case results in a strangulated inguinal hernia, in which gangrene of the contents of the sac has been occurred. Strangulated inguinal hernia is a life-threatening condition which requires urgent surgical intervention. Historically, the prominence of “adhesive bands” as a cause of intestinal obstruction was already known, and was also the main historical cause of small intestinal obstruction before the advent of anesthesia. The descriptive history of hernias can be traced back through the centuries to Hippocrates and the knowledge of the catastrophic effects of incarceration of a hernia dates back to immemorial times. Celsus had referred many interesting historical incidences and he was also the first to describe the surgical techniques for the correction of recurring hernias. Of course, these procedures were very brutal compared to modern techniques, involving various techniques of cautery or caustics [1].

The modern era of thoughtful anatomical and surgical approach to hernia restoration dates back to the beginning of the nineteenth century with Sir Ashley Cooper’s and Antonio Scarpa’s illustrated monographs in England and in Italy respectively. It is interesting that the life threatening problem of strangulated inguinal hernia was occasionally successfully managed by the simple process of resecting the ischemic part of the bowel, leaving what amounted to a double-barreled enterostomy. Undoubtedly, few patients survived the debilitating effects of small bowel fistula but occasionally intestinal continuity was spontaneously re-established by retraction of the open ends of the bowel and gradual closing of the external fistula. Some of the well-known surgeons of the nineteenth century, such as Gimbernat (1793), Richter (1778),

Camper (1801), Hesselbach (1806) and Scarborough (1809), contributed to the anatomy and clinical findings associated with hernias. There was a limit, however, to what could be accomplished surgically until the introduction of antisepsis, and anesthesia techniques, so subsequent surgeons such as Bassini, Halsted, Billroth, Marcy and others defined the various types of surgical approach to abdominal wall hernias, up to 1880.

2. Anatomy

In the groin, an indirect inguinal hernia is caused when obliteration of the processus vaginalis (the peritoneal extension which accompanies the testicle in its descent into its final position, the scrotum) fails to occur. The hernia sac which has been formed passes through the internal inguinal ring, a defect in the transversalis fascia, between the anterior iliac spine and the pubic tubercle. The sac may extend partway along the inguinal canal, or it can pass through the external inguinal ring, a defect medially in the external oblique muscle, above the pubic tubercle. When the hernia sac reaches fully into the scrotum is called *complete hernia*. The hernia sac and the spermatic cord are invested by the cremaster muscle which is just an extension of internal oblique muscle's fibers [2].

A direct inguinal hernia however, is caused by a weakness or defect in the floor of Hesselbach triangle. The Hesselbach triangle is defined inferiorly by the inguinal ligament, laterally by the inferior epigastric arteries, and medially by the conjoint tendon. Usually, the transversalis fascia, which forms the floor of Hesselbach triangle, is weakened, though a discrete defect in the fascia may occasionally occur. This type of direct inguinal hernia has distinct borders, thus it is more possible to incarcerate [2].

At this point, we need to mention some anatomic structures, which are important, not only for understanding the pathophysiology of hernias, but also for understanding the surgical techniques being used. The conjoint tendon is a fusion of the medial aponeurosis of transversus abdominis and internal oblique muscles, that passes along the inferolateral edge of the rectus abdominis muscle and attaches to the pubic tubercle. The inguinal ligament is formed by the lowermost border of the external oblique aponeurosis, and it passes between the pubic tubercle and the anterior iliac spine. The Cooper ligament is a strong, fibrous band that extends laterally for about 2.5 cm along the iliopectineal line on the superior aspect of the superior pubic ramus. Finally, the iliopubic tract, parallel to inguinal ligament, is a band of connective tissue that starts from the iliopsoas fascia, crosses below the internal inguinal ring, and inserts into the superior pubic ramus, in order to form the Gimbernat ligament.

3. Pathophysiology

The majority of inguinal hernias are indirect hernias. As we mentioned above, an inguinal hernia is formed when the processus vaginalis cannot obliterate, and a direct inguinal hernia is caused when the floor of Hesselbach triangle is weakened. An indirect hernia may dilate the

internal ring and displace or attenuate the inguinal floor. Then the peritoneum may protrude on either side of epigastric vessels, to form a combined direct and indirect hernia, which is called "*pantaloon hernia*". Contents of this hernia can be part of small intestine, omentum, peritoneum, bladder, and part of colon.

The appearance and progression of a hernia is caused by the increase of intra-abdominal pressure. Many conditions are responsible for this increase. Marked obesity, abdominal strain from heavy exercise, cough, constipation with straining at stool and prostatism with straining on micturition are some of the common reasons of intra-abdominal pressure's increase. Cirrhosis with ascites, chronic ambulatory peritoneal dialysis and chronically enlarged pelvic organs can also contribute. Last but not least, advanced age and chronic debilitating disease can result to transversalis fascia (which forms the floor of Hesselbach triangle) debilitation.

The *strangulation of inguinal hernia* implies interference with the blood supply associated with an obstruction, which may not necessarily be complete. In most cases, it occurs as a complication of intussusception, torsion, volvulus, or any other form of closed-loop obstruction. Interference with the blood supply may occur either from twisting of the bowel on the mesentery or from distension of an obstructed closed loop. It has been pointed out that there is a distinction between long, medium (8±20 inches), and short loop strangulated obstruction. Medium strangulated loops usually result to toxic shock syndrome by the formation of exotoxins of *Clostridium welchii*, and short loops tend to perforate and cause peritonitis. The contents of the hernia sac can be only ileum, only omentum, ileum with omentum, and rarely only colon, ileum with colon, colon with omentum, testicle, appendix, urinary bladder, Meckel's diverticulum, and preperitoneal tissue.

4. Epidemiology

The incidence rate of strangulated inguinal hernia varies between 0.29 and 2.9 %. The mortality rate also ranges between 2.6 to 9 %, but Tanaka et al[3] have shown that a delay of 12 h increased significantly intestinal resection rate. Needless to say, the delay in diagnosis can also affect the length of hospital stay and hospital costs. Moreover, mortality risk is seven times higher in cases after emergency strangulated inguinal hernia surgery and 20 times higher if bowel resection was undertaken. Strangulated hernias are more frequently seen in elderly patients, and their prevalence in the over-60-year-old population has been reported to be 9.8 % compared with 1.8 % for younger patients; morbidity and mortality rates are 55 and 15 %, respectively, for patients over 65 years in case of herniorrhaphy in emergency. In addition, it has been reported that advanced age in the patients with strangulated inguinal hernia is considered as a prognostic factor of surgical or medical postoperative complications. The relation between mortality and age is understandable, poor risk being related to both intestinal necrosis and systemic complications of more dubious control in emergency circumstances.

5. Diagnosis

5.1. Risk factors

Many habits, conditions and diseases have been accused of development of an inguinal hernia. Patients with abnormal collagen metabolism have an increased risk, due to transversalis fascia debilitation. This fact is substantiated by the higher incidence of inguinal hernias in patients with aortic aneurysm. Abnormality in collagen metabolism can be familial, and studies have revealed families with increased incidence rates of hernias. Smokers have also an abnormal collagen metabolism, as a result smoking is almost certainly considered as a risk factor. Another risk factor is a patent processus vaginalis. Chronic coughing in patients with chronic obstructive pulmonary disease (COPD) seems to be a risk factor, as it contributes to an increase of intraabdominal pressure. Ascites in terms of hepatic cirrhosis and peritoneal dialysis can increase the risk of inguinal hernia or a recurrent hernia. Although physical work is not a risk factor, some studies revealed that long-term and heavy work does increase the risk of hernias [3]. Needless to say that, the patient should be questioned, if it is possible, about these factors. This would help a lot to an early and a safer diagnosis.

Inguinal hernia is a known complication after radical retropubic prostatectomy, whether if it is open or laparoscopic, and has been reported to occur in 7–21% of patients. Other types of lower midline incision surgery as well could promote the development of postoperative inguinal hernia, such as a low (cosmetic) incision for appendectomy, which can disrupt the shutter mechanism and increase the risk of an inguinal hernia. Surgeons should be aware of this important postoperative complication and prophylactic surgical procedures must be evaluated to address the problem.

5.2. Signs and symptoms

As we mentioned above, it has been reported that a delay in diagnosis of 12 h or more, increases significantly morbidity and mortality [4]. This fact points out the importance of the early diagnosis. Strangulated hernia should be regarded as a possible diagnosis in cases of acute small bowel obstruction, especially when no previous laparotomy has been carried out. The first diagnostic tool is the physical examination of the patient. The most common presenting clinical findings for emergency admission are an irreducible mass in the abdominal wall and localized pain (Fig. 1). Patients may have also signs and symptoms of mechanical bowel obstruction, as well as metabolic disorders, such as breath odor, constipation, diarrhea, vomiting and inability for gas exit. Duration of symptoms prior to admission can be from a few hours, up to several days. Significant concomitant medical illnesses can also be found in some cases, though essential hypertension and cardiovascular disorders are considered to be the commonest problems seen. The palpation of the infected area can provide additional information. A punctilious palpation of the inguinal area is needed, in order to locate the hernia site. In the majority of cases, the physical examination establishes the diagnosis of strangulated hernia, and no further examination is needed. The diagnosis of inguinal hernia can be established by physical examination with a sensitivity of 74.5–92% and a specificity of 93%.

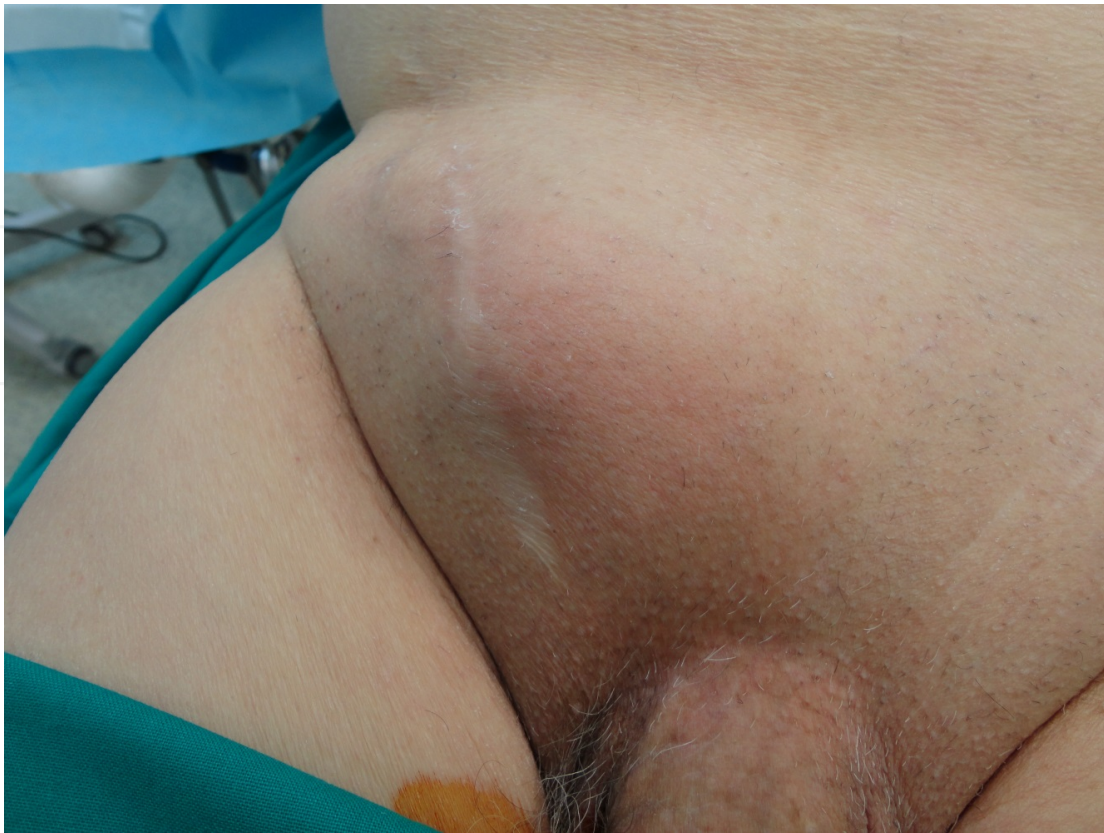

Figure 1. Strangulated recurrent hernia 2 years after a mesh repair. Local swelling, redness, edema and tenderness are the main local signs.

5.3. Imaging examinations

Although they are considered to be rare, there are some cases in which the hernia is occulted, particularly in obese patients, where a small part of the small intestine is strangulated. In these cases, the physical examination cannot establish the diagnosis of strangulated inguinal hernia by itself, and further imaging examinations are carried out. An ultrasonography of the lower abdomen can be performed, after patient's metabolic stabilization, but its sensitivity is low. A computed tomography is another diagnostic tool, with low specificity, but it is useful in the rare case of involvement of the urinary bladder. MRI can also be performed, and is capable for revealing the inflammatory site, and the bowel obstruction, which occurs in strangulated hernias. MRI's sensitivity is 94.5% and specificity is 96.3%. Herniography is also safe, sensitive (100%) and specific (98–100%) imaging examination [4]. Imaging findings are taken into account in combination with physical examination's findings and the general condition of the patient, and the diagnosis is established.

5.4. Laboratory examinations

Although laboratory findings are remarkable, they cannot be used for diagnosis of strangulated inguinal hernia. Hemoconcentration and leucocytosis (especially when is not accounted

for by hemoconcentration) can indicate bowel obstruction and strangulation, and so do lactic acidosis, when it does not resolve with volume resuscitation. When the strangulation of small intestine is diagnosed, however, the reason (in this case strangulated inguinal hernia) is not pointed out.

5.5. Surgical diagnostics

A definitive diagnosis of strangulation of the intestine can only be made through surgical exploration. Very little data have been published regarding the laparoscopy and exploratory laparotomy in comparison as a first approach in cases of strangulated groin hernia, when intestinal ischemia is suspected. Although midline laparotomies increase morbidity, due to possible intestinal resection, in some studies, almost the half of overall of midline laparotomies were performed without any intestinal resection [5]. When the patient is older, and there is a big possibility to have a lot of co-morbidities, the laparoscopy or hernioscopy could be of most benefit, avoiding the alternative of a laparotomy. Laparoscopy could help to diagnose bowel ischemia thus decreasing both negative and nontherapeutic laparotomy rates. Once the diagnosis of bowel ischemia is established, laparotomy could be performed. Evisceration, which is a rare occurrence of any incision, is more possible when the patient is old and he/she undergoes an emergency surgery. This complication could be avoided in emergency cases in this advanced aged population by using laparoscopy. Moreover, the decision to perform a bowel resection can be reliably made only by using laparoscopy.

5.6. Differential diagnosis

Strangulated hernia should be distinguished from other conditions which include swelling in the groin. First of all, a differential diagnosis should be made between strangulated inguinal and other types of hernias, such as femoral and incisional hernias. Other cases, in which the patient has groin swelling mass are lymphadenopathy, varicocele, aneurysm, soft-tissue tumor and an abscess, which can be a result of many pathological conditions in the inguinal area. Other relatively rare conditions are endometriosis and several genital anomalies (for example, ectopic testis). Cases that include pain in the inguinal area, but not the typical swelling are adductor tendinitis, pubic osteitis, hip artrosis and bursitis iliopsoas [4].

6. Treatment

A strangulated inguinal hernia, as an incident of acute abdomen, needs emergency surgery. As we mentioned above, the incidence rate of strangulated inguinal hernias is relatively low, because of the high acceptance of the value of elective hernia repair, but it is still a frequent incident of acute abdomen, especially in the elderly patients, in whom the hernia is not always diagnosed until strangulation.

6.1. Anesthesia

The choice between different anesthesia types for inguinal hernia repair is currently under discussion, and it is influenced by patient preferences and his/her medical history. Local

anesthesia allows for quick recovery time and, thus, is safe for early discharge in today's increasingly ambulatory surgery era. For patients with increased age or with elevated American Society of Anesthesiologists (ASA) classification (depending on co-existing cardiovascular and/or pulmonary disease), local anesthesia causes much less hemodynamic disorders and it is believed that it is being better tolerated than general anesthesia. Large randomized control studies have shown decrease in overall anesthesia time, urinary retention, and postoperative pain following use of local anesthesia compared to regional and general anesthesia. It has also been indicated that local anesthesia is associated with recurrence rates, but it doubtful whether this increased recurrence rate is a result of local anesthesia, or the use of Lichtenstein repair technique [6].

Needles to say, when herniorrhaphy is performed under local anesthesia, patients still feel the pressure and little pain. These effects can be minimized with the addition of anxiolytic agents. Additionally, the patient must always give consent for the possibility of conversion to general anesthesia, should he or she develop difficulty tolerating the procedure because of anxiety or discomfort.

Commonly used local anesthetics are 0.5-1% lidocaine with epinephrine, or 0.25% bupivacaine, or a combination of these 2 agents in 50:50 mixtures. A field block is applied by injecting along the site of incision, superficial to deep, and lateral to the pubic tubercle, to provide anesthesia to the deeper structures. In order to block the ilioinguinal nerve, an injection is placed just medial to the anterior superior iliac spine. Additional local anesthetic can be injected throughout the procedure. For example, the administration below the fibers of the external oblique aponeurosis, as described by Lichtenstein's group, anesthetizes its 3 major nerves by flooding the enclosed inguinal canal and serves to hydrodissect the underlying ilioinguinal nerve (making it less prone to injury when the aponeurosis is incised). Other techniques, such as epidural anesthesia, have been widely reported, but results depend largely on local expertise.

Elective inguinal hernia repair is considered an aseptic procedure as there is only a <2% surgical site infection rate. Although current data remain controversial, it is suggested (by numerous recent meta-analysis) to use antibiotic prophylaxis when performing a mesh-based repair. Cephalosporins (eg, cefazolin) are commonly administered by the anesthesiologist as a single dose prior to the skin incision. However, a properly funded, prospectively randomized study is still needed to definitively reveal the safest choice of anesthesia.

6.2. Traditional techniques

Traditional surgical repairs, like Bassini and Shouldice techniques are not used very common in elective inguinal hernia repair. However, in an emergency surgery, as in cases of strangulated inguinal hernias, these techniques are preferred from contemporary tension-free techniques, due to high possibility of mesh infection, in tension free techniques. Regardless the choice between traditional and tension-free techniques, the operation begins with an oblique skin incision (or along the Langer lines) approximately 2 centimeter superior to and parallel to the thigh crease, and then the incision is being extended 5 cm toward the anterior superior iliac spine, starting from just lateral to the pubic tubercle. In thin patients, the external ring can actually be palpated just lateral and slightly above the pubic tubercle and should be

the medial starting point of incision. Then the dissection is going deeper through the subcutaneous tissue until the aponeurosis of the external oblique is identified. In strangulated hernia the tissues maybe inflamed and edematous, therefore careful dissection of the anatomic structures is mandatory. Along with external oblique aponeurosis, the apex of the inguinal canal and also the external inguinal ring must be identified, before incising the external oblique muscle. The inguinal canal should be entered at its apex. For a correct identification of the apex of the canal, the lower wall of the canal, which is where the external oblique aponeurosis disappears into the fat of the thigh, should be pointed out. Approximately one finger breadth above this point is a good entry site into the canal. The external inguinal ring is also important because the external ring is ultimately the end point of the division to be made in the external oblique aponeurosis and defines the orientation of this cut [6].

Once the external oblique aponeurosis is identified, is thoroughly exposed and a gentle stab incision in its mid-portion along the orientation of its fibers is made. This incision is extended superiorly, and medially downward, through the superficial ring, thus exposing the inguinal canal and the cord structures. Afterwards comes the circumferentially mobilization of the cord structures off the floor of the canal by working on the pubic tubercle as a fulcrum. With blunt dissection of the index finger in a sweeping and medially encircling fashion, the cord is sufficiently freed, so that the cord structures can be surrounded by a Penrose drain for convenient retraction. This allows exposure of the inguinal floor and protects the cord structures. Then, an examination of the anteromedial aspect of the cord should be made, for an indirect component of the hernia. Separating the cremasteric muscle along its fibers often facilitates this. The cremasteric muscle fibers must be dissected carefully with slow electrocautery coagulation, as the cut muscle fibers tend to bleed. If an indirect hernia is present, the sac is dissected off the cord structures, down toward its base at the internal inguinal ring, until it is comfortably invaginated into the preperitoneal space. This is preferably achieved without division of the sac. However, if necessary, as with certain large hernias, the sac can be entered carefully and examined for visceral contents, and then divided with a high ligation. The peritoneal fluid within the sac should be sucked and sent for culture. If there is ischemic bowel inside the sac it should be resected promptly and anastomosed with an end-to-end manner. Occasionally there may be only strangulation of a portion of the greater omentum or strangulation of a portion of the sac itself, which maybe the cause of local discomfort and pain (Fig. 2). Direct hernias, which protrude through the inguinal floor at the Hesselbach triangle, are similarly dissected away from the cord structures toward their base and then are inverted below the transversalis fascia.

Closure of the defect and buttressing of the inguinal canal floor can now be performed. The Bassini technique is widely used, but the Shouldice technique is considered to be better, in terms of recurrence, is not usually used, because of the more extensive dissection, and a belief that the skill of surgeons is important as well. The Bassini repair is a technique in which the surgeon sutures the conjoined tendon to the inguinal ligament, which slides the patient's own muscles together to cover the hole in the abdominal wall and repair the hernia. The spermatic cord remains in its normal anatomic position under the external oblique aponeurosis. The surgeon closes the incision with a stitch known as the simple interrupted suture pattern, a

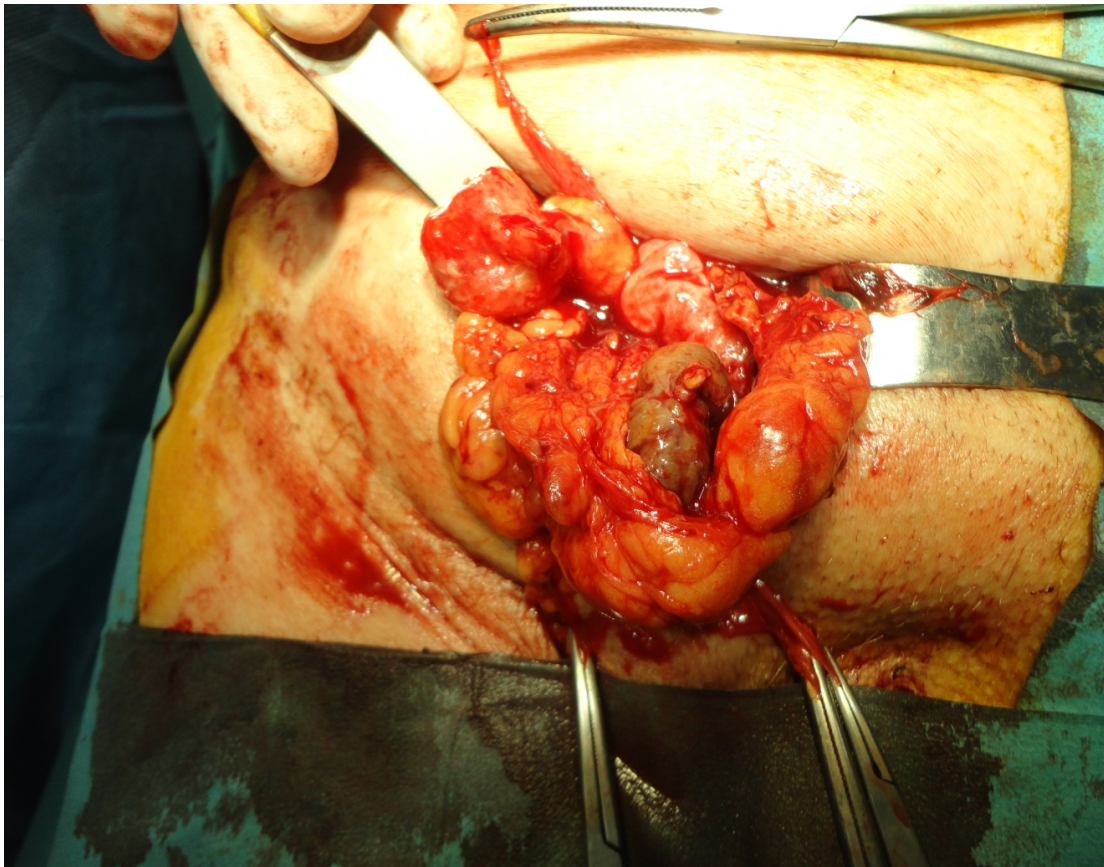


Figure 2. After opening of the subcutaneous tissue, a gangrenous portion of the sac and the adjacent preperitoneal tissue was revealed, which was resected.

speedy stitch that allows for surgery to be complete in approximately one hour. Bassini's original technique yielded outstanding results for a pure tissue technique; however, problems occurred when surgeons failed to open the posterior wall. So, a new operation, known as the "modified" or "North American" Bassini was introduced. By not opening the posterior wall, the wall tissue was damaged in its most medial portion by sutures placed under tension, and recurrences resulted, primarily in the pubic tubercle area. Thus, the failure of this operation in its first year was more likely due to an overlooked second hernia or to poor surgical technique, rather than a metabolic or tissue defect that might predispose to recurrent hernia.

The Shouldice technique (it is also known as ilio-inguinal incision) begins with the ligation of superficial veins. Afterwards, comes the same procedure as described above. The reconstruction in Shouldice technique is achieved by continuous suturing using 2.0 or 3.0 polypropylene sutures; starting medially, not through the periosteum of the pubic tubercle. Suture of the inferior edge of the fascia transversalis (Thomson's ligament) to a fold of the anterior side of the conjoint tendon ("white line") is being made, until the internal ring is constricted (in order to allow passage for the spermatic cord and point of tweezers). Then comes the second layer after including cremaster stump with the same thread to the iliopubic tract (inferior edge of the inguinal ligament). The third layer begins laterally, with the closure of the conjoint tendon to inguinal ligament. Original Shouldice has a fourth layer in the same plane. Finally,

the reapproximation of the external oblique aponeurosis is achieved with a running 3-0 polyglactin suture; at that stage the surgeon must be careful for the underlying ilioinguinal nerve. Reapproximation of the Scarpa fascia is followed with interrupted 3-0 polyglactin suture and then a running subcuticular closure of the skin with 3-0 poliglecaprone suture. The operative site is cleaned and sterile dressings are applied

6.3. Tension-free techniques

The Lichtenstein repair is widely accepted as the tension-free technique of choice. The operation starts again with medial incision as possible, for good exposure of the tubercle of pubic bone and rectus sheath. The superficial veins are ligated and the external oblique is cleaved, just like the traditional operation (with caution of the ilioinguinal nerve). The spermatic cord is surrounded and the posterior wall is assessed. Cremaster does not need to be excised unless hypertrophic, thus, leaving an unacceptably wide internal ring. The hernia sac is dissected until inside the internal ring, and then it can be reduced (which is the preferable option), transected, or resected. If necessary, the surgeon sutures a large direct hernia tension-free with continuous soluble sutures until a flat posterior wall has been created with a normal internal ring. All nerves should be preserved in principle, but it is advised that if a nerve is damaged or interferes with the placement of mesh it should be resected. Special attention to the iliohypogastric nerve should be paid; this nerve may lie under the mesh, but preferably not against a sharp edge. In that case the prosthesis is cut to the size it needs to be, because it is obvious that dividing a nerve is better than causing neuralgic pain. Polypropylene mesh 7x9x14 cm is applied (trimming is often necessary) with a 2-cm overlap at the pubic tubercle. Then the prosthesis is sutured continuously with polypropylene sutures 3.0 starting 2 cm mediotocranially from the pubic tubercle on the lateral rectus edge and then on the inguinal ligament to the internal ring. An incision in the mesh is made on 1/3 of the lower side until just medial to the spermatic cord. And both flaps of the prosthesis are sutured, overlapping on the lateral side to the inguinal ligament with one polypropylene suture; upper flap over the lower flap. The cranial edge of the mesh is also stabilized with one or more sutures (which may be soluble) to the aponeurosis of the internal oblique, avoiding muscle in order to avoid injury to the intramuscular segment of the iliohypogastric nerve. Again particular attention should be paid in order not to entrap nerves by suturing. Mesh must lie tension-free (domed) after removal of the wound spreader. The closure procedure is the same as in the Shouldice technique. In women, it is important to preserve the round ligament and the ilioinguinal nerve (like the spermatic cord). If both structures are cut, it is not necessary to create flaps in the mesh.

6.4. Endoscopic technique

Endoscopic technique has been used rarely in the management of strangulated inguinal hernias, but lately, even more surgeons prefer that technique. In the endoscopic repair (or extraperitoneal approach TEP) the bladder must be empty before the operation. An incision (2 cm) is made just under and next to the umbilicus until inside the anterior rectus sheath. The preperitoneal space is opened with the finger and, if needs be, a balloon (optional) is inserted,

up to the pubic bone. The surgeon insufflates with gas, under camera control, and replaces the balloon with blunt balloon or Hasson trocar. The patient is during the procedure in Trendelenburg position. Then, identification of os pubis, Cooper's ligament, epigastric vessels and internal ring takes place. Next, the surgeon dissects with a second trocar (5 or 10 mm in medial line) the lateral space until ASIS and inserts a third trocar (5 mm). The lateral hernia sac is dissected from the spermatic cord which is put aside over 5–7 cm. Polypropylene prosthesis with dimensions 15x9x15 or 10x9x15 cm is inserted and it is draped over the abdominal wall with plenty of overlap for all potential hernia defects. Finally, the surgeon desufflates carefully and removes instruments while holding the peritoneal sac 'inside' the mesh.

6.5. Choice of the most suitable technique

Lately, the use of prosthetic material for inguinal hernia repair has increased dramatically. Tension-free repairs have gained popularity not only for elective or recurrent hernias but also for complicated inguinal hernia repairs as well. Inguinal hernia mesh repair according to Lichtenstein "tension-free" technique has gained great acceptance from the surgeons all over the world, showing efficacy to consolidate the posterior wall of the inguinal canal and to reduce postoperative pain and recurrence risk due to tension on suture lines. Recent clinical trials on tension-free anterior repair of inguinal hernia using a mesh revealed that the immediate postoperative complications were rare and always minor, and rate of long-term recurrence is very low (0.5%) [7].

The presence of a strangulated inguinal hernia cannot be considered a contraindication for the use of a prosthetic mesh, although the use of traditional repairs, such as the Bassini repair in strangulated inguinal hernia is a common practice. Lichtenstein hernioplasty can be successfully used not only as an elective operation but also as an emergency operation for incarcerated inguinal hernia with a good outcome, with a low risk of the local infectious complications and a decently low rate of postoperative complications. However, the outcomes of emergency Lichtenstein hernioplasty were inferior to the outcomes of elective Lichtenstein hernioplasty [8]. Wound infection is a potential complication of all hernia repairs and an infection involving an inserted mesh may result in chronic groin sepsis, which usually necessitates complete removal of mesh. Along with the catastrophic effects of a groin sepsis, removal of mesh would potentially result in a weakness of the repair and as a result, a recurrent hernia. It has been proved however that hernia recurrence following mesh removal for chronic groin sepsis, was not a common phenomenon, and the explanation of that fact is that the strength of a mesh repair lies mostly in the fibrous reaction evoked within the transversalis fascia by the prosthetic material rather than in the physical presence of the mesh itself. Of course, when there is established deep infection, there should be no unnecessary delay in removing an infected mesh in order to allow resolution of chronic groin sepsis. However, that procedure has a relative risk of bowel injury.

Surgical techniques and implanted materials are crucial to the results and costs associated with hernia repair considering that specific mesh materials are related to specific complications. Polypropylene meshes are ideal for use in contaminated or potentially contaminated fields. The macroporous structure of the meshes of polypropylene, with pores of diameter larger than

70 micronmeters, allows contact among the bacteria, which measures almost one micrometer in diameter, and the cells of the immune system, granulocytes and macrophages, with a diameter of 15–20 micronmeters, which is significant for the recovery from infections [7]. The use of antibiotic prophylaxis for tension-free mesh herniorrhaphy may contribute in lowering the incidence of postoperative mesh infection, although there is little direct clinical evidence supporting this fact, and it is not officially recommended.

At this time, a few randomized studies comparing tension-free repairs and classical techniques have been performed, and the available data are considered to be low [9]. It is known that mean operative time and postoperative hospital stay were significantly longer for modified Bassini technique in comparison with tension-free repair, but postoperative complication rate and recurrence rate did not differ significantly between the two operations, according to the latest studies. It is important that in the majority of cases where tension-free repair has been chosen, no mesh had to be removed. Postoperative wound infection rate following Lichtenstein technique is not by far different from that following Bassini technique.

Recurrence rate in cases where a Bassini repair has been performed is approximately 20% and the worst results were observed with direct hernias (29% recurrence) when compared with indirect ones (16% recurrence). Moreover, the use of slowly absorbable suture material in the Bassini technique was reported to result in a high recurrence rate. Also, long-term (12–15 years) recurrence rate following Bassini repair is around 33% [7]. In conclusion, it seems that tension-free repair has lower recurrence rate, and the risk of mesh infection is not as important as it was believed to be during the past decades. Further randomized studies must be carried out, in order to ensure this fact

7. Complications

Postoperative complications are not uncommon after strangulated inguinal hernia repair. Identification of risk factors can be used in order to establish a high-risk group of patients, who are more likely to have a strangulated inguinal hernia. As we mentioned above, advanced age is the most important predisposing factor, as the reserve capacity of the older individual to compensate for stress, metabolic derangement, and drug metabolism is increasingly low. Functional disability occurs faster and it is more difficult to remediate. Some type of complication is encountered in almost half of patients older than 65 years and in 25% of younger patients who have undergone a strangulated inguinal hernia repair. The most frequent serious complications are pulmonary diseases and cardiovascular disorders. Pneumonia is not uncommon, as well as acute exacerbation of chronic obstructive pulmonary disease. Heart failure, coronary artery disease and cardiac arrhythmia are the most frequent complications from the cardiovascular system. Gastrointestinal bleeding, and hepatic failure (in existing cirrhosis) can be found in patients after strangulated hernia repair [10].

Local wound complications are seen in one third of overall patients, Wound infections, hematoma, seroma, and wound dehiscence are some of the most significant wound compli-

cations. Urinary retention has been reported in some cases, after the removal of urinary catheter.

Reoperations are not frequent. The causes of reoperations are necrosis of strangulated bowel, evisceration of the bowel, and small bowel obstruction by adhesions. Postoperative mortality has been reduced during the last years, and deaths are usually happening in patients over 65 years who have significant coexisting illness. The causes of death were the following: respiratory failure (which is common between patients with chronic obstructive pulmonary disease), sepsis, which is associated with resection of necrotic bowel in reoperations, and multiorgan failure.

It is doubtful whether there is a significant difference between indirect and direct inguinal hernias in terms of strangulation rate. Postoperative complications have been found by some studies to be more commonly in patients with hernia more than 10 year. Late hospitalization is generally considered to be an important factor for bowel resection and subsequent morbidity and mortality [11]. Usually, the cause of delay in admission is through the patients fault, but a wrong diagnosis can also result in delay of treatment.

Concomitant diseases in patients with incarcerated groin hernias have been reported to be associated with poor outcome, affecting not only the morbidity, but also the mortality rate. The length of hospital stay was also encountered to be longer in patients with concomitant diseases. The ASA class considers the patients' comorbidity and acute physiological disturbance. It has been reported that high ASA score was found to be an independent predictor of gangrenous bowel [12]. A significantly longer hospital stay and a significantly higher morbidity in elderly patients with ASA class III or IV who underwent emergency hernia repair was also reported.

The effect of anesthesia on the outcome of hernia repair has also been examined in the literature [13]. As we mentioned before, it is believed that general and spinal anesthesia were associated with higher rates of postoperative complications, but this fact is not widely accepted.

8. Recurrent inguinal hernia

Recurrent groin hernias are a special complication of strangulated inguinal hernia repair and they are more difficult and hazardous to repair. The frequency of recurrent groin hernias observed after a treatment of strangulated inguinal hernia varied from 10% through 30%. The time to recurrence varies; it is believed to be approximately 25 years, but around 5.6% of recurrences appear during the first postoperative month, and 39.1% of overall recurrent hernias appear during the first year.

The mechanisms of recurrence after a repair are difficult to identify, especially when the recurrence is late, and the previous treatment technique is unknown. Even during the reoperation, the previously used procedure is often not identifiable. Incorrect technique is responsible for most recurrences during the first postoperative year. Examples include not dissecting or not finding a sac, leaving too long a peritoneal "stump", incorrect closure of the hernia

orifice, as demonstrated by the frequency of indirect recurrences, and suture under tension, which is most involved in direct recurrences. We previously mentioned that some techniques are more likely than others to lead to a recurrence. These include totally pre- or retrofunicular repairs. Large hernias recur twice as often as small ones, and careless management results in a recurrence. Extended dissection or traumatic sutures may change a contractible inguinal wall into a fibrous wall exposed to progressive rupture. Other risk factors, independent of the quality of the operation, are the patient's general condition and age, abdominal wall weakness, and obesity. The most dangerous factors are postoperative sepsis and chronic cough. It used to blame early activity or return to work for recurrence, but this has been turned down lately, as 80% percent of recurrent hernias are independent of heavy work [14].

Recurrences after prosthetic repair result exclusively from technical mistakes and, thus, appear during the first postoperative year. During the postoperative course, seromas and hematomas must be distinguished from recurrent hernias. The classic clinical signs can be confirmed by ultrasonography. Recurrence rate of strangulated inguinal hernias is high, and it is strongly correlated with the surgical technique. Moreover, technical mistakes during the procedure may worsen this rate. The surgeon must be very careful about the choice of treatment method, considering the predisposing factors that may be present.

Author details

Evangelos P. Misiakos, George Bagias, Nickolaos Zavras, Panagiotis Tzanetis, Paul Patapis and Anastasios Machairas

*Address all correspondence to: misiakos@med.uoa.gr

3rd Department of Surgery, University of Athens School of Medicine, Attikon University Hospital, Athens, Greece

References

- [1] McDermott WV Jr. Incarcerated and strangulated hernia. *Surg Clin North Am.* 1966 46: 789-96.
- [2] Skandalakis JE. Embryologic and anatomic basis of inguinal herniorrhaphy. 1993 73:799
- [3] Tanaka N, Uchida N, Ogihara H, Sasamoto H, Kato H, Kuwano H. Clinical study of inguinal and femoral incarcerated hernias. *Surg Today* 2010; 40:1144-7
- [4] Simons MP, Aufenacker T, Bay-Nielsen M, Bouillot JL, Campanelli G, Conze J, De Lange D, Fortelny R, Heikkinen T, Kingsnorth A, Kukleta J, Morales-Conde S, Nordin P, Schumpelick V, Smedberg S, Smietanski M, Weber G, Miserez M. European

Hernia Society guidelines on the treatment of inguinal hernia in adult patients. *Hernia* 2009 13: 343–403.

- [5] Romain B, Chemaly R, Meyer N, Brigand C, Steinmetz JP, Rohr S. Prognostic factors of postoperative morbidity and mortality in strangulated groin hernia. *Hernia*. 2012 16: 405-10.
- [6] Stoppa RE. The treatment of complicated groin and incisional hernias. *World J Surg*. 1989 13: 545-54
- [7] Elsebae MM, Nasr M, Said M. Tension-free repair versus Bassini technique for strangulated inguinal hernia: A controlled randomized study. *Int J Surg*. 2008 6:302-5.
- [8] Papaziogas B, Lazaridis Ch, Makris J, Koutelidakis J, Patsas A, Grigoriou M, Chatzimavroudis G, Psaralexis K, Atmatzidis K. Tension-free repair versus modified Bassini technique (Andrews technique) for strangulated inguinal hernia: a comparative study. *Hernia*. 2005 9: 156-9.
- [9] Bessa SS, Katri KM, Abdel Salam WN, Abdel-Baki NA.. Early results from the use of the Lichtenstein repair in the management of strangulated groin hernia. *Hernia*. 2007 11: 239-42.
- [10] Alvarez JA, Baldonado RF, Bear IG, Solís JA, Alvarez P, Jorge JJ. Incarcerated groin hernias in adults: presentation and outcome. *Hernia*. 2004 8: 121-6
- [11] Brittenden J, Heys SD, Eremin O Femoral hernia: mortality and morbidity following elective and emergency surgery. *J R Coll Surg Edinb* 1991 36:86–88
- [12] Golub R, Cantu R Incarcerated anterior abdominal wallhernias in a community hospital. *Hernia* 1998 2:157–161
- [13] Young DV Comparison of local, spinal, and general anesthesia for inguinal herniorrhaphy. *Am J Surg* 1987 153:560–563
- [14] Deveney KE. Hernias & other lesions of the abdominal wall. *Current diagnosis and treatment*. 2012 724-36

