

# We are IntechOpen, the world's leading publisher of Open Access books Built by scientists, for scientists

6,900

Open access books available

186,000

International authors and editors

200M

Downloads

Our authors are among the

154

Countries delivered to

TOP 1%

most cited scientists

12.2%

Contributors from top 500 universities



WEB OF SCIENCE™

Selection of our books indexed in the Book Citation Index  
in Web of Science™ Core Collection (BKCI)

Interested in publishing with us?  
Contact [book.department@intechopen.com](mailto:book.department@intechopen.com)

Numbers displayed above are based on latest data collected.  
For more information visit [www.intechopen.com](http://www.intechopen.com)



---

# The Navigable Percutaneous Disc Decompression Device (L'DISQ & L'DISQ-C) in Patients with Herniated Nucleus Pulposus Related to Radicular Pain

---

Sang Chul Lee and Sang Heon Lee

Additional information is available at the end of the chapter

<http://dx.doi.org/10.5772/57600>

---

## 1. Introduction

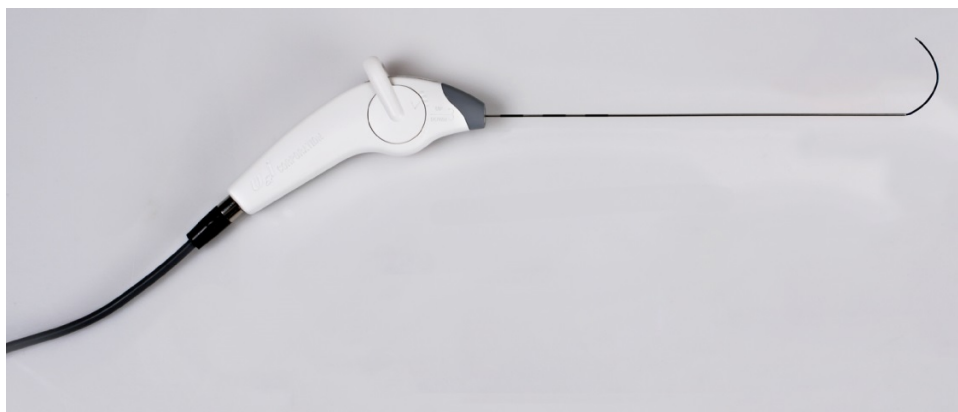Minimally-invasive disc decompression procedures have been developed over the last circa twenty years to treat radicular pain caused by disc herniations as an alternative treatment to open disc surgery. [1] Various interventional techniques include chemonucleolysis, ozone, automated percutaneous lumbar discectomy, intradiscal laser discectomy, intradiscal electrothermal therapy, and percutaneous nucleoplasty. [2-7] Even injectable liquids and gasses may reach the herniated nucleus, most devices are designed to decompress the center of the nucleus instead of the herniated disc. Although partial nuclear decompression by various minimally invasive techniques is generally safe and less invasive than open surgery, studies report inconsistent axial pain relief and most studies report a lower success rate than open and microdiscectomy for relieving radicular pain. [8] One reason for these inconsistent results may be the device design does not easily allow direct decompression of herniated disc material.

Introduced in 1999 and promoted to cause minimal collateral thermal damage, [9] Nucleoplasty (ArthroCare Co., Sunnyvale, CA) is representative of nuclear decompression devices that remove nuclear tissue through introducer needles that is typically inserted into a lumbar disc using a posterior lateral approach. Although different devices use various methods to remove nuclear tissue, the Nucleoplasty wand vaporizes nuclear tissue using a bipolar radiofrequency technology applied to a saline conducting medium. The disadvantage of the Nucleoplasty device, and indeed the disadvantage of most other minimally invasive devices and techniques, is the inability to easily reach the herniated nucleus. Direct removal of herniated disc tissue is, therefore, limited and removal of disc extrusions is impossible. Instead, nuclear decompression relies on pressure reduction and “implosion” of a disc protrusion to

reduce pressure on the traversing or exiting nerve roots. While studies show reduced disc pressure in hydrated discs, [10] implosion of nuclear material has not been validated. [11]

## 2. Navigable percutaneous disc decompression device (L'DISQ) for lumbar spine

A new navigable percutaneous disc decompressor (L'DISQ, U&I Co., Uijeongbu, Korea) is designed to allow direct access to herniated disc material. The device vaporizes herniated nucleus using bipolar radiofrequency current similar to Nucleoplasty. (Figure 1) Unlike the Nucleoplasty device, the L'DISQ wand can be curved by rotating a control wheel and directed into a disc herniation.



**Figure 1.** The wand and navigable tip of the L'DISQ is illustrated. The tip of the wand is curved to the desired angle by rotating the control wheel.

Unlike most percutaneous nucleotomy devices that use a rigid and uncontrolled tip, L' DISQ has a navigable tip that can be curved to the desired angles by rotation of the control wheel. Direct removal of the herniated tissue by the L'DISQ allows access to larger herniations and extruded fragments which are currently considered a contraindication for most percutaneous devices. [12-14] In addition, compared to open surgical discectomy, percutaneous removal through a relatively small bore introducer cannulae placed directly into the herniation or through the posterior-lateral annulus will theoretically better preserve the integrity of the outer annulus and potentially reduce the re-herniation rate following open discectomy. [15]

## 3. Safety of the procedure

Although the L'DISQ uses bipolar radio-frequency current to ablate tissue and therefore has the potential to injure unintended tissue due to high temperature caused by electric current and plasma energy, a previous study reported the thermal safety of this procedure. [16] The

temperature did not exceed 13°C above the initial temperature at any location and no denaturation of the adjacent neural tissue was observed. The histopathology examination demonstrated decompression of the nucleus pulposus without thermal damage to the surrounding neural tissues. [16]

Furthermore, as the distance between the two electrodes on L'DISQ tip is 1 mm, a nerve root greater than 1 mm from the tip is theoretically safe from electric injury. Indeed, the electric currents should pass to the other electrode instead of the nerve root rather than passing to the nerve root. In addition, the thin outer annulus membrane is at best a poor conductor of electrical current which should theoretically reduce neural damage due to the bipolar electrical current. Closely monitoring for the occurrence of leg pain should prevent injury due to heat. In addition, the wand tip should obviously be moved if electric stimulation causes lower extremity contraction.

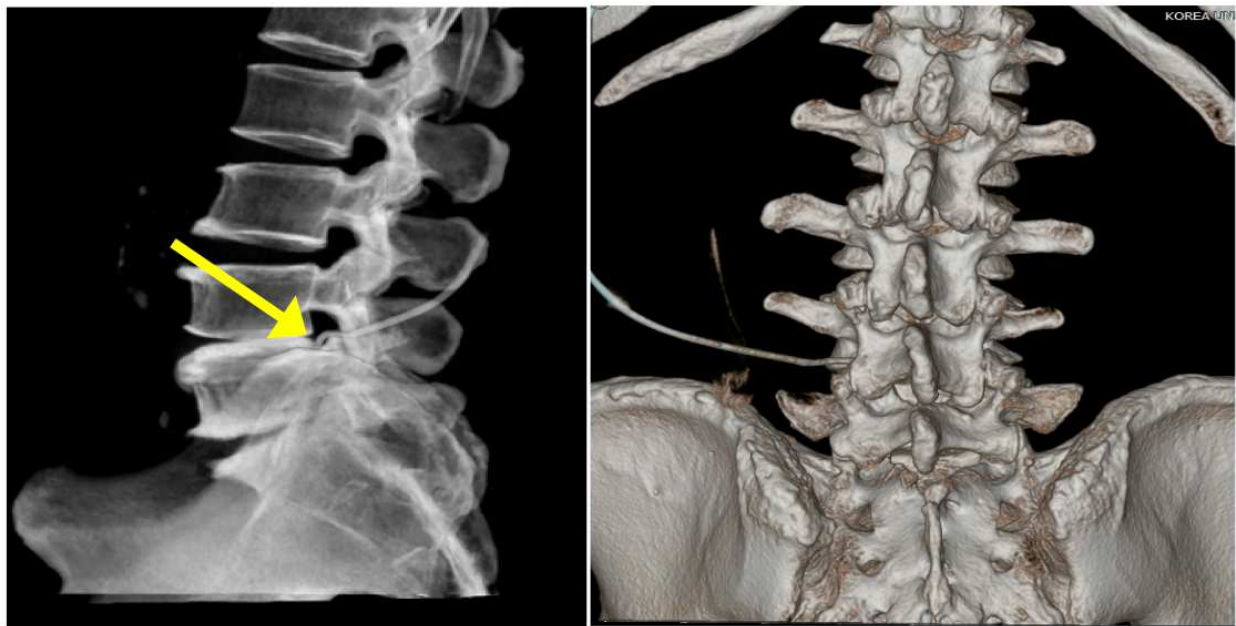#### 4. Procedure technique

**Patient preparation.** Prophylactic intravenous antibiotics must be administered 30 minutes before the procedure and monitor patients with electrocardiogram, pulse oximetry, and automated blood pressures. The patients are positioned prone on the surgical table and fluoroscopic examination of the spine is performed to confirm segmentation and determine the appropriate level of needle. Sedation is limited to 20 mg of propofol administered as necessary during anesthetization of the skin and subcutaneous fascia onto the superior articular process contralateral to the herniated disc.

**Standard procedure.** Use a standard posterior lateral approach to the disc as previously described, [17] but modified technique is to approach the disc further lateral so that the introducer needle would contact the disc margin at a line drawn between the medial border of adjacent pedicles rather than the midline. Slightly curve the distal end of the introducer needle to facilitate directing the introduced wand medial across the posterior annulus either slightly within or in some cases outside the posterior disc annulus.

A 25 gauge needle is first inserted into the target disc nucleus and 0.5 to 1 ml of contrast can be injected to outline the disc herniation. Next, mark the skin 12 to 15 cm from the midline to provide the approximate site of needle entry. The endplates of the target disc space are aligned and the C-arm rotated ipsilateral to position the lateral margin of the ipsilateral superior articular process approximately 3/5 distance across the vertebral body as visualized in the oblique position. This typically required rotating the C-Arm 20 degrees from a zero degree lateral projection (70° oblique view). After anesthetizing the skin and subcutaneous fascia to the superior articular process, manually curve the 15 gauge introducer needle approximately 15 degrees in the distal ~ 1cm from the distal tip. The introducer needle is directed toward the lateral edge of the superior articular process following the local anesthesia tract and guided by intermittent fluoroscopic "down the beam" projection using a "corkscrew" rotation of the slightly curved distal tip. Once the lateral edge is touched, the needle tip is directed laterally over the process and once the tip is over the SAP, the tip is rotated back toward the midline.

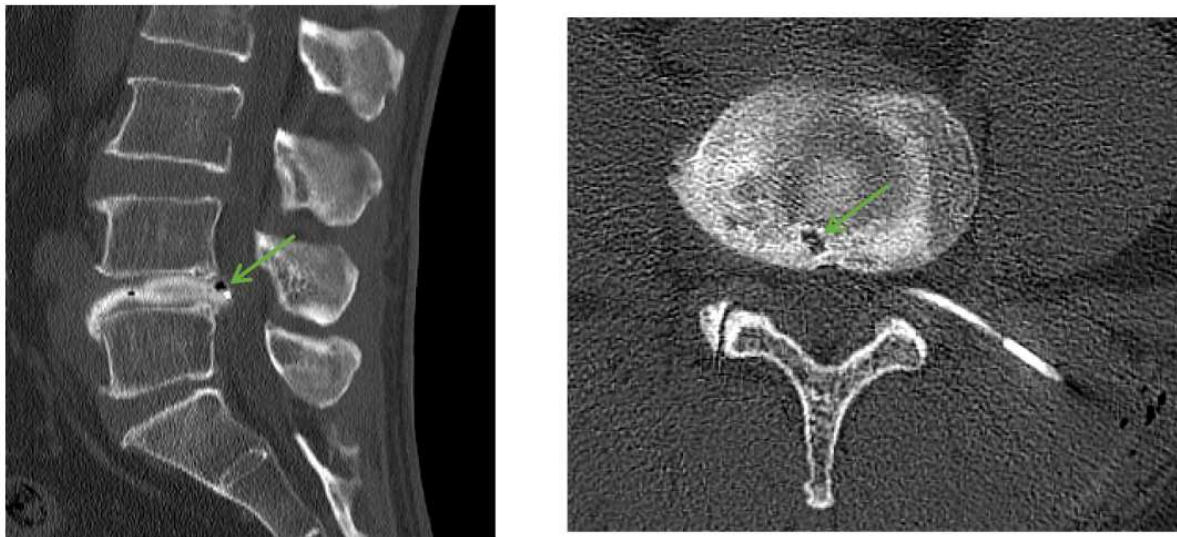
Prior to advancing the introducer needle across the midline the AP projection need to be checked. A lateral projection is used to slowly advance the needle across the foramen toward the disc margin. As the needle tip is directed toward the midline, the AP projection is intermittently checked to assure that the needle tip is always lateral the medial border of the pedicle. Be careful not to penetrate the neural tissues and the patient need to be asked to report any buttock or leg pain. Ideal technique is to avoid puncturing a normal posterior annulus if doctor feels that he could safely pass the introducer needle directly into central protrusions, or pass the wand posterior to the disc annulus in cases of contra-lateral disc extrusions. (Figure 2)



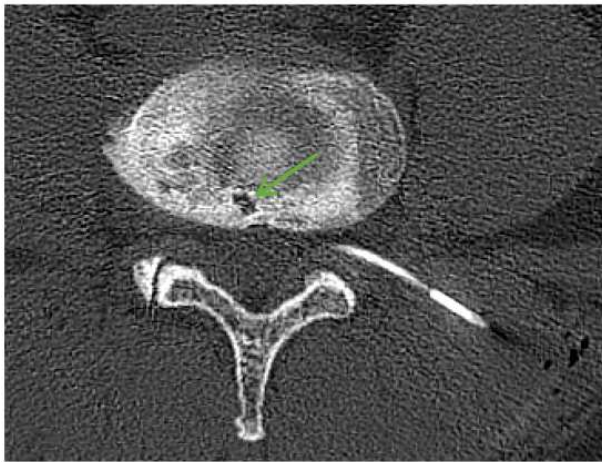
**Figure 2.** A three-dimension computed tomographic reconstruction image of the pathway of the L'DISQ wand is shown. In this case, the introducer needle was advanced posterior to the annulus into the annular extrusion. The tip of the L'DISQ wand (yellow arrow) is seen within the extrusion disc. The computed tomography scan was obtained with the patient's permission to evaluate immediate post procedure changes.

The advancement of the needle is precisely controlled by rotating the direction of the needle tip bend. Entering the herniation is identified by a sudden loss of resistance. After confirming the introducer needle position with the lateral and AP view, the stylet is removed and the through the introducer needle the wand is advanced to the center of the herniated disc using fluoroscopic monitoring of the AP and lateral views. Before ablation, negative motor nerve stimulation confirmed the needle is not close to the traversing or exiting nerve root. During the ablation, the tip of the wand the tip is continuously rotated and moved back and forth to increase the ablated volume. We also strived to remove disc material within the annular tears with either the same wand position or in some cases after repositioning of the wand.(Figure 3) The entire procedure need to be monitored, recorded and evaluated by C-arm fluoroscopy.





Tissue defect around the torn annulus

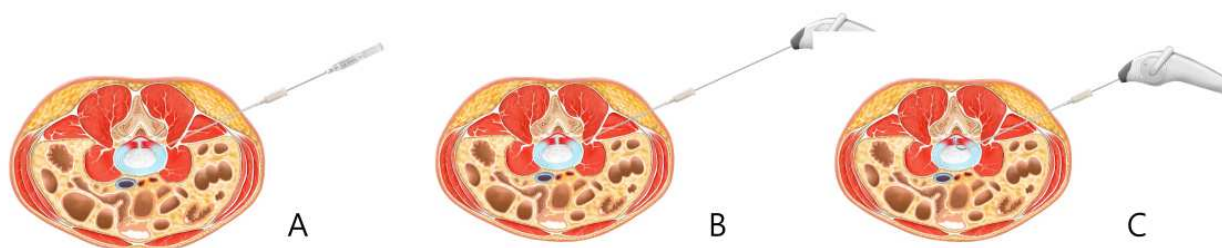


**Figure 3.** A computed tomographic scan performed just after the procedure illustrates the probable results of radio-frequency ablation as indicated by opacity (arrow) around the treated disc herniation.

## 5. Trans-annulus approach technique by directly inserting the wand into the herniated disc

For this technique, 70° oblique view is recommended. Trocar needle pass through the skin, fat, and muscle, so it is easy to correct the needle position or pathway up to 1cm before reaching the disc. With the guide needle continuing toward the target as a single spot in the C-arm image, check the position every 1-2cm until the guide needle reaches the disc. Although the needle tip continues in toward the target, because the tip of the needle is bent, pushing straight will cause the needle to rotate posteriorly. In a 70° oblique view, needle is seen as slightly bent

posteriorly, rather than a single spot. Once the needle tip reaches the disc, change from the 70° oblique view to the lateral view and arrange the needle so that the distal end is in-line as a spot with the C-arm image. Push the guide needle in between the rear portion of the disc's vertebral pulp to the herniated disc. At this time, inject small amounts of contrast dye in the herniated disc. If the contrast dye does not visualize clearly in the image, inject saline solution and then reposition the needle into the desired location. When entering the annulus fibrosus, saline solution is not injected, but once the needle tip enters the herniated portion of the intervertebral disc, saline solution is easily injected. Also, the herniated position from the MRI image and the C-arm's AP & lateral views should match to indicate the correct location. The location of the guide needle tip is confirmed through the image of the A-P view and the contrast dye. (figure4)



**Figure 4.** Trocar needle pass through the skin, fat, and muscle, so it is easy to correct the needle position or pathway up to 1cm before reaching the disc. (A) Push the guide needle in between the rear portion of the disc's vertebral pulp to the herniated disc. (B). The needle tip enters the herniated portion of the intervertebral disc. (C)

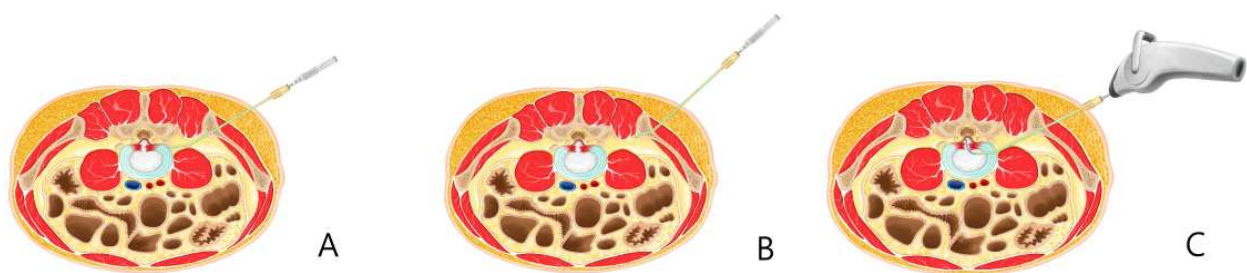
After the removal of the stylet, the L'DISQ wand is inserted into the guide polymer needle. After inserting the wand tip into the lesion, carry out a nerve impulse test with a test ablation. If the patient does feel anything, then the wand is in a safe position to continue with the high-frequency ablation. Using the control wheel for the wand tip, pull the wand while rotating it in a bent position. This method will allow the wand to contact the largest area and remove the most vertebral pulp. Inject 0.5-1cc saline solution, as needed, for improved plasma effect.

## 6. 30° rotation technique for L5/S1 disc

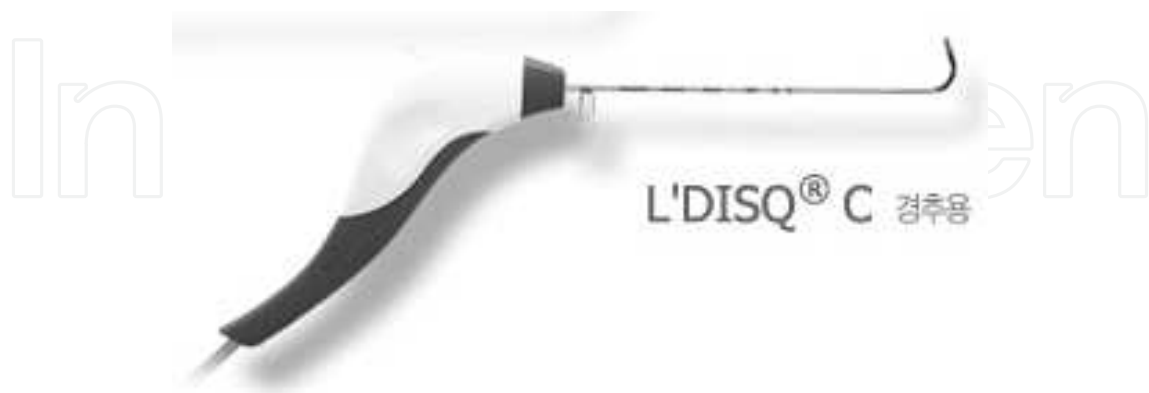The best view to avoid getting caught on the pelvic bone is the 30° rotation view (60° oblique view).

However, it is difficult to approach a large herniated disc with the guide needle at this position because of the angle and the anatomical structure. The target region using the 60° oblique view is the center or rear 2/5 of the disc. This region of the L5/S1 is where the intervertebral foramen or neural foramen is located. Since the pelvic bone is blocking the target, the start position should be 1cm above the pelvic bone. For the Lumbar 4/5 (L4/5) disc, position the needle so

that the tip creates a spot and advancement into the annulus fibrosus should be easy. For the lumbosacral joint (L5/S1), after passing the pelvic bone, guide the bent tip of the needle like a car by pointing the bent portion down toward the disc before pushing the tip in. Advance forward into the neural foramen, particularly at the S1 vertebral body, until you reach the superior articular process. Once the superior articular process of the S1 vertebral body is reached, rotate to the lateral view and proceed. Using the oblique 60° lateral view make visualization of the needle easier. Once the needle reached the vertebral pulp and the feeling of the hard vertebral pulp disappears, use the AP & lateral views to check location while injecting saline solution. Position the guide needle in the disc and remove the stylet. Then replace the stylet with the wand tip and begin high frequency ablation.(figure5)

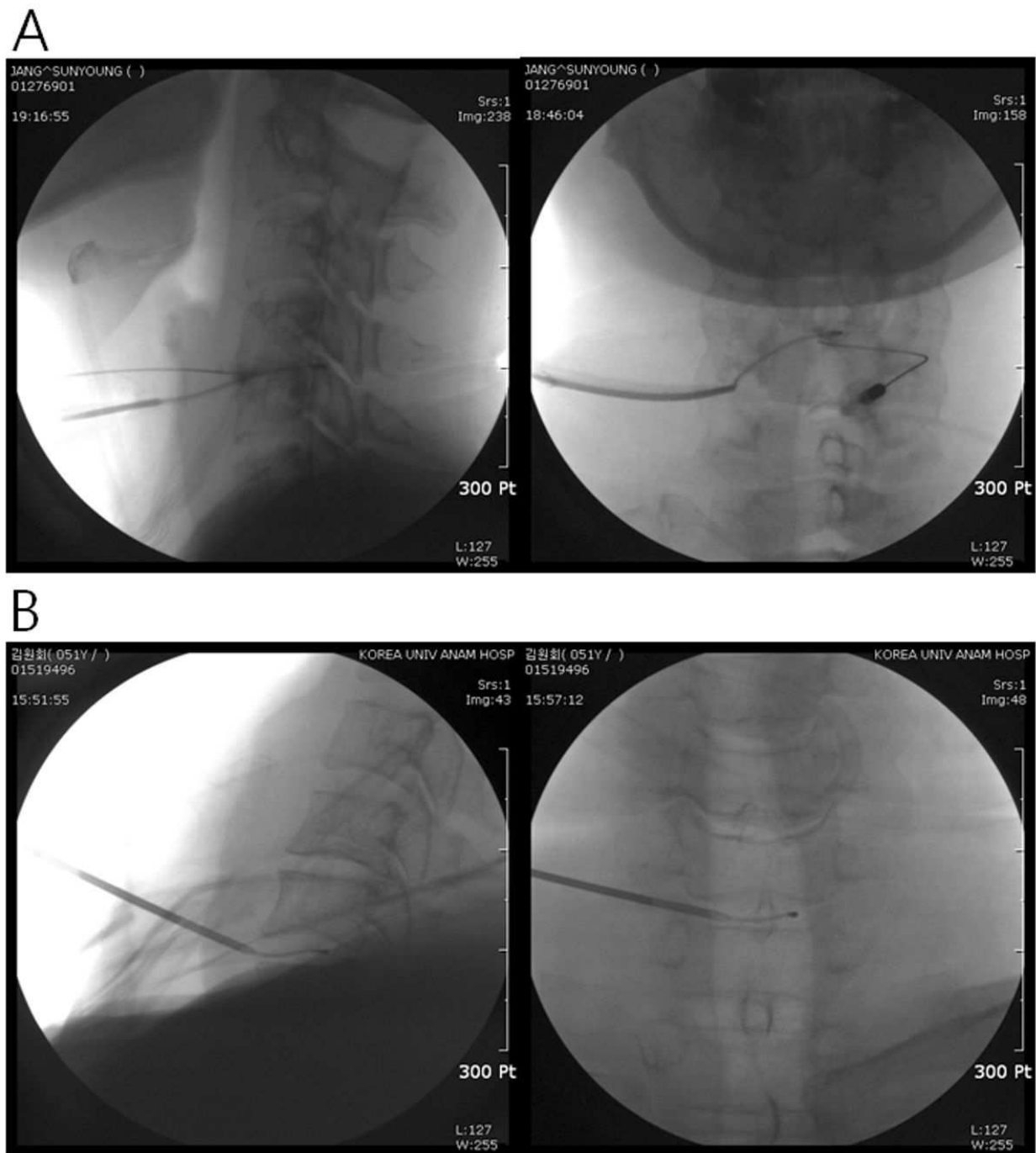


**Figure 5.** For the lumbosacral joint (L5/S1), after passing the pelvic bone, guide the bent tip of the needle like a car by pointing the bent portion down toward the disc before pushing the tip in.(A) Once the needle reached the vertebral pulp and the feeling of the hard vertebral pulp disappears, use the AP & lateral views to check location while injecting saline solution.(B) Place the stylet with the wand tip and begin high frequency ablation(C)

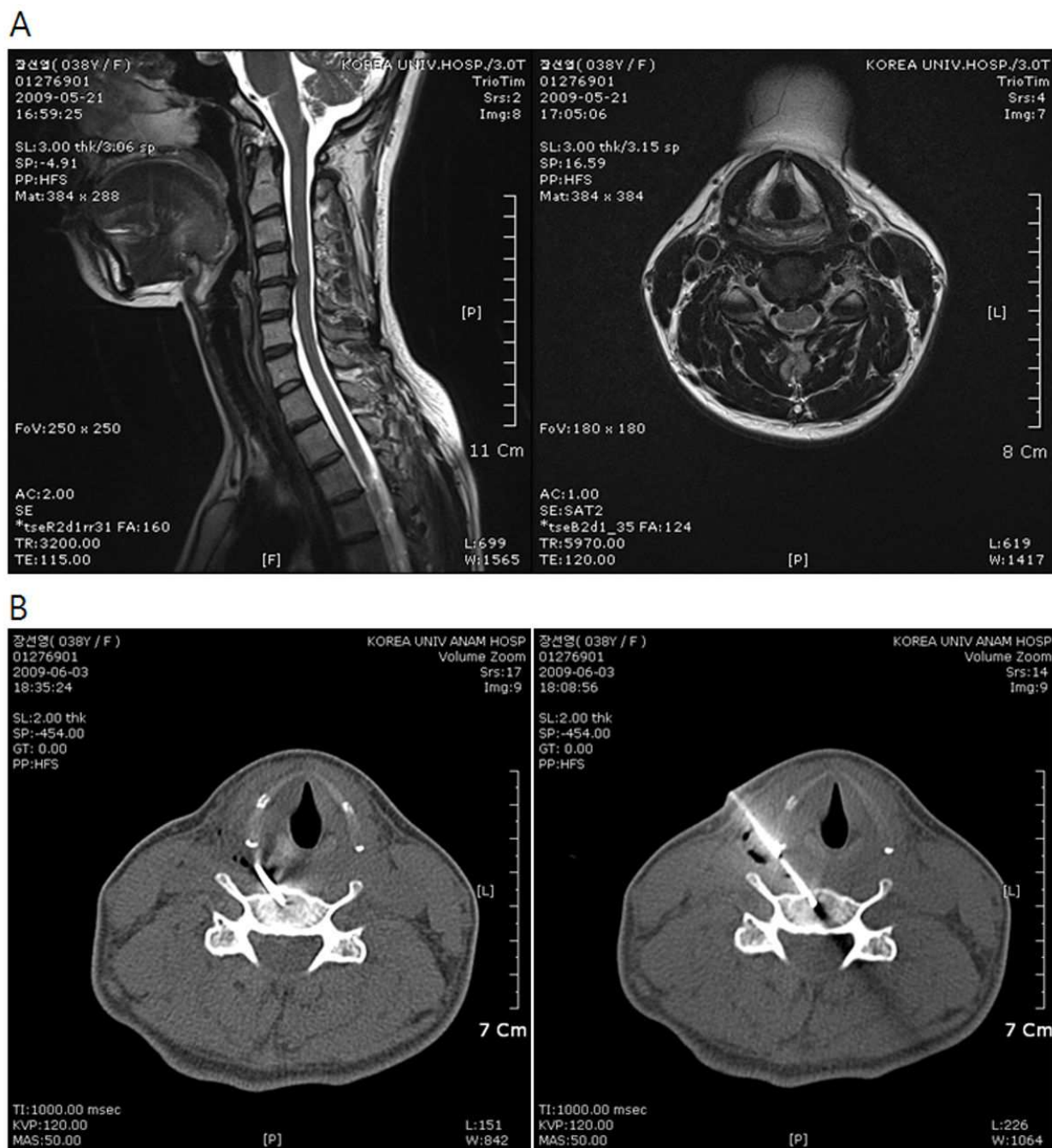


**Figure 6.** The wand and navigable tip of the L'DISQ-C is shown. The tip of the wand can be curved to the desired angle by rotating the control wheel. After placing the tip into the posterior annulus, plasma energy induced by radio-frequency is used to ablate and decompress the disc herniation.





**Figure 7.** Exact positions of the L'DISQ-C wand tip (arrow) placed in the center of herniation. C-arm fluoroscopy was used in anteroposterior and lateral planes to confirm the correct placement with reference to MRI studies. (A) Placing the tip of the L-DISQ catheter into the herniated disc. (B) Cervical disc decompressions were performed using L-DISQ catheter with fluoroscopic guidance



**Figure 8.** (A) Pre-procedure MRI noted a central disc extrusion at C4/5.(B) Placing the tip of the L-DISQ catheter into the herniated disc with computed tomography guidance of the standard midline approach

## 7. Outcomes

Recently, Lee et al. [18] reported the outcomes of this procedure. Results were shown that the VAS fell from 7.08 to 1.84 at 24 weeks post-procedure. At 6 months, the success rate, defined as a reduction of VAS more than 50%, was reported 88%. [18]

The L'DISQ device is specifically designed to remove herniated disc using a wand that can be navigated into a disc protrusion or extrusion. [18] Following decompression, we measured clinically significant pain improvement and decreased disability for patients with both radicular and axial pain caused by protruded and extruded discs. [18]

## 8. Navigable percutaneous disc decompression device (L'DISQ-C) for cervical spine

Neck pain is the second most common problem following back pain [19]. Although typically self-limiting, cervical disc herniation (CDH) with an annual incidence of 83.2/100,000 persons [20] may cause persistent pain refractory to conservative. Continued conservative care versus surgical management are both viable long term treatment strategies [21], however patients suffering more extreme pain, neurological compromise, or both are more likely to be offered a variety of disc decompression techniques [6, 7, 22, 23]. Although the efficacy and safety of the disc ablation with radiofrequency energy has been previously demonstrated [9, 24], focal direct removal of the herniated disc is restricted by the inability to navigate the catheter within the herniation. To overcome this liability, a navigable decompression device named L'DISQ-C was developed that is designed to allow direct access to the herniated disc material by rotating a control wheel directed into the disc herniation. In addition to direct mechanical decompression, the plasma energy applied within the disc herniation would theoretically destroy nociceptive nerve endings and disrupt inflammatory cytokines in the periphery of the annulus [25-28].

The perceived benefits of percutaneous disc decompression compared to open surgical decompression initiated the development and use of minimally invasive percutaneous devices to ablate nuclear tissue. The effectiveness versus risk of cartilaginous end plate damage, bleedings, osteonecrosis of the vertebral body, and end plate damage [29, 30] are ongoing debate.

It is crucial that interventionalists are careful when manipulating the device and before each ablation, one should perform a brief test electrical stimulation. If stimulation or limb movement is detected, the wand must be repositioned. Movement of the wand forward during ablation must be prevented.

## 9. Procedure technique

**Patient preparation.** First, inject antibiotics intravenously 30 minutes prior the procedure and monitor blood pressure, heart rate, electrocardiogram, oxygen saturation, and respiration rate during the procedure. Patients are placed in the supine position with the neck extended by placing a cushion beneath the shoulder. A soft strap is placed over the forehead for stabilization. Patients are asked to gently distract both shoulders downward the operation table. The neck is prepped and draped in a sterile fashion. An aseptic technique must be used throughout the procedure. Deep sedation should be avoided so that complete neurological monitoring of the patient is possible during the whole procedure.

**Standard procedure.** The procedure is performed under fluoroscopic guidance using a standard midline approach [31]. During the initiatory stage, fluoroscopic examination identifies the target disc and appropriate skin site to needle trajectory. Displace the trachea medially and vessels laterally using two digits applied with firm pressure to the space between the trachea and the medial border of the sternocleidomastoid muscle. After encounter with the anterior cervical spine, a 25 gauge needle is inserted into the disc ipsilateral to the herniation and the 16 gauge introducer needle (Fig. 2) passed contralateral to the herniation. After confirming needle placement with AP and lateral fluoroscopic views, Outline the herniation with 0.2 mL contrast injected through the 25 gauge needle. The stylet of the introducer needle is withdrawn from the introducer cannula and the L'DISQ-C wand with 17mm flexible tip is replaced. By manipulating the L'DISQ-C control wheel with or without force of the wand into the introducer needle, advance the tip of the wand to the center of the herniation. After connecting the L'DISQ-C wand to the power generator and testing with a brief test electrical stimulation before each ablation and any complaint of radiating pain or muscular contraction prompted withdrawal of the tip by 1 mm and retesting. Use brief bursts of 50W-75W for 2~5 seconds to ablate disc tissue. After each ablation the wand slightly repositioned and after test stimulation, ablation is repeated to a total of 100~150 seconds. In the intervals of ablation a small amount of saline can be injected through the 25 gauge needle to support the plasma well-evoking.

## 10. Outcomes

Recently, Lee et al. [32] reported the outcomes of this procedure in the patients with cervical herniated nucleus pulposus. Results were shown that the average VAS fell from 7.29 to 1.14 scores at 1 year post procedure. [32] All seven patients reported successful outcomes with a reduction of VAS more than 50%. However, the lack of a control group and a few patients are limitations. Following decompression with L'DISQ-C patients reported clinically significant pain improvement and decreased disability for patients with both cervical radicular and axial pain caused by protruded and extruded discs. [32]

## Author details

Sang Chul Lee<sup>1</sup> and Sang Heon Lee<sup>2,3,4</sup>

1 Department of Anesthesiology and Pain, Seoul National University Medical Center, Seoul National University, Seoul, South Korea

2 Department of Physical Medicine & Rehabilitation, Korea University Medical Center, Seoul, South Korea

3 Spinal Diagnostics & Treatment Center, Daly City, CA, USA

4 Department of Biomedical Science, Korea University Graduate School, South Korea

## References

- [1] Chen Y, Derby R, Lee SH. Percutaneous disc decompression in the management of chronic low back pain. *Orthop Clin North Am.* Jan 2004;35(1):17-23.
- [2] Mirzai H, Tekin I, Yaman O, Bursali A. The results of nucleoplasty in patients with lumbar herniated disc: a prospective clinical study of 52 consecutive patients. *Spine J.* Jan-Feb 2007;7(1):88-92; discussion 92-83.
- [3] Erdine S, Ozyalcin NS, Cimen A. [Percutaneous lumbar nucleoplasty]. *Agri.* Apr 2005;17(2):17-22.
- [4] Andreula C, Muto M, Leonardi M. Interventional spinal procedures. *European journal of radiology.* May 2004;50(2):112-119.
- [5] Kambin P, Schaffer JL. Percutaneous lumbar discectomy. Review of 100 patients and current practice. *Clinical orthopaedics and related research.* Jan 1989(238):24-34.
- [6] Karasek M, Bogduk N. Twelve-month follow-up of a controlled trial of intradiscal thermal anuloplasty for back pain due to internal disc disruption. *Spine.* Oct 15 2000;25(20):2601-2607.
- [7] Nerubay J, Caspi I, Levinkopf M, Tadmor A, Bubis JJ. Percutaneous laser nucleolysis of the intervertebral lumbar disc. An experimental study. *Clinical orthopaedics and related research.* Apr 1997(337):42-44.
- [8] Faciszewski T, Winter RB, Lonstein JE, Denis F, Johnson L. The surgical and medical perioperative complications of anterior spinal fusion surgery in the thoracic and lumbar spine in adults. A review of 1223 procedures. *Spine.* Jul 15 1995;20(14):1592-1599.



- [9] Chen YC, Lee SH, Saenz Y, Lehman NL. Histologic findings of disc, end plate and neural elements after coblation of nucleus pulposus: an experimental nucleoplasty study. *Spine J.* Nov-Dec 2003;3(6):466-470.
- [10] Chen YC, Lee SH, Chen D. Intradiscal pressure study of percutaneous disc decompression with nucleoplasty in human cadavers. *Spine (Phila Pa 1976).* Apr 1 2003;28(7):661-665.
- [11] Delamarter RB, Howard MW, Goldstein T, Deutsch AL, Mink JH, Dawson EG. Percutaneous lumbar discectomy. Preoperative and postoperative magnetic resonance imaging. *J Bone Joint Surg Am.* Apr 1995;77(4):578-584.
- [12] Hirsch JA, Singh V, Falco FJ, Benyamin RM, Manchikanti L. Automated percutaneous lumbar discectomy for the contained herniated lumbar disc: a systematic assessment of evidence. *Pain Physician.* May-Jun 2009;12(3):601-620.
- [13] Ohnmeiss DD, Guyer RD, Hochschuler SH. Laser disc decompression. The importance of proper patient selection. *Spine (Phila Pa 1976).* Sep 15 1994;19(18):2054-2058; discussion 2059.
- [14] Philip SK. Nucleoplasty. *Techniques in Regional Anesthesia and Pain Management.* 2004;8(1):46-52.
- [15] Carragee EJ, Spinnickie AO, Alamin TF, Paragioudakis S. A prospective controlled study of limited versus subtotal posterior discectomy: short-term outcomes in patients with herniated lumbar intervertebral discs and large posterior annular defect. *Spine.* Mar 15 2006;31(6):653-657.
- [16] Kang CH, Kim YH, Lee SH, et al. Can magnetic resonance imaging accurately predict concordant pain provocation during provocative disc injection? *Skeletal radiology.* Sep 2009;38(9):877-885.
- [17] Derby R, Lee SH, Kim BJ. Discography. In: Slipman CW, Derby R, Simeone FA, Mayer TG, eds. *Interventional Spine: an algorithmic approach*. Elsevier; 2008:291-302.
- [18] Lee SH, Derby R, Sul D, et al. Efficacy of a new navigable percutaneous disc decompression device (L'DISQ) in patients with herniated nucleus pulposus related to radicular pain. *Pain Med.* Mar 2011;12(3):370-376.
- [19] Nachemson A, Waddell G, Norlund A. Epidemiology of neck and neck pain. In: Nachemson AL, Jonsson E, editors. *Neck and back pain: the scientific evidence of causes, diagnosis and treatment*. Philadelphia (PA): Lippincott Williams and Wilkins; 2000. 164-87.
- [20] Radhakrishnan K, Litchy WJ, O'Fallon WM, Kurland LT. Epidemiology of cervical radiculopathy. A population-based study from Rochester, Minnesota, 1976 through 1990. *Brain : a journal of neurology.* Apr 1994;117 (Pt 2):325-335.

- [21] Persson LC, Carlsson CA, Carlsson JY. Long-lasting cervical radicular pain managed with surgery, physiotherapy, or a cervical collar. A prospective, randomized study. *Spine (Phila Pa 1976)*. Apr 1 1997;22(7):751-758.
- [22] Smith L. Enzyme Dissolution of the Nucleus Pulposus in Humans. *JAMA*. Jan 11 1964;187:137-140.
- [23] Hijikata S. Percutaneous nucleotomy. A new concept technique and 12 years' experience. *Clin Orthop Relat Res*. Jan 1989(238):9-23.
- [24] Lee MS, Cooper G, Lutz GE, Doty SB. Histologic characterization of coblation nucleoplasty performed on sheep intervertebral discs. *Pain physician*. Oct 2003;6(4):439-442.
- [25] Bogduk N, Tynan W, Wilson AS. The nerve supply to the human lumbar intervertebral discs. *J Anat*. Jan 1981;132(Pt 1):39-56.
- [26] Konttinen YT, Gronblad M, Antti-Poika I, et al. Neuroimmunohistochemical analysis of peridiscal nociceptive neural elements. *Spine (Phila Pa 1976)*. May 1990;15(5):383-386.
- [27] Ashton IK, Roberts S, Jaffray DC, Polak JM, Eisenstein SM. Neuropeptides in the human intervertebral disc. *J Orthop Res*. Mar 1994;12(2):186-192.
- [28] Freemont AJ, Peacock TE, Goupille P, Hoyland JA, O'Brien J, Jayson MI. Nerve ingrowth into diseased intervertebral disc in chronic back pain. *Lancet*. Jul 19 1997;350(9072):178-181.
- [29] Melrose J, Taylor TK, Ghosh P, Holbert C, Macpherson C, Bellenger CR. Intervertebral disc reconstitution after chemonucleolysis with chymopapain is dependent on dosage. *Spine*. Jan 1 1996;21(1):9-17.
- [30] Tonami H, Kuginuki M, Kuginuki Y, et al. MR imaging of subchondral osteonecrosis of the vertebral body after percutaneous laser discectomy. *AJR. American journal of roentgenology*. Nov 1999;173(5):1383-1386.
- [31] Slipman CW. *Interventional spine : an algorithmic approach*. Philadelphia, PA: Saunders Elsevier; 2008.
- [32] Lee SH, Derby R, Sul D, et al. Efficacy of the Navigable Percutaneous Disc Decompression Device (L'DISQ-C) in Patients with the Cervical Herniated Nucleus Pulposus: prospective outcome study with a minimum 1-year follow-up. *Pain Med*. 2013;on submission.