

We are IntechOpen, the world's leading publisher of Open Access books Built by scientists, for scientists

6,900

Open access books available

186,000

International authors and editors

200M

Downloads

Our authors are among the

154

Countries delivered to

TOP 1%

most cited scientists

12.2%

Contributors from top 500 universities



WEB OF SCIENCE™

Selection of our books indexed in the Book Citation Index
in Web of Science™ Core Collection (BKCI)

Interested in publishing with us?
Contact book.department@intechopen.com

Numbers displayed above are based on latest data collected.
For more information visit www.intechopen.com



Imaging Devices and Glaucoma Management

Pinakin Gunvant Davey

Additional information is available at the end of the chapter

<http://dx.doi.org/10.5772/58568>

1. Introduction

The definition of glaucoma varies depending upon the source or criteria of the randomized controlled trial evaluated. Thus the diagnosis of glaucoma can be enigmatic due to lack of universally accepted definition of glaucoma that covers all facets of glaucoma pathogenesis. The classic definition of having the triad of visual field damage, nerve head damage and elevated intraocular pressure is no longer valid. Although intraocular pressure remains arguably the most important risk factor its absolute value may be elevated or remain within the statistical limits of normality depending upon the type of glaucoma. Issues related to glaucoma management are anything but cookbook type Therefore glaucoma remains interesting for clinicians that manage patients with glaucoma and researchers that study its pathogenesis.

The patients at risk of glaucoma undergo cellular level damage that is manifests as both structural damage at posterior pole of the eye and damage to functional vision. The major goals of glaucoma management are quite clear; to halt the progressive damage of the disease and maintain functional vision with least disruption to quality of life. As we know now that structure damage (optic nerve or retinal nerve fiber layer) often precede functional damage, however this is not universal as imaging devices many not be sensitive enough to pick up subtle damages.[1] Given that scenario it is the recommendation of both and American Optometric association and American Academy of Ophthalmology to record both structure and visual function in patients at risk of glaucomatous optic neuropathy.[2 3]

Obtaining objective data on the morphology and the structure of optic nerve and nerve fiber layer is of great advantage particularly if it is repeatable and reproducible because there is great amount of intra and inter observer variability amongst clinicians. To this accord the computerized imaging technologies can obtain automated evaluation of structural damage in eyes at risk of glaucoma particularly because imaging is less influenced by disease severity and has low long term variability. [4] This article will cover: 1) the technology behind each

imaging device, 2) understand parts of the output that is important parameters that have shown to be clinically useful, having diagnostic or prognostic ability. This article will also evaluate: 3) the output of imaging devices to evaluate progressive damage in individuals at risk of glaucoma. Further this article will also discuss the common imaging artifacts that can influence the outcome of the imaging tests.

Most experts in the field will agree to the fact that stereo optic disc imaging is perhaps the gold standard of all techniques of optic disc evaluation.[3 5 6] Fundus cameras can generate a stereo disc images by either displacing the camera system thus creating an offset and obtain two pictures sequentially. The disadvantage of such a technique is that the amount of displacement can differ from one visit to another that can lead to erroneous judgment. Ideally stereo optic disc pictures should be captured by simultaneously this can be achieved by having a dual camera system that captures two images simultaneously. Also until recent years automated analysis of the optic disc morphology was not readily available and investigators of various studies performed planimetry to evaluate disc morphology.[5 6] With the advances in automated analysis this technique may see a revival and increased use in clinical care.

The computerized imaging devices are fundamentally Scanning Laser Ophthalmoscope, Scanning Laser Polarimeter or Optical Coherence Tomograph. These technologies may provide similar information but there are fundamental differences between devices that makes the measurements obtained from each non-interchangeable. Furthermore there is benefit to be gained by performing multiple imaging on the same patient as it may yield additional clinical details.

2. Scanning laser ophthalmoscope

Heidelberg Engineering manufactures Heidelberg Retina Tomograph III (HRT which is the current generation scanning laser ophthalmoscope that provides topographical data of the optic nerve and peri-papillary retina. Using high speed raster scanning technique and diode laser for illumination HRT obtains two-dimensional images of retina and optic nerve. The depth of focal plane is automatically adjusted to obtain multiple two-dimensional images. The HRT III acquires 16 to 64 2-dimensional images to a maximum depth of 4 mm that starts at vitreo-retinal interface to beyond the bottom of the optic disc cupping. The number of optic section varies in different eyes. The eye with deep cupping has an increase in number of sections (two-dimensional images). The optic sections are combined to produce a three-dimensional topography of the optic disc surface. This is repeated up to six time and the best three are selected and averaged to obtain the final output.

2.1. Interpretation of a HRT III output

There are various reports with different level of information that is produced by the device. The author believes that the OU report (Figure 1) is an excellent output of various parameters that are clinically useful in making judgment and patient education. The quality of the scan is judged on the value of standard deviation; the lower the value of standard deviation the better is the quality of the scan (see section A Figure 1). The HRT III provides useful information on

optic disc size. The device software classifies the optic disc, average or large once the user has outlined the optic disc margin (see section A Figure 1). Overall HRT's optic disc analysis provides details of cup information, neuro-retinal rim information and retinal nerve fiber layer (RNFL) information. The right eye of the patient is compared to the left eye and the between eyes asymmetry is also provided. All parameters provided are also compared to the normative database to evaluate if parameters are within statistical limits of normality, borderline or outside normal limits.

A color coded figure provides the cupping information (section B Figure 1). The cupping is represented by the red color where as the neuro retinal rim is represented by blue and green with blue being sloping rim and the green the stable rim. The cup volume is provided as one of the parameters and in eyes suspicious of glaucoma or progressive loss of neuro-retinal rim we can see an increase in cup volume. The cup shape measure is an overall value of three-dimensional representation of cupping and the values are negative in an ocular healthy eye and more positive in an eye suspicious of glaucoma.

The rim details provided are rim area and rim volume both will see a decline with progression of glaucomatous optic neuropathy (see Section C Figure 1). Additionally once the outline of optic disc is marked the device automatically generates Moorfields Regression Analysis. This is arguably the single most important parameter and is discussed in greater detail below. HRT also provides RNFL which is measured 360 degrees just outside the disc margin (see Section D Figure 1). This location of measurement differs from the location of measurement of both the Scanning Laser Polarimeter-GDx-Pro and Optical Coherence Tomograph. Thus the RNFL measured using one technology will not match the values obtained by other and should not be used interchangeably.

All HRT parameters are given symbols of green check mark, yellow exclamation point, or red X which represents statistical limits of normality that is within normal limits, borderline or outside normal limits respectively.

2.2. Moorfield's regression analysis

The Moorfields Regression Analysis was developed by Dr. David Garway-Heath and colleagues [7 8] at the Moorfields hospital, London England. The Moorfields Regression Analysis (MRA) provides an ability to perform cross-sectional analysis, thus classifying an eye as at risk or within normal limits. The analysis exploits prior knowledge that the neuro retinal rim area is positively correlated with the disc size that is the larger the disc size greater is the rim area[9 10] and additionally the rim area narrows in eyes with glaucomatous optic neuropathy[11 12]. The MRA provides information if the rim area of an eye is within 95%, 99% or 99.9% of population. The optic nerve is divided into six sectors, superior 90 degrees is divided into superior nasal and superior temporal, similarly inferior 90 degrees are divided into inferior nasal and inferior temporal. The nasal and temporal 90 degrees form the remaining two sectors. If a rim area falls between 95 to 99% or greater than 99% of predicted population interval it is labeled as borderline or outside normal limits respectively. If any sector falls in either of these two categories the MRA is classified as Outside Normal Limits.

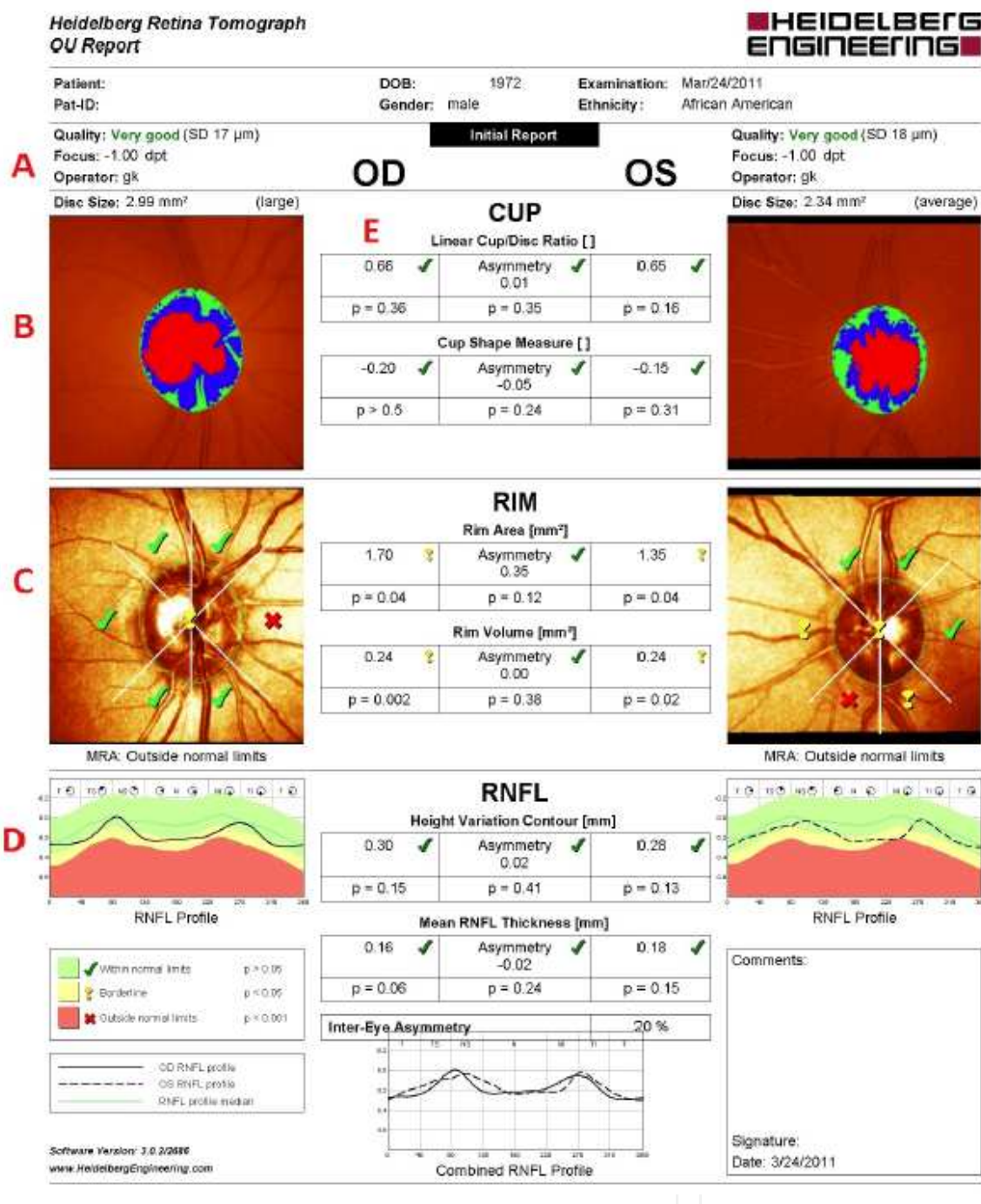


Figure 1. An OU report obtained using HRT III. Section A shows that reliability of the scan and the size of the disc which is obtained once the operator outlines the disc margin. Section B is a courtesy pseudo-isochromatic fundus image that shows the rim and cupping. Red color represents the cupping whereas the blue and the green are rim tissue. Section C shows the Moorfields regression analysis of various sectors of optic disc and section D shows RNFL in the TSNIT region. The section E provides the right eye and left eye information of various parameters measured and its asymmetry analysis along with statistical significance

This parameter was investigated in an Ancillary Study to Ocular Hypertension Treatment Study and was found to be a significant predictor of future development of glaucomatous optic neuropathy in a group of ocular hypertensive eyes.[13] Additionally a more recent report from

the same study indicates that these parameters are as effective as stereo photographs at estimating risk of development of primary open angle glaucoma in a group of ocular hypertensive eyes. [14]

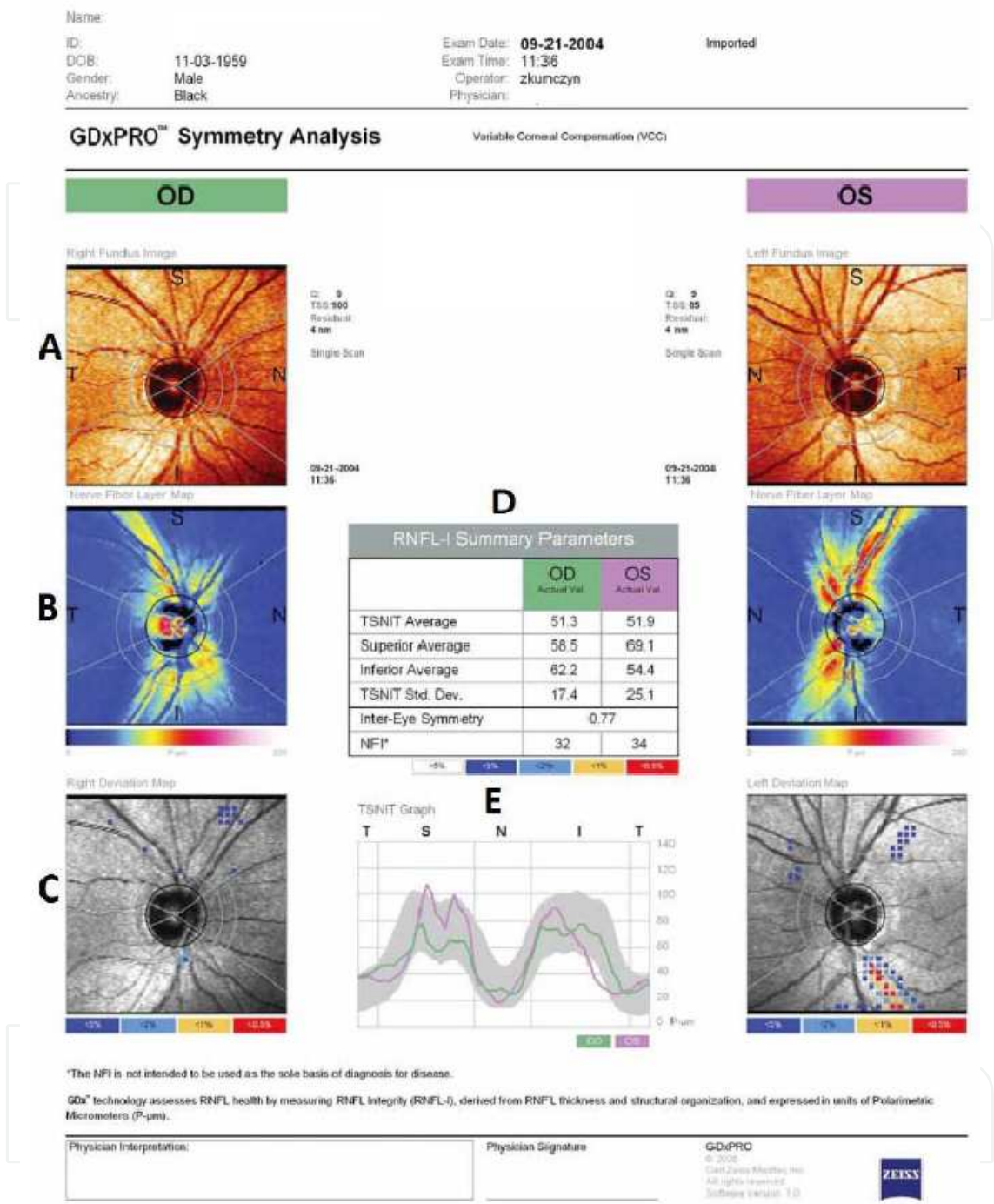
3. Scanning laser polarimetry

Carl Zeiss Meditec manufactures the GDx-Pro which is the current generation scanning laser polarimeter. The scanning laser polarimeter uses near infrared laser (780 nm) in a raster pattern to image both the macula and peripapillary region. Details about the working principles can be found in detail elsewhere. [15] Birefringence is optical property that split a light wave by a polar material into two components. These components travel at different velocities which creates a relative phase shift. The phase shift is termed retardation. A few ocular structures, cornea, lens and retinal nerve fiber layer that are highly organized and parallel structures are birefringent. The scanning laser polarimeter is a confocal scanning laser ophthalmoscope that is capable of measuring retardation. It is shown that the RNFL retardation measured using the scanning laser polarimeter correlates well with the retinal RNFL determined by histology. [16 17]

3.1. Measurement and Interpretation of GDx — Pro output

The scanning laser polarimeter as a first step calculates anterior segment birefringence. This procedure is needed only once when examining the patient for the first time as anterior segment birefringence remains similar throughout life. If there is a significant change in anterior segment like refractive or cataract surgery it is recommended to re-calculate the anterior segment birefringence. [18-20] Second part of the test is to obtain the birefringence of the peripapillary retina. Clinicians can choose to scan the eye once or thrice. Obtaining more than one scan during the visit and averaging the scans decreases the variability in measurements obtained.

The output of optic nerve head and peripapillary images are divided into three parts: the fundus image, retinal nerve fiber layer map and deviation map (see Figure 2 section A, B and C respectively). The fundus image (Figure 2 section A) in a GDx-Pro printout is a misnomer because the device uses a monochromatic light to capture the image. This image is only utilized to evaluate the focus, centration of scan and to be certain that the scan is evenly illuminated. The retinal nerve fiber layer map provides information about the thickness of the retinal nerve fiber layer in a 20-degree image with the optic nerve in the center (Figure 2 section B). It is expected that in healthy eyes the inferior and superior retinal nerve fiber layer is thick and represented with bright red and yellow, whereas the nasal and temporal regions are thinner and are represented with cooler colors like blue. The deviation map provides information if the retinal nerve fiber layer thickness points on the 20 degree image are within statistical limits of normality or have a less than 5%, 2%, 1% or 0.5% chance of being normal (Figure 2 section C).



peripapillary retina of both eyes (Figure 2 E). The more similar the profiles are the less likely they are glaucomatous, however one has to remember the two eyes of an individual although similar most definitely will have differences.

There are various thickness parameters like TSNIT average, inferior average, superior average are provided along with color coding to indicate if they are within statistical limits of normality. The GDx-Pro also provides with a classifier the Nerve Fiber Indicator (NFI) that ranges 0 to 100 and a higher number is likely suggestive of damage. The manufacturers recommend that a NFI value of less than 30 has a low likelihood of glaucoma, a value between 30 and 50 should be considered a suspect and a value greater than 50 has a high likelihood of glaucoma. Numerous studies have shown that the NFI is the best GDx parameter at differentiating ocular healthy and glaucoma eyes. [21-24]

4. Optical coherence tomography

It is indeed an understatement to say that optical coherence tomography (OCT) has revolutionized clinical imaging in eye care. It was one of the fastest accepted technologies in eye care which is capable of obtaining micron resolution cross-sectional or tomographic scans of biological tissue in vivo. The principles of OCT are similar to ultrasound devices. The OCT uses light instead of sound thus providing excellent resolution (5-10 microns and 15 microns transverse). The echo time delay (that is the delay in time from when the ray of light leaves the device till the reflected light is received back) is calculated thus measuring distance that is an axial scan (A-scan). This is done at about 400 times per second. The axial scans are added to obtain the B-scan of the location being measured. The OCT principles described above is a "Time-domain (TD) OCT". The TD OCT devices are manufactured by Carl Zeiss Meditec. Although a phenomenal breakthrough in itself it was limited by number of scans it was capable of measuring. The scan regions measured were small and time taken was much larger. This was remedied by the "Fourier-Domain" technology. The Fourier domain technology uses a broader band width light source than the time domain OCT with a spectrometer to obtain the spectral interferogram that when analyzed using Fast-Fourier Transformation obtains the A-scan. The A-scans are obtained at a rate of 26,000 to 40,000 per second. Thus large amounts of data can be obtained in a short duration which was not possible accurately using the Time-domain OCT.

Numerous companies' manufacture the Fourier-domain OCT. This article will discuss general parameters output by all OCTs. Furthermore the OCT is capable of measuring both anterior segment and posterior segment. This article is going to restrict to analyzing output of posterior segment scan.

The OCT outputs the retinal nerve fiber layer thickness map and a deviation map (Figure 3 sections A and B). The RNFL thickness map (Figure 3 section A) is similar in interpretation as GDx-Pro which is color coded and it is expected that the inferior and superior region will show thicker RNFL compared to nasal and temporal regions in healthy eyes. The deviation map (Figure 3 section B) provides information if the given region is within statistical limits of normality. It also doubles as a fundus image; a careful look at this region

Figure 3. An output of RNFL analysis of Cirrus OCT. Section A shows the thickness map and section B shows the fundus image and highlights regions that are not within statistical limits of normality. Section C provides with the table of various parameters. Section D provides the TSNIT RNFL thickness profile and Section E provides thickness in various sectors and clock hours respectively. The section B,C,D and E are color coded to give an idea if the thickness measurement region or a parameter are within statistical limits of normality or outside normal limits. Section F provides with the vertical and horizontal tomogram obtained at the 12 and 6 O'clock & 3 and 9 O'clock of disc and peripapillary retina providing layer by layer thickness profile of retina and optic disc. The Circular tomogram in Section F is the cross-sectional thickness profile taken on the region of purple ring in section B.

The purple ring in Figure 3 Section B denotes the region where the RNFL is measured on the Temporal Superior, Nasal, Inferior and Temporal (TSNIT) region. This is utilized to calculate the RNFL parameters like the Average RNFL thickness and symmetry provided in the table (Figure 3 Section C). The RNFL thickness profile obtained from the purple ring around the optic nerve is plotted graphically for both eyes to obtain symmetry information (Figure 3 section D). The graph has three color coded regions: 1) green represents 95% of normal distribution. 2) The yellow in RNFL plot represents the population that has less than 5% but greater than 1% chance of being normal and is also called the “borderline” category, whereas, 3) the red in the RNFL plot represents <1% chance of being normal; the “outside normal limits” category. The OCT also provides disc parameters in the table of parameters that includes cup to disc ratio cup volume, disc area and rim area (Figure 3 section C). The OCT also provides the RNFL values in each quadrant and each clock hour (Figure 3 Section E). The analysis reports of Optovue OCT Heidelberg and Engineering Spectralis is very similar to that of explained of Cirrus OCT (See Figure 4 and 5).

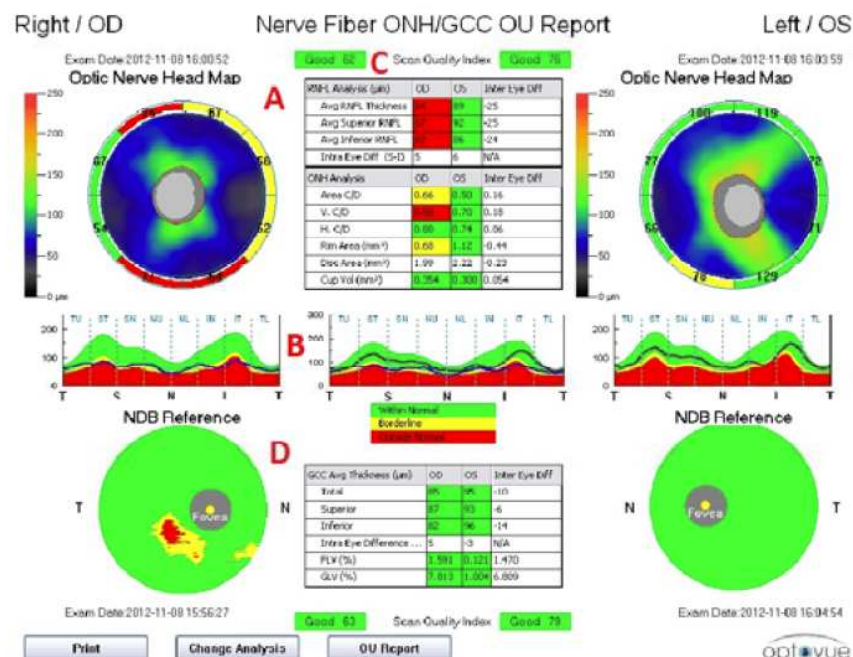


Figure 4. A combined output of retinal nerve fiber layer and ganglion cell complex map obtained by Optovue iVue OCT. The section A provides thickness information around the disc, section B the RNFL thickness in TSNIT region and section C provides the various parameters. The section D provides the ganglion cell complex parameters and the map. The right eye data shows that the infero temporal macula region shows damage that is statistically significant. All sections are color coded to provide information on statistical significance. Image courtesy Dr. Qienyuan Zhou PhD Optovue Inc.

Because OCTs are relatively new technology, automated machine learning algorithms similar to NFI of GDx-Pro and Moorfields regression analysis of HRT III are not available in OCT. It is seen that inferior average consistently shows up as the best parameter in differentiating early glaucoma from ocular healthy eyes.[5 25-32]

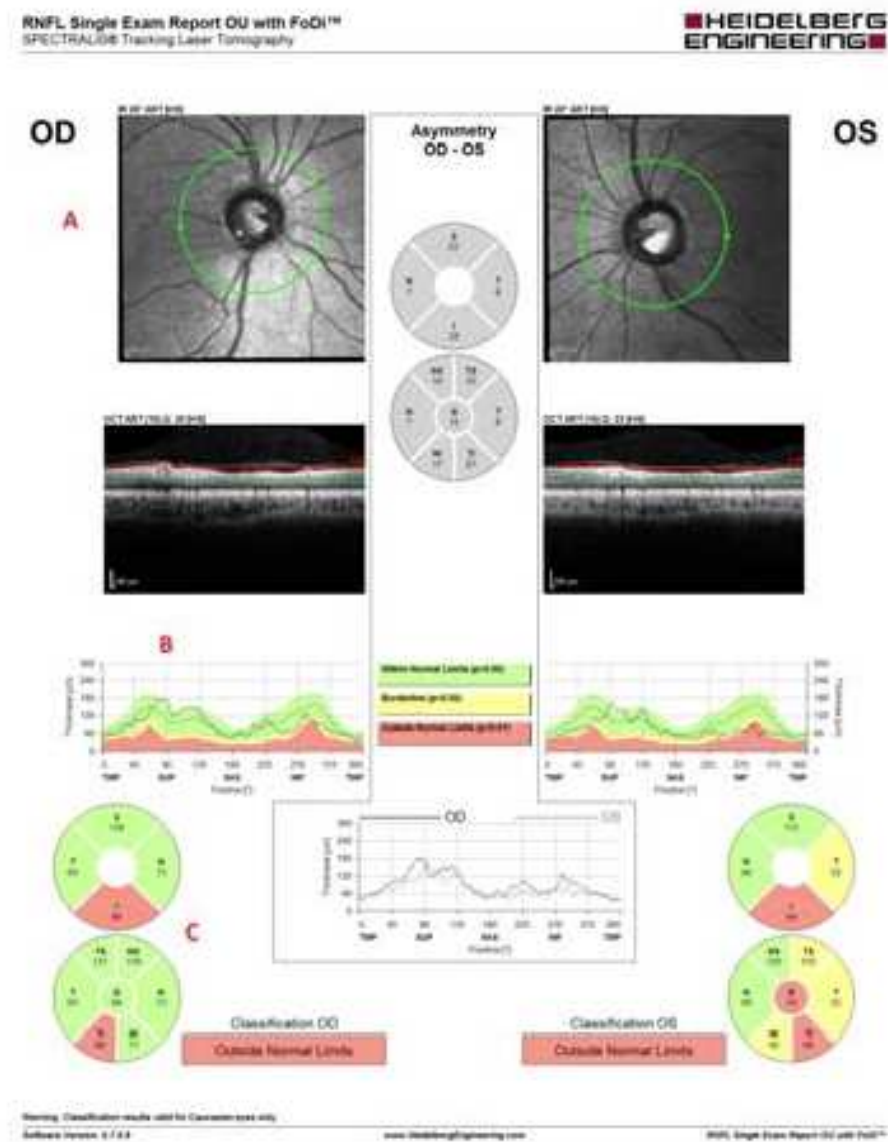


Figure 5. An OU report of RNFL with section A, B and C showing fundus image, RNFL thickness profile in TSNIT region and RNFL thickness in various quadrants respectively. Both the section B and C are color coded to provide information on statistical significance. Image courtesy Mr. Ali Tafreshi of Heidelberg Engineering.

4.1. Macula analysis in glaucoma

A new macula analysis is proposed to evaluate patients at risk of glaucoma. This analysis was proposed by Dr. Sanjay Asrani MD as additional data that might help managing glaucoma patients.[33 34] A separate scanning of the macula region is needed to obtain ganglion cell analysis. Different manufactures perform the analysis with slight variation. The Optovue manufactures of RTvue and iVue OCT call it the Ganglion Cell Complex that includes the nerve fiber layer, ganglion cell layer and the inner plexiform layer (Figure 4 section D). Carl Zeiss Meditec the manufacturers of Cirrus OCT calls it the Ganglion Cell Analysis that includes the

Ganglion cell layer and inner plexiform layer. There is no agreement if one analysis yields better results than the other. Further there is some conflicting reports about the diagnostic accuracy of the macular parameters in glaucoma however they tend to perform at par with other parameters generated by Fourier domain OCT (See review article by Wong et al., [35].)

5. Imaging artifacts

Although invaluable in clinical practice imaging devices like other clinical diagnostic techniques are susceptible to artifacts. Some which can be controlled and some that are not possible to control. When there is reduced signal strength which could possibly be due to image focusing issues, eye movement, tear film issues, or optical quality lowered due to presence of media opacity there is degradation in image quality which leads to errors in measured parameters and diagnostic ability of the devices.

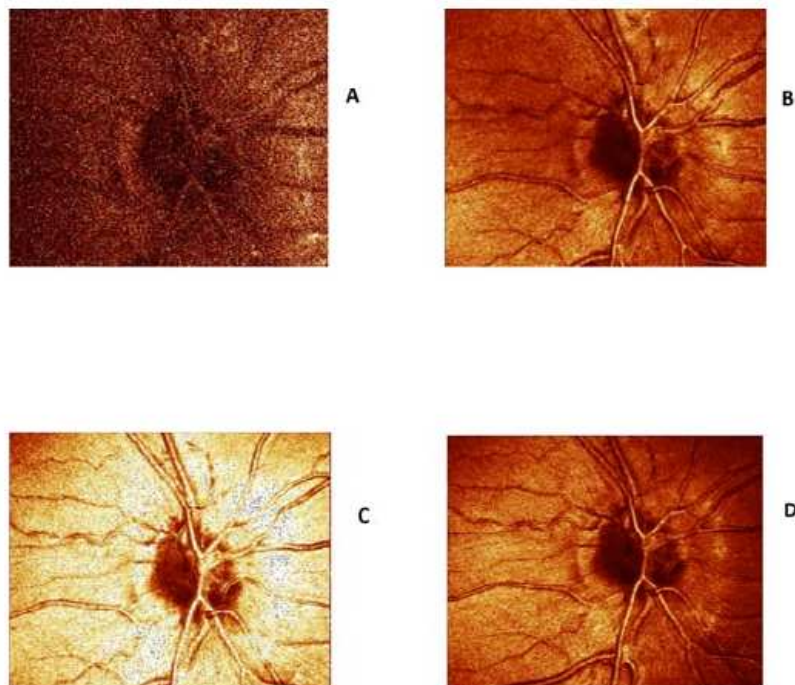


Figure 6. Common errors in imaging, these decrease the signal strength and image quality which in turn decreases the accuracy of parameters obtained. Section A shows an image of a severe dry eye patient that improved upon instillation of artificial tears (Section B). Section C shows the same patient with 2 diopter myopic defocus. As seen the image is over exposed with imaging artifacts visible. Section D shows the same patient with appropriate focus set.

All imaging devices outcomes would be affected if the image is defocused or if there was image quality degradation. Studies have looked at the effect of dryness and tear film issues that influence the outcome of the imaging. [36-38] It is advisable that patient's blink regularly between scans or artificial tears/lubricants be utilized to form a uniform regular optical surface. It is also be ideal if procedures that require ocular contact be avoided and performed after

imaging is complete. Similarly reduced pupil size and optic media can have effect on imaging because the amount of light reaching retina will be decreased thus signal received from the eye will be of decreased leading to missing details.[36] This causes erroneous estimation of parameters measured and also to excessive false positive diagnosis. See figure 6 A-D for error in imaging due to dry eye or defocus and improvement in images when appropriate corrective methods were used.

Involuntary eye movement often leads to measurements obtained not at the intended region. [39] This leads to major errors in imaging. Some of these errors may be obvious to detect however some so subtle and leaving no obvious artifacts (See figure 7A B C and D “eye movement artifacts”). The eye movement artifacts are particularly a serious issue in the case of time domain OCTs slow scans or any scan that takes longer time. The errors in imaging due to eye movements can be avoided in the image acquisition phase as done by re-scanning as done in Spectralis OCT or done post acquisition (post image capture) processing as done in Optovue’s OCTs.

The device may also fail in identifying appropriate layers of retinal and thus leading to segmentation errors. The scans should be viewed carefully and imaging performed again if such errors are observed. These errors are becoming less common with advanced instrumentation and algorithms that are in development to provide image registration.

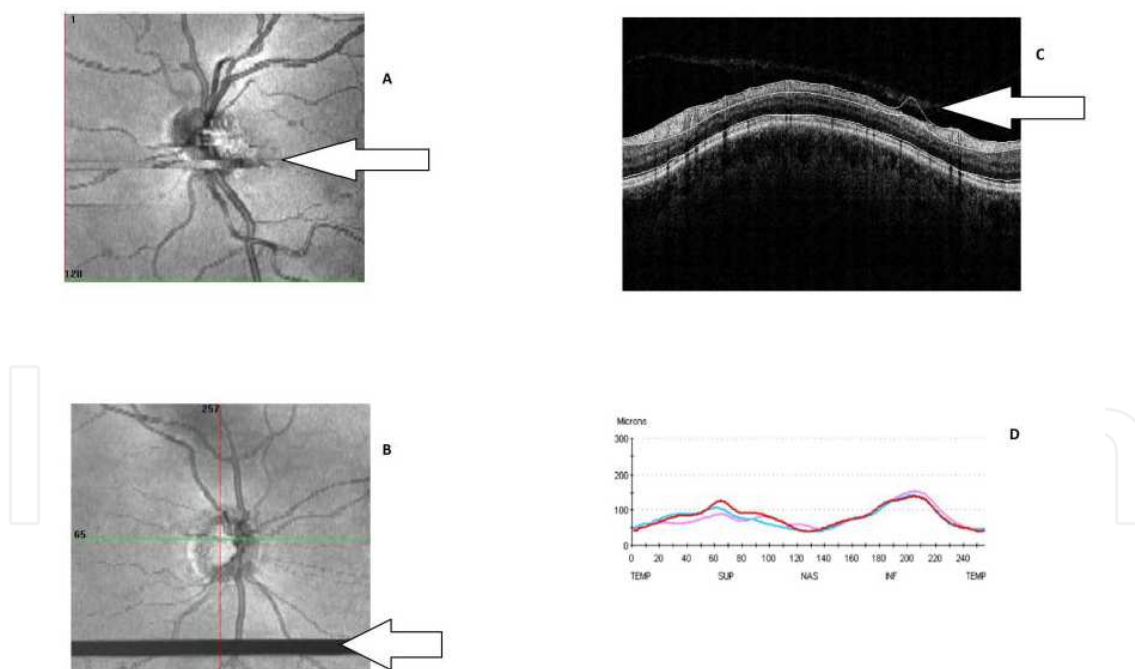


Figure 7. Various errors in imaging marked by an arrow in individual images. Section A shows an eye movement artifact that is seen as non continuous blood vessels and optic disc. Section B shows blink artifact that is seen as a black band of missing data. Section C shows a segmentation error of RNFL which the machine algorithm has outlined incorrect upper lower layer of RNFL erroneously including the vitreo-retinal interface. Section D shows three consecutive scans obtained using Time domain OCT that were obtained 1-minute apart in a patient moving his eye. Images A,B, C courtesy Miss Kelly Soules Optovue Inc.

Atypical Birefringence pattern is an imaging artifact that affects images obtained in eyes with poor choroidal pigmentation also called “blonde fundus” and influenced results obtained using the prior generation polarimetry device GDx-Variable Corneal Compensator (VCC). These patterns were prevalent in 10-15% of the population when examined with GDx-VCC. [22 40] The images tended to not follow the normal physiological pattern of nerve fiber layer and the RNFL map shows “bicycle spoke like pattern” or “tie dye pattern” (See figure 8). These eyes were deemed not appropriate for imaging using GDx-VCC. With the new generation polarimeter GDx-Pro (Enhanced Corneal Compensator) has dramatically decreased the prevalence of these atypical patterns and long term measurement variability.[41]

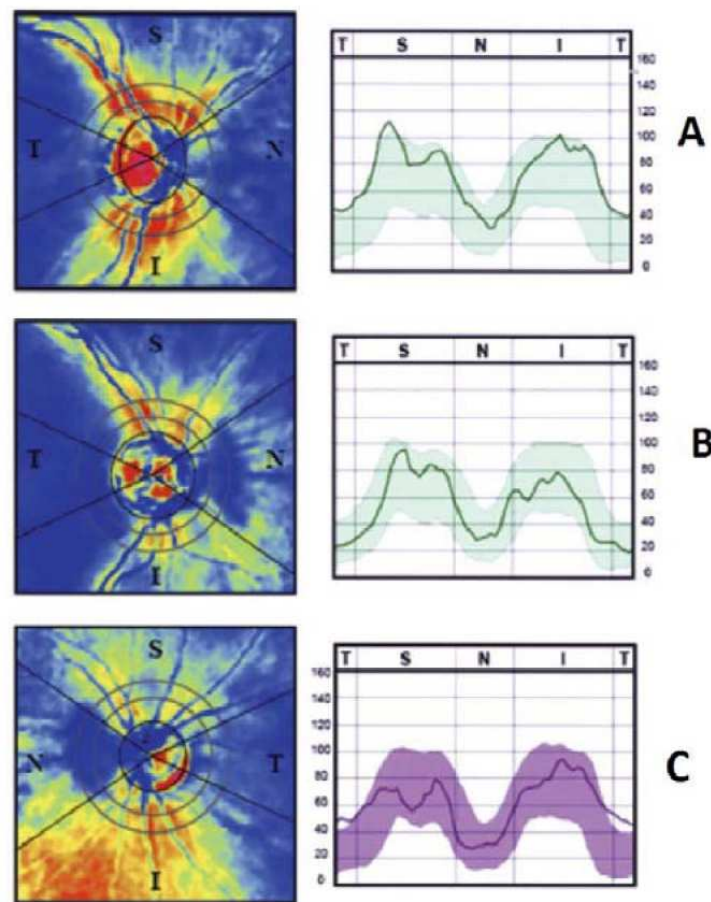


Figure 8. Three eyes with Atypical Retardation Pattern also known as "tie-dye" pattern in RNFL thickness profile map. These are an outcome of poor signal to noise ratio due to poor choroidal pigmentation. These scans are an outcome of an artifact and should not be utilized in managing patients.

6. Diagnostic accuracy and comparison of individual devices

Overall the principles behind the confocal scanning laser ophthalmoscope HRT-I, HRT-II and HRT-III manufactured by Heidelberg engineering are very similar that the data can be

transferred from one generation to another. The agreement in stereometric parameters obtained by HRT-I is very similar to HRT-II.[42] Thus as expected the diagnostic accuracy of these different generation devices should be similar.

Whereas where GDx is concerned each generation of technology has fixed an error or problem in the imaging. For example the initial generation device: GDx-Fixed Corneal Compensator (GDx-FCC) used a standard correction factor to correct for anterior segment birefringence. The anterior segment birefringence varies in population thus the technology was changed to GDx Variable Corneal Compensator (GDx-VCC). [43 44] Recently the new generation GDx-Pro was introduced to improve upon the GDx-VCC. It is shown that the GDx-Enhanced Corneal Compensator (ECC now called GDx-Pro) better characterized the RNFL, decreased the number of atypical retardation pattern found in the study population.[45] It is shown by Mai and co-workers that the GDX-Pro has better repeatability, diagnostic ability, and a better structure and function relationship than GDx-VCC.[46-48] Thus it has to be remembered that where polarimetry is concerned newer devices are better than older generation devices.

Similarly the Fourier domain OCT compared to the older generation “time-domain” TD-OCT shows a marked improvement as it tried to address issues related to improved resolution, faster scanning speed. Where glaucoma is concerned the diagnostic accuracy of the TD OCT is similar to FD OCT [49 50], also the population mean RNFL values may not vary significantly however it has to be remembered the RNFL measurements are not comparable and cannot be used interchangeably.[51] The TD OCT RNFL tends to be thicker than FD OCT except for advanced glaucoma.[51] Unlike GDx-Pro and HRT III there are various manufacturers that make the Fourier Domain OCT. Overall comparing various Fourier domain OCT techniques the diagnostic accuracy in identifying individuals with glaucomatous optic neuropathy is very similar in these devices despite having difference in resolution and scanning speed.[52]

7. Comparison of diagnostic accuracy of various devices

Diagnostic accuracy of the imaging devices varies as a function of disease severity.[28 53-57] As the severity of glaucoma increases devices accuracy to detect glaucoma accurately also increases. For various reasons it is difficult to compare all imaging devices and its ability to diagnose glaucoma as there is no large scale population based study that have compared the latest technology that is available. Additionally there are inherent differences in the design and population of the cross-sectional studies that will influence the outcome of the study. For example the nerve fiber layer analysis may better suit than disc topography in evaluating myopes at risk of glaucoma. [58] These factors need to be kept in mind when comparing diagnostic accuracy of various imaging devices.

Studies have compared diagnostic capacity of GDx, OCT and HRT and although slight differences exist in identification of true-positive overall the ROC area which is a function of sensitivity and specificity (true positive and true negative) is similar in all the devices.[32 59] Because both the OCT and GDx provide RNFL data and numerous studies have evaluated its ability in identifying individuals with glaucoma.[5 32 59-62]. Over all these studies report that

the diagnostic accuracy of GDx is very similar to OCT in identifying glaucoma eyes from a group of ocular healthy eyes. So in summary it is safe to conclude that although there are differences in diagnostic accuracy of various imaging devices overall they tends to perform quite similar.

8. Progression and imaging

Detecting progression or change over time in eyes at risk of glaucoma or with glaucoma is probably one of the most difficult tasks clinically. Progression in an optic nerve due to open angle glaucoma is subtle, slow and can easily be missed in casual observation. Thus the objectivity and reproducibility of the imaging devices can be of great benefit. All imaging devices have parameters that can be followed over time to monitor progression. These algorithms are overall based on simple regression analysis that is analyzing change in parameters with follow-up over time. This analysis identifies if there is a trend of values lowering or increasing over time was statistically significant also known as trend analysis.

Heidelberg retina tomography has topographical change analysis (TCA). The TCA is a statistical method that compares topographic values in small discrete regions of 4x4 pixels called superpixels. This method is distinctly different than trend analysis as the analysis is performed on raw topography values. The figure 9 shows an optic nerve head with progressive damage compared to the baseline scans. Studies have shown that this may be useful in identifying progressive damage in glaucoma.[63 64]

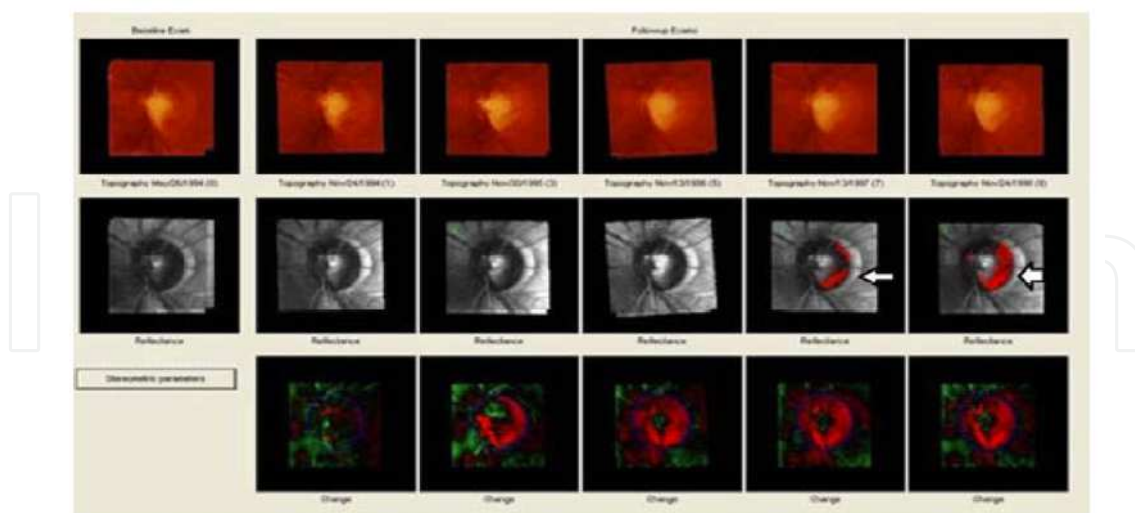
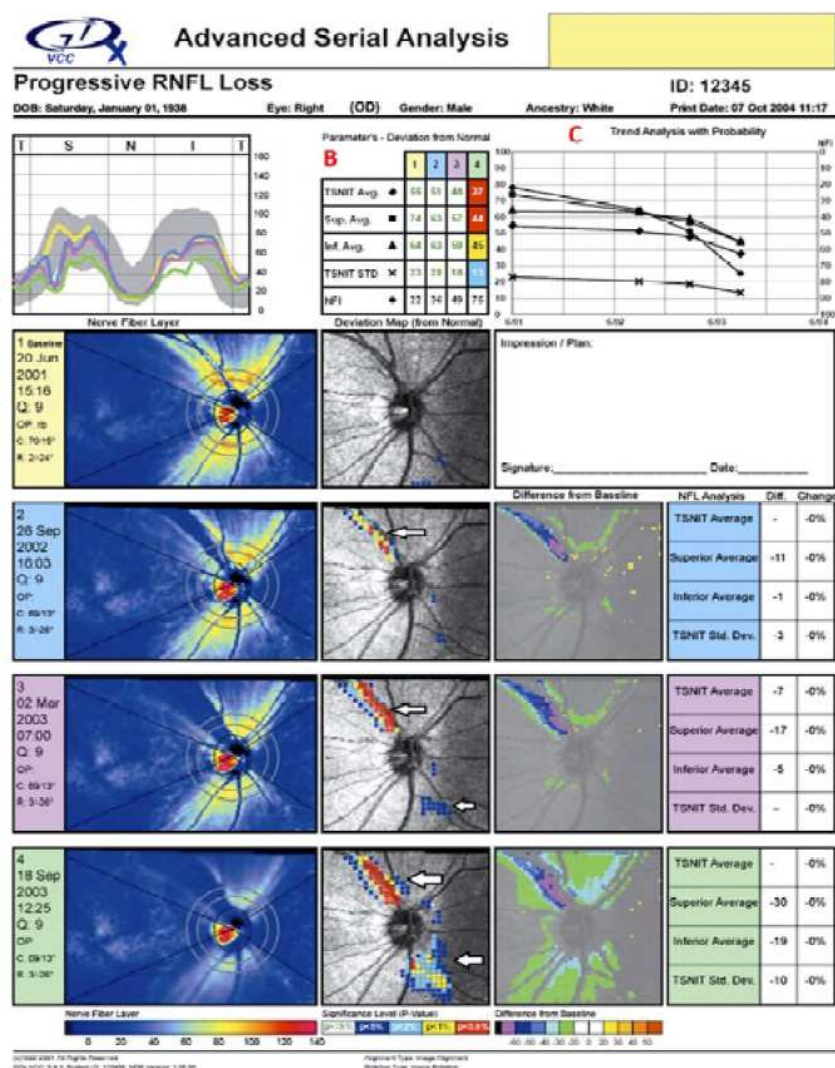


Figure 9. A Topographical Change Analysis output obtained using the HRT. The arrows indicate region of change in thickness particularly thinning in rim area. Image courtesy Mr. Ali Tafreshi of Heidelberg Engineering.

The scanning laser polarimetry GDx-VCC has advanced serial analysis that outputs trend over time in diagnosing progressive change in glaucoma (Figure 10). More recently an advanced



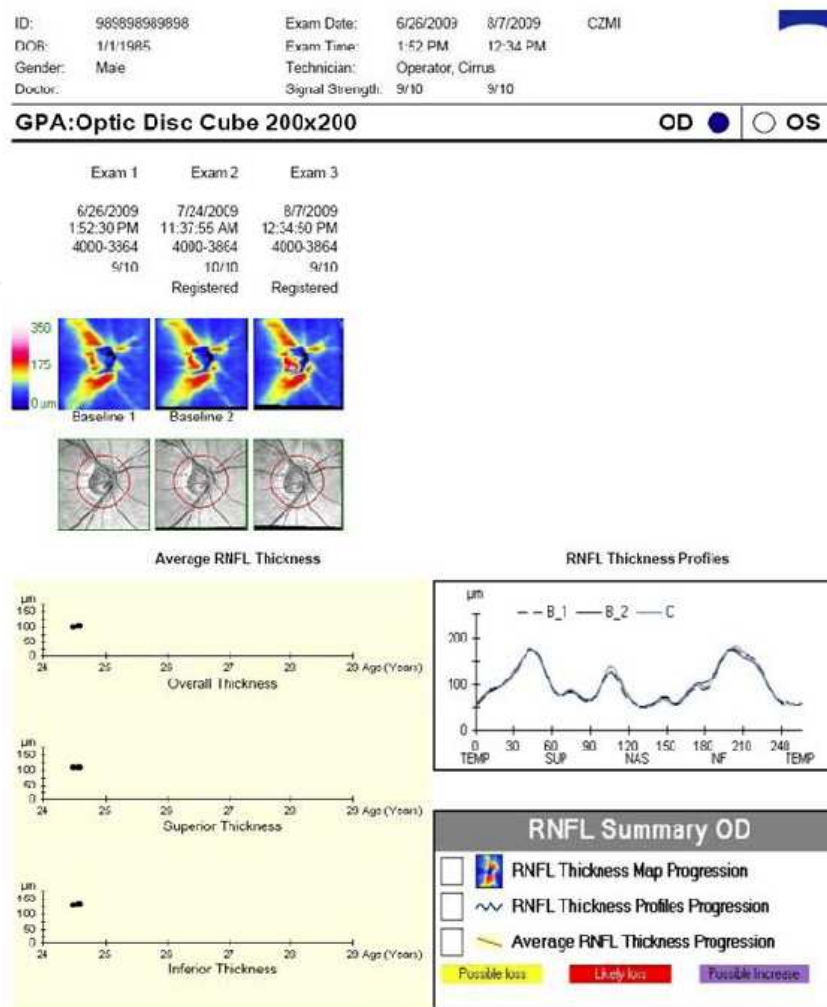


Figure 11. A Guided Progression Analysis (GPA) of Cirrus OCT that is obtained on an ocular hypertensive patient. The scans show no progressive damage in the short duration of follow-up with both RNFL thickness profile and RNFL summary.

provement in correlation of structure-functional loss in eyes with glaucoma.[68-73] This can improve overall diagnostic and prognostic ability in managing patients with glaucoma. With further advance in adaptive optics and improvement in transverse resolution has given us ability to image cones astrocytes, ganglion cells and its dendrites. [74] This should be able to bring the next wave in improvement of patient care and improve understanding of glaucoma pathogenesis.

Author details

Pinakin Gunvant Davey

Western University of Health Sciences, College of Optometry, Pomona CA, USA

References

- [1] Gordon MO, Beiser JA, Brandt JD, et al. The Ocular Hypertension Treatment Study: baseline factors that predict the onset of primary open-angle glaucoma. *Archives of ophthalmology* 2002;120(6):714-20; discussion 829-30
- [2] Fingeret M, Mancil L, Bailey IL, et al. Optometric Clinical Practice Guideline: Care of the Patient with Open Angle Glaucoma. Secondary Optometric Clinical Practice Guideline: Care of the Patient with Open Angle Glaucoma 2011.
- [3] Prum B, Friedman D, Gedde S, et al. Primary Open Angle Glaucoma. Secondary Primary Open Angle Glaucoma 2010.
- [4] Leung CK, Cheung CY, Lin D, et al. Longitudinal variability of optic disc and retinal nerve fiber layer measurements. *Investigative ophthalmology & visual science* 2008;49(11):4886-92 doi: 10.1167/iovs.07-1187[published Online First: Epub Date] |.
- [5] Greaney MJ, Hoffman DC, Garway-Heath DF, et al. Comparison of optic nerve imaging methods to distinguish normal eyes from those with glaucoma. *Investigative ophthalmology & visual science* 2002;43(1):140-5
- [6] Jonas JB, Budde WM, Panda-Jonas S. Ophthalmoscopic evaluation of the optic nerve head. *Survey of ophthalmology* 1999;43(4):293-320
- [7] Garway-Heath DF, Wollstein G, Hitchings RA. Aging changes of the optic nerve head in relation to open angle glaucoma. *The British journal of ophthalmology* 1997;81(10):840-5
- [8] Wollstein G, Garway-Heath DF, Hitchings RA. Identification of early glaucoma cases with the scanning laser ophthalmoscope. *Ophthalmology* 1998;105(8):1557-63 doi: 10.1016/s0161-6420(98)98047-2[published Online First: Epub Date] |.
- [9] Betz P, Camps F, Collignon-Brach C, et al. [Stereophotography and photogrammetry of the physiological cup of the disc (author's transl)]. *Journal francais d'ophtalmologie* 1981;4(3):193-203
- [10] Jonas JB, Gusek GC, Naumann GO. Optic disc, cup and neuroretinal rim size, configuration and correlations in normal eyes. *Investigative ophthalmology & visual science* 1988;29(7):1151-8
- [11] Read RM, Spaeth GL. The practical clinical appraisal of the optic disc in glaucoma: the natural history of cup progression and some specific disc-field correlations. *Transactions-American Academy of Ophthalmology and Otolaryngology. American Academy of Ophthalmology and Otolaryngology* 1974;78(2):OP255-74
- [12] Tuulonen A, Airaksinen PJ. Initial glaucomatous optic disk and retinal nerve fiber layer abnormalities and their progression. *American journal of ophthalmology* 1991;111(4):485-90

- [13] Zangwill LM, Weinreb RN, Beiser JA, et al. Baseline topographic optic disc measurements are associated with the development of primary open-angle glaucoma: the Confocal Scanning Laser Ophthalmoscopy Ancillary Study to the Ocular Hypertension Treatment Study. *Archives of ophthalmology* 2005;123(9):1188-97 doi: 10.1001/archophth.123.9.1188[published Online First: Epub Date] |.
- [14] Weinreb RN, Zangwill LM, Jain S, et al. Predicting the onset of glaucoma: the confocal scanning laser ophthalmoscopy ancillary study to the Ocular Hypertension Treatment Study. *Ophthalmology* 2010;117(9):1674-83 doi: 10.1016/j.ophtha.2010.03.044[published Online First: Epub Date] |.
- [15] RNFL analysis with GDx VCC: A primer and a clinical guide. [http://www.mediatec.zeiss.com/C125679E00525939/EmbedTitelIntern/GDxPrimerChapter2/\\$File/GDx_Primer_Chapter2.pdf%5Ct_blank](http://www.mediatec.zeiss.com/C125679E00525939/EmbedTitelIntern/GDxPrimerChapter2/$File/GDx_Primer_Chapter2.pdf%5Ct_blank), 2004.
- [16] Morgan JE, Waldock A, Jeffery G, et al. Retinal nerve fibre layer polarimetry: histological and clinical comparison. *The British journal of ophthalmology* 1998;82(6):684-90
- [17] Weinreb RN, Dreher AW, Coleman A, et al. Histopathologic validation of Fourier-ellipsometry measurements of retinal nerve fiber layer thickness. *Archives of ophthalmology* 1990;108(4):557-60
- [18] Dada T, Behera G, Agarwal A, et al. Effect of cataract surgery on retinal nerve fiber layer thickness parameters using scanning laser polarimetry (GDxVCC). *Indian journal of ophthalmology* 2010;58(5):389-94 doi: 10.4103/0301-4738.67048[published Online First: Epub Date] |.
- [19] Sanchez-Cano A, Pablo LE, Larrosa JM, et al. The effect of phacoemulsification cataract surgery on polarimetry and tomography measurements for glaucoma diagnosis. *Journal of glaucoma* 2010;19(7):468-74 doi: 10.1097/IJG.0b013e3181c4aed8[published Online First: Epub Date] |.
- [20] Zangwill LM, Abunto T, Bowd C, et al. Scanning laser polarimetry retinal nerve fiber layer thickness measurements after LASIK. *Ophthalmology* 2005;112(2):200-7 doi: 10.1016/j.ophtha.2004.08.019[published Online First: Epub Date] |.
- [21] Da Pozzo S, Iacono P, Marchesan R, et al. Scanning laser polarimetry with variable corneal compensation and detection of glaucomatous optic neuropathy. *Graefes archive for clinical and experimental ophthalmology=Albrecht von Graefes Archiv fur klinische und experimentelle Ophthalmologie* 2005;243(8):774-9 doi: 10.1007/s00417-004-1118-1[published Online First: Epub Date] |.
- [22] Gunvant P, Zheng Y, Toth M, et al. Atypical retardation pattern: can performance of classification be improved? *Optometry and vision science : official publication of the American Academy of Optometry* 2008;85(6):482-8 doi: 10.1097/OPX.0b013e3181783aa2[published Online First: Epub Date] |.

- [23] Iester M, Perdicchi A, De Feo F, et al. Comparison between GDx VCC parameter and achromatic perimetry in glaucoma patients. *Journal of glaucoma* 2006;15(4):281-5 doi: 10.1097/01.jig.0000212235.88416.bd[published Online First: Epub Date] |.
- [24] Reus NJ, Lemij HG. Diagnostic accuracy of the GDx VCC for glaucoma. *Ophthalmology* 2004;111(10):1860-5 doi: 10.1016/j.ophtha.2004.04.024[published Online First: Epub Date] |.
- [25] Bowd C, Zangwill LM, Berry CC, et al. Detecting early glaucoma by assessment of retinal nerve fiber layer thickness and visual function. *Investigative ophthalmology & visual science* 2001;42(9):1993-2003
- [26] Budenz DL, Michael A, Chang RT, et al. Sensitivity and specificity of the StratusOCT for perimetric glaucoma. *Ophthalmology* 2005;112(1):3-9 doi: 10.1016/j.ophtha.2004.06.039[published Online First: Epub Date] |.
- [27] Chen HY, Huang ML. Discrimination between normal and glaucomatous eyes using Stratus optical coherence tomography in Taiwan Chinese subjects. *Graefes archive for clinical and experimental ophthalmology=Albrecht von Graefes Archiv fur klinische und experimentelle Ophthalmologie* 2005;243(9):894-902 doi: 10.1007/s00417-005-1140-y[published Online First: Epub Date] |.
- [28] Guntav P, Zheng Y, Essock EA, et al. Application of shape-based analysis methods to OCT retinal nerve fiber layer data in glaucoma. *Journal of glaucoma* 2007;16(6):543-8 doi: 10.1097/IJG.0b013e318050ab65[published Online First: Epub Date] |.
- [29] Kanamori A, Nakamura M, Escano MF, et al. Evaluation of the glaucomatous damage on retinal nerve fiber layer thickness measured by optical coherence tomography. *American journal of ophthalmology* 2003;135(4):513-20
- [30] Lu AT, Wang M, Varma R, et al. Combining nerve fiber layer parameters to optimize glaucoma diagnosis with optical coherence tomography. *Ophthalmology* 2008;115(8):1352-7, 57 e1-2 doi: 10.1016/j.ophtha.2008.01.011[published Online First: Epub Date] |.
- [31] Medeiros FA, Zangwill LM, Bowd C, et al. Evaluation of retinal nerve fiber layer, optic nerve head, and macular thickness measurements for glaucoma detection using optical coherence tomography. *American journal of ophthalmology* 2005;139(1):44-55 doi: 10.1016/j.ajo.2004.08.069[published Online First: Epub Date] |.
- [32] Zangwill LM, Bowd C, Berry CC, et al. Discriminating between normal and glaucomatous eyes using the Heidelberg Retina Tomograph, GDx Nerve Fiber Analyzer, and Optical Coherence Tomograph. *Archives of ophthalmology* 2001;119(7):985-93
- [33] Asrani S, Zeimer R, Jampel H, et al. Macular symmetry testing for glaucoma detection. *Journal of glaucoma* 2006;15(2):182; author reply 82
- [34] Mathers K, Rosdahl JA, Asrani S. Correlation of Macular Thickness With Visual Fields in Glaucoma Patients and Suspects. *Journal of glaucoma* 2013 doi: 10.1097/IJG.0b013e31829539c3[published Online First: Epub Date] |.

- [35] Wong JJ, Chen TC, Shen LQ, et al. Macular imaging for glaucoma using spectral-domain optical coherence tomography: a review. *Seminars in ophthalmology* 2012;27(5-6):160-6 doi: 10.3109/08820538.2012.712734[published Online First: Epub Date] |.
- [36] Asrani S, Edghill B, Gupta Y, et al. Optical coherence tomography errors in glaucoma. *Journal of glaucoma* 2010;19(4):237-42 doi: 10.1097/IJG.0b013e3181b21f99[published Online First: Epub Date] |.
- [37] Hoh ST, Greenfield DS, Liebmann JM, et al. Factors affecting image acquisition during scanning laser polarimetry. *Ophthalmic surgery and lasers* 1998;29(7):545-51
- [38] Stein DM, Wollstein G, Ishikawa H, et al. Effect of corneal drying on optical coherence tomography. *Ophthalmology* 2006;113(6):985-91 doi: 10.1016/j.ophtha.2006.02.018[published Online First: Epub Date] |.
- [39] Koozekanani D, Boyer KL, Roberts C. Tracking the optic nervehead in OCT video using dual eigenspaces and an adaptive vascular distribution model. *IEEE transactions on medical imaging* 2003;22(12):1519-36 doi: 10.1109/tmi.2003.817753[published Online First: Epub Date] |.
- [40] Toth M, Hollo G. Enhanced corneal compensation for scanning laser polarimetry on eyes with atypical polarisation pattern. *The British journal of ophthalmology* 2005;89(9):1139-42 doi: 10.1136/bjo.2005.070011[published Online First: Epub Date] |.
- [41] Grewal DS, Sehi M, Cook RJ, et al. The impact of retardance pattern variability on nerve fiber layer measurements over time using GDx with variable and enhanced corneal compensation. *Investigative ophthalmology & visual science* 2011;52(7):4516-24 doi: 10.1167/iovs.10-5969[published Online First: Epub Date] |.
- [42] Balasubramanian M, Bowd C, Weinreb RN, et al. Agreement between the Heidelberg Retina Tomograph (HRT) stereometric parameters estimated using HRT-I and HRT-II. *Optometry and vision science : official publication of the American Academy of Optometry* 2011;88(1):140-9 doi: 10.1097/OPX.0b013e3181fc3467[published Online First: Epub Date] |.
- [43] Choplin NT, Zhou Q, Knighton RW. Effect of individualized compensation for anterior segment birefringence on retinal nerve fiber layer assessments as determined by scanning laser polarimetry. *Ophthalmology* 2003;110(4):719-25 doi: 10.1016/s0161-6420(02)01899-7[published Online First: Epub Date] |.
- [44] Zhou Q, Weinreb RN. Individualized compensation of anterior segment birefringence during scanning laser polarimetry. *Investigative ophthalmology & visual science* 2002;43(7):2221-8
- [45] Reus NJ, Zhou Q, Lemij HG. Enhanced imaging algorithm for scanning laser polarimetry with variable corneal compensation. *Investigative ophthalmology & visual science*

- science 2006;47(9):3870-7 doi: 10.1167/iovs.05-0067[published Online First: Epub Date] |.
- [46] Mai TA, Reus NJ, Lemij HG. Structure-function relationship is stronger with enhanced corneal compensation than with variable corneal compensation in scanning laser polarimetry. *Investigative ophthalmology & visual science* 2007;48(4):1651-8 doi: 10.1167/iovs.06-1003[published Online First: Epub Date] |.
 - [47] Mai TA, Reus NJ, Lemij HG. Diagnostic accuracy of scanning laser polarimetry with enhanced versus variable corneal compensation. *Ophthalmology* 2007;114(11):1988-93 doi: 10.1016/j.ophtha.2007.01.022[published Online First: Epub Date] |.
 - [48] Mai TA, Reus NJ, Lemij HG. Retinal nerve fiber layer measurement repeatability in scanning laser polarimetry with enhanced corneal compensation. *Journal of glaucoma* 2008;17(4):269-74 doi: 10.1097/IJG.0b013e31815c3a6b[published Online First: Epub Date] |.
 - [49] Chang RT, Knight OJ, Feuer WJ, et al. Sensitivity and specificity of time-domain versus spectral-domain optical coherence tomography in diagnosing early to moderate glaucoma. *Ophthalmology* 2009;116(12):2294-9 doi: 10.1016/j.ophtha.2009.06.012[published Online First: Epub Date] |.
 - [50] Chen HY, Chang YC, Wang IJ, et al. Comparison of Glaucoma Diagnoses Using Stratus and Cirrus Optical Coherence Tomography in Different Glaucoma Types in a Chinese Population. *Journal of glaucoma* 2012 doi: 10.1097/IJG.0b013e3182594f42[published Online First: Epub Date] |.
 - [51] Knight OJ, Chang RT, Feuer WJ, et al. Comparison of retinal nerve fiber layer measurements using time domain and spectral domain optical coherent tomography. *Ophthalmology* 2009;116(7):1271-7 doi: 10.1016/j.ophtha.2008.12.032[published Online First: Epub Date] |.
 - [52] Leite MT, Rao HL, Zangwill LM, et al. Comparison of the diagnostic accuracies of the Spectralis, Cirrus, and RTVue optical coherence tomography devices in glaucoma. *Ophthalmology* 2011;118(7):1334-9 doi: 10.1016/j.ophtha.2010.11.029[published Online First: Epub Date] |.
 - [53] Essock EA, Zheng Y, Gunvant P. Analysis of GDx-VCC polarimetry data by Wavelet-Fourier analysis across glaucoma stages. *Investigative ophthalmology & visual science* 2005;46(8):2838-47 doi: 10.1167/iovs.04-1156[published Online First: Epub Date] |.
 - [54] Girkin CA, Liebmann J, Fingeret M, et al. The effects of race, optic disc area, age, and disease severity on the diagnostic performance of spectral-domain optical coherence tomography. *Investigative ophthalmology & visual science* 2011;52(9):6148-53 doi: 10.1167/iovs.10-6698[published Online First: Epub Date] |.
 - [55] Leite MT, Zangwill LM, Weinreb RN, et al. Effect of disease severity on the performance of Cirrus spectral-domain OCT for glaucoma diagnosis. *Investigative ophthalmol-*

mology & visual science 2010;51(8):4104-9 doi: 10.1167/iovs.09-4716[published Online First: Epub Date] |.

- [56] Rao HL, Leite MT, Weinreb RN, et al. Effect of disease severity and optic disc size on diagnostic accuracy of RTVue spectral domain optical coherence tomograph in glaucoma. *Investigative ophthalmology & visual science* 2011;52(3):1290-6 doi: 10.1167/iovs.10-5546[published Online First: Epub Date] |.
- [57] Reddy S, Xing D, Arthur SN, et al. HRT III glaucoma probability score and Moorfields regression across the glaucoma spectrum. *Journal of glaucoma* 2009;18(5):368-72 doi: 10.1097/IJG.0b013e31818c6edd[published Online First: Epub Date] |.
- [58] Leung CK, Medeiros FA, Zangwill LM, et al. American Chinese glaucoma imaging study: a comparison of the optic disc and retinal nerve fiber layer in detecting glaucomatous damage. *Investigative ophthalmology & visual science* 2007;48(6):2644-52 doi: 10.1167/iovs.06-1332[published Online First: Epub Date] |.
- [59] Medeiros FA, Zangwill LM, Bowd C, et al. Comparison of the GDx VCC scanning laser polarimeter, HRT II confocal scanning laser ophthalmoscope, and stratus OCT optical coherence tomograph for the detection of glaucoma. *Archives of ophthalmology* 2004;122(6):827-37 doi: 10.1001/archophth.122.6.827[published Online First: Epub Date] |.
- [60] Gunvant P, Zheng Y, Essock EA, et al. Comparison of shape-based analysis of retinal nerve fiber layer data obtained From OCT and GDx-VCC. *Journal of glaucoma* 2009;18(6):464-71 doi: 10.1097/IJG.0b013e31818c6f2b[published Online First: Epub Date] |.
- [61] Kanamori A, Nagai-Kusuhara A, Escano MF, et al. Comparison of confocal scanning laser ophthalmoscopy, scanning laser polarimetry and optical coherence tomography to discriminate ocular hypertension and glaucoma at an early stage. *Graefe's archive for clinical and experimental ophthalmology=Albrecht von Graefes Archiv fur klinische und experimentelle Ophthalmologie* 2006;244(1):58-68 doi: 10.1007/s00417-005-0029-0[published Online First: Epub Date] |.
- [62] Leung CK, Chan WM, Chong KK, et al. Comparative study of retinal nerve fiber layer measurement by StratusOCT and GDx VCC, I: correlation analysis in glaucoma. *Investigative ophthalmology & visual science* 2005;46(9):3214-20 doi: 10.1167/iovs.05-0294[published Online First: Epub Date] |.
- [63] Bowd C, Balasubramanian M, Weinreb RN, et al. Performance of confocal scanning laser tomograph Topographic Change Analysis (TCA) for assessing glaucomatous progression. *Investigative ophthalmology & visual science* 2009;50(2):691-701 doi: 10.1167/iovs.08-2136[published Online First: Epub Date] |.
- [64] Chauhan BC, McCormick TA, Nicolela MT, et al. Optic disc and visual field changes in a prospective longitudinal study of patients with glaucoma: comparison of scan-

ning laser tomography with conventional perimetry and optic disc photography. *Archives of ophthalmology* 2001;119(10):1492-9

- [65] Alencar LM, Zangwill LM, Weinreb RN, et al. Agreement for detecting glaucoma progression with the GDx guided progression analysis, automated perimetry, and optic disc photography. *Ophthalmology* 2010;117(3):462-70 doi: 10.1016/j.opthta.2009.08.012[published Online First: Epub Date] |.
- [66] Grewal DS, Sehi M, Greenfield DS. Detecting glaucomatous progression using GDx with variable and enhanced corneal compensation using Guided Progression Analysis. *The British journal of ophthalmology* 2011;95(4):502-8 doi: 10.1136/bjo.2010.180810[published Online First: Epub Date] |.
- [67] Kjaergaard SM, Alencar LM, Nguyen B, et al. Detection of retinal nerve fibre layer progression: comparison of the fast and extended modes of GDx guided progression analysis. *The British journal of ophthalmology* 2011;95(12):1707-12 doi: 10.1136/bjophthalmol-2011-300354[published Online First: Epub Date] |.
- [68] Kanamori A, Nakamura M, Tomioka M, et al. Structure-function relationship among three types of spectral-domain optical coherent tomography instruments in measuring parapapillary retinal nerve fibre layer thickness. *Acta ophthalmologica* 2013;91(3):e196-202 doi: 10.1111/aos.12028[published Online First: Epub Date] |.
- [69] 69. Lamparter J, Russell RA, Schulze A, et al. Structure-function relationship between FDF, FDT, SAP, and scanning laser ophthalmoscopy in glaucoma patients. *Investigative ophthalmology & visual science* 2012;53(12):7553-9 doi: 10.1167/iovs.12-10892[published Online First: Epub Date] |.
- [70] 70. Medeiros FA, Zangwill LM, Bowd C, et al. The structure and function relationship in glaucoma: implications for detection of progression and measurement of rates of change. *Investigative ophthalmology & visual science* 2012;53(11):6939-46 doi: 10.1167/iovs.12-10345[published Online First: Epub Date] |.
- [71] Naghizadeh F, Garas A, Vargha P, et al. Structure-Function Relationship Between the Octopus Perimeter Cluster Mean Sensitivity and Sector Retinal Nerve Fiber Layer Thickness Measured With the RTVue Optical Coherence Tomography and Scanning Laser Polarimetry. *Journal of glaucoma* 2012 doi: 10.1097/IJG.0b013e318264cda2[published Online First: Epub Date] |.
- [72] Park HY, Park CK. Structure-function relationship and diagnostic value of RNFL Area Index compared with circumpapillary RNFL thickness by spectral-domain OCT. *Journal of glaucoma* 2013;22(2):88-97 doi: 10.1097/IJG.0b013e318231202f[published Online First: Epub Date] |.
- [73] Sato S, Hirooka K, Baba T, et al. Correlation Between the Ganglion Cell-Inner Plexiform Layer Thickness Measured With Cirrus HD-OCT and Macular Visual Field Sensitivity Measured With Microperimetry. *Investigative ophthalmology & visual*

science 2013;54(4):3046-51 doi: 10.1167/iovs.12-11173[published Online First: Epub Date] |.

- [74] Werkmeister RM, Cherecheanu AP, Garhofer G, et al. Imaging of retinal ganglion cells in glaucoma: pitfalls and challenges. Cell and tissue research 2013 doi: 10.1007/s00441-013-1600-3[published Online First: Epub Date] |.

IntechOpen

IntechOpen

