

We are IntechOpen, the world's leading publisher of Open Access books Built by scientists, for scientists

6,900

Open access books available

186,000

International authors and editors

200M

Downloads

Our authors are among the

154

Countries delivered to

TOP 1%

most cited scientists

12.2%

Contributors from top 500 universities



WEB OF SCIENCE™

Selection of our books indexed in the Book Citation Index
in Web of Science™ Core Collection (BKCI)

Interested in publishing with us?
Contact book.department@intechopen.com

Numbers displayed above are based on latest data collected.
For more information visit www.intechopen.com



Groin Pain in Athletes — Sports Hernia and Osteitis Pubis

Baki Ekçi and Tahsin Beyzadeoglu

Additional information is available at the end of the chapter

<http://dx.doi.org/10.5772/58621>

1. Introduction

Sport is all forms of usually competitive physical activity. This intense activity might result with injuries associated with the overload to the muscles and joints. During competitive sports activities made under tough conditions, the load over the groin is often excessive. It was suggested that groin injuries are more common in sports that require repetitive fast twisting and turning movements (eg, soccer and hockey). It is caused by muscular imbalances and weaknesses that result in an uneven distribution of forces. In this chapter, common reasons for the groin pain in athletes, namely sports hernia and osteitis pubis will be extensively reviewed and discussed.

It is estimated that groin pain occurs in 5% to 28% of athletes [1]. On the other hand, activity restricting lower abdomen and groin pain is frequent in some sports, such as soccer, accounting for 10% to 13% of all injuries per year [2]. The prevalence of groin pain may be higher in some types of sports activities involving repeated kicking and rapid change of direction, such as soccer, tennis, football, and ice and field hockey. In these higher competitive sports, the incidence may rise to 5–7% of all injuries [3]. The patients presenting with groin pain are usually highly competitive athletes pushing the limits, runners and players who are willing to achieve college auditions or top league. This is a common problem that can be career-limiting or career ending for a player and remains a serious clinical challenge for the sports physician and treating surgeon.

The most common causes of groin pain in athletes are injuries to the adductor longus, iliopsoas, and rectus femoris muscles and injury to the inguinal floor. These conditions may cause hyperextension injury, insertion tendinitis and direct hernia or bulge. Other causes of groin pain include ilioinguinal neuralgia, osteitis pubis, genitourinary sources (prostatitis, epididymitis, urethritis, and hydrocele), nerve compression, bursitis, and arthritis of the hip.

Sports hernia is the overflow of the internal organs and intestine through a particular weak point. This condition is not a complete herniation. However, due to the overuse of the muscles, this pushing movement might cause recurring pain at that area. Since, this condition occurs at every repeating movement, the athlete will eventually avoid making such movements thereby exerting negative influence on his performance. So-called Gilmore's groin, athletic pubalgia, sports hernia, incipient hernia, and posterior abdominal wall deficiency, the term "sports hernia" (athletic pubalgia), is described as a condition of chronic exercise-related supra-inguinal groin pain, which is associated with an incipient direct bulge of the inguinal wall whenever the abdominal muscles contract forcefully. Sports hernia is also termed as external oblique tear-occult hernia, nonspecific attenuation of the inguinal floor with cord lipoma, internal ring weakness, occult hernia, not true hernia-injury at the rectus insertion, muscular injury due to overexertion of the inguinal region, medial inguinal floor injury, deficiency of the posterior inguinal wall [4-11]. This condition has been poorly understood by the clinicians [12-15].

First described by Beer in 1924, osteitis pubis is a noninfectious, self-limited inflammatory condition of the symphysis pubis involving the adjoining pubic bones, the perichondrium, and the periosteum [16-19]. Osteitis pubis is known as one of the causes of groin pain, which is associated with the overuse related to kicking and running resulting in shearing stress at the symphysis. Thus, it is very common among athletes. It is also typical in sports comprising a lot of sprinting and sudden changes of direction, such as running, basketball, soccer, ice hockey, and tennis [20, 21]. On the other hand, it has been reported to complicate a variety of pelvic surgeries, including abdominoperineal resection, inguinal herniorrhaphy, endoscopic resection of the prostate, after anterior colporrhaphy, retropubic urethropexy, even after periurethral collagen injection and endoscopic inguinal hernia repair resulting from attachment of the stapler to os pubis [22, 23].

The clinician must also consider that athletes with groin pain may have other orthopaedic and nonorthopaedic potential causes of the groin pain. The differential diagnosis is various. Muscle strain (adductor, rectus, iliopsoas), osteitis pubis, stress fracture, avulsion fracture, hip joint injury, nerve entrapment, and lumbar radiculopathy can be orthopaedic problems, such as classic hernia, appendicitis, diverticulitis, irritable bowel syndrome, adhesions, urinary tract infection, prostatitis, testicular pain, varicoceles, endometriosis, ovarian cyst, and round ligament entrapment can be non-orthopaedic conditions [24, 25].

2. Mechanism of injury

The aetiology of both conditions has not been completely understood. However, excessive physical activity is assumed as the etiological factor since these conditions are quite common among athletes. Athletes with a previous groin injury history, elder athletes, players having inactive periods out of the season, and the players making sports involving only a particular part of their muscles have a higher risk [26, 27]. Various factors have been suggested for the mechanism of sports hernia. Athletic pubalgia is described as an occult hernia process or an

incipient hernia, with the major abnormality being a defect in the transversalis fascia, which forms the posterior wall of the inguinal canal, and not a muscle tear [2] (Figure 1).

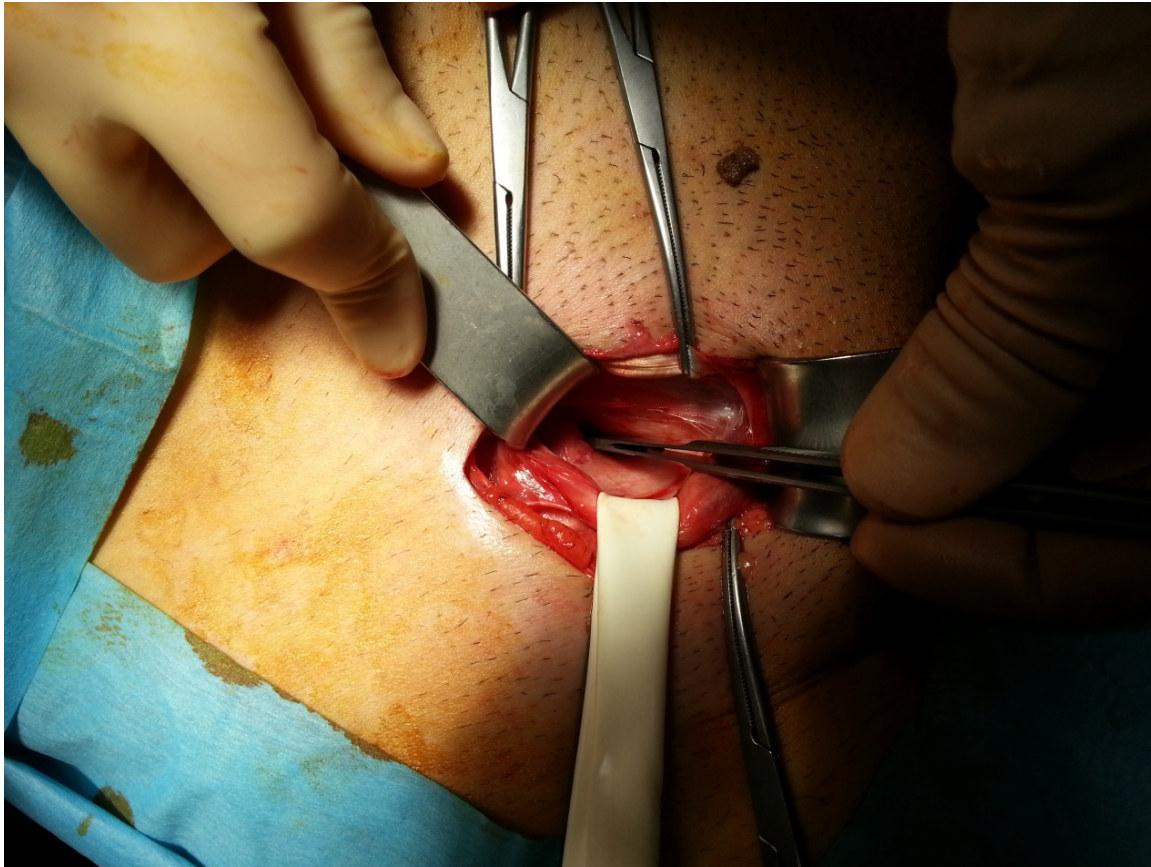


Figure 1. Abnormality being a defect in the transversalis fascia

Gilmore proposed a mechanism of injury in athletic pubalgia, that was a tear in external oblique aponeurosis, conjoined tendon tears from pubic tubercle and conjoined tendon splits from inguinal ligament (7, 28, 29). Furthermore, Meyers et al. [30] suggested that the primary mechanism for most of these injuries involves hyperextension of the abdomen and/or hyperabduction of the thigh, and the pain occurs primarily with exertion, often in multiple locations, rarely involving the internal ring. The cutaneous nerves include the iliohypogastric nerve (sensory to the lower abdomen), the ilioinguinal nerve (sensory to the groin), and the genital branch of the genitofemoral nerve (sensory to the scrotum and labia)[24]. Muschawek reported that posterior inguinal swelling exerts pressure on genital nerve and this might cause pain [7, 31]. This nerve irritation produces a dull or burning pain that radiates into the inner thigh or scrotum. In addition, external oblique defects traumatize ilioinguinal and iliohypogastric nerves resulting with inguinal pain [30, 32] (Figure 2). As it is understood, this condition cannot be explained with only one mechanism. Muscular imbalances in high performance athletes, coordination disorders, excess weight and continuous training, irregular training are among important factors resulting with groin pain.

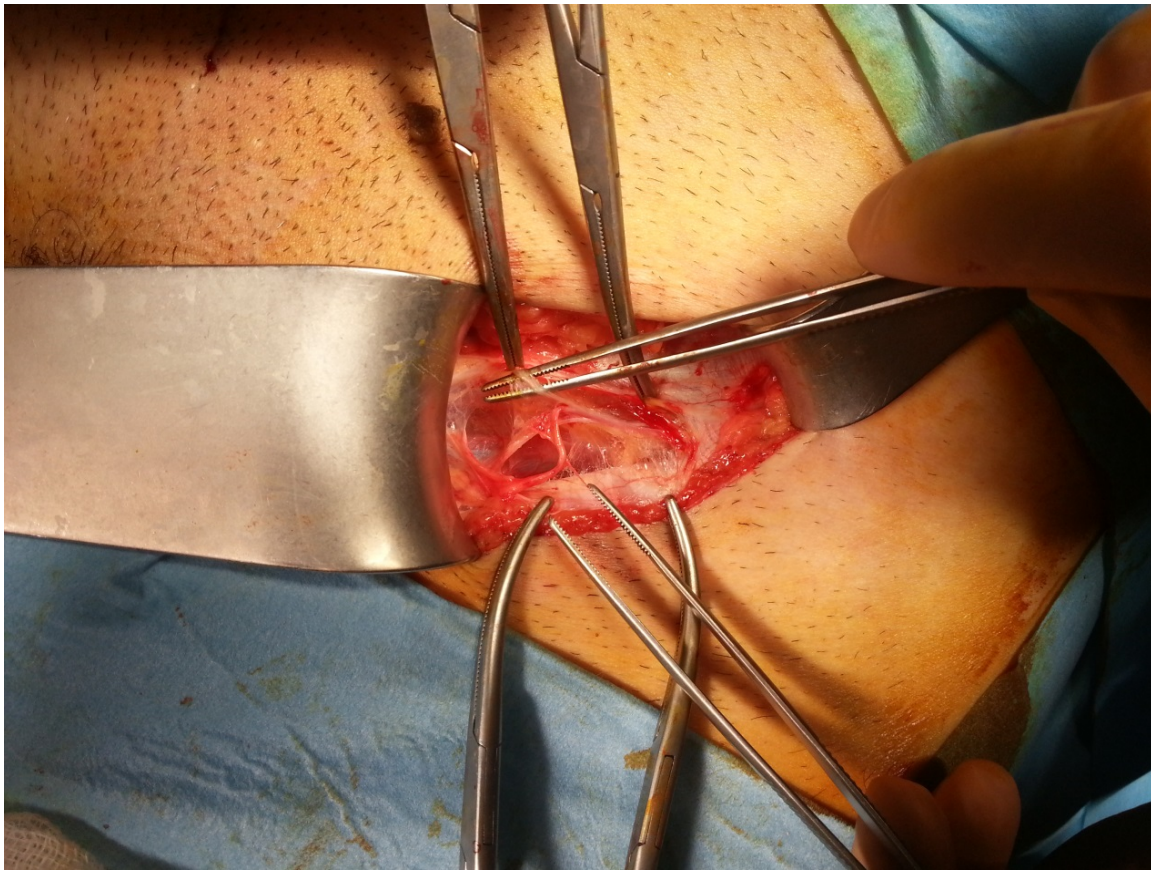


Figure 2. External oblique defects traumatize ilioinguinal and iliohypogastric nerves resulting with inguinal pain

The symphysis pubis is a nonsynovial-lined, amphiarthrodial joint located between the two pubic bones. Biomechanical analysis of the pelvis has revealed that the innominate bones function as arches, thus transferring the weight of the upright trunk from the sacrum to the hips. The exact cause of this condition is unclear; however, it appears that the overuse related to kicking and running results in shearing stress at the symphysis. Traction, micro trauma and instability of the sacroiliac joint and symphysis pubis can be the possible causes of osteitis [19, 33]. The four main hypotheses for the cause of postoperative osteitis pubis include trauma, impaired vascular circulation, trophic bone changes related to a causalgia-like mechanism and infection [17, 20, 34]. Osteitis pubis is the result of intraoperative trauma to the symphysis and its muscular attachments either from surgical instruments or retractors [16, 22, 34]. In Marshall-Marchetti-Krantz procedure, in which sutures are placed directly into the periosteum or cartilage of the symphysis pubis, osteitis pubis is uncommon [35, 36].

3. Physical examination

In sports hernia, moderate pain and discomfort in the region of inguinal area associated with exertion, sneezing and coughing are mostly noted. These are usually abated with rest. The presenting symptom develops during exercise, aggravated by sudden movements. Pain

persists after a game, abates during a period of lay-off, but returns on the resumption of sport [37]. In physical examination, physician should evaluate inguinal hernia, pubis, rectus abdominis, hips and adductor muscles. In addition, local tenderness at the conjoined tendon, pubic tubercle, or inguinal canal might be observed. On examination, the athlete usually has pain with passive stretch of the adductors and pain on adduction against resistance. The athlete will often have pain with resisted sit-ups and resisted hip adduction [37]. Coughing, sneezing, and other Valsalva-type maneuvers often worsen the pain. Over the conjoined tendon or medial inguinal canal, the distal rectus insertion, pubic tubercle, and/or adductor origin points are tenderness [38]. The most common finding is a dilated, tender internal inguinal ring, true inguinal hernia is rarely found (1, 6, 10). But, the physician should exclude the presence of an inguinal or femoral hernia. The onset of complaints, the types of movements causing pain, measures for avoiding pain, time of resting and acts for coping with pain should be learned in details. A true herniation is rarely seen in this group of patients; the base of inguinal canal is weakly detected and might be sensitive [39, 40].

The diagnosis of osteitis pubis is based on typical clinical symptoms and abnormal radiographic findings. Common clinical symptoms are suprapubic pain, difficulty, and pain with ambulation. Pain can occur while walking, radiating to the perineal, suprapubic region [41, 42]. The anterior portion of the pelvis and the adductor muscles are tender and spasm may accompany. Pain is usually radiates to the suprapubic area and the adductor surfaces of the thighs and it usually begins ten days to two months after an operation upon the urinary bladder [43]. Pain is the primary symptom associated typically with difficulty in ambulation and the characteristic "waddling gait" [42, 44]. Symptoms may develop from 1 to 8 weeks after the initiating event. The duration of the signs and symptoms is related to the severity of the inflammation and the response to therapy after the appropriate diagnosis is established [42]. Laboratory findings may be mild leucocytosis, raised levels of acute phase proteins (fibrinogen, C reactive protein), and increased erythrocyte sedimentation rate.

4. Diagnostic test

Diagnostic tests are required to rule out other pathologies associated with lower abdominal, hip or groin pain. After a complete history and physical exam, the patient should have a complete blood count, urinalysis, and ultrasound of the groin firstly. Diagnostic imaging includes an erect pelvic radiograph (X-ray) with flamingo stress views of the symphysis pubis, real-time ultrasound and, occasionally, computed tomography (CT) scanning and magnetic resonance imaging (MRI), but seldom contrast herniography [25, 37]. The patient is examined with USG while lying in a supine position. A high-resolution linear array transducer of 10 MHz or greater frequency is recommended [15]. Other imaging tests occasionally performed can include nuclear bone scan, limb leg measurement.

A standard athletic pubalgia protocol includes coronal and axial large field-of-view fluid-sensitive, fat-suppressed images that should adequately cover this region and identify the injury and this MRI protocol is generally adequate [45]. Stress fractures, tendon avulsion and

hip arthrosis might be detected by x-ray, and ultrasound might show incipient inguinal hernia. If physician suspect bone tumours, hip ring pathologies, spine or retroperitoneal problems may want to see CT. Hip problems and bursitis, MRI be the best choice in determination of aetiology of inguinal pain in sports but it may be normal in sport's hernia [45]. Pelvic MRI might give more detailed information regarding the condition of pelvis and soft tissue, alterations due to edema and stress, muscle tears, adductor muscle groups, and the location of pubis muscle insertions. An advantage of USG assessment is that this method may show the dynamic movements of inguinal floor with the help of Valsalva maneuver. If the results of these tests are negative and the symptoms continue with sports hernia symptoms, a laparoscopic preperitoneal exploration might be carried out [11].

Early in the course of osteitis pubis, radiographs are typically normal [19]. After approximately 6 months, x-rays of the symphysis may show a frayed appearance of the pubic periosteum, loss of cortex, widening, erosions, and sclerosis along the articular border [15, 35]. These findings included erosion, rarefaction, resorption, and sclerosis of the pubic bones. In its early stages, osteomyelitis presents similarly to osteitis pubis and its make the diagnosis difficulty. Close monitoring of patients diagnosed with osteitis pubis is recommended in these patients. If a question about the diagnosis exists, computed tomography-guided pubic bone aspiration for culture is advocated [22]. The athletes who have this disease with normal AP radiographs had bone scans that demonstrated increased radiotracer (^{99m}Tc) uptake throughout the area of the symphysis pubis as a characteristic of osteitis pubis. A bone scan, which is more sensitive than radiography, usually shows the increased uptake in the pubic bones on both sides of the symphysis and pubic ramus, often before any radiographic changes are seen [46, 47] [48]. MRI and computed tomography scans can show inflammatory changes in the bone. MRI illustrates joint-space alteration, articular surface irregularity, para-articular marrow edema and extrusions of the symphyseal disk and includes low intensity signal on T1 weighted and a high intensity signal on T2 weighted images [49]. Sclerosis has low intensity signal on both T1 and T2 weighted images [50]. (Figure 3) High-resolution MRI and ultrasound may identify subtle tears and defects within one or more of the structures that inserts around the groin region [15]. MRI appearances in osteomyelitis and osteitis are similar in the initial stages. Both osteitis pubis, an inflammatory disease, and osteomyelitis, an infectious disease, can appear in one patient at the same time. In these cases, biopsy and culture may be necessary to make a differential diagnosis [18, 49].

MRI and ultrasound (US) can be used to exclude co-existing abnormalities in the patients undergoing a groin repair. Bilateral abdominal abnormalities on ultrasound may appear to be a valid marker for inguinal pain and the anatomic injury [51]. According to the location and morphology of the patient medium to high-frequency linear probes can use and colour Doppler examination may be useful. Investigation carried out in dynamic conditions (coughing and the Valsalva maneuver) may important. Additionally US can show the reinforcement positioned in the area of wall weakness after surgery [52]. Posterior inguinal wall deficiency can be demonstrated sonographically, as the contraction of the anterior abdominal wall results in loss of the normal valve-like effect of the canal [15] (Figure 4).

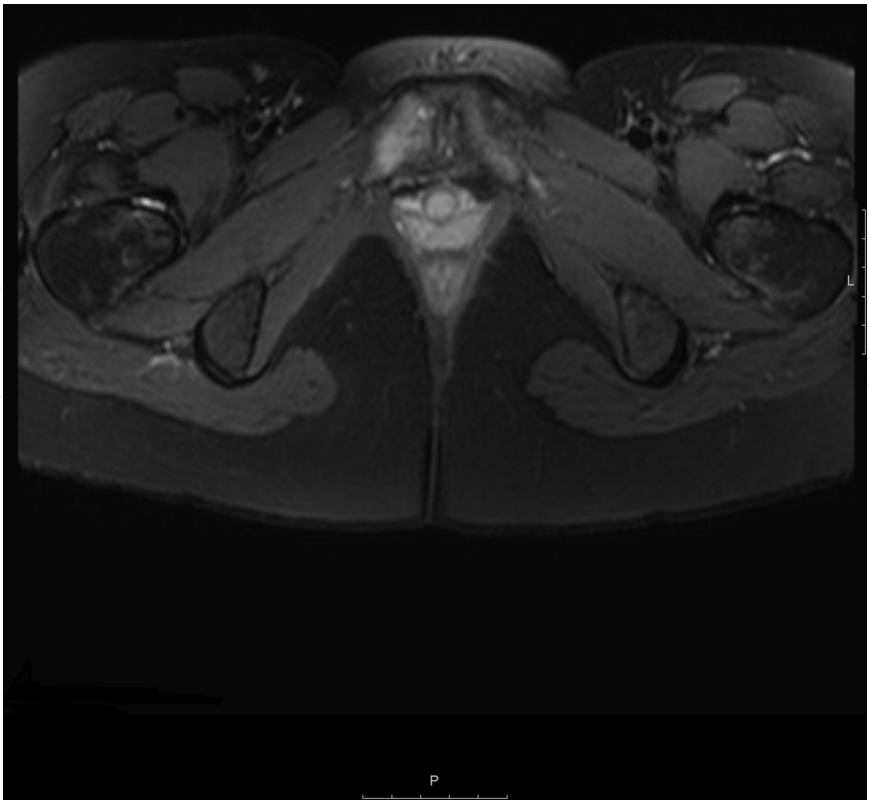

Figure 3. MRI illustrates joint-space alteration, articular surface irregularity, para-articular marrow edema and extrusions of the symphyseal disk and includes low intensity signal on T1 weighted and a high intensity signal on T2 weighted images. Osteitis pubis on the right pubic bone.

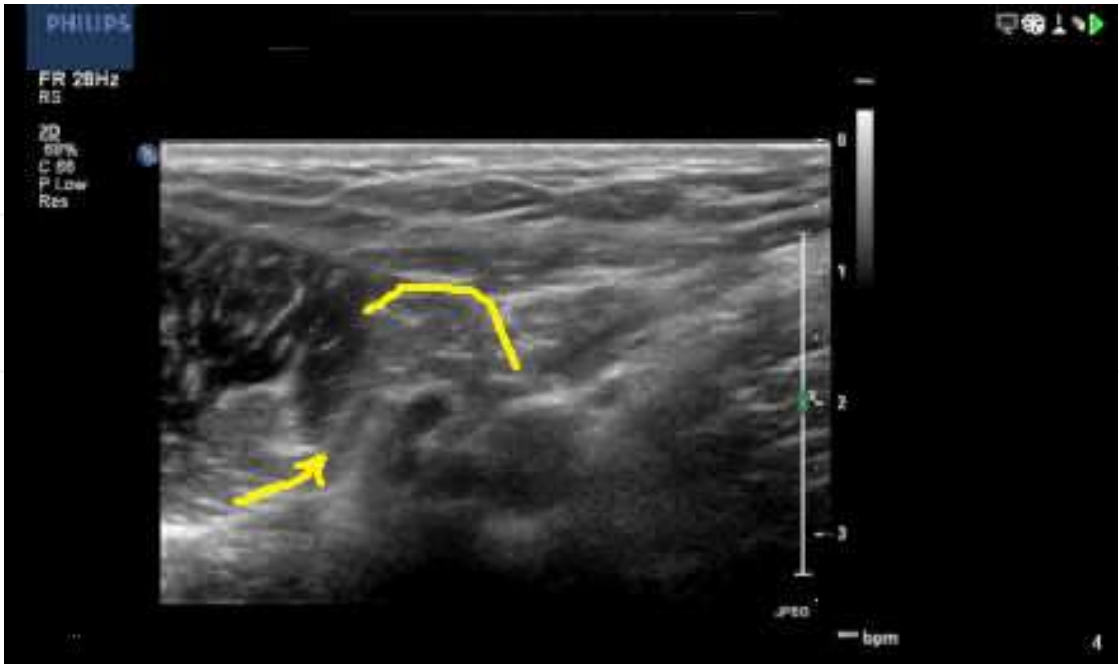


Figure 4. Posterior inguinal wall deficiency can be demonstrated sonographically

5. Management

In both conditions, the first treatment choice is resting and standard conservative treatment. In sports hernia, it is important to determine the movements causing symptoms and avoiding them. Conservative treatments are effective in relieving pain and returning the athlete to normal sports activities. This approach might involve the application of heat or ice, stretching and strengthening exercises, analgesic medications and other physical-therapy interventions. In elective cases, the use of corticosteroids and local analgesics might relieve symptoms. If the symptoms are relieved and under control, slight lower body exercises might be started. This period may last for 6-8 weeks, or occasionally 10 weeks. There is still no consensus on the surgical treatment techniques. Open primary repair, open mesh repair, laparoscopic mesh repair, neurectomy, and adductor tendon relaxation are among the surgical techniques [24]. Mesh repair technique is so-called Lichtenstein hernia repair. In open repair, Muschawek technique, also called minimal repair might be used [24, 31]. A number of different modified repairs of the posterior wall deficiency have also been described [30, 37]. Groin reconstruction operation consists of a Maloney darn hernia repair technique, repair of the conjoint tendon, transverse adductor tenotomy and obturator nerve release [37]. Laparoscopic mesh repair technique is also used. In this technique, synthetic and biological meshes, which have been advocated to reinforce the posterior wall of the inguinal canal, are preferred [53, 54]. Rehabilitation treatment is important in the post-operative course. On the other hand, sutureless tension-free hernia repair with fibrin glue may be the choose for treatment of hernia[55] Rehabilitation programs in which activities are gradually increased in the 5-8 weeks period are utilized. Specific rehabilitation targeted at abdominal strengthening, adductor muscle flexibility, and a graduated return to activity. Rehabilitation may takes about 3 months after surgery [24, 37, 56].

Management of osteitis pubis can be difficult; whether to make conservative treatment or surgical intervention is controversial. Conservative treatment usually involves rest, oral medication with non-steroidal anti-inflammatory drugs, daily use of therapeutic modalities a progressive rehabilitation programme [57-59]. Earlier return to full activity has been reported injection of corticosteroid and local anaesthetic [21, 60]. Complete recovery can take over a few months. Curettage, arthrodesis, wedge resection and wide resection are described for surgical intervention of osteitis pubis [41, 61].

In conclusion, sports hernia and osteitis pubis are particularly common among athletes making sports with excessive load on their muscles that may compromise their professional careers. Being cautious while training and making exercises might be helpful at preventing such injuries. The diagnosis of these conditions might be easily mixed up with the other causes of groin pain. Treatment is substantially conservative or surgical intervention might be preferred in some cases if required.

Author details

Baki Ekçi¹ and Tahsin Beyzadeoglu²

1 Yeditepe University, Medical School, Department of General Surgery, Istanbul, Turkey

2 Private Practice of Orthopedics and Traumatology, Beyzadeoglu Sports Medicine Clinic, Istanbul, Turkey

References

- [1] Nam A, Brody F. Management and therapy for sports hernia. *Journal of the American College of Surgeons*. 2008;206(1):154-64.
- [2] Litwin DE, Sneider EB, McEnaney PM, Busconi BD. Athletic pubalgia (sports hernia). *Clinics in sports medicine*. 2011;30(2):417-34.
- [3] Kavanagh EC, Koulouris G, Ford S, McMahon P, Johnson C, Eustace SJ. MR imaging of groin pain in the athlete. *Seminars in musculoskeletal radiology*. 2006;10(3):197-207.
- [4] Fon LJ, Spence RA. Sportsman's hernia. *The British journal of surgery*. 2000;87(5):545-52.
- [5] Ahumada LA, Ashruf S, Espinosa-de-los-Monteros A, Long JN, de la Torre JI, Garth WP, et al. Athletic pubalgia: definition and surgical treatment. *Annals of plastic surgery*. 2005;55(4):393-6.
- [6] Farber AJ, Wilckens JH. Sports hernia: diagnosis and therapeutic approach. *The Journal of the American Academy of Orthopaedic Surgeons*. 2007;15(8):507-14.
- [7] Muschaweck U, Berger LM. Sportsmen's Groin-Diagnostic Approach and Treatment With the Minimal Repair Technique: A Single-Center Uncontrolled Clinical Review. *Sports health*. 2010;2(3):216-21.
- [8] Paajanen H, Ristolainen L, Turunen H, Kujala UM. Prevalence and etiological factors of sport-related groin injuries in top-level soccer compared to non-contact sports. *Archives of orthopaedic and trauma surgery*. 2011;131(2):261-6.
- [9] Paajanen H. ["Sports hernia" and osteitis pubis in an athlete]. *Duodecim; laaketieteellinen aikakauskirja*. 2009;125(3):261-6.
- [10] Diesen DL, Pappas TN. Sports hernias. *Advances in surgery*. 2007;41:177-87.
- [11] Edelman DS, Selesnick H. "Sports" hernia: treatment with biologic mesh (Surgisis): a preliminary study. *Surgical endoscopy*. 2006;20(6):971-3.

- [12] Akita K, Niga S, Yamato Y, Muneta T, Sato T. Anatomic basis of chronic groin pain with special reference to sports hernia. *Surgical and radiologic anatomy* : SRA. 1999;21(1):1-5.
- [13] Brown A, Abrahams S, Remedios D, Chadwick SJ. Sports hernia: a clinical update. *The British journal of general practice : the journal of the Royal College of General Practitioners*. 2013;63(608):e235-7.
- [14] Shortt CP, Zoga AC, Kavanagh EC, Meyers WC. Anatomy, pathology, and MRI findings in the sports hernia. *Seminars in musculoskeletal radiology*. 2008;12(1):54-61.
- [15] Davies AG, Clarke AW, Gilmore J, Wotherspoon M, Connell DA. Review: imaging of groin pain in the athlete. *Skeletal radiology*. 2010;39(7):629-44.
- [16] Beer E. Periostitis of the symphysis and descending rami of the pubis following suprapubic operations. *Int J Med Surg*. 1924;37:224-5.
- [17] Cibert J. Post-operative osteitis pubis: causes and treatment. *British journal of urology*. 1952;24(3):213-5.
- [18] Gibbon WW, Hession PR. Diseases of the pubis and pubic symphysis: MR imaging appearances. *AJR American journal of roentgenology*. 1997;169(3):849-53.
- [19] Middleton RG, Carlile RG. The spectrum of osteitis pubis. *Comprehensive therapy*. 1993;19(3):99-102.
- [20] Fricker PA, Taunton JE, Ammann W. Osteitis pubis in athletes. Infection, inflammation or injury? *Sports medicine*. 1991;12(4):266-79.
- [21] Holt MA, Keene JS, Graf BK, Helwig DC. Treatment of osteitis pubis in athletes. Results of corticosteroid injections. *The American journal of sports medicine*. 1995;23(5):601-6.
- [22] Frederick RW, Carey JM, Leach GE. Osseous complications after transvaginal bone anchor fixation in female pelvic reconstructive surgery: report from single largest prospective series and literature review. *Urology*. 2004;64(4):669-74.
- [23] Karray S, Karray M, Zlith M, Bahri H, Litaïem T, Douik M, et al. [Pubic osteitis after treatment for inguinal hernia. Apropos of 2 cases]. *Annales de chirurgie*. 1995;49(1):78.
- [24] Minnich JM, Hanks JB, Muschaweck U, Brunt LM, Diduch DR. Sports hernia: diagnosis and treatment highlighting a minimal repair surgical technique. *The American journal of sports medicine*. 2011;39(6):1341-9.
- [25] Swan KG, Jr., Wolcott M. The athletic hernia: a systematic review. *Clinical orthopaedics and related research*. 2007;455:78-87.
- [26] Emery CA, Meeuwisse WH. Risk factors for groin injuries in hockey. *Medicine and science in sports and exercise*. 2001;33(9):1423-33.

- [27] Tyler TF, Nicholas SJ, Campbell RJ, McHugh MP. The association of hip strength and flexibility with the incidence of adductor muscle strains in professional ice hockey players. *The American journal of sports medicine*. 2001;29(2):124-8.
- [28] Gilmore J. Groin pain in the soccer athlete: fact, fiction, and treatment. *Clinics in sports medicine*. 1998;17(4):787-93, vii.
- [29] Sheen AJ, Stephenson BM, Lloyd DM, Robinson P, Fevre D, Paajanen H, et al. 'Treatment of the Sportsman's groin': British Hernia Society's 2014 position statement based on the Manchester Consensus Conference. *British journal of sports medicine*. 2013.
- [30] Meyers WC, Foley DP, Garrett WE, Lohnes JH, Mandlebaum BR. Management of severe lower abdominal or inguinal pain in high-performance athletes. PAIN (Performing Athletes with Abdominal or Inguinal Neuromuscular Pain Study Group). *Am J Sports Med*. 2000;28(1):2-8.
- [31] Muschaweck U, Berger L. Minimal Repair technique of sportsmen's groin: an innovative open-suture repair to treat chronic inguinal pain. *Hernia : the journal of hernias and abdominal wall surgery*. 2010;14(1):27-33.
- [32] Irshad K, Feldman LS, Lavoie C, Lacroix VJ, Mulder DS, Brown RA. Operative management of "hockey groin syndrome": 12 years of experience in National Hockey League players. *Surgery*. 2001;130(4):759-64; discussion 64-6.
- [33] Harris NH, Murray RO. Lesions of the symphysis in athletes. *British medical journal*. 1974;4(5938):211-4.
- [34] Lavalley LL, Hamm F. Osteitis pubis: its etiology and pathology. *The Journal of urology*. 1951;66(3):418-32.
- [35] Kammerer-Doak DN, Cornella JL, Magrina JF, Stanhope CR, Smilack J. Osteitis pubis after Marshall-Marchetti-Krantz urethropexy: a pubic osteomyelitis. *American journal of obstetrics and gynecology*. 1998;179(3 Pt 1):586-90.
- [36] Garcia-Porrua C, Picallo JA, Gonzalez-Gay MA. Osteitis pubis after Marshall-Marchetti-Krantz urethropexy. *Joint, bone, spine : revue du rhumatisme*. 2003;70(1):61-3.
- [37] Garvey JF, Read JW, Turner A. Sportsman hernia: what can we do? *Hernia : the journal of hernias and abdominal wall surgery*. 2010;14(1):17-25.
- [38] Caudill P, Nyland J, Smith C, Yerasimides J, Lach J. Sports hernias: a systematic literature review. *British journal of sports medicine*. 2008;42(12):954-64.
- [39] Cavalli M, Bombini G, Campanelli G. Pubic Inguinal Pain Syndrome: the So-called Sports Hernia. *Surgical technology international*. 2014;XXIV.
- [40] Campanelli G. Pubic inguinal pain syndrome: the so-called sports hernia. *Hernia : the journal of hernias and abdominal wall surgery*. 2010;14(1):1-4.

- [41] Mehin R, Meek R, O'Brien P, Blachut P. Surgery for osteitis pubis. Canadian journal of surgery Journal canadien de chirurgie. 2006;49(3):170-6.
- [42] Lentz SS. Osteitis pubis: a review. Obstetrical & gynecological survey. 1995;50(4):310-5.
- [43] Friedenberg ZB. Osteitis pubis with involvement of the hip joint. The Journal of bone and joint surgery American volume. 1950;32(A:4):924-7.
- [44] Matsuda DK. Endoscopic pubic symphysectomy for retractor osteitis pubis associated with bilateral femoroacetabular impingement. Orthopedics. 2010;33(3).
- [45] Zoga AC, Meyers WC. Magnetic resonance imaging for pain after surgical treatment for athletic pubalgia and the "sports hernia". Seminars in musculoskeletal radiology. 2011;15(4):372-82.
- [46] Briggs RC, Kolbjornsen PH, Southall RC. Osteitis pubis, Tc-99m MDP, and professional hockey players. Clinical nuclear medicine. 1992;17(11):861-3.
- [47] Burke G, Joe C, Levine M, Sabio H. Tc-99m bone scan in unilateral osteitis pubis. Clinical nuclear medicine. 1994;19(6):535.
- [48] O'Kane JW. Anterior hip pain. American family physician. 1999;60(6):1687-96.
- [49] Pauli S, Willemsen P, Declerck K, Chappel R, Vanderveken M. Osteomyelitis pubis versus osteitis pubis: a case presentation and review of the literature. British journal of sports medicine. 2002;36(1):71-3.
- [50] Andrews SK, Carek PJ. Osteitis pubis: a diagnosis for the family physician. The Journal of the American Board of Family Practice / American Board of Family Practice. 1998;11(4):291-5.
- [51] Jansen JA, Mens JM, Backx FJ, Stam HJ. Diagnostics in athletes with long-standing groin pain. Scandinavian journal of medicine & science in sports. 2008;18(6):679-90.
- [52] Balconi G. US in pubalgia. Journal of ultrasound. 2011;14(3):157-66.
- [53] Ingoldby CJ. Laparoscopic and conventional repair of groin disruption in sportsmen. The British journal of surgery. 1997;84(2):213-5.
- [54] Genitsaris M, Goulmaris I, Sikas N. Laparoscopic repair of groin pain in athletes. The American journal of sports medicine. 2004;32(5):1238-42.
- [55] Canonico S, Benevento R, Della Corte A, Fattopace A, Canonico R. Sutureless tension-free hernia repair with human fibrin glue (tissucol) in soccer players with chronic inguinal pain: initial experience. International journal of sports medicine. 2007;28(10):873-6.
- [56] Biedert RM, Warnke K, Meyer S. Symphysis syndrome in athletes: surgical treatment for chronic lower abdominal, groin, and adductor pain in athletes. Clinical journal of

sport medicine : official journal of the Canadian Academy of Sport Medicine. 2003;13(5):278-84.

- [57] Sudarshan A. Physical therapy management of osteitis pubis in a 10-year-old cricket fast bowler. *Physiotherapy theory and practice*. 2013;29(6):476-86.
- [58] Jarosz BS. Individualized multi-modal management of osteitis pubis in an Australian Rules footballer. *Journal of chiropractic medicine*. 2011;10(2):105-10.
- [59] Holmich P, Uhrskou P, Ulnits L, Kanstrup IL, Nielsen MB, Bjerg AM, et al. Effectiveness of active physical training as treatment for long-standing adductor-related groin pain in athletes: randomised trial. *Lancet*. 1999;353(9151):439-43.
- [60] Batt ME, McShane JM, Dillingham MF. Osteitis pubis in collegiate football players. *Medicine and science in sports and exercise*. 1995;27(5):629-33.
- [61] Radic R, Annear P. Use of pubic symphysis curettage for treatment-resistant osteitis pubis in athletes. *The American journal of sports medicine*. 2008;36(1):122-8.

