

We are IntechOpen, the world's leading publisher of Open Access books Built by scientists, for scientists

6,900

Open access books available

185,000

International authors and editors

200M

Downloads

Our authors are among the

154

Countries delivered to

TOP 1%

most cited scientists

12.2%

Contributors from top 500 universities



WEB OF SCIENCE™

Selection of our books indexed in the Book Citation Index
in Web of Science™ Core Collection (BKCI)

Interested in publishing with us?
Contact book.department@intechopen.com

Numbers displayed above are based on latest data collected.
For more information visit www.intechopen.com



Keratitis — A Clinical Approach

Patricio A. Pacheco

Additional information is available at the end of the chapter

<http://dx.doi.org/10.5772/58411>

1. Introduction

Any inflammatory reaction of the cornea of the eye is known as keratitis. The concept originates from the Greek word “κέρας-(kerat)” that means “horn” and “itis” which represents the classical suffix in medicine for inflammation. Since early civilization, the cornea was considered to be “strong as a horn”. Its highly complex, almost indestructible, collagen conformation gives it strong physical properties that made the ancients to name it like that.

Keratitis is a frequent clinical condition. A correct initial diagnosis and treatment are critical in limiting the amount of residual damage and scarring left to the cornea, as the preservation of its transparent property is critical in the recovery and maintenance of useful vision in any affected patient.

In the present chapter a description of the clinical findings in different forms of keratitis, intend to illustrate ophthalmic practitioners with the different potential diagnosis associated to this condition and through this, to orientate them in the useful investigations that will lead to the correct diagnosis.

2. Anatomy and physiology

The cornea has five layers: a superficial one called “epithelial”, an intermediate one or “stromal”, an internal named “endothelial” and two limiting membranes: Bowman’s and Descemet’s (Fig.1). Each of these layers is conformed by different structures and types of cells that give them unique properties and different responses when affected by disease, this difference between the layers produces an inflammatory response that is typical to each layer, with clinical findings that can orientate to the primarily affected site.

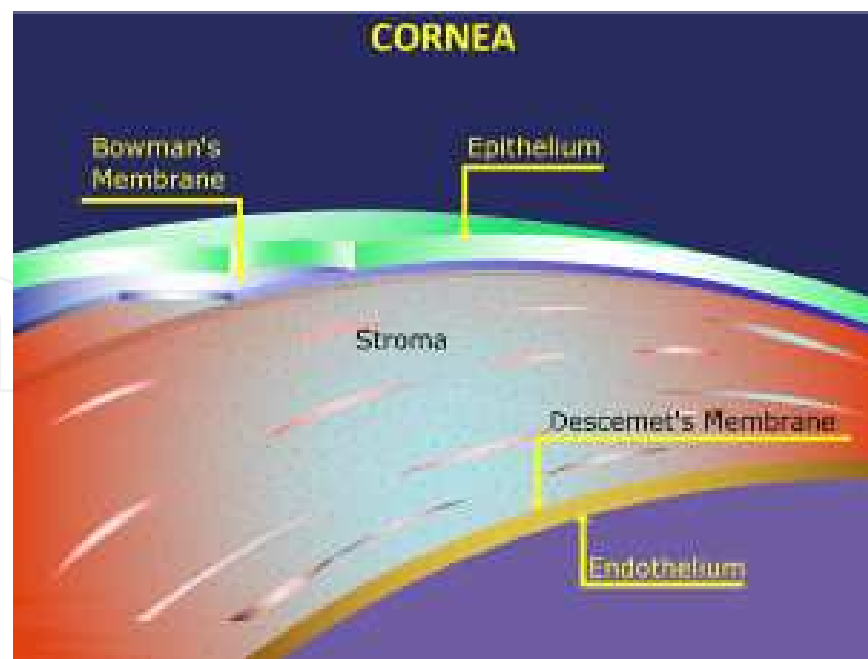


Figure 1. Corneal layers

The epithelial layer is formed by a stratified, squamous and non-keratinized epithelium that comprises a single layer of basal columnar cells attached by hemi-desmosomes to the underlying basement membrane followed by two to three rows of epithelial wing cells and two external layers of squamous surface cells which surface area is increased by microplacae and microvilli that facilitates the attachment of the mucin layer of the tear film. After a lifespan of approximately twenty-four hours the superficial cells are often shed into the tear film. The epithelial stem cells are located in the limbal region (this is the area between the cornea and the sclera), within the palisades of Vogt mainly located in the superior and inferior limbus. The indemnity of the corneal stem cells is essential for the maintenance of a healthy corneal epithelium and they also act as a barrier, preventing conjunctival epithelium from growing on to the clear cornea.

The stromal layer makes up to 90% of the corneal thickness, it is composed of regularly orientated collagen type I and V fibrils layers whose space is maintained by proteoglycan ground substance (chondroitin and keratan sulphate) with interspread modified fibroblast cells (keratocytes). The superficial portion of the stroma is called the Bowman membrane that constitutes an acellular portion of the stroma. It is, in part, the congruent and precise distribution of the collagen fibers of the stromal layer that permits the structure of the cornea to be transparent, letting the spectrum of visible light to pass through into the inner structures of the eye to finally allowing us to see.

The endothelial layer consists of a single layer of hexagonal cells that sits on a fine basal membrane made of a latticework of collagen fibers named the Descemet membrane. This layer and its indemnity is also crucial in keeping the transparency of the cornea by reducing the amount of water in the corneal stroma through an active membrane channels mechanism that

allows the movement of water from the stroma into the anterior chamber of the eye. The endothelial cells cannot regenerate as they are arrested in the G1 phase of the cell cycle; the normal adult cell density is about 2500 cells/mm², this amount of cells decreases at a rate of 0.6% per year. When the cell density falls to about 500 cells/mm², corneal edema develops and then corneal transparency is reduced.

In 2013, the Dua's layer was described for the first time. In a paper published by Dua et al., experimental and electron microscopy studies revealed the existence of a thin layer (15 microns) of corneal collagen between the corneal stroma and the Descemet membrane. This layer has physical properties that are different to the stromal layer and the Descemet membrane, having the highest resistance to pressure among the corneal layers. Its discovery has implications in corneal surgical procedures.

Macrophages and dendritic antigen presenting cells are present mainly in the epithelium and the anterior stroma. Small numbers of macrophages are also present in the posterior stroma.

The sensory innervation of the cornea derives from the trigeminal nerve (V₁) and it is mainly distributed in the sub-epithelial region and anterior stroma as sub-epithelial plexus, it is therefore at this level that we can find most nerves in the corneal structure.

3. Keratitis: Clinical history

A detailed clinical history is crucial in the diagnosis keratitis. Demographic aspects like age, sex, ethnicity and occupation are always needed and can orientate to certain specific associated pathologies or risk factors. The use of contact lenses is important to note in detail including the type of lenses, length of use, cleaning systems used and daily routines (i.e. tap water washing, swimming, etc). History of any recent injury to the eye or systemic disease that might relate to corneal compromise is also needed. History of recent infections, cold sores or flu can be helpful in orientating a diagnosis. The use of topical eye drops or any other medication needs to be recorded as the use of topical steroids, anesthetics, etc can be significant as a risk factor for infections and anatomical/ functional changes of the corneal surface.

4. Keratitis: Anatomical classification

Keratitis can be classified on the portion of the cornea affected. It is important to note that perhaps most of the cases have more than one layer involved and in some cases all three are compromised, however this classification can help the diagnosis of more pure forms of keratitis.

Epithelial: when the most superficial layer of the cornea is affected, a characteristic epithelial defect or epithelial cellular infiltrate can be seen, fluorescein staining can help in the

diagnosis, there are multiple sizes and possible shapes for both the defect and/or the infiltration. Some of the epithelial defects are pathognomonic as it is the dendriform seen in herpes simplex virus keratitis, it is therefore important to note the size, shape and depth of the defect in any epithelial form, as it will certainly help not only in the diagnosis but also in the assessment of the progression or recovery of the affected patient. In the case of the infiltrate, it is important to note the size, color and quality of the borders that can be of help in diagnosis and follow up. Any satellite lesions need also to be assessed as well as the upper and lower tarsal plates in search for any foreign bodies or other associated lesions like calcareous concretions, meibomian gland cysts, papillae or follicles. The epithelial form of keratitis is extremely painful and at times enlarged or infiltrated corneal nerves can be seen. Usually the anterior stroma is also affected with an inflammatory cellular infiltrate surrounding the epithelial lesions, it has in general poorly defined borders. Corneal pannus can be seen as a result of previous episodes of epithelial keratitis in some cases. Examples include herpetic epithelial keratitis, adenoviral keratoconjunctivitis, microbial corneal ulcers and contact lens related keratitis.

Stromal: this is the keratitis that has primarily a compromise of the corneal stroma. An associated epithelial defect may be or not detected at initial presentation. The main finding in this type of keratitis is an infiltration of the collagen layers in the stroma by inflammatory cells, this can be seen at any depth, it can be unifocal or multifocal, with many different shapes and sizes, but usually has a very well defined and regular edge. There is in general some degree of anterior chamber cell reaction and at times keratic precipitates can be seen. Thickening of the cornea is another way to appreciate the cellular infiltration seen in these cases. Examples are herpetic stromal keratitis, sclero-keratitis and fungal/atypical microorganisms' related keratitis.

Endothelial: the main structure affected in these cases is the endothelial layer. Characteristic features include keratic precipitates, descemet folds and almost invariably a significant anterior chamber cells reaction. Secondary diffuse corneal thickening at later stages can be seen as a result of impaired endothelial function. Examples include corneal graft rejection, herpetic endothelial keratitis, any form of kerato-uveitis, and post-traumatic/post-surgical endothelial damage.

5. Keratitis: Causes

The cornea is sometimes the target of one direct pathophysiological condition, others, the compromise is secondary to an external indirect event in the complex functional anatomical triad between the lids, the cornea and the tear film.

There are multiple different causes of keratitis; these can be grouped in three major groups including infectious, autoimmune/inflammatory, neoplastic and traumatic causes.

5.1. Infectious keratitis

As an important component of the anatomical anterior wall of the eye, the cornea is a structure highly exposed and vulnerable to external pathogens. The use of contact lenses constitutes an accumulative risk for developing infectious keratitis, as it is also any history of chronic corneal disease or the use of topical steroids. Any corneal epithelial disruption as seen sometimes in dry eye syndrome, severe blepharitis and injuries are able to cause disruptions of the epithelial barrier as seen in corneal abrasions, post-surgical procedures or corneal foreign bodies that can predispose to corneal infections. Sometimes it is the result of highly pathogenic microorganisms with high affinity to the epithelial cells the ones that can cause a direct involvement as it is frequently seen with the herpes virus family.

5.1.1. Viral

By far the most frequent cause of viral keratitis is the one caused by herpes viruses type 1 and 2, also varicella-zoster virus can sometimes be responsible in the context of herpes zoster ophthalmicus. The typical form of viral keratitis is epithelial, with a characteristic dendritiform epithelial defect and secondary infiltrate very easy to diagnose with fluorescein staining (Fig 2). The epithelial defect seen in herpes zoster infection is classically described as geographic rather than dendritiform. In less than 10% of the cases the compromise can be primarily stromal or endothelial that typically is associated with elevated intraocular pressure (Fig 3). A PCR for virology in a swab of the epithelial lesion usually confirms diagnosis. Recent history of herpes zoster or recurrent cold sores can also orientate the clinician. If PCR is not available, another way of confirming diagnosis is by performing antibodies serology (IgG / IgM) for HSV and VZV at the time of presentation, an elevated IgM would confirm the diagnosis of recent infection and an elevated IgG a recurrence. This form of keratitis leaves behind sometimes significant corneal scarring with pannus, this clinical finding, in the context of an atypical recurrent hypertensive stromal or endothelial keratouveitis, can help sometimes achieve the correct clinical diagnosis.

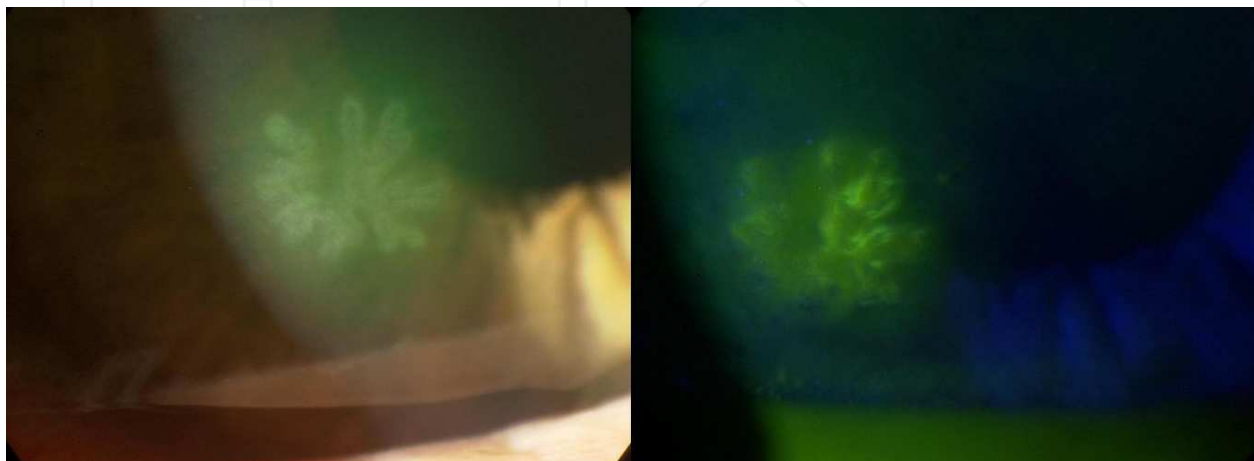


Figure 2. Herpes simplex virus epithelial keratitis as typical dendrite.

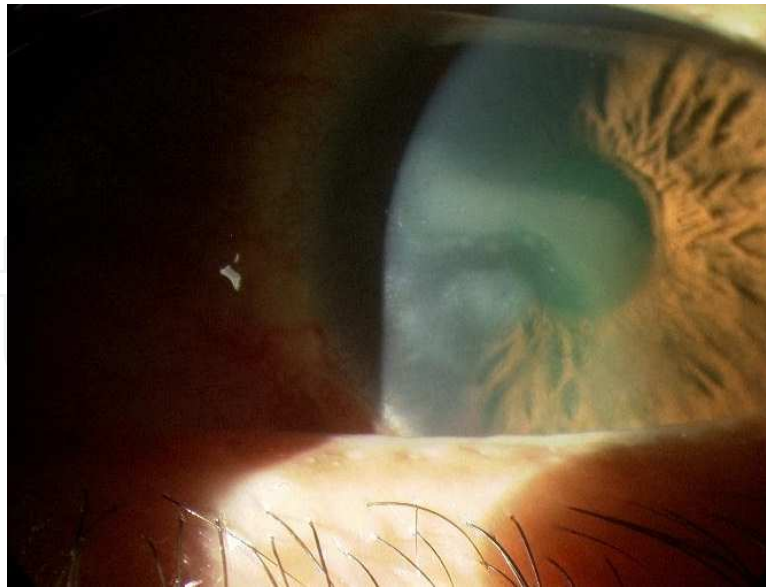


Figure 3. Herpes simplex virus stromal keratitis.

5.1.2. Bacterial

For bacteria to act as a pathogen in the cornea, it is necessary a disruption in the epithelial barrier like the ones seen in injuries (corneal foreign bodies and corneal abrasions) or a significant risk factor like contact lens wear or use of topical steroids. Almost any bacterium is able to cause keratitis, the most frequently involved are the ones that are the gram positive microorganisms found in the eyelids margin and skin (*staphylococcus* sp, *streptococcus* sp), sometimes gram negative bacteria like *pseudomonas* sp can be isolated. The typical keratitis caused by bacteria is epithelial and the presentation is acute; it usually has a well-defined epithelial defect surrounded by a stromal grayish infiltrate, which has a depth and extension proportional to the time of onset to presentation. Often a level of hypopyon and anterior chamber reaction are seen. The speed and extension of the compromise also depends on the pathogenicity of the bacteria involved, often being worse in the case of gram-negative microorganisms (Fig 4). Slow growth bacteria like *streptococcus viridans* can give the aspect of crystalline keratitis, as the invasion of the corneal stroma is very slow following the branching of the collagen layers. The diagnosis is usually confirmed by a corneal scrape of the lesion that can be sent for microbiological studies; in any ophthalmic setting it is crucial to perform a gram stain, blood agar, brain heart infusion (BHI) and cooked meat broth (CMB) cultures to be able to isolate the pathogen and determine the sensitivities to antibiotic therapy. The gram stain can give immediate initial information of the type of microorganism excluding other causes of keratitis. In contact lens wearers is important also to send for culture the contact lenses container and the last pair of lenses used.

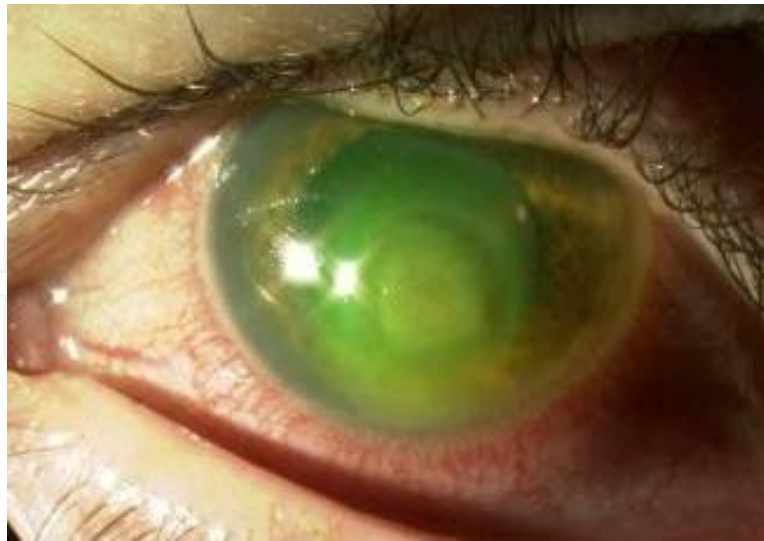

Figure 4. A patient with *pseudomonas* sp keratitis.

5.1.3. Fungal

It is a rare cause of keratitis in temperate climates but common cause of keratitis in tropical countries. It is difficult to treat. Usually occurs following trauma to the cornea especially the one caused by vegetable matter. Also contact lens wearing is emerging as a significant risk factor. The course is indolent sub-acute, it takes weeks for the patient to seek help as it does not cause significant discomfort in the early stages as fungi are slow in replicate. The clinical presentation is that of a stromal form of keratitis, an epithelial defect can or not be present, but usually is small compared to the amount of stromal infiltrate associated. The stromal infiltrate is always irregular in the borders and poorly defined, it has a 'fluffy' aspect and very white (Fig 5). In very advanced cases the infiltration of the stroma can be full thickness with associated anterior chamber whitish solid hypopyon. The diagnosis is often confirmed by a corneal scrape or a corneal biopsy sent for microbiological studies; the gram stain can be very useful in identifying hyphae, filaments or microorganisms very quickly, for the culture it is important to repeat the cultures described for bacteria (in case of mixed infection) and also a Sabouraud's media that is more specific for fungal growth.

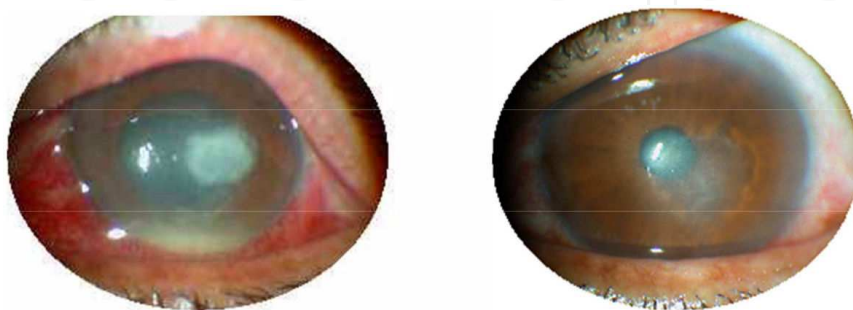
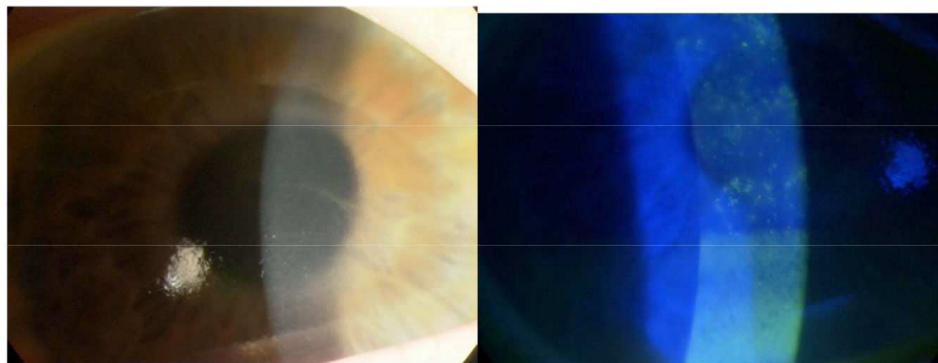


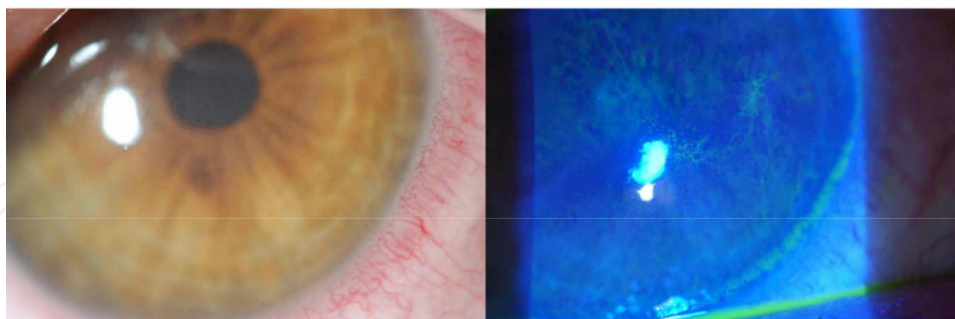
Figure 5. Fungal keratitis pre / post treatment.

5.1.4. *Acanthamoeba*

It is a rare cause of keratitis caused by one of the most common protozoa found in soil and water. In 90% of the cases a history of contact lens wear is found. Clinically this form of keratitis is combined with an epithelial and stromal component. The epithelial component is characteristically a large epithelial defect with abundant sub-epithelial infiltrate and enlargement of the corneal nerves that have been described as invaded by the pathogen at some stages of the disease, causing intense pain; this is perhaps the most painful form of keratitis, and this is regarded as a significant clinical finding at the time of diagnosing contact lens related keratitis. The stromal infiltrate is grey-whitish with irregular, multiple or single lesions, sometimes satellite areas can be seen (Fig 6 a & b). The diagnosis is confirmed by scrape or corneal epithelial biopsy sent for microbiological studies, it is important to repeat the gram and all the previously described medias (blood, BHI, CMB, Sabouraud's) and add the E. coli enriched non-nutrient agar media where this pathogen can be detected easily.



a)



b)

Figure 6. a) Epithelial infiltrate with perineuritis in a patient with acanthamoeba keratitis. b) Diffuse stromal infiltrate in early acanthamoeba keratitis.

5.1.5. *Atypical*

This term is used to describe an infectious keratitis caused by atypical microorganisms like mycobacterium. The pattern of keratitis can be very confusing as it occurs usually in the context

of postoperative, traumatic or previous corneal pathology situations. The course is always chronic, unresponsive to multiple previous treatments and the clinical picture varies between an epithelial and stromal form of keratitis with atypical features (Fig 7). Perhaps the most important aspect is the invariable presence of a significant risk factor like previous surgery, as this pathogen needs a significant break in the epithelial barrier to be able to invade and cause the condition due to its relative large size. The isolation of mycobacterium to confirm diagnosis depends on a high level of suspicion and the scrape or corneal biopsy culture that needs all the previously described media plus a Zhiel-Neelsen gram stain for identification of acid-fast bacteria and Lowenstein-Jensen agar for culture growth.

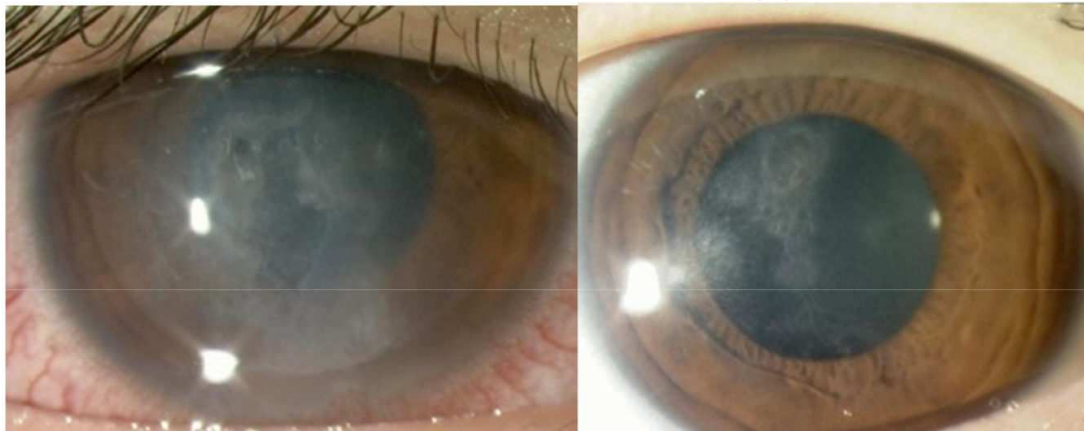

Figure 7. Atypical keratitis caused by mycobacterium abscessus after LASIK pre / post treatment.

5.2. Inflammatory — Autoimmune keratitis (Non suppurative keratitis)

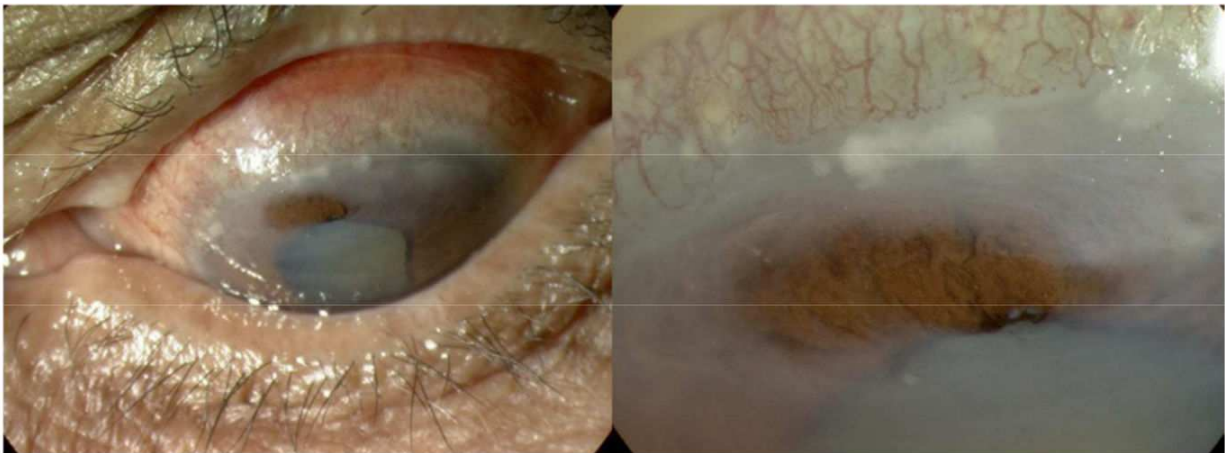
Any condition that can induce an inflammatory response of the cornea can be classified in this group of causes of keratitis. There are autoimmune and no autoimmune related diseases.

5.2.1. Autoimmune

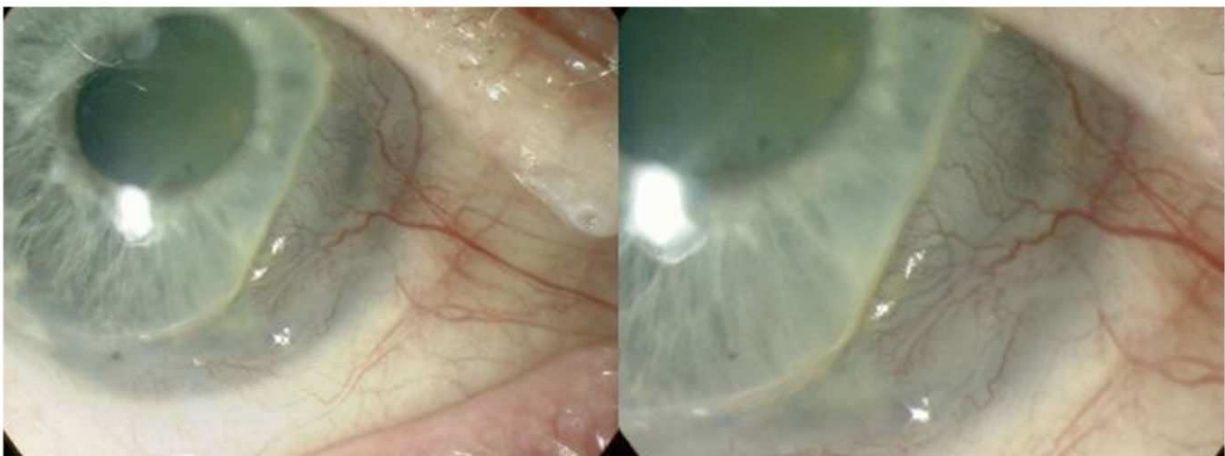
Like in any other autoimmune condition where the main target is the collagen in the body, the so-called autoimmune collagen or connective tissue diseases can be responsible for various forms of inflammatory keratitis, due to the high content of collagen seen in the corneal and scleral tissue. In some patients the cornea is the initial manifestation of the autoimmune process sometimes well in advance before the systemic condition manifests. The collagen diseases related to peripheral corneo-scleral ulceration or sclero-keratitis, include systemic lupus erythematosus, rheumatoid arthritis, Wegener's granulomatosis and polyarteritis nodosa. The form of keratitis seen in these cases is epithelial with a significant stromal component mainly in the form of subtle infiltrate with severe stromal melting and associated episcleral or scleral vasculitis (Fig 8). In other circumstances the cornea is the only affected structure as it is seen in Mooren's or peripheral ulcerative keratitis, the characteristic clinical finding is corneal stromal melting associated to inflammation (Fig 9 a & b).

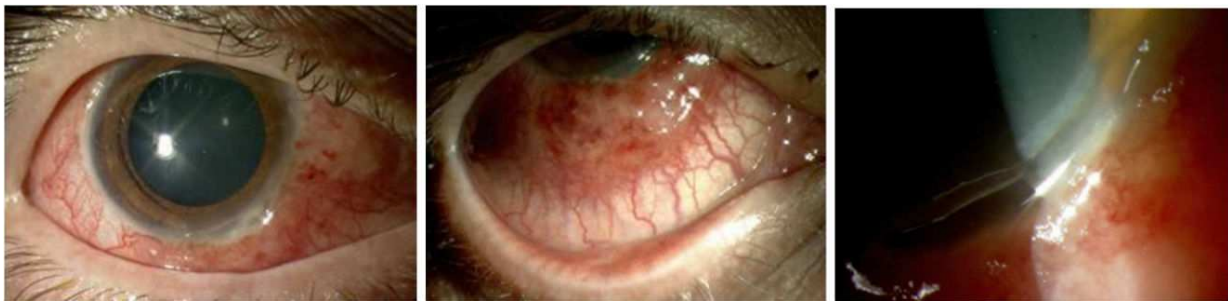

Figure 8. Sclerokeratitis in a patient with Wegener's granulomatosis.



a)



b)

Figure 9. a) Peripheral ulcerative keratitis with associated scleritis and corneal stromal corneal infiltrate. b) Typical case of Mooren's keratitis.

5.2.2. *Non autoimmune*

In this group, we find conditions that can compromise the delicate functional triad between the cornea, the tear film and the lids. If any of these is affected it will indirectly affect the anatomy and function of the other, potentially causing an inflammatory keratitis. Lids conditions like blepharitis, rosacea, lagophthalmos, entropion, ectropion, tarsal calcareous concretions or tear film dysfunctions like the ones seen in Sjogren's or severe dry eye syndrome can directly or indirectly cause keratitis in the form of marginal keratitis (Fig 10), phlyctenular keratoconjunctivitis and sometimes diffuse punctate keratitis as seen in Thygeson's keratitis. Usually the clinical pattern in this form of keratitis is epithelial with isolated or multiple epithelial defects and sub-epithelial superficial mild infiltrates (Fig 11), filaments can also sometimes be seen. When chronically affected a peripheral corneal pannus can often be seen (Fig 12).

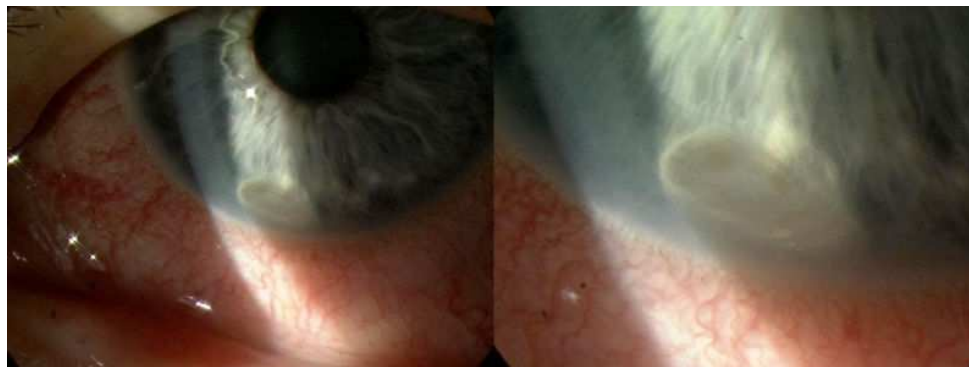

Figure 10. Typical marginal keratitis associated to rosacea.

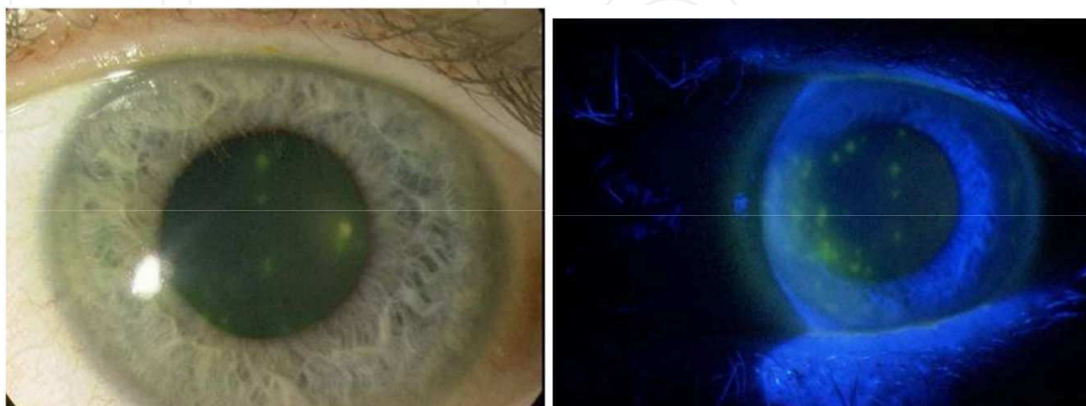


Figure 11. Superficial epithelial defects in dry eye syndrome.

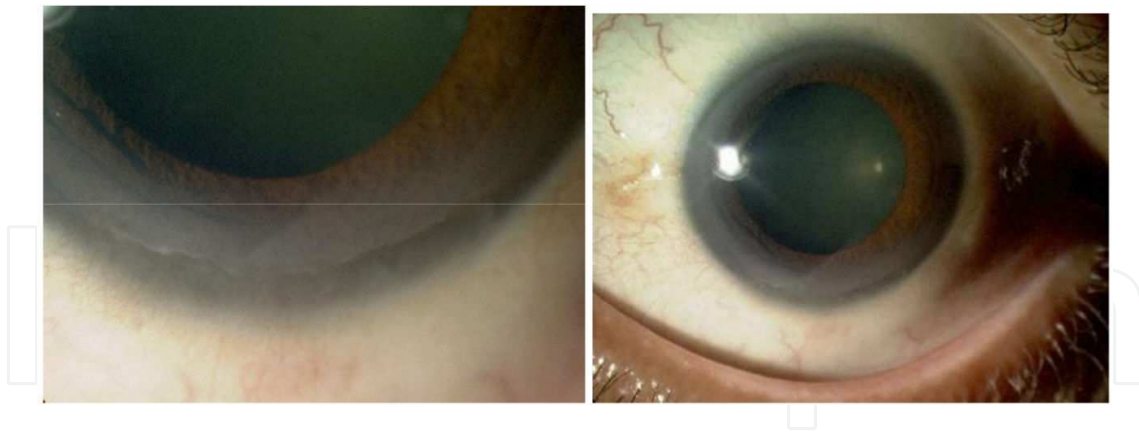


Figure 12. Peripheral pannus in chronic dry eye syndrome.

5.3. Neoplasia associated inflammatory corneal involvement

Any neoplastic process in the limbal region and surrounding conjunctiva can indirectly extend to the cornea and cause an inflammatory reaction, this is generally not considered in the differential diagnosis of keratitis and is perhaps the most rare and less suspected cause of corneal and limbal inflammation, however it is important to consider it in order to achieve an early diagnosis, as this type of conditions untreated can extend quickly with some mortality rate.

5.3.1. Conjunctival intraepithelial neoplasia and squamous carcinoma

Neoplasia of the conjunctival epithelial cells is more commonly seen in the elderly. There are different grades of penetration in the underlying tissue and the amount of cellular atypical cells defines also the degree of malignancy ranging from grade 1 to a carcinoma in situ. The more invasive the type of neoplasia, the more likely this will extend to the adjacent corneal tissue and regional lymphonodes; the corneal involvement always remains superficial (Fig 13, 14).

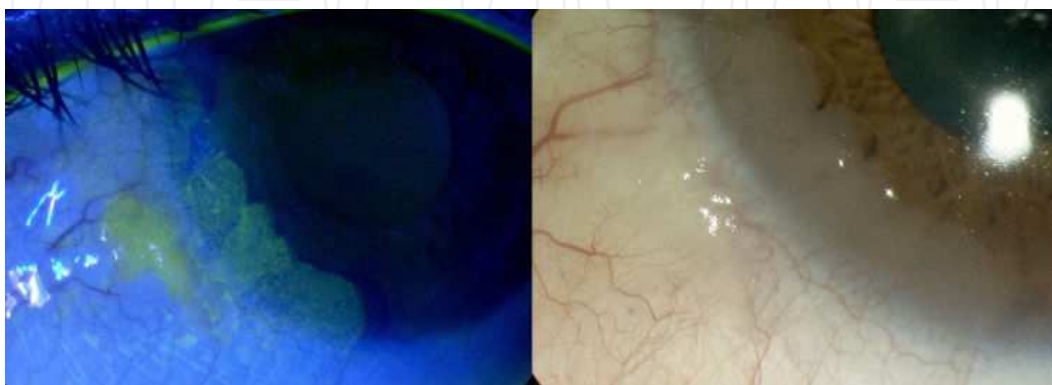


Figure 13. Conjunctival intraepithelial neoplasia (CIN) grade 3 with and without fluorescein staining.

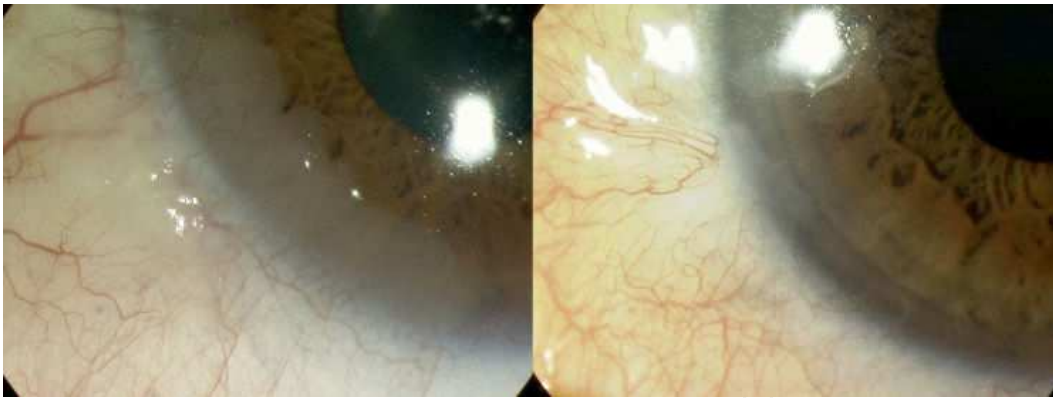


Figure 14. Conjunctival intraepithelial neoplasia (CIN) grade 3 treated with topical mytomicin C.

5.3.2. Conjunctival / limbal melanomas

They are rare but lethal. They can be very polymorphic with multiple types of different clinical presentation, pigmented (melanotic) or not pigmented (amelanotic), they are of rapid growth and can invade distant organs especially lungs and liver. The most likely origin is at the conjunctival epithelial cells when some pigmentation is associated. Isolated or multiple sentinel vessels are a pathognomonic feature (Fig. 15).

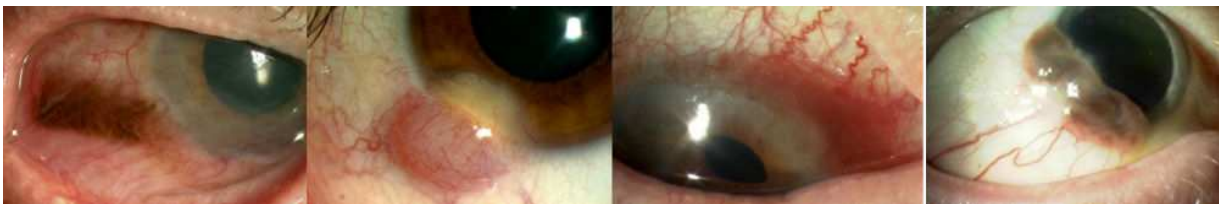

Figure 15. Four different conjunctival melanomas with corneal involvement, notice the polymorphism in clinical presentation.

5.4. Traumatic keratitis

In this group we can consider trauma by direct blunt injury with secondary corneal abrasion and corneal edema, or a surgical injury that damages the endothelial layer causing secondary corneal edema and endothelial failure with concurrent bullous keratopathy. The type of keratitis seen in these situations is mainly endothelial and stromal with multiple descemet folds, stromal collagen fibers disorganization, keratic precipitates and often associated anterior chamber reaction. At later stages if the endothelial layer does not recover from the insult, a severe corneal edema may lead to epithelial bullous formation and consequent epithelial keratitis. A clear history of trauma might not be obvious and the clinicians are encouraged to obtain it from the clinical history remembering that sometimes the traumatic event can precede the clinical manifestation for many years (i.e. previous cataract surgery, etc)

6. Keratitis: Treatment

The treatment of keratitis will depend on the direct cause; it is for this reason that an appropriate diagnosis is crucial at the moment of deciding the initial treatment.

6.1. Infectious causes

In viral herpetic keratitis cases, the drug of choice is acyclovir in topical or oral form depending on the extension of the keratitis within the corneal layers. A typical dose is ointment acyclovir 3% five times daily for one week or 400 mg orally five times a day for the same period. In severe cases both forms can be used to maximize effect. In children and the elderly the oral formulation is recommended due to difficulties in the application of the ointment. In resistant cases the alternative treatment will be topical trifluorothymidine 1% (F3T) or vidarabine 3% (Vira-Atm). If high intraocular pressure (IOP) is detected this also need to be treated with lowering IOP agents. Other antiviral agents like topical ganciclovir 0.15% (Zirgantm) have started to be used more widely in recent years.

In bacterial suspected infections the initial treatment of choice is topical ciprofloxacin 0.3%, Ofloxacin 0.3% or levofloxacin 0.3% hourly, when significant anterior chamber reaction is found a cycloplegic/dilating drop to minimize pain and reduce the formation of posterior synechias is recommended and depending on the bacterial sensitivities results the treatment should be adjusted accordingly.

In acanthamoeba the treatment requires a combination of poly-hexyl-methyl-biguanide 0.02% (PHMB) and propamide isethionate 0.1% (Brolenetm), alternatively preparations of chlorhexidine 0.02% can be used as well.

In atypical keratitis one can start treatment based on the suspicious on the most likely clinically apparent etiological cause and adequate it based on the findings from the sampling.

6.2. Inflammatory / autoimmune

For autoimmune keratitis usually systemic therapy is needed, the important approach in the treatment is to identify corneal limbal ischemia and/or corneal melting as these are reasons not to use topical steroids due to the high risk of perforation. Severe cases will need high dose of oral steroids and immunosuppressant agents. No autoimmune cases, presenting with inflammatory features due to blepharitis and/or dry eyes with marginal infiltrates do benefit from topical steroids, however is also very important to treat the initial cause of corneal inflammation as this is usually secondary, i.e. removal of concretions and ectopic eyelashes, repair lagophthalmos or other lids malpositions, treat dry eyes with topical lubricants, etc.

6.3. Neoplasia associated

Surgical removal and biopsy is important as it is based on the histological diagnosis that further interventions like cryotherapy or radiotherapy might be indicated and planned. The excision

of any suspicious lesion ideally has to have a margin of two centimeters of healthy tissue to prevent recurrences. In CIN cases concomitant cryotherapy is useful as well as topical mytomicin C or 5 – fluorouracil at different concentrations. In melanomas a systemic workup including chest CT scan and liver function tests at regular intervals to detect metastasis is important, concomitant local radiotherapy has been advocated as well at the time of removal of the lesion.

6.4. Traumatic

In cases of corneal abrasion the treatment of choice is to use topical antibiotic ointments to prevent infections and to pad the eye for 24 hours to allow epithelisation of the cornea, the use of preservative free cycloplegic drops initially to relief pain is recommended before padding. In blunt injuries the use of topical anti-inflammatory or steroid drops is useful depending on the severity of the inflammation. In cases of bullose keratopathy, endothelial corneal transplantation is highly successful, the use of highly osmotic drops like NACL 5% or bandage contact lenses can sometimes clear the corneal stroma and relief pain while waiting for a corneal donor.

7. Conclusion

A clear and simple approach to the differential diagnosis of keratitis has been presented. The methodological clinical diagnostic remains the cornerstone of medicine at anytime, the clinical history, examination of the patient and auxiliary diagnostic methods to confirm a suspected diagnosis are all crucial in achieving a clinical improvement of the clinical condition known as keratitis.

The simple classification based on clinical findings will help ophthalmologists, general practitioners to assess patients with this condition and start an adequate initial investigation and treatment

Keratitis remains one of the most frequent diagnoses in ophthalmology and a comprehensive review like the one here presented is useful for any levels of clinical practice.

Author details

Patricio A. Pacheco^{1,2}

1 Moorfields Eye Hospital, London, UK

2 West Hertfordshire Hospitals, NHS trust, UK

References

- [1] Chow, C.Y.; Foster, C.S. (1996). Mooren's ulcer. *International Ophthalmology clinics*, Vol. 36, (Winter 1996), pp. 1-13
- [2] Donzis, P.B.; Mondino, B.J. (1987). Management of non infectious corneal ulcers. *Survey Ophthalmology*, Vol. 32, (January 1987), pp. 94-110
- [3] Dua, H.S.; Faraj, L.A.; Said, D.G.; Gray, T.; Lowe, J. *Ophthalmology*, Vol. 120 (9), (September 2013), pp. 1778-1785
- [4] Holland, E.J.; Schwartz, G.S. (1999). Classification of herpes simplex virus keratitis, *Cornea*, Vol. 18, (March 1999), pp. 144-154
- [5] Kanski, J.; Pavesio C. & Tuft S. (2006). Ocular Inflammatory Disease, Mosby-Elsevier, ISBN 0-323-03737, 1st edition, Philadelphia, USA
- [6] Ladas, J.G.; Mondino, B.J. (2000). Systemic disorders associated with peripheral corneal ulceration. *Current opinion Ophthalmology*, Vol. 11, (December 2000), pp. 468-471
- [7] Radford, C.F.; Minassian, D.C. & Dart, J.K. (2002). Acanthamoeba keratitis in England and Wales: incidence, outcomes and risk factors. *British Journal Ophthalmology*, Vol. 86, (May 2002), pp. 536-542
- [8] Rohatgi, J.; Dhaliwal, U. (2000). Phlyctenular eye disease. *Japanese Journal Ophthalmology*, Vol. 44, (March-April 2000), pp. 146-150
- [9] Suchecki, J.K. ; Donshik, P. & Ehlers W.H. (2003). Contact lens complications. *Ophthalmology Clinics North America*, Vol. 16, (March 2003), pp. 471-484
- [10] Solomon, A.; Karp, C.L. & Miller, D. (2001). Mycobacterium interface keratitis after laser in situ keratomileusis. *Ophthalmology*, Vol. 108, (December 2001), pp. 2201-2208
- [11] Stern, M.; Gao, J & Siemasko, K. F. (2004). The rôle of the lacrimal functional unit in the pathophysiology of dry eye. *Experimental Eye Research*, Vol. 78, (March 2004), pp. 409-416