

We are IntechOpen, the world's leading publisher of Open Access books Built by scientists, for scientists

6,900

Open access books available

185,000

International authors and editors

200M

Downloads

Our authors are among the

154

Countries delivered to

TOP 1%

most cited scientists

12.2%

Contributors from top 500 universities



WEB OF SCIENCE™

Selection of our books indexed in the Book Citation Index
in Web of Science™ Core Collection (BKCI)

Interested in publishing with us?
Contact book.department@intechopen.com

Numbers displayed above are based on latest data collected.
For more information visit www.intechopen.com



High Grade Glioma — Standard Approach, Obstacles and Future Directions

Siddharth K. Joshi and Richard Zuniga

Additional information is available at the end of the chapter

<http://dx.doi.org/10.5772/58548>

1. Introduction

Glioblastoma Multiforme is the most malignant of gliomas. These malignancies that arise from glial cells remain one of the pre-eminent and confounding therapeutic challenges in oncology and medicine at-large. Though uncommon, it continues to be responsible for disproportionate rates of morbidity and mortality the world over, as qualified by a median survival of only about 15 months despite optimal treatment [1, 2]. This is in large part due to its heterogeneous biology, exceedingly complex molecular pathogenesis, and the tumor's predilection for growth in the CNS. Ongoing research, particularly in the last decade, has provided the scientific and medical worlds with ever deeper insight into, and further elucidation of, the biology and molecular pathogenesis of Glioblastoma Multiforme (GBM). This in turn has led to compelling novel treatment modalities that range from rudimentarily conceptual to, excitingly, on the very cusp of implementation. This chapter aims to provide the reader with a comprehensive survey of Glioblastoma Multiforme contextualized within the broader realm of malignant gliomas.

GBM is the most common malignant primary brain cancer in adults, accounting for roughly 3 new cases per 100,000 people [3]. Underscoring its importance as a therapeutic target, GBM accounts for nearly 16% of all brain tumors and, furthermore, nearly 46% of malignant gliomas [3]. The average age at diagnosis of GBM is 64 years of age, and, for reasons yet unclear, it has demonstrated a clear male predilection, being about 1.6 times more common in males than females [3].

Running in tandem with the quest for more effective therapies for GBM has been a long and intensive search for clear risk factors positively associated with the development of GBM. This search, however, has been fraught with many dead ends. Indeed, no clear inciting cause has been identified for the vast majority of cases of GBM and the only bona-fide established risk factor is exposure to ionizing radiation. The cause-effect relationship between ionizing

radiation and the development of GBM was established with studies that demonstrated that children treated with radiotherapy for malignancies like leukemia have a markedly increased risk for developing GBM [4]. Family history of cancer of any type also has a suggested association, being found in the family members of roughly 19% of patients diagnosed with GBM in one small study [5]. In a small minority, approximately 5%, of diagnosed primary brain tumors, there is the presence of genetically inherited syndromes (e.g. Neurofibromatosis Types I and II, Li-Fraumeni Syndrome, von Hippel-Lindau Syndrome, Turcot Syndrome, Tuberous Sclerosis), which suggests a putative genetic relationship [6]. As with other malignancies, it has also been suggested that viral infections, specifically by SV40, HHV-6, and CMV, may be associated with the development of GBM by tumorigenesis through integration of viral genetic material into normal DNA [7-10]. Another putative association that has garnered much in the way of publicity is the relationship between cell phone use and development of primary brain tumors. This is a weakly-supported association based on the aggregate epidemiological data on hand that deserves further study and follow-up in the years to come as cell phone use becomes more ubiquitous the world over [11,12].

2. Histopathology

GBM is, in a manner of speaking, the pathological culmination of and histological end point on the broader continuum of gliomas/astrocytomas. The word Glioma literally translates in Greek into the English equivalent of "glue" [13]. This connotes the functional conception of the cells that beget gliomas, i.e. gliomas arise from those cells in the CNS that form the support framework for neurons. It merits a side note here that though this has been the traditional conception of glial cells, new studies have shown them to possess a more autonomous role than previously supposed [15]. The WHO has classified gliomas/astrocytomas into 4 grades that, successively, convey graver prognostic significance (See Table 1); this is the 4th iteration of this classification system published in 2007 and originally conceived in 1979 [15]. This method of classification, based on histopathological features, is one that has built a certain assumed relevance for clinical decision making. The neuro-oncologist uses it as a template to guide whether a patient may qualify for a conservative strategy of watchful waiting, as with Grades I and sometimes with Grade II, or aggressive radiotherapy with chemotherapy, as with Grades III and IV. Indeed, only Grades III (Anaplastic astrocytoma/oligodendroglioma) and IV (GBM) are considered malignant gliomas. There are discrete histological features that qualify Grade III and IV astrocytomas as malignant. Grade III gliomas when compared to lower grades, is distinguished by a significant increase in cellularity, mitotic activity, and nuclear atypia [16] (See Figure 3). Grade IV gliomas, in addition to these telltale harbingers of malignant transformation, is embodied, uniquely, by areas of microvascular proliferation and/or neoplastic tissue necrosis [16] (See Figure 4). Indeed, it is worthy of emphatic mention that one of the overarching and typifying characteristics of malignant gliomas is their histological heterogeneity, i.e. consisting of both neoplastic and stromal tissue [16]

Localized Astrocytoma
WHO Grade I
Pilocytic Astrocytoma
Pleomorphic Xanthoastrocytoma
Subependymal Giant Cell Astrocytoma
Diffuse Astrocytomas/Oligodendrogliomas
WHO Grade II (Astrocytoma)
Fibrillary
Protoplasmic
Gemistocytic
WHO Grade II (Oligodendroglioma_
WHO Grade III (Anaplastic Astrocytoma)
WHO Grade III (Anaplastic Oligodendroglioma)
WHO Grade IV (Glioblastoma Multiforme)
Giant Cell Glioblastoma
Gliosarcoma

Table 1. WHO Classification of Gliomas

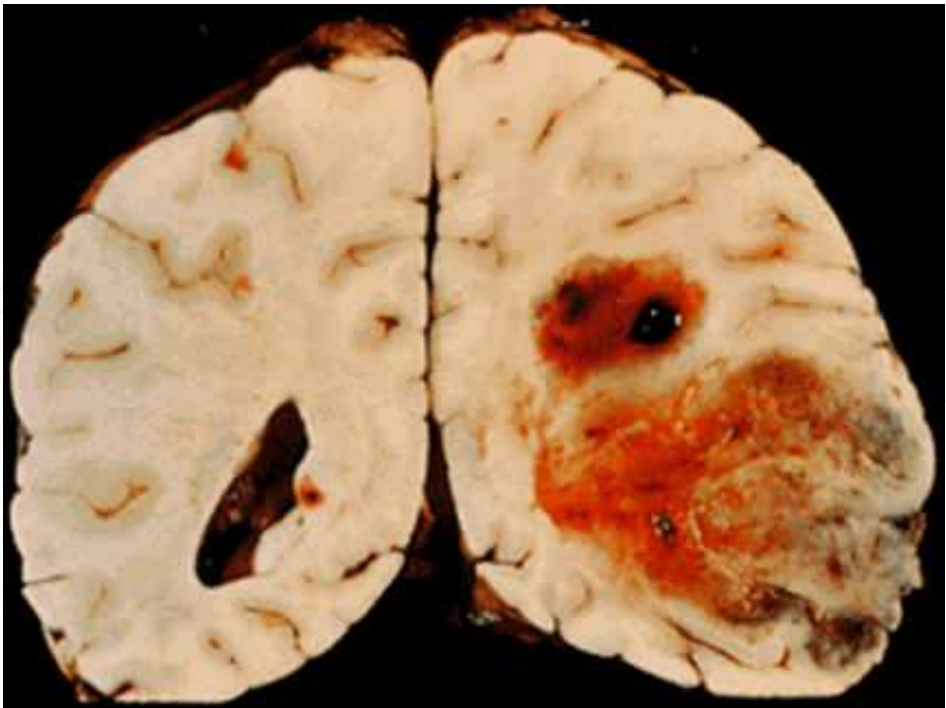


Figure 1. Gross Appearance of GBM

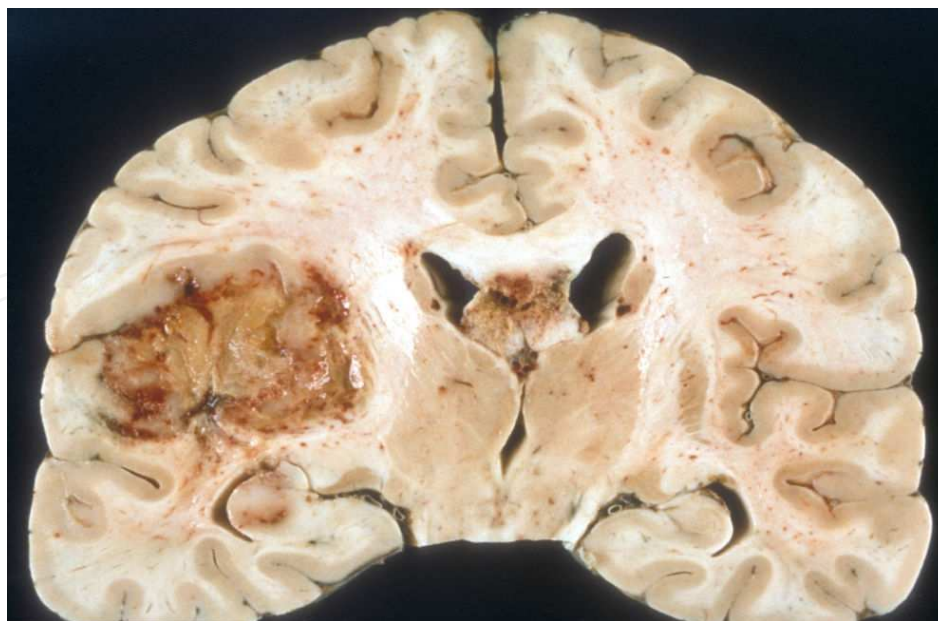


Figure 2. Gross Appearance of GBM

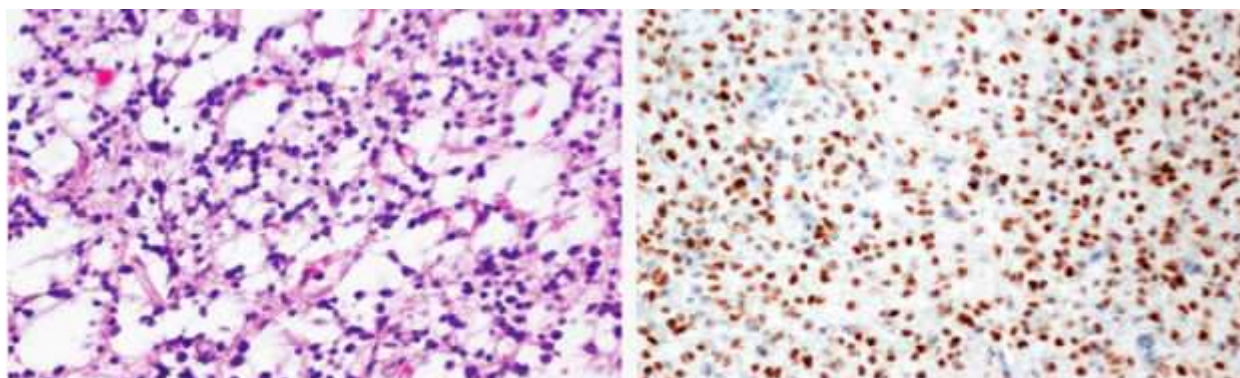


Figure 3. Histological Appearance of Grade III Anaplastic Oligodendroglioma. [16]

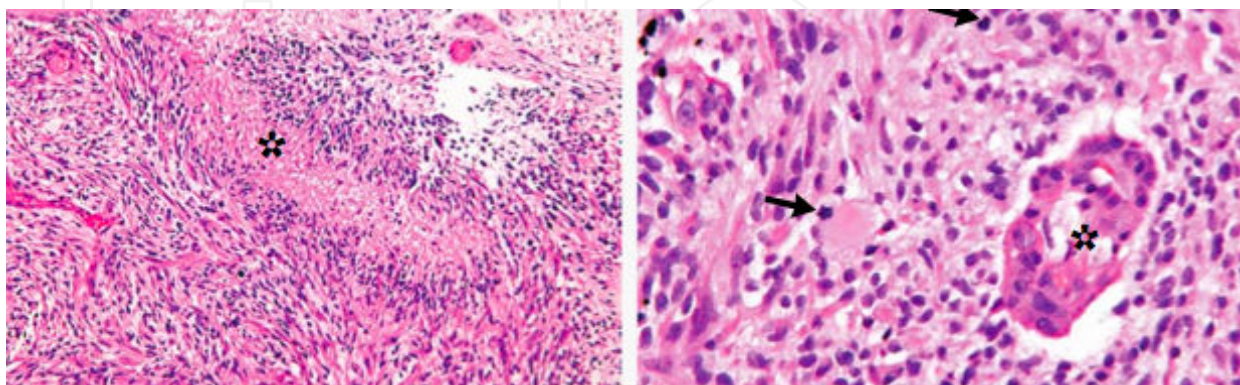


Figure 4. Histological Appearance of GBM. First Panel shows Pseudopalisading Nuclei at area of asterisk; second panel shows mitotic figures at arrows and endothelial proliferation at asterisk. [16]

The pathology of GBM, quite simply, is summated by foci of necrotic tissue surrounded by anaplastic cells and microvascular hyperplasia. The anaplastic cells surrounding the foci of necrosis are unique for malignant gliomas and are known as “pseudopalisading cells” due to their configuration around the necrotic foci (Refer to asterisk in Figure 4, which shows a necrotic center surrounded by pseudopalisading cells). It is interesting to note that the pseudopalisades, hyperplastic vasculature and necrotic centers are all inextricably linked to one another. The pseudopalisading cells are found to be severely hypoxic which causes over-expression of hypoxia-inducible factor (HIF-1) and secretion of pro-angiogenic factors VEGF and IL-8. It is thought that the telltale hypoxia and necrosis that distinguish malignant gliomas arise as a result of vascular occlusion and intravascular thrombosis that are inevitable consequences of tumor outgrowing blood supply. By this model, then, the pseudopalisading nuclei are seen as waves allowing for tumor cells to extend outwards from necrotic foci into normal surrounding parenchyma [33]. Another tumor type of neuroepithelial tissue with malignant capacity is oligodendroglioma. This type of tumor usually presents in younger patients within the white matter of the frontal and temporal lobes. Histologically, oligodendrogliomas are characterized by round nuclei and perinuclear halos dispersed in a monotonous pattern. The perinuclear halos are a preparation artifact that is characteristic of oligodendrogliomas and are frequently described as having a “fried-egg appearance”. This type of tumor can be classified as WHO grade II or III (diffuse oligodendroglioma and anaplastic oligodendroglioma respectively) and the presence of a high mitotic rate (most 5-10%), vascular endothelial hyperplasia and nuclear pleomorphism categorizes the tumor as Grade III anaplastic oligodendroglioma.

When one considers the origin of malignant gliomas, i.e. the inciting events that herald transformation of normal glial tissue/parenchyma into malignant tissue, they conform to the general oncological orthodoxy. That is, they are basically the end-result of stepwise mutations in genes responsible for essential biological processes, most notably cell growth, proliferation and controlled cell death. Oncogenesis of GBM is essentially representative of that basic canon in oncology--activation of oncogenes and silencing of tumor suppressor genes. In other words, stepwise acquisition of new biological properties/characteristics by oncogenesis confers phenotypic characteristics that allow the malignant cells to outcompete their wild-type counterparts in their micro-milieu.

3. Primary vs. secondary GBM

Upon diagnosis, GBM is customarily delineated into one of two broad categories--Primary GBM, which arises *de novo* in brain tissue, or Secondary, which develops from lower grade astrocytomas (Refer to Table 2 for salient respective features and differences). In addition to the fundamental etiological difference, primary GBM possesses categorically different genetic and epigenetic differences from Secondary GBM. (Epigenetics refers to those meiotically or mitotically heritable traits resulting in phenotypic/gene expression patterns not related to changes in the underlying actual DNA code.) The vast majority of cases are GBM are primary, i.e. *de novo*, and comprise upwards of 90% of diagnosed cases. Epidemiologically, Primary

GBMs are almost always found in the elderly population with a mean age of diagnosis of 62 years and is characterized by a rapidly inexorable course till death [27]. The genetic/epigenetic features that beget the malignant transformation in primary GBM and encompass its difference from secondary GBM include: mutations in and amplification of EGFR, loss of heterozygosity of Chromosome 10q, deletion of the phosphatase and tensin homologue (PTEN) on Chromosome 10, and p16 deletion [16,23]. Secondary GBM, on the other hand, predominantly affects younger patients with a mean age at diagnosis of 45 years, and is characterized by a much slower, more smoldering course than Primary GBM [23]. Secondary GBM evolves from Grade II (Low Grade Well-Differentiated) and Grade III (Anaplastic) astrocytomas, has a predilection for the frontal lobes, and develops from its precursors over the course of years. An epidemiological study from 2005 showed that the time of progression from low-grade astrocytoma to GBM was approximately 5.3 years whereas the time of progression from anaplastic astrocytoma to GBM was approximately 1.4 years [28]. This stands in stark contrast to the rapidity of Primary GBM progression, with roughly two-thirds of patients having a clinical history from time of diagnosis to death of less than 3 months [27]. As stated, secondary glioblastoma has a genetic/epigenetic footprint that differs from Primary GBM, the exception being the commonality of loss of heterozygosity of Chromosome 10q. The differences in this epigenetic footprint include: mutations in p53, over expression of Platelet-Derived Growth Factor Receptor (PDGFR), aberrancies in p16/Retinoblastoma pathways, and global differences in transcription patterns and DNA copy numbers [16]. It is worthy of emphatic mention here that primary and secondary GBM, though developing through distinct genetic and molecular pathways, are grossly and histologically indistinguishable from one another.

	Primary GBM	Secondary GBM
Mean Age at Diagnosis	~ 62 years of age	~45 years of age
Percentage of Cases	> 90%	< 10%
Clinical Course	Rapid	Smoldering
Genetic Hallmarks	EGFR, etc.	PDGFR, etc.

Table 2. Primary vs. Secondary GBM

4. Clinical characteristics

The clinical presentation of GBM is, as intuited, dependent in large part on the location of the tumor. Continuing to bode ill for both treatment and prognosis is the sobering fact that malignant gliomas, and GBM in particular, grow insidiously and largely asymptotically until they are big enough to elicit symptoms by sheer mass effect. By that time, tellingly, the options for surgical resection are relatively limited given extension into vital CNS parenchyma. Common presenting symptoms include recalcitrant headaches, unprovoked new-onset seizures, unprecedented memory loss, unaccountable changes in personality or consciousness, cognitive/language impairments, and other miscellaneous symptoms, i.e. nausea/vomiting.

Though there are no pathognomonic symptoms that may help the clinician to reliably distinguish between the two WHO Grades of malignant gliomas, there have been cohort studies done that have shown some nuances in symptomatology between Anaplastic

Astrocytoma and Glioblastoma Multiforme (See Table 3). Prognostic factors boding favorably for patients diagnosed with malignant gliomas include a lower tumor grade, resection of tumor mass, younger age (less than 50 years) at time of diagnosis, higher performance status (e.g. ECOG) score and intact neurological function [35].

Symptom	Grade III, %	Grade IV, %
Headache	53	57
Seizure	56	23
Memory Loss	26	39
Motor Weakness	25	36
Visual Symptoms	23	21
Language Deficits	22	36
Cognitive Changes	22	39
Personality Changes	11	27
Change in Consciousness	11	18
Nausea and Vomiting	8	15
Sensory Deficit	5	12
Papilledema	5	5

Table 3. Initial Symptoms in 565 Patients with Grade III or Grade IV Malignant Glioma (Data from Glioma Outcomes Project [29])

5. Diagnosis

The diagnostic modalities for suspected GBM in the appropriate clinical setting are, broadly, twofold: imaging and biopsy. The cornerstone of imaging is MRI with and without Gadolinium contrast enhancement. Prior to administration of contrast, malignant gliomas are hypo-intense on T1-weighted images (See Figure 5). Upon administration of Gadolinium, it is found that tumor enhances heterogeneously; this allows it to be distinguished from surrounding edema that remains hypo-intense on T-1 weighted images (See Figure 5). Another ancillary MRI sub-modality is FLAIR (Fluid Attenuated Inverse Reconstruction) MRI (See Figure 5) [30]. The utility of FLAIR MRI is that, as an inversion recovery MRI technique, it can essentially nullify or subtract the effects of fluid, thereby suppressing CSF in brain imaging. This can be especially useful in planning radiation therapy (to be discussed in more detail below) when it is of vital importance to delineate malignancy from native vital brain parenchyma [31].

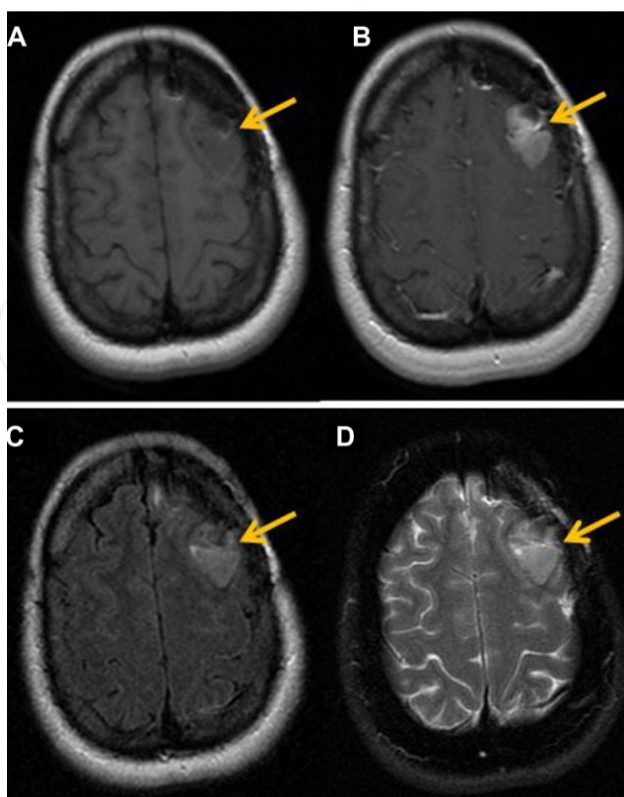


Figure 5. (A) T1 pre-contrast images exhibit a hypointense lesion in the left frontal lobe region (arrow). (B) Axial T1 post-contrast images, after injection of 20 cc of intravenous MultiHance®, demonstrate a focus of enhancement in left frontal lobe. (C) Axial T2 FLAIR images show increase in FLAIR signal in the left frontal lobe, which demonstrates enhancement. (D) T2 FSE images also demonstrate increase in signal in the region of the left frontal lobe.[30]

The gold standard for diagnosis, of course, remains procurement of tissue for histological confirmation that can either be accomplished either diagnostically through stereotactic biopsy or, more commonly, diagnostically and therapeutically with tissue samples obtained during craniotomy for the purposes of tumor resection or debulking.

6. Role of surgical resection

The standard treatment for newly-diagnosed GBM has remained relatively staid as evinced by the relatively abysmal prognosis over the aggregate of decades. However, caveat emptor must once again be invoked as there is a sea change in elucidation of the molecular features of GBM that promises much in the way of therapeutic potential on the horizon. This will be discussed in detail in content to follow.

The first modality in treatment is maximally safe surgical resection. This, it needs bearing in mind, is not curative. At the time of diagnosis, newly-found GBM has invariably infiltrated extensively into normal brain parenchyma. GBM is almost always diagnosed after it has grown large enough to elicit symptoms due to mass effect and parenchymal disruption. However, the benefits of maximally-safe surgical resection of tumor are manifold: sampling of tissue for

pathological diagnosis, palliation of mass effect, and some indication of improvement in survival [16]. Though rote surgical resection has remained somewhat limited due to the intricate insinuation of the tumor into brain tissue, new surgical technologies have allowed for more elegant and discriminating extrication of malignant tissue. One example is neuroendoscopy, use of an endoscope deployed through the ventricles for a minimally-invasive approach to allow for biopsy, resection and alleviation of lesions causing obstructive hydrocephalus [13]. Another surgical technology is fluorescence-guided resection. This involves the administration of a non-fluorescent prodrug 5-aminolevulinic acid (ALA) that, when taken up by tumor tissue, is converted to fluorescent metabolite protoporphyrin IX (PpIX) and accumulates to a marked degree in Grade III and IV gliomas. The neurosurgeon intra-operatively deploys “blue light” which allows tumor tissue to be visualized as “red” due to the fluorescent biomarker. This, in turn, has been shown to allow for more optimal and extensive tumor resection [13] (See Figure 6).

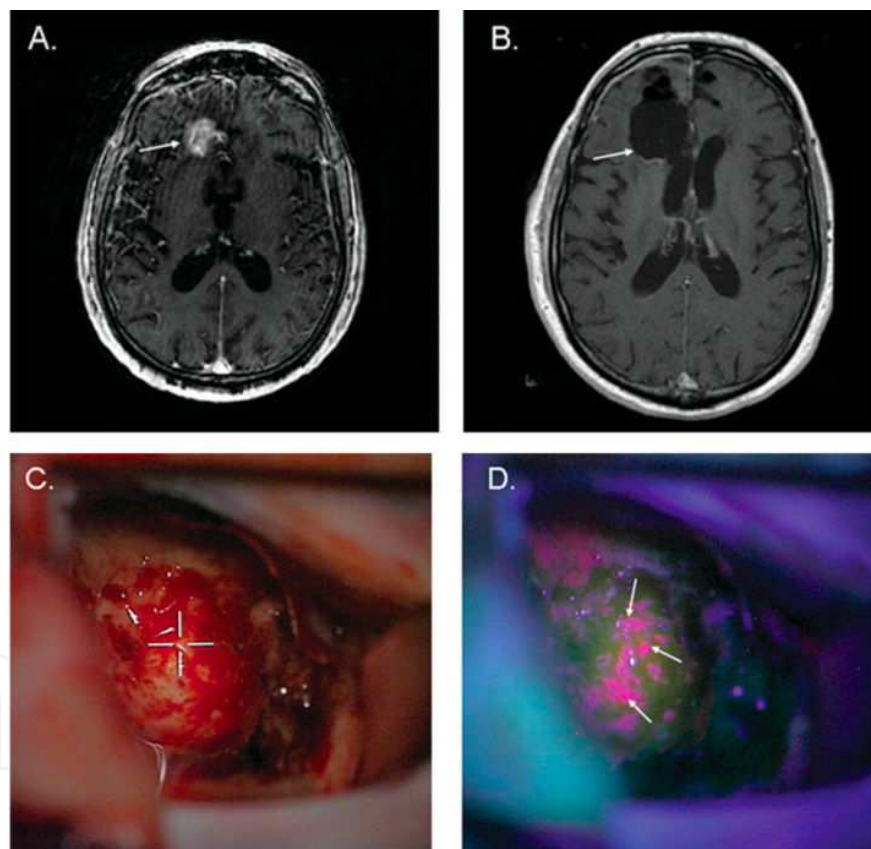


Figure 6. Fluorescence/ALA-Guided Surgical Resection of GBM [13]

An important concept to invoke here in the discussion of surgical treatment is Extent Of Resection (EOR), i.e. the extent of tumor tissue that can be safely resected. There is, as would be intuited, a likely positive association between (EOR) and patient survival/patient outcome. Data from the ALA-glioma Study Group out of Germany provided the highest level of evidence--2b--for a positive association between patient outcome, i.e. progression free

Survival	RT	RT + TMZ
Median, mos	12.1	14.6
2 yr, %	10.9	27.2
3 yr, %	4.4	16.0
4 yr, %	3.0	12.1%
5 yr, %	1.9	9.8

Figure 7. EORTC/NCIC Trial 5-Yr Follow-up [35]

survival, and EOR [34]. There are, however, some retrospective studies (volumetric and non-volumetric) that have shown no survival benefit with increased EOR. However, the aggregate of evidence does support the thesis that patients with high-grade gliomas do show survival benefit with increased EOR.

7. Standard adjuvant therapy

After maximally-safe surgical resection, the standard of care for GBM is a 6 week course of External Beam Focused Radiation Therapy with concurrent chemotherapy followed by 6 months of adjuvant chemotherapy.

With the support of Level IA evidence, fractionated focal radiotherapy (60 Gy, 30-33 fractions of 1.8-2 Gy) is the established radiation regimen after resection or biopsy of malignant gliomas [37]. The fundamental nature of the ionizing radiation utilized has, needless to say, not changed; however, leaps and bounds have been made in efforts to focus the beam, tailor it to the highly-serrated and convoluted contours of tumor, and limit the dose to nearby critical structures/tissue by the use of intensity-attenuated and image-guided technologies, all with positive effect.

The single first-line chemotherapeutic agent for GBM is temozolomide, an oral alkylating agent that exerts its anti-tumorigenic effect by methylating/alkylating DNA at the N-7/O-6 positions of guanine residues, thereby causing irreparable damage to (tumor) DNA and instigating the process of tumor cell death. The benefits of the addition of concurrent with adjuvant chemotherapy to the foundation of radiation therapy were demonstrated by a seminal landmark study by Stupp *et al* that showed a 14.6 to 12.1 month median overall survival benefit and showed a sustained survival advantage of 9.8% vs 1.9% at 5 year analysis (Figure 7) [35].

High-dose corticosteroids have a role to play in reduction of tumor-associated edema and associated symptoms but are not indicated for long periods of time [37]. There is an established role for anti-seizure therapy in patients who present with seizures, but the role for seizure prophylaxis after surgery is only indicated in symptomatic patients. It ought to be kept in mind

that many anti-epileptics, particularly of the first generation (e.g. phenytoin, carbamazepine), may decrease the serum concentration of certain chemotherapy agents by dint of inducing increased hepatic metabolism [37].

As evinced by the yet-sobering statistics on overall GBM survival/patient outcome, there are many-a-challenge and obstacle that remain in treatment, especially regarding the development of resistance to both radiation therapy and, more so, to temozolomide chemotherapy.

8. Signaling pathways in high grade glioma

To understand the fundamentals of GBM oncogenesis, it is essential to understand that there are certain cellular signal transduction pathways responsible for cell proliferation that are normally highly regulated. However, in malignant gliomas, these pathways aberrantly lose regulatory control and end up constitutively activated to disastrous consequence. This occurs mainly through anomalies in the receptors that initiate the signal transduction cascades for growth factors. In one common mechanism, epigenetic mutations result in overexpression or amplification of the genes that encode growth factor receptors. Increased expression of these growth factor receptors results in increased activation of signal transduction cascades. This ultimately yields exponentially increased expression of growth factors which begets malignant cellular proliferation [16].

Some of the best-characterized growth factor mutations in GBM oncogenesis are, as previously introduced, EGFR in primary GBM and PDGFR in secondary GBM. In upwards of 40% of cases of primary GBM, EGFR is amplified to significant pathologic effect (27). Most cases have a genetic lesion of EGFR from deletion of exons 2-7 that results in the anomalous gene *EGFR-vIII*. The normal gene product of the wild-type *EGFR* gene is the EGFR receptor. This receptor, by default, is phosphorylated at the intracellular domain which sets in motion a cascade of signal transduction events that culminates in cell proliferation and survival. In normal cells, the EGFR receptor is regulated by binding of extracellular ligands to the extracellular domain which acts to antagonize phosphorylation at the intracellular domain and thereby down-regulate the mitogenic function of the growth factor cascade. The mutant gene *EGFRvIII* generates the aberrant gene product EGFRvIII that is constitutively phosphorylated/activated due to lacking a down-regulating extracellular ligand-binding domain that would otherwise have been coded by the missing exons 2-7 [16].

There is an ever-burgeoning body of information with the molecular features of malignant gliomas that casts the WHO system in a stark light for the limitations it makes apparent. This molecular information has allowed for determination of discrete subtypes of gliomas within each WHO grade that, through the rigors of clinical trials, have borne out true clinical utility for diagnosis, prognostication and treatment [13]. Within one grade, molecular signatures have identified subtypes that respectively take demonstrably different clinical courses and have discrete treatment responses. Another aspect illuminated by molecular markers is that, when placing a new specimen into one of the 4 WHO grades, there still remains, considerable variability between pathologists/centers. This is particularly so for Grades III and IV [17].

9. Predictive and prognostic molecular markers: Clinical implications

Before embarking further on the discussion of molecular profiling of malignant gliomas, it is imperative to make the distinction that, on the face of it, appears but a matter of simple semantics. Within the context of this discussion, there exists a fundamental difference between Prognostic and Predictive. Prognostic connotes the effect a certain marker gives an outcome that is independent of the therapeutic intervention(s) employed. On the other hand, when a marker is said to have predictive utility, this indicates that it foretells benefit specifically from one type of treatment over others [17].

This discussion will first consider 1p/19q codeletion, a molecular profile that comes from unbalanced translocation between chromosomes 1p and 19q, leading to net loss of genetic material which ultimately leads to loss of one hybrid chromosome, and ultimately, loss of heterozygosity [17]. Mutations have been found in genes that correspond to this translocation; however, the biological underpinnings of these mutations have yet to be understood. The 1p/19q Codeletion has been reliably found in oligodendroglial tumor subtypes that are interspersed between the WHO Grades [17]. Three randomized clinical trials (RTOG 9402, EORTC 26951, NOA-04) have shown that anaplastic oligodendroglioma patients with 1p/19q codeletions have a survival benefit over those without the codeletion when receiving radiation therapy (RT), alkylating chemotherapy, or both [18-20].

First, the RTOG 9402 trial randomly assigned 289 patients with anaplastic oligodendroglioma or anaplastic oligoastrocytoma to receive either adjuvant RT alone or four cycles of Procarbazine/CCNU/Vincristine (PCV) chemotherapy followed by RT (PCV-> RT). Of 201 patients tested by FISH, 93 (46%) were found to have the codeletion. The first initial analysis of results at 3 years out found a median progression free survival (PFS) of 1.7 years for the RT alone contingent vs. 2.6 years for the PCV-> RT contingent; however, no overall survival benefit of either study arm was found at this time, with a median overall survival (OS) of 4.9 years in the PCV-> RT group vs. 4.7 years with RT alone. The 1p/19q codeletion was found to confer an overall survival benefit, with a median OS of > 7 years vs. 2.8 years in those patients without the codeletion. The type of treatment (RT vs. PCV-> RT) was not found to have statistically significant bearing on this increase in OS in patients with tumors possessing the codeletion at this interim analysis of study results. Extended follow up of patients in 2012 continued to show an OS benefit of the 1p/19q codeletion but also found, interestingly, that PCV-> RT did improve survival. At the 2012 reevaluation, those patients without the codeletion had median OS of 2.6 years for PCV-> RT vs. 2.7 years for RT alone, corresponding to earlier results. Those patients with the codeletion who received PCV-> RT were found to have a median OS of 14.7 years vs. 7.3 years with RT alone, yielding a hazard ratio of 0.59 (95% CI, 0.37-0.95; P=0.03).

Very analogous to the RTOG trial was the EORTC 26951 trial, which randomized 368 patients with anaplastic oligodendroglioma or anaplastic oligoastrocytoma to receiving either RT or RT followed by six cycles of PCV (RT-> PCV). In this study, there were 78 patients (21%) whose tumors were found to have the 1p/19q codeletion by FISH. When taken as a whole, the results were similar to the RTOG study, finding that addition of PCV to RT increased PFS to 23 months vs. 13.2 months but not finding a statistically significant difference in OS between the RT alone

group (30.6 months) and the RT-> PCV group (40.3 months) at a median follow-up of 60 months. On stratification of patients based upon co-deletion status, a discernible survival benefit was once again found, with no median OS reached for patients possessing the co-deletion (irrespective of RT-> PCV vs. RT alone) vs. median OS of 25.2 and 21.4 months for RT-> PCV and RT alone, respectively, in patients with partial or no deletion. Updated results from 2012, reflecting a median follow up of close to 12 years, went further to demonstrate that receipt of adjuvant chemotherapy in patients possessing the co-deletion conferred an additional survival benefit, the median OS for the subgroup of 42 patients with co-deleted tumors and receiving RT-> PCV having not been reached vs. median OS for the subgroup of 38 patients with co-deleted tumors receiving RT alone being 9.3 years. With respect to patients without the co-deletion, this study's results were in accord with the RTOG trial, with a median OS of 25 months for the RT-> PCV subgroup vs. median OS of 21 months for the RT alone subgroup.

The third trial, NOA-04, by the German Neuro-Oncology Group, randomized 318 patients with anaplastic astrocytoma, anaplastic oligodendroglioma, and mixed anaplastic oligoastrocytoma into three single modality treatment groups--RT, PCV, or TMZ--by the ratio of 2:1:1, respectively. This study had crossover design built into it, with patients experiencing unacceptable toxicity or progression from RT being further randomized to receive either PCV or TMZ, or patients experiencing unacceptable toxicity or progression from chemotherapy further randomized to RT. In this study, FISH analysis revealed 74 patients (23%) to possess 1p/19q co-deletion. The first analysis of results was undertaken at 54 months of follow-up at which time 43% of patients had met the criteria for treatment failure, the primary endpoint of the study. This analysis revealed that across all groups there was similar PFS and similar OS. As with the RTOG and EORTC studies discussed above, the 1p/19q co-deletion was found to bode well for prognosis, conferring a risk reduction of nearly 50% irrespective of treatment arm.

Thusly, the molecular signature of 1p/19q codeletion has a predictive and prognostic utility as it shows increased overall survival in patients who receive alkylating chemotherapy, radiotherapy or both as compared to those who do not possess it. However, this benefit was not demonstrated in the group comprised of anaplastic astrocytoma which included 53% of the patient population in this study. There was no statistical difference in outcome, time to progression, nor overall survival whether patients were first treated with RT or alkylating chemotherapy. However, given the worse overall prognosis in patients with anaplastic astrocytoma the generally accepted approach to therapy is combined adjuvant chemotherapy-radiation. This approach is extrapolated from data obtained in trials including patients with glioblastoma.

MGMT is a DNA repair protein that canonically exemplifies the concept of chemotherapeutic resistance. It does so by removing the alkylation of the O6 position of Guanine, which represents the seminal mechanism of action of alkylating chemotherapeutic agents. The beneficial epigenetic profile associated with MGMT is methylation of the MGMT promoter, which silences the MGMT gene and thereby reduces the repair of chemotherapy induced alkylation of DNA. This molecular marker was first suggested to have predictive utility by Stupp *et al* in 2005 [21] in a post-hoc analysis of 203 (out of 573 patients treated in that study)

assessable tumors. In that analysis, MGMT methylation status had significant bearing on progression free survival (PFS) in patients from the experimental arm receiving TMZ in addition to RT whereas it showed minimal benefit in PFS in those patients from the control arm receiving RT alone. It was then shown to have prognostic, but not predictive, utility by the results of the RTOG 0525 study, which showed an overall survival benefit of 23.2 months in patients with MGMT methylated tumors vs. 16 months in patients with unmethylated tumors irrespective of whether in the experimental arm (3 weeks on-one week off adjuvant dose-intensified TMZ) or the control arm (standard TMZ) [22]. Based on these results, MGMT methylation status is only accepted as a prognostic factor without predictive value in the population studied. It is also very intriguing to note herein the results of studies aimed at studying single vs. combined modality treatments in elderly patients greater than 70 years of age in whom combined modality treatments are less tolerable and perhaps less effective. These studies showed that in this subset of patients, MGMT methylation status has a predictive utility. Patients with MGMT methylation had longer PFS when receiving chemotherapy plus RT or chemotherapy alone as opposed to RT alone whereas patients without MGMT methylation accrued no comparable survival benefit from chemotherapy [17]. This supposition--that MGMT status is useful as a predictive tool in stratifying elderly patients to receipt of either chemo or RT--was further corroborated by two trials--the NOA-08 trial and the Nordic Trial. The NOA-08 trial, in brief, set out to prove non-inferiority of TMZ alone (one week on one week off) with RT alone in patients 66 years of age and older. While there was no OS or PFS difference between the two arms, it was noteworthy that patients with MGMT methylation showed PFS of 8.4 months vs. PFS of 4.6 in the TMZ arm whereas in the RT arm, MGMT methylation status had the opposite effect, conferring a PFS of 4.6 months in those without MGMT methylation vs. 3.3 months in those with [23]. It is important to note that the temozolomide regimen used in this study varies significantly from the standard schedule used today for patients with glioblastoma. In the Nordic Trial, patients were randomized into one of three groups--standard RT (60 Gy) vs. hypofractionated RT (34 Gy over 2 weeks) vs. standard TMZ schedule. Between the three groups, OS was found to be inferior in the standard RT group when compared to TMZ and hypo fractionated RT. However, MGMT methylation did show better OS in TMZ-treated patients whereas no such benefit was found in RT treated patients [24]. In addition, a recently published meta-analysis performed by Yin et al [25], also supports the predictive value of MGMT methylation status in the elderly population. These results make it reasonable that MGMT status be brought to bear when considering single modality treatment with RT or TMZ in elderly glioblastoma patients.

A third example of genetic/molecular markers that has proven prognostic is the genes IDH1 and IDH2 which encode the ubiquitous metabolic enzyme Isocitrate Dehydrogenase in the cytoplasm and mitochondria, respectively. The native function of wild-type IDH protein is to produce alpha-ketoglutarate. IDH Mutants catalyze a reaction that converts the native metabolic intermediary alpha-ketoglutarate into D-2-hydroxyglutarate, an onco-metabolite (this can be reliably measured by magnetic spectroscopy in situ and mediates the oncogenic activity of the provoking IDH mutations [26]. The classification of gliomas based on IDH is to categorize them based on IDH-wild-type vs. IDH-mutant gliomas. IDH-wild-type tumors are inclusive of Grade I Pilocytic Astrocytomas and Primary Glioblastomas; these, of course,

acquire their tumorigenesis independently of IDH-mutating pathways. IDH-mutant gliomas are inclusive of most Grade II and Grade III Gliomas along with a few Secondary GBMs. It is exceedingly interesting to note that IDH mutants tend to carry a better prognosis than IDH-wild-type gliomas of the same histological grade (e.g. Secondary GBM carries a better prognosis than Primary GBM). Indeed, an insightful pooled analysis of 382 WHO Grade III and IV gliomas by Hartmann et al in 2010 corroborated this--that IDH status bears more valuable prognostic information than simple histological grade [27]. So revelatory has the delineation of gliomas been based on IDH status that, despite unequivocal similarities in histological grade and morphology between tumors that would otherwise have classified them together, it is now considered insufficient that they be grouped together if one were to be IDH-wild-type and the other IDH mutant.

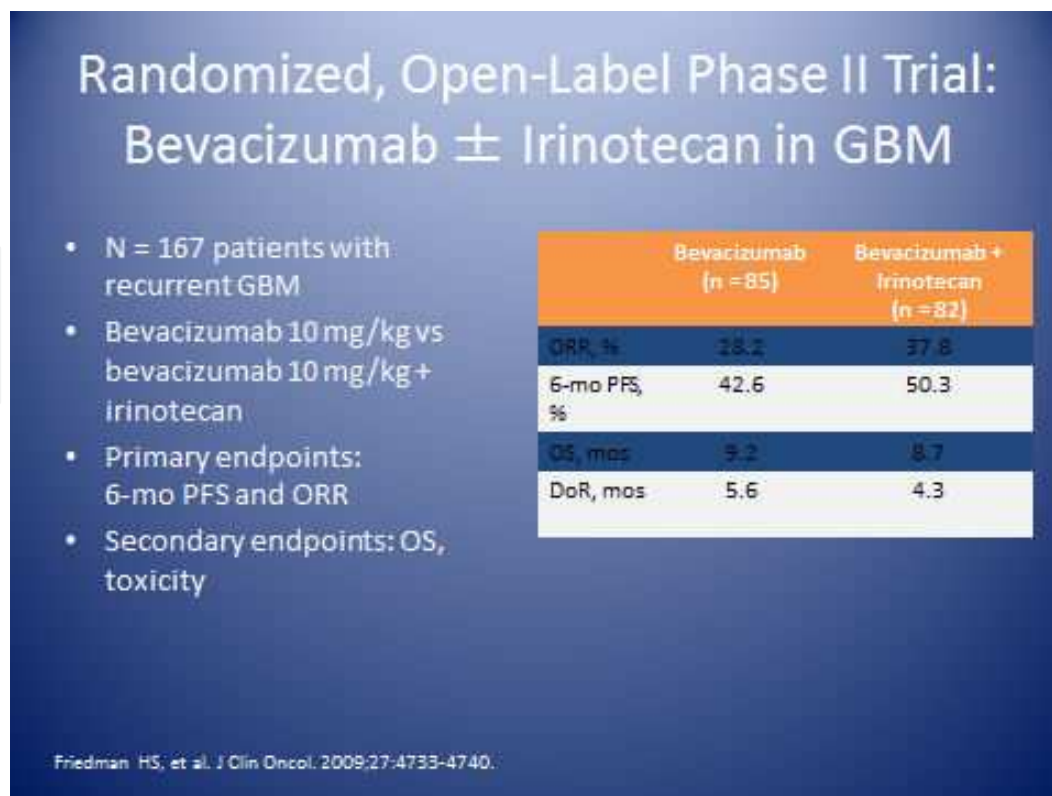
10. Angiogenesis: Vascular Endothelial Growth Factor (VEGF) and Glioblastoma stem-like cells (GSC)

As alluded to earlier in the chapter, angiogenesis is an essential part of the pathogenesis of malignant gliomas which, as a rule, are among the most vascularized of tumors [40, 41]. This is due to: (1) upregulation of genes encoding proangiogenic factors, which include VEGF, fibroblast growth factor (FGF), IL-8 and -6, hypoxia-inducible factor 1 alpha (HIF-1alpha) and angiopoietins, and (2) downregulation of angiogenesis inhibitors, including thrombospondins, angiostatin, endostatin and interferons. Indeed, the lynchpin that begets the transformation from low grade to high grade gliomas is induction of expression of the above-cited proangiogenic factors [40]. The most prominent and well-characterized of the proangiogenic factors is VEGF-A, commonly denoted simply as VEGF, which is directly secreted by tumor cells. VEGF exerts its function by binding the receptor VEGFR2 on endothelial cells nearby the tumor. This action initiates a paracrine signaling loop that results in the proliferation of endothelial cells and, as a result, neo-vasculature. Interestingly, the level of VEGF produced by a tumor is proportional to the degree of malignancy, the aggressiveness and poor outcome; high-grade tumors are found to have orders of magnitude more VEGF than low grade tumors [13, 42]. There has thusly been a significant amount of clinical research focus on anti-angiogenic therapy for malignant gliomas. Anti-angiogenic therapy has multiple hypothesized mechanisms of action for the treatment of malignant gliomas. The primary mechanism of action is direct cytotoxicity to endothelial cells, inducing apoptosis. This, by merit of the resultant attenuated blood supply, decreases oxygen and nutrient delivery to tumor cells which preempts further growth for a short period of time. A second hypothesized mechanism of action based upon the results of select clinical studies is that, when used alongside cytotoxic chemotherapeutic agents, anti-VEGF agents are thought to synergistically sensitize endothelial cells to penetration by these cytotoxic agents. Intriguingly, it is also very likely that anti-VEGF agents work to counteract an upsurge of VEGF expression and endothelial cell recruitment observed with the tumoral insult caused by chemotherapy and radiation. Another hypothesis is that, during a discrete window of time after administration, anti-VEGF agents elicit a phenomenon known as “vascular normalization” during which there is reduced vessel diameter/permeability,

improved vessel perfusion, a reduction in tumor interstitial pressure, and improved tumor oxygenation. Summarily, these changes all translate into an observed improvement in the delivery and efficacy of cytotoxic chemotherapy. A newer and exceedingly compelling hypothesis is that antiangiogenic agents appear to exercise antagonism to Glioblastoma stem-like cells (GSCs). GSCs play an inextricable part in the angiogenic potentiation of malignant gliomas. They appear to contribute to the resistance that glioblastoma is known to have to cytotoxic chemotherapy treatment by augmenting the repair of DNA damaged by cytotoxic agents and activating the DNA damage checkpoint response system. Antiangiogenic therapy appears to antagonize the functionality of GSCs by merit of GSCs embodying a categorically structural and functional vascular niche in the tumoral micro-milieu. GSCs have been found to upregulate VEGF expression, instigate formation of very angiogenic tumors in animal models, and bear a predilection for stem cell hot beds in areas around endothelial cells. In the self-same animal models, antiangiogenic agents appear to fundamentally disrupt the structural framework of the hot beds in which GSCs reside and resultantly provoke GSC death.

The canonical agent that has garnered the most investigation and use is the humanized anti-VEGF monoclonal antibody bevacizumab, originally used for treating colorectal cancer and also used routinely for metastatic lung adenocarcinoma. Its use for CNS tumors, recurrent gliomas in particular, was conceived of after improved outcomes were noted when it was used in conjunction with chemotherapy for colorectal and lung cancers. Recurrent gliomas have historically had a low radiographic response rate after re-exposure to temozolomide after failing initial therapy, ranging from only 5-8%. However, in the very first published study of the use of bevacizumab with irinotecan, a radiographic response rate of 66% (19 of 29 patients) was found [40]. This was followed by a number of retrospective studies on recurrent gliomas which showed progression free survival at 6 months (PF6) of 32-64% with bevacizumab vs. 21% PF6 rate for temozolomide [13]. The aggregate of these very positive results prompted two phase 2 trials designed for the purposes of fast track FDA approval of bevacizumab for the indication of recurrent gliomas. These two trials corroborated the prior results--a significant radiographic response rate and increase in PF6. The largest bevacizumab trial to date, designated the BRAIN trial and conducted by Freidman et al in 2009, randomized patients with glioblastoma either after first or second recurrence to be treated with bevacizumab alone (n=85) or bevacizumab plus irinotecan (n=82). Both response rates (using MacDonald response criteria) and six month progression free survival were markedly higher when compared to historical controls in both groups (higher response rate in bevacizumab plus irinotecan group). However, overall survival was not statistically significant between the two groups at 9.2 months for bevacizumab alone and 8.7 months for the combination regimen. Bevacizumab was well tolerated. The most common or significant adverse events included thromboembolic events, hypertension and proteinuria.

It is important to remind the reader here of the interdependence between angiogenesis and the propagation of peritumoral edema in malignant gliomas. In fact, the original name for VEGF was vascular permeability factor due to its increasing the permeability of tumor vessels, which leads to the phenomenon of vasogenic brain edema. Vasogenic brain edema is a telltale hallmark of malignant gliomas and qualifies much of the morbidity associated with them. It



is for this reason that many patients with brain tumors are maintained over long periods of time on high doses of corticosteroids, not without insubstantial side effects. Both clinical and radiographic studies have found reductions in peritumoral edema with the administration of anti-VEGF agents. This in turn allowed for reduction in corticosteroid use by as much as 50%, a significant benefit for many of the patients experiencing the multifarious ill effects of chronic corticosteroid use [41].

11. Hypoxia as means of resistance and poor outcome

Despite the many promising aspects of antiangiogenic therapy outlined above, there have recently come to the fore many challenges that remain to the use of antiangiogenic agents for the treatment of malignant gliomas. One challenge that has become evident is based upon, in a matter of speaking, “tipping the balance” too far towards antiangiogenesis by significant use of antiangiogenesis agents. Animal and human biopsy results have showed that when used overzealously, antiangiogenic therapy actually works to promote a hypoxic environment within the tumor bed. Tumor hypoxia has been well established as a formidable means of resistance to chemotherapy and radiation [38]. Pre-clinical data obtained from xenograft models suggests that hypoxia and the hypoxia-inducible factors (HIFs) play a central role in maintaining the stem-like fraction in gliomas. This is achieved by providing the essential cellular interactions and signals needed to arrest differentiation of these stem-like cells. These interactions lead to stem-like cell survival and self-propagation. Upregulation of HIF-1alpha

also activates autophagy, a lysosomal degradation pathway which may promote tumor cell survival.

Though clinical trials have largely focused on VEGF-A antagonism through bevacuzimab, there are a multitude of other pro-angiogenic factors/cytokines that contribute to glioma angiogenesis, including basic FGF (bFGF), angiopoietins, PDGF, interleukin-8 (IL-8), and hepatocyte growth factor/scatter factor (HGF/SF). It is thought that the contribution of these alternative mediators of angiogenesis mediate the phenomenon of antioangiogenic therapy resistance. In other words, these alternative proangiogenic factors are thought to allow for continuing angiogenesis in the face of VEGFR inhibition. Quite sobering is the harsh reality that though antiangiogenic therapy does prolong PFS and response rates are high in patients with recurrent GBM/gliomas, progression of disease inevitably occurs and once tumor burden breaks through, no therapeutic recourse presently exists. Confoundingly, patients with recurrent GBM die very shortly after failing antiangiogenic therapy (figure 8) [44].

Author	N	Treatment	Median PFS, Wks	6-Mo OS, %	Median OS, mos
Norden ^[1]	23	Bevacizumab + a different chemo (most often carboplatin)	7	2	NS
Kreis ^[2]	19	Bevacizumab + irinotecan	4	0	NS
Quant ^[3]	35	Bevacizumab + carboplatin	5	3	3.0
Iwamoto ^[4]	19	Bevacizumab + chemo	8	0	5.2

Figure 8. Post-Bevacizumab Salvage Therapy [44]

12. Response criteria and pseudoprogression

Anti-angiogenic agents also have made assessing response and progression a nebulous task. Prior to the era of anti-angiogenic agents, response assessment was performed via the MacDonald criteria which only utilized post-gadolinium MRI sequences. It was previously accepted that a decrease in enhancement represents eradication of tumor but this has proven not to be entirely valid with the use of anti-angiogenic agents. The development of a post-treatment hypoxic microenvironment favors a metabolic change in the tumor cells toward glycolysis, which leads to enhanced tumor cell invasion into the normal brain that is not represented by MRI contrast enhancement. Pre-clinical data suggests that Anti-VEGF treatment reduces vessel contrast leakage, reduces vessel density and promotes invasiveness of tumor cells which can be observed by an incongruent decrease in contrast enhancement along

with hyper-intense T2 FLAIR MRI signal. Due to this new understanding, a revised response criteria was developed that, in addition to post-gadolinium sequences, incorporates FLAIR MRI sequences, steroid dependence and clinical stability. This new set of criteria is known as the RANO criteria (Response Assessment in Neuro-Oncology) and now is standard in clinical practice.

Response	Criteria	
	Macdonald criteria	RANO criteria
Complete response	All: complete disappearance of all enhancing measurable and nonmeasurable diseases sustained for at least 4 weeks, no new lesions, no corticosteroids, and being stable or improved clinically.	All: T1 gadolinium enhancing disease, none; T2/FLAIR, stable or decreasing; new lesion, none; corticosteroids, none; clinical status: stable or improving.
Partial response	All: $\geq 50\%$ decrease in sum of products of perpendicular diameters of all measurable enhancing lesions sustained for at least 4 weeks, no new lesions, stable or reduced corticosteroid dose, and being stable or improved clinically.	All: T1 gadolinium enhancing disease, $\geq 50\%$ decrease; T2/FLAIR, stable or decreasing; new lesion, none; corticosteroids, stable or decreasing; clinical status: stable or improving.
Stable disease	All: being not qualified for complete response, partial response, or progression; being stable clinically.	All: T1 gadolinium enhancing disease: $< 50\%$ decrease but $< 25\%$ increase; T2/FLAIR: stable or decreasing; new lesion: none; corticosteroids: stable or decreasing; clinical status: stable or improving.
Progression	Any: $\geq 25\%$ increase in sum of the products of perpendicular diameters of enhancing lesions, any new lesion, or clinical deterioration.	Any: T1 gadolinium enhancing disease: $\geq 25\%$ increase; T2/FLAIR: increasing; new lesion: none; corticosteroids: not applicable; clinical status: deteriorating.

RANO: Response Assessment in Neuro-Oncology; FLAIR: fluid-attenuated inversion recovery.

An important concept to invoke at this juncture, and one unique to the treatment of Glioblastoma with chemotherapy and radiation, is that of Pseudoprogression. A few months after completion of concurrent temozolomide with radiation, many patients show increased contrast enhancement and T2/FLAIR hyperintensity in the radiation treatment field. This generally occurs about 3 months after completion of chemo-radiation and sometimes persists for about 6 months. The MacDonald criterion does not take this phenomenon into account when defining disease progression. The more contemporary RANO criteria defines progression at less than 12 weeks after chemoradiotherapy as the development of a new area of enhancement outside of the prior radiation field, confirmed tumor via biopsy, or clinical decline. Pseudoprogression, as the name implies, denotes these changes that are not due to tumor progression, but rather due to unique cytotoxic effects on the tumor and its microenvironment. Approximately 1/3 of patients with pseudoprogression are found to be symptomatic due to associated inflammation and edema and require treatment with corticosteroids. There is preliminary evidence at hand that indicates that administration of an anti-VEGF agent with standard of care concurrent temozolomide and radiation may reduce the incidence of pseudoprogression [45]. As in the case of vasogenic cerebral edema, this may spare, if not limit, the ill effects of heavy corticosteroid use in many patients. Distinguishing pseudoprogression and true disease progression is very challenging and new imaging techniques (i.e. MR spectroscopy, MR perfusion study) are being developed to help with this dilemma and guide treatment approach. Accumulating data shows promise using these new techniques but have yet to be validated in large clinical studies.

13. Bevacizumab as first line therapy

Two large phase III double-blinded randomized studies published in NEJM in February, 2014 evaluated the use of bevacizumab in the first line setting in patients with glioblastoma. Gilbert et al, led a study that randomized 637 patients with newly diagnosed glioblastoma to standard six weeks of chemo-radiotherapy (adjuvant temozolomide and concurrent radiotherapy) followed by up to twelve months or until disease progression of maintenance temozolomide, with or without bevacizumab starting at week four of chemo-radiotherapy [46]. The results were disappointing in that no survival benefit was determined between the two groups. The bevacizumab group reported a median overall survival (OS) of 15.7 months and the placebo group had an OS of 16.1 months. Progression-free survival favored the bevacizumab group at 10.7 months vs. 7.3 months in the placebo group. Interestingly, over time the patients who received bevacizumab did not benefit from a quality of life standpoint despite better response rates. These points further reinforce the question as to whether PFS is an appropriate surrogate maker for overall survival.

A second published in the same issue of NEJM performed by Chinot et al, studied the use of bevacizumab in the front line setting as well [49]. Similar conclusions were reported in this study compared to the performed by Gilbert et al. The treatment regimen used in the study differed in that after 6 months of maintenance temozolomide with or without bevacizumab were continued with bevacizumab alone or placebo until disease progression or until suffering from intolerable side effects. The results were again disappointing in that the addition of bevacizumab to standard chemo-radiation and maintenance therapy with this anti-angiogenic agent did not provide a survival benefit (72% and 33.9% one and two year survival rate respectively in the bevacizumab group versus 66.3% and 30.1%) despite a significantly better PFS (10.6 months in bevacizumab group vs. 6.2 months in placebo group). Baseline quality of life was maintained for a longer period of time in the bevacizumab group.

These results, in particular the study by Gilbert et al, appears to possibly support the use of maintenance temozolomide for twelve months instead of traditional standard therapy with six months as conducted in the landmark study by Stupp et al now considered standard of care. This is a question that every neuro-oncologist has to address when treating patients with newly diagnosed glioblastoma. Although difficult to extrapolate data from two separate studies, no large scale study has been performed making a direct comparison of twelve months versus six months of maintenance temozolomide. However, this data suggests that twelve months of maintenance temozolomide leads to an improvement in OS reporting 16.1 months versus 14.6 months reported in the EORTC trial led by Stupp et al.

14. Patterns of recurrence

As we gain more experience using anti-angiogenic agents in high grade gliomas, we also learn more about what occurs after treatment failure. Mancuso et al. conducted a pre-clinical study

using a mouse xenograft model to address the reversibility of VEGF inhibition after cessation of anti-VEGF therapy. It was noted that even after a 50–60% reduction of tumour vascularity, “empty sleeves of basement membrane were left behind.” By day 7 after drug cessation, tumours were fully re-vascularized, suggesting that these remaining empty sleeves of basement membrane and pericytes are responsible for this tumor revascularization. These basement membranes also serve as storage sites for angiogenic growth factors as well as “tracks” for tumor vascular regrowth. This “rebound” phenomenon has also been observed in clinical studies (figure 9) [46]. This phenomenon appears to be associated with rapid clinical demise and dismal prognosis.

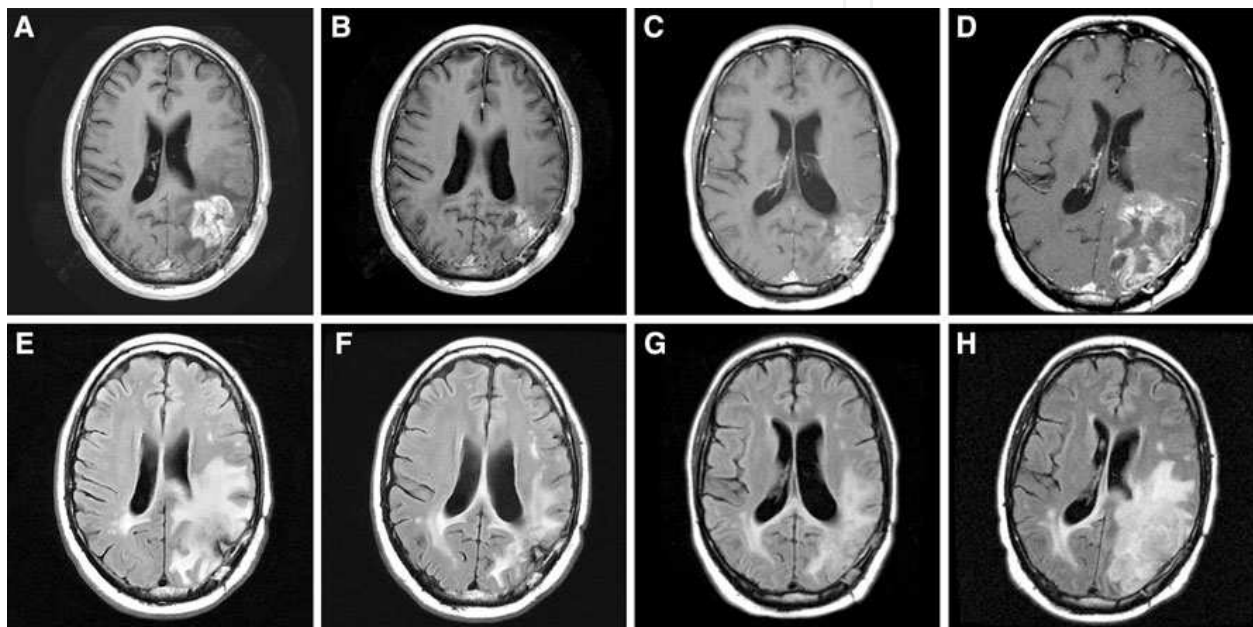


Figure 9. Rebound progression after discontinuation of bevacizumab: Original tumor area seen on post-Gd T1 weighted (a) and FLAIR MRI (e) sequences prior to initiating therapy with bevacizumab in a patient with recurrent high-grade glioma. Post-Gd T1 weighted (b) and FLAIR MRI (f) sequences that demonstrate partial response after 1 six-week cycle of treatment with bevacizumab. Post-Gd T1 weighted (c) and FLAIR MRI (g) sequences at the time of bevacizumab failure and subsequent cessation of bevacizumab therapy. Post-Gd T1 weighted (d) and FLAIR MRI (h) sequences at the time of “rebound” progression demonstrating a dramatic increase in area of enhancement and abnormal FLAIR signal 6 weeks after cessation of therapy with bevacizumab. [44]

15. MicroRNA – Potential target

MicroRNAs (miRNAs) are molecules of RNA numbering 20-23 nucleotides that function to interfere with messenger RNA (mRNA) translation into protein, the final step in gene expression. Through a complex and elegantly-characterized molecular sequence of steps, miRNAs function to “flag” mRNAs for decay, translational inhibition, or cleavage prior to the process of translation. This, in turn, results in a decreased level of encoded proteins, which in turn affects a myriad of essential cell functions, i.e. growth, proliferation, metabolism, apoptosis, etc. [43] Interestingly, though miRNA constitutes roughly 1-3% of

the human genome, it is postulated that these molecules have influence on as much as ~30% of all gene expression [44]. The expression of one mRNA may be affected by numerous miRNAs; on the same token, one miRNA may affect the expression of multiple mRNAs [44]. The deregulation of miRNA has been pivotally implicated in tumorigenesis; a positive association has been found between those sites in the human genome associated with cancer and areas of miRNA expression [44]. Furthermore, miRNAs have been found to exemplify both oncogenic and tumor suppressor functions in the tumorigenesis of pancreatic cancer, prostate cancer, thyroid cancer, ovarian cancer, colon cancer, breast cancer, and melanoma. Of recent, the same has also been found in GBM wherein a multitude of miRNAs have been reported to have roles in tumor suppression or oncogenesis. Therapeutic strategies with respect to miRNA aim to augment tumor suppression or antagonize oncogenesis, respectively. In the former case, it is postulated that viral vectors may be utilized to deliver gene therapy to increase the *in situ* expression of tumor suppressive miRNAs. In the latter case, studies pursuing anti-miRNA therapies, e.g. the use of anti-miRNA oligonucleotides, are underway for downregulation of oncogenic miRNAs [44].

16. Promising treatment approaches: Convection enhanced nanoparticle delivery

An utterly novel modality of treatment actively under investigation is the utilization of nanoparticles for the directed delivery of radionuclides into tumor bed. The premise behind this modality is to maximize delivery of radiation therapy to tumor tissue while limiting damage to surrounding normal tissue; external beam radiation is limited to 60 Gy due to toxicity to normal tissue and lack of clinical benefit with higher dose of EBRT. Recently, studies have been published in which radionuclide particles, e.g. 186-Rhenium, are encased in liposomal nanoparticles and injected straight into the GBM tumor bed. In a study published in 2012, Brenner *et al* injected 186-Rhenium liposomes directly into GBM Xenografts transplanted into the brains of rat models. It was found that up to 1850 Gy could be delivered by this method without overt clinical or microscopic evidence of toxicity. Those animals in the experimental arm treated with 186-Rhenium liposomes were found to have a median survival of 126 days vs. a median survival of 49 days for those animals in the control group. Compellingly, it was found that a large number of the animal subjects that were treated 21 days after tumor grafting were found to have multiple objective indicators of tumor cure (See Figure 10). This included lack of detecting contrast-enhancing tumor on MRI, lack of detecting luminescence by the luminescent molecule embedded in tumor cells, and no tumor cells found on histopathology of resected animal brain tissue. These results suggest that nanoparticle delivery of radioisotopes to the cavities of resected GBM either intra- or postoperatively may have limitless therapeutic potential, particularly when used alongside adjuvant cytotoxic chemotherapy [45].

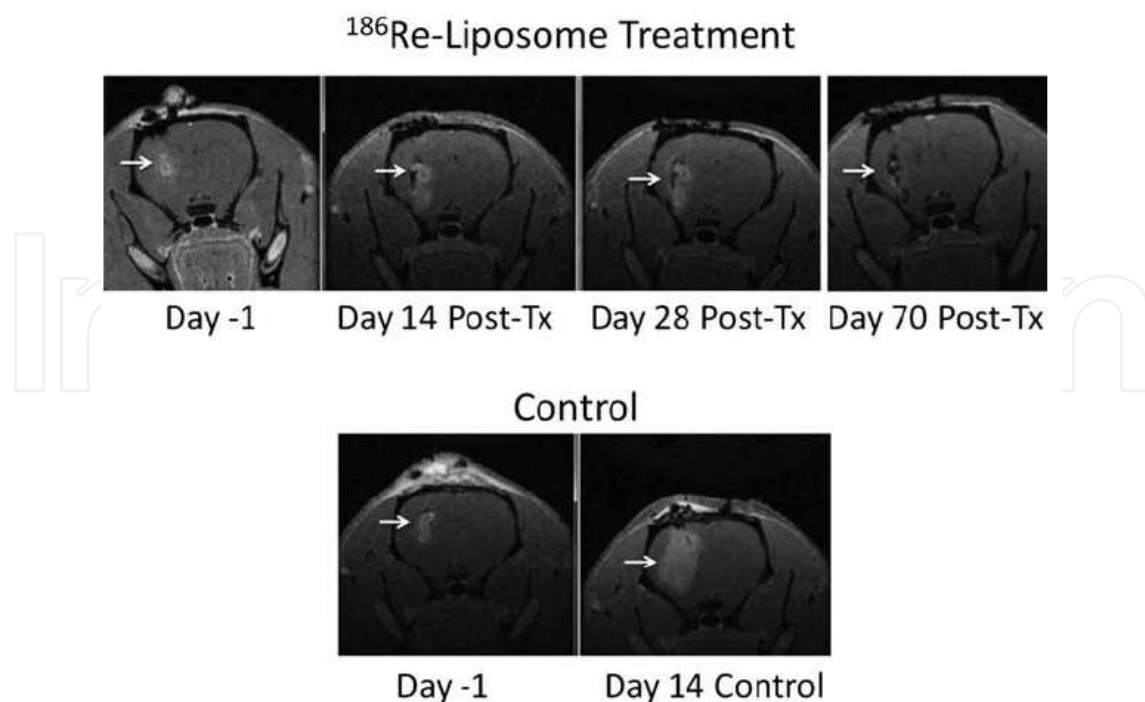


Figure 10. [45]

17. Conclusion

Glioblastoma is a deadly and devastating disease that is, as this chapter has made abundantly clear, in need of the development of effective new agents to treat this aggressive tumor. Our understanding of the intrinsic molecular and genetic make of this tumor, although still lacking, has improved rapidly over the past decade and has shed light on current obstacles and is leading to an array of promising agents on the horizon.

Author details

Siddharth K. Joshi¹ and Richard Zuniga^{2*}

*Address all correspondence to: rickzunigaperu@hotmail.com

¹ Department of Medicine, New York Methodist Hospital, Brooklyn, New York, USA

² Department of Medicine-Division of Hematology-Oncology, New York Methodist Hospital, Brooklyn, New York, USA

References

- [1] Bleeker, FE et al. Recent Advances in the Molecular Understanding of Glioblastoma. *J Neurooncol* 2012;108:11-27.
- [2] Krex, D. et al. Long-term survival with glioblastoma multiforme. *Brain* 2007;130:2596-2606.
- [3] Ostrom Q.T. et al. CBTRUS Statistical Report. *Neuro-Oncology* 2013;15:ii1-ii56.
- [4] Neglia J.P. et al. New Primary Neoplasms of the CNS in Survivors of Childhood Cancer 2006. *JNCI* 2006;98(21):1528-37.
- [5] Grossman SA, et al. CNS Cancers in First-Degree Relatives and Spouses. *Cancer Invest* 1999;17:299-308.
- [6] Alentorn, A. et al. [Genetics and Brain Gliomas] *Presse Med* 2013;42(5): 806-13.
- [7] Vilchez, RA et al. Simian virus 40 in human cancers. *Am J Med* 2003;114(8): 675-84.
- [8] Crawford JR et al. Detection of human herpesvirus-6 variants in pediatric brain tumors: association of viral antigen in low grade gliomas. *J Clin Virol* 2009;46(1):37-42.
- [9] Chi, J et al. Human herpesvirus 6 latent infection in patients with glioma. *J Infect Dis* 2012;206(9):1394-8.
- [10] Cobbs, CS et al. Human Cytomegalovirus Infection and Expression in Human Malignant Glioma. *Cancer Research* 2002;62:3347-3350.
- [11] Kan, P et al. Cellular phone use and brain tumor: a meta-analysis. *J Neurooncol* 2008;86(1):71-8.
- [12] Hardell, L et al. Epidemiological evidence for an association between use of wireless phones and tumor diseases. *Pathophysiology* 2009;16(2-3):113-22.
- [13] Van Meir, EG et al. Exciting New Advances in Neuro-Oncology: The Avenue to a Cure for Malignant Glioma. *CA Cancer J Clin* 2010;60(3):166-193.
- [14] Smith, SL et al. Dendritic spikes enhance stimulus selectivity in cortical neurons in vivo. *Nature* 2013;503(7474):115-120.
- [15] Louis, DL et al. The 2007 WHO Classification of Tumours of the Central Nervous System. *Acta Neuropathol* 2007;114:97-109.
- [16] Wen, PY and Kesari, S. Malignant Gliomas in Adults. *NEJM* 2008;359:492-507.
- [17] Weller, M et al. Personalized care in neuro-oncology coming of age: why we need MGMT and 1p/19q testing for malignant glioma patients in clinical practice. *Neuro-Oncology* 2012;14:iv100-iv108.

- [18] Cairncross JG et al. Chemotherapy plus radiotherapy (CT-RT) versus RT alone for patients with anaplastic oligodendro-glioma: long-term results of the RTOG 9402 phase III study. *J Clin Oncol* 30:2008b.
- [19] Van den Bent MJ et al. Adjuvant procarba-zine, lomustine, and vincristine improves progression-free survival but not overall survival in newly diagnosed anaplastic oligodendrogliomas and oligoastrocytomas: a randomized European Organisation for Research and Treatment of Cancer phase III trial. *J Clin Oncol* 2006;24:2715-2722.
- [20] Wick W et al. NOA-04 randomized phase III trial of sequential radiochemotherapy of anaplastic glioma with PCV or temozolomide. *J Clin Oncol* 2009;27:5874-5880.
- [21] Stupp, R et al. MGMT Gene Silencing and Benefit from Temozolomide in Glioblastoma. *NEJM* 2005;352:997-1003.
- [22] Gilbert MR, et al RTOG 0525: A randomized phase III trial comparing standard adjuvant temozolomide (TMZ) with a dose-dense (dd) schedule in newly diagnosed glioblastoma (GBM). [Abstract] *J Clin Oncol* 2011; 29:2006.
- [23] The NOA-08 Study Group of the Neuro-oncology Working Group (NOA) of the German Cancer Society. Temozolomide chemotherapy alone versus radiotherapy alone for malignant astrocytoma in the elderly: the NOA-08 randomised, phase 3 trial. *Lancet Oncol* 2012;13:707-715.
- [24] Malmstrom A et al. Temozolomide versus standard 6-week radiotherapy versus hypofractionated radiotherapy for patients aged over 60 years with glioblastoma: the Nordic randomized phase 3 trial. *Lancet Oncol* 2012;13(9):916-26.
- [25] Yin A-a, Zhang L-h, Cheng J-x, Dong Y, Liu B-l, et al. The Predictive but Not Prognostic Value of MGMT Promoter Methylation Status in Elderly blastoma Patients: A Meta-Analysis. *PLoS ONE* 2014;9(1):e85102.
- [26] Stupp R et al. Molecular neuro-oncology in clinical practice: a new horizon. *Lancet Oncol* 2013;14:e370-79.
- [27] Hartmann C et al. Patients with IDH1 wild type anaplastic astrocytomas exhibit worse prognosis than IDH1-mutated glioblastomas, and IDH1 mutation status accounts for the unfavorable prognostic effect of higher age: implications for classification of gliomas. *Acta Neuropathol* 2010;120:707–18.
- [28] Ohgaki, H and Kleihues, P. Genetic alterations and signaling pathways in the evolution of gliomas. *Cancer Sci* 2009;100(12):2235-2241.
- [29] Ohgaki, H and Kleihues, P. Population-based studies on incidence, survival rates, and genetic alterations in astrocytic and oligodendroglial gliomas. *J Neuropathol Exp Neurol* 2005;64:479–89.
- [30] Chang, SM et al. Patterns of care for adults with newly diagnosed malignant glioma. *JAMA* 2005;293(5):557-64.

- [31] Stall, B et al. Comparison of T2 and FLAIR imaging for target delineation in high grade gliomas. *Radiation Oncology* 2010;5:5.
- [32] Stummer W et al. Extent of resection and survival in glioblastoma multiforme: identification of and adjustment for bias. *Neurosurgery* 2008;62:564-76.
- [33] Stupp R. et al. Radiotherapy plus Concomitant and Adjuvant Temozolomide for Glioblastoma. *NEJM* 2005;352(10):987-96.
- [34] Rong Y et al. 'Pseudopalisading' necrosis in glioblastoma: a familiar morphologic feature that links vascular pathology, hypoxia, and angiogenesis. *J Neuropathol Exp Neurol* 2006;65(6):529-39.
- [35] Smirniotopoulos, JG et al. Patterns of Contrast Enhancement in the Brain and Meninges. *Radiographics* 2007;27:525-551.
- [36] Stupp, R. and Roila, F. Malignant glioma: ESMO Clinical Recommendations for diagnosis, treatment and follow-up. *Annals of Oncology* 20 (Supplement 4) 2009; iv126-iv128.
- [37] Stark VV. Bevacizumab and CPT-11 in the treatment of relapsed malignant glioma. *Neurooncol* 2005;7:369.
- [38] Reardon, DA and Wen, PY. Therapeutic Advances in the Treatment of Glioblastoma: Rationale and Potential Role of Targeted Agents. *The Oncologist* 2006; 11:152-164.
- [39] Reardon, DA et al. Glioblastoma multiforme: an emerging paradigm of anti-VEGF therapy. *Expert Opin Biol Ther* 2008;8(4):541-553.
- [40] Leon, SP et al. Microvessel density is a prognostic indicator for patients with astroglial brain tumors. *Cancer* 1996;77(2):362-72.
- [41] Moller, HG, Rasmussen AP et al. A Systematic Review of MicroRNA in Glioblastoma Multiforme: Micro-modulators in the Mesenchymal Mode of Migration and Invasion. *Mol Neurobiol* 1996;47:131-144.
- [42] LeBrun, DL and Li, M. MicroRNAs in Glioblastoma Multiforme: Profiling Studies and Therapeutic Impacts. *Mol Cell Pharmacol* 2011;3(3):93-105.
- [43] Phillips WT, Zuniga, RM, Brenner, AJ *et al.* Rhenium-186 liposomes as convection-enhanced nanoparticle brachytherapy for treatment of glioblastoma. *Neuro-Oncology* 2012;14(4):416–428.
- [44] Zuniga, RM, Torcuator R et al. Rebound tumour progression after the cessation of bevacizumab therapy in patients with recurrent high-grade glioma. *J Neurooncol* 2010;99(2):237-42.
- [45] Pinho M, Polaskova P, Jennings D, et al. Impact of adjuvant anti-VEGF therapy on treatment-related pseudoprogression in patients with newly diagnosed glioblastoma

receiving chemoradiation with or without anti-VEGF therapy. J Clin Oncol 2012;30(suppl;abstr 2025).

- [46] Gilbert, M et al. A Randomized Trial of Bevacizumab for Newly Diagnosed Glioblastoma. N Engl J Med 2014;370:699-708.
- [47] Chinot, O et al. Bevacizumab plus Radiotherapy–Temozolomide for Newly Diagnosed Glioblastoma. N Engl J Med 2014;370:709-722.

