

We are IntechOpen, the world's leading publisher of Open Access books Built by scientists, for scientists

6,900

Open access books available

186,000

International authors and editors

200M

Downloads

Our authors are among the

154

Countries delivered to

TOP 1%

most cited scientists

12.2%

Contributors from top 500 universities



WEB OF SCIENCE™

Selection of our books indexed in the Book Citation Index
in Web of Science™ Core Collection (BKCI)

Interested in publishing with us?
Contact book.department@intechopen.com

Numbers displayed above are based on latest data collected.
For more information visit www.intechopen.com



Sliding Inguinal Hernias

Andrzej L. Komorowski, David Domínguez Usero,
José Ramón Martín-Hidalgo Rodil and
Jorge Morán-Rodríguez

Additional information is available at the end of the chapter

<http://dx.doi.org/10.5772/58223>

1. Introduction

A sliding inguinal hernia is a protrusion of a retroperitoneal organ through an abdominal wall defect. Frequency of sliding hernias is estimated at 3-8% of all elective operations of inguinal hernias. Sliding hernias are supposed to be more anatomically challenging for a surgeon than an uncomplicated non-sliding inguinal hernias. The anatomical and physiological concept of sliding inguinal hernia is frequently misunderstood by surgeons of all levels of experience. Not infrequently, any inguinal hernia that is big enough or has any organ (e.g. small intestine) inside its sac is referred to as sliding hernia. In this chapter we will try to clarify the pathology behind the sliding inguinal hernia and explain its correct management.

2. History and current classification

Sliding hernias are known to surgeons for almost three centuries. Since the first description by Italian surgeon and anatomist from Pavia, Antonio Scarpa in 1809 [1] they were feared as a complicated surgical conditions. The main obstacle in surgical approach to this type of hernias was-and still is-the fact that part of the hernia sac is in reality a retroperitoneal organ thus, during opening of the sac an inadvertent damage to a vital organ can be made. The advance of anatomical knowledge and evolution of surgical technique allowed for a better understanding of this entity. With the better understanding of pathological anatomy of the sliding hernia various classification systems have been introduced. Currently the best and most frequently used classification of sliding hernias is the one by Robert Bendavid [2]. Bendavid divides the sliding inguinal hernia into three anatomical variants depending on the size of the sac and its relation to the retroperitoneal „slided” organ. Type I is defined as any hernia in which part of

the peritoneal sac is made up by the wall of a viscus (Figure 1). Type II is defined as any hernia containing a retroperitoneal viscus and its mesentery, in which the mesentery forms part of the wall of the peritoneal sac (Figure 2). In type III the sliding hernia consists on a protrusion of a viscus itself, and the peritoneal sac is very small or even absent. This last variant is an extremely rare finding and accounts for approximately only 0.01% of all inguinal hernias. Figure 1 and Figure 2 depict in a schematic way two most common types of sliding inguinal hernias according to Bendavid. We strongly advocate the use of this classification in everyday practice as it enables surgeons to better understand the concept and hence better plan the operation of a sliding inguinal hernia.

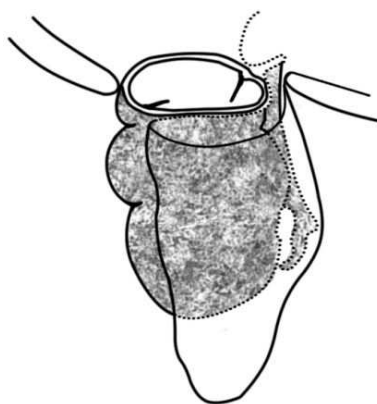


Figure 1. Schematic drawing of Bendavid Type I sliding inguinal hernia. The posterolateral aspect of the hernia sac is made up of the caecum and ascending colon. This type of sliding inguinal hernia accounts for almost 95% of all sliding inguinal hernia cases. The most common contents are: sigmoid, caecum, appendix (by dr Jerzy W. Mituś based on Bendavid [2]).

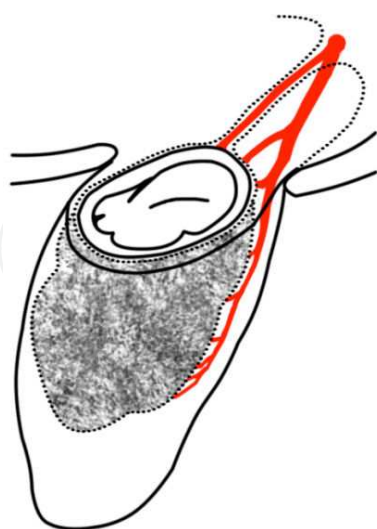


Figure 2. Schematic drawing of Bendavid Type II sliding inguinal hernia. In this hernia the mesentery forms part of the posterior wall of the sac and part of the anterior wall of the caecum forms part of the posterior wall of the sac. This type of sliding inguinal hernia accounts for about 5% of all sliding inguinal hernia cases. The most common contents is sigmoid (by dr Jerzy W. Mituś based on Bendavid [2]).

3. Clinical presentation

Sliding hernia is quite a common finding in infant girls: up to 20% of all hernias in this group of patients are sliding hernias containing ovary and fallopian tube [3]. In the adult population almost all cases of sliding hernias are seen in men [4, 5] with only isolated reports of sliding inguinal hernias in women [6]. Frequency of the sliding hernia in adults was historically estimated at around 6–8% of all hernia cases [4] but more recent report by our group estimate its frequency at 3.4% [5]. Most probably it is due to the fact that today's hernia patient present with smaller hernias with shorter duration of symptoms or even before the onset of symptoms. The sliding hernias tend to occur in older patients that develop symptoms for quite a long time. In one of the biggest series of inguinal sliding hernias, published by Ryan in 1956, the average age of patients with sliding hernia was 60 years [4]. On the other hand, in our recently published series the average age of patients presenting with sliding inguinal hernia was estimated at 70 [5] and is higher than some current series reporting a mean age of 63 years [7]. The mean duration of symptoms in the series by Ryan was 12 years, 6 years in our series and in some reports it can be as low as 9 months [8]. As one can see the age of patients and duration of symptoms have dropped over the time, but still are higher than the same numbers describing current general population of inguinal hernia patients. The mean age of an inguinal hernia patient is estimated at 53 years and the mean duration of symptoms at 2.8 years for UK patients [9]. These numbers can be quite different in some selected groups of patients as in the aforementioned report by Adams which cited only 9 months median duration of symptoms of a sliding inguinal hernia patients in his Australian patient population [8].

It is very rare to establish preoperative diagnosis of a sliding inguinal hernia as there are no particular clinical signs indicating the possibility of sliding hernia. Older patients with big hernias, presenting with a long history of inguinal lump are the group most likely to have a retroperitoneal organ protruding into the hernia sac [5]. In the literature there are rare case reports of preoperative diagnosis of a sliding inguinal hernia containing urinary bladder based on a plain abdominal x-ray showing urinary bladder calculi within the groin [10]. However, in the vast majority of cases the diagnosis is made after the hernia sac is opened (as seen on Figure 3). If a surgeon does not open a hernia sac, a small sliding hernia can be easily overlooked. If the sac is manipulated gently this should not have any influence on the outcome of surgery in terms of early and late complications. As in the current practice it is becoming increasingly rare for surgeons to routinely open an inguinal hernia sac, a number of sliding hernias can undergo surgery without being recognized as such.

Interestingly, important percentage of sliding inguinal hernias can present as complicated cases with almost 12% of all sliding hernias presenting with intestinal obstruction to the emergency department [7]. This finding is obviously absent in reports on sliding hernias that are dealing only with elective inguinal hernia cases [5].

Another possible form of acute presentation of a sliding inguinal hernia is a perforation of the cancer of the sigmoid colon forming part of the hernia sac. This complication, although extremely rare implies a change in operative strategy as correction of the hernial defect falls

behind the priorities of resolving perforation and performing adequate oncologic colon resection [11].

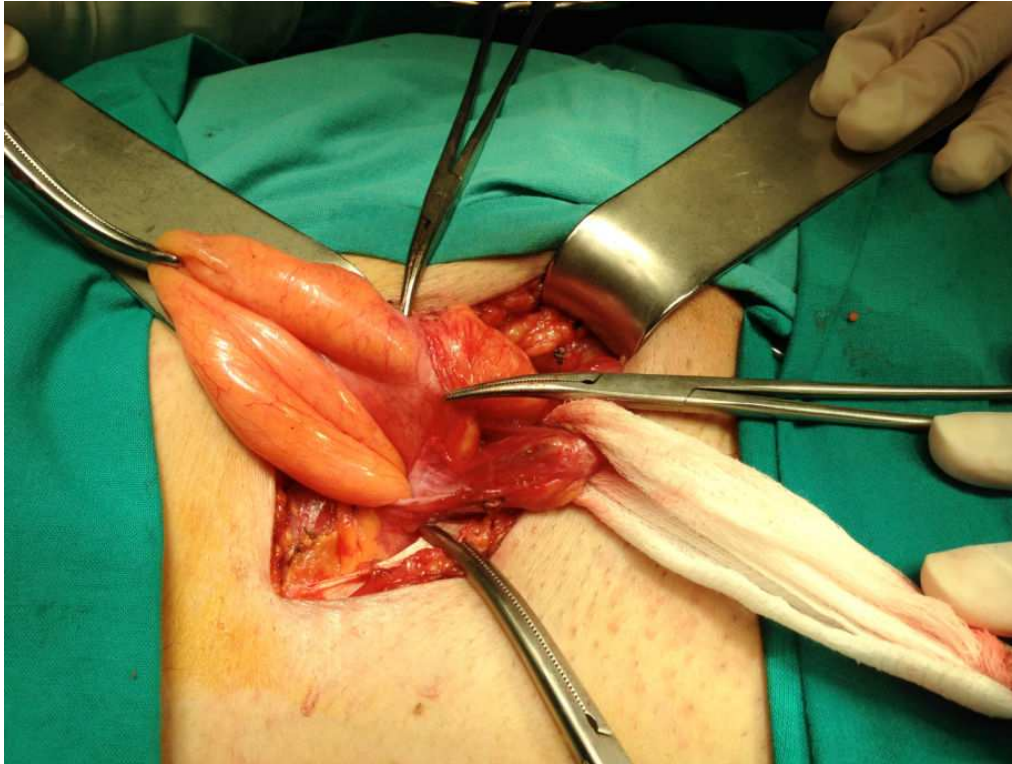


Figure 3. Opening of an inguinal sliding hernia sac. (Servicio de Cirugía General, Hospital Virgen del Camino, Sanlúcar de Barrameda-Cádiz, Spain)

4. Management

Traditionally sliding hernias were considered difficult to operate on. For an inexperienced or non-prepared surgeon even today it can pose quite a challenge [8]. One of the main reason why sliding inguinal hernia used to be considered such a difficult operation, was that in previous decades it was customary to aim at the excision of a whole peritoneal hernia sac and high ligation of a remaining stump. Given that in a sliding hernia a part of the sac is formed by the retroperitoneal organ the risk of injury of that organ was indeed higher. Currently the excision of a sac is not considered mandatory. Gentle dissection of the sac allows to perform tension free repair as in any inguinal hernia operation [2].

In the recently published paper our group have tried to identify all sliding inguinal hernias in a series of almost 500 elective hernia operations [5]. During the study period we have recorded 16 cases of a sliding inguinal hernias (incidence 3.4%). All patients with sliding hernias were

male. The dominant hernia side was left (69%) similarly to the majority of the published series e.g. in the series by Patle [7] it reached 76%, with sigmoid colon being the most common slided organ. Other slided organs were retroperitoneal appendix, caecum and urinary bladder and all were Bendavid type I hernias (Figure 1).

The opening of the sac and control of its content was performed in all our cases to confirm the diagnosis of a sliding hernia. However, some authors suggest that in case of a doubt as to the nature of the sac it is advisable not to open it, as the sac itself may prove to be intestinal or urinary bladder wall [2]. As mentioned before it is not necessary to open all hernia sacs. In our series the opening of all suspected sacs was indeed performed but only due to the experimental nature of the study. All patients in our experience were operated using prosthetic mesh with or without plug. This approach can be seen as a bit risky but once again we should stress that gentle dissection and clear anatomy are the keys to the success of the operation and the safe use of the same prosthetic materials that we routinely use for our inguinal hernia patients. We have indeed not seen any intestinal complications in our group of sliding inguinal elective hernias. The only postoperative complications that might be attributable to the use of mesh in this series are wound infection and seroma formations. However, none of these complications required explanations of the mesh [5]. In the long term follow-up we have not observed any rise in the abdominal symptoms that could be attributable to the use of prosthetic material close to the serous surface of the retroperitoneal organ that formed the hernia sac.

The laparoscopic repair of a sliding inguinal hernia is possible, however it requires important technical skills. Even in the hands of the most experienced laparoscopic hernia surgeons the conversion to open procedure can be necessary in as much as 10% of all cases [7].

5. Conclusion

The fundamentals of sliding inguinal repair are meticulous, gentle dissection and identification of all anatomical structures. Opening of the sac is not necessary. A surgeon operating according to these principles and supported by a wide range of prosthetic material is in a far better situation than his surgical predecessors. The good operating technique and the use of modern prosthetic materials should allow us to have the same risk of early and late complications after operating on a sliding and non-sliding inguinal hernia.

Acknowledgements

The authors wish to thank dr Jerzy W.Mituś from Kraków, Poland for the preparation of the Figures 1 and 2.

Author details

Andrzej L. Komorowski¹, David Domínguez Usero², José Ramón Martín-Hidalgo Rodil² and Jorge Morán-Rodríguez³

¹ Department of Surgical Oncology, Maria Skłodowska-Curie Memorial Cancer Centre, Kraków, Poland

² Department of General Surgery, Hospital Virgen del Camino, Sanlucar de Barrameda, Cadiz, Spain

³ Department of General Surgery, Hospital San Juan Grande, Jerez de la Frontera, Cadiz, Spain

References

- [1] Scarpa A. Sull'ernie: memorie anatomo-chirurgiche. Milan: Stamperia Reale, 1809-1820
- [2] Bendavid R. Sliding hernias. *Hernia* 2002; 6:137-140.
- [3] Kaneko K, Ando H, Tsuda M. New surgical procedure for sliding inguinal hernia repair in female infants and girls. *J Am Coll Surg* 2002; 194: 544-546.
- [4] Ryan EA. An analysis of 313 consecutive cases of indirect sliding inguinal hernias. *Surg Gyn Obst* 1956; 102:45-58.
- [5] Komorowski AL, Moran Rodriguez J, Kazi R, Wysocki WM. Sliding Inguinal Hernias. *Int J Surg* 2012;10(4):206-208
- [6] Ozkan OV, Semerci E, Aslan E, Ozkan S, Dolapcioglu K, Besirov E. A right sliding indirect inguinal hernia containing paraovarian cyst, fallopian. *Arch Gynecol Obstet* 2009;279:897e9.
- [7] Patle NM, Tania O, Prasad P, Khanna S, Sen B. Sliding inguinal hernias: scope of laparoscopic repair. *J Laparoendosc Adv Surg Tech A*. 2011 Apr;21(3):227-31.
- [8] Adams RA, Wysocki AP. Outcome of sliding inguinal hernia repair. *Hernia*. 2010 Feb;14(1):47-9.
- [9] Browne J, Jamieson L, Lewsey J, van der Meulen J, Copley L, Black N. Case-mix & patients' reports of outcome in Independent Sector Treatment Centres: Comparison with NHS providers. *BMC Health Serv Res* 2008; 8:78.

- [10] Chi Fai Ng A, Leung AKC, Robson WLM. Urinary bladder calculi in a sliding vesical-inguinal-scrotal hernia diagnosed preoperatively by plain abdominal radiography. *Adv Ther* 2007; 24:1016-1019.
- [11] Tan A, Taylor G, Ahmed T. Perforated sigmoid colon carcinoma in an irreducible inguinoscrotal hernia. *Ann R Coll Surg Engl.* 2013 Oct;95(7):125-6

IntechOpen

IntechOpen

