

We are IntechOpen, the world's leading publisher of Open Access books Built by scientists, for scientists

6,900

Open access books available

185,000

International authors and editors

200M

Downloads

Our authors are among the

154

Countries delivered to

TOP 1%

most cited scientists

12.2%

Contributors from top 500 universities



WEB OF SCIENCE™

Selection of our books indexed in the Book Citation Index
in Web of Science™ Core Collection (BKCI)

Interested in publishing with us?
Contact book.department@intechopen.com

Numbers displayed above are based on latest data collected.
For more information visit www.intechopen.com



A Novel Concept on the Patho-Physiology of Defecation and Fecal Incontinence (FI) in Women – Moreover, Its Reconstructive Surgery

Abdel Karim M. El Hemaly, Laila A.E.S. Mousa,
Ibrahim M. Kandil, Magdy S. Al Sayed,
Mohammad Abdel Zaher, Magdi S.A. Soliman and
Ahmad G. Serour

Additional information is available at the end of the chapter

1. Introduction

We put forward a new concept explaining the physiology of defecation and the anatomy of the internal anal sphincter (IAS). We explain the important role that the IAS plays in the control of defecation and fecal continence. Our aim is to explain the physiology of defecation, factors that control fecal continence and causes of fecal incontinence in women together with the importance and the structure of the internal anal sphincter (IAS) and how it maintains fecal continence. The harmony between the central nervous system (CNS), the autonomic nervous system, the integrity of the anal sphincters and the muscles of the body are essential for keeping fecal continence. Traumatic injury can occur during childbirth affecting the anal sphincters and causing fecal incontinence (FI). Difficult vaginal deliveries can lead to more than one lesion at the same time. Simultaneous stress urinary incontinence (SUI), vaginal prolapse and fecal incontinence (FI) arise as a sequel to the cumulative trauma of recurrent frequent vaginal deliveries.

We will describe a novel technique for the surgical repair of vaginal wall prolapse, SUI and fecal incontinence.

Fecal Continence depends on a closed and empty anal canal, which in turn depends on four main factors:

1. The integrity of the two anal sphincters: (the internal anal sphincter (IAS) and the external anal sphincter (EAS)); both anal sphincters must be intact with healthy and strong walls. Intact healthy vascular and nerve supply are important factors for anal sphincter function.
2. An acquired high alpha-sympathetic tone at the IAS that keeps the anal canal closed and empty at all times until there is a desire and/ or a need to pass flatus &/ or stool and under suitable social circumstances. The high alpha-sympathetic tone is gained by learning and training in early childhood.
3. Healthy and strong pelvic floor muscles, including the levator ani, that maintain the angle between the rectum and the anal canal.
4. Synchronization and synergistic actions between the central nervous system (CNS), the autonomic nervous system, peripheral somatic nerves, the muscles and the anal sphincters.

The closed and empty anal canal has a high anal pressure that is much higher than rectal pressure; rectal pressure reflects the abdominal pressure.

We put forward a novel concept on the patho-physiology of defecation (1,2,3,4) (figure 1).

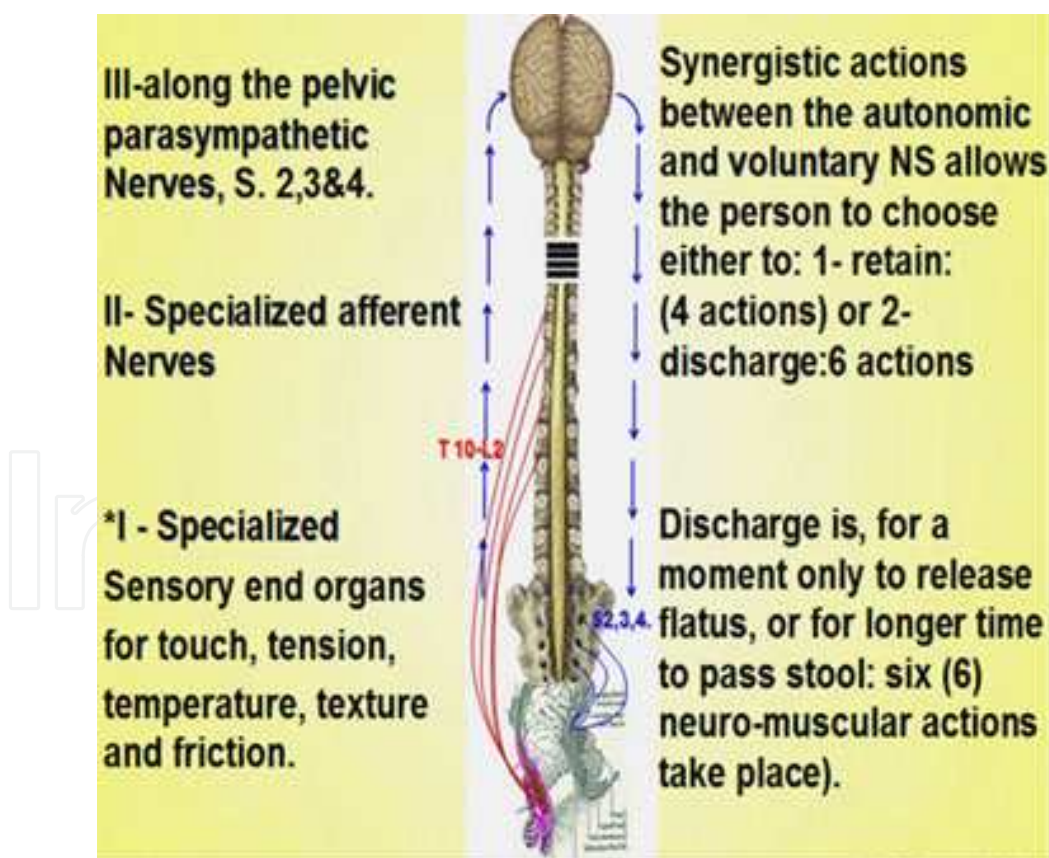


Figure 1. Physiology of defecation

Diagram that explains the steps that take place sequentially during defecation.

2. Defecation in infancy and early childhood, before training

Activation of stretch receptors in the rectum trigger impulses conveying rectal fullness which travel along the pelvic Parasympathetic (S2, 3 and 4) to the spinal cord sacral centers and lead to:

1. Reflex contraction of the rectal muscles.
2. Opening of the anal canal and relaxation of the external anal sphincter (EAS) allowing defecation to occur.

Mothers start to teach their children from the age of about two to three years how to control themselves and hold on until favorable social circumstances allow defecation.

3. Gaining control of defecation

Gaining control is achieved by maintaining high alpha-sympathetic tone in the IAS keeping it contracted and the anal canal closed and empty at all times and until an appropriate place and time are available. On rectal distension, stretch receptors are stimulated. The sensation of rectal distension travels along the pelvic parasympathetic nerves to S 2, 3 and 4 to the sacral spinal cord centers. The ano-rectal junction contains specialized sensory end organs for tension, temperature, texture, touch and friction. Specialized afferent nerves sub serve these organized nerve endings. Controlled by the central nervous system (CNS), an intact sampling reflex allows the individual to choose whether to:

- a. Retain the rectal contents or,
- b. Discharge the contents whether flatus and/ or stool.

Dependent on the available social circumstances, and once maturational control of continence has been achieved, if the woman chooses to retain rectal contents until a later time when social circumstances are more favourable, then she will:

1. Increase acquired high alpha-sympathetic tone at the IAS, ensuring its contraction and closure of the anal canal.
2. Augment the contraction of the EAS, which is a voluntary muscle, innervated with somatic nerve supply.
3. Increase the contraction of the levator ani muscles to exaggerate the angle between the rectum and anal canal.
4. Inhibit pelvic parasympathetic activity to the colon and the rectum preventing their muscular contractions.

Discharge of the rectal contents occurs by relaxation of both anal sphincters (IAS & EAS) and the pelvic floor muscles, for a moment only to pass flatus, or for a longer time to release stool.

When, an appropriate time and place are available and there is a desire to evacuate, under the control of the high CNS centers, through synergistic synchronized nervous actions between the autonomic, and the voluntary nervous systems, six neuromuscular actions will occur:

1. The woman will lower the acquired high alpha-sympathetic tone at the IAS relaxing it, opening the anal canal.
2. Through the voluntary NS, she will relax the pelvic floor muscles thus annulling the ano-rectal angle, to bring the anal canal and the rectum on one axis. She does so through relaxing the pelvic floor muscles.
3. Through the voluntary NS, she will also relax the EAS, which is a skeletal muscle innervated by the pudendal nerve. Then two synergistic synchronized actions between the voluntary and autonomic nervous system will occur.
4. The abdominal muscles and the diaphragm contract to increase the intra-abdominal pressure thus forcing the feces through the anal canal (The voluntary nervous system controls this action).
5. The smooth muscles of the distal colon and rectum contract; propelling the feces into the anal canal then to outside, (The autonomic nervous system does this action).
6. Subsequently, there will be sequential contractions of the three parts of the EAS: the deep, then the superficial then the subcutaneous parts that will squeeze the anal canal propelling any residual contents and emptying the anal canal completely.

Fecal incontinence means involuntary escape of flatus, mucus and/ or stool. Fecal incontinence (FI) is one of the most distressing conditions, psychologically and socially, in any individual. It can lead to depression, social isolation, loss of self-esteem, loss of self-confidence and poor quality of life (QOL).

Causes of FI include (5-17):

- a. Anal Sphincter damage: Traumatic injury to the anal sphincter, its nerve or blood supply, can lead to FI. Commonest causes are:
 1. Childbirth trauma,
 2. Trauma during and after surgery e.g. during performing surgical operation for piles; surgery for a pelvic or perineal tumor.
 3. Traumatic injury caused by exposure to irradiation.
 4. Damage of the nervous system.
- b. Pelvic floor dysfunction:
 1. Rectocele,
 2. Rectal prolapse,
 3. Generalized weakness and sagging of the pelvic floor.

- c. Pelvic floor neuromuscular damage e.g. decreased perception of rectal sensations, decrease anal canal pressure, decreased squeeze pressure of the anal canal & impaired anal sensation.
- d. Constipation: Constipation is a common cause of fecal incontinence (it is similar to retention with overflow in urinary incontinence, UI). Constipation causes prolonged muscle and nerve stretching and leads to weakness of the intestinal muscles and nerves resulting in fecal incontinence.
- e. Diarrhea: Diarrhea, (similar to urge and urge incontinence in UI; overactive bladder in urinary incontinence) loose stool is more difficult to control than solid stool.

Diarrhea can be:

- 1. Acute: e.g. G.I. infections, food poisoning.
- 2. Chronic: e.g. ulcerative colitis, Crohn's disease, diverticulitis or neoplasm; gastrectomy, vagotomy; malabsorption; thyrotoxicosis. When the cause of diarrhea is temporary such as G.I. infections or food reactions, incontinence tends to last for a short period.
- f. Nerve damage: damage to the autonomic, voluntary nervous systems or to the CNS can lead to FI.

The sensation of rectal distension travels along the parasympathetic system to S 2, 3& 4. Damage to the sensory nerves &/or the motor nerves; or to the CNS can cause FI. If the damage affects the sensory nerves, detection of stool in the rectum is disabled, and one will not feel the need to defecate until it is too late.

Causes of nerve damage include:

- 1. Childbirth trauma,
- 2. Long-term constipation,
- 3. Cerebral vascular accident, stroke,

Neuropathy result of diseases such as diabetes mellitus, systemic lupus erythematosus (SLE) and disseminated sclerosis (DS).

- g. Loss of storage capacity of the rectum:

Normally, the rectum stretches to hold stool until it is voluntarily discharged. However, rectal surgery, radiation treatment, and inflammatory bowel disease can cause scarring of the rectal wall. The rectal walls are unable to stretch as much and are unable to accommodate as much stool. Inflammatory bowel disease also can make rectal walls very irritated and thereby unable to keep stool

- h. Other causes:

Fecal incontinence can have other causes including one or a combination of the following:

1. Congenital causes: In cases of imperforate anus, partial or complete lack of the sphincter mechanism (rare).
2. Patulous anus is associated with mental retardation.
3. Malabsorption conditions e.g. cystic fibrosis; drugs; and indigestible dietary fats that interfere with the intestinal absorption will lead to FI.
4. Lateral internal sphincterotomy (surgery for anal fissures); and surgery for high fistula-in-ano.
5. Seizures and fits.
6. Perineal resection of the rectum for carcinoma.

A major cause of fecal incontinence in young healthy women is anal sphincter damage during vaginal delivery, which occurs in as many as 18% in the USA. Studies from other countries indicate 5-20% of women report incontinence of stool 3-6 months after sphincter tear (EAS), and 29-53% of women report incontinence of flatus, despite having the tear repaired at delivery (5).

Surgical repair of the torn EAS is by suturing end-to-end the torn edges of the EAS; or suturing after overlapping the torn edges. All published reports of the results of overlapping technique have shown significant improvements in symptoms of FI, with 60-80% achieving continence (6). It is also clear, however, that fecal control deteriorates over time with only 50% of the initial successful outcomes having improved continence at five years (7). Poor understanding of perineal anatomy and inadequate training in repair techniques are possible reasons for the high incidence of persistent symptoms (6,7). In addition, this can explain why repair of the EAS in cases of complete perineal tear whether by end-to-end or overlapping techniques does not lead to complete continence (7).

The problem is that the role of the Internal Anal Sphincter (IAS) in defecation and FI is not quite clear.

We will describe the IAS in a novel way and its important role in maintaining fecal continence and defecation (1, 2, 33), (figure 2).

The IAS is a collagen-muscle tissue cylinder that surrounds the anal canal, and is in turn surrounded externally in its lower part by the EAS. Its nerve supply is from the alpha-sympathetic nerves coming through the thoracolumbar alpha-sympathetic nerves, from the hypogastric plexus (T10-L2). The collagen constitutes the firm frame (chassis) of the IAS, while the muscle is the mover of the sphincter in response to nerve stimulus. Its functions are:

1. On contraction, to keep the anal canal closed and empty with high anal pressure.
2. On relaxation, to open the anal canal to allow passage of flatus and/ or stool.

An intact and strong IAS, through the acquired high alpha-sympathetic tone that maintains its contraction, keeps the anal canal closed and empty with high anal pressure, much higher than the rectal pressure.

Three dimension ultrasound (3DUS) images of the rectum and anal canal with torn IAS in patients with fecal incontinence (FI).

FI is the main complaint in posterior vaginal wall prolapse (rectocele). Concomitant troubles, which commonly occur, are vaginal prolapse (anterior and posterior), stress urinary incontinence (SUI) and FI (1) (Figures: 13, 14 &15). The internal urethral sphincter (IUS) is in close contact to the anterior vaginal wall and will be involved in the childbirth trauma with subsequent SUI and anterior vaginal wall prolapse.

Childbirth trauma is the major cause of damage, but aging, hormone deficiency (menopause) and degeneration from chronic and/or repeated infections causing collagen degeneration and atrophy can add to the weakness of the internal urethral sphincter (IUS), IAS and the vagina. in women; Moreover, its Reconstructive Surgery

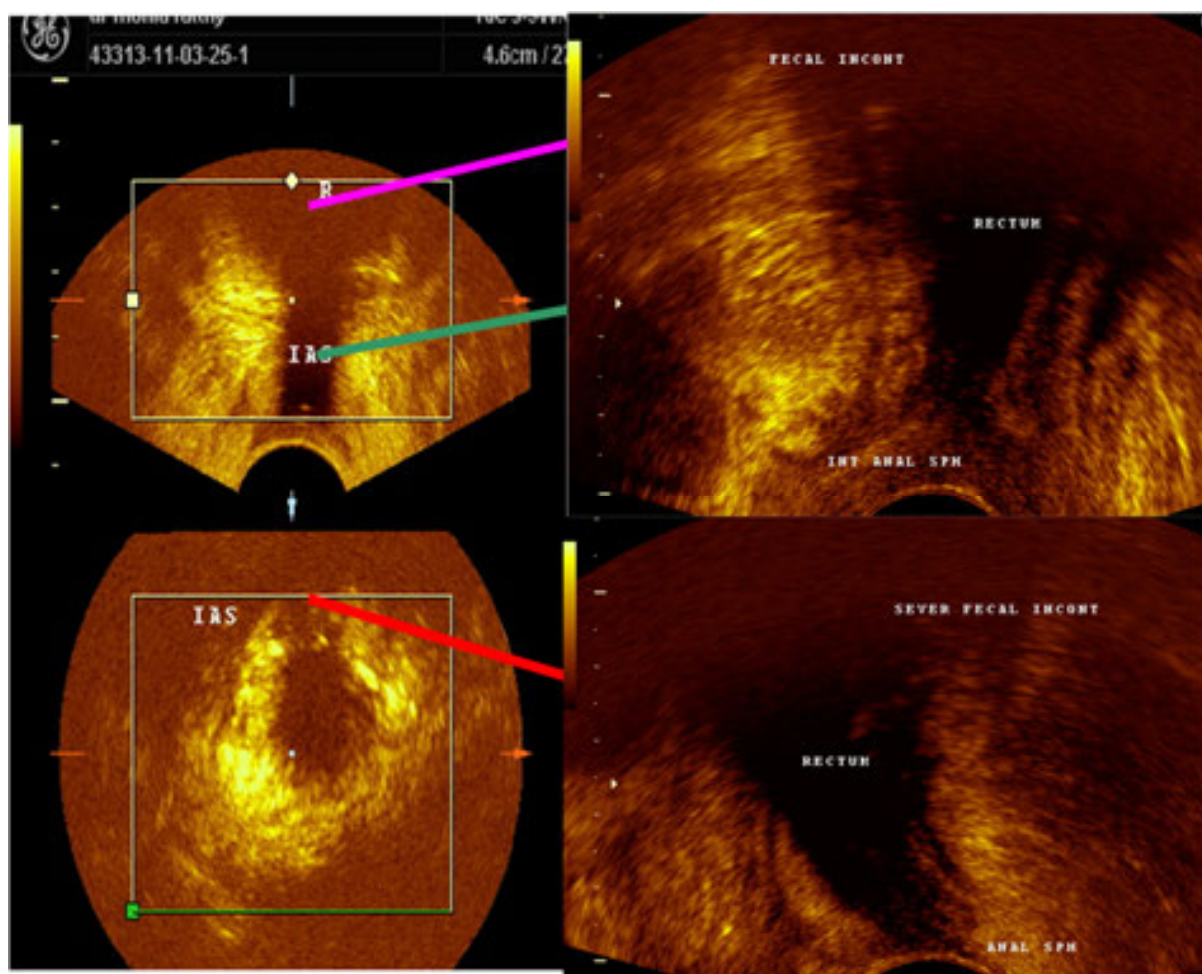


Figure 3: Three dimension ultrasound (3DUS) images of the rectum and anal canal with torn IAS in patients with fecal incontinence (FI).
 Figure 3. MRI images of a continent patient, (A), with an intact internal urethral sphincter (IUS), an intact IAS with a closed and empty anal canal. In addition, the vagina is standing up and not prolapsed. In contrast, patient, (B) suffers from urinary incontinence, FI and vaginal prolapse as demonstrated by torn IUS, IAS and vagina.

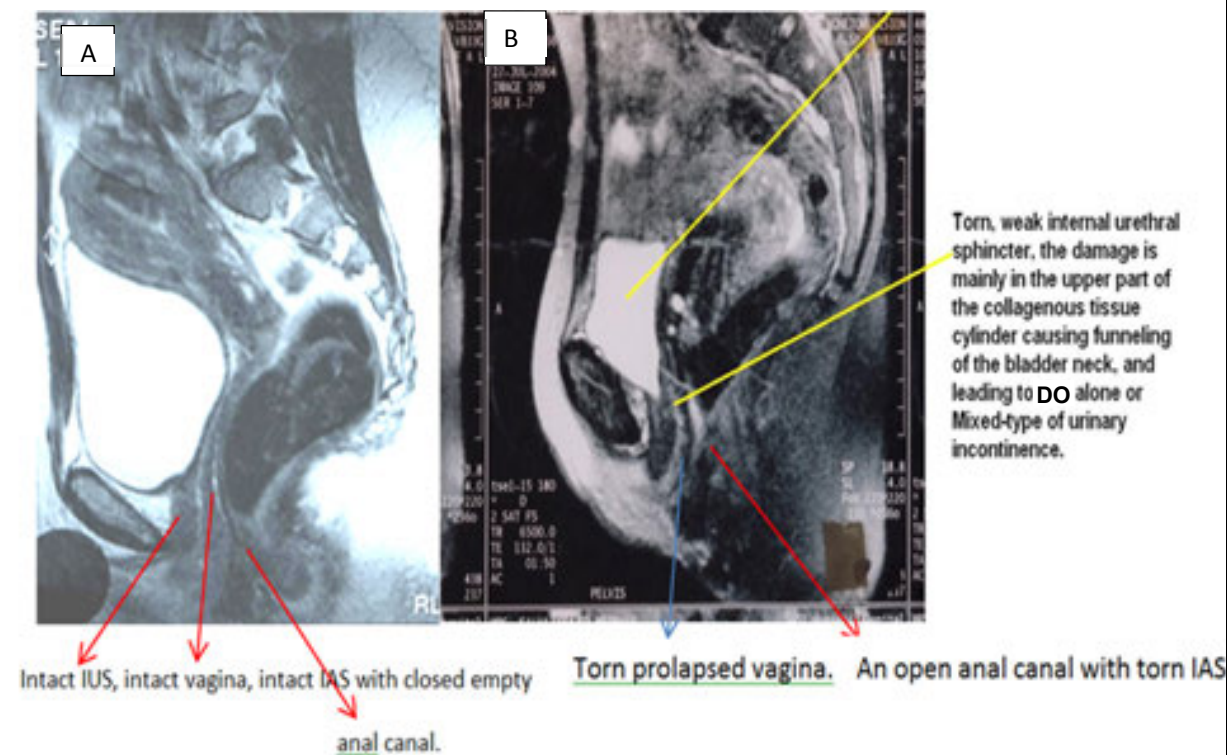


Figure 4: MRI images of a continent patient, (A), with an intact internal urethral sphincter (IUS), an intact IAS with a closed empty anal canal. In addition, the vagina is standing up and not prolapsed. In contrast, patient, (B), suffers from urinary incontinence, FI and vagina open as demonstrated by torn IUS, IAS and vagina.

A Novel Concept on the Patho-Physiology of Defecation and Fecal Incontinence (FI) in women; Moreover, its Reconstructive Surgery

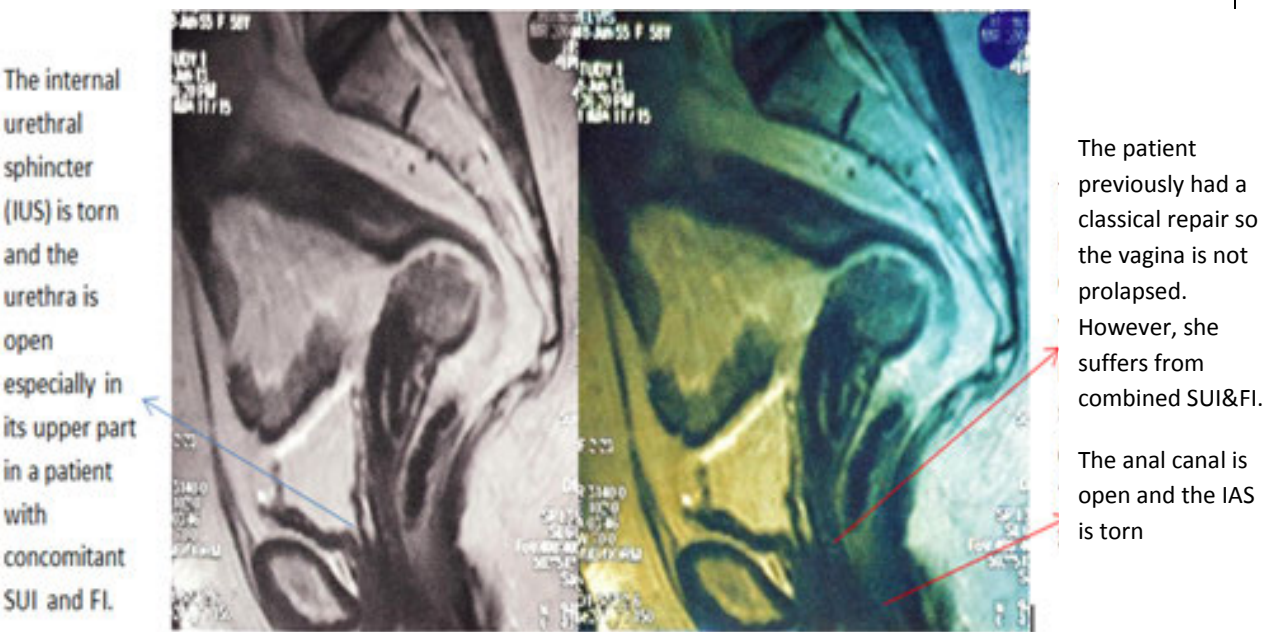
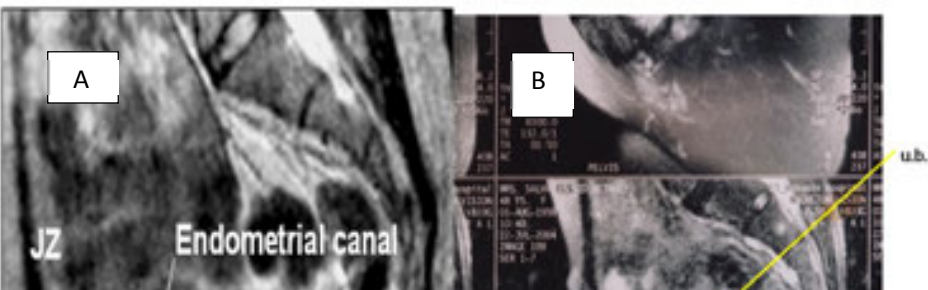


Figure 5: MRI images of a patient who suffers from SUI and FI. The IUS is torn especially in its upper part with funneling of the bladder neck, and with an open anal canal.





10 Fecal Incontinence

Figure 5: MRI images of a patient who suffers from SUI and FI. The IUS is torn especially in its upper part with funneling of the bladder neck, and torn IAS with an open anal canal.

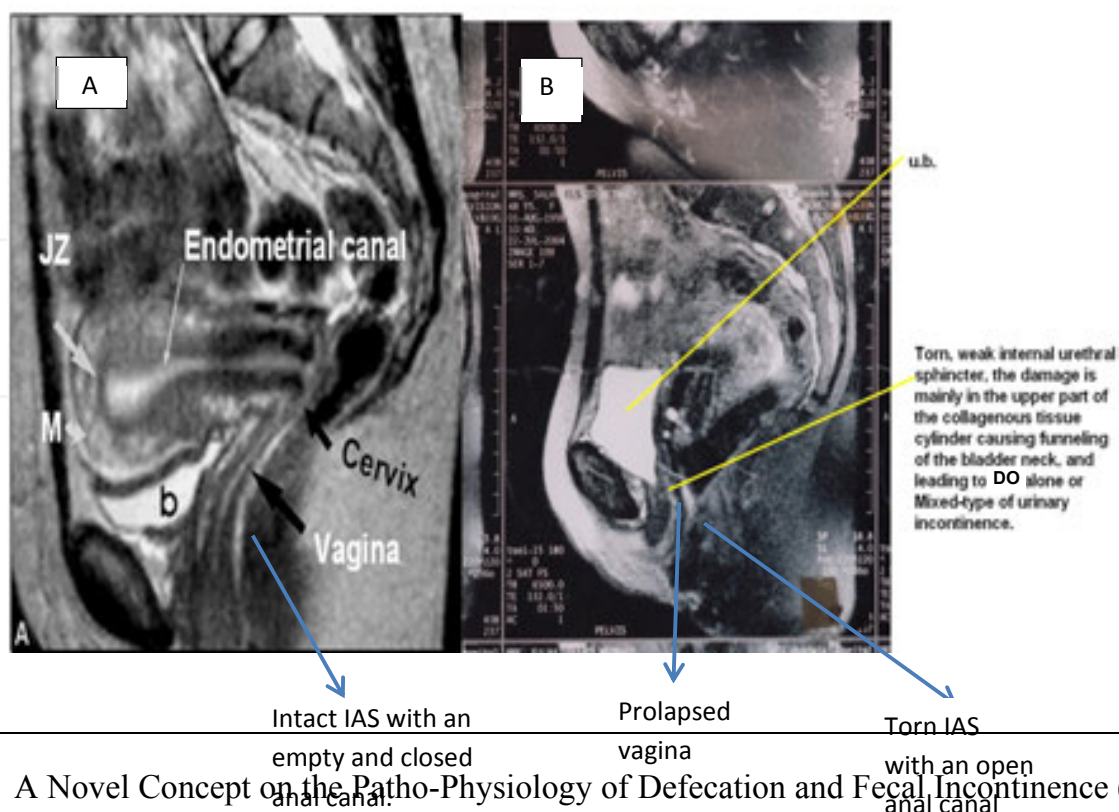


Figure 6. MRI images of a normal continent woman (A) with intact IUS, IAS with a closed empty anal canal and normal non-prolapsing vagina. Image (B) is of an incontinent patient with torn IUS and torn IAS and prolapsed vagina.

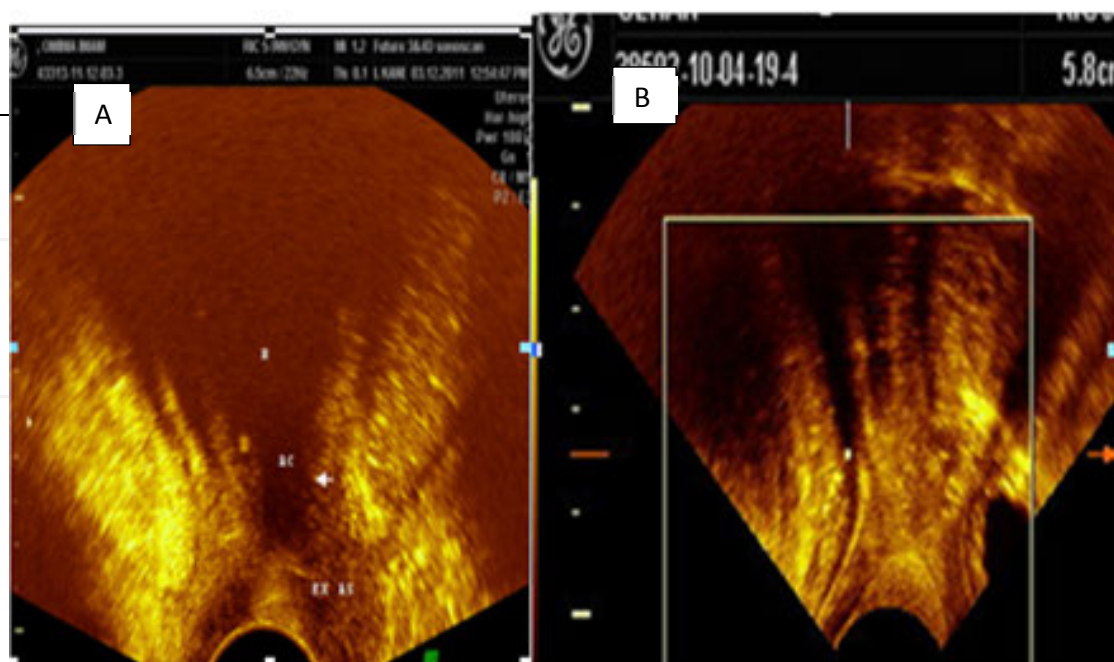


Figure 7. Images with 3DUS of the rectum and anal canal in normal continent woman (B) with healthy, intact IAS and a closed empty anal canal. In contrast, in (A) the IAS is torn leading to a widely open anal canal in a patient with FI.

A Novel Concept on the Patho-Physiology of Defecation and Fecal Incontinence (FI) in women; Moreover, its Reconstructive Surgery

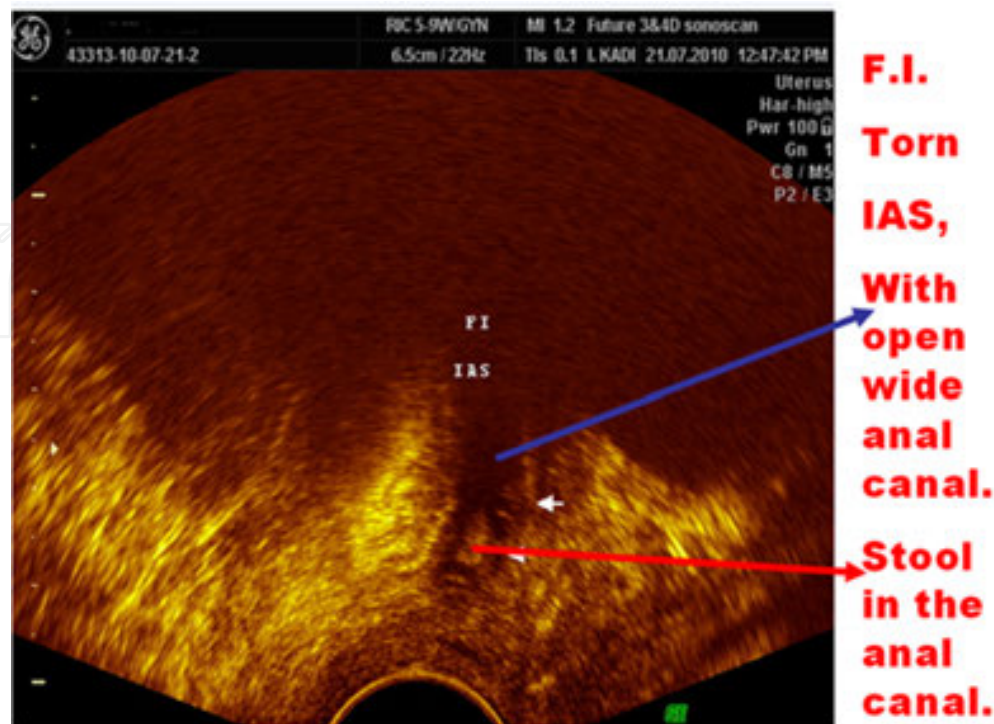


Figure 8. An image with 3DUS of a patient with FI that shows torn IAS, and an open anal canal with a piece of stool in the anal canal.

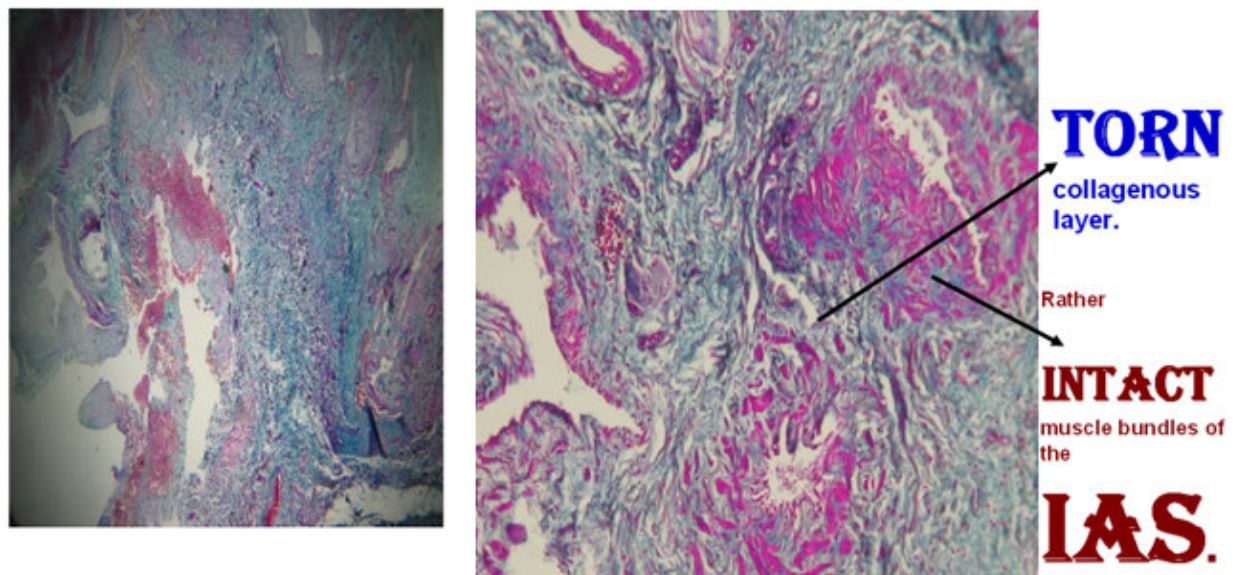


Figure 9. Histopathology of a surgical specimen of the IAS stained with Masson trichrome acetate, showing a torn collagen sheet with relative healthy muscle bundles.

A Novel Concept on the Patho-Physiology of Defecation and Fecal Incontinence (FI) in women; Moreover, its Reconstructive Surgery

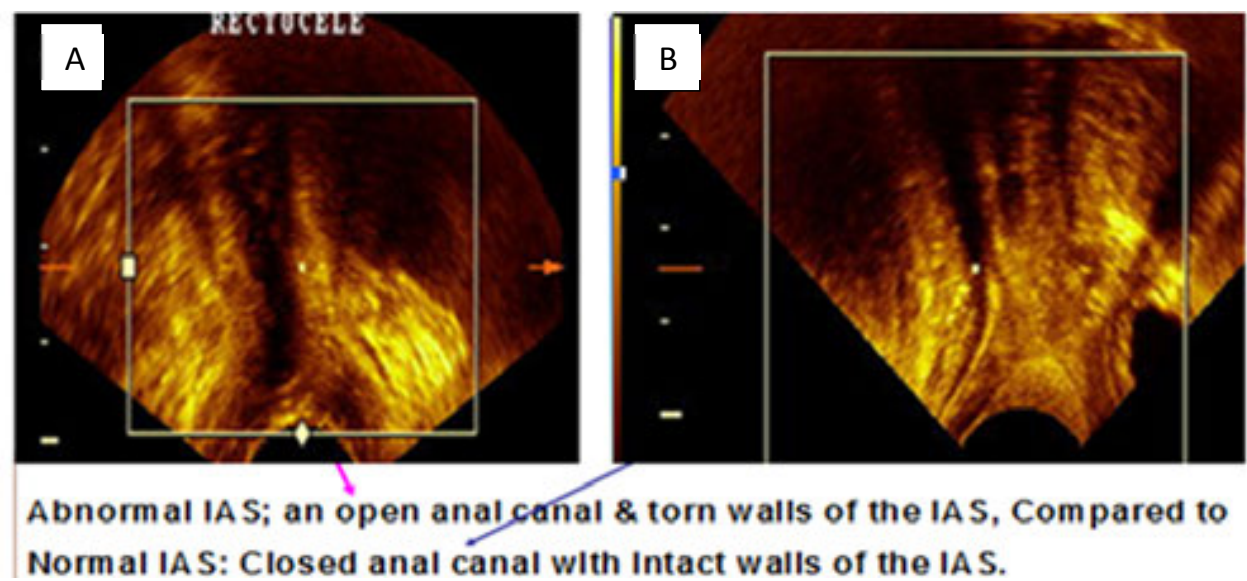


Figure 10: Images with 3DUS of the rectum and anal canal in a normal continent woman (B) with a healthy, intact IAS and a closed empty anal canal. In contrast, in (A) the IAS is torn leading to a widely open anal canal in a patient with FI.

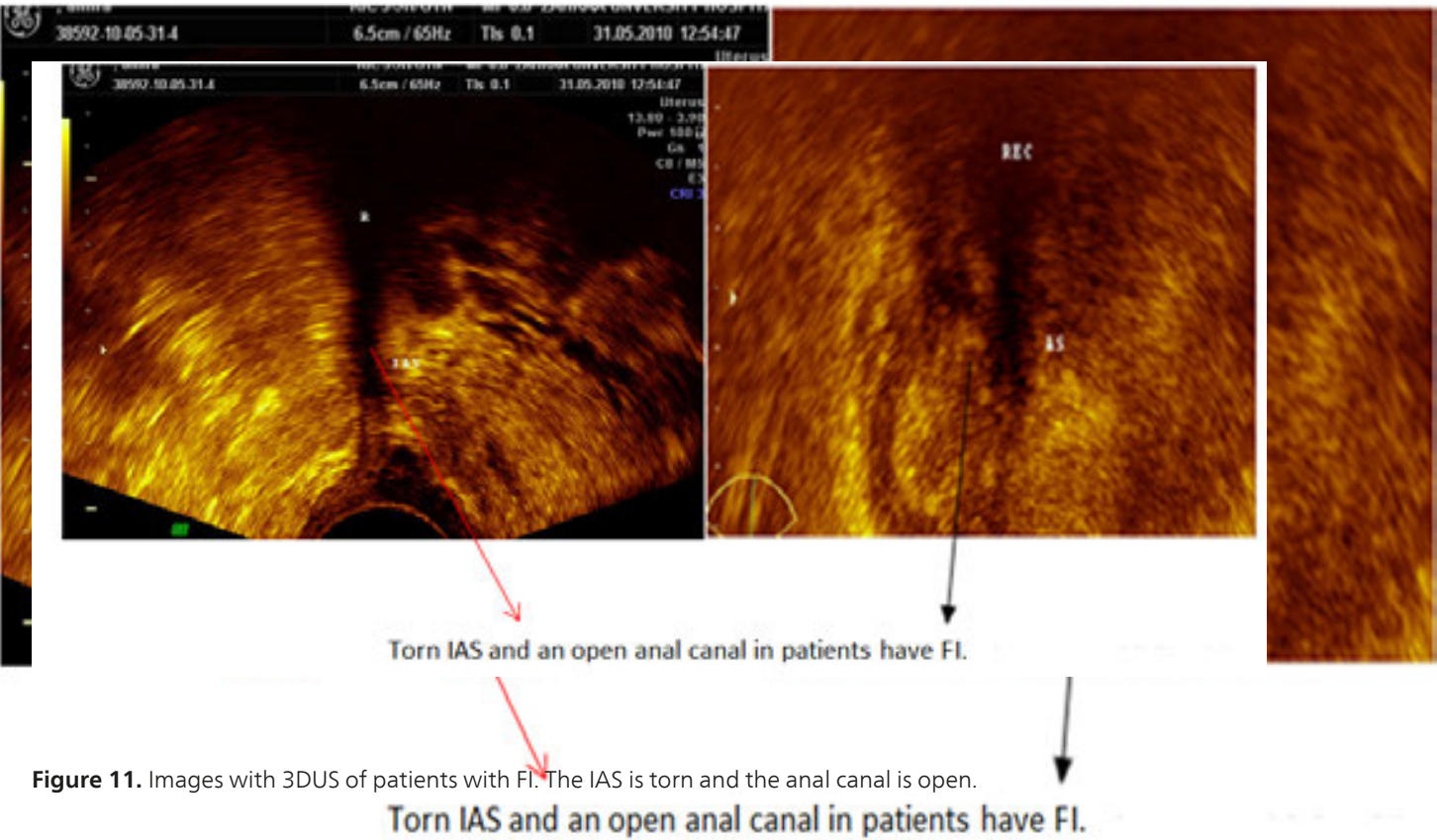


Figure 11: Images with 3DUS of patients with FI. The IAS is torn and the anal canal is open.

A Novel Concept on the Patho-Physiology of Defecation and Fecal Incontinence (FI) in women; Moreover, its Reconstructive Surgery

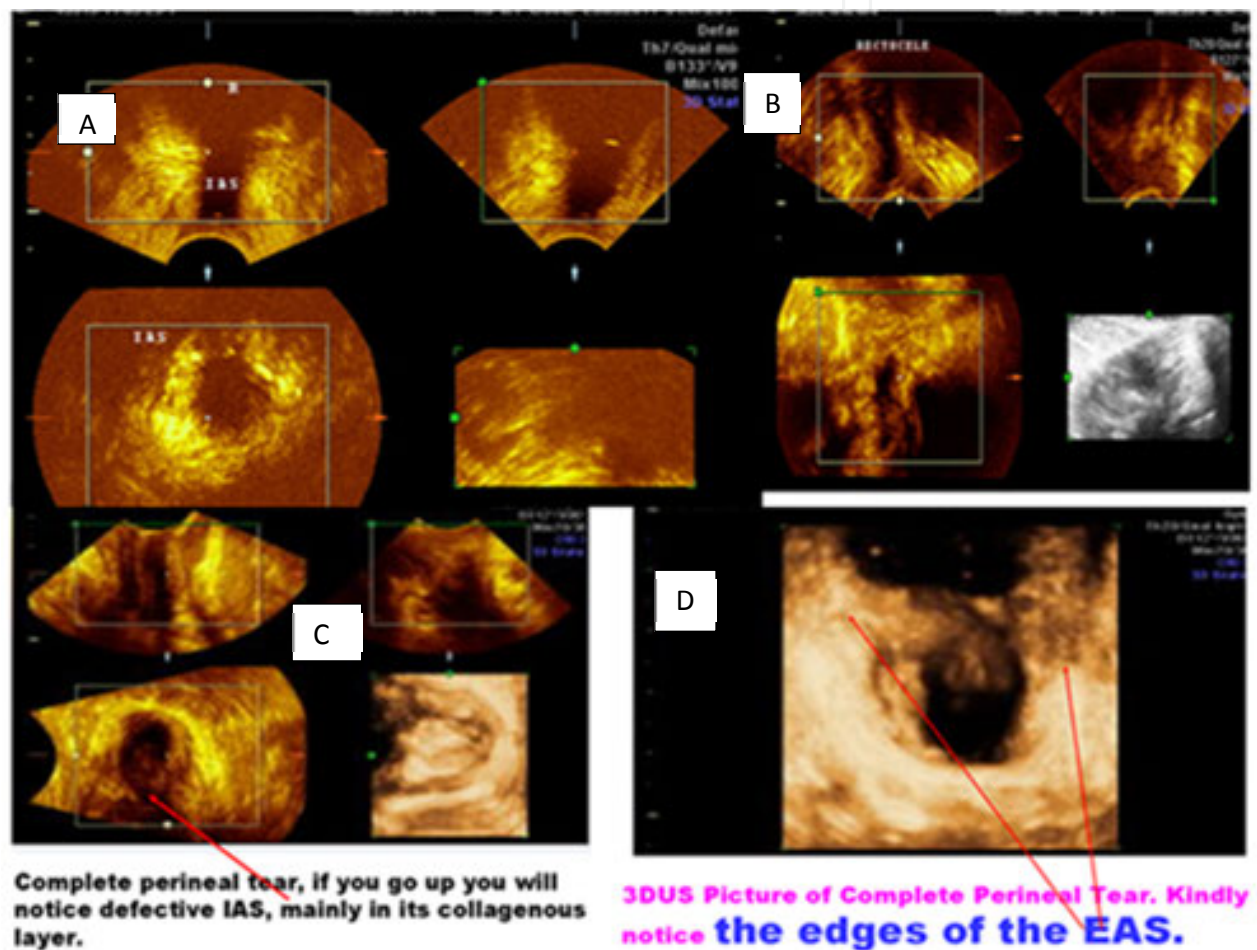


Figure 12: Images with 3DUS of the rectum and anal canal in patients with FI. Images in C & D are of a complete perineal tear (fourth degree). The external anal sphincter is torn and appears as a horseshoe; in addition, the internal anal sphincter is torn as well. Images in A and B are of the internal anal sphincter, which is torn leading to an open dilated anal canal. The IAS in this image also appears like a horseshoe.

Figure 12. Images with 3DUS of the rectum and anal canal in patients with FI. Images in C & D are of a complete perineal tear (fourth degree). The external anal sphincter is torn and appears as a horseshoe; in addition, the internal anal sphincter is torn as well. Images in A and B are of the internal anal sphincter, which is torn leading to an open dilated anal canal. The IAS in this image also appears like a horseshoe.

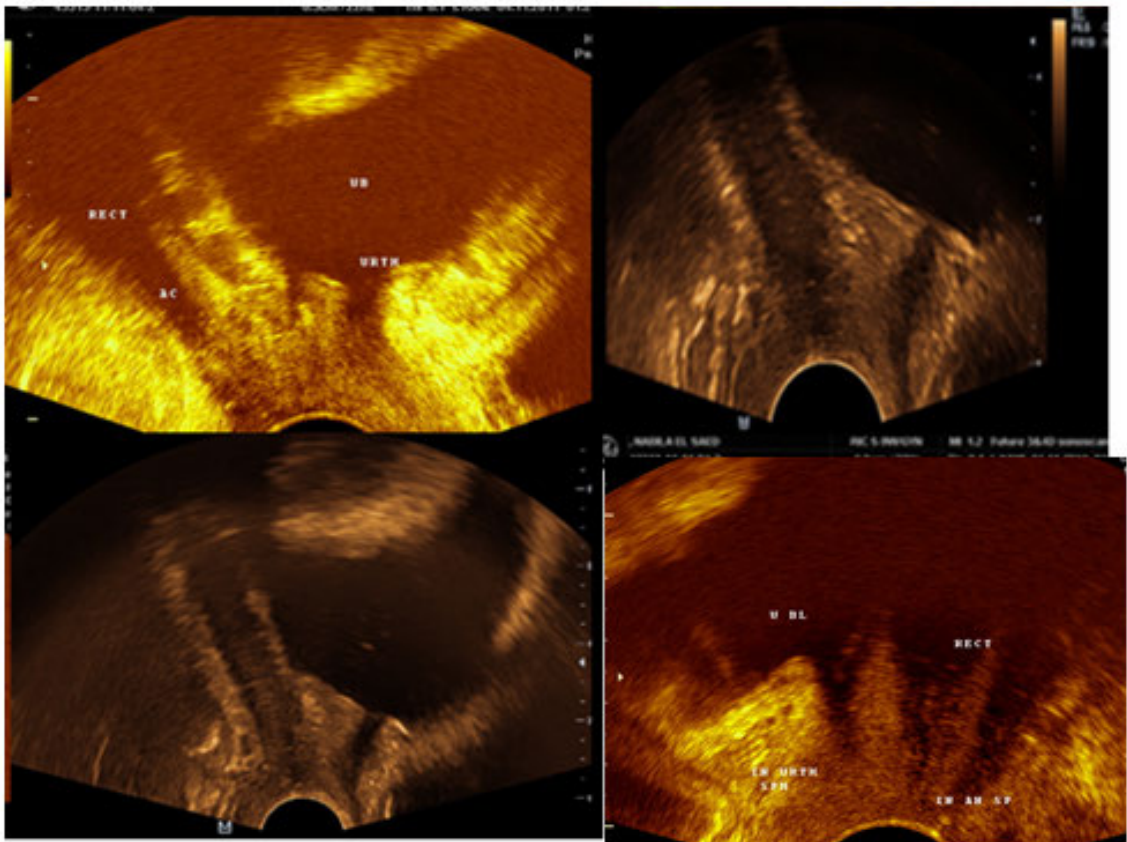
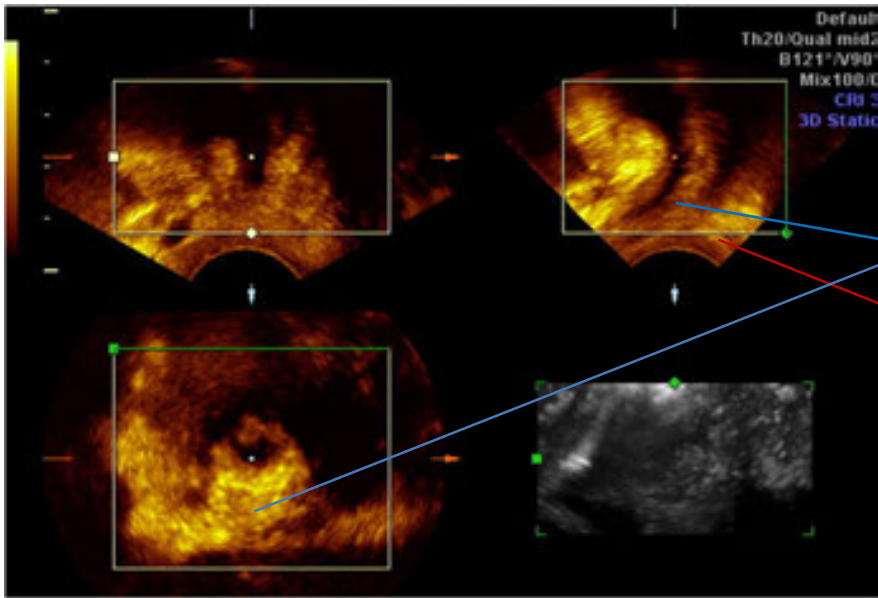


Figure 13: images of patients who suffer from pelvic organ dysfunction with SUI, FI and vaginal prolapse simultaneously. The images show torn IUS and IAS.
A Novel Concept on the Patho-Physiology of Defecation and Fecal Incontinence (FI) in women; Moreover, its Reconstructive Surgery



A patient, who has SUI and FI, had 3DUS examination; the IUS is torn and the urethra is open. The IAS is torn and the anal canal is open and dilated.

Figure 14: images which show concomitant torn IUS and IAS in a patient who suffers pelvic floor dysfunction

A Novel Concept on the Patho-Physiology of Defecation and Fecal Incontinence (FI) in women; Moreover, its Reconstructive Surgery

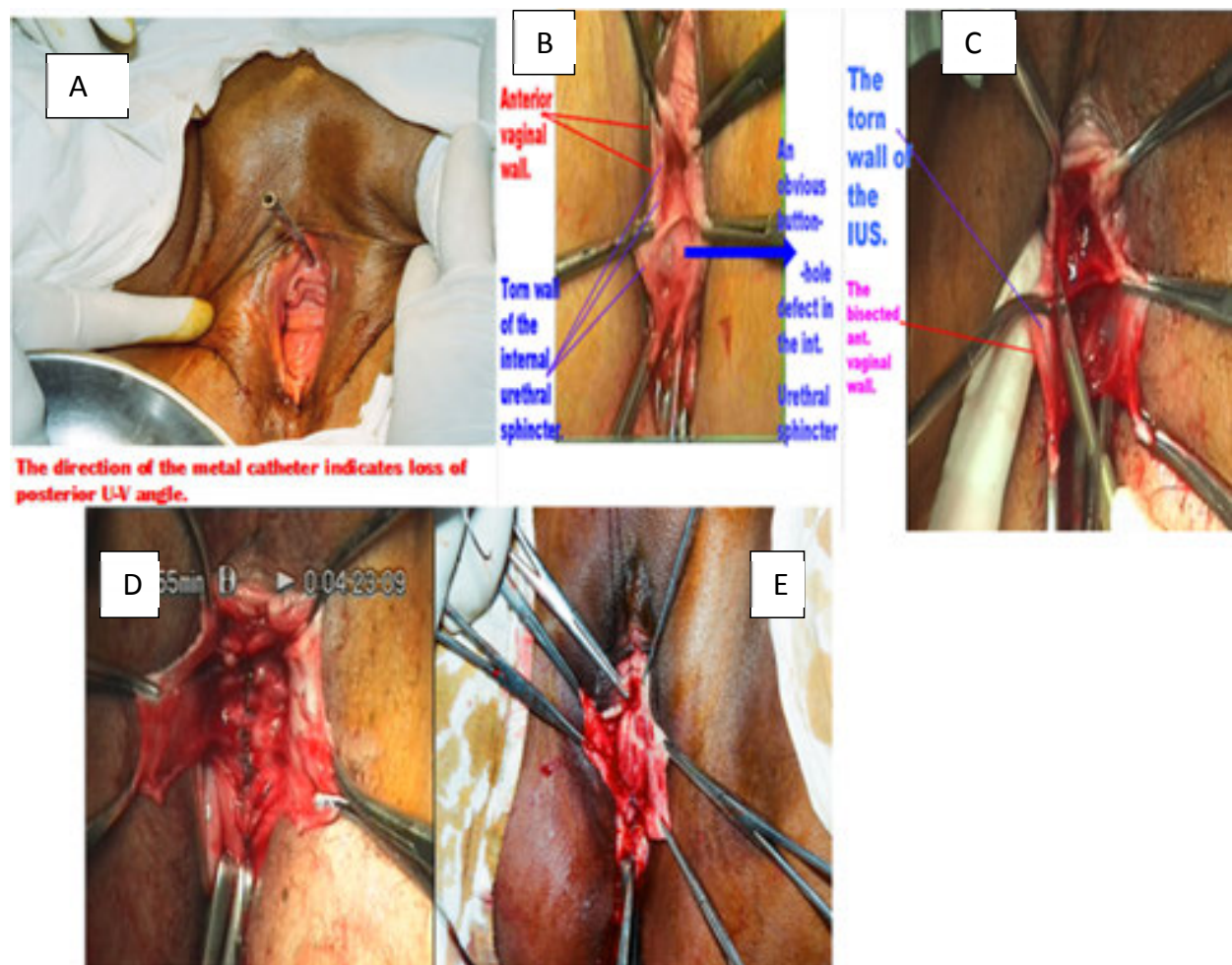


Figure 15: Surgical photos of a patient with anterior vaginal wall prolapse, posterior vaginal wall prolapse, SUI, and FI. The metal catheter is directed forward and upward (A), which means loss of posterior urethra-vesical angle. We dissect the IUS from the anterior vaginal wall (B&C) and mended the torn IUS with simple interrupted sutures (D&E) in the anterior vaginal wall (B&C) and mended the torn IUS with simple interrupted sutures (D&E).

In addition, anal intercourse can cause traumatic damage of the IAS with subsequent FI (1, 2 & 3).

4. Diagnosis

In addition to the clinical history and examination, imaging with three-dimension ultrasound (3DUS) and magnetic resonance (MRI) is an essential tool in the management of cases of FI. Typically, it shows an open anal canal with torn IAS. It may also reveal an open urethra and torn IUS with concomitant SUI and vaginal prolapse (figures: 3, 4, 5, 6, 7, 8, 10, 11, 12, 13 & 14). Histopathological examination of a torn piece of the IAS confirm that the rupture mainly affects the collagen frame of the IAS (figure 9).

5. Reconstructive surgery (figures: 15, 16, 17, 18 & 19)

In conclusion, a major cause of FI in young patients is torn IAS. We have developed an operative procedure to expose and mend the torn edges of the IAS. Since there is usually concomitant vaginal prolapse and SUI, we try to correct these concurrently as part of this new operation.

“Urethro-Ano-Vaginoplasty” “Al Azhar repair operation”

A Novel Concept on the Patho-Physiology of Defecation and Fecal Incontinence (FI) in women; Moreover, its Reconstructive Surgery

In the Anterior section, we correct the SUI and the anterior vaginal wall descent through the following steps: (Figures: 15 & 16).

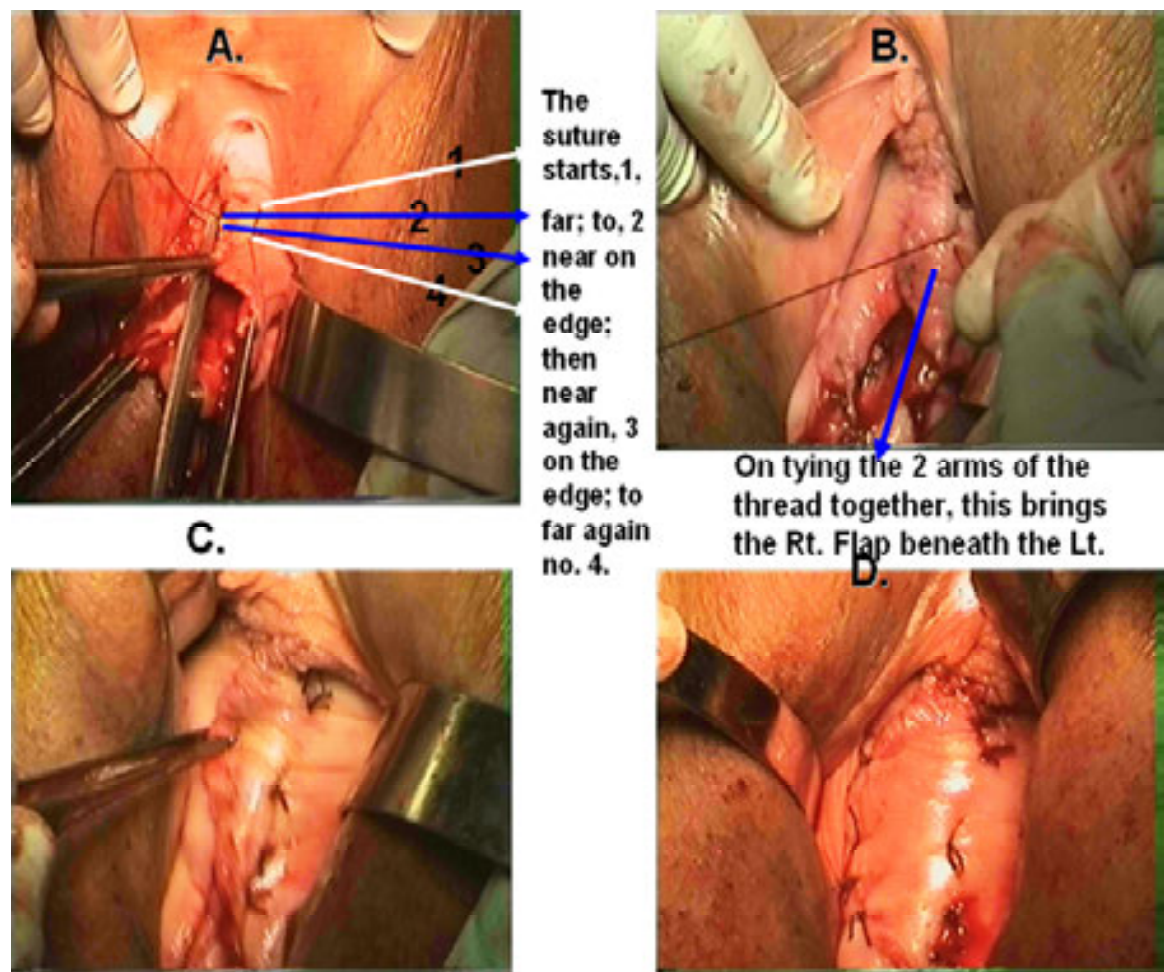


Figure 16. After mending the IUS, we do overlapped the two vaginal flaps as seen in the photos. We bring the right vaginal flap underneath the left vaginal flap with this novel dragging suture as seen in (A) and (B), repeating it 4-6 times. Then we suture the free edge of the left vaginal flap as far laterally in the vagina on the right as seen in (C) & (D). Thus we strengthen the anterior vaginal wall and add extra strength to the mended IUS. We irrigate the wound with 100-200 ml. normal saline with adrenaline (2 per 200 thousand concentration), beneath the vaginal wall to act as a hydro

dissection and vasoconstrictor. This separates the anterior vaginal wall from the posterior wall of the IUS. We make a 2-4 cm transverse incision about three cm above the external cervical os. With a pair of dissecting scissors, we separate the anterior vaginal wall from the IUS. We cut the anterior vaginal wall longitudinally from the transverse cut all the way, “down”, to the submeatal sulcus, which correspond to the perineal membrane. We grasp each vaginal flap with three pairs of Kocher’s forceps. The defect in the IUS will be apparent and on each side, we can clearly see two clear edges. One edge is of the anterior vaginal wall and the other is the torn posterior wall of the IUS.

1. Expose the IUS (we dissect the IUS clear from the anterior vaginal wall).
2. Mend the torn posterior wall of the IUS by several (6-8) simple interrupted sutures using number 0 polyglycan thread, sutures (figure 15).
3. Strengthen the anterior vaginal wall by overlapping the two vaginal flaps, using a novel dragging sutures, dragging the right vaginal flap underneath the left vaginal flap. Then we suture the free edge of the left vaginal flap as far lateral on the right side of the vagina. This strengthens the anterior vaginal wall and decreases its width, also adding extra support to the mended IUS, and preserving the body collagen.

Posterior section (figures: 17, 18 & 19).

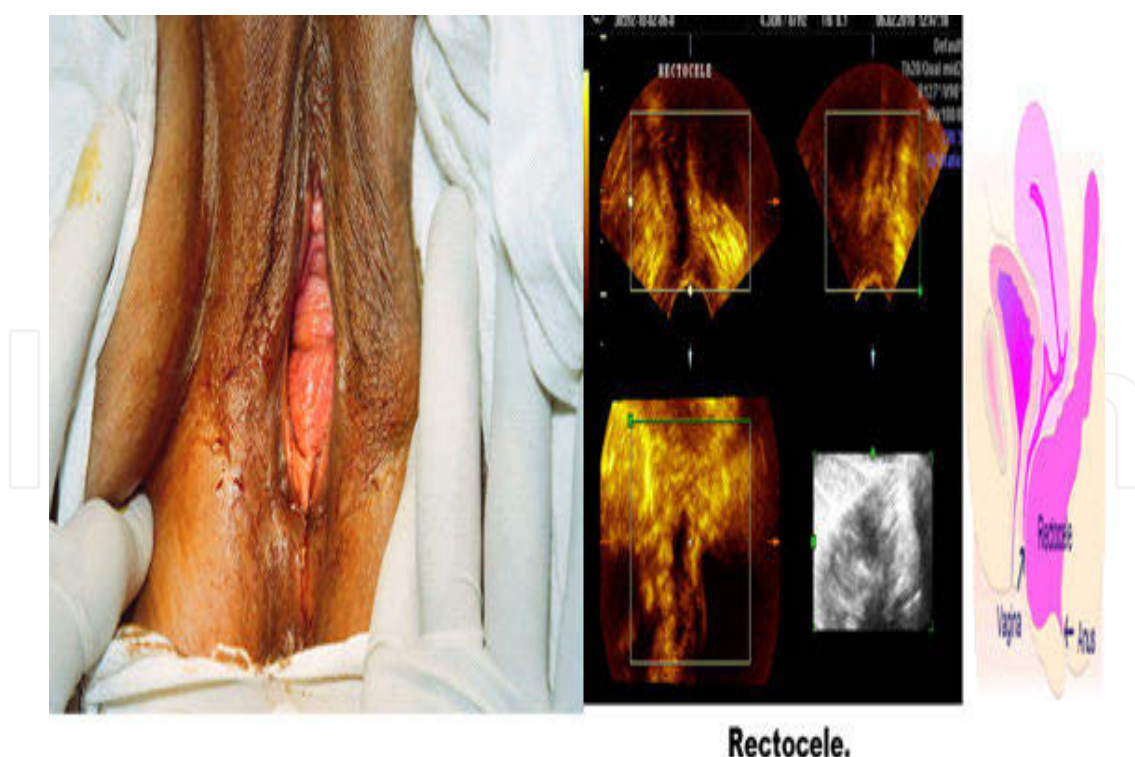

Figure 17. Image A clearly shows the posterior vaginal wall even without straining. This is visible with posterior vaginal wall prolapse. Image (B) is 3DUS showing rectocele of the same patient who suffers FI.

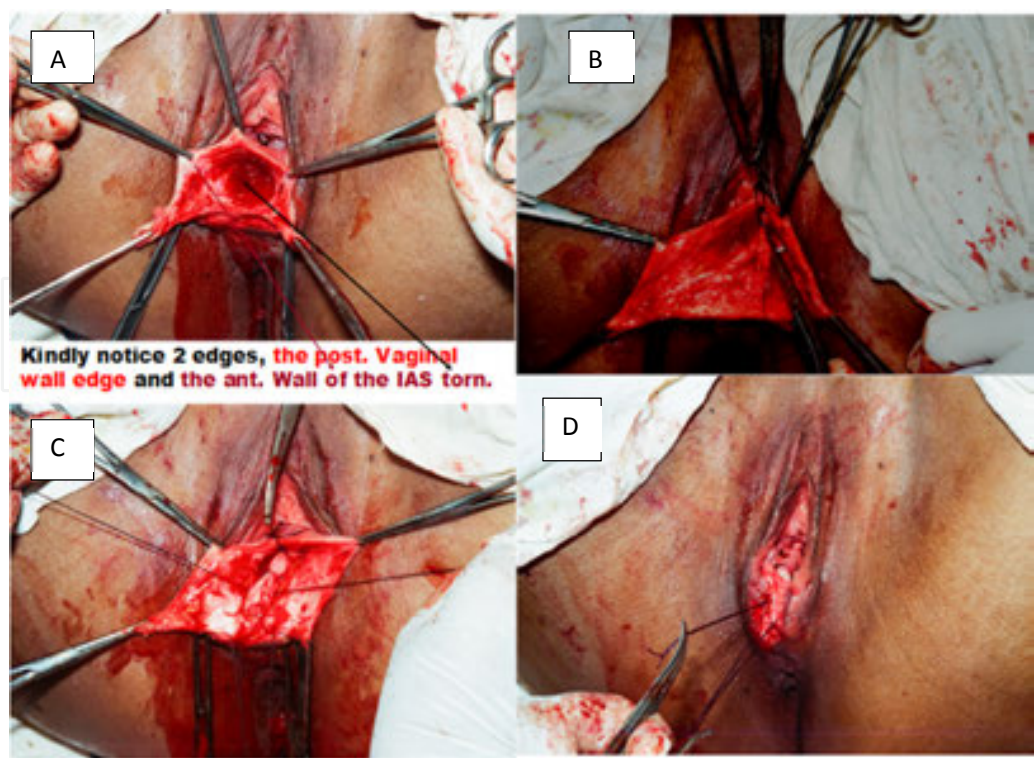


Figure 18. Surgical steps of posterior repair. We dissect the IAS from the posterior vaginal wall (A). We mend the sphincter (B). We mend the IAS from the posterior vaginal wall (C). We mend the sphincter (D). In addition, we approximate the two levator ani muscles by two stitches, but we do not tie them till we finish overlapping the posterior vaginal wall (D).

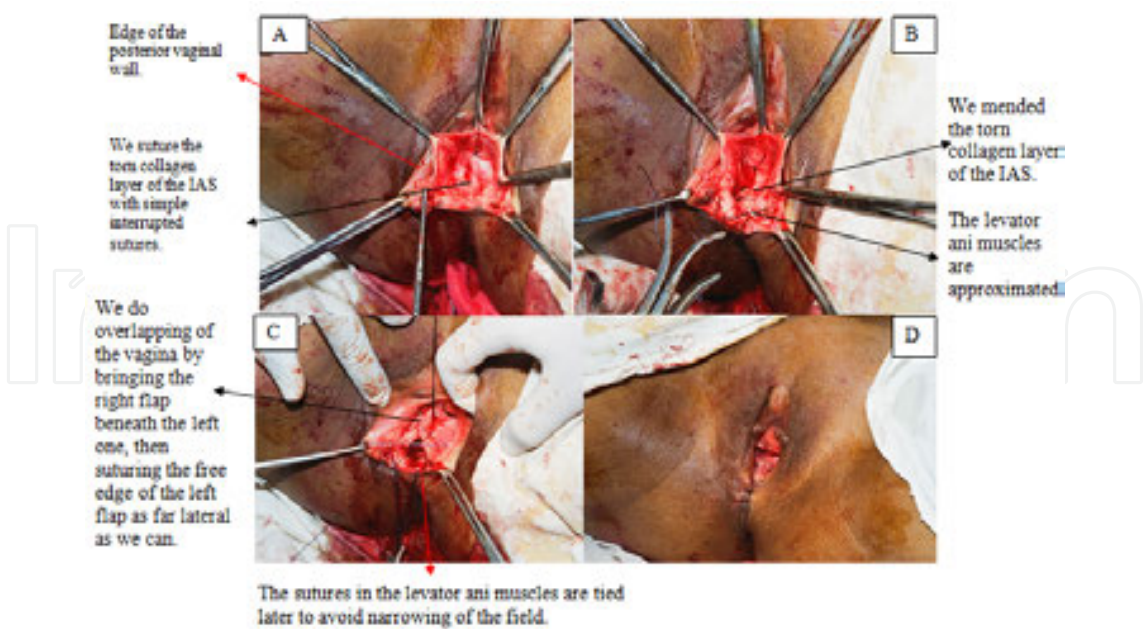


Figure 19. Images that show the steps taken to expose the torn IAS and mend it (A&B). We then overlapped the redundant posterior vaginal wall as is seen in (C). Next, we approximated the two levator ani muscles; and finally repaired the perineum as is seen in (D).

We hydro dissect between the posterior vaginal wall, the anal canal and the rectum; and in the perineum as described for the anterior section.

We make a V-shape incision at the line between the posterior vaginal wall and the perineal skin down to the perineum. Then we try to create a space between the posterior vaginal wall and the anal canal by sharp and blunt dissection. Next with a pair of dissecting scissors, we separate the posterior vaginal wall from the rectum and anal canal. Then we cut the posterior vaginal wall longitudinally in the midline to beyond the apex of the prolapse protrusion. We hold each vaginal flap with three pairs of Kocher's forceps. Two different edges can clearly be seen on each side, one is the vaginal edge, and the other is the anterior wall of the torn IAS.

1. We dissect the torn IAS clear from the posterior vaginal wall.
2. Mend the torn wall of the sphincter by serial interrupted simple sutures with number 0 polyglcan thread.
3. Approximate the two levator ani muscles.
4. Strengthen the posterior vaginal wall by overlapping the two vaginal flaps; thus, we also add extra support to the mended IAS and keeping the natural body collagen.
5. Repair the perineum.

We put a Foley's catheter and vagina pack for 24 hours.

List of abbreviations

3DUS: Three-Dimension Ultra Sound.

CNS: Central Nervous System.

EAS: External Anal Sphincter.

EAS: External Anal Sphincter.

EUS: External Urethral Sphincter.

FI: Fecal Incontinence.

GI: Gastro-Intestinal.

IAS: Internal Anal Sphincter.

IUS: Internal Urethral Sphincter

MRI: Magnetic Resonance Imaging.

NS: Nervous System.

QOL: Quality Of Life.

SUI: Stress Urinary Incontinence.

T10-L2: Thoracic 10 to Lumbar two.

UI: Urinary Incontinence.

Author details

Abdel Karim M. El Hemaly¹, Laila A.E.S. Mousa¹, Ibrahim M. Kandil¹, Magdy S. Al Sayed², Mohammad Abdel Zaher^{1,3}, Magdi S.A. Soliman³ and Ahmad G. Serour¹

*Address all correspondence to: profakhemaly@hotmail.com

1 Al Azhar University, Cairo, Egypt

2 University Hospital, Salman Bin Abdul Aziz University, K.S.A., Egypt

3 Salman Bin Abdul Aziz University, K.S.A., Egypt

References

- [1] Abdel Karim M El Hemaly, Laila A Mousa, Asim Kurjak, Ibrahim M Kandil, Ahmad G Serour. Pelvic Floor Dysfunction, the Role of Imaging and Reconstructive Surgery, Donald School Journal of Ultrasound in Obstetrics and Gynecology, DSJUOG, January-March 2013;7(1):86-97
- [2] Abdel Karim M. El Hemaly*, Ibrahim M. Kandil, Asim Kurjak, Laila A. S. Mousa, Hossam H. Kamel, Ahmad G. Serour. Ultrasound Assessment of the Internal Anal Sphincter in Women with Fecal Incontinence and Posterior Vaginal Wall Prolapse (Rectocele). Donald School Journal of Ultrasound in Obstetrics and Gynecology, DSJUOG, vol. 5, No 4, 330-42; October-December 2011.
- [3] Abdel Karim M. El Hemaly*, Laila A. S. Mousa Ibrahim M. Kandil, Fatma S. El Sokkary, Ahmad G. Serour, Hossam Hussein. Fecal Incontinence, A Novel Concept: The Role of the internal Anal sphincter (IAS) in defecation and fecal incontinence. Gynaecologia et Perinatologia, Vol19, No 2; 79-85 April -June 2010.
- [4] Abdel Karim M. El Hemaly*, Laila A. S. Mousa Ibrahim M. Kandil, Fatma S. El Sokkary, Ahmad G. Serour, Hossam Hussein. Surgical Treatment of Stress Urinary Incontinence, Fecal Incontinence and Vaginal Prolapse by A Novel Operation "Urethro-Ano-Vaginoplasty" Gynaecologia et Perinatologia, Vol19, No 3; 129-188 July-September 2010.
- [5] Pinta TM, Kylanpaa ML, Salmi TK, et al. Primary sphincter repair: Are the results of the operation good enough? Dis Colon Rectum 2004; 47:18-23.

- [6] France-Borello Diane, Kathryn L.Burgio, Holly E. Richter, Hallina Zycnski, Mary Pat Fitzgerald, William Whitehead, Paul Fine, Ingrid Nygaard, Victoria L. Handa, Anthony G. Vesco, Anne M. Wiber and Morton B. Brown; PhD, for the Pelvic Floor Disorders, Network, Fecal and Urinary incontinence in primiparous women. *Obstet & Gynecol* 2006; 108(4):863-72.
- [7] Halverson AL, Hull TL. Long-term outcome of overlapping anal sphincter repair. *Dis Colon Rectum* 2002; 45:345-48.
- [8] Sultan AH, Thakar R. Lower genital tract and anal sphincter trauma. *Best Pract Res Clin Obstet Gynecol* 2002; 16:99-115.
- [9] Faltin DL, Boulvain M, Floris LA, et al. Diagnosis of anal sphincter tears to prevent fecal incontinence: a randomized controlled trial. *Obstet Gynecol* 2005;106(1): 6–13.
- [10] Nichols CM, Ramakrishnan V, Gill EJ, et al. Anal incontinence in women with and those without pelvic floor disorders. *Obstet Gynecol* 2005; 106(6): 1266–71.
- [11] Dietz HP, Lanzarone V. Levator trauma after vaginal delivery. *Obstet Gynecol* 2005;106(4):707–12.
- [12] Jackson SL, Weber AM, Hull TL, et al. Fecal incontinence in women with urinary incontinence and pelvic organ prolapse. *Obstet Gynecol* 1997; 89(3):423–7.
- [13] Mimura T, Kaminishi M, Kamm MA. Diagnostic evaluation of patients with faecal incontinence at a specialist institution. *Dig Surg* 2004; 21(3):235–41
- [14] Kruger JA, Heap SW, Murphy BA, et al. Pelvic floor function in nulliparous women using three-dimensional ultrasound and magnetic resonance imaging. *Obstet Gynecol* 2008;111(3):631–8.
- [15] Soligo M, Salvatore S, Milani R, et al. Double incontinence in urogynecologic practice: a new insight. *Am J Obstet Gynecol* 2003; 189(2):438–43.
- [16] Nichols CM, Gill EJ, Nguyen T, et al. Anal sphincter injury in women with pelvic floor disorders. *Obstet Gynecol* 2004; 104(4):690–6.
- [17] Chen GD, Hu SW, Chen YC, et al. Prevalence and correlations of anal incontinence and constipation in Taiwanese women. *Neurourol Urodyn* 2003; 22(7):664–9.
- [18] Gray's Anatomy: Roger Warwick and Peter L. Williams (editors), 35th edition; Longman Group Ltd, 1973; anal musculature, 1293.
- [19] Clinical Anatomy: A Revision and Applied Anatomy for Clinical Students, fifth edition, Harold Ellis (editor); Blackwell Scientific Publications, 1972; 80.

