

We are IntechOpen, the world's leading publisher of Open Access books Built by scientists, for scientists

6,900

Open access books available

186,000

International authors and editors

200M

Downloads

Our authors are among the

154

Countries delivered to

TOP 1%

most cited scientists

12.2%

Contributors from top 500 universities



WEB OF SCIENCE™

Selection of our books indexed in the Book Citation Index
in Web of Science™ Core Collection (BKCI)

Interested in publishing with us?
Contact book.department@intechopen.com

Numbers displayed above are based on latest data collected.
For more information visit www.intechopen.com



Disorders of Optic Nerve and Visual Pathways

Ipek Midi

Additional information is available at the end of the chapter

<http://dx.doi.org/10.5772/58312>

1. Introduction

The evaluation of a patient with visual acuity and visual field defect depends on a detailed history, careful examination and knowledge of anatomic pathways. The structures which are responsible for these pathologies include the retina, optic nerve, optic chiasm, optic tract, optic radiation and visual cortex of the occipital lobe. These structures are called the afferent systems of visual pathways.

Multiple aetiologies can affect and cause different disorders. The history gives the information about the possible aetiologies of the optic neuropathy. There are simple and advanced investigation methods that can support the diagnosis of optic neuropathy. Visual field testing by either manual kinetic or automated static perimetry, cranial and orbital MR, visually evoked potentials and optic coherence tomography are the investigation methods that help in diagnosis. In this chapter optic nerve and visual pathway disorders will be discussed.

1.1. The anatomy of optic nerve and the visual pathways

The visual pathway begins from the globes and extends to the visual cortex in the occipital lobe [1]. The optic nerve (cranial nerve II) leaves the orbit; it reaches to the optic chiasm, which is located besides the pituitary gland. The optic nerve fibres originate from the nasal half of each retina decussate at the optic chiasm level and form an X-shaped structure; on the other hand the nerve fibres of the temporal retina continue their way without crossing [1-3]. From there, most of the axons of the nerve fibres terminate in the lateral geniculate nucleus of the thalamus which is called the **optic tract**, while the other axons terminate in the pretectal nucleus which is responsible for pupillary reflex movements. In its course from the lateral geniculate nucleus to the striate cortex, **optic radiation** fans out under the temporal and parietal lobes. Some of the optic radiation axons run out into the temporal lobe called Meyer's loop. Meyer's loop carries information from the superior portion of the contralateral visual field. More medial

parts of the optic radiation, which pass under the cortex of the parietal lobe, carry information from the inferior portion of the contralateral visual field. Damage to parts of the temporal lobe results in a superior homonymous quadrantanopsia; damage to the optic radiation underlying the parietal cortex results in an inferior homonymous quadrantanopsia type in the visual field. Then the fibres from both the temporal and parietal lobe reach the visual cortex in the occipital lobe [1-3].

Signs of optic nerve dysfunction

1. Reduced visual acuity
2. Afferent pupillary defect
3. Dyschromatopsia (impairment of colour vision)
4. Diminished light brightness sensitivity
5. Diminished contrast sensitivity
6. Visual field defect

1.2. Examination of visual field

Confrontation technique is used to examine the central or peripheral visual dysfunction. The examiner asks the patient to cover one eye and the examiner also covers the opposite eye at the same time. The examiner moves a colourful object in his hand out of the patient's visual field and then brings it centrally. He has to tell the examiner when he notices the object. The same examination must be done for the opposite side [4].

1.3. Clinical features of visual field defect

Damage to the optic nerve causes permanent and severe loss of vision and pupillary reflex abnormalities. According to the localization of lesion, different type of visual field defect can occur. In general [1, 5]:

- If the optic nerve is damaged anterior to the optic chiasm, it causes loss of vision on the same side as the damage
- If the optic nerve is damaged in the optic chiasm level, it causes bitemporal hemianopia. This may occur in expanding pituitary adenoma (Figure 1).
- If optic nerve is damaged posterior to the optic chiasm (optic tract, optic radiation), it causes a visual field defect on the opposite side to the damage [5-7].

The main symptom is vision loss, frequently maximal within one or two days and varying from a small central or paracentral scotoma to complete blindness. Most patients complain of mild eye pain, which often feels worse with eye movements [3, 8].

Optic neuropathy describes abnormalities of the optic nerve [8]. This may occur as a result of ischaemia, vascular and blood pressure abnormalities, toxins, compression, infiltrations and trauma [9,10]. Optic neuropathy is divided into anterior and posterior types: anterior optic

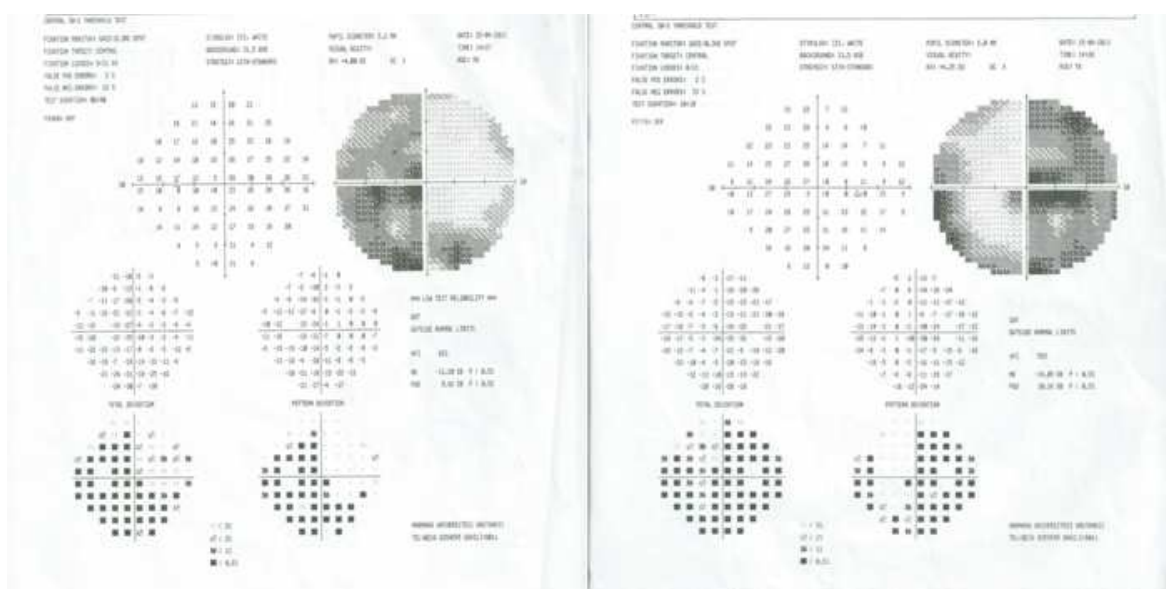


Figure 1. Visual field analysis shows bitemporal hemianopia in a patient with pituitary adenoma.

neuropathy, which causes a pale oedema of the optic disc; and posterior, in which the optic disc is not swollen and the abnormality occurs between the globe and the optic chiasm [3, 4, 8].

1.4. Optic disc oedema and papilloedema

Optic disc oedema is the swelling and elevation of the disc. It can be caused by a number of conditions. Papilloedema relates more specifically to optic nerve head swelling secondary to raised intracranial pressure (Table 1). Disc swelling is distinct from disc atrophy which refers to a loss of nerve fibres at the optic nerve head [2, 3, 11]. There are various signs visible during fundoscopic evaluation. These are: optic disc swelling, unclarity around the margin of the disc, optic disc hyperaemia, venous dilatation, peripapillary haemorrhages, disc exuda or exuda in peripapillary area and cotton wood spots [11].

The pathogenesis of optic disc oedema is mostly related to inhibition of axoplasmic flow. Although histopathological and ophthalmoscopic findings are similar, it is important for treatment approaches to find the causes of optic disc swelling. Often, the cause remains obscure despite undergoing a thorough evaluation [3-11].

Papilloedema is swelling of the optic nerve head, secondary to raised intracranial pressure. This may be due to obstruction of the ventricular system, space-occupying lesion, impairment of cerebro-spinal fluid (CSF) absorption, diffuse cerebral oedema or idiopathic (benign/essential) intracranial hypertension. The patient complains of headache (worse on waking and when coughing) and may have nausea/vomiting. There may be diplopia if there is a VI cranial nerve palsy [3].

In papilloedema, disc swelling is nearly always bilateral (it may be asymmetrical in the early phase) and may be hyperaemic; dilatation of veins and loss of spontaneous venous pulsation

Optic nerve lesions	Tumour (optic nerve sheath meningioma, glioma) Infiltrative lesions (leukaemia, lymphoma) Inflammatory lesions (sarcoidosis) Anterior ischemic optic neuropathy (hypertension, diabetes) Parainfectious and infectious optic neuropathy Trauma
Orbital lesions	Tumour Carotid-cavernous fistula Thyroid ophthalmopathy Trauma or surgery related
Intraocular events	Central retinal vein occlusion Uveitis Ocular hypotonia Papillophelbitis (optic disc vasculitis)
Systemic disease	Hypertension Anaemia Diabetes Mellitus
Leber's optic neuropathy	
Raised intracranial pressure: papilloedema	

Table 1. Causes of optic disc swelling

are the findings of fundoscopic examination. All other causes of disc oedema in the absence of raised intracranial pressure are referred to as disc swelling. But not all patients who have raised intracranial pressure will necessarily develop papilloedema [3]. Visual acuity (VA) is normal in the early stage and will be reduced in the late stage. Colour vision is impaired and there may have a relative afferent pupillary defect (RAPD). Transient obscurations are frequently seen. VI cranial nerve palsy and diplopia are the others clinical features of raised intracranial pressure. In some cases chronic papilloedema can progress to chronic atrophic papilloedema and in this situation visual loss develops [3, 8].

Papilloedema is a neurological emergency. The underlying cause needs to be investigated. After taking a detailed history and physical examination, Cranial CT or MRI has to be evaluated. If there is no space-occupying lesion on Cranial CT or MRI, lumbar puncture decreases the pressure.

2. Disorders of optic nerve (clinical symptoms/ diagnosis/ treatment/ imaging)

2.1. Arteritic ischemic optic neuropathy

Ischemic optic neuropathy is the most commonly seen neuropathy in elderly. Ischemic neuropathy is divided into two parts: 1) Anterior and 2) Posterior. (Both of them are also divided arteritic and non-arteritic forms.)

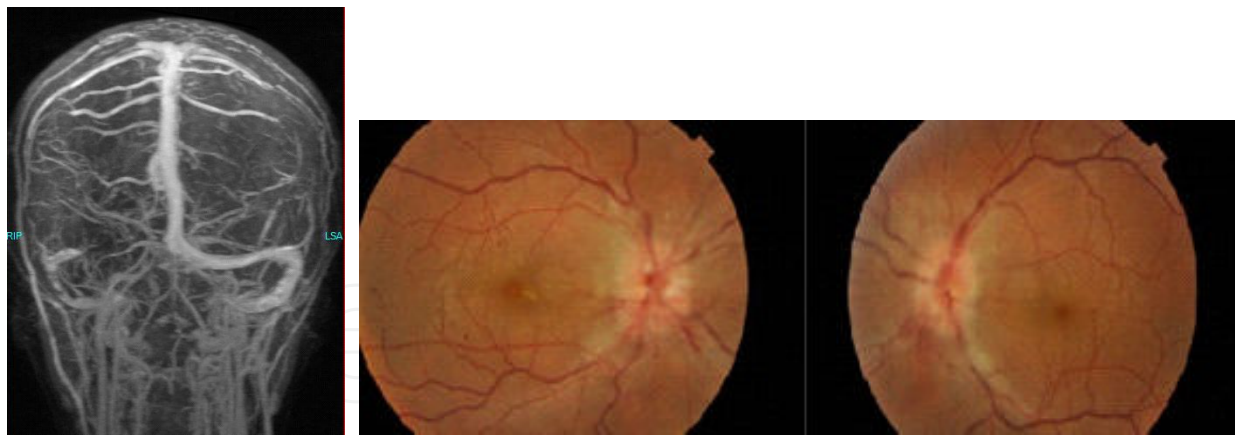


Figure 2. 37 year-old man with venous sinus thrombosis. Papilloedema in early phase is seen. The boundaries of the optic disc are not seen clearly. We do not observe vascular tortuosity (With the permission of Marmara University Dept. of Ophthalmology).

2.1.1. Non-Arteritic Anterior Ischemic Optic Neuropathy (NAAION)

Non-arteritic anterior ischemic optic neuropathy is the most common form of ischemic optic neuropathy. The underlying mechanism of **anterior ischemic optic neuropathy** is the interruption of the blood flow in the short posterior ciliary arteries that supply the optic nerve head. It generally occurs between the ages of 55 and 70 years old. The non-arteritic type involves mainly vascular occlusive disease or disorders that reduce the circulation of blood in the short posterior ciliary arteries. Predisposing systemic conditions include hypertension, diabetes mellitus, hypercholesterolaemia and collagen vascular disease (Table 2).

Visual loss may be sudden or occur over several days. Most of the patients complain of painless *monocular visual loss*. Visual acuity may be normal in about 30% of patients. Impairment of visual acuity in ischemic optic neuropathy may vary from moderate to severe with no light perception. Fundoscopic examination shows a pale, swollen optic disk, with peripapillary haemorrhages noticeable (Figure 3). Inferior altitudinal visual field defects are typical findings but other defects may also be seen. An afferent pupillary defect is present [3, 8, 12, 13].

Investigations: Fasting lipid profile and blood glucose, serological analysis, vasculitis markers, investigations of the carotid artery [3].

Treatment: There is no definite treatment to reverse the damage. Aspirin treatment is effective in reducing systemic vascular events but it does not appear to prevent the involvement of the other eye [3]. However, a recent large study has shown that if patients are treated with large doses of corticosteroid therapy during the early stages of NAION, there was visual acuity improvement in 70% of the treated group compared to 41% in the untreated group (odds ratio of improvement: 3.39; 95% CI:1.62, 7.11; $p < 0.001$) [14]. That study and a natural history study on NAION [15] showed that visual acuity can improve for up to six months. To minimize the risk of further visual loss in the other eye or the same eye, it is essential to reduce the risk factors.

Prognosis: In most patients, there is no further loss of vision but vision loss continues for six weeks in a small percentage of patients. Recurrence rate in the same eye occur is about 6% of patients. Bilateral visual loss may be seen in non-arteritic anterior ischemic optic neuropathy and it usually occurs sequentially instead of simultaneously [16]. The second eye involvement occurs in about 10% of patients after two years and 15% after five years. When the second eye becomes involved, optic atrophy in one eye and disc oedema in the other eye gives the definition of “pseudo-Foster Kennedy Syndrome” [3].

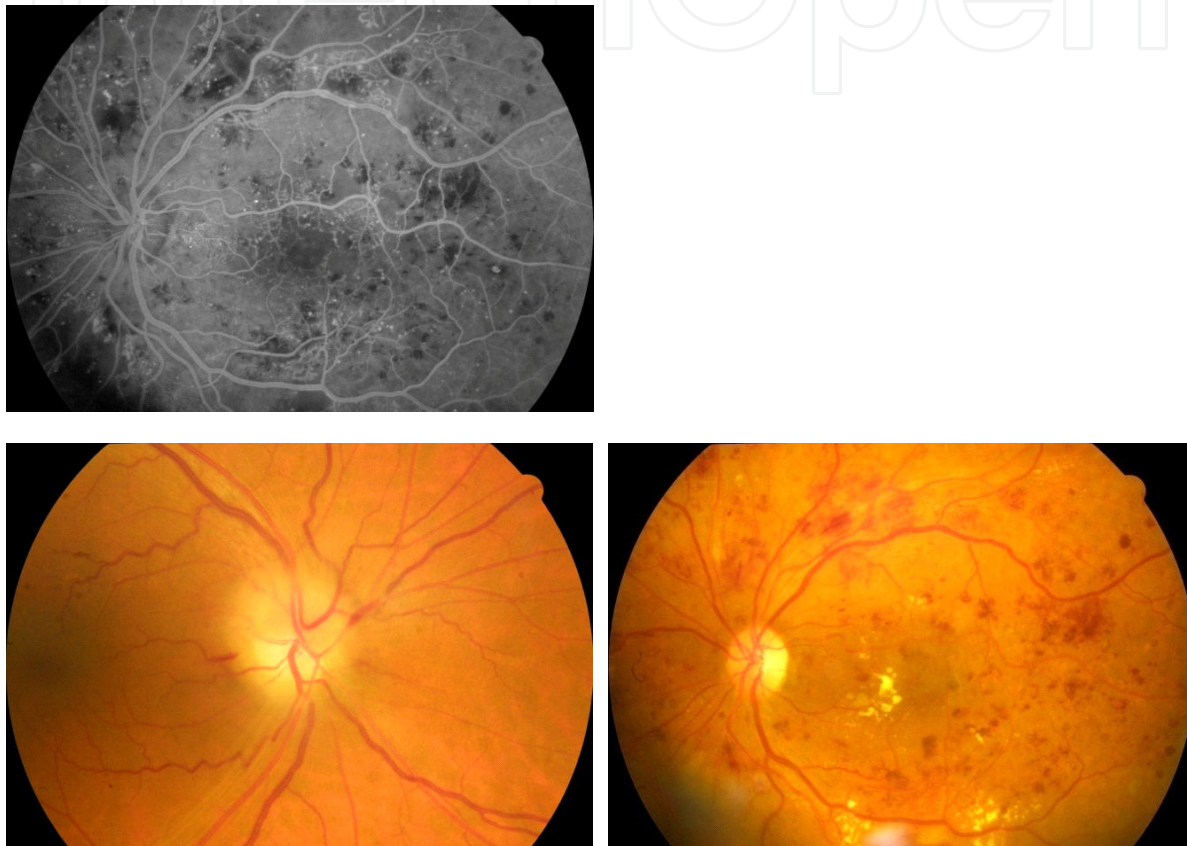


Figure 3. Non-arteritic anterior ischemic optic neuropathy: FFA shows hypofluorescence area caused by diffuse haemorrhage; diffuse microaneurysms, ischemic hypofluorescence area related to peripheral capillary blockages (right eye); crowded optic disc; oedema especially on the upper side; and boundaries on the nasal and temporal side show haemorrhages (left eye) diffuse haemorrhages, exudates and microvascular abnormalities in intraretinal segments (With the permission of Bezmialem University Dept. of Ophthalmology).

2.1.2. Arteritic Anterior Ischemic Optic Neuropathy (AAION)

The arteritic type is less common (25 %). Arteritic anterior ischemic optic neuropathy (AAION) is an acute ischaemia of the posterior ciliary arteries and/or ophthalmic artery due to inflammation. It is also known as giant cell arteritis. The ischaemia of the posterior ciliary arteries and/or the ophthalmic artery is caused by a granulomatous vasculitis of the vessel walls. Therapy is immediate intervention with systemic steroids, especially to protect against vision loss in the other eye [17-19].

The visual loss is sudden and unilateral, but if the treatment is delayed, bilateral visual loss may be seen. Patients with arteritic anterior ischemic optic neuropathy (AION) often have symptoms other than visual loss, such as malaise, weight loss, headache, scalp tenderness and loss of pulsation of one or both temporal arteries, jaw pain on mastication (jaw claudication), generalized muscle aches and swelling. [3, 20]

Investigations: ESR and CRP should be evaluated and they are usually raised. Temporal artery biopsy is the gold standard for diagnosis and should be performed within seven days of starting treatment. But the treatment should never be delayed while waiting for biopsy.

Treatment: Most patients’ treatment continues for one or two years. a) Intravenous methylprednisolone: 1 gr/day for three days and oral prednisolone 80 mg/daily. The treatment regime continues by tapering the oral doses.

CRP is a sensitive marker in monitoring disease activity.

Prognosis: The course of the illness results in poor prognosis. Visual loss is generally permanent; partial visual recovery can be achieved by steroid therapy [3].

Posterior ischemic optic neuropathy is a rare type of neuropathy and diagnosis depends largely upon exclusion of other causes, such as stroke and brain tumour. Decreased visual acuity and altitudinal visual field defects are present. Decreased blood flow in the pial capillary plexus supplying the nerve, connective tissue disorders, diabetes mellitus, trauma and radiotherapy to the orbit have all been described as causes. It is also divided into two types; arteritic and non-arteritic [3, 12] (Table 2).

NON-ARTERITIC	ARTERITIC
Hypertension	Takayasu arteritis
Diabetes Mellitus	Romatoid arterid
Hypercholesterolaemia	Poliarteritis nodusa
Cardiac disease	Behçet’s Disease
Anaemia, hypotension	Crohn’s Disease
Cataract surgery	
Coagulopathies	
Collagen vascular disease	
Hyperhomocysteinaemia	
Antiphospholipid antibody synd.	
Sleep apnoea synd.	

Table 2. Anterior ischemic optic neuropathy

2.2. Inflammatory optic neuropathy

The dysfunction of the optic nerve due to inflammation is called optic neuritis. The acute demyelinating optic neuropathy is the most common type of inflammatory optic neuropathy. Systemic or local inflammations and infections can cause inflammatory optic neuropathy other than acute optic neuropathy [21].

Symptoms are usually unilateral, with eye pain and partial or complete vision loss. Diagnosis is primarily clinical. Treatment is directed at the underlying condition; most cases resolve spontaneously [3, 8].

Optic neuritis: Optic neuritis is an inflammatory, demyelinating condition occurring in 50% of individuals at some point in the course of their illness [21]. Optic neuritis is highly associated with multiple sclerosis (MS), approximately 15-20% of MS patients attend hospital with optic neuritis and optic neuritis occurs in 50% of patients with established MS [3]. The ages of the patients are generally between 18 and 40 years. Symptoms develop over a few to several days, reaching maximum severity within two weeks. Fundoscopic examination shows that the appearance of optic disc is normal because the illness enhances the optic nerves of the retrobulbar type. Ninety-five percent of patients demonstrate an optic nerve enhancement in Gadolinium-enhanced magnetic resonance imaging (MRI).

Patients typically present with subacute, monocular visual loss. The patients complain of pain in or around the eye which increases with ocular movement. Characteristic findings other than visual loss include a visual field deficit (usually central scotoma type), disturbed colour vision, an afferent pupillary defect, diminished light brightness and impairment contrast sensitivity. The Optic disc is normal in about two thirds of patients (inflammation is entirely retrobulbar). The rest show disc hyperaemia, oedema in or around the disk and vessel engorgement. A few exudates and haemorrhages may be present. Visual recovery is common and often complete; most patients achieve better vision over 6-12 months [3]. Despite the return of visual acuity, colour vision, contrast sensitivity and light brightness often remain abnormal [3]. Recurrent attacks may cause optic atrophy.

The Optic Neuritis Study Group published their findings in 2003 [22]. The aim of the study was to identify the factors associated with a high and low risk of developing multiple sclerosis after an initial episode of optic neuritis. Three hundred and eighty-eight patients who had acute optic neuritis were included the study and were followed up for the development of multiple sclerosis after an initial episode of acute optic neuritis for a 10 year risk. The 10-year risk of multiple sclerosis was 38% (95% confidence interval, 33%-43%). Patients (160) who had one or more typical lesions on baseline T2 weighted magnetic resonance imaging (MRI) scan of the brain had a 56% ; those with no lesions (191) had a 22% risk ($P < .001$, log rank test).

Diagnosis: Optic neuritis is suspected in patients with characteristic pain and vision loss. Gadolinium-enhanced orbital MRI may show an enlarged, enhanced optic nerve. Typical demyelinating lesions in a periventricular location in cranial MRI especially T2 or FLAIR weighed imaging may also help the diagnosis of multiple sclerosis (Figure 4).

Prognosis: Prognosis depends on the underlying condition. Most episodes resolve spontaneously, but > 25% have a recurrence in the same eye or in the other eye.

Treatment: Corticosteroids are an option, especially if multiple sclerosis is suspected. Treatment with methylprednisolone (1 gr /day) for five to seven days may speed recovery, but ultimate visual recovery is no different from those with observation alone.

Final visual outcomes are not influenced by treatment, but recovery can be reached quickly by intravenous methylprednisolone. Oral prednisone therapy alone is contraindicated because it is associated with a significantly higher recurrence rate. Patients at high risk for multiple sclerosis, assessed on the basis of MRI, may benefit from immunomodulatory therapy [3].

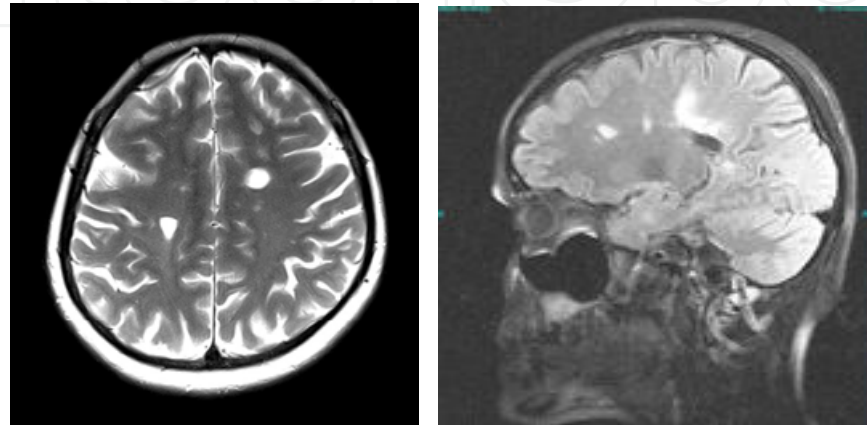


Figure 4. The hyperintense lesion on T2-and FLAIR weighted images. Corpus callosum involvement is noted on the sagittal T2WI.

2.3. Traumatic Optic Neuropathy (TON)

TON refers to the direct or indirect injury of the optic nerve secondary to trauma. The optic nerve runs in the optic canal and can be affected indirectly from blunt head trauma. The visual loss may be partial or complete and generally causes severe and permanent visual defects.

The incidence of traumatic optic neuropathy in a closed traumatic head injury ranges from 0.5-5%. The International Optic Nerve Trauma Study revealed that it was much more common in males (up to 85%) and that the average age of patients was 34 years old [23]. The most common causes were motor vehicle and bicycle accidents, followed by falls and assaults. Loss of consciousness can accompany 40-72% of cases. The diagnosis of TON is difficult and can be delayed when life-threatening systemic symptoms are present.

Direct optic nerve injury is generally rare because of the protecting effect of the orbital bones. It is caused by trauma to the head or orbit. In direct trauma, the anatomy and function of the optic nerve are disrupted. Penetrating injury to the orbit and bony fragments in the optic canal or orbit can result in optic nerve piercing. Orbital haemorrhage and optic nerve sheath haematoma can also cause TON by direct compression. The diagnosis of TON depends on the clinical signs. The cases of TON are generally of monocular involvement. Visual acuity is generally below 0.1. Visual defect is often seen in the acute phase. But delayed visual loss can develop in 10% of cases. The diagnosis of it is important because of the possibility of surgical

intervention. Colour vision dysfunction, visual field defect and visual evoked potential are established.

Indirect injuries transmit force to the optic nerve without transgressing tissue planes. This type of injury is most common in the intracanalicular portion of the nerve. Direct optic nerve injuries crosses normal tissue planes and disrupts the anatomy and function of the optic nerve; e.g., a bullet or forceps that physically injures the optic nerve. Indirect injuries, like blunt trauma to the forehead during a motor vehicle accident, transmit force to the optic nerve without transgressing tissue planes. This type of force causes the optic nerve to absorb excess energy at the time of impact. The most common site of injury is the intracanalicular portion of the nerve. Optic neuropathy is most commonly seen in patients in an unconsciousness state associated with a fall [3, 8, 24, 25].

2.4. Compressive optic neuropathy (CON)

CON is the result of compression of the optic nerve. The optic nerve can be pressed in the orbit, the optic canal and the intracranial levels. But it is much more strongly related to orbital pathologies. The optic nerve is most vulnerable to injury by a compressive force in the orbital apex or optic canal [26]. The optic nerve is resistant to force in other parts of the orbita and intracranial level. The most common causes of compressive optic neuropathy in the orbit are inflammatory disease (thyroid orbitopathy, pseudotumour orbita, orbital cellulitis), tumours and orbital traumas. A variety of tumours can produce optic nerve compression. Sellar and parasellar masses (craniopharyngioma, meningioma, or pituitary adenoma), optic nerve sheath meningiomas and metastatic lesions are included in the differential diagnosis. The other causes related to intracranial pathologies include hypophysis tumours, meningiomas, craniopharyngiomas and aneurisms [3, 8, 27].

Tumours can also infiltrate the optic nerve, particularly optic nerve gliomas (in neurofibromatosis), also lymphoma and other hematologic malignancies. These pathologies can also infiltrate rather than compress the optic nerve [28, 29].

Cranial computerized tomography is preferred as a means to detect orbital lesions and MRI is a useful technique to find out intracranial pathologies [3, 27].

Tumours and thyroid orbitopathy cause slowly progressive visual loss in the course of the disease [27, 30]. But in the situations like orbital trauma, hematoma and cellulitis cause acute vision loss. If compressive optic neuropathy cannot be treated, the results will be optic atrophy and blindness. Pain is variable in these cases.

2.5. Toxic and nutritional optic neuropathy

The causes of these disorders are various. A lot of drugs may cause toxic optic neuropathy; alcohol and tobacco have also a greater risk of causing toxic neuropathy [31-38].

2.6. Nutritional optic neuropathy

The predominant cause of nutritional optic neuropathy is thought to be a deficiency of B-complex vitamins while folic acid also seems to play a role. The toxic agents are summarized in Table 3.

Signs and symptoms: vision loss in toxic and nutritional optic neuropathy is bilateral, usually symmetric, painless, onset may be abrupt or gradual and progressive [3, 8, 32] (Figure 5).

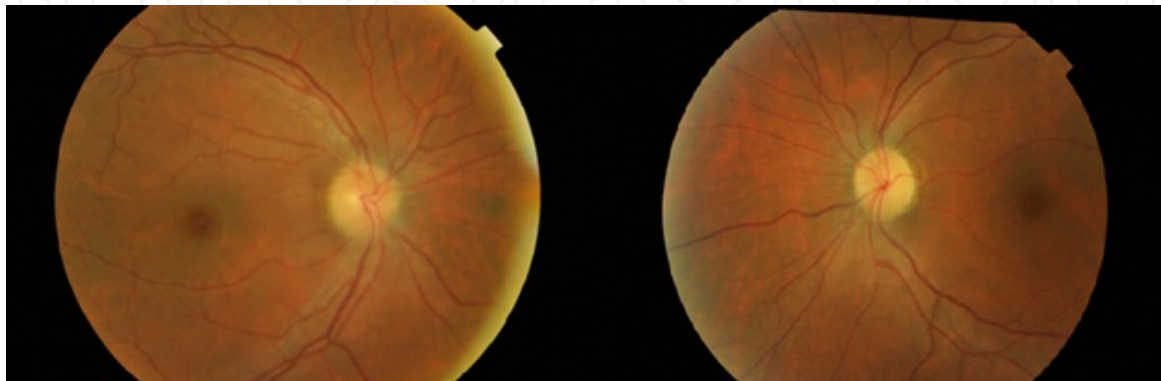


Figure 5. 56 year-old man who has a diagnosis of gastric cancer and is being treated with chemotherapy. Optic atrophy on the right eye and oedema of the optic nerve head on the left eye. The boundary of the optic disc is not seen clearly (With the permission of Marmara University Dept. of Ophthalmology).

DRUGS	Antibiotics: Chloramphenicol, linezolid, sulphonamides
	Antitubercular drugs: Ethambutol, isoniazid, streptomycin
	Antimalarials: Quinine, chloroquine
	Antiarrhythmic drugs: Amiodarone, digitals
	Anticancer drugs: Methotrexate, vincristine, 5FU, carboblastine
	Immune modulators and suppressants: Cyclosporine, tacrolimus, α interferon-2b
	Other: Sildenafil, cimetidine, infliximab, melatonin, sertraline hydrochloride (Zoloft)
ALCOHOLS	Alcohols derives: Methanol, ethylene glycol (antifreeze), toluen
METALS	Heavy metals: Lead, mercury, thallium
OTHERS	Carbon monoxide, tobacco, radiation (unshielded exposure to >3,000 rads)
NUTRITIONALS	Vitamin B1 (tiamin), vitamin B2 (riboflavin), vitamin B3 (niacin), vitamin B6 (pyridoxine), vitamin B12 (cyanocobalamin), folic acid

Table 3. Common causes of toxic and nutritional optic neuropathy

Management: The first step in the treatment of toxic optic neuropathy is to remove the offending agent. The prognosis is variable and dependent upon the affected individual, the nature of the agent, the total exposure duration and doses before the removal of agent and the degree of vision loss at diagnosis.

Patients with toxic/nutritional optic neuropathy should be observed initially every four to six weeks and then, depending on their recovery, every six to 12 months. The patient’s visual acuity, pupils, optic nerves, colour vision and visual fields should be checked at each visit. Vision gradually recovers to normal over several weeks, though it may take months for full recovery. Some patients have a risk of permanent residual vision deficit. Visual acuity usually recovers before colour vision [30].

2.7. Hereditary optic neuropathy

Hereditary optic neuropathies are divided into two types. Primary hereditary optic neuropathy refers to cases in which optic nerve pathology is the only sign. On the other hand there are also other groups of hereditary diseases which include various neurological and systemic abnormalities other than optic nerve abnormalities. [(These include: autosomal recessive and maternal inheritance forms of optic atrophy with diabetes incipidus, diabetes mellitus and deafness (Wolfram syndrome, DIDMOAD); autosomal recessive bilateral optic atrophy with spastic paraparesia, chorea and cognitive impairment (Costeff syndrome)]. The most common of these disorders are autosomal dominant optic atrophy (Kjer’s disease) and maternally-inherited Leber’s hereditary optic neuropathy (Table 4) and these will be discussed in this chapter. However autosomal recessive and X-recessive pattern have been shown in very rare cases [3, 8, 39, 40].

Autosomal Dominant Optic Atrophy (OPA1, Kjer’s type)
Leber’s Hereditary Optic Neuropathy (LHON)

Table 4. Primary hereditary optic neuropathies

With the remarkable advances in genetic science, the locus of the chromosome was defined and localized in optic neuropathies related to hereditary origin. Despite their genetic origin, these two hereditary optic neuropathies have a pathophysiology reflecting a common pathway in mitochondrial dysfunction. (LHON is a result of point mutations in the mitochondrial DNA and Dominant Optic Atrophy (DOA) is a consequence of mutations in nuclear chromosomes).

Kjer’s type autosomal dominant optic atrophy: This is the most commonly seen hereditary optic neuropathy. The incidence of dominant optic atrophy has been estimated to be 1:50000 with a prevalence of 1:10000 in the Danish population. This entity primarily affects children in the first decade of life. But in some cases the beginning of the disease is delayed to 60-70 years of age. Bilateral visual acuity loss is commonly present and relatively symmetrical. Most patients cannot identify a precise onset and the illness usually shows mild, slow and gradual progression. More than 80% of patients maintain better than 20/200 vision, but interfamilial and intrafamilial variation in visual acuity can be seen [41]. There is pallor of the optic disc, cecentral scotoma and colour vision loss also accompanies the visual acuity [42-43].

Kjer et al. have examined 62 patients from three large Danish families with autosomal dominant optic atrophy and followed up 30 patients retrospectively. They found great inter-

and intrafamilial variation in visual acuity and visual decline. They analysed 175 chromosomal markers in 118 family members. All markers are located on chromosome 3q in the telomeric area. They found the most probable location for the OPA1 gene was D3S1601-OPA1-D3S1265. Using data from the Danish Family Register of Hereditary Eye Diseases, the minimum prevalence rate was estimated to be 1:12.301. With the results of this investigation, DOA has become the most common hereditary optic atrophy [44].

Leber's hereditary optic neuropathy (LHON): this is a rare disease when compared to Kjer's. Maternal inheritance is present. So this disorder affects young males predominantly (80 to 90% of patients) between the ages of 15 and 35 years. It is inherited through a mitochondrial DNA mutation. More than 90% of all cases have three mutations at positions 11778, 3460 and 14484 [45]. These genes are involved in the Complex I enzyme subunit in the mitochondrial respiratory chain [39].

The vision loss in patients with LHON is subacute and painless, severe, with sequential involvement of both eyes over a period of weeks to months. Fundoscopic examination usually shows circumpapillary telangiectasia, but up to 30% of patients can have normal disc appearance. Nerve fibre layer swelling around the disc can be seen; leakage from the disc or papillary area is not present in the fluorescein angiography [46]. Central vision is affected more severely. With the progression of the disease, telangiectasia vessels and pseudopapilloedema of the disc disappears and optic atrophy takes place. Optic nerve abnormality can be shown in MRI, but enhancement usually does not occur [47, 48]. LHON shows varying penetration and the prognosis for recovery depends on the mutation [45]. The 11778 mutation carries the worst prognosis.

Management: Therapies for mitochondrial disorders are very limited. Currently there is no effective therapy for dominant optic atrophy. Children of patients should be screened regularly for visual changes related to dominant optic atrophy. Nutritional supplements such as vitamin B12 and C, Coenzyme-Q10 and lutein have been suggested [49, 50].

2.8. Parainfectious optic neuritis

Optic neuropathy may be associated with postviral infections and occur as a post vaccination phenomenon [3, 8]. Underlying mechanisms may be related to immune mediated process. Children are affected more frequently than adults and this may occur after immunizations [51].

Presentation: Severe acute visual loss, usually bilateral and occurs one to three weeks following a viral infection (e.g., measles, mumps, chickenpox, whooping cough, glandular fever). Other neurological features such as headache, seizure or ataxia may also be seen. There may also be a meningoencephalitis. Bilateral optic neuritis can also occur in Guillain-Barré syndrome [52, 53].

Ocular findings: The optic disc frequently shows bilateral papillitis or may be normal.

Treatment: Treatment is not necessary in the majority of patients. Spontaneous visual recovery is very good [3]. However when visual loss is severe and bilateral, intravenous steroids should be considered.

2.9. Infectious optic neuritis

Meningitis or encephalitis may cause optic neuritis, either as a direct effect of the infectious organism or from secondary vasculitis [51]. Signs and symptoms related to infection, MRI and CSF findings carry some information about causative agents [54-62]. When the meningitis is more indolent, as in some cases of tuberculosis and cryptococcus, optic nerve involvement may be a primary manifestation.

Sinus infections: Sinus related optic neuritis is a rare condition. It may occur following sphenoidal sinusitis. The underlying mechanisms include spread of infection directly, occlusive vasculitis and pressure by a mucocele. Patients complain of severe headaches and recurrent episodes of unilateral visual loss. Treatment with systemic antibiotics is necessary but surgical drainage of the sinus may also be needed.

Acute viral infections, as well as cat scratch disease and toxoplasmosis and others, can cause an isolated infection of the eye. Inflammation of the retina associated with the optic disc is called neuroretinitis. Neuroretinitis is another finding of ophthalmoscopic investigation. Fundoscopic examination usually reveals macular oedema, in addition to optic disc swelling. Corticosteroids and systemic antibiotics can be used for treatment. The West Nile virus in particular has been reported to produce optic neuritis in association with meningitis. Syphilitic optic neuritis may be monocular or binocular and is associated with vitreal inflammation; acute optic neuritis may occur both in the primary or secondary stages. Antibiotic therapy may improve the symptoms, but relapse may be seen. Lyme disease may cause acute retrobulbar optic neuritis and neuroretinitis. It may mimic multiple sclerosis symptoms. The treatment includes intravenous ceftriaxone [3].

Varicella-zoster virus: primary optic neuritis is uncommon unless the patient is immunocompromised. Secondary optic neuritis arises from viruses spread from contiguous retinitis. Treatment is with intravenous (IV) antivirals. Cat-scratch fever: this self-limiting infection has a good prognosis with visual recovery. Treatment is with antimicrobial agents.

2.10. Infiltrative optic neuropathy

The optic nerve can be infiltrated by a variety of factors, including tumours, inflammation and infections [63].

The optic nerve has three parts as described by anatomic localization: intraocular, intraorbital and intracranial. The tumours which originate in these locations can expand to the optic nerve. Optic neuropathy related to tumours is generally of the compressive type, but the tumour cells can also infiltrate directly into the optic nerve, which cause infiltrative optic neuropathy. The difference between these two entities is important because removing the compression is the only solution in compressive neuropathy whereas in infiltrative neuropathy the eradication of tumour is the treatment. Tumours that infiltrate the optic nerve can be primary (optic gliomas, capillary haemangioma and cavernous haemangioma) or secondary (metastatic carcinoma, nasopharyngeal carcinoma, lymphoma and leukaemia). The underlying mechanism of paraneoplastic optic neuropathy is related to the development of autoantibodies (ex:anti-CV2) (Figure 6).

Infections, which include viruses, bacteria and opportunistic fungi, may also infiltrate the optic nerve. The appearance of the nerve on examination depends on the portion of the nerve that is affected. If the infiltration occurs in the proximal portion of the nerve, the optic nerve may be elevated. The optic nerve can be affected by a variety of systemic, auto-immune and infectious disorders such as sarcoidosis, systemic lupus erythematosus, Behçet's disease, inflammation, bowel disease, Sjogren's syndrome, Wegener's granulomatosis, syphilis, Lyme disease and cat-scratch disease. [8, 64, 65] (Figure 7).

Sarcoidosis is the most common inflammatory disorder that infiltrates the optic nerve. One to 5% of patients with neurosarcoid develop optic neuritis. Optic nerve head exhibits a characteristic lumpy appearance. Steroid treatment is effective and rapid, but some patients require long term low dose steroid therapy. In addition to steroids, some patients may also be given methotrexate treatment and methotrexate is an alternative to steroids for intolerant patients [3].

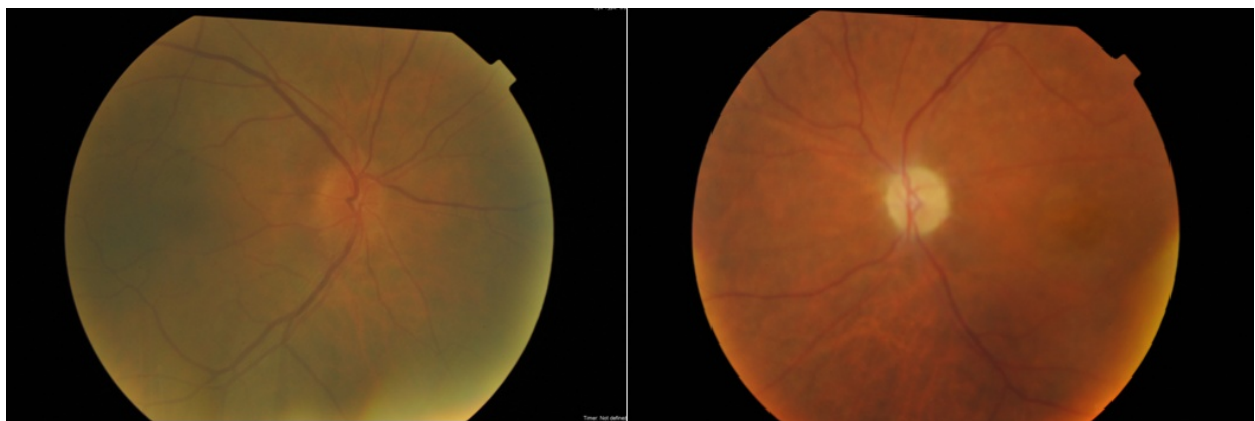


Figure 6. Optic neuropathy with underlying paraneoplastic aetiology (With the permission of Marmara University Dept. of Ophthalmology).

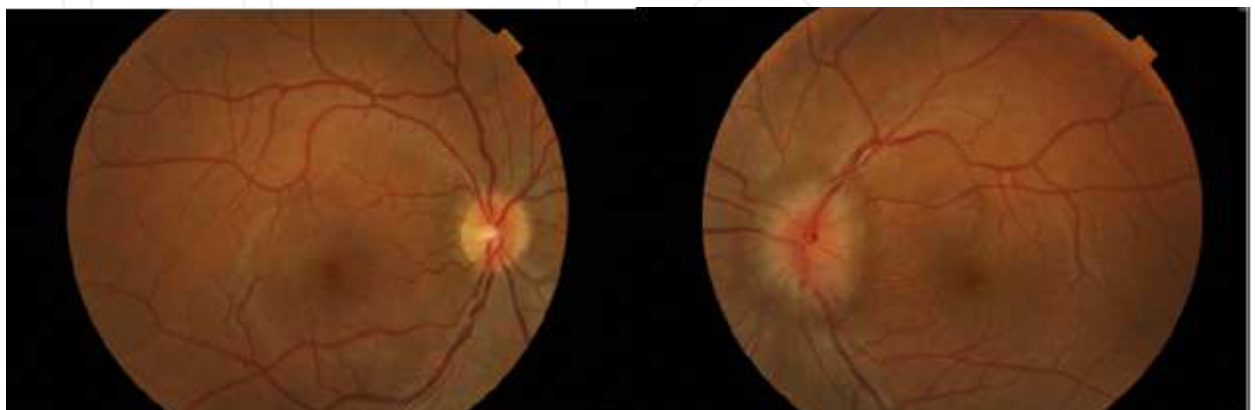


Figure 7. 43 year-old female patient using plaquenil (hydroxychloroquine) following diagnosis SLE. (With the permission of Marmara University Dept. Of Neurology)

2.11. Idiopathic intracranial hypertension (*pseudotumour cerebri, benign intracranial hypertension*)

Idiopathic intracranial hypertension (IIH) is known by raised intracranial pressure in the absence of a mass lesion or of hydrocephalus. It is mostly related to impaired cerebrospinal fluid (CSF) absorption from the subarachnoid space. It is common in obese woman of 20-40 years of age. The female to male ratio is between 3:1 and 8:1. Up to 90% of patients are overweight. IIH may result in permanent visual loss due to papilloedema (Figure 8). The clinical signs and symptoms are summarized in Table 5 (66). IIH may also be caused by drugs. Lumbar puncture (LP) is one of the treatment methods and is also useful for the diagnosis. If the opening pressure is >250 mm H2O and LP shows no inflammatory cells with normal CSF protein and glucose levels, the diagnosis will be achieved. Cranial MRI shows normal ventricles and often an empty sellar. Venous sinus thrombosis should be excluded by the cranial MR venography. Other secondary causes are summarized in Table 6. Regular perimetric examination is important to follow the progression of the disease [3].

Medical and lifestyle treatment: 1) weight loss, 2) Asetozolamide, 3) Furosemide, 4) Topiramate.

Surgical treatment: 1) repeated lumbar puncture, 2) optic nerve sheath decompressions, 3) ventriculoperitoneal shunt placements, 4) lumboperitoneal shunt placement [3]

Symptoms (68)	Signs
Headache (92%)	Papilloedema
Transient visual obscurations (72%)	Visual fields deficit
Pulsatil tinnitus (60%)	Contrast sensitivity loss
Photopsia (54%)	Decrease in visual acuity
Retrobulbar pain (44%)	Problems in colour vision
Diplopia (38%)	Relative afferent pupillary defect
Sustained visual loss (26%)	VI nerve paralysis (transient)

Table 5. Signs and symptoms in intracranial hypertension

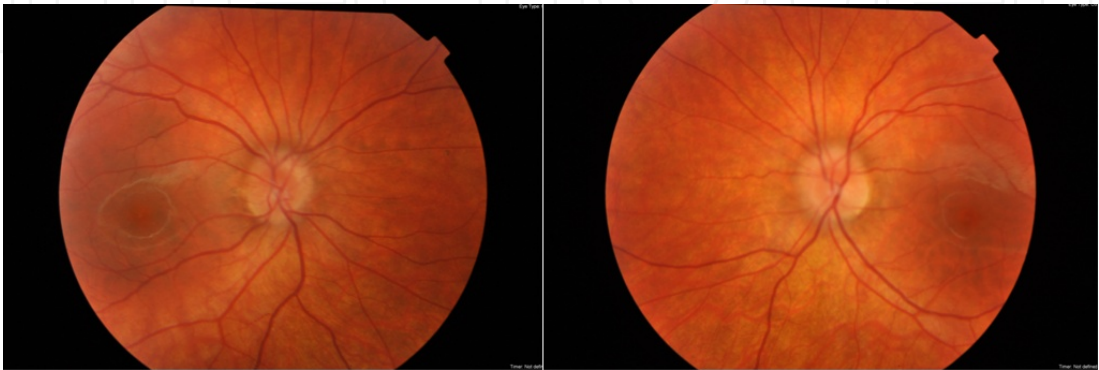


Figure 8. Early papilloedema (With the permission of Marmara University Dept. of Ophthalmology).

Endocrine	Addison disease, Cushing disease, puerperium, polycystic ovarian syndrome, hyper and hypothyroidism, hypoparathyroidism
Venous hypertension	Venous sinus thrombosis
Metabolic disease	Renal insufficiency, Diabetes mellitus, iron deficiency, pernicious anaemia, hypercapnia, Addison disease, Cushing disease, puerperium, polycystic over syndrome, hyper and hypothyroidism, hypoparathyroidism
Cranial trauma	
Parainfectious and immunological states	Behçet's disease, systemic lupus erithomatosus, sarcoidosis, HIV, Lyme
Meningial carcinomatosis	
Gliomatosis cerebri	
Medication and vitamin	cimetidine, corticosteroids, levothyroxine, lithium, minocycline, nalidixic acid, nitrofurantoin, tamoxifen, tetracycline, ciclosporin, oral contraceptive, recombinant and natural human growth hormone, Hypervitaminosis A
Obstructive sleep apnoea syndrome	

Table 6. Causes of secondary intracranial hypertension

2.12. Pseudopapilloedema (Drusen)

Hyaline-like calcific material on the optic nerve head is the characteristic feature of optic disc drusen. They are generally bilateral. In early childhood, its diagnosis is difficult because they lie deep. They may mimic papilloedema. Hyperaemia is absent and the surface vessels are not obscured. Disc is elevated without a physiological cup [3].

Ultrasound B-scan is the most reliable method and calcific deposits are detected easily. CT also shows the disc calcification but it is less sensitive than ophthalmic ultrasound [3] (Figure 9).

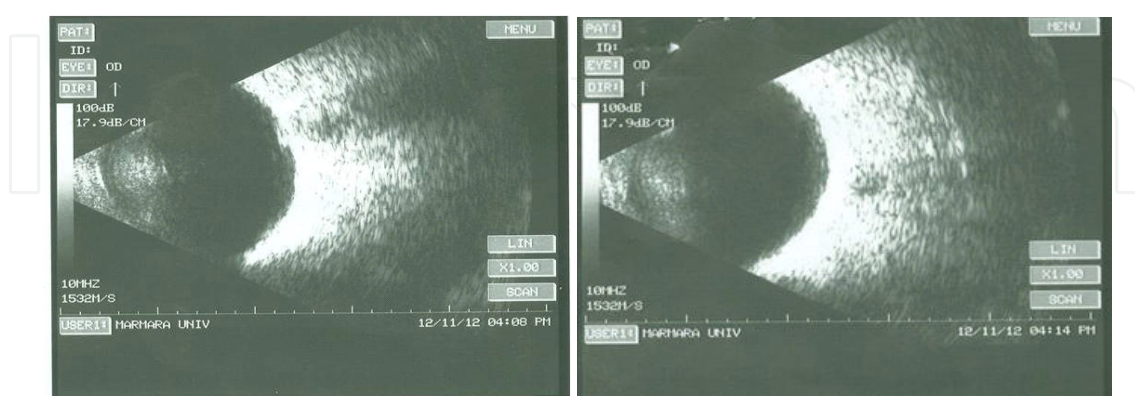


Figure 9. B-scan shows high acoustic reflectivity (With the permission of Marmara University Dept. of Ophthalmology).

In conclusion, disorders of the optic nerve may be related to congenital or acquired causes. There are many aetiologies that affect the optic nerve and according to the localization of lesion,

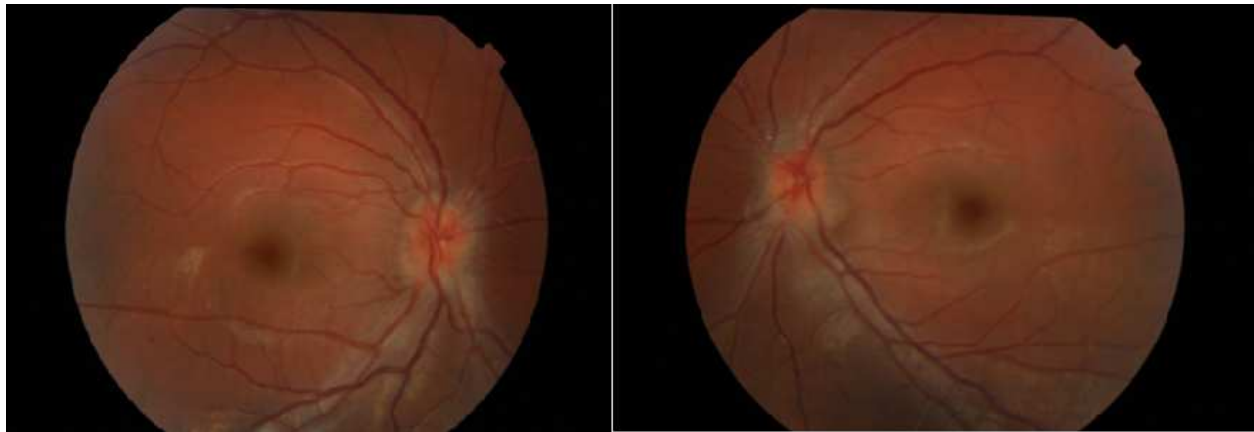


Figure 10. Optic disc drusen (With the permission of Marmara University Dept. of Ophthalmology).

different types of visual field defect can occur. The optic disc may show different abnormalities or may be of normal appearance on fundoscopic examination.

Acknowledgements

I greatly appreciate the Ophthalmology Department of Marmara University Hospital for supplying images for this chapter. I am very grateful to the following colleagues for their help Professor Dr. Ozlem Sahin, Assistant Dr. Umeyye Taka Aydin from Marmara University Dept. of Ophthalmology and Assistant Associate Professor Dr. Arif Koytak from Bezmialem University in the Dept. of Ophthalmology.

Author details

Ipek Midi*

Marmara University Pendik Research and Training Hospital, Department of Neurology, Istanbul, Turkey

References

- [1] Smith MM, Strottmann JM. Imaging of the optic nerve and visual pathways. *Semin Ultrasound CT MR.* 2001; 22(6): 473-87.
- [2] Anatomy and Physiology of the Retina and Optic Nerve. In Walsh & Hoyt's. *Clinical Neuro-ophthalmology.* 5th ed. The Essentials. Ed. NR Miller, NJ Newman. Williams & Wilkins. 1999: 59-86.

- [3] Burton B. Chapter 21: Neuro-ophthalmology. In *Clinical Ophthalmology A Systemic Approach*. 6th ed. Ed. Kanski JJ. Butterworth Heinemann Elsevier 2007: 785-836.
- [4] Kansu T. Chapter 2 (Section I): Afferent System (Examination and diagnosis) In *Neuro-ophthalmology Handbook*. 1st ed. Ed. O'Dwyer PA, Kansu T, Torun T. Güneş Medicine Publishing;2008: 9-17 (Turkish).
- [5] Sadun AA. The afferent visual system: Anatomy and Physiology. In *Ophthalmology*, 2nd ed. Ed. Yanoff M, Duker JS. Mosby, St. Louis 2004: 186.
- [6] Glaser JS. Topical diagnosis: Prechiasmal visual pathways. In *Neuro-ophthalmology*. Ed. Glaser JS. JB Lippincott, Philadelphia 1990: 83.
- [7] Purves D, Augustine GJ, Fitzpatrick D, et al., Visual Field Deficits. In *Neuroscience*. 2nd ed. Ed. Sunderland (MA). Sinauer Associates; 2001.
- [8] Osborne B, Balcer LJ. Optic Neuropathies. Section Ed: Brazis PW. Up to date 2013.
- [9] Behbehani R. Clinical approach to optic neuropathies. *Clin. Ophthalmol.* 2007; 1(3): 233-46.
- [10] Purvin VA. Optic neuropathies for the neurologist. *Semin Neurol.* 2000; 20(1): 97-110.
- [11] Kadayifcilar S. Chapter 9 (Section II): Optic disc edema and papilloedema. In *Neuro-ophthalmology Handbook*. 1st ed. Ed. O'Dwyer PA, Kansu T, Torun T. Güneş Medicine Publishing;2008: 101-5. (Turkish).
- [12] Bajin MS. Chapter 2 (Section II): Ischeic Optic Neuropathies. In *Neuro-ophthalmology Handbook*. 1st ed. Ed. O'Dwyer PA, Kansu T, Torun T. Güneş Medicine Publishing; 2008:51-8. (Turkish).
- [13] Newman NJ, Scherer R, Langenberg P, Kelman S, Feldon S, Kaufman D, Dickersin K; Ischemic Optic Neuropathy Decompression Trial Research Group. "The fellow eye in NAION: report from the ischemic optic neuropathy decompression trial follow-up study." *Am J Ophthalmol.* 2002; 134(3): 317-28.
- [14] Hayreh SS, Zimmerman MB. Non-arteritic anterior ischemic optic neuropathy: role of systemic corticosteroid therapy. *Graefes Arch Clin Exp Ophthalmol.* 2008; 246(7): 1029-46.
- [15] Hayreh SS, Zimmerman MB. Non-arteritic anterior ischemic optic neuropathy: natural history of visual outcome. *Ophthalmology* 2008; 115:298-305.
- [16] Anterior Ischemic Optic Neuropathy Author: Brian R Younge; Chief Editor: Hampton Roy Sr, et al. Medscape Jan 2012.
- [17] Thorne JE, Jabs DA. Ocular manifestations of the rheumatic diseases. In: *Duane's Clinical Ophthalmology*. Ed. Tasman William. Vol. 5. Philadelphia: Lippincott Williams & Wilkins; 2005: 22-24.

- [18] Hayreh SS, Zimmerman B, Kardon RH. Visual improvement with corticosteroid therapy in giant cell arteritis. Report of a large study and review of literature. *Acta Ophthalmol Scand.* 2002; 80:353–67.
- [19] Foroozan R, Deramo VA, Buono LM, et al. Recovery of visual function in patients with biopsy-proven giant cell arteritis. *Ophthalmology.* 2003; 110: 539–42.
- [20] Hayreh SS. Anterior ischaemic optic neuropathy, differentiation of arteritic from non-arteritic type and its management. *Eye* 1990; 4: 25–41;
- [21] Acaroglu G. Chapter 1 (Section II): Inflammatory Optic Neuropathy. In *Neuro-ophthalmology Handbook* 1st ed. Ed. O'Dwyer PA, Kansu T, Torun T. Güneş Medicine Publishing;2008: 43-49 (Turkish)
- [22] Beck RW, Trobe JD, Moke PS, GalRL, Xing D, BhattiMT, et al; Optic Neuritis Study Group. High-and low-risk profiles for the development of multiple sclerosis within 10 years after optic neuritis: experience of the optic neuritis treatment trial. *Arch Ophthalmol.*2003; 121(7): 944-9.
- [23] Levin LA, et al., The treatment of traumatic optic neuropathy: the International Optic Nerve Trauma Study. *Ophthalmology*, 1999. 106(7): 1268-77.
- [24] Steinsapir KD, Goldberg RA. Traumatic optic neuropathy: an evolving understanding. *American Journal of Ophthalmology.* 2011; 151: 928-933.
- [25] Onder F. Chapter 3 (Section II): Afferent System (Examination and diagnosis). In *Neuro-ophthalmology Handbook.* 1st ed. Ed. O'Dwyer PA, Kansu T, Torun T. Güneş Medicine Publishing;2008: 59-64 (Turkish)
- [26] Miller NR, Newman NJ, Biousse V. Walsh and Hoyt's Clinical Neuro-Ophthalmology. 6th ed. Lippincott, Williams & Wilkins; 2004.
- [27] Yazici B. Chapter 4 (Section II): Compressive Optic Neuropathy. In *Neuro-ophthalmology Handbook.* 1st ed. Ed. O'Dwyer PA, Kansu T, Torun T. Güneş Medicine Publishing;2008: 65-71 (Turkish)
- [28] Lee AG, Tang RA, Roberts D, et al. Primary central nervous system lymphoma involving the optic chiasm in AIDS. *J Neuro-ophthalmol* 2001; 21:95.
- [29] Grimm SA, McCannel CA, Omuro AM, et al. Primary CNS lymphoma with intraocular involvement: International PCNSL Collaborative Group Report. *Neurology* 2008; 71:1355.
- [30] Maheshwari R, Weis Ezekiel. Thyroid associated orbitopathy. *Indian J Ophthalmol.* 2012; 60(2): 87–93.
- [31] Sharma P and Sharma R. Toxic optic neuropathy. *Indian J Ophthalmol.* 2011; 59(2): 137–141.

- [32] Kargi SH. Chapter 6 (Section II): Toxic and Nutritional Optic Neuropathy. In Neuro-ophthalmology Handbook. 1st ed. Ed. O'Dwyer PA, Kansu T, Torun T. Güneş Medicine Publishing;2008: 81-88 (Turkish)
- [33] Lim SA. Ethambutol-associated optic neuropathy. *Ann Acad Med Singapore*. 2006; 35(4): 274-8.
- [34] Orssaud C, Roche O, Dufier JL. Nutritional optic neuropathies. *J Neurol Sci*. 2007; 262(1-2): 158-64.
- [35] Murphy MA, Murphy JF. Amiodarone and optic neuropathy: the heart of the matter. *J Neuroophthalmol*. Sep 2005; 25(3): 232-6.
- [36] Grzybowski A, Holder GE. Tobacco optic neuropathy (TON)-the historical and present concept of the disease. *Acta Ophthalmol*. 2011; 89(5): 495-9.
- [37] Wilczynski M, Wilczynska O. Severe acute bilateral alcohol-induced toxic optic neuropathy-case report. *Klin Oczna*. 2012; 114(3): 208-12.
- [38] Kerrison JB. Optic neuropathies caused by toxins and adverse drug reactions. *Ophthalmol Clin North Am* 2004; 17:481.
- [39] Dogulu C. Chapter 7 (Section II): Hereditary Optic Neuropathy. In Neuro-ophthalmology Handbook. 1st ed. Ed. O'Dwyer PA, Kansu T, Torun T. Güneş Medicine Publishing;2008: 89-94 (Turkish).
- [40] Newman NJ. Hereditary Optic Neuropathies: from the mitochondria to the optic nerve. *Am J Ophthalmol*. 2005; 140(3): 517-523.
- [41] Votruba M, Fitzke FW, Holder CE, Carter A, Bhattacharya SS, Moore AT. Clinical features in affected individuals from 21 pedigrees with dominant optic atrophy. *Arch Ophthalmol*. 1998; 116(3): 353-358.
- [42] Votruba M, Thiselton D, Bhattacharya SS. Optic disc morphology of patients with OPA1 autosomal dominant optic atrophy. *Br J Ophthalmol* 2003; 87:48.
- [43] Alexander C, Votruba M, Pesch UE, et al. OPA1, encoding a dynamin-related GTPase, is mutated in autosomal dominant optic atrophy linked to chromosome 3q28. *Nat Genet* 2000; 26:211.
- [44] Kjer B, Eiberg H, Kjer P, Rosenberg T. Dominant optic atrophy mapped to chromosome 3q region. II. Clinical and epidemiological aspects. *Acta Ophthalmol Scand*. 1996; 74(1): 3-7
- [45] Howell N. LHON and other optic nerve atrophies: the mitochondrial connection. *Dev Ophthalmol*. 2003: 37:94.
- [46] Smith JL, Hoyt WF, Susac JO. Ocular fundus in acute Leber optic neuropathy. *Arch Ophthalmol* 1973; 90:349.

- [47] Kermode AG, Moseley IF, Kendall BE, et al. Magnetic resonance imaging in Leber's optic neuropathy. *J Neurol Neurosurg Psychiatry* 1989; 52:671.
- [48] Lamirel C, Cassereau J, Cochereau I, et al. Papilloedema and MRI enhancement of the prechiasmal optic nerve at the acute stage of Leber hereditary optic neuropathy. *J Neurol Neurosurg Psychiatry* 2010; 81:578.
- [49] Carelli V, La Morgia C, Sadun AA. Mitochondrial dysfunction in optic neuropathies: animal models and therapeutic options. *Curr Opin Neurol*. 2013; 26(1): 52-58.
- [50] DiMauro S, Mancuso M. Mitochondrial diseases: therapeutic approaches. *Biosci Rep*. 2007; 27:125-3751-Golnik KC. Infectious optic neuropathy. *Semin Ophthalmol* 2002; 17:11.
- [51] Ginestal RC, Plaza JF, Callejo JM, et al. Bilateral optic neuritis and Guillain-Barré syndrome following an acute *Mycoplasma pneumoniae* infection. *J Neurol* 2004; 251:767.
- [52] Pfausler B, Engelhardt K, Kampfl A, et al. Post-infectious central and peripheral nervous system diseases complicating *Mycoplasma pneumoniae* infection. Report of three cases and review of the literature. *Eur J Neurol* 2002; 9:93.
- [53] Venkatesh P, Garg SP, Verma L, et al. Combined optic neuropathy and central retinal artery occlusion in miliary tuberculosis. *Retina* 2001; 21:375.
- [54] Rex JH, Larsen RA, Dismukes WE, et al. Catastrophic visual loss due to *Cryptococcus neoformans* meningitis. *Medicine (Baltimore)* 1993; 72:207.
- [55] Fukushima A, Yasuoka M, Tsukahara M, Ueno H. A case of cat scratch disease neuroretinitis confirmed by polymerase chain reaction. *Jpn J Ophthalmol* 2003; 47:405.
- [56] Gilden DH, Mahalingam R, Cohrs RJ, Tyler KL. Herpesvirus infections of the nervous system. *Nat Clin Pract Neurol* 2007; 3:82.
- [57] Küçükerdönmez C, Akova YA, Yilmaz G. Ocular toxoplasmosis presenting as neuroretinitis: report of two cases. *Ocul Immunol Inflamm* 2002 10:229.
- [58] Benz MS, Glaser JS, Davis JL. Progressive outer retinal necrosis in immunocompetent patients treated initially for optic neuropathy with systemic corticosteroids. *Am J Ophthalmol* 2003; 135:551.
- [59] Ray S, Gragoudas E. Neuroretinitis. *Int Ophthalmol Clin* 2001: 41:83.
- [60] Smith GT, Goldmeier D, Migdal C. Neurosyphilis with optic neuritis: an update. *Postgrad Med J* 2006; 82:36.
- [61] Sibony P, Halperin J, Coyle PK, Patel K. Reactive Lyme serology in optic neuritis. *J Neuroophthalmol* 2005; 25:71.
- [62] Tunc M. Chapter 5 (Section II): Inflammatory Optic Neuropathy. In *Neuro-ophthalmology Handbooks*. 1st ed. Ed. O'Dwyer PA, Kansu T, Torun T. Güneş Medicine Publishing;2008: 73-80 (Turkish)

- [63] Jabs DA, Miller NR, Newman SA, et al. Optic neuropathy in systemic lupus erythematosus. *Arch Ophthalmol* 1986; 104:564.
- [64] Kansu T, Kirkali P, Kansu E, Zileli T. Optic neuropathy in Behçet's disease. *J Clin Neuroophthalmol* 1989; 9:277.
- [65] Wall M, George D. Idiopathic intracranial hypertension. A prospective study of 50 patients. *Brain* 1991; 114 (Pt 1A): 155.

