

# We are IntechOpen, the world's leading publisher of Open Access books Built by scientists, for scientists

6,900

Open access books available

185,000

International authors and editors

200M

Downloads

Our authors are among the

154

Countries delivered to

TOP 1%

most cited scientists

12.2%

Contributors from top 500 universities



WEB OF SCIENCE™

Selection of our books indexed in the Book Citation Index  
in Web of Science™ Core Collection (BKCI)

Interested in publishing with us?  
Contact [book.department@intechopen.com](mailto:book.department@intechopen.com)

Numbers displayed above are based on latest data collected.  
For more information visit [www.intechopen.com](http://www.intechopen.com)



# Trophoblastic Hyperthyroidism and Its Perioperative Concerns

Madhuri S. Kurdi

Additional information is available at the end of the chapter

<http://dx.doi.org/10.5772/57523>

## 1. Introduction

*A moderately built 25-year-old female with a 24-week pregnancy and per-vaginal bleeding is brought to the operation theatre in the wee hours of the morning for suction evacuation. Her medical and surgical histories are unremarkable. She is highly irritable and moderately pale. She has a pulse rate of 156 beats per minute, blood pressure of 110/80 mm of Hg, respiratory rate of 32 breaths per minute and mild pedal oedema. Her haemoglobin level is 8 gm/dl. Her thyroid function tests are markedly deranged showing severe biochemical hyperthyroidism (Serum  $T_3$  – 6.46 mmol/L,  $T_4$  – 470 nmol/L and TSH – 0.03  $\mu$  IU/ml). The serum  $\beta$  hCG levels are markedly raised. An ultra-sonogram shows signs of a complete molar pregnancy.*

This is a typical presentation of gestational trophoblastic disease with trophoblastic hyperthyroidism.

Gestational trophoblastic disease includes a group of pregnancy-related tumours called trophoblastic tumours. These include hydatidiform mole and choriocarcinoma. Hyperthyroidism is a rare complication of gestational trophoblastic disease. It is called trophoblastic hyperthyroidism.

## 2. Gestational trophoblastic disease

The abnormal proliferation of trophoblastic tissue in the developing human placenta results in the condition known as Gestational Trophoblastic Neoplasia [1,2]. Gestational Trophoblastic Neoplasia lesions are histologically distinct malignant lesions that include hydatidiform mole, choriocarcinoma, placental site trophoblastic tumour and epithelioid trophoblastic tumour.

Gestational Trophoblastic Neoplasia often arises after molar pregnancy. It can also occur after any gestation including miscarriages and term pregnancies [2].

Gestational trophoblastic disease is a family of diseases that includes complete and partial molar pregnancy also known as hydatidiform mole, locally invasive or Disseminated choriocarcinoma and placental site trophoblastic tumour [3]. Placental site trophoblastic tumour, invasive mole and choriocarcinoma are termed Gestational Trophoblastic Tumours. They are malignant while hydatidiform mole is a benign form of Gestational Trophoblastic Disease [4].

### **2.1. Classification of gestational trophoblastic disease (FIGO) (International Federation of Gynaecology and Obstetrics) [5]**

Hydatidiform mole-

- complete
- partial

Gestational Trophoblastic Neoplasia-

- Invasive mole
- Choriocarcinoma
- Placental site trophoblastic tumor
- Epithelioid trophoblastic tumor

### **2.2. Hydatidiform mole**

It is an abnormal condition of the ovum where there are partly degenerative and partly hyperplastic changes in the young chorionic villi. These result in the formation of clusters of small cysts of varying sizes. Because of its superficial resemblance to hydatid cyst, it is named as hydatidiform mole and the pregnancy associated with it is known as molar pregnancy. It is best regarded as a benign neoplasia of the chorion with malignant potential [6].

Molar pregnancy is common in Oriental countries – Philippines, China, Indonesia, Japan and India as also in Africa and Central and Latin America [6]. The incidence of molar pregnancy has been reported to range between 0.5 and 2 to 2.5 per one thousand pregnancies [7,8,9]. In some Asian countries, the incidence is as high as 1 in 82 pregnancies [1]. The highest incidence is in Philippines being 1 in 80 pregnancies and lowest in European countries, North America, Australia and New Zealand [6,10]. In the United States, hydatidiform moles are observed in approximately 1 in 600 therapeutic abortions and 1 in 1000-2000 pregnancies [2,11]. The incidence in India is about 1 in 400 pregnancies [12]. In Nepal, the incidence of gestational trophoblastic disease as per records from different hospitals is 5.1, 2.9, 2.8 and 4.1 per 1000 live births [13]. The incidence of hydatidiform mole in the Middle East is 1:60 to 1:500 [14].

Molar pregnancies develop as a result of abnormal fertilisation [6]. Risk factors for developing a molar pregnancy include advanced maternal age, teen age, inadequate nutrition, disturbed

maternal immune mechanisms, cytogenetic abnormality, environmental factors and a history of hydatidiform mole [1]. Although most molar pregnancies are sporadic, a familial syndrome of recurrent hydatidiform mole has been described and first reported in 1980, suggesting an autosomal recessive inheritance pattern [15,16].

#### *2.2.1. Pathology of hydatidiform mole [6]*

##### **Naked eye appearance. (fig 1)**

The mass in the uterus is made of multiple chains and clusters of cysts of varying sizes from a pin head to that of a large grape. The embryo and amniotic sac may or may not be seen. Red areas may be seen suggesting haemorrhage in the decidual space [6] (fig 1)



**Figure 1.** Gross appearance of hydatidiform mole

##### **Microscopic appearance**

The villus pattern is distinctly maintained. The vesicles are filled with interstitial fluid that is almost similar to ascitic or oedema fluid but rich in hCG. There are no blood vessels.

#### *2.2.2. Clinical features of hydatidiform mole*

The traditional presenting features include vaginal bleeding, excessive uterine size, hyperemesis gravidarum, theca lutein cysts and preeclampsia in early pregnancy [17,18]. The clinical presentation has significantly changed in the past years [19]. Modern facilities like ultrasonography and serum alpha hCG help early diagnosis even before any signs and symptoms appear [20].

**Symptoms:** [6]

1. Vaginal bleeding – It may be mixed with fluid from the ruptured cysts giving the appearance of ‘white currant in red currant juice’. This is the most common symptom, being present in about 70-90% cases. [19]
2. Lower abdominal pain-This is due to infection, uterine perforation or uterine contractions.
3. Constitutional symptoms – Patient appears sick, has excessive vomiting, breathlessness, thyrotoxic features like tremors, palpitations, anxiety, weight loss and increased appetite.
4. Expulsion of grape-like vesicles per vaginum.

**Signs:** [6]

1. Signs of early pregnancy.
2. Patient looks very ill.
3. Prominent pallor out of proportion to blood loss.
4. Features of toxæmia (hypertension, oedema and proteinuria) are present in about 50% of cases. Rarely convulsions may occur.
5. Per abdomen –
  - a. The size of uterus is more than expected for the period of amenorrhoea.
  - b. The uterus feels firm and elastic(doughy) because of the absence of amniotic fluid sac.
  - c. Foetal parts are not felt; absence of foetal movements.
  - d. Absent foetal heart sounds.
6. Per vaginum-
  - a. Internal ballotment cannot be elicited.
  - b. Unilateral or bilateral enlarged palpable ovaries are seen in 25-50% of cases.
  - c. Vesicles are seen in vaginal discharge.

*2.2.3. Investigations and diagnosis*

1. Serial quantitative estimation of hCG-The hallmark of diagnosing hydatidiform mole is a positive  $\beta$ -hCG urine assay pregnancy test [18]. High hCG titre in urine diluted up to 1 in 200 to 1 in 500 beyond 100 days of gestation is very suggestive [6]. A retrospective analysis of molar pregnancies reported that 75% of patients present with vaginal bleeding, while 54% presented with enlarged uterus for gestational dates and 100% had excessively elevated  $\beta$ -hCG levels [18]. Qualitative  $\beta$ -hCG urine assays may be misleading in molar pregnancy. There have been reports of false negative both, urine and serum  $\beta$ -hCG pregnancy tests in hydatidiform mole [18].

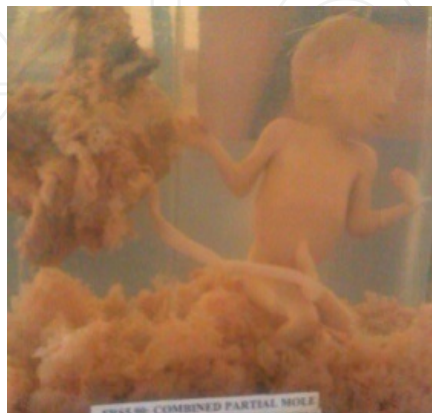*Christopher and Ladde reported a case of a molar pregnancy presenting with abdominal pain and vaginal spotting with multiple false negative urinary pregnancy tests. The laboratory qualitative urine  $\beta$ -hCG assays were negative. As she was being prepared for transport to the ultrasound suite, she discharged a large, fleshy vesicular mass followed by profuse vaginal bleeding. They attributed this to the fact that qualitative  $\beta$ -hCG assays like sandwich chromatography immunoassays may produce false negative results in a phenomenon known as the high dose hook effect [18].*

2. Ultrasonography-The characteristic 'snowstorm appearance' is seen (fig 3).

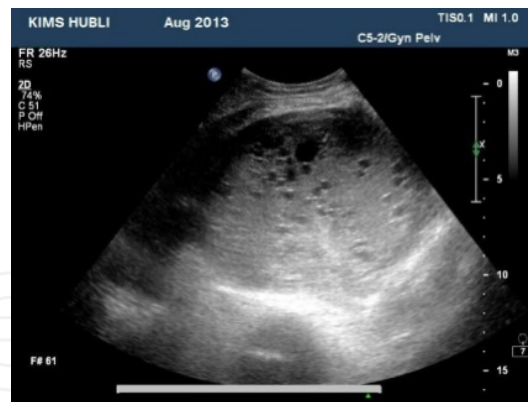#### 2.2.4. Types of hydatidiform mole – Molar pregnancies are categorised as complete or partial

Complete moles have diploid karyotype of solely paternal origin [18]. In a complete molar pregnancy, the placenta becomes oedematous secondary to grossly enlarged hydropic chorionic villi and in most cases the foetus, cord and amniotic membranes are absent [1]. The traditional presenting features like vaginal bleeding, excessive uterine size, hyperemesis gravidarum, hyperthyroidism, theca lutein cysts and preeclampsia in early pregnancy are present [17,18]. Patients with a complete molar pregnancy have excessively high levels of serum and urinary hCG resulting from trophoblastic proliferation [1]. hCG serves as a marker for the tumour. The diagnosis is made by ultrasonogram demonstrating a snowstorm appearance without a foetus (fig 3) [7].

Partial moles have triploid karyotype of both maternal and paternal origin. Partial molar pregnancies account for 10% of all hydatidiform moles [1]. In partial mole, there will be some identifiable foetal tissue (fig 2). Sanchez-Ferrer ML et al have described an extremely rare case of a partial hydatidiform mole with a normal fetus [21]. The classic clinical presentation described for complete mole is rare in partial mole and significant hCG level elevation is less common [15]. Ultrasonography will not show the classical snow-storm appearance (fig 3). Most often the diagnosis is made upon histological review of curettage specimens [15].



**Figure 2.** Specimen of partial mole.



**Figure 3.** Transabdominal ultrasonogram showing 'snowstorm' appearance of a complete mole in the uterus.

## 2.3. Complications of molar pregnancy

### 2.3.1. Immediate

#### Surgical [6]

1. Haemorrhage and shock – due to separation of vesicles or uterine perforation.
2. Sepsis – due to surgery and presence of degenerated vesicles and blood.
3. Uterine perforation – due to perforation by the mole or during surgery.

#### Medical

Eighty percent of cases of molar pregnancy are uncomplicated and twenty percent are associated with an extensive list of medical complications like hyperthyroidism, severe anaemia, haemorrhage, trophoblastic embolisation and pregnancy induced hypertension, some of which may be of a critical nature [1,12,22].

### 2.3.2. Late

18-28% of patients with complete mole and 2-4% of patients with partial mole can develop persistent neoplasia or post molar gestational trophoblastic neoplasia [15]. The development of choriocarcinoma following hydatidiform mole ranges from 2-10% [6].

## 2.4. Management of hydatidiform mole [6]

The principles are:

1. To give adequate supportive therapy to restore blood volume.
2. To evacuate the uterus as soon as diagnosis is made. Complete evacuation of the uterus is made by suction evacuation [1,12]. Hysterotomy is done in case of very low general condition of the patient or profuse vaginal bleeding. Hysterectomy is done in patients having three or more children or if patient's age is more than 35 years.

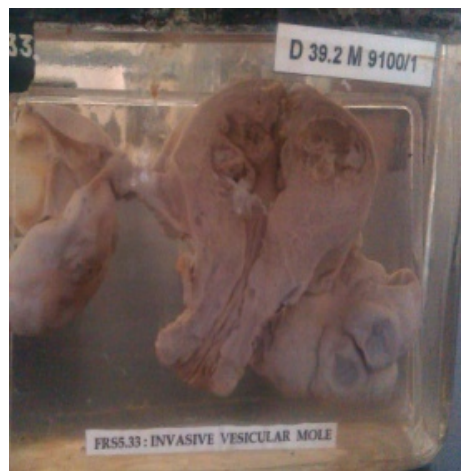

**Suction dilatation and evacuation**-Suction dilatation and evacuation is a safe, rapid and effective method for evacuating hydatidiform moles [23,24]. If the patient has already started to expel the mole, the process is hastened by starting an oxytocin drip of 10-20units. The products can then be rapidly evacuated either digitally or with the help of suction cannula [25]. If the process of expulsion of mole has not started, then a definitive plan for uterine evacuation is made. The cervix is dilated gently and slowly [19].If necessary,prostaglandin gels can be introduced into the cervix to promote cervical softening and dilatation [25].Light and careful curettage should be performed following the suction procedure to ensure complete evacuation of the uterine content [19].The use of a bedside ultrasound unit at the time of the procedure will ensure complete evacuation of uterine contents [23].

3. Prophylactic chemotherapy with oral methotrexate for 3 courses of 5 days each.

## 2.5. Invasive mole

The villus structure is maintained as in hydatidiform mole but the uterine wall may be perforated in multiple areas (fig 4). Distant metastasis can occur via blood stream to lungs, vagina or brain. The treatment is hysterectomy followed by cytotoxic therapy [6].



**Figure 4.** Specimen of an invasive mole

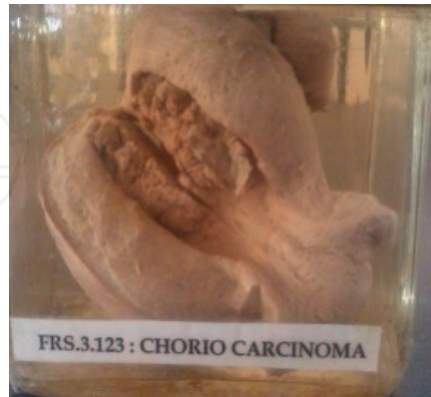## 2.6. Choriocarcinoma

The incidence is 1 in 5000 pregnancies in Oriental countries and 1 in 50,000 in Europe and North America. 50% of cases occur after molar pregnancies. The villous pattern of hydatidiform mole is lost here and invasion of uterine wall accompanied by necrosis and haemorrhage is seen.(fig 5) Distant metastases can occur to lungs(70%), anterior vaginal wall(50%), brain(10%) and others [6]. Treatment is done with- [2,6]

1. Cytotoxic drugs.
2. Hysterectomy and cytotoxic drugs.



3. Adjuvant procedures like brain irradiation for cerebral metastasis, craniotomy in cerebral metastasis, hepatic resection to control bleeding from hepatic metastasis and vaginal packing for bleeding from vagina.



**Figure 5.** Specimen of choriocarcinoma of the uterus

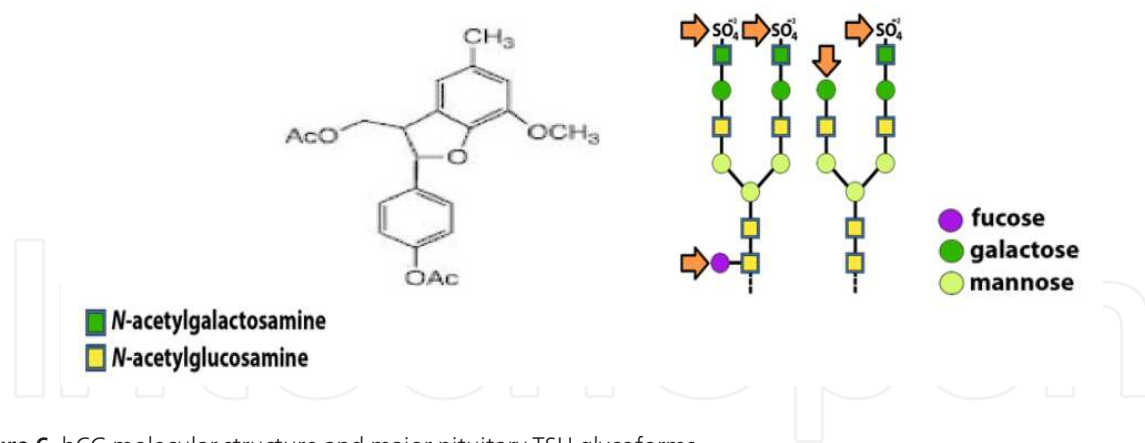
## 2.7. Cytotoxic drugs in Gestational Trophoblastic Neoplasias [2]

Gestational Trophoblastic Neoplasias are highly responsive to chemotherapy. Early stage Gestational Trophoblastic Neoplasia is often cured with single agent chemotherapy. Advanced stage requires multiple agent combination regimens. EMACO (Etoposide, Methotrexate, Actinomycin-D, Cyclophosphamide and Vincristine) is the most commonly used regimen for stage IV tumours. MAC regimen with Methotrexate, Actinomycin-D and Cyclophosphamide is also used.

## 3. Relationship between hCG and thyroid

hCG is a placental glycoprotein. Its levels are high in the first trimester of pregnancy. It shares some structural similarity with TSH [26,27] (fig6). It is composed of alpha and beta subunits, non covalently linked. The alpha subunit is identical to that found in TSH. It consists of a 92 aminoacid chain containing two nitrogen linked oligosaccharide side chains [3]. The beta subunit of hCG consists of 145 aminoacid residues with two N linked and four O linked oligosaccharides. The beta subunit of TSH is composed of 112 residues and one N linked oligosaccharide [28]. TSH and hCG thus share a molecular mimicry and have similar effects on the thyroid [29]. Nonetheless, hCG receptors share 45% homology with the TSH receptors [3].

Several data indicate that hCG is a weak human thyrotropin [30]. In 1967, Burger reported that impure, commercial hCG had thyroid stimulating activity in a mouse bioassay [31]. Bioassays in mice, rats, chicks show that hCG stimulates iodine uptake, activates adenylate cyclase and increases DNA synthesis in cultured rat thyroid cells [32]. It also activates the TSH receptor. But the relative potency of hCG for the TSH receptor is 4000 times less than TSH [3]. It has

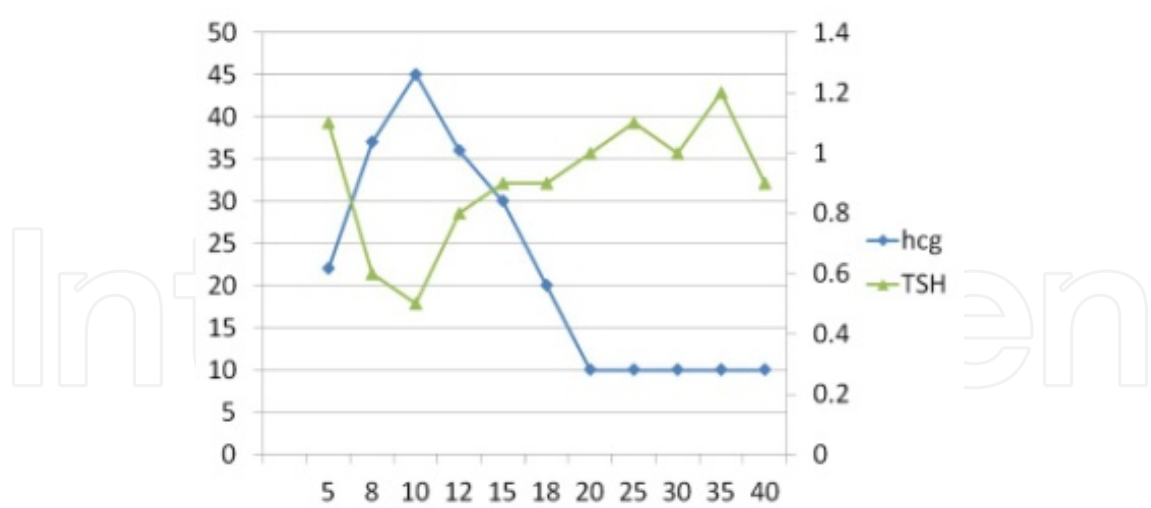


**Figure 6.** hCG molecular structure and major pituitary TSH glycoforms

been calculated that hCG contains approximately  $1/4000^{\text{th}}$  of the thyrotropic activity of human TSH. In bioassays, hCG is only about  $1/10000^{\text{th}}$  as potent as human TSH during normal pregnancy [33]. High circulating levels of hCG with their TSH like activity in the first trimester of pregnancy may result in a slightly low TSH and an increase in free  $T_4$  concentration. hCG may stimulate maternal  $T_4$  secretion [34]. It is estimated that an increment of hCG of  $10,000\text{UL}^{-1}$  results in an increase of free  $T_4$  of  $0.6\text{pmolL}^{-1}$  and a decrease in TSH of  $0.1\text{mUL}^{-1}$  [35]. Braunstein and Hershman reported that there was an inverse relationship between TSH and hCG at about 10-12 weeks of pregnancy, the time of peak hCG levels [36]. Harada showed an increase of free  $T_4$  and free  $T_3$  associated with the peak hCG [37,38]. Serum TSH levels particularly between 7 and 12 weeks of gestation fall to a nadir and present a mirror image with peak hCG values. (fig 7) The lower normal TSH limits in first trimester is approximately  $0.03\text{-}0.08\text{mIU}^{-1}$  secondary to the thyrotropic activity of hCG [7].

Highly purified standard hCG has only trivial TSH like activity [39,40]. Certain fractions of hCG have greater TSH like activity than others [35]. The thyrotropic activity of hCG is influenced by the number and structure of its oligosaccharide side chains. Deglycosylation and partial desialation (removal of sialic acid) of  $\beta$  subunit of hCG enhances its thyrotropic potency in rat thyroid cells [41]. Nevertheless, the circulating hCG patterns are different at various stages of gestation [42]. HCG with reduced sialic acid content is increased in pregnant patients with hyperthyroidism [40]. Partially desialated hCG has the greatest TSH like activity and is often increased in molar pregnancy [35].

The development of hyperthyroidism due to hCG is largely influenced by the level of hCG. Clinically measurable changes in thyroid hormone concentration are only likely if hCG levels are around  $50,000\text{-}70,000\text{mIU}^{-1}$  or more [35]. Extremely high levels are required for the development of clinical hyperthyroidism. Case studies have indicated that, serum levels of hCG of  $>100,000\text{mIU}^{-1}$  are usually needed to produce clinical evidence of thyrotoxicosis [3]. Such high levels are seen in conditions like hyperplacental, hyperemesis gravidarum, gestational trophoblastic disease, multiple pregnancy and hyper reaction-luteinalis [7]. These conditions are associated with the clinical entity known as 'transient non autoimmune hyperthyroidism in early pregnancy' wherein hCG is the main mediator of hyperthyroidism [7].



**Figure 7.** The pattern of serum TSH and HCG changes are shown as a function of gestation age. Between 8 and 14 weeks gestation, changes in serum hCG and TSH are mirror images of each other, and there is a significant negative correlation between the individual TSH (nadir) and peak hCG levels.

**4. Epidemiology of hyperthyroidism in gestational trophoblastic disease**

Concomitant biochemical thyroid disease in patients with gestational trophoblastic disease is relatively common [3]. Although hyperthyroidism has been reported more frequently in women with a hydatidiform mole than in those with choriocarcinoma, there have been many reports of hyperthyroidism in women with choriocarcinoma as well as a few men with testicular tumours [28].

The prevalence of hyperthyroidism in patients with hydatidiform mole and choriocarcinoma has been reported to be as high as 25-64% [28]. Hyperthyroidism develops in 5-10% cases of molar pregnancy and an incidence up to 30% is reported in India [43]. The prevalence of hyperthyroidism during complete molar pregnancy is as high as 7% [43]. In a study, 30 of 52 patients with gestational trophoblastic neoplasia were found to be thyrotoxic. The New England Trophoblastic Disease Centre estimated that 20% of women with complete moles have hyperthyroidism [28]. But in the same centre, between 1988 and 1993, none of 74 patients with complete mole demonstrated evidence of hyperthyroidism [15]. Biochemical hyperthyroidism has been reported in a patient with a dichorionic pregnancy with one viable foetus and a hydatidiform mole [44].

Clinical hyperthyroidism is found in approximately 5% of women with a hydatidiform mole [26]. Clinical thyrotoxicosis is rare in molar pregnancy [45]. Clinical thyrotoxicosis is even more rare in patients with partial mole. The first such case was reported in 2008 [46]. Rarely the thyroid stimulation can have potentially life threatening consequences [3]. The prevalence of thyrotoxicosis in patients with trophoblastic tumors was reported to be close to 50% in some older studies [7,47]. But nowadays with the ability of early detection of the disease, the incidence is much lower.

## 5. Aetiology of hyperthyroidism in molar pregnancy

Historically, the first association between hyperthyroidism and a product of the trophoblast was noted in patients with trophoblastic tumours [28]. In 1971, Hirshman and Higgins reported two case of severe hyperthyroidism in patients with hydatidiform mole and demonstrated for the first time thyrotropic activity in molar tissue [48]. This stimulator differed biologically and immunologically from the other three human stimulators i.e. pituitary thyrotropin, chorionic thyrotropin found in normal pregnancies and the LATS in Grave's disease [7]. They speculated that an excessive amount of the extracted molar stimulator was responsible for the hyperthyroidism in both people [7]. Hyperthyroidism in patients with molar pregnancy is thought to occur as a manifestation of excessive levels of circulating hCG which has a weak intrinsic thyroid stimulating activity, or from a thyrotropin like substance released from the mole [1,33,43].

Extremely high levels of hCG are typically required for the development of clinical hyperthyroidism as the relative potency of hCG for the TSH receptor is relatively low [3]. HCG levels always exceed 300 IUml<sup>-1</sup> in patients with hyperthyroidism caused by trophoblastic disease [41]. The hCG levels are particularly high at 10-14 weeks of gestation in trophoblastic disease [44]. In gestational trophoblastic disease, high levels of hCG cause activation of the thyrotropin receptor and stimulate supraphysiological secretion of thyroid hormone [44]. The level of thyroid stimulation is directly proportional to the hCG concentration [3]. Lemon et al studying thyroid function in trophoblastic diseases reported a high correlation between levels of hCG and TSH measured by radio-immunoassay secondary to cross-sensitivity of TSH and hCG with the antibody they used [49]. None of their patients were clinically hyperthyroid and there was poor correlation between hCG and T3 or T4 levels although high levels of thyroid hormone occurred only at hCG levels greater than 100,000mIU/ml. Basic isoforms of hCG with high bioactivity-immunoactivity ratio may be responsible for hyperthyroidism in some patients with trophoblastic disease [28]. Nevertheless, the hCG molecule from women with trophoblastic diseases has been found to display enhanced thyrotropic activity [50].

Some studies have however, revealed no significant relationship between elevation of serum hCG and abnormally high values of free thyroxine index in patient with trophoblastic tumors. These studies suggest that a substance distinct from hCG and elaborated by the gestational trophoblastic tissue is responsible for thyrotoxicosis observed in patients with trophoblastic tumours. The molar thyrotropin existing in the serum of patients with a hydatidiform mole differs from hCG by its larger molecular size and the duration of action, which is longer [33,43,51].

## 6. Spectrum of biochemical abnormalities in trophoblastic hyperthyroidism

1. The level of thyroid stimulation is directly proportional to hCG concentration and hence the severity of clinical hyperthyroidism reflects the hCG level in gestational trophoblas-

tic disease. In patients with molar hyperthyroidism, serum hCG levels usually exceed 300U/ml and always exceed 100 U/ml. Patients with clinical evidence of thyrotoxicosis may have serum levels of hCG of >100,000 mIU/L. However, some patients with trophoblastic tumors with very high serum hCG levels do not manifest hyperthyroidism [3,28].

2. In patients with molar pregnancy, evidence for pronounced hypersecretion of  $T_4$  is present. Hence, elevated serum free  $T_4$  &  $T_3$  levels are found [47].
3. A pattern of high values of serum protein bound iodine(PBI) and serum tri-iodothyronine reaction( $T_3$ test)and relatively low values of serum cholesterol have been seen in most patients with hydatidiform mole [52].
4. Pronounced increase in urinary P/C ratio occurs in patients with molar pregnancy suggesting that they are hypermetabolic [47].
5. Dowling, Ingbar and Freinkel were the first to note the occurrence of striking abnormalities in several aspects of thyroid economy in patients with molar pregnancy. They found marked increases in serum PBI,  $PB^{131}I$ , butanol-extractable  $^{131}I$ , thyroidal  $^{131}I$  uptake and absolute iodine uptake(AIU) in the patients [53]
6. In some cases, even when serum free  $T_4$  and  $T_3$  concentrations were only slightly elevated, serum TSH concentrations were low and serum TSH responses to TRH were low [28].
7. Several patients of trophoblastic tumors demonstrated thyroid hyperfunction or marked increases in serum PBI but failed to display signs or symptoms of frank thyrotoxicosis [47].

## **7. Comparison of trophoblastic hyperthyroidism with other types of hyperthyroidism and with the thyroid economy of normal pregnancy [28,47]**

1. Patients with trophoblastic hyperthyroidism have higher serum  $T_4/T_3$  ratios than patients with Grave's hyperthyroidism.
2. Thyroid stimulating immunoglobulin is not detectable in trophoblastic hyperthyroidism unlike Grave's Disease.
3. Several of the changes in certain aspects of thyroid economy which occur in molar pregnancy resemble superficially those seen in normal pregnancy. These include the increase in thyroidal  $^{131}I$  uptake and serum  $PB^{131}I$ ; in patients with molar pregnancy, however, these indices tend to be more markedly increased. Values for serum PBI and  $T_4$  concentration in molar pregnancy are usually much greater than in normal pregnancy.
4. In patients with the usual varieties of hyperthyroidism, the absolute concentration of free  $T_4$  in serum is usually quite elevated as a result of increase in both: the total concentration of  $T_4$  in serum and the free proportion. In patients with molar pregnancy, a smaller increase in concentration of free  $T_4$  is generally seen since the proportion of free  $T_4$  is subnormal.



5. Trophoblastic tumours secrete less oestrogen than normal placental tissue so that the increase in serum thyroxine-binding globulin (TBG) concentration is less in molar pregnancy than in normal pregnancy.

## 8. Some biochemical case profiles of trophoblastic hyperthyroidism

There is a spectrum of thyroid function abnormalities in gestational trophoblastic neoplasias and thyroid function in an individual patient is determined by the relative influence of the thyroid stimulator, nonthyroidal illnesses and the pregnancy [54].

1. In a study of the thyroid status of 27 African patients with gestational trophoblastic neoplasia, 15 patients were found to be biochemically hyperthyroid. Of the 15 patients, 9 were clinically thyrotoxic. It was found that when serum levels of hCG reached a level of about  $0.1 \times 10^6$  IU/L, 13 of 16 patients were biochemically hyperthyroid; at serum levels of  $0.3 \times 10^6$  IU/L of hCG, most patients were clinically thyrotoxic.  $T_4$  was invariably raised in these patients but the  $T_3:T_4$  ratios tended to be low ( $0.015 \pm 0.005$ );  $rT_3:T_3$  ratios were high and TSH levels were not raised [55].
2. In 7 patients with metastatic trophoblastic disease, there was laboratory evidence of increased thyroid function but clinical hyperthyroidism was either not present or minimal and thyroid gland size was normal. There was uniform elevation of 24 hour radioiodine uptake, serum PBI, BMR and the serum cholesterol was depressed [56].
3. In a study on 47 patients with hydatidiform mole, only 1 was found to be clinically hyperthyroid, although 10 had serum total thyroxine values exceeding those found in normal pregnancy (8 to 17  $\mu$  gm/dl). Among 34 patients in whom free thyroxine indices could be calculated, 18 had elevated values for the free thyroxine index ( $>10.6$ ), and 9 had elevated values for total thyroxine and free thyroxine index [57].
4. An  $^{131}\text{I}$  -tracer test performed in a patient with molar pregnancy indicated a very high thyroidal  $^{131}\text{I}$  uptake, conversion ratio and thyroidal  $^{131}\text{I}$  secretion rate [58].
5. Studies on 11 patients were done before and after removal of a molar pregnancy. Before evacuation of the mole, all patients demonstrated moderately to greatly elevated values for thyroidal  $^{131}\text{I}$  uptake, absolute iodine uptake and serum protein bound  $^{131}\text{I}$ . Values for serum PBI and serum thyroxine ( $T_4$ ) concentration were consistently increased averaging more than twice found in normal pregnancy. The maximum binding capacity of the  $T_4$ -binding globulin (TBG) was variably affected and ranged between the values found in normal controls and those found in the normal pregnancy. Values for the absolute of free  $T_4$  in the serum were only moderately elevated since the proportion of free  $T_4$  was moderately low, although not as low as in normal pregnancy [47].



## 9. Clinical presentation of hyperthyroidism in gestational trophoblastic disease

Hyperthyroidism has been reported as a complication of complete mole and persistent trophoblastic disease, both metastatic and non metastatic [41]. Trophoblastic hyperthyroidism has a widely divergent clinical pattern. Clinical hyperthyroidism is usually seen in patients with extremely high levels of hCG [30]. The clinical scenario may vary from absence of symptoms to thyroid storm [41,59]. Hyperthyroidism presents clinically as a physiological state dominated by an increased metabolic rate. Myocardial contractility, heart rate, stroke volume and ventricular size increase. Peripheral vascular resistance decreases in skin and muscle. The typical clinical findings include fatigue, weight loss, nervousness, excessive sweating, heat intolerance, hyperactivity, tremor, weakness, hyperdynamic precordium, diarrhoea, increased appetite, incapacitation [27], muscle weakness, tachycardia, minimal or no enlargement of thyroid gland. Ophthalmopathy is not observed in this condition [41]. Cardiomyopathy is seen. Reflexes become hyper-reactive. [27].

Mild to moderate hyperthyroidism may be difficult to diagnose clinically during pregnancy since normal parturients may experience symptoms such as heat intolerance, tachycardia, emotional instability and vomiting. A resting tachycardia not slowed by the Valsalva manoeuvre is a strong indication of hyperthyroidism [60]. Several patients develop supraventricular tachycardia and pulmonary oedema. The nausea, vomiting and toxæmia of pregnancy that occur commonly in molar gestation may obscure the features of hyperthyroidism [28].

The development of biochemical and clinical thyrotoxicosis in patients with choriocarcinoma depends upon the duration of the choriocarcinoma and the level of hCG [61]. In choriocarcinoma, the symptoms of metastasis to pelvis, lung, liver and brain may dominate the clinical picture. There may be laboratory evidence of increased thyroid function without clinically overt hyperthyroidism just as in hydatidiform mole [28].

During emergency surgery, the cardiovascular clinical manifestations of hyperthyroidism like tachycardia can often be missed because they may be attributed to hypovolaemia [59].

## 10. Management of trophoblastic hyperthyroidism

Surgical removal of the hydatidiform mole in a hyperthyroid patient rapidly cures the hyperthyroidism and should be performed as soon as possible [43,59]. Therapy of hyperthyroidism is not indicated in the vast majority of cases, since evacuation of the mole or chemotherapy in the management of choriocarcinoma, removing high levels of hCG, cures the hyperthyroidism. In those cases of severe symptoms, Lugol's solution, intravenous iodine and  $\beta$  blocking agents are indicated [7]. Therapy with potassium iodide given orally or sodium iodide given intravenously (1 gm q8 hourly) will rapidly reduce serum free T4 and T3 levels. Propranolol and other beta-adrenergic antagonist drugs are helpful to control tachycardia and

other symptoms of sympathetic activation. Supportive measures such as fluid and electrolyte replacement should be done as needed [28].

When hyperthyroidism occurs in the context of choriocarcinoma, case reports have demonstrated that the biomarkers of choriocarcinoma and thyroid function parallel the regression and subsequent relapse of the tumor [3]. Several women with metastatic choriocarcinoma and hyperthyroidism have achieved complete remission with chemotherapy. In the thyrotoxic patient with choriocarcinoma, the hyperthyroidism should be treated by any of the usual medical therapies [28]. The hyperthyroidism status secondary to molar disease rapidly resolves after evacuation while that secondary to choriocarcinoma takes a longer time to resolve [41].

*Moskovitz JB and Bond MC reported the successful management of a case of thyroid storm in a 17 year old patient. She presented to a community hospital's emergency department with history of palpitations and tachycardia since one week. Beta blockers and calcium channel blockers were administered. The tachycardia partially responded. She was then referred to a tertiary centre for evaluation. There the diagnosis of molar pregnancy was made using ultrasonogram and thyroid storm was diagnosed. She was given intensive care support, treated with  $\beta$ -blockers and propylthiouracil. Surgical evacuation of molar pregnancy was done and her symptoms soon resolved [62].*

*Walkington et al reported a case of a 21 year old woman who presented 2 months after a right salphingectomy for a ruptured ectopic pregnancy. She was breathless at rest, agitated and had a resting tachycardia. Pelvis ultrasound and MRI showed a mass near right ovary. She was diagnosed with choriocarcinoma with no evidence of metastasis. Serum hCG was  $1.176 \times 10^6 \text{ IU L}^{-1}$ . Thyroid functions showed her to be hyperthyroid with  $\text{TSH} < 0.03 \text{ mIU L}^{-1}$ , free  $\text{T}_4 = 73 \text{ pmol L}^{-1}$  and free  $\text{T}_3 = 21.6 \text{ pmol L}^{-1}$ . She was commenced on carbimazole and propranolol. Her serum hCG and TFT measurements were as follows (table 1). Her TFTs normalised in parallel with the fall in serum hCG. She was slowly weaned off her anti-thyroid treatment and she became biochemically euthyroid at commencement of her third cycle of chemotherapy [3].*

Day	HCG (IU L <sup>-1</sup> )	TSH(mIU L <sup>-1</sup> )	FT <sub>4</sub> (pmol L <sup>-1</sup> )	Carbimazole
0	791711	<0.03	73	40mgOD
7	156420	<0.03	15.2	40mgOD
21	19986	0.15	16.1	20mgOD
42	333	0.83	12.2	Stop

Abbreviations: FT<sub>4</sub>=free T<sub>4</sub>; HCG=human chorionic gonadotrophin; OD=once daily; TFT=thyroid function tests; TSH=thyroid stimulating hormone

**Table 1.** Summary of serial HCG and TFT measurements

## 11. Perioperative management of trophoblastic hyperthyroidism

20% of cases of trophoblastic hyperthyroidism can develop severe perioperative complications like high output cardiac failure secondary to thyrotoxicosis, thyroid storm, embolisa-

tion of pulmonary arteries by trophoblastic materials, hypovolaemia, disseminated intravascular coagulation, pulmonary oedema secondary to severe anaemia and acute pulmonary distress secondary to any of these problems. They may require intensive care support [1]. Hence the perioperative management and optimisation of hyperthyroid state prior to surgical evacuation of the mole is very important [59]. The perioperative management of hyperthyroidism focuses on the control of sympathetic activity so that cardiovascular side-effects are not manifested [51].

### **11.1. Preoperative preparation**

Preoperative optimisation with anti-thyroid and chemotherapeutic drugs is imperative to reduce perioperative morbidity [59]. Every anaesthesiologist should be well aware of the critical nature of perioperative complications that can be associated with a molar pregnancy. A detailed pre-anaesthesia work up, preoperative optimisation of the patients' thyroid and volume status, planning and conducting anaesthesia carefully and being prepared for advanced perioperative management are a must [63].

Preoperative evaluation of these patients should be based on history, physical examination and laboratory testing [64]. The patient must be admitted to an intensive care unit preoperatively. Blood count, electrolytes, blood gases, thyroid, hepatic, renal functions,  $\beta$ -hCG and chest radiogram should be carefully evaluated [51]. Treatment has to be individualised. The patient can be prepared for surgery with oral propylthiouracil (50-100mg qid), propranolol (20mg tid), intravenous glucocorticoids and sodium iodide [27]. Some cases may require only beta blockers whereas others may require in addition antithyroid drugs. Some may not require any treatment if the hyperthyroidism is only biochemical and asymptomatic [41]. Dehydration and anaemia if present should be corrected [25].

The diagnosis of hyperthyroidism in molar pregnancy is often made in semi-urgent conditions. Hence rapid stabilisation of the disease before surgery becomes important [45]. If there is no time to make the patient pharmacologically euthyroid, intravenous administration of iodine and  $\beta$ -adrenergic receptor blockers for emergency treatment of hyperthyroidism may be advisable [65]. These drugs, however, may be hazardous in patients who have heart failure or pulmonary complications [64]. The role of plasmapheresis for the rapid hormonal control in the preoperative period has been described. The use of plasmapheresis for the first time in the treatment of hyperthyroidism is reported in the 1970s. Erbil et al reported the use of plasmapheresis in a patient with severe hyperthyroidism due to hydatidiform mole for the rapid control of hormonal levels [66]. A case of successful rapid preoperative preparation by 3-4 sittings of plasmapheresis of a patient with secondary hyperthyroidism due to molar pregnancy has been described [67]. A study conducted by Ozbey et al concluded that plasmapheresis is a treatment option to be considered only when anti-thyroid drugs are contraindicated [68].

### **11.2. Anaesthetic management**

Sedation, monitored anaesthesia care, TIVA, general anaesthesia and spinal anaesthesia are the various anaesthetic techniques that can be adopted for a case of evacuation of molar

pregnancy [1,22,25,63]. Beta blockers for attenuation of sympathetic activity, emergency drugs like lidocaine for ventricular arrhythmias, steroids and hypotensive agents like sodium nitroprusside should be kept ready [69]. For patients with thyrotoxicosis due to molar pregnancy, it is recommended that placement of invasive monitors like central venous pressure be considered before induction of anaesthesia [1].

General anaesthesia may be the preferred technique in hypotensive bleeding patients scheduled for emergency evacuation. Uterine relaxation caused by inhaled anaesthetics may however increase blood loss [69]. Hence inhaled anaesthetics with known tocolytic qualities such as halothane, enflurane and isoflurane should be used in lower concentrations [64]. A nitrous oxide, opioid, muscle relaxant technique may also be preferred [51,64]. The safe use of sevoflurane at 2.5 % concentrations has been reported by some authors without increasing the chances of bleeding due to uterine relaxation [51]. Drugs that minimally affect the cardiovascular system are the most rational choice in these patients [69]. Adequate premedication is important to decrease unnecessary catecholamine release [69]. The anaesthesiologist should avoid the administration of medications that stimulate the sympathetic nervous system and should achieve an adequate depth of anaesthesia prior to surgical stimulation [69]. Medications associated with tachycardia should be avoided e.g. atropine, ketamine.

In stable patients, spinal anaesthesia is preferable [69]. It can be used because

- a. It is probably safe in patients with thyrotoxicosis.
- b. It has favourable nontocolytic pharmacological properties.
- c. It has preferable effects on the pulmonary system.
- d. The sympathetic blockade associated with a regional technique may be desirable.
- e. It is associated with a decrease in heart rate and blood pressure during surgery.
- f. One can diagnose complications like thyroid storm at an earlier stage than when the patient is sedated or under GA by maintaining the patients consciousness [64,69].

Intravenous fluids and blood must be administered judiciously as these patients have a propensity to develop pulmonary oedema. Blood replacement may be required to treat bleeding. Diuretics may be given intermittently [51].

Successful use of total intravenous anaesthesia (TIVA) has been reported for evacuation of molar pregnancy with hyperthyroidism. E. Erturk et al reported the anaesthetic management of a 25 year old woman having a hydatidiform mole with hyperthyroidism using TIVA technique with propofol, remifentanyl and esmolol infusion for controlling sympathetic hyperactivity during surgery [26].

### 11.3. Postoperative care

Postoperatively, intensive care management may be indicated because most of the cardiopulmonary complications develop in the postoperative period [64]. Mechanical ventilatory support must be provided if necessary. Treatment of thyroid storm, if it occurs, includes



general supportive measures plus the administration of glucocorticoids, propylthiouracil, sodium iodide and propranolol [27].

Solak M and Akturk G reported the successful perioperative management of a case of trophoblastic hyperthyroidism. A 22 year old woman, in her third month of pregnancy, presented for emergency evacuation. She had a history of vaginal bleeding and signs of hyperthyroidism like tremor, palpitation, sweating and tachycardia for three weeks. Examination revealed an arterial blood pressure of 140/70 mm of Hg, a heart rate ranging from 110 to 130 beats per minute, a small thyroid nodule and signs of hydatidiform mole in sonography and computerised tomography. Studies of thyroid function were obtained: free triiodothyronine –  $8.50 \text{ pgml}^{-1}$  (normal range  $3.05\text{--}5.35 \text{ pgml}^{-1}$ ) and free thyroxine –  $5.56 \text{ ngdl}^{-1}$  (normal range  $0.71\text{--}1.85 \text{ ngdl}^{-1}$ ). Serum  $\beta\text{-hCG}$  was  $961.96 \text{ mIUml}^{-1}$  (normal range  $0\text{--}5 \text{ mIUml}^{-1}$ ). Serum thyroid stimulating hormone levels were within normal limits. The patient appeared apprehensive, pale and shivering. She was administered intramuscular diazepam 5 mg 45 minutes preoperatively. Arterial blood pressure came down to 110/70 mm of Hg and there was sinus tachycardia (130 beats per minute). Spinal anaesthesia with 4 ml of 0.5% bupivacaine was administered at  $\text{L}_{3-4}$  level. She lost 1000 – 1500 ml of blood intraoperatively and received approximately 100 ml of whole blood. She was haemodynamically stable throughout the surgery which lasted for 30 minutes. Serum free  $\text{T}_4$  values were 4.13 and  $1.25 \text{ ngml}^{-1}$  on the 7<sup>th</sup> and 14<sup>th</sup> post-operative days respectively. She became euthyroid few weeks after evacuation of the mole [64].

Puneet Khanna, Anil Kumar and Maya Dehnan reported the successful perioperative management of a 44 year old female with hydatidiform mole. She had a history of irregular menstrual cycles since three months. Preoperatively she appeared anxious, afebrile with a pulse rate of 116 per minute, blood pressure of 120/80 mm of Hg and a respiratory rate of 20 per minute. The height of uterus was 14 weeks on per abdominal examination. Haemoglobin was 13.1gms%. Thyroid function tests revealed  $\text{TSH}=0.03 \text{ IU/ml}$  ( $0.03\text{--}5$ ),  $\text{T}_3=221 \text{ IU/ml}$  ( $70\text{--}200$ ) and  $\text{T}_4=14 \text{ IU/ml}$  ( $4.5\text{--}12.5$ ). Ultra-sonogram of the abdomen showed signs of an invasive hydatidiform mole.  $\beta\text{-hCG}$  levels were raised to  $8,35,300 \text{ mIUl}^{-1}$ . She was put on tab. neomercazole 15 mg TDS, tab. propranolol 20 mg BD, Lugol's iodine 4 drops TDS and inj. dexamethasone 2mg 6<sup>th</sup> hourly. She was also started on chemotherapy with methotrexate on alternate days and three cycles were given. Her  $\beta\text{-hCG}$  levels and thyroid functions were closely monitored. She was posted for total abdominal hysterectomy and bilateral salphingo-oophorectomy but was postponed due to persistent tachycardia reflecting an uncontrolled hyperthyroid state. The dose and frequency of tab. propranolol was increased to 40mg 6<sup>th</sup> hourly. After three weeks her hyperthyroid state was partly optimised ( $\text{T}_4=9.94 \text{ IU/ml}$  and  $\text{T}_3=0.014 \text{ IU/ml}$ ) and she was accepted for the planned procedure. Tab. diazepam 5mg was given on the night before and on the day of surgery. Patient was given combined spinal epidural block in  $\text{L}_{3-4}$  space. Intravenous sedation was given with midazolam and fentanyl. Intravenous dexamethasone was also given. Tabs. neomercazole, propranolol, amlodipine and dexamethasone were continued post-operatively and Lugol's iodine was stopped. Epidural analgesia with morphine was provided postoperatively and on 3<sup>rd</sup> post-operative day thyroid function test started showing improvement. On the 10<sup>th</sup> post-operative day, both  $\beta\text{-hCG}$  levels and thyroid function tests normalised [59].

Laurent V and co-authors reported a case of successful perioperative management of a Senegalese patient with hydatidiform mole. The patient had serum hCG levels of 900,000 IU. She was clinically hyperthyroid with raised  $\text{T}_4$  and  $\text{T}_3$  levels but a very low TSH concentration. She was given

*propranolol and carbimazole for 2 days. After that suction curettage was performed under general anaesthesia. Propranolol was again administered 6 hours after surgery. Thyroid function tests returned to normal levels two weeks after mole removal and serum hCG concentrations closely paralleled those of free thyroxine [45].*

## **12. Complications of hyperthyroidism in molar pregnancy**

The two most serious maternal complications of untreated hyperthyroidism are heart failure, being more common and thyroid storm [70]

### **12.1. Heart failure**

High output cardiac failure secondary to the thyrotoxicosis can occur in the perioperative period [43]. High output heart failure is caused by the myocardial effects of thyroxine. Pulmonary hypertension which is correlated with untreated or inadequately controlled hyperthyroidism can result in heart failure and pulmonary oedema [70]. Haemodynamic problems like tachycardia, hypertension, increase in total blood volume, decrease in systemic vascular resistance and increased cardiac output can result in cardiac decompensation and arrhythmias [69]. Symptoms of high output cardiac failure include breathlessness at rest or on exertion, exercise intolerance, fatigue, fluid retention and signs like tachycardia, tachypnea, raised jugular venous pressure, pulmonary rales, pleural effusion, peripheral oedema and warm peripheries due to peripheral vasodilatation. Cardiac ultra-sound may show preserved left ventricular ejection fraction [71].

Management of high output cardiac failure includes [72,73]

- Correction of the underlying hyperthyroidism.
- Carbimazole to alleviate thyrotoxicosis.
- Diuretics like frusemide to reverse the volume overload.
- Beta adrenoceptor blockers like esmolol and propranolol in particular to alleviate the symptoms of hyperthyroidism and to control the heart rate. A cautious trial of ultrashort acting beta blockers like esmolol can be done with invasive monitoring to detect the occurrence of depressed myocardial contractility.
- Amiodarone to treat atrial fibrillation if present.
- Digoxin to slow down ventricular response rate in atrial fibrillation.

### **12.2. Thyrotoxicosis and thyroid storm**

Thyroid storm occurs perioperatively in patients who have received either incomplete or no treatment for the pre-existing hyperthyroidism [43,74]. Thyroid storm can lead to high output cardiac failure [12]. Cases of thyroid storm occurring in the intraoperative period have been reported [75]. Severe thyrotoxicosis can occur even after surgical evacuation of the mole



[76]. Thyroid storm is a clinical diagnosis with manifestations like hyperpyrexia, severe dehydration, tachycardia, tachypnoea, diaphoresis, diarrhoea, atrial fibrillation, extreme anxiety, altered consciousness and haemodynamic instability leading to cardiovascular collapse [27,69]. Treatment of thyroid storm includes cooling blankets, intravenous hydration, glucose and electrolyte replacement, oxygen, glucocorticoids like dexamethasone or hydrocortisone intravenously, anti-thyroid drugs like oral/rectal propylthiouracil, methimazole, iodine in the form of intravenous sodium iodide or oral Lugol's iodine,  $\beta$  blockers like propranolol or esmolol, plasma exchange, dantrolene and B-complex multivitamins [27].

### 12.3. Mortality and pulmonary morbidity

Few cases of mortality after surgical evacuation in patients with molar pregnancy have been described [63,12] and some of them were hyperthyroid [63,77]. Respiratory complications including pulmonary oedema and acute respiratory distress syndrome (ARDS) were observed in these cases [63,77]. Few authors have also reported successful intensive treatment of ARDS occurring in hyperthyroid patients with molar pregnancy [74].

*Severe thyrotoxicosis has been reported after commencing treatment for gestational trophoblastic disease. A 53-year-old woman developed profound cardiovascular instability one day after surgical evacuation of a complete hydatidiform mole. She was not known to have pre-existing thyroid disease but investigations confirmed thyrotoxicosis [76]*

*Carrasco C and Cotoras J reported an interesting case of molar pregnancy with complications of hyperthyroidism. An 18 year old woman was admitted with a history of four days of cardiac failure with acute pulmonary oedema, high blood pressure, left ventricular dilatation and moderate to severe systolic dysfunction. Twenty four hours after admission she had a miscarriage expelling a mole. The diagnosis of hyperthyroidism caused by a mole and early preeclampsia was confirmed and the patient was managed with diuretics and dopamine. Symptoms abated. Thyroid function tests, cardiac function and size returned to normal values [78].*

*Hershman JM and Higgins HP reported a case of a 29 year old, 4 months pregnant Italian woman. She came complaining of shortness of breath, extreme fatigue, nervousness and heat intolerance. Since the past one week she had severe nausea and vomiting and vaginal spotting. On examination, she appeared anxious with soft, warm skin, fine hair and sweaty palms. The pulse rate was 110 per minute and regular, the blood pressure was 150/60 mm of Hg. The thyroid gland was slightly enlarged. Grade 2 ejection murmur was heard over the pulmonary area and a ventricular gallop was heard over the apex. The peripheral pulses were bounding. Ultrasonography showed signs of a molar pregnancy. The protein bound iodine (PBI) level was 22.7  $\mu\text{g}$ , serum thyroxine-iodine was 18  $\mu\text{g}/100\text{ml}$ , 24 hour uptake of radioactive iodine was 75% and serum free thyroxine was raised: 14.8  $\mu\text{g}/100\text{ml}$  (normal 3-5  $\mu\text{g} / 100 \text{ ml}$ ). Carbimazole 60mg per day was started. On the evening of the 7<sup>th</sup> day, supraventricular tachycardia suddenly developed and acute pulmonary oedema ensued shortly. She was treated with nasal oxygen, digoxin, ouabain and diuretics. A plasmapheresis was performed and packed red cells were transfused. The next day, there was a rapid tachycardia but no evidence of congestive heart failure. On the 8<sup>th</sup> day, a total abdominal hysterectomy was performed. Two further episodes of pulmonary oedema treated successfully with digoxin, occurred on the first and third post-operative days. She improved*

markedly. Tachycardia came back to normal; radio iodine uptake and PBI came back to normal by 14 days [48].

*An unusual case of a 13 year old Caucasian patient with a complete hydatidiform mole was reported wherein during anaesthesia induction, she presented symptoms compatible with a thyrotoxic crisis. The patient had complaints of amenorrhoea, abdominal pain and vaginal bleeding. She was tachypnoeic, tachycardic, hypertensive, pale and dehydrated. Her haemoglobin was 9.9gm/dl, serum TSH was 0.009mIU/ml (normal 0.35 – 5.5). HCG levels were higher than 400,000 IU/L. She underwent chest, abdominal and pelvic CT scanning with iodinated contrast and was scheduled to undergo a uterine curettage. General anaesthesia was administered via intravenous induction with fentanyl, propofol, endotracheal intubation and muscle relaxation with atracurium. After oro-tracheal intubation, she developed sinus tachycardia (170 beats per minute), hypertension (160/120 mm of Hg), hypercarbia (52 mm of Hg) and acute pulmonary oedema. She was diagnosed to be in a thyrotoxic crisis. She was treated with intravenous esmolol and sodium nitroprusside 75µg/kg/min respectively with satisfactory response and transferred to the ICU and managed there till she became haemodynamically stable. The use of iodinated substances can trigger thyrotoxic crisis (Jod-Basedow phenomenon) and in this case, the iodinated contrast used to perform scan preoperatively could have contributed to the development of thyrotoxic crisis [79].*

### 13. Conclusions

Trophoblastic tumors are associated with biochemical and clinical hyperthyroidism. Hence measurement of thyroid function in patients with gestational trophoblastic disease is important. Thyroid function normalises rapidly with treatment of the underlying gestational trophoblastic disease and consequent fall in hCG levels. Treatment of gestational trophoblastic disease includes surgical evacuation or chemotherapy. Hydatidiform mole with hyperthyroidism is a perioperative challenge. All patients should be stabilised with  $\beta$ -blockers and anti-thyroid medications prior to induction of anaesthesia for surgical evacuation. Vigilant monitoring and intensive care should be done perioperatively to watch for the occurrence of cardiopulmonary complications or thyroid storm.

### Acknowledgements

The author wishes to express her heartfelt thanks to Dr. Kaushic Theerth, Dr. Radhika Deva of the department of Anaesthesiology, Dr. Venkatesh K V of the department of Obstetrics and Gynaecology, Dr. Jagadish Sutagatti and Dr. Gurunandini Achar of the department of Radiodiagnosis, Professor and Head of the department of Pathology Dr. Sujata Giriyan, Karnataka Institute of Medical Sciences, Hubli for their generous help in literature search and technical aspects of writing this chapter.

## Author details

Madhuri S. Kurdi\*

Address all correspondence to: drmadhuri\_kurdi@yahoo.com

Department of Anaesthesiology and Critical Care, Karnataka Institute Of Medical Sciences (KIMS) Hubli, Karnataka, India

## References

- [1] Celeski D, Micho J, Walters L. Anesthetic implications of a partial molar pregnancy and associated complications. *AANAJ* 2001; 69:49-53.
- [2] Taymaa May, Goldstein DP, Berkowitz Ross S. Current chemotherapeutic management of patients with gestational trophoblastic neoplasia. *Chemotherapy Research and Practice* 2011. Available from <http://dx.doi.org/10.1155/2011/806256>.
- [3] Walkington L, Webster J, Hancock BW, Everard J, Coleman RE. Hyperthyroidism and human chorionic gonadotropin production in gestational trophoblastic disease. *British Journal of Cancer* 2011; 104:1665-9.
- [4] Newlands ES, Bower M, Fisher RA, Paradinas FJ. Management of placental site trophoblastic tumors. *J Reprod Med* 1998;43:53-59.
- [5] Cunningham Gary F, Leveno Kenneth J, Bloom Stoven L, Hauth John C, Rouse DJ, Spong CY. Gestational trophoblastic diseases. In: Alyssa Fried, Karen Davis, editors. *William's Obstetrics*. 23rd ed. USA:McGraw Hill Companies; 2010. p257-265.
- [6] Dutta DC. Haemorrhage in early pregnancy. In: Hiralal Konar, editor. *Textbook of Obstetrics*. 7th ed. Kolkata: New Central Book Agency; 2011 p158-199.
- [7] Goldman AM, Mestman JH. Transient non-autoimmune hyperthyroidism of early pregnancy. *Journal of Thyroid Research* 2011; Available from <http://dx.doi.org/10.4061/2011/142413>.
- [8] Atrash HK, Hogue CJ, Grimes DA. Epidemiology of hydatidiform mole during early gestation. *Am J Obstet Gynecol* 1986; 154:906-9.
- [9] Smith H O. Gestational trophoblastic disease epidemiology and trends. *Clin Obstet Gynecol* 2003;46: 541-56.
- [10] Heidarpour M, Khanahmadi M. Diagnostic value of P63 in differentiating normal gestation from molar pregnancy. *J Res Med Sci* 2013;462-6.
- [11] Steigrad SJ. Epidemiology of gestational trophoblastic diseases. *Best Pract Res Clin Obstet Gynaecol* 2003;17:837-847.

- [12] Bhatia S, Naithani Udit, Chhetty YK, Prasad Narendra, Jagtap RS, Agrawal I. Case report – Acute pulmonary edema after evacuation of molar pregnancy. *Anaesthesia, Pain and Intensive Care* 2011; 15(2):114-117. Available from <http://www.apicareonline.com>
- [13] Thepa K, Shreshtha M, Sharma S, Pandey S. Trend of complete hydatidiform mole. *J Nepal Med Assoc* 2010;49:10-3.
- [14] Padubidri V, AnandEl. Gestational trophoblastic diseases. In: *Textbook of Obstetrics*. 1st ed New Delhi: B. I. publications private limited; 2006. p88-96.
- [15] Garner EIO, Goldstein DP, Feltmate CM, Berkowitz RS. Gestational trophoblastic disease. *Clinical Obstetrics and Gynecology* 2007; 50(1):112-22.
- [16] Fisher RA, Hodges MD, Newlands ES. Familial recurrent hydatidiform mole: a review. *J Reprod Med* 2004; 49:595-601.
- [17] Soto-Wright Valena, Bernstein Marilyn, Goldstein Donald Peter, Berkowitz RS. The changing clinical presentation of complete molar pregnancy. *Obstet and Gynecol* 1995; 86(5):775-9.
- [18] Hunter Christopher L, Ladde Jay. Molar pregnancy with false negative  $\beta$ -hCG urine in the emergency department. *West J Emerg Med* 2011; 12(2):213-5.
- [19] Riadh B et al. Clinical analysis and management of gestational trophoblastic diseases. A 90 cases study. *Int Journal of Biomedical Sciences* 2009;5(4):321-325.
- [20] Koirala A, Khatiwada P, Giri A, Kandel P, Regmi M, Upreti D. The demographics of molar pregnancies in BPKIHS. *Kathmandu Univ Med J* 2011; 36(4): 298-300.
- [21] Sanchez-Ferrer ML et al. Partial mole with a diploid fetus: Case study and literature review. *Fetal Diagn Ther* 2009; 25(3):34-8.
- [22] Chantigan RC, Chantigan PD. Problems of early pregnancy. In: Chestnut DM, editor. *Obstetric Anaesthesia Principles and Practice*. 3rd ed. St Louis: Mosby; 2004, p241-54.
- [23] Hanna R K, Soper J T. The role of surgery and radiation therapy in the management of gestational trophoblastic disease. *Oncologist* 2010;15(6):593-600.
- [24] Soper J T. Role of surgery and radiation therapy in the management of gestational trophoblastic disease. *Best Pract Res Clin Obstet Gynaecol* 2003;17:943-957.
- [25] DaftaryShirish N, Chakravarti Sudip. Gestational trophoblastic disease. In: *Manual of Obstetrics* 2nd ed. New Delhi: Elsevier ; 2005. p 252-59.
- [26] Erturk E, Bostan H, Geze S, Saracoglu S, Erciyes N, Eroglu A. Total intravenous anaesthesia for evacuation of a hydatidiform mole and termination of pregnancy in a patient with thyrotoxicosis. *Int J Obstet Anesth* 2007; 16(4):363-6.
- [27] Wissler RN. Endocrine disorders. In: Chestnut DH. (ed) *Obstetric Anaesthesia Principles and Practice*. 3rd ed. Philadelphia Elsevier Mosby 2004:744-9.

- [28] Goodwin Thomas M, Hershman JM. Hyperthyroidism due to inappropriate production of human chorionic gonadotropin. *Clinical Obstetrics and Gynecology* 1997; 40(1):32-44.
- [29] Fisher PM, Hancock BW. Gestational trophoblastic diseases and their treatment. *Cancer Treat Rev* 1997; 23:1-16.
- [30] Rajan R. Thyroid and reproduction. In: *Postgraduate Reproductive Endocrinology* 4th ed. New Delhi: Jaypee Brothers Medical Publishers (P) ltd; 1997 p145-7.
- [31] Burger A. Studies on a thyroid stimulating factor in urinary chorionic gonadotropin preparations. *Acta Endocrinol (Copen)* 1967; 55: 587-599.
- [32] Hershman JM. "Physiological and pathological aspects of the effects of human chorionic gonadotropin on the thyroid". *Best practice and research: Clinical Endocrinology and Metabolism* 2004; 18(2):249-265.
- [33] Hershman JM. Role of human chorionic gonadotropin as a thyroid stimulator. *J Clin Endocrinol Metab* 1992; 74:258-9.
- [34] Zaman Maseehuz. Management of thyroid disorders in pregnancy. *Pakistan Journal of Radiology* 2008; 18(1):09-11.
- [35] Girling Joanna. Thyroid disease and pregnancy. In: Michael de Swiet, editor. *Medical Disorders in Obstetric Practice* 4th ed. UK: Blackwell Science Ltd; 2002 p415-38.
- [36] Braunstein GD, Hershman JM. Comparison of serum pituitary thyrotropin and chorionic gonadotropin concentrations throughout pregnancy. *J Clin Endocrinol Metab* 1976; 42:1123-26.
- [37] Hershman JM. The role of human chorionic gonadotropin as a thyroid stimulator in normal pregnancy. *J Clin Endocrinol Metab* 2008; 93(9):3305 –6.
- [38] Harada A, Hershman JM, Reed AW, Braunstein GD, Dignam WJ, Derzkoc, Friedman S, Jewelenicz R, Pekary AF. Comparison of thyroid stimulators and thyroid hormone concentrations in the sera of thyroid hormone concentrations in the sera of pregnant women. *J Clin Endocrinol Metab* 1979; 48:793-97.
- [39] Yamazaki K, Sato K, Shizumek Kanaji Y, Ito Y, Obara T, Nakagawa T, Koizumi T, Nishimura R. Potent thyrotropic activity of human chorionic gonadotropin variants in terms of I125 incorporation and de novo synthesized thyroid hormone release in human thyroid follicles. *J Clin Endocrinol Metab* 1995; 80:473.
- [40] Leon Sproff, Robert H Glass, Nathan G Kase. Reproduction and the thyroid. In: Charles Mitchel, editor. *Clinical Gynaecologic Endocrinology and Infertility* 6th ed. USA: Lippincott Williams and Wilkins; 1999 p821-8.
- [41] Padmanabhan LD, Mhaskar R, Mhaskar A, Vallikad E. Trophoblastic hyperthyroidism. *JAPI* 2003; 51:1011-13.



- [42] Ballabio M, Poshychinda M, Ekins RP. Pregnancy induced changes in thyroid function: role of human chorionic gonadotropin as putative regulator of maternal thyroid. *J Clin Endocrinol Metab* 1991; 73(4):824-31.
- [43] Dave N, Fernandes S, Ambi U, Iyer H. hydatidiform mole with hyperthyroidism – perioperative challenges. *J Obstet Gynecol India* 2009; 59:356-7. Hershman JM, Higgins HP. Hydatidiform mole – a cause of clinical hyperthyroidism. *The New England Journal of Medicine* 1971; 284(11):573-7.
- [44] Hughes Katherine, Campbell Alastair, Cooper Sarah, Sandeep Thekkepat, Adamson K. Thyrotoxicosis complicating molar pregnancy. *Endocrine Abstracts* 2007; 13:326.
- [45] Laurent V, Besson L, Doussin JF, Rondelet B, Banssillon V. Hyperthyroidism induced by molar pregnancy. *Ann Fr Anesth Reanim* 1993; 12(4):424-7.
- [46] Chiniwala NU, Wolf PD, Bruno CP, Kaur S, Spector H, Yacono K. Thyroid storm caused by a partial Hydatidiform mole. *Thyroid* 2008;18(4):479-81.
- [47] Galton VA, Ingbar SH, Jimenez FJ, Hershman JM. Alterations in thyroid hormone economy in patients with hydatidiform mole. *The Journal of Clinical Investigations* 1971; 50:1345-54.
- [48] Hershman JM, Higgins HP. Hydatidiform mole-a cause of clinical hyperthyroidism. *The New England Journal of Medicine* 1971;284(11):573-7.
- [49] Lemon M et al. Thyroid function in trophoblastic disease. *Br J Obstet Gynecol* 1987; 11:1084-8.
- [50] Kato K, Mostafa MH, Mann K, Schindler AE, Hoermann R. The human chorionic gonadotropin molecule from patients with trophoblastic diseases has a high thyrotropic activity but is less active in the ovary. *Gynecol Endocrinol* 2004; 18(5):269-77.
- [51] Erol DD, Serhan CA, Ihsan U. Preoperative preparation and general anaesthesia administration with sevoflurane in a patient who develops thyrotoxicosis and cardiogenic dysfunction due to a hydatidiform mole. *The Internet Journal of Anesthesiology* 2004; Available from:[http://www.ispub.com/journal/the\\_internet\\_journal\\_of\\_anesthesiology/archive/volume\\_8\\_number\\_1\\_12.html](http://www.ispub.com/journal/the_internet_journal_of_anesthesiology/archive/volume_8_number_1_12.html)
- [52] Bruun T, Kristoffersen K. Thyroid function during pregnancy with special reference to hydatidiform mole and hyperemesis. *Acta Endocrinol (Copenh)* 1978; 88(2):383-9.
- [53] Dowling JT, Ingbar SH, Freinkel N. Iodine metabolism in hydatidiform mole and choriocarcinoma. *The Journal of Clinical Endocrinology and Metabolism* 1960; 20(1): 1-12.
- [54] Desai RK, Norman RJ, Jialal I, Joubert SM. Spectrum of thyroid function abnormalities in gestational trophoblastic neoplasia. *Clin Endocrinol (Oxf)* 1988; 29(6):583-92.



- [55] Norman RJ, Green-Thompson RW, Jialal I, Soutter WP, Pillay NL, Joubert SM. Hyperthyroidism in gestational trophoblastic neoplasia. *Clin Endocrinol (Oxf)* 1981; 15(4):395-401.
- [56] Odell WD, Bates RW, Rivlin RS, Lipsett MB, Hertz RB. Increased thyroid function without clinical hyperthyroidism in patients with choriocarcinoma. *J Clin Endocrinol Metab* 1963; 23: 658-664.
- [57] Amir SM, Osathanondh R, Berkowitz RS, Goldstein DP. Human chorionic gonadotropin and thyroid function in patients with hydatidiform mole. *Am J Obstet Gynecol* 1984; 150(6):723-8.
- [58] Kock H, von Kessel H, Stolte L, von Leusden H. Thyroid function in molar pregnancy. *J Clin Endocrinol Metab* 1966; 26:1128-1134.
- [59] Khanna P, Kumar A, Dehran M. Gestational trophoblastic disease with hyperthyroidism: Anesthetic management. *J Obstet Anaesth Crit Care* 2012; 2(1):31-3.
- [60] Halpern SH. Anaesthesia for Caesarean Section in patients with uncontrolled hyperthyroidism *Can J Anaesth* 1989; 36(4):454-9.
- [61] Morley JE, Jacobson RJ, Melamed J, Hershman JM. Choriocarcinoma as a cause of thyrotoxicosis. *Am J Med* 1976; 60(7):1036-40.
- [62] Moskovitz JB, Bond MC. Molar pregnancy induced thyroid storm. *The Journal of Emergency Medicine* 2010; 38(5):e71-e76.
- [63] Kurdi MS. Hydatidiform mole: A sour encounter with a grapy case. *Indian J Anaesth* 2011; 55:171-3.
- [64] Solak M, Akturk G. Spinal anaesthesia in a patient with hyperthyroidism due to hydatidiform mole. *Anesth Analg* 1993; 77:851-2.
- [65] Soutter WP, Norman R, Green-Thompson RW. The treatment of choriocarcinoma causing severe thyrotoxicosis. *Br J Obstet Gynecol* 1981; 88(9):938-43.
- [66] Erbil Y et al. Severe hyperthyroidism requiring therapeutic plasmapheresis in a patient with hydatidiform mole. *Gynecol Endocrinol* 2006; 22(7):402-4.
- [67] Azezli Adil, Bayraktaroglu Taner, Topuz Sanet, Kalayoglu-Besisik Sevgi. Hyperthyroidism in molar pregnancy: rapid preoperative preparation by plasmapheresis and complete improvement after evacuation. *Transfus Apher Sci* 2007; 36(1): 87-9.
- [68] Ozbey N, Kalayoglu-Besisik S, Gul N, Bozbora A, Sencer E, Molevalilar S. Therapeutic plasmapheresis in patients with severe hyperthyroidism in whom antithyroid drugs are contraindicated. *Int J Clin Pract* 2004; 58(6):554-8.
- [69] Lynch EP. Endocrine disease. In: Andre Van Zundert, Gerard W Ostheimer, editors. *Pain Relief and Anaesthesia in Obstetrics* 1st ed. New York: Churchill Livingstone; 1996 p605-48.

- [70] Yang Ming-Jie, Cheng Ming-Huei. Pregnancy complicated with pulmonary oedema due to hyperthyroidism. *J Chin Med Assoc* 2005; 68(7):336-338.
- [71] Mehta P A, Dubrey SW. High output heart failure. *QJM* 2009;102(4):235-41.
- [72] Panagoulis C, Halapas A, Chariatis E, Driva P, Matsakas E. Hyperthyroidism and the heart. *Hellenic J Cardiol* 2008;49:169-175.
- [73] Choudhury R P, Mac Dermot J. Heart failure in thyrotoxicosis, an approach to management. *Br J Clin Pharmacol* 1998; 46(5):421-24.
- [74] Malyer RH, Trivedi TH, Padhiyar NN, Moulick ND, Yeolekar ME. ARDS in a case of vesicular with secondary hyperthyroidism. *J Assoc Physicians India* 2004; 52:992-3.
- [75] Kim JM, Arakawa K, McCann V. Severe hyperthyroidism associated with hydatidiform mole. *Anaesthesiology* 1976;44(5):445-48.
- [76] Struthmann L, Gunthner Biller M, Bergaver F, Friesse K, Mylovas I. Complete hydatidiform mole in a perimenopausal woman with a subsequent severe thyrotoxicosis. *Arch Gynecol Obstet* 2009; 279(3):411-3.
- [77] Huberman RP, Fon GT, Bein ME. Benign molar pregnancies: pulmonary complications. *Am J Roentgenol* 1982; 138:71-74.
- [78] Carrasco C, Cotoras J. Gestational hyperthyroidism: a case associated to molar pregnancy. *Rev Med Chil* 2001; 129(3):303-6.
- [79] Carlos Edvardo David de Almeida, Erick Freitas Curi, Carlos Roberto David de Almeida, Denise Fernandes Vieira. Thyrotoxic crisis associated with gestational trophoblastic disease. *Rev Bras Anesthesiol* 2011; 61(5):604-609.

