

We are IntechOpen, the world's leading publisher of Open Access books Built by scientists, for scientists

6,900

Open access books available

185,000

International authors and editors

200M

Downloads

Our authors are among the

154

Countries delivered to

TOP 1%

most cited scientists

12.2%

Contributors from top 500 universities



WEB OF SCIENCE™

Selection of our books indexed in the Book Citation Index
in Web of Science™ Core Collection (BKCI)

Interested in publishing with us?
Contact book.department@intechopen.com

Numbers displayed above are based on latest data collected.
For more information visit www.intechopen.com



Pre-Cancer and Cancer

Actinic cheilitis

Tobacco pouch keratosis (Smokeless tobacco lesion, snuff dipper's lesion)

Leukoplakia

Erythroplakia

Speckled leukoplakia (Erythroleukoplakia)

Proliferative verrucous leukoplakia

Squamous cell carcinoma

1. Actinic cheilitis (actinic cheilosis)

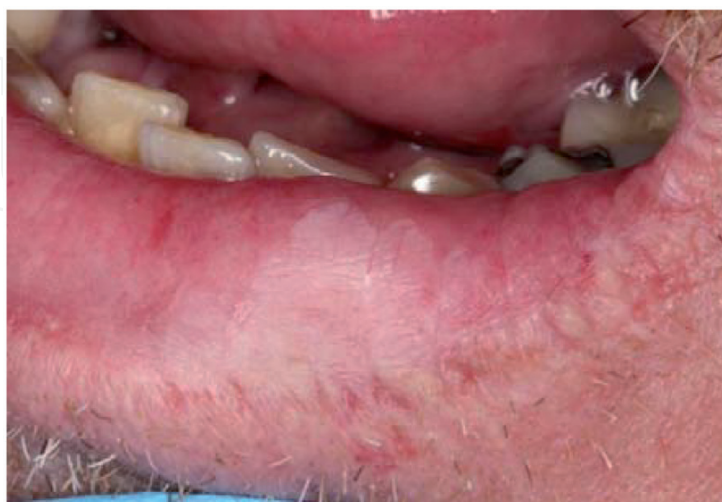Description: Actinic cheilitis is an irreversible precancerous change of the lower lip vermilion. Adult males are the predominant demographic group affected and fair-skinned individuals or those who have an outdoor occupation are at greatest risk. Early changes include the development of blotchy, pale areas and an indistinct margin between the lip vermilion and skin. Rough, scaly areas, leukoplakia, and ulceration may develop as the lesion progresses.

Etiology: Chronic sun exposure

Treatment: Patients should be encouraged to use lip sunscreens or broad-brimmed hats to protect the lip from further damage when outdoors. Scaly, ulcerated, or indurated areas should be biopsied to evaluate for the possibility of transformation to squamous cell carcinoma. Extensive involvement may require vermillionectomy, a procedure where the entire lip vermilion is removed and the labial mucosa is pulled forward.

Prognosis: Good. Actinic cheilitis behaves similarly to actinic keratosis of the skin. Over time, a small proportion of lesions will undergo malignant transformation, which is generally amenable to surgical excision.

Differential diagnosis: Cheilocandidiasis, lip chapping, traumatic ulcer



2. Smokeless tobacco keratosis (tobacco pouch keratosis, snuff dipper's lesion)

Description: Smokeless tobacco keratosis is a reversible alteration of the oral mucosa in immediate contact with a smokeless tobacco product (chewing tobacco, moist snuff, dry snuff). The characteristic appearance is a gray/white mucosal discoloration with a wrinkled or fissured surface texture. The most common locations are the lower labial or buccal vestibule, where the product is held. Gingival recession around teeth in the area of contact is frequently seen.

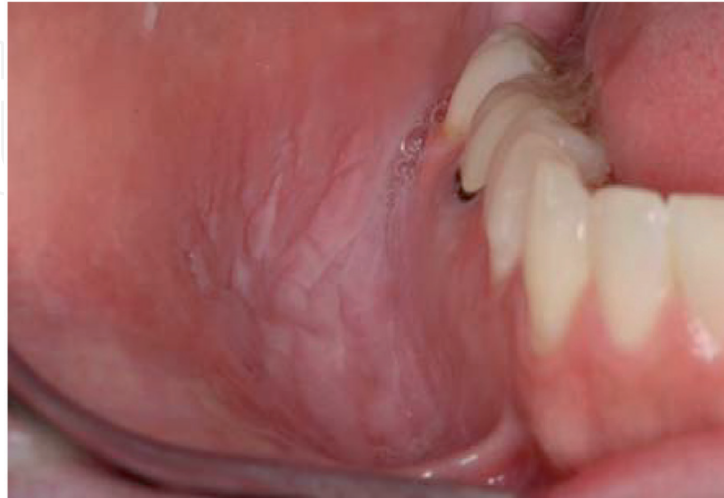Etiology: Reactive mucosal change in response to habitual use of smokeless tobacco products.

Treatment: The patient should be encouraged to discontinue smokeless tobacco use. If the patient is unwilling to quit, moving the product to a different intraoral location is recommended. Lesions should resolve after two weeks of having no smokeless tobacco product in contact with the site. Biopsy is recommended for persistent lesions.

Prognosis: Controversial. The potential dangers of chronic smokeless tobacco use have been debated for many years. While verrucous carcinoma and squamous cell carcinoma have been known to develop within smokeless tobacco keratosis, the risk of developing oral cancer is often overstated. An extensive review of published studies demonstrated a significant but weak association between smokeless tobacco use and oral cancer. When the data was limited to studies published since 1990 and those which adjusted for smoking, the relative risk of developing oral cancer was close to 1.0 compared to individuals who had never used smokeless tobacco. Based on the available evidence, modern day smokeless tobacco products seem to

impart a much lower risk than those used in the past in the U.S. and the associated risk for oral cancer is undoubtedly less than that from smoking.

Differential diagnosis: Leukoplakia, hyperkeratosis



3. Leukoplakia

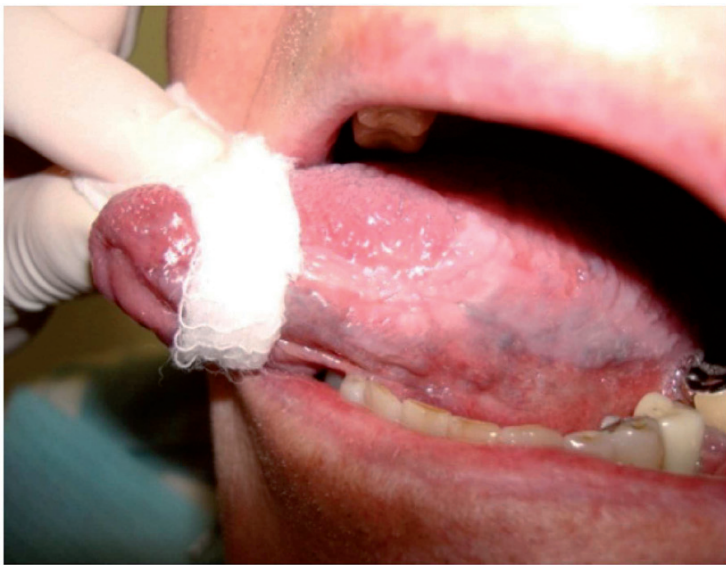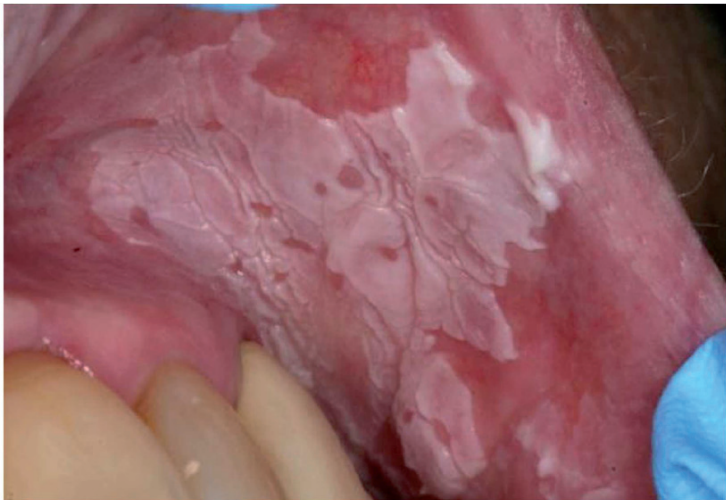Description: Leukoplakia is defined as an adherent white plaque that cannot be explained or diagnosed clinically as any other pathologic entity. It is seen most often in adults over age 40 and may occur in any intraoral location. Leukoplakia is a clinical term used only after exclusion of other characteristic white lesions. While it does not imply a specific histopathologic diagnosis, leukoplakia is considered to be potentially precancerous. Approximately 85% of all oral precancerous lesions present as a leukoplakia.

Etiology: The precise cause is unknown and probably varies among individuals. Many potential causes have been proposed such as trauma, smoking, alcohol, and sanguinaria.

Treatment: Because leukoplakia is a clinical term only, biopsy is required to establish a definitive diagnosis. The histopathologic findings are the most important factor in determining the appropriate treatment. The size of the lesion, location, and other patient factors may also be considered in guiding the treatment protocol. Lesions on the tongue, lip vermillion, and floor of mouth account for over 90% of leukoplakias that are dysplastic or malignant. Unfortunately, no diagnostic test exists at this time to help identify which lesions are likely to transform to squamous cell carcinoma and which are not. The management of mild epithelial dysplasia is controversial, with some experts advising close clinical observation, particularly for large lesions that would be difficult to excise. Leukoplakias which demonstrate epithelial dysplasia that is moderate or worse in severity should be removed entirely if possible. Long-term clinical follow-up is important because leukoplakia often recurs or may develop in a new location.

Prognosis: The prognosis of leukoplakia is dependent on both the clinical features and the histopathologic findings. Thin, homogenous lesions are less likely to undergo malignant transformation than those that are more thickened, granular, or heterogeneous in appearance. Microscopically, the greater the severity of epithelial dysplasia, the greater the risk for malignant transformation. Valid data regarding the precise risk of transformation to squamous cell carcinoma may never be available as many leukoplakias are treated when diagnosed. Furthermore, a long-term study in which no treatment is given to patients with a precancerous lesion would be considered unethical.

Differential diagnosis: Frictional hyperkeratosis, hyperplastic candidiasis, chemical burn, lichen planus, squamous cell carcinoma



4. Erythroplakia

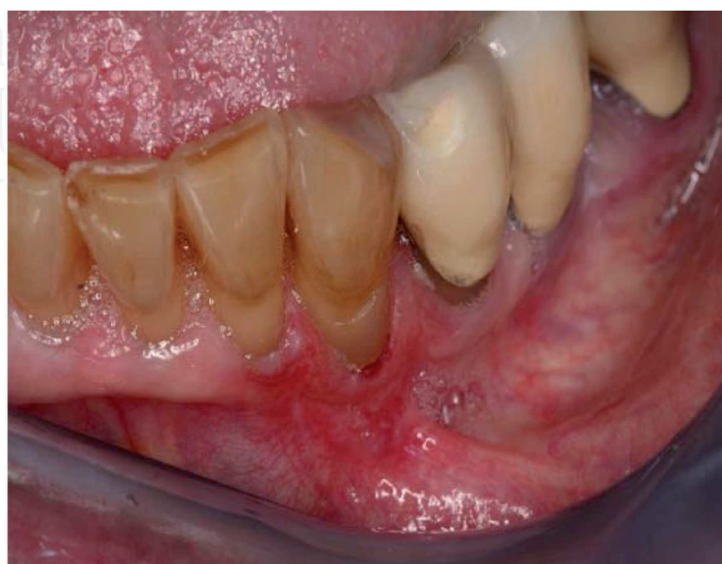Description: Erythroplakia is defined as a red patch that cannot be explained or diagnosed clinically as any other pathologic entity. It is seen most often in middle-aged or older adults and occurs most frequently on the tongue, floor of mouth, and soft palate. Erythroplakia is much less common than leukoplakia, but much more likely to be precancerous.

Etiology: Multiple potential etiologic agents due to several diseases having the clinical appearance of an erythroplakia. For lesions that prove to be precancerous or cancerous on biopsy, the etiology and risk factors are thought to be similar to those of oral squamous cell carcinoma.

Treatment: If there is suspicion for a reactive lesion, removal of any potential etiologic factors and follow-up in 2 weeks is acceptable. Persistent lesions or erythroplakia in a high-risk location (floor of mouth, ventral or lateral tongue) should be biopsied. Similar to leukoplakia, the treatment is determined by the histopathologic findings.

Prognosis: Guarded. As with leukoplakia, the prognosis depends on the definitive microscopic diagnosis. However, 90% of oral erythroplakias demonstrate severe dysplasia, carcinoma in situ, or superficially invasive squamous cell carcinoma at the time of biopsy.

Differential diagnosis: Non-specific mucositis, erythematous candidiasis, anemia, vascular lesions, submucosal hemorrhage



5. Speckled leukoplakia (erythroleukoplakia)

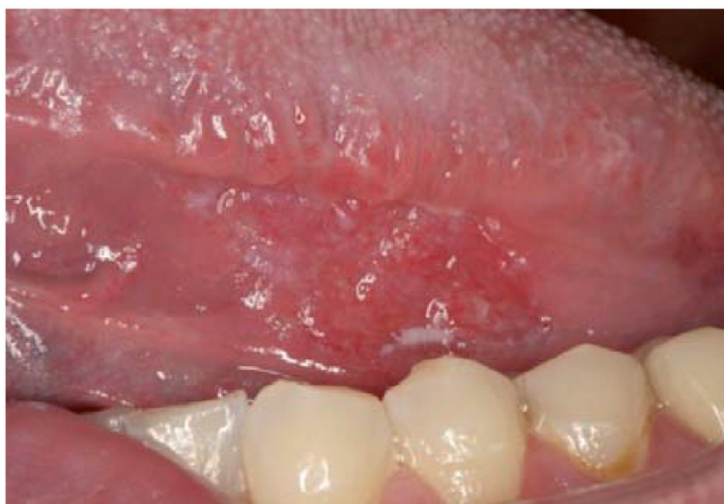Description: Speckled leukoplakia is a mixed red-and-white precancerous lesion considered to be a type of leukoplakia. Red areas within a leukoplakia often represent locations where the epithelial cells are so poorly-differentiated that they are no longer able to produce keratin.

Etiology: Same etiology and risk factors as squamous cell carcinoma

Treatment: Same as erythroplakia. Speckled leukoplakia often demonstrates significant epithelial dysplasia when biopsied.

Prognosis: Guarded. As with leukoplakia and erythroplakia, the prognosis depends on the definitive microscopic diagnosis.

Differential diagnosis: Lichen planus, trauma



6. Proliferative verrucous leukoplakia

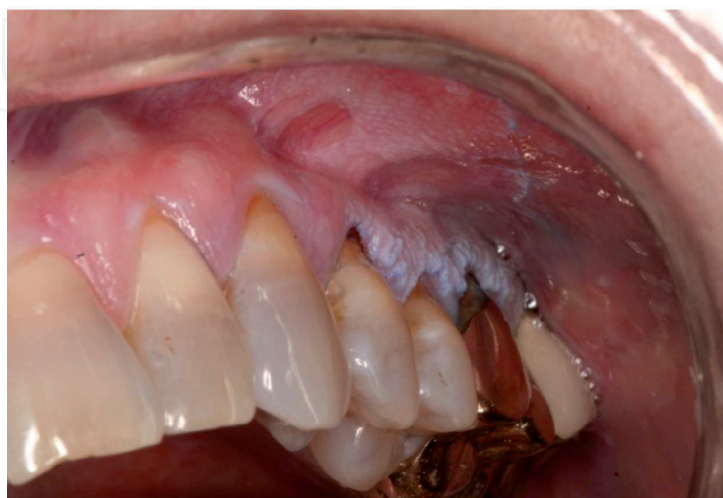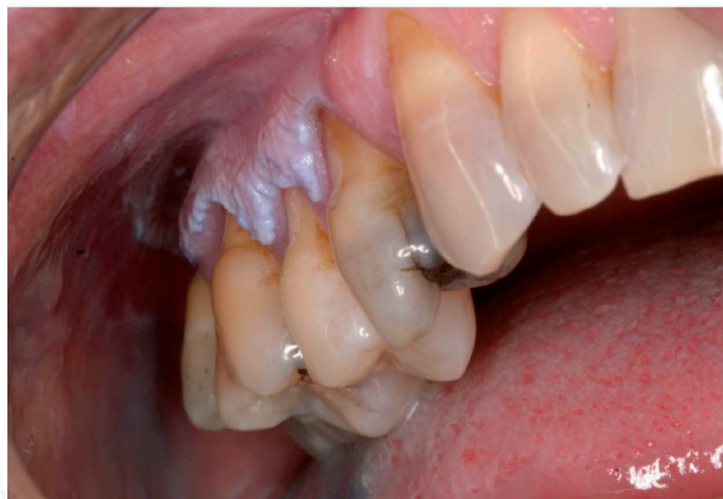Description: Proliferative verrucous leukoplakia (PVL) is a precancerous condition characterized by the development and progression of multiple intraoral leukoplakias. Any combination of locations may be affected, but the buccal mucosa, tongue, and gingiva are common sites of involvement. Lesions begin as thin leukoplakias that slowly evolve a thicker, verrucous surface texture. PVL is three to four times more common in females compared to males, with most patients diagnosed in the 7th decade.

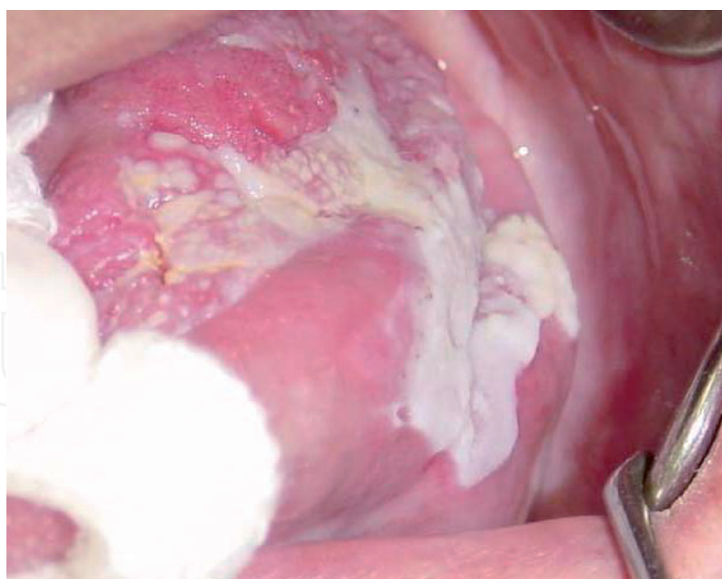
Etiology: Unknown. The majority of PVL cases are not associated with tobacco smoking or other suspected risk factors for traditional leukoplakia and squamous cell carcinoma.

Treatment: Due to the multifocal and often extensive nature of PVL, complete removal of all lesions is not feasible in most cases. Periodic biopsy to assess for dysplasia is appropriate, with selective excision of areas that appear most suspicious clinically. Frequent, long-term re-evaluation is critical due to the persistent and progressive nature of the condition.

Prognosis: Poor. A recent review found that 74% of patients developed squamous cell carcinoma after an average follow-up period of 7-8 years.

Differential diagnosis: Lichen planus, hyperplastic candidiasis, white sponge nevus





7. Squamous cell carcinoma

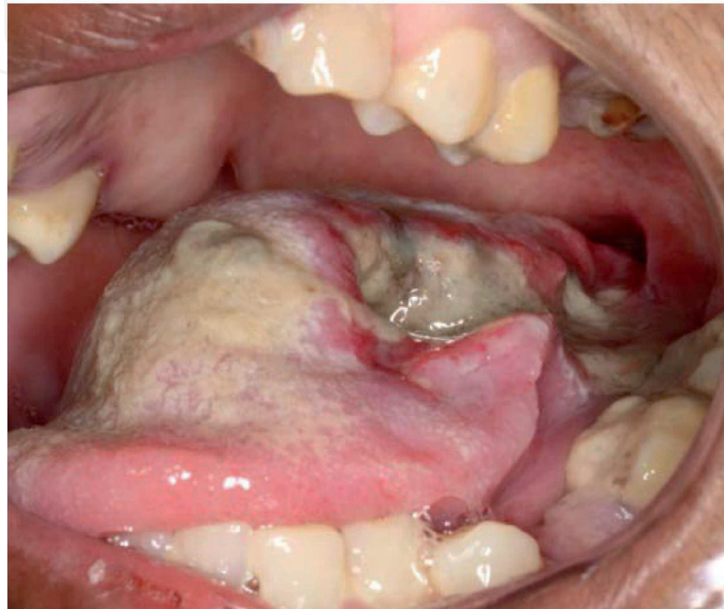
Description: Squamous cell carcinoma (SCC) is a malignancy derived from the surface epithelial cells that line the oral cavity. SCC accounts for over 90% of oral cancers. The risk of developing SCC increases with age and is over twice as common in males compared to females. Early lesions are usually asymptomatic. The lateral and ventral tongue are the most frequent sites of involvement, followed by the floor of mouth, soft palate, gingiva, and buccal mucosa. SCC is variable in appearance. The color may be red, white, or mixed and lesions can be exophytic or endophytic in nature. Ulceration is common and most lesions will feel firm upon palpation (indurated).

Etiology: Multifactorial. Several known or suspected risk factors have been identified. Tobacco smoking is a major etiologic agent in the majority of SCCs. Alcohol abuse, x-irradiation, and genetic mutations have also been implicated. SCC of the lip vermillion is similar in pathophysiology to cutaneous SCC, with sunlight being the primary cause. Human papillomavirus (HPV) infection has recently been established as an independent risk factor for SCC of the oropharynx (tonsils and base of tongue), but not for cancers of the oral cavity. High-risk HPV-16 or HPV-18 subtypes can be identified in the majority of oropharyngeal SCCs. Importantly, 20-25% of oral SCCs are not associated with any of the aforementioned risk factors.

Treatment: SCC of the lip vermillion is treated by surgical excision. The treatment of other oral SCCs is guided by the stage, which is a quantification of the size of the tumor and the extent of its spread (if any) to regional lymph nodes or distant locations. PET/CT imaging is performed to help determine the stage. Surgery, chemotherapy, and radiation therapy (or any combination of these) may be performed, as well as neck dissection if regional lymph node metastasis is suspected. Targeted drug therapy that affects only the cancer cells is being used with increasing frequency and causes much fewer side effects than traditional chemotherapy.

Prognosis: SCC of the lip vermilion behaves similarly to SCC of the skin and has a very good prognosis. The prognosis of other oral SCCs is highly dependent on the stage and also somewhat on location. The overall 5-year survival rate (considering all stages) is estimated to be around 60%. Oral SCC and its treatment can also cause significant morbidity among surviving patients such as facial disfigurement, speech problems, and difficulty eating.

Differential diagnosis: Histoplasmosis, tuberculosis, syphilis, traumatic ulcer



Additional reading

Neville B, Damm DD, Allen CM, and Bouquot J. *Oral and Maxillofacial Pathology*, 3rd edition. Saunders, 2009.

Cabay RJ, Morton TH Jr, Epstein JB. Proliferative verrucous leukoplakia and its progression to oral carcinoma: a review of the literature. *J Oral Pathol Med*. 2007 May;36(5):255-61

Lee PN, Hamling J. Systematic review of the relation between smokeless tobacco and cancer in Europe and North America. *BMC Med*. 2009 Jul29;7:36

American Cancer Society website (www.cancer.org)