

# We are IntechOpen, the world's leading publisher of Open Access books Built by scientists, for scientists

6,900

Open access books available

185,000

International authors and editors

200M

Downloads

Our authors are among the

154

Countries delivered to

TOP 1%

most cited scientists

12.2%

Contributors from top 500 universities



WEB OF SCIENCE™

Selection of our books indexed in the Book Citation Index  
in Web of Science™ Core Collection (BKCI)

Interested in publishing with us?  
Contact [book.department@intechopen.com](mailto:book.department@intechopen.com)

Numbers displayed above are based on latest data collected.  
For more information visit [www.intechopen.com](http://www.intechopen.com)



---

# **Current State-of-the-Science Adjuvant and Neoadjuvant Therapy in Surgically Resected Colorectal Cancer**

---

I.H. Sahin and C.R. Garrett

Additional information is available at the end of the chapter

<http://dx.doi.org/10.5772/57481>

---

## **1. Introduction**

Colorectal cancer represents the third most prevalent cancer in the United States, and the third most common cause of cancer-related mortality [1]. Due to the widespread introduction of screening of asymptomatic patients age 50 and above, the incidence of colorectal cancer has been declining [2]. Unfortunately the incidence of colorectal cancer in those under the age of 50 is increasing [3]. In its earliest stages colorectal cancer is highly treatable and curable. Cures in patients with advanced disease are uncommon, but with improved systemic therapies and oncologic surgery, is increasing over time. However, despite modern therapeutic advances, less than 20% of patients with distant metastatic disease will be alive and disease free for five years following the diagnosis [4].

Management of colorectal cancer highlights the importance of oncologic multidisciplinary care. Surgical adjuvant chemotherapy and chemoradiation therapy have led to improved outcomes for patients with colon cancer and rectal cancer, respectively. This is one of the factors associated with a decrease in colorectal cancer mortality over the last decade. Adherence to treatment guidelines has been shown to be associated with improved patient outcomes [5]. Further refinements in adjuvant therapy will involve molecular risk adaption and improved selection of patients for chemotherapy and adjuvant chemoradiation therapy, incorporation of molecularly targeted agents into the treatment paradigm, and studies to define more clearly the optimal time and duration of adjuvant therapy following colorectal surgery.

## **2. Staging of colon cancer**

The pathologic stage of colon cancer is currently based on the seventh version of the American Joint Commission of Cancer Staging [6]; a simplified version is reproduced in Table 1.

Pathologic stage is currently the most accurate predictor of those at greatest risk of relapse, and those most likely to benefit from additional adjuvant therapy. As greater than 80% of patients with stage I disease are cured with surgery alone additional adjuvant therapy has not been shown to improve the already favorable prognosis. Patients with stage II and III are at high risk of systemic relapse and in stage III patients the benefit of adjuvant chemotherapy has clearly been demonstrated and the data supporting it will be reviewed in section 3. Systemic therapy for patients with resected stage II disease remains highly controversial and will be addressed in section 4.

Stage	Description	5-year survival
I	T1,2, N0	85-95%
II	T3,4 N0	60-80%
III	Any T, N 1,2, M0	30-60%
IV	M1	< 20%

**Table 1.** Simplified AJCC Staging Classification and Estimated 5-year Survival

3. Treatment of stage III colon cancer

*5-Flurouracil -based Adjuvant Chemotherapy*

The prodrug 5-flurouracil was synthesized and patented in 1957 [7] and had shown modest efficacy in the treatment of patients with metastatic colorectal cancer, increasing the median survival from 6-9 months without therapy to an average of 12-14 months. Initial studies evaluating its efficacy, combined with the immune modulatory agent levamisole, were conducted by the North Central Cancer Treatment Group (NCCTG) in the 1980s. In a large, randomized, prospective trial, involving multiple sites across the United States, patients treated with 5-flurouracil and levamisole for 12 months were noted to have a 40% reduction in the relative risk of recurrence, and a 33% reduction in the relative risk of mortality [8]. Long term follow up data from this study confirms the increased cure rate in association with the use of adjuvant chemotherapy, not merely the representation of a lead-time bias [9]. Thus 5-flurouracil became, and remains, the backbone of surgical adjuvant therapy for resected stage III colon cancer. Levamisole was associated with significant toxicity however, and subsequent clinical trials demonstrated that 5-flurouracil, modulated by leucovorin, was also associated with a survival benefit [10] but with less neurological toxicity.

Adjuvant 5-flurouracil -based chemotherapy for colon cancer has been refined over time. Weekly 5-flurouracil has been administered (Roswell Park regimen) and in a randomized clinical trial, was demonstrated to be superior to the combination of 5-FU, semustine, and vincristine [10]. Studies comparing 5-flurouracil combined with leucovorin versus levamisole demonstrated that 6 months treatment of 5-flurouracil + leucovorin was equivalent to 12 months 5-flurouracil levamisole; 6 months of 5-flurouracil plus levamisole was determined to

be less effective, in terms of 5-year disease free survival. Thus, six months of therapy is determined to be the optimal. As will be reviewed the optimal duration of chemotherapy is currently under active investigation.

It had been noted that in the metastatic setting, meta-analysis of randomized phase II trials suggested that infusional 5-fluorouracil is more active when compared to bolus intravenous 5-fluorouracil [11]. 5-fluorouracil has a different mechanism of action when given continuously, with a greater inhibition of messenger ribonucleic acid (RNA), when compared to bolus 5-fluorouracil, where the action is more directed at targeting DNA synthesis through inhibition of thymidylate synthetase. Reduced folate (leucovorin) increases the binding of 5-fluorouracil to thymidylate synthase, thereby increasing the efficacy of 5-fluorouracil in inhibiting DNA synthesis (see Figure 1). Although no large, randomized studies comparing bolus 5-fluorouracil compared to infusional 5-fluorouracil have been performed, the superior toxicity profile of infusional 5-fluorouracil (less diarrhea, mucositis, and myelosuppression), and the potential for additive benefit of infusional 5-fluorouracil (given its different mechanism of action) have led to infusional 5-fluorouracil combined with bolus 5-fluorouracil being used more commonly in 5-fluorouracil adjuvant chemotherapy combined with other novel agents.

#### *Oral Fluoropyrimidines*

Capecitabine is an oral pro-drug which is converted to thymidine phosphorylase into 5-fluorouracil. It has been demonstrated that tumor cells have higher levels of thymidine phosphorylase and therefore at least theoretically there could be preferential accumulation of 5-FU in tumor cells. In a large phase III study (the X-ACT) trial was found to be non-inferior to bolus 5-fluorouracil/leucovorin (Mayo Clinic regimen) [12]. Therefore capecitabine is currently approved for patients who are deemed to be suitable candidates for monotherapy, and is an alternative to bolus or infusional 5-fluorouracil. Other oral fluoropyrimidines have been examined for efficacy; UFT is a combination of uracil (a dihydropyrimidine dehydrogenase inhibitor (DPD), the enzyme responsible for metabolizing 5-FU, and tegafur (a 5-FU prodrug). When evaluated in a randomized phase III study of stage II and III patients, and compared to bolus fluorouracil modulated with leucovorin (Roswell Park regimen) it was found to be equal in efficacy [13]. UFT was approved for use in much Europe and Asia but has not been approved for use in the United States.

CapeOx is currently recommended as one of the chemotherapy regimens in the latest version of the National Comprehensive Cancer Network (NCCN) Clinical Practice Guidelines in Oncology (version 1.2011) for the adjuvant treatment of stage III colon cancer. The NO16968 (XELOXA) trial, a large randomized phase III study of CapeOx versus bolus 5-fluorouracil (Roswell Park) was performed in more than 1,800 stage III colon cancer patients. It showed a significantly superior three-year disease free survival with CapeOx when compared to the control arm (71% versus 67%,  $P = 0.0045$ ) [14]. CapeOx was associated with less febrile neutropenia and stomatitis than 5FU/LV, although as expected peripheral neuropathy were more frequent; peripheral neuropathy was observed in a similar proportion of patients receiving FOLFOX or CapeOx.

As a consequence of the efficacy of oxaliplatin, demonstrated in the metastatic setting, a large randomized trial compared the efficacy of infusional 5-FU plus oxaliplatin, and infusional 5-FU combined with bolus 5-FU (the Multi-center International Study of Oxaliplatin, 5-FU, and Leucovorin, in the Adjuvant Treatment of Colon Cancer, or MOSAIC Study). Initial data reported a 23% risk reduction of disease recurrence at three years [15]. Updated 6-year disease-free survival data demonstrated a 6% improvement in disease-free survival, confirming the initial positive results [16]. Since 2003 FOLFOX has been the standard-of-care for patients with resected stage III disease with no contraindications to adjuvant chemotherapy.

Due to the young age of participants in the MOSAIC trial the efficacy of FOLFOX chemotherapy has been questioned in elderly patients, given its increased toxicity, primarily peripheral neuropathy. Pooled analysis of four randomized trials, involving 3,742 patients (of whom 614 were greater or equal to 70 years old) demonstrated that the benefit of FOLFOX chemotherapy did not differ by age, nor did dose intensity [17]. Thus in patients over the age of 70 who are deemed appropriate candidates may still benefit from the addition of oxaliplatin, although very few patients over 80 were included in these studies, thus the data for octogenarians and nonagenarians is limited.

Oxaliplatin was also evaluated in combination with bolus 5-FU (FLOX); in the National Surgical Adjuvant Breast **Project (NSABP)** randomized 2,407 patients with stage II or III colon cancer to either the Roswell Park regiment (bolus 5-FU modulated with leucovorin) or the Roswell Park regimen combined with fortnightly oxaliplatin. There was a superior 5-year disease-free survival with FLOX but not a difference in 5-year overall survival [18].

#### *Adjuvant Irinotecan*

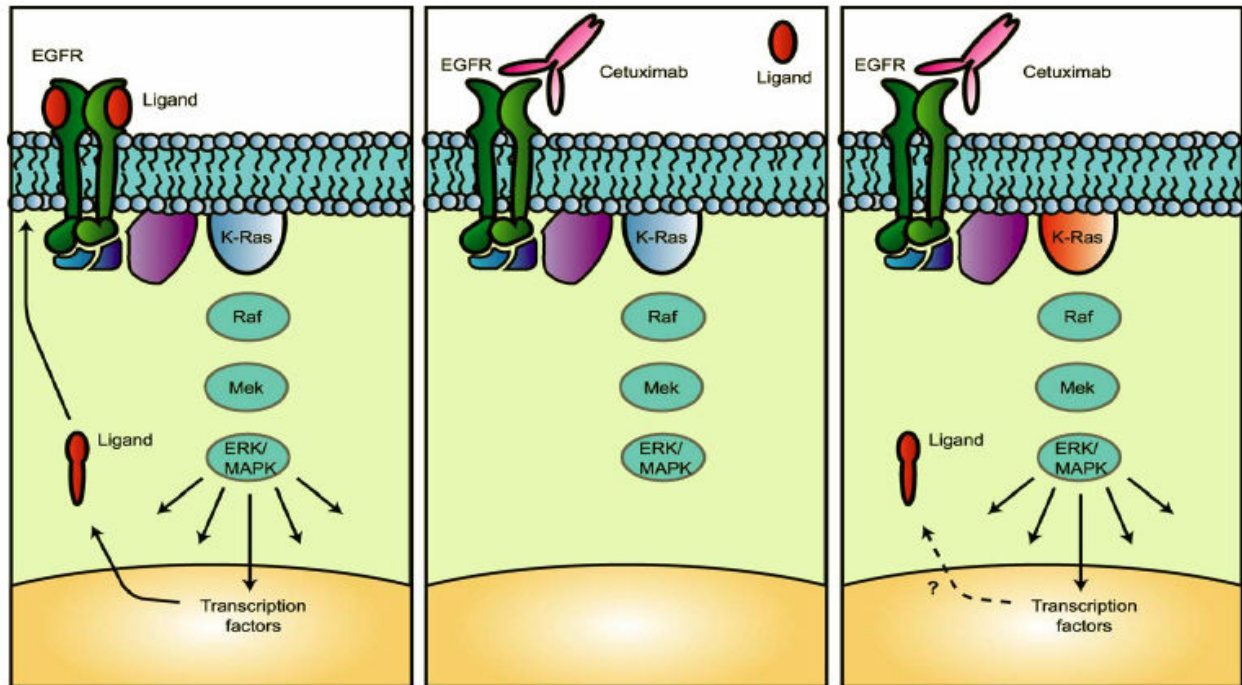
Other combination cytotoxic regimens have been subjected to randomized phase III clinical trial evaluation in the stage III setting. Given the trend to evaluate agents with efficacy in the metastatic setting, and assume at least the potential for benefit in the adjuvant setting, irinotecan has been studied in combination with 5-FU. Prior metastatic studies confirmed the superiority of combination bolus 5-FU plus irinotecan when compared to bolus 5-Fluorouracil monotherapy alone [19], as well as when combined with infusional 5-FU (FOLFIRI) (Douillard JY, et al. 2000). Thus irinotecan was evaluated in the surgical adjuvant setting for high risk patients, both combined with bolus 5-FU (IFL) [21] or as FOLFIRI compared to infusional and bolus 5-fluorouracil (LV5-FU2), the **PETACC-3 study** [22]; neither of these studies demonstrated a benefit to the addition of irinotecan. Therefore at this time irinotecan is not indicated in the adjuvant treatment of colon cancer.

#### *Efficacy of Anti-Epidermal Growth Factor Monoclonal Antibodies in the Adjuvant Therapy of Colon Cancer*

Given the efficacy of the anti-epidermal growth factor antibodies cetuximab [23] and panitumumab [24] in the metastatic setting, it seemed reasonable to explore the efficacy of these antibodies in the adjuvant setting. A large prospective randomized study evaluated the efficacy of FOLFOX with or without cetuximab chemotherapy. During the course of the trial studies demonstrated that the benefit to cetuximab therapy was limited to those patients with KRAS wild type tumors [25]; thus protocol entry to limited to those patients whose tumors



harbored a KRAS mutation (see Figure 2). Despite this selection of therapy there was no improvement in the disease-free survival in the cetuximab treated arm [26].



**Figure 1.** Possible Explanation for Lack of Efficacy of Anti-Epidermal Growth Factor Antibodies in KRAS Mutant Colorectal Cancer

### *Efficacy of Anti-Epidermal Growth Factor Monoclonal Antibodies in the Adjuvant Therapy of Colon Cancer*

Colorectal cancer is the first tumor for which anti-angiogenesis therapies have proven to be effective. The addition of irinotecan plus 5-FU plus the fully humanized anti-vascular endothelial antibody bevacizumab was associated with a 5 month prolongation in overall survival when compared to chemotherapy alone in patients with metastatic disease. This suggested a potential role for this novel targeted agent in the adjuvant therapy of stage III colon cancer. However two studies, the C08 [27] and the AVANT trial [28], both failed to demonstrate a disease free survival benefit to the addition of bevacizumab to standard chemotherapy.

### *Future Cytotoxic Approaches to Adjuvant Colon Therapy*

Although irinotecan did not add to the efficacy of adjuvant chemotherapy there is a suggestion that certain patients with molecular subtypes of colon cancer may benefit from it, possibly patients with microsatellite instable disease [29] Recent randomized phase III clinical trials suggests superior efficacy of the three agents (5-FU, oxaliplatin, and irinotecan, or FOLFOXIRI) when compared to two agents FOLFIRI [30-33]. The efficacy of FOLFOXIRI is under consideration for testing in a prospective randomized clinical trial compared to FOLFOX chemotherapy.

Duration of Adjuvant Therapy in Colon Cancer

As discussed previously, the standard duration of adjuvant chemotherapy was initially 12 months when adjuvant therapy was first approved for colon cancer in 1990. As noted previously subsequent studies determined that 6 months adjuvant duration was determined to be equally effective. A prospective randomized trial comparing 3 months of LV5-FU2 when compared to 6 months 5-fluorouracil modulated with leucovorin (Mayo regimen) did not demonstrate a statistically significant difference in overall survival ( $P>0.05$ ). Given as the trial was not powered as a non-inferiority study, there are four ongoing studies comparing 3 versus 6 months adjuvant chemotherapy (see table 2). Although there are some differences in the study design, close to 18,000 patients will be entered on these four studies during this decade. In order to pool the data from these studies, the International Drug Evaluation of Adjuvant Chemotherapy (IDEA) was formed to coordinate the data analysis of the pooled results. It is hoped that by the end of the decade the question of whether or not the shorter course (3 months) is equally effective will be satisfactorily answered.

Clinical Trial	Stage Evaluated	Start Date	Target Accrual	Treatment Plan
SCOT*	III	3/27/2008	9,500	CapeOx/FOLFOX 6 months vs. CapeOx/FOLFOX 3 months
TOSCA	II, III	6/20/2007	3,450	FOLFOX 6 vs. 3 months (plus optional bevacizumab randomization for stage IIIc)
GERCOR	III	5/2/2009	2,500	FOLFOX 6 vs. 3 months
CALGB/SWOG C80702	III	7/1/2010	2,500	FOLFOX 6 vs. 3 ± celecoxib/placebo

\*Short Course Oncology Therapy

Table 2. Planned Randomized Phase III Studies Evaluating the Duration of Adjuvant Chemotherapy

4. Adjuvant radiation therapy for colon cancer

No prospective data to date has suggested a survival benefit with the addition of radiation therapy as adjuvant following surgery. Retrospective data suggests that patients with high risk features for recurrence may receive benefit from radiation, including those who had T4 disease (involving another organ), a positive margin (microscopic residual disease, not true adjuvant), and clinical perforation had a better disease-free survival with the addition of adjuvant chemoradiation [34]. One large prospective randomized study evaluating the efficacy of radiation in colon cancers (non-transverse colon) was inconclusive due to the failure to meet accrual. The study was underpowered but was not able to demonstrate a benefit of the addition of radiation to chemotherapy [35]. Treatment decisions have to be made based upon the

patient's specific risk factors for local recurrence. At this time the use of radiation as adjuvant for resected stage III colon cancer is mainly limited to those patients with microscopic residual disease (positive pathologic margin).

## 5. Adjuvant treatment of stage II colon cancer

Due to the significantly better prognosis, with the majority of patients being cured with surgery alone, it is more difficult to demonstrate a significant survival benefit with the use of adjuvant chemotherapy. The initial adjuvant NCCTG adjuvant study of 5-flurouracil and levamisole was unable to demonstrate a survival benefit for the chemotherapy arm; this may in part be due to the higher number of non-cancer-related deaths in the 5-flurouracil treated group [8]. A large randomized, prospective trial of 3,239 patients with resected stage II disease demonstrated a 3.6% 5-year improvement in survival following 6 months adjuvant 5-fluorouracil and leucovorin (Mayo regimen) when compared to observation alone [35]. All agree that if a benefit exists it is relatively small and that the routine use of chemotherapy is not indicated. Of note, in the MOSIAC trial, there was no difference in outcome between stage II patients treated with FOLFOX when compared to infusional and bolus 5-flurouracil chemotherapy. Different pathologic characteristics may indicate those patients at slightly higher risk of relapse [see table 3]. Tumor microsatellite instability analysis has been associated with a more favorable prognosis, as well as a lack of benefit from adjuvant 5-flurouracil chemotherapy in resected stage II and stage III tumors; in stage II tumors those patients with mismatch repair tumors had an inferior outcome with the use of 5-fluoruracil adjuvant chemotherapy when compared to observation [39]. Tumor molecular genotyping is being utilized in order to predict those stage II tumors most likely to relapse. To date, these genomic tests have not been sufficiently predictive of those most likely to relapse and are of limited clinical utility [40-41].

Pathologic Feature	Reference
Less than 12 Lymph Nodes Analyzed	36, 37
Poorly differentiated	38
Clinical Perforation	38

**Table 3.** Pathologic Features Associated with a Relatively Adverse Prognosis in Stage II Disease

## 6. Adjuvant and neoadjuvant approaches in rectal cancer

Rectal adenocarcinomas present a unique challenge given its anatomic location in the pelvis and the fact that part of the rectum is intraperitoneal and part is extraperitoneal. The vast majority of rectal malignancies are adenocarcinomas; less common pathologies are gastrointestinal stromal tumor (GIST), carcinoid, squamous, adenosquamous tumors and melanoma. For the purposes of this chapter we will limit our discussed to rectal adenocarcinomas.



Compared the large bowel the close proximity of rectum to other local organs such as urogenital system requires different surgical techniques and significantly increases the likelihood of local relapse after surgery when compared to colon cancer [42]. For this reason, in addition to total mesorectal excision combination therapeutic options have arisen to decrease local recurrence. Subsequently, these multimodality therapy approaches have become standard-of-care in locally advanced rectal cancer. In this book chapter, we aimed to summarize scientific progression in the field of treatment of locally advanced rectal cancer.

#### *Development of Adjuvant Therapy*

The standard care of rectal cancer remains surgery with a total mesorectal excision. However locally advanced disease were relapsing significantly higher than early stage disease after surgery-only approach [43]. Rectal cancer transmurally invades the rectal wall directly and can spread through the lymphatic system to regional lymph nodes. These characteristics of locally advanced disease put the patients at higher risk of local and distant recurrence which is associated worse overall survival. Given the high rate of the recurrent disease, combination treatment approaches have evolved in locally advanced rectal cancer over the last two decades. First, adjuvant radiotherapy and then combined modality therapy (chemotherapy concurrently with radiation therapy) was integrated in standard care to enhance survival outcomes of locally advanced rectal cancer.

An early prospectively randomized clinical trial was conducted to assess the question of the adjuvant benefit roles of radiation, chemotherapy, or combined modality therapy (chemoradiation) in the treatment of locally advanced rectal cancer by the Gastrointestinal Tumor Study Group (GTSG) in 1985 [44]. In this study, patients after having curative surgery (202 in total), were enrolled and randomized into four different groups including; patients received no adjuvant treatment, patients treated with adjuvant radiotherapy either at dose of 40 or 48 Gray, patients received adjuvant chemotherapy with semustine and 5-fluorouracil, and a final group treated with combination of chemotherapy and radiotherapy. All patients were followed up to for 80 months. Although there was no significant difference for OS in four groups, authors found significantly better disease-free survival in combination therapy arm compared to resection-alone [44]. In same study, recurrence rate was highest in resection-alone with 55%, while the lowest relapse was observed in combination therapy group (33%). The follow-up results of this study confirmed a significantly improved overall survival reported in combination treatment group compared to surgery alone group [45]. By the end of the 10 year follow up, 10-year survival rates were 26% vs. 45% in control group vs. combination treatment group and was showing the superiority of combination treatment group. Independently, The National Surgical Adjuvant Breast and Bowel Project (NSABP) released the result of R-01 that comparing adjuvant radiation or chemotherapy to surgery alone and provided superior overall and disease-free survival in chemo group respect to the surgery alone ( $P = 0.03$ ,  $P = 0.006$  respectively) [46]. No significant survival benefit observed in radiation alone group.

The North Central Cancer Treatment Group (NCCTG) reported a trial comparing the adjuvant radiation versus the combined chemoradiation. In this study, total 209 patients randomized

in two arms. The combined modality arm was found to have 34% reduced overall recurrence compared to the radiation alone. ( $P < 0.003$ ) [47]. Decreased recurrence incidence was observed in both local (25% versus 13%  $P < 0.02$ ) and distant relapse (43% versus 29.5%  $P < 0.003$ ). After this study National Surgical Adjuvant Breast Program (NSABP) examined the impact of the adjuvant chemotherapy alone versus chemoradiotherapy on overall survival and disease free survival in protocol R-02. In this study, all female patients received 5-fluorouracil and leucovorin whereas male patients either received MOF regimen including 5-fluorouracil, semustine, vincristine or 5-fluorouracil combined with leucovorin. Radiotherapy was given in 25 fractions at a daily 18 Gray dose. Although there was a significant decrease in cumulative local relapse incidence after 5-year follow-up (13% versus 8%,  $P = 0.02$ ), they observed no overall or disease-free survival differences in between these two groups.

#### *Neoadjuvant Radiotherapy*

Absence of clinical evidence to use radiotherapy in adjuvant settings urged the researchers to test the efficacy of radiotherapy in preoperative settings. Swedish investigators conducted a phase III clinical trial to understand the possible role of neoadjuvant radiotherapy (i.e. pre-operative radiation therapy) [48]. They enrolled 1,168 patients and randomly assigned to receive either conventional surgery alone or surgery with preceded neoadjuvant radiotherapy designed as a total dose of 25 Gy in five fractions. After five years follow up, recurrence rate was found 11% in neoadjuvant radiotherapy group, whereas it was observed as high as 27% in patients with surgery alone ( $P < 0.001$ ). Additionally, the authors reported significantly better five year-survival in radiotherapy arm (58% compared to 48%,  $P = 0.004$ ). Since conventional surgery was performed in this study, the additive role of the radiation in TME was still not clear. In 2007, this question was addressed by Dutch Colorectal Cancer Group. They conducted a randomized clinical trial enrolled the patients into TME alone and 5 fractions radiotherapy with total 25 Gray dose plus total mesorectal excision [49]. After a median 6.1 years follow-up, no significant overall survival difference was demonstrated. Moreover, there was no significant difference in distal recurrence incidence. On the other hand, they found a significant decrease in local recurrence rate (5.6 % vs 10.9%,  $P < 0.001$ ).

Currently, two different preoperative radiotherapy protocols are commonly preferred in locally advanced rectal cancer treatment including conventional (50.4 Gray administered in 28 fractions) and short-term treatment (25 Gray in 5 fractions). Although both models have been shown to decrease local recurrence, there are debates on prolonged side effect in short-term radiotherapy modality [50]. While short-term neoadjuvant radiation treatment is commonly used in European countries, conventional radiation is standard-of-care of locally advanced rectal cancer in USA.

#### *Neoadjuvant Chemoradiation Therapy (Combined Modality Therapy)*

Better outcomes observed in chemoradiation in adjuvant settings raised the question of possible neoadjuvant chemoradiation for treatment of patients with locally advanced rectal cancer. In 2004, German Rectal Cancer Study Group (GRC SG) examined the role preoperative chemoradiation in rectal cancer patients with T3 or T4 stages or node positivity [51]. They randomized 823 patients in two groups; the neoadjuvant arm received a total 50.4 Gray dose

radiation in 28 fractions and 5-fluorouracil 120-hour continuous infusion during the first and fifth weeks of radiation at a dose of 1,000 mg per square meter of body surface then followed by surgery after completing the chemoradiation. Patients also received four cycles of 5-fluorouracil (500 mg per square meter body surface) which was designed as five times weekly during the four weeks. The adjuvant group also received the same treatment except additional a boost of 5.4 Gray radiation after total mesorectal excision. No significant difference was reported for five year-survival in between neoadjuvant and adjuvant group (74% vs 76% respectively,  $P = 0.80$ ). Interestingly, five years cumulative incidence of local recurrence was significantly lower in neoadjuvant group than the adjuvant. (6% versus 13% respectively,  $P = 0.006$ ). Moreover they observed less acute and long term toxicity in neoadjuvant arm of the study compared the adjuvant arm ( $P = 0.001$  versus  $P = 0.01$ ).

In another study, European Organization for Research and Treatment of Cancer (EORTC) randomized 1,011 patients with locally advanced rectal cancer into four different groups: a) preoperative radiotherapy designed as 45 Gy in five weeks, b) preoperative radiotherapy plus two course of 5-fluorouracil and leucovorin (350 mg/m<sup>2</sup>/day and 20 mg/m<sup>2</sup>/day), c) preoperative radiotherapy plus postoperative four course of 5-fluorouracil and leucovorin, and d) preoperative radiotherapy and two course of bolus 5-fluorouracil and leucovorin, plus postoperative four course of postoperative 5-fluorouracil and leucovorin. In early preliminary results of the study, authors reported a significant benefit towards preoperative chemoradiotherapy groups for tumor size, lymph node involvement, pathological complete response ( $P < 0.0001$ ,  $P = 0.046$ ,  $P < 0.001$ ). [52]. Later in follow up results, no significant difference was observed in OS between neoadjuvant chemoradiotherapy and neoadjuvant radiotherapy ( $P = 0.085$ ). On the other hand, local recurrence was significantly lower in preoperative chemoradiation groups ( $P = 0.002$ ) [53]. Chemotherapy protocol which was given in this study was an uncommon protocol possibly is a contributing factor for absence of survival difference in between chemoradiation and radiation alone group in preoperative settings.

To better understand the additive role of neoadjuvant chemoradiation for patients with locally advanced rectal cancer, NSABP R-03 trial was conducted. Two hundreds and sixty-seven patients enrolled in two arms; patients who received neoadjuvant or adjuvant chemoradiation. Neoadjuvant group received a bolus of 5-fluorouracil with leucovorin for six weeks followed by radiation given as a total 45 Gray dose in 25 fractions with an additional 5.4 Gray boost. Then, patients were resected and postoperatively received 24 more weeks of weekly 5-FU and LV. Patients in adjuvant arm also received same courses of treatment in the same order except initial surgical resection. The most striking finding of this study was superior 5-year disease-free survival observed in neoadjuvant arm (64.7% vs 53.4%,  $P = 0.011$ ). Although there was not a significant difference in OS ( $P = 0.65$ ), There was trend for observed five-year overall survival as 74.7% vs 65.6% in the neoadjuvant and adjuvant arms respectively [54]. Overall, all these clinical trials support the use neoadjuvant chemoradiation as standard-care-of locally advanced colorectal cancer. Although there is no clear result proving as an evidence for the superior OS compared to adjuvant chemoradiation, decreased local recurrence incidence with neoadjuvant treatment promises better local disease control. Moreover decreased acute and

prolonged treatment related toxicities and improved sphincter preservation observed in preoperative treatment also favor the neoadjuvant chemoradiation modality [54].

### *Current Drugs for Neoadjuvant Therapy of Rectal Cancer*

#### *5-Fluorouracil*

5-fluorouracil has become the recommended first-line chemotherapy in locally advanced rectal cancer patients based on the GTSG and NCCTG data [44,47]. The most commonly preferred administration mode of 5-fluorouracil is continuous intravenous infusion (225-300 mg/m<sup>2</sup> daily). To compare the bolus administration with continuous intravenous infusion, the NCCTG randomized 660 patients in two arms. Both arms received concurrent radiotherapy. First group received bolus 5-fluorouracil on three consecutive days as a rapid infusion of 500 mg/m<sup>2</sup> while the other group received as protracted infusion (225 mg/m<sup>2</sup>/day). Four-year relapse free survival was 63% in continuous infusion group while it was 53% in the bolus arm ( $P = 0.01$ ). Significant difference for 4-year overall survival was also observed in the same study. Four-year overall survival was 70% as compared to 60% in continuous infusion and bolus group respectively ( $P = 0.005$ ). Interestingly, no benefit was observed for local relapse in continuous infusion group ( $P = 0.110$ ). While leukopenia was more common in bolus group, diarrhea incidence was found higher in continuous infusion group.

#### *Capecitabine*

Since superior outcomes observed in continuous intravenous administration of 5-fluorouracil in chemoradiation regimens, an equivalent fluoropyrimidine, capecitabine was studied for locally advanced rectal cancer treatment. Oral administration of capecitabine which has very similar pharmacokinetics to continuous intravenous 5-fluorouracil provided more convenient treatment for patients if they are able to tolerate oral administration. In a phase I clinical study, the recommended dose of the capecitabine was determined as 1800 mg/m<sup>2</sup> daily given orally in two divided doses combined with 50.4 Gray preoperative radiation [56]. A prospectively randomized study of 1,987 patients was enrolled into two groups; a) patients who received capecitabine orally, b) patients who were administered bolus 5-fluorouracil modulated with leucovorin [58]. In the results of this study, non-inferior disease-free survival was observed in capecitabine group. The capecitabine improved relapse-free survival ( $P = 0.04$ ). Moreover, fewer adverse effects were seen with capecitabine treatment compared to bolus 5-fluorouracil plus leucovorin arm ( $P < 0.001$ ) [58].

The NSABP R-04 trial compared the use of capecitabine to continuous infusion 5-fluorouracil with or without oxaliplatin during combined modality therapy in locally advanced rectal cancer. 5-fluorouracil was given as a 225 mg/m<sup>2</sup> daily protracted venous infusion during radiation and capecitabine was given at 1650 mg/m<sup>2</sup> orally in two divided doses daily on the days of radiation only. There was no significant difference regarding pathologic complete response, surgical downstaging or sphincter-saving surgery. Local recurrence and overall survival have yet to be reported [59].

More recently, in a randomized phase III study, German researchers compared the efficacy of capecitabine with 5-fluorouracil as neoadjuvant radiosensitizing agent [60]. In this study, 392



patients were randomized into two groups. Patients in capecitabine arm were enrolled to receive two cycles of capecitabine ( $2,500 \text{ mg/m}^2$  days 1-14, repeated day 22), then followed by chemoradiotherapy (50.4 Gray plus capecitabine  $1,650 \text{ mg/m}^2$  days 1-38 and additionally three cycles of capecitabine). Two cycles of bolus 5-fluorouracil ( $500 \text{ mg/m}^2$  days 1-5, repeated day 29), followed by chemoradiotherapy (50.4 Gray plus infusional 5-fluorouracil  $225 \text{ mg/m}^2$  daily), finally two cycles of bolus 5-FU were administered patients in 5-fluorouracil arm. Results were promising for non-inferiority with significantly better 5-year OS in capecitabine group (76% as compared to 67%,  $P = 0.05$ ). Similarly disease-free survival was also higher in capecitabine group (75% versus 67%,  $P = 0.07$ ).

### *Oxaliplatin*

Given the promising results of oxaliplatin treatment of colon cancer in adjuvant setting [15] and metastatic disease [61] its possible additive effect to the neoadjuvant treatment of rectal cancer has been investigated. In a phase II clinical trial, oxaliplatin (at  $50 \text{ mg/m}^2$  on days 1, 8, 22, and 29) plus capecitabine ( $1,650 \text{ mg/m}^2$  on days 1 to 14 and 22 to 35) with radiotherapy (50.4 Gray in 28 fraction) was tested both for activity and safety [62]. Pathologic complete response was achieved in 17% patients whereas 53/103 patients showed more than 50% tumor regression. Although results were not superior to standard 5-FU treatment phase III trials were warranted. The randomized phase III Studio Terapia Adiuvante Retto (STAR)-01 trial has tested to outcomes of addition of oxaliplatin ( $60 \text{ mg/m}^2$ ) to chemoradiation ( $225 \text{ mg/m}^2/\text{day}$  plus 50.4 Gray in 28 daily fractions) comparing with standard chemoradiation [62]. Addition of oxaliplatin did not increase pathologic complete response rate (16% versus 16%) but rather increased grade 3 to 4 adverse events in oxaliplatin arms ( $P < 0.001$ ).

Recently published German CAO/ARO/AIO-04 randomised phase III trial also investigated the role of oxaliplatin in neoadjuvant chemoradiation [63]. In the study control group was treated with standard 5-fluorouracil-based combined modality treatment, consisting of preoperative radiotherapy of 50.4 Gray plus infusional 5-fluorouracil ( $1000 \text{ mg/m}^2$  days 1-5 and 29-33), followed by surgery and four cycles of bolus fluorouracil ( $500 \text{ mg/m}^2$  days 1-5 and 29). Oxaliplatin arm received preoperative radiotherapy of 50.4 Gray plus infusional 5-fluorouracil ( $250 \text{ mg/m}^2$  days 1-14 and 22-35) and oxaliplatin ( $50 \text{ mg/m}^2$  days 1, 8, 22, and 29), followed by surgery and eight cycles of adjuvant chemotherapy with oxaliplatin ( $100 \text{ mg/m}^2$  days 1 and 15), leucovorin ( $400 \text{ mg/m}^2$  days 1 and 15), and again infusional 5-fluorouracil. Authors reported better pathologic complete response outcomes in oxaliplatin treatment arm compared to standard group (17% vs 13% respectively,  $P = 0.038$ ). Controversially, ACCORD 12/0405-PRODIGE 2 trial reported no benefit with additional oxaliplatin [64]. In this study control patients were assigned to receive 5 weeks of treatment with radiotherapy 45 Gy/25 fractions with concurrent capecitabine  $800 \text{ mg/m}^2$  twice daily (5 days per week). The experimental arm of the study received 50 Gray in 25 fractions radiation with capecitabine  $800 \text{ mg/m}^2$  twice daily (5 days per week) and oxaliplatin  $50 \text{ mg/m}^2$  (once weekly). Although there was trend toward oxaliplatin plus group for pCR it was not significant (19.2% vs 13.9%  $P=0.09$ ). Preoperative grade 3 and 4 toxicities were observed significantly higher in oxaliplatin plus arm ( $P < 0.001$ ). Since there is no consensus in clinical trials for benefit with additional oxaliplatin it is not currently standard-of-care of locally advanced rectal cancer.



### *Targeted Therapies*

Monoclonal antibodies targeting the critical survival signaling pathways such as epidermal growth factor receptor (EGFR) and vascular endothelial growth factor receptor (VEGFR) are currently under the investigation to determine their role in neoadjuvant chemoradiation treatment in rectal cancers. The potential role of cetuximab and bevacizumab in the treatment of locally advanced rectal cancer has been tested in phase I and phase II clinical trials.

In a phase I/II clinical study the safety and potential benefit of cetuximab in neoadjuvant chemoradiation investigated in locally advanced rectal cancer patients. Forty patients enrolled to receive initial intravenous dose of 400 mg/m<sup>2</sup> cetuximab which was given 1 week before the initiation of radiation followed by 250 mg/m<sup>2</sup>/week for 5 weeks and capecitabine during the radiotherapy 650 mg/m<sup>2</sup> orally twice daily and 825 mg/m<sup>2</sup> twice daily, as a second dose level [65]. Observed pathologic complete response was only in two patients (5%), while diarrhea was seen in 65% of the patients. Grade 3 diarrhea was detected in 15% of cases. In one patient three grade 4 toxic effect was reported by authors; one myocardial infarction, one pulmonary embolism, and one pulmonary infection with sepsis.

In the EXPERT-C trial, combination of cetuximab and capecitabine plus oxaliplatin was studied in neoadjuvant settings. One hundred sixty-five patients enrolled in two arms to receive four cycles of capecitabine/oxaliplatin and then capecitabine chemoradiotherapy, surgery, and adjuvant CAPOX (four cycles) or the same regimen plus weekly cetuximab [66]. In this study the most striking finding was significantly improved OS in cetuximab plus group ( $P = 0.034$ ). Additionally, a better radiologic response was determined in cetuximab group. On the other hand there was no difference either in pathologic complete response rate or progression-free survival ( $P = 1.0$ ,  $P = 0.363$  respectively)

Another fully humanized monoclonal antibody, that binds circulating anti-vascular epithelial growth factor, bevacizumab, has also been investigated in combination neoadjuvant treatment of rectal cancer. In a phase I/II study, bevacizumab combined with preoperative 5-FU and radiotherapy in 32 locally advanced rectal cancer patients [67]. Patients were administered four cycles of bevacizumab infusion (5 or 10 mg/kg) on day 1 of each cycle; 5-FU (225 mg/m<sup>2</sup>/24 hours) during cycles 2 to 4; radiotherapy in 28 fractions with a total dose of 50.4 Gy over 5.5 weeks. Surgery was performed 7 to 10 weeks after completion of all therapies. No grade 4 toxicity was detected and the most frequent toxicity was diarrhea. Pathologic complete response was achieved in 5 out of 32 patients. In another phase II study, bevacizumab was explored in a combination treatment of capecitabine and radiotherapy [68]. Twenty-five rectal cancer patients received neoadjuvant therapy with radiotherapy (50.4 Gy in 28 fractions over 5.5 weeks), bevacizumab every 2 weeks (3 doses of 5 mg/kg), and capecitabine (900 mg/m<sup>2</sup> orally twice daily during the radiation). Surgical resection was performed a median of 7.3 weeks later initial treatment. An encouraging pathologic complete response rate was reported in 8 of 25 patients (32%). Six of 24 patients showed less than 10% viable tumor cells in final pathological specimens. No patient was reported with grade 3 gastrointestinal toxicity or significant hematologic toxicity.

In a recent study, bevacizumab was tested in a combined treatment including the oxaliplatin, 5-FU, and radiotherapy in 26 patients [69]. Patients were initially treated with 1 month of induction bevacizumab and FOLFOX6, then received 50.4 Gy of radiation and concurrent bevacizumab (5 mg/kg on Days 1, 15, and 29), oxaliplatin (50 mg/m<sup>2</sup>/week for 6 weeks), and continuous infusion 5-FU (200 mg/m<sup>2</sup>/day). This trial was terminated early because of high incidence of significant grade 3 toxicity. Authors reported 19 (75%) of 25 patients experienced grade 3 toxicities. Five (20%) out of 25 patients had pathologic response. The effect of bevacizumab was also studied with erlotinib, a small molecule epidermal growth factor receptor tyrosine kinase inhibitor in a combination treatment of 5-fluorouracil and external beam radiation in 21 patients [70]. Seven (47%) of 15 patients who completed the therapy and had surgery achieved pathologic complete response. Reported toxicities were including lymphopenia 6 (40%), diarrhea 4 (24%), rash 2 (12%), cardiac ischemia 1(6%), transaminitis (6%) and mucositis (6%).

Obtained promising pathologic response and observed safety results by the addition of monoclonal antibodies in neoadjuvant chemoradiation encourages to further explore the role of these drugs in treatment of locally advanced rectal cancer. On the other hand these targeting agents are yet to be standard-care-of rectal cancer in neoadjuvant settings.

## 7. Conclusions

The clinical advances over the last two decades have led to demonstrable improvements in the outcomes of patients with colorectal cancer and are a testament to the success of multidisciplinary cancer care. Continued development of novel therapeutics in the metastatic setting will undoubtedly lead to changes in our surgical adjuvant treatments. Refinement in predictive and prognostic studies will allow us greater ability to tailor the appropriate therapy for patients, and allow for greater patient's participation in the shared decision process.

## Author details

I.H. Sahin and C.R. Garrett

University of Texas MD Anderson Cancer Center Houston, Texas, USA

## References

- [1] Siegel R, DeSantis C, Virgo K, Stein K, Mariotto A, Smith T, et al. Cancer treatment and survivorship statistics, 2012. CA: a cancer journal for clinicians. 2012 Jul-Aug; 62(4):220-41. PubMed PMID: 22700443.

- [2] Printz C. American Cancer Society reports progress in reducing cancer deaths. *Cancer*. 2011;117(20):4573-4.
- [3] Siegel RL, Jemal A, Ward EM. Increase in incidence of colorectal cancer among young men and women in the United States. *Cancer Epidemiology Biomarkers & Prevention*. 2009;18(6):1695-8.
- [4] Kopetz S, Chang GJ, Overman MJ, Eng C, Sargent DJ, Larson DW, et al. Improved survival in metastatic colorectal cancer is associated with adoption of hepatic resection and improved chemotherapy. *Journal of Clinical Oncology*. 2009;27(22):3677-83.
- [5] Chagpar R, Xing Y, Chiang YJ, Feig BW, Chang GJ, You YN, et al. Adherence to Stage-Specific Treatment Guidelines for Patients With Colon Cancer. *Journal of Clinical Oncology*. 2012;30(9):972-9.
- [6] Compton CC, Byrd DR, Garcia-Aguilar J, Kurtzman S, Olawaiye A, Washington MK. *AJCC Cancer Staging Atlas*: Springer; 2012.
- [7] Chu E. Ode to 5-Fluorouracil. *Clinical colorectal cancer*. 2007;6(9).
- [8] Moertel CG, Fleming TR, Macdonald JS, Haller DG, Laurie JA, Goodman PJ, et al. Levamisole and fluorouracil for adjuvant therapy of resected colon carcinoma. *New England Journal of Medicine*. 1990;322(6):352-8.
- [9] Moertel CG, Fleming TR, Macdonald JS, Haller DG, Laurie JA, Tangen CM, et al. Fluorouracil plus levamisole as effective adjuvant therapy after resection of stage III colon carcinoma: a final report. *Annals of internal medicine*. 1995;122(5):321.
- [10] Wolmark N, Rockette H, Fisher B, Wickerham DL, Redmond C, Fisher ER, et al. The benefit of leucovorin-modulated fluorouracil as postoperative adjuvant therapy for primary colon cancer: results from National Surgical Adjuvant Breast and Bowel Project protocol C-03. *Journal of Clinical Oncology*. 1993;11(10):1879-87.
- [11] Efficacy of intravenous continuous infusion of fluorouracil compared with bolus administration in advanced colorectal cancer. Meta-analysis Group In Cancer. *Journal of clinical oncology : official journal of the American Society of Clinical Oncology*. 1998 Jan;16(1):301-8. PubMed PMID: 9440757.
- [12] Twelves C, Wong A, Nowacki MP, Abt M, Burris III H, Carrato A, et al. Capecitabine as adjuvant treatment for stage III colon cancer. *New England Journal of Medicine*. 2005;352(26):2696-704.
- [13] Lembersky BC, Wieand HS, Petrelli NJ, O'Connell MJ, Colangelo LH, Smith RE, et al. Oral uracil and tegafur plus leucovorin compared with intravenous fluorouracil and leucovorin in stage II and III carcinoma of the colon: results from National Surgical Adjuvant Breast and Bowel Project Protocol C-06. *Journal of Clinical Oncology*. 2006;24(13):2059-64.
- [14] Haller D, Tabernero J, Maroun J, De Braud F, Price T, Van Cutsem E, et al. 5LBA First efficacy findings from a randomized phase III trial of capecitabine+ oxaliplatin vs.

bolus 5-FU/LV for stage III colon cancer (NO16968/XELOXA study). *EJC Supplements*. 2009;7(3):4-.

- [15] André T, Boni C, Mounedji-Boudiaf L, Navarro M, Tabernero J, Hickish T, et al. Oxaliplatin, fluorouracil, and leucovorin as adjuvant treatment for colon cancer. *New England Journal of Medicine*. 2004;350(23):2343-51.
- [16] De Gramont A, Boni C, Navarro M, Tabernero J, Hickish T, Topham C, et al., editors. Oxaliplatin/5FU/LV in adjuvant colon cancer: Updated efficacy results of the MOSAIC trial, including survival, with a median follow-up of six years. *ASCO Annual Meeting Proceedings J Clin Oncol*; 2007.
- [17] Goldberg RM, Tabah-Fisch I, Bleiberg H, de Gramont A, Tournigand C, Andre T, et al. Pooled analysis of safety and efficacy of oxaliplatin plus fluorouracil/leucovorin administered bimonthly in elderly patients with colorectal cancer. *Journal of Clinical Oncology*. 2006;24(25):4085-91.
- [18] Kuebler JP, Wieand HS, O'Connell MJ, Smith RE, Colangelo LH, Yothers G, et al. Oxaliplatin combined with weekly bolus fluorouracil and leucovorin as surgical adjuvant chemotherapy for stage II and III colon cancer: results from NSABP C-07. *Journal of clinical oncology*. 2007;25(16):2198-204.
- [19] Saltz LB, Cox JV, Blanke C, Rosen LS, Fehrenbacher L, Moore MJ, et al. Irinotecan plus fluorouracil and leucovorin for metastatic colorectal cancer. *New England Journal of Medicine*. 2000;343(13):905-14.
- [20] Douillard JY, Cunningham D, Roth A, Navarro M, James R, Karasek P, et al. Irinotecan combined with fluorouracil compared with fluorouracil alone as first-line treatment for metastatic colorectal cancer: a multicentre randomised trial. *The Lancet*. 2000;355(9209):1041-7.
- [21] Saltz LB, Niedzwiecki D, Hollis D, Goldberg RM, Hantel A, Thomas JP, et al. Irinotecan fluorouracil plus leucovorin is not superior to fluorouracil plus leucovorin alone as adjuvant treatment for stage III colon cancer: results of CALGB 89803. *Journal of Clinical Oncology*. 2007;25(23):3456-61.
- [22] Van Cutsem E, Labianca R, Bodoky G, Barone C, Aranda E, Nordlinger B, et al. Randomized phase III trial comparing biweekly infusional fluorouracil/leucovorin alone or with irinotecan in the adjuvant treatment of stage III colon cancer: PETACC-3. *Journal of Clinical Oncology*. 2009;27(19):3117-25.
- [23] Garrett CR, Eng C. Cetuximab in the treatment of patients with colorectal cancer. *Expert opinion on biological therapy*. 2011;11(7):937-49.
- [24] Hoda D, Simon GR, Garrett CR. Targeting colorectal cancer with anti-epidermal growth factor receptor antibodies: focus on panitumumab. *Therapeutics and clinical risk management*. 2008;4(6):1221.
- [25] Khambata-Ford S, Garrett CR, Meropol NJ, Basik M, Harbison CT, Wu S, et al. Expression of epiregulin and amphiregulin and K-ras mutation status predict disease

control in metastatic colorectal cancer patients treated with cetuximab. *Journal of Clinical Oncology*. 2007;25(22):3230-7.

- [26] Alberts SR, Sargent DJ, Nair S, Mahoney MR, Mooney M, Thibodeau SN, et al. Effect of Oxaliplatin, Fluorouracil, and Leucovorin With or Without Cetuximab on Survival Among Patients With Resected Stage III Colon Cancer A Randomized Trial. *JAMA: the journal of the American Medical Association*. 2012;307(13):1383-93.
- [27] Allegra CJ, Yothers G, O'Connell MJ, Sharif S, Petrelli NJ, Lopa SH, et al. Bevacizumab in Stage II-III Colon Cancer: 5-Year Update of the National Surgical Adjuvant Breast and Bowel Project C-08 Trial. *Journal of clinical oncology : official journal of the American Society of Clinical Oncology*. 2012 Dec 10. PubMed PMID: 23233715.
- [28] de Gramont A, Van Cutsem E, Schmoll HJ, Tabernero J, Clarke S, Moore MJ, et al. Bevacizumab plus oxaliplatin-based chemotherapy as adjuvant treatment for colon cancer (AVANT): a phase 3 randomised controlled trial. *Lancet Oncol*. 2012 Dec; 13(12):1225-33. PubMed PMID: 23168362.
- [29] Bertagnolli MM, Niedzwiecki D, Compton CC, Hahn HP, Hall M, Damas B, et al. Microsatellite instability predicts improved response to adjuvant therapy with irinotecan, fluorouracil, and leucovorin in stage III colon cancer: Cancer and Leukemia Group B Protocol 89803. *Journal of clinical Oncology*. 2009;27(11):1814-21.
- [30] Falcone A, Ricci S, Brunetti I, Pfanner E, Allegrini G, Barbara C, et al. Phase III trial of infusional fluorouracil, leucovorin, oxaliplatin, and irinotecan (FOLFOXIRI) compared with infusional fluorouracil, leucovorin, and irinotecan (FOLFIRI) as first-line treatment for metastatic colorectal cancer: the Gruppo Oncologico Nord Ovest. *Journal of Clinical Oncology*. 2007;25(13):1670-6.
- [31] Souglakos J, Androulakis N, Syrigos K, Polyzos A, Ziras N, Athanasiadis A, et al. FOLFOXIRI (folinic acid, 5-fluorouracil, oxaliplatin and irinotecan) vs FOLFIRI (folinic acid, 5-fluorouracil and irinotecan) as first-line treatment in metastatic colorectal cancer (MCC): a multicentre randomised phase III trial from the Hellenic Oncology Research Group (HORG). *British journal of cancer*. 2006;94(6):798-805.
- [32] Masi G, Loupakis F, Pollina L, Vasile E, Cupini S, Ricci S, et al. Long-term outcome of initially unresectable metastatic colorectal cancer patients treated with 5-fluorouracil/leucovorin, oxaliplatin, and irinotecan (FOLFOXIRI) followed by radical surgery of metastases. *Annals of surgery*. 2009;249(3):420-5.
- [33] Willett CG, Fung CY, Kaufman DS, Efird J, Shellito PC. Postoperative radiation therapy for high-risk colon carcinoma. *Journal of clinical oncology*. 1993;11(6):1112-7.
- [34] Martenson Jr JA, Willett CG, Sargent DJ, Mailliard JA, Donohue JH, Gunderson LL, et al. Phase III study of adjuvant chemotherapy and radiation therapy compared with chemotherapy alone in the surgical adjuvant treatment of colon cancer: results of intergroup protocol 0130. *Journal of clinical oncology*. 2004;22(16):3277-83.



- [35] Gray R, Barnwell J, McConkey C, Hills RK, Williams NS, Kerr DJ. Adjuvant chemotherapy versus observation in patients with colorectal cancer: a randomised study. *Lancet*. 2007;370(9604):2020.
- [36] Swanson RS, Compton CC, Stewart AK, Bland KI. The prognosis of T3N0 colon cancer is dependent on the number of lymph nodes examined. *Annals of surgical oncology*. 2003;10(1):65-71.
- [37] Le Voyer T, Sigurdson E, Hanlon A, Mayer R, Macdonald J, Catalano P, et al. Colon cancer survival is associated with increasing number of lymph nodes analyzed: a secondary survey of intergroup trial INT-0089. *Journal of Clinical Oncology*. 2003;21(15):2912-9.
- [38] Sargent DJ, Goldberg RM, Jacobson SD, Macdonald JS, Labianca R, Haller DG, et al. A pooled analysis of adjuvant chemotherapy for resected colon cancer in elderly patients. *New England Journal of Medicine*. 2001;345(15):1091-7.
- [39] Sargent DJ, Marsoni S, Monges G, Thibodeau SN, Labianca R, Hamilton SR, et al. Defective mismatch repair as a predictive marker for lack of efficacy of fluorouracil-based adjuvant therapy in colon cancer. *Journal of Clinical Oncology*. 2010;28(20):3219-26.
- [40] O'Connell M, Lavery I, Gray R, Quirke P, Kerr D, Lopatin M, et al., editors. Comparison of molecular and pathologic features of stage II and stage III colon cancer in four large studies conducted for development of the 12-gene colon cancer recurrence score. *J Clin Oncol (Meeting Abstracts)*; 2010.
- [41] Rosenberg R, Maak M, Nitsche U, Schuster T, Kuenzli B, Simon I, et al., editors. Independent validation of a prognostic genomic profile (ColoPrint) for stage II colon cancer (CC) patients. *J Clin Oncol (Meeting Abstracts)*; 2010.
- [42] Enríquez-Navascués JM, Borda N, Lizerazu A, Placer C, Elosegui JL, Ciria JP, et al. Patterns of local recurrence in rectal cancer after a multidisciplinary approach. *World journal of gastroenterology: WJG*. 2011;17(13):1674.
- [43] Rosen L, Veidenheimer MC, Collier JA, Corman ML. Mortality, morbidity, and patterns of recurrence after abdominoperineal resection for cancer of the rectum. *Diseases of the Colon & Rectum*. 1982;25(3):202-8.
- [44] Prolongation of the disease-free interval in surgically treated rectal carcinoma. Gastrointestinal Tumor Study Group. *The New England journal of medicine*. 1985 Jun 6;312(23):1465-72. PubMed PMID: 2859523. Epub 1985/06/06. eng.
- [45] Douglass Jr HO, Moertel CG, Mayer RJ, Thomas PRM, Lindblad AS, Mittleman A, et al. Survival after postoperative combination treatment of rectal cancer. *New England Journal of Medicine*. 1986;315(20):1294-5.
- [46] Fisher B, Wolmark N, Rockette H, Redmond C, Deutsch M, Wickerham DL, et al. Postoperative Adjuvant Chemotherapy or Radiation Therapy for Rectal Cancer: Re-

sults From NSABP Protocol R-011. Journal of the National Cancer Institute. 1988;80(1):21-9.

- [47] Krook JE, Moertel C, Wieand HS. Radiation vs sequential chemotherapy-radiation-chemotherapy. A study of North Central Cancer Treatment Group, Duke University and Mayo Clinic. Proceedings of the American Society of Clinical Oncology. 1988;5(82).
- [48] Improved survival with preoperative radiotherapy in resectable rectal cancer. Swedish Rectal Cancer Trial. The New England journal of medicine. 1997 Apr 3;336(14): 980-7. PubMed PMID: 9091798. Epub 1997/04/03. eng.
- [49] Peeters KCMJ, Marijnen CAM, Nagtegaal ID, Kranenbarg EK, Putter H, Wiggers T, et al. The TME trial after a median follow-up of 6 years: increased local control but no survival benefit in irradiated patients with resectable rectal carcinoma. Annals of surgery. 2007;246(5):693-701.
- [50] Stephens RJ, Thompson LC, Quirke P, Steele R, Grieve R, Couture J, et al. Impact of short-course preoperative radiotherapy for rectal cancer on patients' quality of life: data from the Medical Research Council CR07/National Cancer Institute of Canada Clinical Trials Group C016 randomized clinical trial. Journal of Clinical Oncology. 2010;28(27):4233-9.
- [51] Sauer R, Becker H, Hohenberger W, Rödel C, Wittekind C, Fietkau R, et al. Preoperative versus postoperative chemoradiotherapy for rectal cancer. New England Journal of Medicine. 2004;351(17):1731-40.
- [52] Bosset JF, Calais G, Mineur L, Maingon P, Radosevic-Jelic L, Daban A, et al. Enhanced tumorocidal effect of chemotherapy with preoperative radiotherapy for rectal cancer: preliminary results--EORTC 22921. Journal of clinical oncology : official journal of the American Society of Clinical Oncology. 2005 Aug 20;23(24):5620-7. PubMed PMID: 16009958. Epub 2005/07/13. eng.
- [53] Bosset JF, Collette L, Calais G, Mineur L, Maingon P, Radosevic-Jelic L, et al. Chemotherapy with preoperative radiotherapy in rectal cancer. The New England journal of medicine. 2006 Sep 14;355(11):1114-23. PubMed PMID: 16971718. Epub 2006/09/15. eng.
- [54] Roh MS, Colangelo LH, O'Connell MJ, Yothers G, Deutsch M, Allegra CJ, et al. Preoperative multimodality therapy improves disease-free survival in patients with carcinoma of the rectum: NSABP R-03. Journal of clinical oncology : official journal of the American Society of Clinical Oncology. 2009 Nov 1;27(31):5124-30. PubMed PMID: 19770376. Pubmed Central PMCID: 2773471. Epub 2009/09/23. eng.
- [55] O'Connell MJ, Martenson JA, Wieand HS, Krook JE, Macdonald JS, Haller DG, et al. Improving adjuvant therapy for rectal cancer by combining protracted-infusion fluorouracil with radiation therapy after curative surgery. The New England journal of medicine. 1994 Aug 25;331(8):502-7. PubMed PMID: 8041415. Epub 1994/08/25. eng.

- [56] Ngan SY, Michael M, Mackay J, McKendrick J, Leong T, Lim Joon D, et al. A phase I trial of preoperative radiotherapy and capecitabine for locally advanced, potentially resectable rectal cancer. *British journal of cancer*. 2004 Sep 13;91(6):1019-24. PubMed PMID: 15305186. Pubmed Central PMCID: 2747703. Epub 2004/08/12. eng.
- [57] Kim JC, Kim TW, Kim JH, Yu CS, Kim HC, Chang HM, et al. Preoperative concurrent radiotherapy with capecitabine before total mesorectal excision in locally advanced rectal cancer. *International journal of radiation oncology, biology, physics*. 2005 Oct 1;63(2):346-53. PubMed PMID: 15913913. Epub 2005/05/26. eng.
- [58] Hofheinz RD, Wenz F, Post S, Matzdorff A, Laechelt S, Hartmann JT, et al. Chemoradiotherapy with capecitabine versus fluorouracil for locally advanced rectal cancer: a randomised, multicentre, non-inferiority, phase 3 trial. *The lancet oncology*. 2012 Jun; 13(6):579-88. PubMed PMID: 22503032. Epub 2012/04/17. eng.
- [59] Roh MS, Yothers GA, O'Connell MJ, Beart W, Pitot HC, Shields AF, et al. The impact of capecitabine and oxaliplatin in the preoperative multimodality treatment in patients with carcinoma of the rectum: NSABP R-04. *J Clin Oncol* 29: 2011 (suppl; abstr 3503) 2011.
- [60] Rodel C, Liersch T, Hermann RM, Arnold D, Reese T, Hipp M, et al. Multicenter phase II trial of chemoradiation with oxaliplatin for rectal cancer. *Journal of clinical oncology : official journal of the American Society of Clinical Oncology*. 2007 Jan 1;25(1):110-7. PubMed PMID: 17194912. Epub 2006/12/30. eng.
- [61] Goldberg RM, Sargent DJ, Morton RF, Fuchs CS, Ramanathan RK, Williamson SK, et al. A randomized controlled trial of fluorouracil plus leucovorin, irinotecan, and oxaliplatin combinations in patients with previously untreated metastatic colorectal cancer. *Journal of clinical oncology : official journal of the American Society of Clinical Oncology*. 2004 Jan 1;22(1):23-30. PubMed PMID: 14665611. Epub 2003/12/11. eng.
- [62] Aschele C, Cionini L, Lonardi S, Pinto C, Cordio S, Rosati G, et al. Primary tumor response to preoperative chemoradiation with or without oxaliplatin in locally advanced rectal cancer: pathologic results of the STAR-01 randomized phase III trial. *Journal of clinical oncology : official journal of the American Society of Clinical Oncology*. 2011 Jul 10;29(20):2773-80. PubMed PMID: 21606427. Epub 2011/05/25. eng.
- [63] Rodel C, Liersch T, Becker H, Fietkau R, Hohenberger W, Hothorn T, et al. Preoperative chemoradiotherapy and postoperative chemotherapy with fluorouracil and oxaliplatin versus fluorouracil alone in locally advanced rectal cancer: initial results of the German CAO/ARO/AIO-04 randomised phase 3 trial. *The lancet oncology*. 2012 Jul;13(7):679-87. PubMed PMID: 22627104. Epub 2012/05/26. eng.
- [64] Gerard JP, Azria D, Gourgou-Bourgade S, Martel-Laffay I, Hennequin C, Etienne PL, et al. Comparison of two neoadjuvant chemoradiotherapy regimens for locally advanced rectal cancer: results of the phase III trial ACCORD 12/0405-Prodige 2. *Journal of clinical oncology : official journal of the American Society of Clinical*

Oncology. 2010 Apr 1;28(10):1638-44. PubMed PMID: 20194850. Epub 2010/03/03. eng.

- [65] Machiels JP, Sempoux C, Scalliet P, Coche JC, Humblet Y, Van Cutsem E, et al. Phase I/II study of preoperative cetuximab, capecitabine, and external beam radiotherapy in patients with rectal cancer. *Annals of oncology : official journal of the European Society for Medical Oncology / ESMO*. 2007 Apr;18(4):738-44. PubMed PMID: 17208931. Epub 2007/01/09. eng.
- [66] Dewdney A, Cunningham D, Tabernero J, Capdevila J, Glimelius B, Cervantes A, et al. Multicenter randomized phase II clinical trial comparing neoadjuvant oxaliplatin, capecitabine, and preoperative radiotherapy with or without cetuximab followed by total mesorectal excision in patients with high-risk rectal cancer (EXPERT-C). *Journal of clinical oncology : official journal of the American Society of Clinical Oncology*. 2012 May 10;30(14):1620-7. PubMed PMID: 22473163. Epub 2012/04/05. eng.
- [67] Willett CG, Duda DG, di Tomaso E, Boucher Y, Ancukiewicz M, Sahani DV, et al. Efficacy, safety, and biomarkers of neoadjuvant bevacizumab, radiation therapy, and fluorouracil in rectal cancer: a multidisciplinary phase II study. *Journal of clinical oncology : official journal of the American Society of Clinical Oncology*. 2009 Jun 20;27(18):3020-6. PubMed PMID: 19470921. Pubmed Central PMCID: 2702234. Epub 2009/05/28. eng.
- [68] Crane CH, Eng C, Feig BW, Das P, Skibber JM, Chang GJ, et al. Phase II trial of neoadjuvant bevacizumab, capecitabine, and radiotherapy for locally advanced rectal cancer. *International journal of radiation oncology, biology, physics*. 2010 Mar 1;76(3):824-30. PubMed PMID: 19464823. Epub 2009/05/26. eng.
- [69] Dipetrillo T, Pricolo V, Lagares-Garcia J, Vrees M, Klipfel A, Cataldo T, et al. Neoadjuvant bevacizumab, oxaliplatin, 5-fluorouracil, and radiation for rectal cancer. *International journal of radiation oncology, biology, physics*. 2012 Jan 1;82(1):124-9. PubMed PMID: 20947267. Epub 2010/10/16. eng.
- [70] Blaszkowsky LS, Hong TS, Zhu AX, Kwak EL, Mamon HJ, Shellito PC, et al. A phase I/II study of bevacizumab (beva), erlotinib (erl), and 5-fluorouracil (5-FU) with concurrent external beam radiation therapy (RT) in locally advanced rectal cancer (LARC). *Journal of Clinical Oncology*. 2009;suppl: abstract 4106.

