

We are IntechOpen, the world's leading publisher of Open Access books Built by scientists, for scientists

6,900

Open access books available

186,000

International authors and editors

200M

Downloads

Our authors are among the

154

Countries delivered to

TOP 1%

most cited scientists

12.2%

Contributors from top 500 universities



WEB OF SCIENCE™

Selection of our books indexed in the Book Citation Index
in Web of Science™ Core Collection (BKCI)

Interested in publishing with us?
Contact book.department@intechopen.com

Numbers displayed above are based on latest data collected.
For more information visit www.intechopen.com



Application of Diffusion- and Perfusion- Weighted Imaging in Acute Ischemic Stroke

Vincent Lai

Additional information is available at the end of the chapter

<http://dx.doi.org/10.5772/30857>

1. Introduction

Stroke is one leading cause of morbidity and mortality worldwide, with acute ischemia constituting approximately 80% of all cases (Srinivasan et al. 2006). In the past imaging was primarily used to exclude hemorrhage and other causes. Yet diagnostic classification and clinical prognosis are major challenges in acute stroke. This is of particular importance since the approval of intravenous tissue plasminogen activator therapy for acute ischemic stroke within a narrow therapeutic window of 4.5 hours (Hacke et al. 2008; Wahlgren et al. 2008). It then becomes clear that advance imaging techniques would be much needed to identify this subgroup of patient who could be beneficial for thrombolytic therapy.

Computed tomography (CT) scan has been the traditional method for acute stroke imaging with excellent sensitivity for acute intracerebral hemorrhage, but demonstrates limited sensitivity for detection of ischemic infarction, with a reported sensitivity of 40-60% only within 6 hours of onset, and a negative predictive value of 17% (von Kummer et al. 2001). Magnetic resonance (MR) imaging has no doubt superior spatial and contrast resolution as compared with CT, achieving higher sensitivity and accuracy. It has even emerged over last few years to become as sensitive as CT in depiction of acute intracranial hemorrhage (Fiebach et al. 2004; Kidwell et al. 2004). Perfusion-weighted imaging (PWI) and diffusion-weight imaging (DWI) had played an influencing role since their introduction in late 1980s. Application DWI and PWI offer complex information regarding infarction and perfusion deficits, significantly improving the diagnostic yield. In a recent meta-analysis, Schellinger et al. (2010) found that the ability to correctly diagnose acute ischemic stroke on MR was significantly higher than CT, demonstrating an odds ratio of 25 ($p < 0.0001$; confidence interval: 8-79). It also brings forward the concept of salvageable brain tissue as indicated by penumbra which is a rather dynamic entity that exists within a narrow range of perfusion pressures, carrying

significant implication on therapy selection and prediction of clinical outcome. The goal is to salvage the ischemic but viable penumbral tissue from progression into infarction.

2. Diffusion-weighted imaging

In DWI, the random motion or diffusion pulse of water molecules in a tissue compartment through a magnetic field gradient causes phase shifting leading to intravoxel dephasing and hence loss of signal intensity (Poustchi-Amin et al. 2001). In region of acute infarct or irreversible ischemia, the decreased diffusion of water molecules due to presence of cytotoxic edema (neuronal and glial cell swelling) from intracellular water accumulation and disruption of membrane ionic homeostasis will manifest as an increase in signal intensity, reflecting a decrease in apparent diffusion coefficient (ADC). ADC is “apparent” only because the actual measurement cannot be obtained by DWI due to presence of unmeasured variables that influence the rate of diffusion, such as temperature of the tissue and actual route of the diffusing molecule. Images are acquired sequentially with the axis of diffusion sensitization in three orthogonal planes, with their average yielding an image with minimal anisotropy-related hyperintensity. As a result, infarcted tissue appears bright in comparison with normal brain tissue. This has significant impact in helping to identify area of acute ischemia from chronic ischemic, and hence stratify treatment plan.

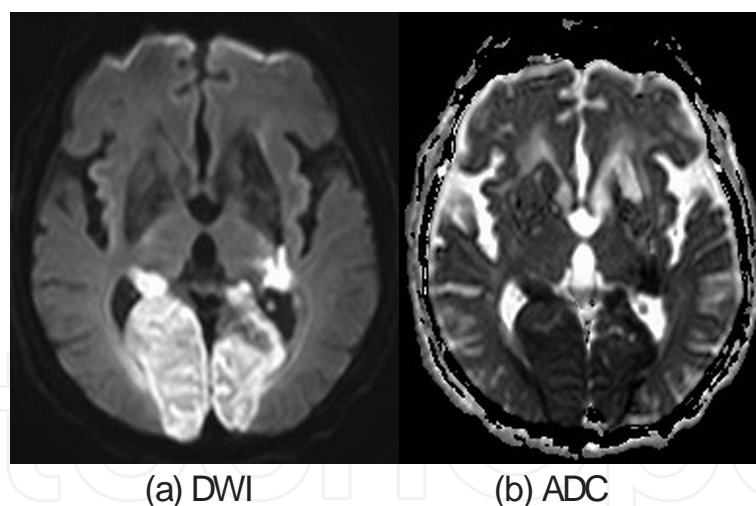


Figure 1. a) DWI shows hyperintense signal along bilateral posterior cerebral arterial territories. b) corresponding ADC map demonstrates hypointense signal.

In human, restricted diffusion showing increased DWI signal with reduced ADC value (Figure 1) have been observed as early as 30 minutes after onset of ischemia (Srinivasan et al. 2006). ADC continues to decrease for 3-5 days, reaching its minimum value of about 50% between 24-48 hours after symptoms onset before returning to baseline at approximately 1-4 weeks, so called pseudonormalization. At this stage, mildly hyperintense DWI signal with normalized ADC value will be seen. ADC increases afterwards with value higher than

normal value associated with variable DWI signal (from T2 effect) for upto months, presumably related to increased quantity of extracellular water. It is important to note that DWI signal can remain hyperintense for a long period (initially due to restricted diffusion but latter due to T2 shine-through effect) and cannot reliably estimate infarct age alone, while reduced ADC value almost always point to acute infarction. Yet, tissue with very low ADC value may recover and no single threshold can distinguish salvageable from unsalvageable tissue (Fiehler et al. 2002). Therefore we must interpret DWI with ADC maps together cautiously.

DWI-ADC carries high sensitivity (88-100%) and specificity (86-100%) in depiction of acute ischemia (Beaulieu et al. 1999; Gonzalez et al. 1999; Lövblad et al. 1997, 1998). However, with increasing cases of DWI-negative stroke reported and bearing in mind the existence of patient selection bias in the reported series, the true sensitivity probably lies between 80%-90% in general (Schellinger et al. 2010). In a prospective randomized study comparing between DWI and CT scan in evaluation of acute ischemic stroke, Fiebach et al. (2002) reported that the sensitivity of infarct detection was significantly better based on DWI (91%) than on CT (61%), achieving good interrater homogeneity and better accuracy even for readers with limited experience. This is due to relative insensitivity of CT for ischemia beyond 10ml per 100/min. as compared with DWI (Barber et al. 1999). False negative is unusual but is generally more common in posterior fossa stroke (Oppenheim et al. 2000) due to the presence of susceptibility artifacts from basal skull. Risk of hemorrhagic transformation is one feared complication and frequently asked question, especially when thrombolysis is contemplated. It had been postulated that a DWI lesion volume $> 100\text{cm}^3$ was highly associated with hemorrhagic transformation, in particular when there was no associated DWI-PWI mismatch, hence contraindication to thrombolysis. However this would require further study for confirmation. Mixed results had been shown regarding the accuracy of baseline DWI in determination of final infarct volume. While it was widely thought that it would underestimate the final size of infarction (Yamada et al. 2002), Warach et al. (2000) in his double-blinded placebo-controlled study involving patients suffering from anterior-circulation stroke syndromes, found that baseline DWI lesion volume significantly correlated with baseline National Institute of Health Stroke Scale (NIHSS) scores and follow-up lesion volume at 12 weeks. Therefore, it is well established that DWI is accurate and superior to CT for diagnosis of acute ischemic stroke and can probably predict baseline clinical stroke severity as well as final lesion volume.

3. Perfusion-weighted imaging

PWI provides information on hypoperfused area and momentary hemodynamic state of the brain tissue before structural brain tissue damage, therefore to identify areas of reversible ischemia early before it progresses to permanent infarction. It can be performed by exogenous method (dynamic or steady state susceptibility contrast-enhanced MR imaging by injection of MR contrast) or by endogenous method (arterial spin labeling by magnetically tagging water protons in arterial blood).

3.1. Mechanism

Dynamic susceptibility contrast-enhanced MR perfusion imaging involves rapid imaging with gradient echo or spin echo echo-planar imaging during the first passage of a paramagnetic contrast agent through the entire brain. 10 to 20 brain slices are usually repeatedly imaged immediately before and for 70 to 80 seconds after contrast injection, with 20 to 40 images per slice obtained. It makes use of the tissue signal changes caused by susceptibility ($T2^*$) effects to generate signal drop (shortening of $T2$ and $T2^*$) and creates a hemodynamic time-signal intensity curve for each voxel, which in turns depends on cerebral blood volume and cerebral blood flow (Seevinck et al. 2010). It is through the dynamic monitoring of these signal changes in perfused tissue that hemodynamic parameters can be estimated. In contrary, steady state susceptibility contrast-enhanced MR perfusion allows estimation of blood volume, microvessel density and vessel size from the contrast-induced signal changes. Spin echo and gradient echo transverse relaxation rates are measured before and after contrast injection, typically with use of ultrasmall superparamagnetic iron oxide particles (longer half-life and higher susceptibility difference) from which parameters are derived (Wu EX et al. 2004). This method however is mainly of use in research level only.

Quantification depends on measuring the signal intensity change within tissues which itself is the susceptibility effect of the contrast agent. The ram images are processed on a pixel-by-pixel basis to generate perfusion maps of different parameters. Time-to-peak (TTP) can be readily obtained by simple data processing from the tissue response curve. Cerebral blood flow (CBF), cerebral blood volume (CBV) and mean transit time (MTT) are time dependent parameters requiring utilization of computational deconvolution methods (such as singular value decomposition, circular value decomposition, Fourier transformation) with knowledge of arterial input function for quantification. The arterial input function is defined under visual control by drawing 5-10 intravascular voxels within the proximal & distal segments of the concerned artery of the unaffected hemisphere (Zaro-Weber et al. 2010a). Point to note is that these are relative values only due to variable confounding factors which will be discussed in later section.

Arterial spin labeling is a non-invasive method exploiting the spins of endogenous water protons to measure perfusion without the need of gadolinium. An inversion radiofrequency pulse is used to tag & invert the spin polarity of the flowing arterial protons with respect to stationary arterial proton, at a level proximal to the imaging slab (Deibler et al. 2008). The tagged spins then enter the imaging plane and exchange with tissue, allowing pair-wise subtraction to yield the perfusion map after acquisition of multiple runs for signal intensity averaging. The detected MR signals would be analyzed and perfusion parameters can be obtained. However, it has a low signal-to-noise ratio requiring longer imaging time.

3.2. Image analysis

Perfusion imaging is the method of choice for demonstrating ischemic brain tissue in hyperacute stage of stroke. The central portion with maximal perfusion abnormality will progress irreversibly to infarction while the outer area with only slight perfusion abnormality may recover (Hossmann 1994; Rohl et al. 2001). No single threshold has thus far been able to reliably

discriminate salvageable from unsalvageable tissue definitely (Wu O et al. 2006) since absolute quantification of cerebral perfusion is not really possible and perfusion thresholds change with time (Butcher et al. 2003). Interpretation is based on the concept that as CBF falls, CBV is initially unchanged or increased (from vasodilatation due to autoregulation) in conjunction with prolonged MTT and TTP. If such autoregulatory mechanism is exhausted, CBV will then decrease and CBF continues to fall to a level of irreversible ischemia with eventual infarction. Therefore a mismatch between MTT/TTP and CBV or CBF map indicates presence of potentially salvageable tissue (Figure 2).

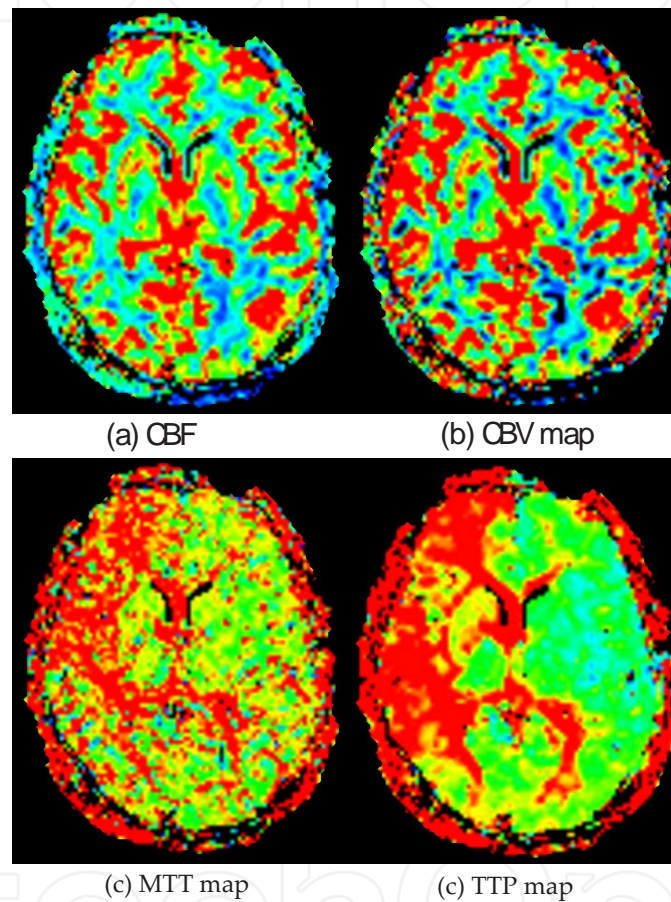


Figure 2. Patient with right internal carotid artery (ICA) occlusion shows mild reduced a) CBF & b) CBV; but marked elevated c) MTT & d) TTP along right ICA territory.

3.3. Parameters threshold

Depending on different processing methods, differing results regarding the reliability and threshold of each parameter resulted. MTT or TTP delay relative to the contralateral hemisphere has been used in preference to CBF & CBV because of the more conspicuous changes and better correlation with initial stroke severity and change in infarct size, hence final functional outcomes in individual patient (Kane et al. 2007; Muir et al. 2006). In the contrary, pre-treatment lesions on DWI and ADC maps were non-discriminative.

3.3.1. Time-to-peak (TTP)

Restrepo et al. (2004) found that TTP map was most useful in demonstrating perfusion changes, showing good signal-to-noise ratio facilitating identification of lesion boundary, rendering it a parametric surrogate marker for efficacy of acute stroke treatment. A perfusion delay of 6 seconds relative to the non-affected hemisphere on TTP maps acquired before the initiation of stroke treatment helped predict the lesion size on T2-weighted images on day 8 irrespective of the treatment regimen (Kidwell et al. 2002; Nighoghossian et al. 2003; Seitz et al. 2005). Neumann-Haefelin et al. (1999) reported a TTP delay of >6 seconds best predicted final infarct volume while a TTP delay >4 seconds correlated best with acute stage neurologic deficit, signifying the true penumbra lies between 4 to 6 seconds. Kajimoto et al. (2003) depicted same result with a TTP delay of >4 seconds (sensitivity 79%, specificity 96%) in his study evaluating patients with chronic stroke. Sobesky et al. (2004 & 2005) validated these threshold values in patients with acute stroke, and demonstrated matched results when comparing with PET-derived data, also showing a TTP delay threshold of >4 seconds with sensitivity of 84% & specificity of 77%, and a penumbral volume threshold of >6 seconds. Takasawa et al. (2008) later reported a TTP delay threshold of >4.8 seconds which is also similar, as supported more recently, by Zaro-Weber et al. (2010a) showing a TTP delay threshold of >4.2 seconds best predicted penumbral flow, with a sensitivity of 91% and specificity of 82%. These consistent findings strengthen the TTP delay threshold to lie between >4-5 seconds.

3.3.2. Mean transit time (MTT)

Grandin et al. (2001 & 2003) reported a MTT delay of 8.1 seconds best predicted infarct growth whereas a MTT delay of 5.3 seconds defined the hypoperfused area that did not progress to infarction, to indicate oligemic tissue. Yamada et al (2002) supported the accuracy of MTT maps showing a sensitivity of 85-94% and positive predictive value of 54-61% for final infarct volume. Such results were in coherent with other studies, with Parsons et al. (2002) depicting a >6 seconds threshold, Bristow et al. (2005) depicting a >7seconds threshold, Takasawa et al. (2008) depicting a > 6-7 seconds threshold, and more recently, Zaro-Weber (2010a) demonstrating a >5.3 seconds threshold with a sensitivity of 88% & specificity of 78%. Therefore, we can conclude that a MTT delay between 5.3 -8.1 seconds denotes the true penumbra.

3.3.3. Cerebral blood flow (CBF)

CBF has found to be a good indicator of penumbral flow. Early study by Liu et al. (2000) revealed a cut off value of 48% of the unaffected hemisphere for depiction of penumbral flow. From positron emission tomography (PET) scan, it was found that neurological dysfunction occurred after CBF dropped below 20mL/100g of brain tissue per minute while infarction occurred shortly after CBF dropped below 10mL/100g of brain tissue per minute (Latchaw et al. 2003). Zaro-Weber et al. confirmed in two of his recent trials (2009 & 2010a) that threshold values of <20mL/100g/min (sensitivity 76%, specificity 96%) and <21.7mL/100g/min (sensitivity 89%, specificity 87%) respectively were of best estimate of penumbral flow, adding to its consistency and strength in validation. Therefore, a CBF between 10 -20mL/100g of brain tissue per minute becomes the intermediate zone and represents penumbral flow.

3.3.4. Cerebral blood volume (CBV)

CBV shows the least correlation with penumbral flow with limited studies validating its penumbral threshold level in past literatures, especially in comparison with PET. Liu et al. (2000) depicted the threshold level to be 87% of the unaffected hemisphere while Hatazawa et al. (1999) found the threshold level to be 85% in their studies comparing with single photon emission CT (SPECT). Zaro-Weber et al. (2010a) recently, in the only study comparing with PET, found the penumbral threshold flow at $<1.5\text{mL}/100\text{g}$ with a sensitivity of 82% and specificity of 79%.

4. Diffusion-weighted — Perfusion-weighted imaging

Ischemia is a complex and multifactorial process. Its clinical severity on initial presentation is a major determinant of clinical outcome, correlating strongly with the extent of the lesion. Proportion of patients with diffusion/perfusion mismatch and its size will depend on the severity of stroke and time delay to imaging. Based on the heterogeneity of the ADC and PWI values in depiction of ischemic lesion (Bandera et al. 2006), as well as occasional recovery of DWI-abnormal tissue (Davis & Donnan 2005), it becomes clear that it is unlikely any single DWI or PWI parameters or threshold values will reliably predict the degree of ischemia or infarct. Combination of diffusion- and perfusion-weighted imaging has revolutionized acute stroke imaging, allowing early & accurate delineation of the actual ischemic lesion or penumbra. Diffusion-perfusion mismatch is a quantitative and reliable measure with important pathophysiologic & therapeutic implications, becoming the surrogate of ischemic penumbra that provides valuable information for neurointervention planning, especially within the crucial therapeutic window. The Desmoteplase for Acute Ischemic Stroke and Dose Escalation of Desmoteplase for Acute Ischemic Stroke studies demonstrated that patients with PWI-DWI mismatches who were treated with desmoteplase experienced higher rate of reperfusion and better clinical outcome (Furlan et al. 2006; Hacke et al. 2005). Earlier studies by Parsons et al. (2001 & 2002) demonstrated greater recanalization, reperfusion and penumbral salvage in a group of patients with DWI-PWI mismatch compared with the control group in acute stroke patients treated with intravenous tissue plasminogen activator. Luby & Warach (2007) also found that mismatch volumes can provide highly reliable and consistent results with improved sensitivity. Early PWI lesions are typically larger than early DWI lesions. Finding of normal diffusion-weighted images and altered perfusion parameters (mismatch) is a simple and practical mean to define the tissue at risk, which correlates with poor clinical outcome (Derex et al. 2004; Parsons et al. 2002). If untreated or reperfusion does not occur, progressive enlargement of the DWI lesion over time is expected, signifying progressive infarction of the initial PWI lesion. This can be rapid in patient with poor collateral circulation. Conversely, a pattern of DWI lesion equaling the volume of PWI lesion indicates absence of penumbra or no salvageable tissue.

5. Reliability and pitfalls

The reliability of mismatch volume and percentage of measurements had been discussed though not extensively investigated. Obtaining precise parameters is one major problem as only the “relative” but not absolute perfusion changes can be measured due to presence of significant confounding factors, hence nowadays we mostly rely on the relative maps of perfusion. So, exactly how precise can the penumbral threshold be quantitatively estimated by CBF, CBV, TTP and MTT? What are the overall accuracy, reproducibility and reliability?

Firstly, perfusion imaging is sensitive to vascular delays (tracer arrival delay and tissue transit time) and dispersion effects (Calamante et al. 2002), especially in the derivation of the nondeconvoluted TTP map. Any minor physiologic change such as heart rate and cardiac output can potentially change the mismatch zone. Lack of standardization between MR machines, measurement technique or associated errors from pulse sequence parameters, image processing and analytic software are other major concerns. Measurement of arterial input function is particularly problematic with lack of standardized protocol in measurement of signal intensity around the artery. Besides, the tissue signal intensity does not demonstrate a linear relationship to tissue contrast concentration (Latchaw et al. 2003). Past studies attempted to optimize perfusion maps by venous output function (Knutsson et al. 2007), separated measurement of CBV (Newman et al. 2003), advanced mathematical correction (van Osch et al. 2003), partial volume artifact correction, and bulk-blood correction (Zaharchuk et al. 2009) but were found technically difficult requiring further validation.

We have to understand that considerable individual variation regarding the penumbral flow exists and absolute quantification of the perfusion maps is difficult. So far, perfusion maps had been mainly validated with respect to infarct delineation on follow-up MR imaging but with uncertainty of perfusion changes during the time interval in between (Zaro-Weber et al. 2010a). Improved validation had been made by direct comparison with PET for in vivo perfusion measurement in normal subjects and chronic cerebrovascular disease, but with only few in acute stroke setting (Grandin et al. 2005; Ibaraki et al. 2007; Lin et al. 2001; Ostergaard et al. 1998; Tanaka et al. 2006), raising uncertainty that such values may not precisely demonstrate the exact tissue at greatest risk of infarction, hence leading to misleading & unreliable interpretation (Keir & Wardlaw 2000). Despite so, PET-based calibration of perfusion imaging demonstrated superior result with best correction of the absolute perfusion values. Nevertheless, different post-processing algorithms differ, producing variations in lesion size and measured parameters. Indeed, ideal technique of perfusion imaging and its post-processing have not yet established. Zaro-Weber et al. (2010b) found that the variation of penumbral flow for each patient was high and hence with great error, emphasizing the need for an individual correction procedure or calibration with independent cohort. In a later study, he also found that the mean flow rate on contralateral hemisphere well explained the variability of individual perfusion thresholds such that it could be used to yield the best estimate of penumbral threshold. Based on these, a PET-validated look-up table was derived to calibrate the best individual penumbral threshold from the values of the contralateral hemispheric reference, allowing a much improved volumetric congruence. Linear regression analysis demonstrated

best agreement for TTP and good agreement for CBF and MMT while that for CBV was less pronounced. Despite this seemingly advantage, further validation (especially in an independent cohort) will be needed before its implementation in clinical use. In the meantime, standardization in both the data processing methods and software is also much needed. A consensus on which parameter is best to be used for prediction should also be made.

Arterial spin labeling has additional limitation regarding its own method, in that assumptions on tagging efficiency, delay time to imaging and flow quantification are based on normal population. Whether the same setting can be translated to various disease states has yet to be tested properly (Deibler et al. 2008). Besides, it has a relatively low signal-to-noise ratio, further adding to uncertainty in its accuracy. Therefore dynamic contrast enhanced susceptibility MR imaging technique is still the preferred method for quantitative perfusion imaging.

6. Transient ischemic attack

Transient ischemic attack should not be taken lightly as it carries a subsequent risk of ischemic stroke of 10% within 7 days and 30% within 90 days of symptoms onset, in particularly during the first 48 hours (Johnston et al. 2000; Mlynash et al. 2009). Subsequent risk of myocardial infarction, arrhythmia and congestive heart failure are increased. Hence appropriate prevention strategy is important in reducing the risk.

Establishment of the diagnosis of transient ischemic attack has been a major challenge since most patient present normal neurologically with resolution of the clinical deficit at the time of consultation and imaging, resulting in negative finding on conventional MR brain imaging. DWI & PWI can provide objective measurement of brain ischemia, even better than angiography as lesions are mostly small and may reflect occlusion of distal intracranial vessels that is angiographically occulted. Past studies demonstrated variable lesion depiction rate from 16 to 67% on DWI in patients with TIA (Crisostomo et al. 2003; Kastrup et al. 2002; Kidwell et al. 1999; Krol et al. 2005; Redgrave et al. 2007; Restrepo et al. 2004; Rovira et al. 2002) but it had been argued that these patients should be labeled as ischemic stroke with infarction rather, regardless of the duration of symptoms with a clinical implication of potential poorer clinical outcome. This was still much debatable as report had described complete resolution of both DWI and PWI abnormalities on follow-up images (Kidwell et al. 1999; Neumann-Haefelin et al. 2000; Rovira et al. 2002). Initial studies had also found that approximately one-thirds of the DWI lesions would normalized to a certain degree if they were imaged within a 3 hour time window (Fiehler et al. 2002; Kidwell et al. 2000). PWI should substantiate the yield given its ability to reveal hypoperfusion accompanying or preceding development of DWI abnormalities. Nevertheless, the occurrence of patients with positive PWI and negative DWI was variable, reported to be 3 to 33% (Krol et al. 2005; Mlynash et al. 2009; Restrepo et al. 2004). Ma et al. (2009) explained in his study model that the classical mismatch pattern would fragment with time due to a number of more random events such as variable ages & composition of the clots, random locations of vessel occlusion with consequent differences in vulnerability of tissue, and variable degree of collateralization from neighboring vessels.

Therefore, the yield is expected to be >50% if such patients are scanned urgently after symptom onset. It is useful in helping to identify a subset of patients with diffusion-perfusion mismatch who would require close observation, and possible further investigation such as angiography assessment which would then have a high yield (>50%) for detection of potentially relevant lesion, hence to assist in subsequent management. It helps to differentiate those that who are likely to improve or reverse spontaneously from those who are likely to progress.

7. Clinical impact

There is no true imaging gold standard in acute stroke. DWI has a well established role in depiction of acute infarction while it is also clear that perfusion imaging can provide information that cannot be depicted in other techniques, thus seemingly superior. After all, is there a role for perfusion imaging in affecting clinical decision making and hence, influencing patient outcomes? Previously, we have already discussed that perfusion-diffusion mismatch correlates with poor clinical outcome and that treatment of large perfusion-diffusion mismatch can result in improved clinical outcome. Such can lead to the attracting prospect of expanding the narrow therapeutic time window by selecting eligible patients via DWI-PWI mismatch, as demonstrated in various series & trials (Albers et al. 2006; Davis et al. 2008; Furlan et al. 2006; Hacke et al. 2005 & 2009; Parsons et al. 2002; Schellinger et al. 2007), but with lack of proper prospective study or strong evidence-based validation so far to support its role in alteration of patient outcomes. Beside, the exact role of perfusion imaging was often vague and its benefits in decision making were usually under-evaluated or retrospectively compared with clinical parameters only (Provenzale et al. 2008). Further, it is not yet established that patients without mismatch will be unresponsive to thrombolysis, since DWI lesions can potentially resolve as discussed previously. More importantly, nowadays in most stroke centers, decisions for administration of thrombolytic agents in patients suffering from acute ischemic stroke are often made without prior perfusion imaging, nor even diffusion imaging. Decisions are routinely made on clinical ground in particular for those presenting at <4.5 hours, raising doubts over its added value. This is perhaps the main reason for lack of literature addressing the influencing role of perfusion imaging in decision making of thrombolysis. In addition, the feasibility and practicality of MR imaging in acute stroke assessment are always in doubt. Clearly, time is an important factor. The whole process of perfusion imaging together with subsequent data analysis can be time-consuming especially in less experience hands. After all, routine use of PWI to assess acute ischemic stroke is open to dispute. Until we have a compelling randomized prospective blinded study assessing the efficacy of perfusion imaging in decision making in assessment of acute ischemic stroke, perhaps the most convincing role at present is prediction of final infarct volume which demonstrates strong correlation, and hence helping to predict the clinical outcome in individual patient. On the other hand, it can also be of great use in monitoring of evolution of ischemia and subsequent therapeutic response. Despite these seemingly limitations and arguments on methodical issues, many believe that the accumulated evidence of the importance of DWI-PWI mismatch is already good enough to establish a role in daily practice if allow.

8. Conclusion

With advances in imaging technology, there is substantial evidence and data to support the feasibility & superiority of MR imaging in acute ischemic stroke. PWI is complementary to DWI in acute stroke assessment. DWI-PWI mismatch provides a good, rapid & reliable estimation of the penumbra, helping to select suitable candidate for acute thrombolytic therapy, especially for patients presenting with unknown onset time or beyond the 4.5 hours therapeutic window. PWI lesion can resolve rapidly after successful thrombolysis or reperfusion, leading to improved clinical outcome. Only then will we know for every individual patient, at certain time after stroke, with particular clinical features and parameters on DWI/PWI, which will be the best clinical management.

Author details

Vincent Lai

The University of Hong Kong, Hong Kong

References

- [1] Albers GW, Thijs VN, Wechsler L, Kemp S, Schlaug G, Skalabrin E, Bammer R, Kakuda W, Lansberg MG, Shuaib A, Coplin W, Hamilton S, Moseley M & Marks MP; DEFUSE Investigators. (2006). Magnetic resonance imaging profiles predict clinical response to early reperfusion: the diffusion and perfusion imaging evaluation for understanding stroke evolution (DEFUSE) study. *Ann Neurol*, Vol.60, No.5, pp. 508-517
- [2] Bandera E, Botteri M, Minelli C, Sutton A, Abrams KR & Latronico N. (2006). Cerebral blood flow threshold of ischemic penumbra and infarct core in acute ischemic stroke. A systemic review. *Stroke*, Vol.37, No.5, pp. 1334-1339
- [3] Barber PA, Darby DG, Desmond PM, Gerraty RP, Yang Q, Li T, Jolley D, Donnan GA, Tress BM & Davis SM. (1999). Identification of major ischemic change. Diffusion-weighted imaging versus computed tomography. *Stroke*, Vol.30, No.10, pp. 2059-2065
- [4] Beaulieu C, de Crespigny A, Tong DC, Moseley ME, Albers GW & Marks MP. (1999). Longitudinal magnetic resonance imaging study of perfusion and diffusion in stroke: evolution of lesion volume and correlation with clinical outcome. *Ann Neurol*, Vol.46, No.4, pp. 568-578
- [5] Bristow MS, Simon JE, Brown RA, Eliasziw M, Hill MD, Coutts SB, Frayne R, Demchuk AM & Mitchell JR. (2005). MR perfusion and diffusion in acute ischemic stroke:

human gray and white matter have different thresholds for infarction. *J Cereb Blood Flow Metab*, Vol.25, No.10, pp. 1280-1287

- [6] Butcher K, Parsons M, Baird T, Barber A, Donnan G, Desmond P, Tress B & Davis S. (2003). Perfusion thresholds in acute stroke thrombolysis. *Stroke*, Vol.34, No.9, pp. 2159-2164
- [7] Calamante F, Gadian DG & Connelly A. (2002). Quantification of perfusion using bolus tracking magnetic resonance imaging in stroke: assumptions, limitations, and potential implications for clinical use. *Stroke*, Vol.33, No.4, pp. 1146-1151
- [8] Crisostomo RA, Garcia MM & Tong DC. (2003). Detection of diffusion-weighted MRI abnormalities in patients with transient ischemic attack: correlation with clinical characteristics. *Stroke*, Vol.34, No.4, pp. 932-937
- [9] Davis SM & Donnan GA. (2005). Using mismatch on MRI to select thrombolytic responders: an attractive hypothesis awaiting confirmation. *Stroke*, Vol.36, No.5, pp. 1106-1107
- [10] Davis SM, Donnan GA, Parsons MW, Levi C, Butcher KS, Peeters A, Barber PA, Bladin C, De Silva DA, Byrnes G, Chalk JB, Fink JN, Kimber TE, Schultz D, Hand PJ, Hankey G, Muir K, Gerraty R, Tress BM & Desmond PM; EPITHET investigators. (2008). Effects of alteplase beyond 3 h after stroke in the Echoplanar Imaging Thrombolytic Evaluation Trial (EPITHET): a placebo-controlled randomized trial. *Lancet Neurol*, Vol.7, No.4, pp. 299-309
- [11] Deibler AR, Pollock JM, Kraft RA, Tan H, Burdette JH & Maldjian JA. (2008). Arterial spina-labeling in routine clinical practice, part 1: Technique and artifacts. *AJNR Am J Neuroradiol*, Vol.29, No.7, pp. 1228-1234
- [12] Derex L, Nighoghossian N, Hermier M, Adeleine P, Berthezene Y, Philippeau F, Honnorat J, Froment JC & Trouillas P. (2004). Influence of pretreatment MRI parameters on clinical outcome, recanalization and infarct size in 49 stroke patients treated by intravenous tissue plasminogen activator. *J Neurol Sci*, Vol.225, No.1-2, pp. 3-9
- [13] Fiebach JB, Schellinger PD, Jansen O, Meyer M, Wilde P, Bender J, Schramm P, Jüttler E, Oehler J, Hartmann M, Hähnel S, Knauth M, Hacke W & Sartor K. (2002). CT and diffusion-weighted MR imaging results in higher accuracy and lower interrater variability in the diagnosis of hyperacute ischemic stroke. *Stroke*, Vol.33, No.9, pp. 2206-2210
- [14] Fiebach JB, Schellinger PD, Gass A, Kucinski T, Siebler M, Villringer A, Olkers P, Hirsch JG, Heilnd S, Wilde P, Jansen O, Röther J, Hacke W & Sartor K. (2004). Stroke magnetic resonance imaging is accurate in hyperacute intracerebral hemorrhage: a multicenter study on the validity of stroke imaging. *Stroke*, Vol.35, No.2, pp. 502-506

- [15] Fiehler J, Foth M, Kucinski T, Knab R, von Bezold M, Weiller C, Zeumer H & Röther J. (2002). Severe ADC decreases do not predict irreversible tissue damage in humans. *Stroke*, Vol.33, No.1, pp. 79-86
- [16] Furlan AJ, Eyding D, Albers GW, Al-Rawi Y, Lees KR, Rowley HA, Sachara C, Soehngen M, Warach S & Hacke W; DEDAS Investigators. (2006). Dose Escalation of Desmoteplase for Acute Ischemic Stroke (DEDAS): evidence of safety and efficacy 3 to 9 hours after stroke onset. *Stroke*, Vol.37, No.5, pp. 1227-1231
- [17] Gonzalez RG, Schaefer PW, Buonanno FS, Schwamm LH, Budzik RF, Rordorf G, Wang B, Sorensen AG & Koroshetz WJ. (1999). Diffusion-weighted MR imaging: diagnostic accuracy in patients imaged within 6 hours of stroke symptom onset. *Radiology*, Vol.210, No.1, pp. 155-162
- [18] Grandin CB, Duprez TP, Smith AM, Mataligne F, Peeters A, Oppenheim C & Cosnard G. (2001). Usefulness of magnetic resonance-derived quantitative measurements of cerebral blood flow and volume prediction of infarct growth in hyperacute stroke. *Stroke*, Vol.32, No.5, pp. 1147-1153
- [19] Grandin CB. (2003). Assessment of brain perfusion with MRI: methodology and application to acute stroke. *Neuroradiology*, Vol.45, No.11, pp. 755-766
- [20] Grandin CB, Bol A, Smith AM, Michel C & Cosnard G. (2005). Absolute CBF and CBV measurements by MRI bolus tracking before and after acetazolamide challenge: repeatability and comparison with PET in humans. *Neuroimage*, Vol.26, No.2, pp. 525-535
- [21] Hacke W, Albers G, Al-Rawi Y, Boquosslavsky J, Davalos A, Eliasziw M, Fischer M, Furlan A, Kaste M, Lees KR, Soehngen M & Warach S; DIAS Study Group. (2005). The Desmoteplase in Acute Ischemic Stroke Trial (DIAS): a phase II MRI-based 9-hour window acute stroke thrombolysis trial with intravenous desmoteplase. *Stroke*, Vol.36, No.1, pp. 66-73
- [22] Hacke W, Kaste M, Bluhmki E, Brozman M, Dávalos A, Guidetti D, Larrue V, Lees KR, Medeghri Z, Machnig T, Schneider D, von Kummer R, Wahlgren N, Toni D & ECASS investigators. (2008). Thrombolysis with alteplase 3 to 4.5 hours after acute ischemic stroke. *N Engl J Med*, Vol.359, No.13, pp. 1317-1329
- [23] Hacke W, Furlan AJ, Al-Rawi Y, Davalos A, Fiebach JB, Gruber F, Kaste M, Lipka LJ, Pedraza S, Ringleb PA, Rowley HA, Schneider D, Schwamm LH, Leal JS, Söehngen M, Teal PA, Wilhelm-Ogunbiyi K, Wintermark M & Warach S. (2009). Intravenous desmoteplase in patients with acute ischemic stroke selected by MRI perfusion-diffusion weighted imaging or perfusion CT (DIAS-2): a prospective, randomized, double-blind, placebo-controlled study. *Lancet Neurol*, Vol.8, No.2, pp. 141-150
- [24] Hatazawa J, Shimosegawa E, Toyoshima H, Ardekani BA, Suzuki A, Okudera T & Miura Y. (1999). Cerebral blood volume in acute brain infarction : a combined study

with dynamic susceptibility contrast MRI and 99MTC-HMPAO-SPECT. *Stroke*, Vol. 30, No.4, pp. 800-806

- [25] Hossmann KA. (1994) Viability thresholds and the penumbra of focal ischemia. *Ann Neurol*, Vol.36, No.4, pp. 557-565
- [26] Ibaraki M, Ito H, Shimosegawa E, Toyoshima H, Ishigame K, Takahashi K, Kanno I & Miura S. (2007). Cerebral vascular mean transit time in healthy humans: a comparative study with PET and dynamic susceptibility contrast-enhanced MRI. *J Cereb Blood Flow Metab*, Vol.27, No.2, pp. 404-413
- [27] Johnston SC, Gress DR, Browner WS & Sidney S. (2000). Short-term prognosis after emergency-department diagnosis of TIA. *JAMA*, Vol.284, No.22, pp. 2901-2906
- [28] Kajimoto K, Moriwaki H, Yamada N, Hayashida K, Kobayashi J, Miyashita K & Naitomi H. (2003). Cerebral hemodynamic evaluation using perfusion-weighted magnetic resonance imaging : comparison with positron emission tomography values in chronic occlusive carotid disease. *Stroke*, Vol.34, No.7, pp. 1662-1666
- [29] Kane I, Carpenter T, Chappell F, Rivers C, Armitage P, Sandercock P & Wardlaw J. (2007). Comparison of 10 different magnetic resonance imaging processing methods in acute ischemic stroke: Effect on lesion size, proportion of patients with diffusion/perfusion match, clinical scores, and radiologic outcomes. *Stroke*, Vol.38, No.12, pp. 3158-3164
- [30] Kastrup A, Schulz JB, Mader I, Dichgans J & Küker W. (2002). Diffusion-weighted MRI in patients with symptomatic internal carotid artery disease. *J Neurol*, Vol.249, No.9, pp. 1168-1174
- [31] Keir SL & Wardlaw JM. (2000). Systemic review of diffusion and perfusion imaging in acute ischemic stroke. *Stroke*, Vol.31, No.11, pp. 2723-2731
- [32] Kidwell CS, Alger JR, Di Salle F, Starkman S, Villablanca P, Bentson J & Saver JL. (1999). Diffusion MRI in patients with transient ischemic attacks. *Stroke*, Vol.30, No.6, pp. 1174-1180
- [33] Kidwell CS, Saver JL, Mattiello J, Starkman S, Vinuela F, Duckwiler G, Gobin YP, Jahan R, Vespa P, Kalafut M & Alger JR. (2000). Thrombolytic reversal of acute human cerebral ischemic injury shown by diffusion/perfusion magnetic resonance imaging. *Ann Neurol*, Vol.47, No.4, pp. 462-469
- [34] Kidwell CS, Saver JL, Starkman S, Duckwiler G, Jahan R, Vespa P, Villablanca JP, Liebeskind DS, Gobin YP, Vinuela F & Alger JR. (2002). Late secondary ischemic injury in patients receiving intraarterial thrombolysis. *Ann Neurol*, Vol.52, No.6, pp. 698-703
- [35] Kidwell CS, Chalela JA, Saver JL, Starkman S, Hill MD, Demchuk AM, Butman JA, Patronas N, Alger JR, Latour LL, Luby ML, Baird AE, Leary MC, Tremwel M, Ovbiagele B, Fredieu A, Suzuki S, Villablanca JP, Davis S, Dunn B, Todd JW, Ezzeddine

- MA, Haymore J, Lynch JK, Davis L & Warach S. (2004). Comparison of MRI and CT for detection of acute intracerebral hemorrhage. *JAMA*, Vol.292, No.15, pp. 1823-1830
- [36] Knutsson L, Borjesson S, Larsson EM, Risberg J, Gustafson L, Passant U, Stahlberg F & Wirestam R. (2007). Absolute quantification of cerebral blood flow in normal volunteers : correlation between Xe-133 SPECT and dynamic susceptibility contrast MRI. *J Magn Reson Imaging*, Vol.26, No.4, pp. 913-920
- [37] Krol AL, Coutts SB, Simon JE, Hill MD, Sohn CH & Demchuk AM; VISION Study Group. (2005). Perfusion MRI abnormalities in speech or motor transient ischemic attack patients. *Stroke*, Vol.36, No.11, pp. 2487-2489
- [38] Latchaw RE, Yonas H, Hunter GJ, Yuh WT, Ueda T, Sorensen AG, Sunshine JL, Biller J, Wechsler L, Higashida R & Hademenos G. (2003). Guidelines and recommendations for perfusion imaging in cerebral ischemia: a scientific statement for healthcare professionals by the writing group on perfusion imaging, from the Council on Cardiovascular Radiology of the American Heart Association. *Stroke*, Vol.34, No.4, pp. 1084-1104
- [39] Lin W, Celik A, Derdeyn C, An H, Lee Y, Videen T, Ostergaard L & Powers WJ. (2001). Quantitative measurements of cerebral blood flow in patients with unilateral carotid artery occlusion: a PET and MR study. *J Magn Reson Imaging*, Vol.14, No.6, pp. 659-667
- [40] Liu Y, Karonen JO, Vanninen RL, Ostergaard L, Roivainen R, Nuutinen J, Perkio J, Kononen M, Hamalainen A, Vanninen EJ, Soimakallio S, Kuikka JT & Aronen HJ. (2000). Cerebral hemodynamics in human acute ischemic stroke : a study with diffusion- and perfusion-weighted magnetic resonance imaging and SPECT. *J Cereb Blood Flow Metab*, Vol.20, No.6, pp. 910-920
- [41] Lövblad KO, Baird AE, Schlaug G, Benfield A, Siewert B, Voetsch B, Conner A, Burzynski C, Edelman RR & Warach S. (1997). Ischemic lesion volumes in acute stroke by diffusion-weighted magnetic resonance imaging correlate with clinical outcome. *Ann Neurol*, Vol.42, No.2, pp. 164-170
- [42] Lövblad KO, Laubach HJ, Baird AE, Curtin F, Schlaug G, Edelman RR & Warach S. (1998). Clinical experience with diffusion-weighted MR in patients with acute stroke. *AJNR Am J Neuroradiol*, Vol.19, No.6, pp. 1061-1066
- [43] Luby M & Warach S. (2007). Reliability of MR perfusion-weighted and diffusion-weighted imaging mismatch measurement methods. *AJNR Am J Neuroradiol*, Vol.28, No.9, pp. 1674-1678
- [44] Ma H, Zavala JA, Teoh H, Churilov L, Gunawan M, Ly J, Wright P, Phan T, Arakawa S, Davis SM & Donnan GA. (2009). Fragmentation of the classical magnetic resonance mismatch "penumbral" pattern with time. *Stroke*, Vol.40, No.12, pp. 3752-3757

- [45] Mlynash M, Olivot JM, Tong DC, Lansberg MG, Eynhorn I, Kemp S, Moseley ME & Albers GW. (2009). Yield of combined perfusion and diffusion MR imaging in hemispheric TIA. *Neurology*, Vol.72, No.13, pp. 1127-1133
- [46] Muir KW, Buchan A, von Kummer R, Rother J & Baron JC. (2006). Imaging of acute stroke. *Lancet Neurol*, Vol.5, No.9, pp. 755-768
- [47] Newman GC, Delucia-Deranja E, Tudorica A, Hospod FE & Patlak CS. (2003). Cerebral blood volume measurements by T²-weighted MRI and contrast infusion. *Magn Reson Med*, Vol.50, No.4, pp. 844-855
- [48] Neumann-Haefelin T, Wittsack HJ, Wenserski F, Siebler M, Seitz RJ, Modder U & Freund HJ. (1999). Diffusion- and perfusion-weighted MRI: the DWI/PWI mismatch region in acute stroke. *Stroke*, Vol.30, No.8, pp. 1591-1597
- [49] Neumann-Haefelin T, Wittsack HJ, Wenserski F, Li TQ, Moseley ME, Siebler M & Freund HJ. (2000). Diffusion- and perfusion-weighted MRI in a patient with a prolonged reversible ischemic neurological deficit. *Neuroradiology*, Vol.42, No.6, pp. 444-447
- [50] Nighoghossian N, Hermier M, Adeleine P, Derex L, Dugor JF, Philippeau F, Ylmaz H, Honnorat J, Dardel P, Berthezène Y, Froment JC & Trouillas P. (2003). Baseline magnetic resonance imaging parameters and stroke outcome in patients treated by intravenous tissue plasminogen activator. *Stroke*, Vol.34, No.2, pp. 458-463
- [51] Oppenheim C, Logak M, Dormont D, Lehericy S, Manai R, Samson Y, Marsault C & Rancurel G. (2000). Diagnosis of acute ischemic stroke with fluid-attenuated inversion recovery and diffusion-weighted sequences. *Neuroradiology*, Vol.42, No.8, pp. 602-607
- [52] Ostergaard L, Johannsen P, Host-Poulsen P, Vestergaard-Poulsen P, Asboe H, Gee AD, Hansen SB, Cold GE, Gjedde A & Gyldensted C. (1998). Cerebral blood flow measurements by magnetic resonance imaging bolus tracking: comparison with [¹⁵O]H₂O positron emission tomography in humans. *J Cereb Blood Flow Metab*, Vol.18, No.9, pp. 935-940
- [53] Parsons MW, Yang Q, Barber PA, Darby DG, Desmond PM, Gerraty RP, Tress BM & Davis SM. (2001). Perfusion magnetic resonance imaging maps in hyperacute stroke: relative cerebral blood flow most accurately identifies tissue destined to infarct. *Stroke*, Vol.32, No.7, pp. 1581-1587
- [54] Parsons MW, Barber PA, Chalk J, Darby DG, Rose S, Desmond PM, Gerraty RP, Tress BM, Wright PM, Donnan GA & Davis SM. (2002). Diffusion- and perfusion-weighted MRI response to thrombolysis in stroke. *Ann Neurol*, Vol.51, No.1, pp. 28-37
- [55] Poustchi-Amin M, Mirowitz SA, Brown JJ, McKinstry RC & Li T. (2001) Principles and applications of echo-planar imaging: a review for the general radiologist. *Radio-graphics*, Vol.21, No.3, pp. 767-779

- [56] Provenzale JM, Shah K, Patel U & McCrory DC. (2008). Systemic review of CT and MR perfusion imaging for assessment of acute cerebrovascular disease. *AJNR Am J Neuroradiol*, Vol.29, No.8, pp. 1476-1482
- [57] Redgrave JN, Coutts SB, Schulz UG, Briley D & Rothwell PM. (2007). Systemic review of associations between the presence of acute ischemic lesions on diffusion-weighted imaging and clinical predictors of early stroke risk after transient ischemic attack. *Stroke*, Vol.38, No.5, pp. 1482-1488
- [58] Restrepo L, Jacobs MA, Barker PB & Wityk RJ. (2004). Assessment of transient ischemic attack with diffusion- and perfusion-weighted imaging. *AJNR Am J Neuroradiol*, Vol.25, No.10, pp. 1645-1652
- [59] Røhl L, Ostergaard L, Simonsen CZ, Vestergaard-Poulsen P, Andersen G, Sakoh M, Le Bihan D & Gyldensted C. (2001) Viability thresholds of ischemic penumbra of hyperacute stroke defined by perfusion-weighted MEI and apparent diffusion coefficient. *Stroke*, Vol.32, No.5, pp. 1140-1146
- [60] Rovira A, Rovira-Gols A, Pedraza S, Grivé E, Molina C & Alvarez-Sabin J. (2002). Diffusion-weighted MR imaging in the acute phase of transient ischemic attacks. *AJNR Am J Neuroradiol*, Vol.23, No.1, pp. 77-83
- [61] Schellinger PD, Thomalla G, Fiehler JF, Köhrmann M, Molina CA, Neumann-Haefelin T, Ribo M, Singer OC, Zaro-Weber O & Sobesky J. (2007). MRI-based and CT-based thrombolytic therapy in acute stroke within and beyond established time windows: an analysis of 1210 patients. *Stroke*, Vol.38, No.10, pp. 2640-2645
- [62] Schellinger PD, Bryan RN, Caplan LR, Detre JA, Edelman RR, Jaigobin C, Kidwell CS, Mohr JP, Sloan M, Sorensen AG & Warach S. (2010). Evidence-based guideline: The role of diffusion and perfusion MRI for the diagnosis of acute ischemic stroke: report of the Therapeutics and Technology Assessment Subcommittee of the American Academy of Neurology. *Neurology*, Vol.75, No.2, pp. 177-185
- [63] Seevinck PR, Deddens LH & Dijkhuizen RM. (2010). Magnetic resonance imaging of brain angiogenesis after stroke. *Angiogenesis*, Vol.13, No.2, pp. 101-111
- [64] Seitz RJ, Meisel S, Weller P, Junghans U, Wittsack HJ & Siebler M. (2005). Initial ischemic event: perfusion-weighted MR imaging and apparent diffusion coefficient for stroke evaluation. *Radiology*, Vol.237, No.3, pp. 1020-1028
- [65] Sobesky J, Zaro Weber O, Lehnhardt FG, Hesselmann V, Thiel A, Dohmen C, Jacobs A, Neveling M & Heiss WD. (2004). Which time-to-peak threshold best identifies penumbral flow? A comparison of perfusion-weighted magnetic resonance imaging and positron emission tomography in acute ischemic stroke. *Stroke*, Vol.35, No.12, pp. 2843-2847
- [66] Sobesky J, Zaro Weber O, Lehnhardt FG, Hesselmann V, Neveling M, Jacobs A & Heiss WD. (2005). Does the mismatch match the penumbra? Magnetic resonance

- imaging and positron emission tomography in early ischemic stroke. *Stroke*, Vol.36, No.5, pp. 980-985
- [67] Srinivasan A, Goyal M, Azri FA & Lum C. (2006). State-of-the-art imaging of acute stroke. *Radiographics*, Vol.26, Suppl 1, pp. s75-s95
- [68] Takasawa M, Jones PS, Guadagno JV, Christensen S, Fryer TD, Harding S, Gillard JH, Williams GB, Aigbirhio FI, Warburton WA, Ostergaard L & Baron JC. (2008). How reliable is perfusion MR in acute stroke?: validation and determination of the penumbra threshold against quantitative PET. *Stroke*, Vol.39, No.3, pp. 870-877
- [69] Tanaka Y, Nariai T, Nagaoka T, Akimoto H, Ishiwata K, Ishii K, Matsushima Y & Ohno K. (2006). Quantitative evaluation of cerebral hemodynamics in patients with moyamoya disease by dynamic susceptibility contrast magnetic resonance imaging-comparison with positron emission tomography. *J Cereb Blood Flow Metab*, Vol.26, No.2, pp. 291-300
- [70] Tissue plasminogen activator for acute ischemic stroke. The National Institute of Neurological Disorders and Stroke rt-PA Stroke Study Group. (1995). *N Engl J Med*, Vol.333, No. 24, pp. 1581-1587
- [71] van Osch MJ, Vonken EJ, Viergever MA, van der Grond J & Bakker CJ. (2003). Measuring the arterial input function with gradient echo sequences. *Magn Reson Med*, Vol. 49, No.6, pp. 1067-1076
- [72] von Kummer R, Bourquain H, Bastianello S, Bozzao L, Manelfe C, Meier D & Hacke W. (2001). Early prediction of irreversible brain damage after ischemic stroke at CT. *Radiology*, Vol.219, No.1, pp. 95-100.
- [73] Wahlgren N, Ahmed N, Dávalos A, Hacke W, Millán M, Muir K, Roine RO, Toni D, Lees KR & SITS investigators. (2008). Thrombolysis with alteplase 3-4.5 h after acute ischemic stroke (SITS-ISTR) : an observational study. *Lancet*, Vol.372, No.9646, pp. 1303-1309
- [74] Warach S, Pettigrew LC, Dashe JF, Pullicino P, Lefkowitz DM, Sabounjian L, Harnett K, Schwiderski U & Gammans R. (2000). Effect of citicoline on ischemic lesions as measured by diffusion-weighted magnetic resonance imaging. Citicoline 010 Investigators. *Ann Neurol*, Vol.48, No.5, pp. 713-722
- [75] Wu EX, Tang H & Jensen JH. (2004). Applications of ultrasmall superparamagnetic iron oxide contrast agents in the MR study of animal models. *NMR Biomed*, Vol.17, No.7, pp. 478-483
- [76] Wu O, Christensen S, Hjort N, Dijkhuizen RM, Kucinski T, Fiehler J, Thomalla G, Röther J & Ostergaard L. (2006). Characterizing physiological heterogeneity of infarction risk in acute human ischemic stroke using MRI. *Brain*, Vol.129, No.9, pp. 2384-2393
- [77] Yamada K, Wu O, Gonzalez RG, Bakker D, Ostergaard L, Copen WA, Weisskoff RM, Rosen BR, Yagi K, Nishimura T & Sorensen AG. (2002). Magnetic resonance perfu-

sion-weighted imaging of acute cerebral infarction: effect of the calculation methods and underlying vasculopathy. *Stroke*, Vol.33, No.1, pp. 87-94

- [78] Zaharchuk G, Bammer R, Straka M, Newbould RD, Rosenberg J, Olivot JM, Mlynash M, Lansberg MG, Schwartz NE, Marks MM, Albers GW & Moseley ME. (2009). Improving dynamic susceptibility contrast MRI measurement of quantitative cerebral blood flow using corrections for partial volume and nonlinear contrast relaxivity : a Xenon computed tomographic comparative study. *J Magn Reson Imaging*, Vol.30, No. 4, pp. 743-752
- [79] Zaro-Weber O, Moeller-Hartmann W, Heiss WD & Sobesky J. (2009). The performance of MRI-based cerebral blood flow measurements in acute and subacute stroke compared with 15O-water positron emission tomography : identification of penumbral flow. *Stroke*, Vol.40, No.7, pp. 2413-2421
- [80] Zaro-Weber O, Moeller-Hartmann W, Heiss WD & Sobesky J. (2010a). MRI perfusion maps in acute stroke validated with 15o-water positron emission tomography. *Stroke*, Vol.41, No.3, pp. 443-449
- [81] Zaro-Weber O, Moeller-Hartmann W, Heiss WD & Sobesky J. (2010b). A simple positron emission tomography-based calibration for perfusion-weighted magnetic resonance maps to optimize penumbral flow detection in acute stroke. *Stroke*, Vol.41, No. 9, pp. 1939-1945

