

We are IntechOpen, the world's leading publisher of Open Access books Built by scientists, for scientists

6,900

Open access books available

185,000

International authors and editors

200M

Downloads

Our authors are among the

154

Countries delivered to

TOP 1%

most cited scientists

12.2%

Contributors from top 500 universities



WEB OF SCIENCE™

Selection of our books indexed in the Book Citation Index
in Web of Science™ Core Collection (BKCI)

Interested in publishing with us?
Contact book.department@intechopen.com

Numbers displayed above are based on latest data collected.
For more information visit www.intechopen.com



Active and Passive fMRI for Presurgical Mapping of Motor and Language Cortex

Victoria A.L. Mosher, Einat Liebenthal and
Bradley G. Goodyear

Additional information is available at the end of the chapter

<http://dx.doi.org/10.5772/30844>

1. Introduction

1.1. Overview of fMRI and its use in presurgical mapping

Functional magnetic resonance imaging (fMRI) using the blood-oxygenation level dependent (BOLD) contrast measures local changes in the concentration of paramagnetic deoxyhemoglobin associated with an increase in blood flow to active regions of the brain (Bandettini, Wong, Hinks, Tikofsky, & Hyde, 1992; Kwong, et al., 1992; Ogawa, Lee, Kay, & Tank, 1990). Together with structural MRI, BOLD fMRI is increasingly being used for presurgical functional mapping of epilepsy and brain tumor patients (Binder, et al., 1996; Haberg, Kvistad, Unsgard, & Haraldseth, 2004; Hall & Truwit, 2008; Krings, et al., 2001; Lee, et al., 1999; Van Westen, Skagerberg, Olsrud, Fransson, & Larsson, 2005; Liebenthal, 2011). Presurgical fMRI provides patient-specific functional information that may facilitate maximal tumor or epileptic tissue surgical resection, with minimal damage to surrounding gray and white matter structures that support vital sensory and cognitive functions. Presurgical mapping of brain regions and their spatial relationship to the lesion can in some cases help predict possible deficits in sensory, motor or cognitive functions due to surgery or due to continued lesion growth (Haberg, Kvistad, Unsgard, & Haraldseth, 2004). In this way, presurgical mapping can guide the decision for course of intervention (extent of resection, alternative treatment, etc.) and the decision to conduct additional intra-operative functional mapping (e.g., intra-cortical stimulation-ICS). Finally, presurgical mapping is also valuable for planning the pathway of surgical approach.

The main advantages of fMRI in particular for clinical applications are its high spatial resolution, non-invasive nature, relative safety, and the good access to MRI scanners in most medical

centers. Compared to functional mapping using ICS, or the intracarotid sodium amobarbital procedure (Wada test) to assess hemispheric language and memory dominance, fMRI is far less unpleasant to the patient and it is also less expensive (Medina et al., 2004). Unlike ICS, fMRI is performed prior to the surgery, without the time constraints and limitations on patient cognitive ability imposed by the surgery. The Wada test, named after Canadian neurologist and epileptologist Juhn Atsushi Wada, was developed 50 years ago to assess the hemispheric dominance of language and thereby the risk of language decline in patients undergoing brain surgery (Wada & Rasmussen, 1960). The procedure involves some risk to the patient, however, and it is unpleasant, consisting of intracarotid injection of a barbiturate to one brain hemisphere, during which time the other hemisphere is examined for language and memory functions.

One concern sometimes raised with respect to fMRI presurgical mapping is that it identifies neuronal networks involved in a specific function, including regions that may actually be expendable (Desmond & Annabel Chen, 2002). The problem is that, surgical resection of expendable areas of a functional network identified with fMRI should not cause a post-surgical functional decline, and it would therefore be safe and desirable for achieving the surgery goals to resect them. In contrast, ICS is thought to indicate strictly regions that are essential for a function, and should therefore be preserved during surgery in order to prevent functional damage. However it is important to understand that, as with fMRI, a similar concern actually applies to ICS in that regions that are remote from the stimulated region but connected to it may also be affected by the stimulation and 'erroneously' considered essential.

Another difficulty relates to the high inter-and intra-subject variability in the extent of activation foci observed with fMRI even with constant scanning parameters and consistent task performance (Liu, Zhang, Brown, Yue, 2004). This problem usually arises because the extent of active areas is determined by a statistical significance threshold that depends on the quality and quantity of the acquired signal, irrespective of the physiological boundaries of functional fields. In an effort to address this issue, recent work examined the spatial and temporal reproducibility of the relative amplitude of the fMRI signal and found it to be more stable than the absolute amplitude (Voyvodic, 2006). It was further determined empirically that thresholding individual activation maps at 40% of the most active voxels resulted in highly reproducible activity in the sensorimotor hand region during a finger tapping task, both within and across subjects (Voyvodic, Petrella, Friedman, 2009). Thus, relative amplitude maps can be used to improve the reliability and anatomical specificity of functional MR mapping.

Despite the differences between the techniques, there is generally very good concordance between fMRI and ICS mapping of somatosensory and motor functions (Bartos, et al., 2009; Hirsch, et al., 2000; Holodny, et al., 2000; Jack, et al., 1994; Krishnan, et al., 2004; Lehericy, Duffau, et al., 2000; Pujol, et al., 1996; Yetkin, et al., 1997). Nevertheless, in language mapping, reported levels of task sensitivity and specificity are variable and strongly dependent on the particular task that is used (Bookheimer, 2007). High sensitivity (i.e., fMRI activates all or most sites identified by ICS) but low specificity (i.e., fMRI activates additional sites not identified by ICS) has been reported for auditory tasks and in particular word generation to auditory cues (FitzGerald, et al., 1997). Higher sensitivity can generally be achieved with the conjunction

of several fMRI language tasks, but specificity remains low (Pouratian, Bookheimer, Rex, Martin, & Toga, 2002; Rutten, Ramsey, van Rijen, Noordmans, & van Veelen, 2002).

Perhaps the most serious concern with regard to fMRI presurgical mapping (and functional mapping in general) is that the predictive value of this technique for patient outcome has not yet systematically been established in different patient types and using specific activation paradigms. Several studies in small cohorts of brain tumor patients suggest that fMRI mapping can be predictive of surgical outcome. A distance of 10 mm or more between tumor and functional cortex has been suggested to carry reduced risk for postsurgical neurological deficits (Haberg, et al., 2004; Krishnan, et al., 2004). In epilepsy, fMRI of language has been demonstrated to be strongly correlated with Wada language asymmetry (Binder, et al., 1996; Lehericy, Cohen, et al., 2000; Liegeois, et al., 2002) and to predict language (Sabsevitz, et al., 2003) and verbal memory (Binder et al., 2008) outcome after left anterior temporal lobe resection. Despite these recent advances, more work is required to establish guidelines for the use of fMRI in presurgical mapping.

1.2. Selection of fMRI paradigms

Factors related to the choice of fMRI activation paradigm (active or passive experimental task, control task, level of task performance, and the number of trials per task condition) have a critical impact on the resulting functional maps and their interpretation, particularly for mapping cognitive functions such as language and memory (Binder, Swanson, Hammeke, & Sabsevitz, 2008; Bookheimer, 2007). In terms of motor paradigms, simple hand/finger movements are usually sufficient to get a reliable map of motor cortex activity. These types of paradigms will be presented later in the chapter when we compare task-based fMRI with passive resting-state paradigms.

In terms of language tasks, active tasks requiring an overt response are generally considered more reliable because they allow monitoring of the patient's performance, and are thought to engage targeted brain regions more strongly (Lee, Jack, & Riederer, 1998). An active control task rather than passive rest (i.e., no task) is recommended as a baseline for contrasting with an active language task, because activation in the control condition can account for general executive, attentional and motor processes that are nonspecific to the tested cognitive function (Binder, Swanson, et al., 2008; Demonet, et al., 1992). In addition, activation during passive rest can be dominated by continuous processing of linguistically-mediated thoughts (whether day dreaming or intense mental processing), thereby effectively reducing the differential activation of language networks between the active and control tasks (McKiernan, D'Angelo, Kaufman, & Binder, 2006; Stark & Squire, 2001).

Finally, the task demands should be adjusted according to the patient's level of performance. For example, shorter and/or easier versions of the tasks may be needed for young children who tend to have a shorter attention span and a different knowledge base. As will be elaborated in the second part of this chapter, an interesting alternative approach to active task paradigms is passive resting-state fMRI. The resting-state paradigm is independent of patient perform-

ance, is time efficient, and can therefore serve as an alternative for patients who cannot comply with active task demands.

1.3. Comparative evaluation of three fMRI language tasks

To demonstrate the impact of the choice of paradigm on resulting fMRI maps, we compared three language tasks in terms of sensitivity and specificity in regions of interest for language. These tasks are: an auditory semantic word decision task (Binder, et al., 1997), an auditory definition naming task, and a silent word generation task.

The semantic task consists of a dual-criteria go/no-go semantic word decision (SWD) to auditorily presented animal names (i.e., press the keypad if “this animal is found in North America and used by people”), contrasted with a dual-criteria go/no-go auditory decision task (press the keypad if “this tone sequence contains two high-pitch tones”). Sixteen blocks of 8 trials alternating between the tasks are presented in two separate runs. This task has been shown to reliably activate regions in left inferior and middle frontal gyri, left middle temporal gyrus, left fusiform gyrus, and left angular gyrus, involved in phonological and lexico-semantic functions (Binder, et al., 1997). The degree of lateralization of these activated areas has been shown to correspond with Wada language asymmetry in individual epilepsy patients (Binder, et al., 1996) and predicts language and verbal memory outcome after left temporal lobectomy (Binder, et al., 2008; Sabsevitz, et al., 2003).

The auditory definition (or responsive) naming task (DNT) consists of overtly naming (speaking the name of) an object, animal, famous place, or famous person, in response to an auditory description (for example, “a horse with stripes” or “what the king wears on his head”) (Hamberger & Seidel, 2003). This task is contrasted with an auditory control task consisting of speaking the number of siren sounds embedded in a sequence of white noise. This task uses an event-related design with 128 naming trials and 128 control trials, presented intermixed in 4 separate runs. Relative to the SWD, the DNT places additional demands on the language system because it involves word retrieval and overt speech. This task is expected to engage stronger, or more extensive activation within language areas, particularly in the left inferior frontal, middle temporal and parietal cortex (Okada & Hickok, 2006; Tomaszewski Farias, Harrington, Broomand, & Seyal, 2005).

The silent word generation (SWG) task consists of covertly finding words that start with certain letters, each displayed on a screen for 5 seconds. The control task consists of visually fixating on letters from foreign alphabets. We compared the SWG task with the SWD and DNT tasks because it is simple to implement, and therefore often used for fMRI language mapping in clinical settings. Nevertheless, a significant drawback of this task is that there is no monitoring of task performance. In addition, the task engages primarily phonological processing, but imposes fewer demands on the semantic system.

The reliability of each of the three fMRI language tasks was examined in eleven right handed neurologically-healthy volunteers, using sensitivity and specificity measures described previously (Hirsch, et al., 2000). Target regions of interest (ROIs) for language (inferior frontal

gyrus, IFG; middle temporal gyrus, MTG; and angular gyrus, AG) were defined using a digital atlas based on cytoarchitectonic and macro anatomical labels (Eickhoff, et al., 2005). An adaptive thresholding scheme, consisting of mapping the activation in each subject as a percentage of local excitation, was used as a means to reduce the variability in the extent of activation between subjects (Voyvodic, 2006). The amplitude threshold each ROI was set individually at 40% of the peak positive activation within that ROI. This level of thresholding was selected because it was shown to yield highly reproducible and specific individual motor activation maps in a large cohort of subjects (Voyvodic, et al., 2009). Individual maps were then grouped using a random effects model to account for intersubject variability and capture effects in the whole population. Sensitivity measures across the group for each task were computed based on the individual mean value of the t-statistic in all voxels exceeding the threshold in the target ROIs. Specificity was measured across subjects as the proportion of the above-threshold positive activation volume (computed as the mean t-value weighted by the number of voxels exceeding the threshold) in the target ROI relative to the whole brain. Lateralization indices (LI) were computed for each of the ROIs in the language tasks because of the clinical relevance of language dominance as a predictor of post surgical neurological deficit, and because quantitative measures of laterality show better within-subject reproducibility than quantitative measures of the volume of activation (Harrington, Buonocore, & Farias, 2006). The LI was computed as the ratio of the difference and the sum of the activation in each left and right region of interest ($LI = [QLH - QRH] / [QLH + QRH]$), where the activation in the left and right hemispheres (QLH and QRH, respectively) was represented by the sensitivity or specificity measures described above. In this formulation, LI varies between 1 and -1, with positive values reflecting left hemisphere dominance and negative values reflecting right hemisphere dominance. LI measures incorporating both the magnitude and extent of activation were selected here because they have been shown to be more robust and reproducible (Fernandez et al., 2003; Jansen et al., 2006). Note that the size of the contralateral ROIs defined in the atlas were similar though not identical, but this did not bias the LI comparison between tasks because any ROI asymmetries were consistent across tasks.

The group maps of fMRI activation in the language ROIs for the three language tasks are shown in Figure 1, and the corresponding sensitivity and specificity measures in each ROI and task are shown in Figures 2 and 3. Activation was observed in all ROIs for all tasks. The LI based on the sensitivity measure (Figure 2) was similar for all tasks in IFG. However, it was larger for SWD and DNT in AG, with a similar trend in MTG. LI was largest for DNT when all three regions were combined. The LI based on the specificity measure (Figure 3) was larger for SWG in IFG, and larger for SWD and DNT in AG, with no differences observed in MTG. The LI was largest for DNT when all three regions were combined.

Figure 4 shows an example of presurgical fMRI language maps using the SWD and SWG tasks in a patient with right frontotemporal low-grade glioma. Activation for both the SWD and SWG tasks was left lateralized. Only the SWD task activated the angular gyrus. The SWG task produced stronger activation in IFG and MFG. Figure 5 shows an example of fMRI language maps in a neurologically healthy left handed volunteer. In this subject, the three maps

consistently indicate right hemisphere dominance for language. As in previous examples, only the SWD and DNT tasks activated the angular gyrus. The SWG task activated specifically the frontal cortex.

Taken together, these results suggest that an important advantage of the semantic word decision (SWD) and definition naming (DNT) tasks over the silent word generation (SWG) task, is that the former tasks activate the angular gyrus (AG) with high sensitivity and specificity. The AG activation can be used to compute more robust lateralization indices. In contrast, the SWG task activates the inferior frontal gyrus (IFG) with high specificity, such that lateralization patterns in this area are more robust with the SWG compared to the SWD task. Thus, an optimal set of paradigms for presurgical language mapping would consist of a combination of the SWG task with the SWD or DNT tasks.

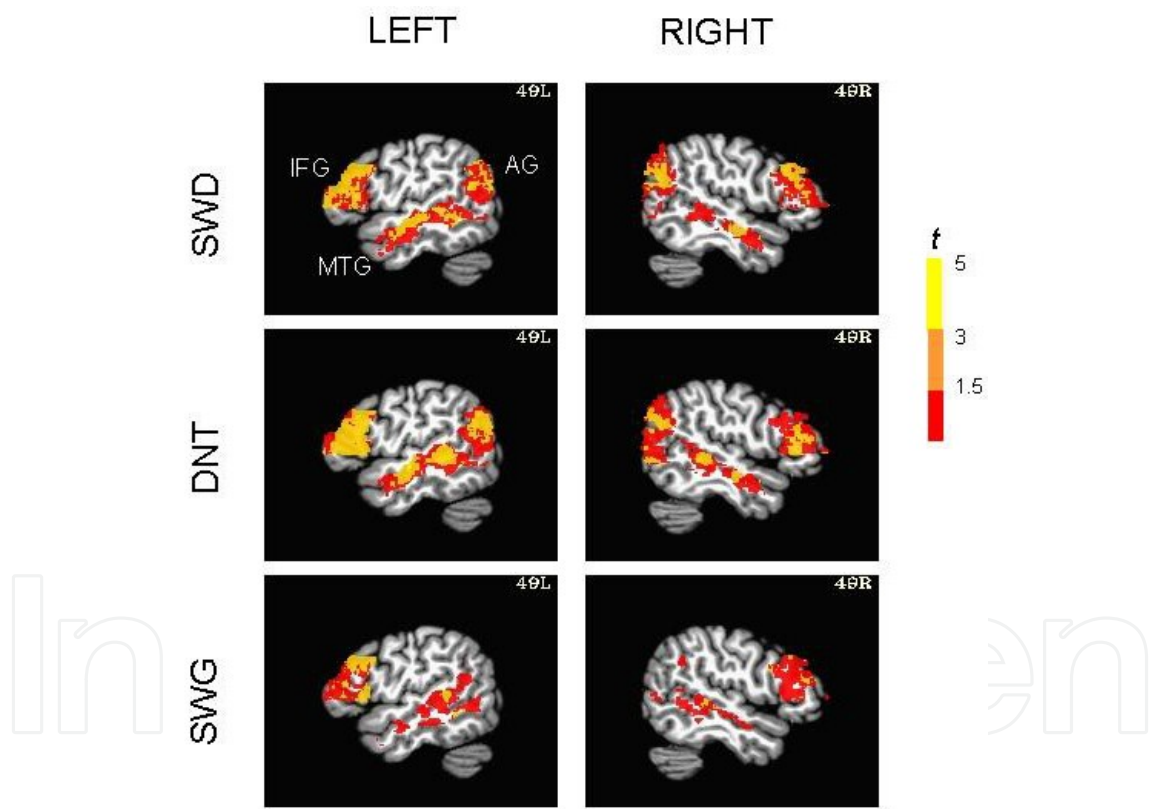


Figure 1. FMRI activation within the three language ROIs for a group of right handed, neurologically healthy adults (n=11), during auditory semantic word decision (SWD), auditory definition naming (DNT), and silent word generation (SWG) tasks. The individual activation maps in each task were thresholded at 40% of the maximum activation in each ROI, projected into standard stereotaxic space (Talairach & Tournoux, 1988), and combined across subjects using random effects analysis. The fMRI activity in the three language ROIs is displayed on sagittal slices of a template brain (Colin N27), at 49 mm to the left (49L, left panels) and to the right (49R, right panels) of the midsagittal plane. In this map, $t=2.57$ corresponds to $p<0.01$ (orange), and $t=3.3$ corresponds to $p<0.001$ (yellow).

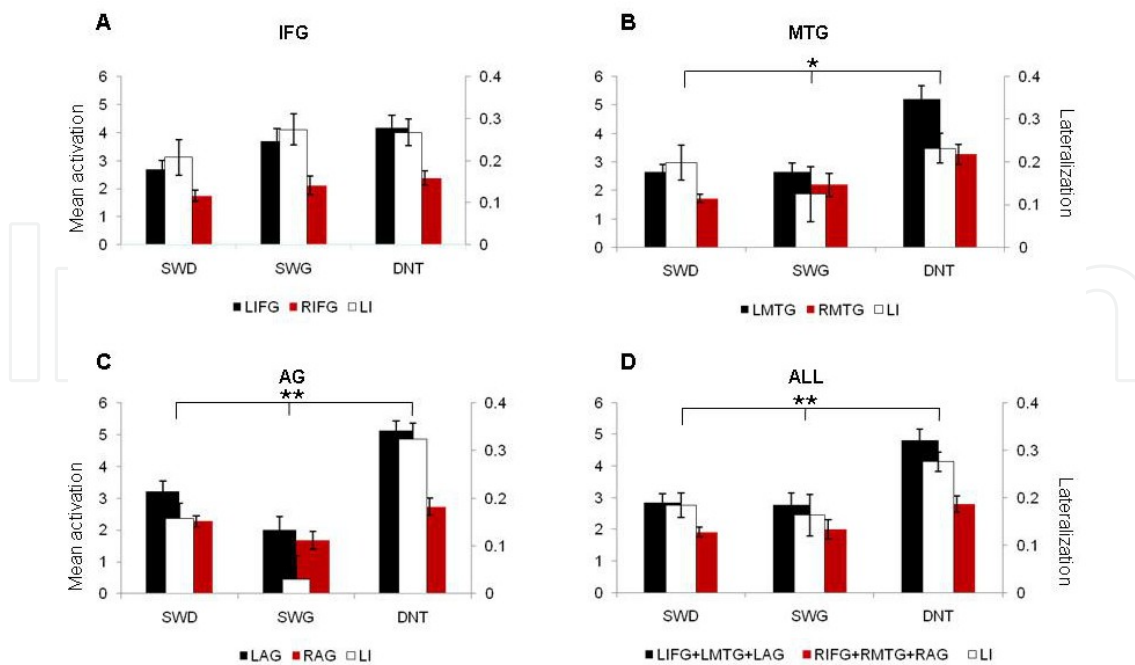


Figure 2. The sensitivity measure (expressed as mean t -value of supra threshold voxels) and corresponding lateralization index (LI) in the regions of interest for language (A. left and right inferior frontal gyri, B. left and right middle temporal gyri, C. left and right angular gyri – LIFG, RIFG, LMTG, RMTG, LAG, RAG, respectively), during semantic word decision (SWD), silent word generation (SWG), and definition naming (DNT). * $p < 0.1$; ** $p < 0.05$.

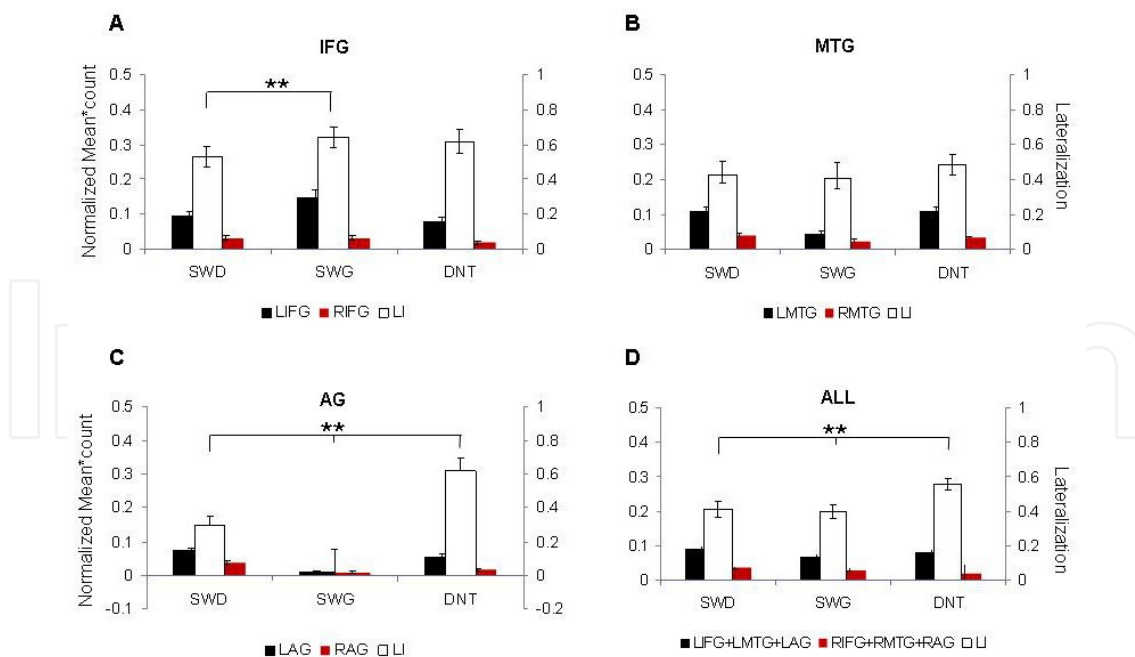


Figure 3. The specificity measure (expressed as mean t -value of supra threshold voxels weighted by voxel count in each ROI, normalized to the whole brain) and corresponding LI in each language task. Abbreviations as in Figure 2. ** $p < 0.05$.

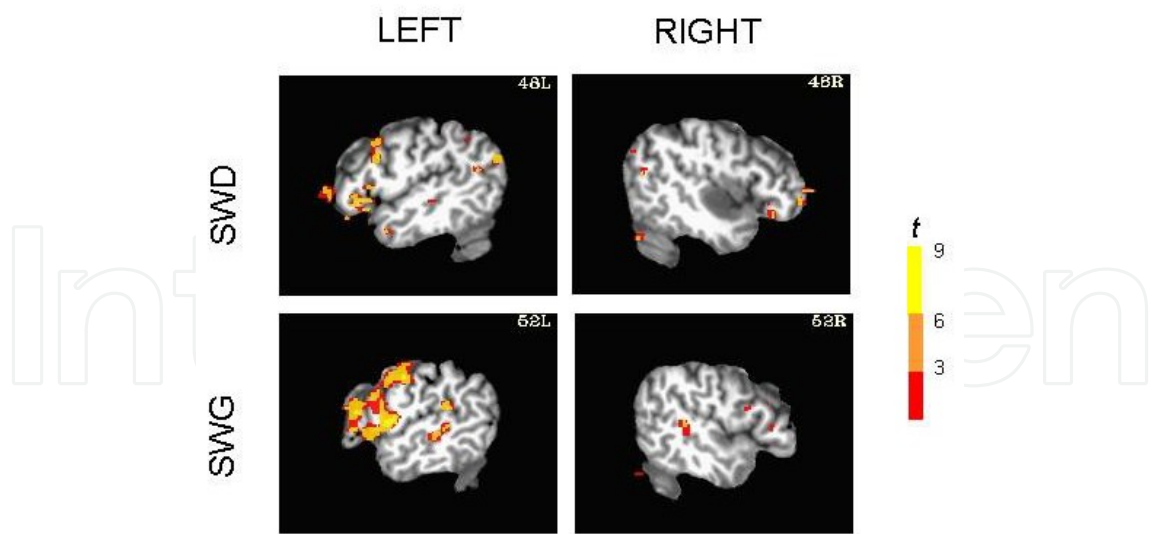


Figure 4. Presurgical fMRI language maps for the semantic word decision (SWD) and silent word generation (SWG) tasks, in a patient with right frontotemporal low-grade glioma (37 year old, right handed, female).

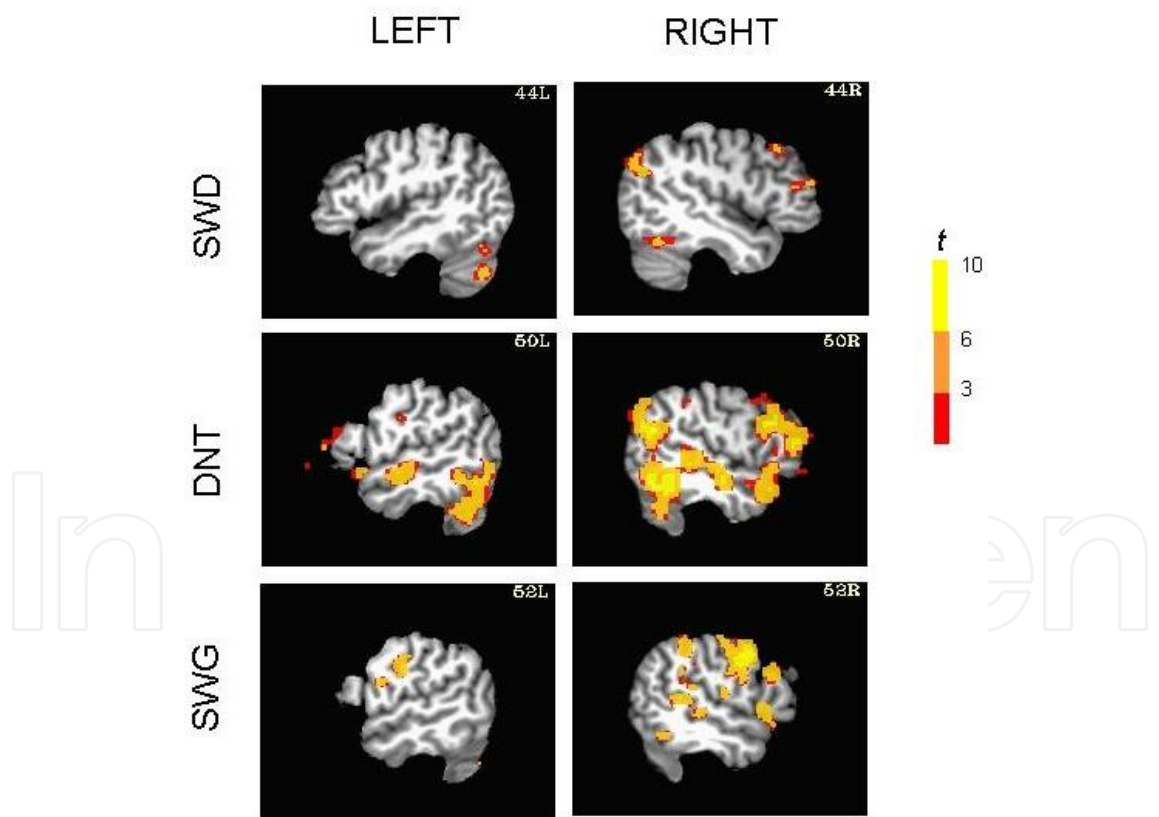


Figure 5. FMRI language maps in the three language tasks, in a neurologically healthy, left handed volunteer (Edinburgh Handedness Inventory score=-0.8). In these maps, the activation was thresholded at 40% of the maximal activation in the entire brain. The three maps are consistent with one another in suggesting right hemisphere dominance for language.

2. The origins of resting-state fMRI

As with many major scientific advances, the use of fMRI to investigate the resting state of the human brain was discovered essentially by accident. In 1995, Biswal and colleagues (Biswal, Yetkin, Haughton, & Hyde, 1995) initially meant to isolate physiological noise in fMRI data collected from subjects during rest; however, it was observed that a prominent low-frequency signal (< 0.1 Hz) remained after removing the physiological noise. To investigate this further, high frequencies were filtered from all voxels in the brain, and the signal from the left primary sensorimotor cortex was compared to the signal from all other voxels in the brain. A high level of correlation was observed with the right primary sensorimotor cortex and other motor areas. It was thus hypothesized that spontaneous low-frequency fluctuations in the BOLD signal were the result of functional connections between these brain regions.

With fMRI itself still in its infancy and no clear explanation of how the resting-state signal was generated, there remained some controversy as to whether the resting-state signal was neurologically significant. One study found that the strength of left/right inter-hemispheric correlations during the resting state decreased when subjects held their breath, and returned to normal levels once the subjects began breathing again (Biswal, Hudetz, Yetkin, Haughton, & Hyde, 1997). This study provided initial evidence that spontaneous low-frequency fluctuations were indeed blood-oxygenation dependent, like the BOLD signal. It was later observed using voltage sensitive dyes that neurons in the visual cortex exhibit patterns of spontaneous activity similar to the activation patterns elicited in response to stimuli of a specific visual orientation angle (Kenet, Bibitchkov, Tsodyks, Grinvald, & Arieli, 2003). This was one of the first studies to provide evidence that the resting-state signal had a physiological basis. In recent years, a number of studies have demonstrated a link between physiological, electrophysiological, and BOLD processes and the resting-state signal (Laufs, et al., 2003; Leopold, Murayama, & Logothetis, 2003; Mantini, Perrucci, Del Gratta, Romani, & Corbetta, 2007).

Through the validation of the resting-state phenomenon, resting-state fMRI has become a valuable tool to investigate how the brain functions at rest and how brain networks at rest are organized; however, the physiological mechanisms underlying the resting-state signal are still under investigation. Higher field scanners (3 Tesla and above) with improved signal-to-noise ratios, improved imaging sequences and head coils, and a better understanding of fMRI in general, have also contributed to the ubiquity of resting-state research. Many resting-state studies have been published since the first study, investigating a multitude of disease and normal brain states (e.g., Lowe, 2010; van den Heuvel & Hulshoff Pol, 2010). Since resting-state fMRI is still a relatively new concept, appropriate methods of collecting and analyzing resting-state data are still under development. With these advances in methodology, resting-state fMRI will continue to be an invaluable research tool for investigations of normal and pathological human brain function. However, as we will discuss in the remainder of this chapter, resting-state fMRI has the added potential of becoming a powerful diagnostic and assessment tool for individual clinical cases (Freilich & Gaillard, 2010; Sakoglu, et al., 2011).

3. Resting-state fMRI: The basics

3.1. The resting-state signal

The resting-state fMRI signal resides within a narrow frequency range of 0.01 to 0.1 Hz (De Luca, et al., 2006; Damoiseaux, et al., 2006). The similarity of these low-frequency fluctuations between spatially distinct brain regions implies a functional connection. The degree of similarity, which quantifies the strength of the functional connection, is called *functional connectivity*, and the collection of brain regions identified as connected constitute a *resting-state network*. These resting-state networks are consistent with our knowledge of structural connections via the connective white matter tracts. In a study of patients with multiple sclerosis, a significant correlation was found between the integrity of the white matter tracts (i.e., structural connectivity) within the motor pathway and functional connectivity of the motor network (Lowe, et al., 2008). This suggests that when white matter cannot function properly, functional connectivity is diminished or even lost in the specific resting-state network. Even in healthy control subjects, the strength of functional connections within resting-state networks seems to be correlated with the strength of anatomical connections in the same area, as measured by diffusion tensor imaging (Skudlarski, et al., 2008). These studies have helped to establish a link between our knowledge of the anatomical connections in the brain and the resting-state fMRI signal.

3.2. The procedure

Acquiring resting-state fMRI data is relatively simple because of its non-demanding nature in terms of effort required from the subject. The subject is asked to remain still inside the MR scanner for a period of five to ten minutes, think of nothing in particular, and stare at a fixation cross or keep their eyes closed. It has been demonstrated that when the eyes are open, the functional connections between the thalamus and visual cortex are weakened as opposed to when the eyes are closed (Zou, et al., 2009). Conversely, it has been shown that the functional connections are stronger within the “default mode” network (consisting of the posterior cingulate cortex, precuneus, medial prefrontal cortex, ventral anterior cingulate cortex and lateral parietal cortex) when subjects have their eyes open (Yan, et al., 2009). Taken together, these studies suggest that the benefit of having subjects stare at a fixation cross or keep their eyes closed differs between resting-state networks, and must be taken into account when a study is planned.

Once the data has been collected, it is subjected to a pre-processing pipeline the same as that for task fMRI: motion correction, spatial and temporal smoothing, and spatial normalization to a standard template (i.e., the Montreal Neurological Institute brain or the Talairach atlas). In terms of the analysis of resting-state data, there are two broad categories: model-dependent or model-independent (Joel, Caffo, van Zijl, & Pekar, 2011; Margulies, et al., 2010). A model-dependent analysis assumes *a priori* knowledge of the approximate location of a brain region within the resting-state network under investigation. Using this knowledge, a seed region (consisting of a voxel or voxels) is typically defined either anatomically or by an a priori task. The average time course of this seed region is extracted and compared to the time course of

every other voxel in the brain, usually by some variant of the General Linear Model including nuisance signals from cerebral spinal fluid, white matter, the average signal from the whole brain and physiological recordings of cardiac and respiratory signals (Glover, Li, & Ress, 2000; Murphy, Birn, Handwerker, Jones, & Bandettini, 2009). The voxels whose time courses are strongly correlated to the seed region are considered to be functionally connected to the seed region, and constitute a whole-brain map of the resting-state network. In contrast, a model-independent analysis is performed when there is no specific hypothesis about a brain region and its inclusion in a resting-state network. One common example of this approach is independent component analysis (ICA) (Hu, Yang, LaConte, & Weng, 2008). The ICA algorithm identifies groupings of spatial clusters (i.e., components) that are maximally independent and whose BOLD signal fluctuations are similar; however, knowledge of brain networks is still required to select and group the components to form a final map of the desired resting-state network. Whether the approach to resting-state connectivity analysis is ICA or a seed region, there is good agreement as to the number and location of these networks in the healthy human brain across studies (Damoiseaux, et al., 2006; De Luca, Beckmann, De Stefano, Matthews, & Smith, 2006; Kiviniemi, et al., 2009).

The ease of data collection from the subject's perspective is just one of the many reasons why resting-state is becoming a popular brain imaging method. As we will discuss in the next few sections, the resting-state method is being applied to a number of neurological and psychiatric disease states, which could eventually advance resting-state fMRI towards actual clinical use.

3.3. Current uses of resting-state fMRI

Because there is no effort required by the subject during imaging, resting-state fMRI is quickly becoming a popular research tool. The majority of resting-state investigations are conducted in tandem with task-related fMRI, to gain complementary information about the brain's functional networks. For some patient populations, however, task-based fMRI may not be possible because patients are non-compliant. Resting-state fMRI may permit the investigation of patients who would otherwise not be studied using fMRI. Thus, resting-state fMRI may be a good candidate for translation into the clinical realm (Freilich & Gaillard, 2010; Sakoglu, et al., 2011). A few of the current uses and techniques of resting-state fMRI will be outlined in this section.

To better understand the nature and mechanisms of functional connectivity, current studies combine resting-state fMRI with diffusion tensor imaging (DTI), an MR technique that provides an anatomical map of white matter tract integrity and quantifies structural connectivity (Skudlarski, et al., 2008). This combination of techniques permits a direct investigation of the relationship between structural and functional connectivity, since white matter tracts may provide the means for distant brain areas to remain functionally connected through correlated fluctuations in the BOLD signal. Studies have shown a strong correlation between structural and functional connectivity in the brain on a whole-brain scale (Skudlarski, et al., 2008) and for individual functional networks (Greicius, Supekar, Menon, & Dougherty, 2009). Hence, these types of studies provide insight into how structure and function are directly related in the human brain.

Resting-state fMRI is also being used to investigate a number of brain diseases and disorders. Disrupted resting-state networks have been identified in neurological disorders such as Alzheimer's disease (Jiang, et al., 2006) and psychopathologies such as schizophrenia (Liu, et al., 2007). One group has even used resting-state fMRI to distinguish patients with major depressive disorder from healthy controls (Craddock, Holtzheimer, Hu, & Mayberg, 2009), demonstrating that resting-state fMRI has the potential for individual patient diagnosis. Studies have also demonstrated changes in resting-state connectivity over the course of mild cognitive impairment (Wang, et al., 2011) and recovery after stroke (Park, et al., 2011). Hence, there is potential for resting-state fMRI in the clinical assessment of disease progression and recovery, as well as in the assessment of treatment strategies.

3.4. Advantages of resting-state fMRI

Resting-state fMRI has a number of advantages over task-based fMRI and other imaging modalities. Unlike PET, fMRI in general is noninvasive and unlike EEG, deep-brain activity can be more easily detected. In comparison to task-based fMRI, there are little or no practice effects associated with multiple resting-state sessions. The main advantage of resting-state fMRI, however, is that it requires no effort from the patient. This is especially helpful when studying patients with physical or psychological deficits who cannot perform or understand the required task. For example, most task-based fMRI studies of stroke involving the upper extremities require patients to perform repetitive finger or hand movements (Buma, Lindeman, Ramsey, & Kwakkel, 2010; Calautti & Baron, 2003). For many stroke patients, it is difficult to move a single finger or hand, and often other fingers or body parts move in unison (i.e. mirror movements) (Nelles, et al., 1998). As a result, it is difficult to obtain a reliable anatomical map of brain activity in response to the desired movement. Typically, these patients, who make up a large proportion of stroke patients, are simply not studied, creating a significant patient selection bias in research studies. As a result, this poses severe limits on the translation of task-based fMRI into clinical use. Since resting-state fMRI does not require any movement or action from the patient, this problem can be avoided. All patients, even the most severely impaired, can undergo a resting-state study, thus increasing the likelihood of gaining significant insight into the disease.

3.5. Disadvantages of resting-state fMRI

Despite continual advances in resting-state fMRI, there are still some drawbacks to the method. The most significant problem is that the physiological basis of the resting-state signal is still not completely understood. As discussed above, a number of studies support the notion that the resting-state BOLD signal has a neuronal basis (e.g., Lowe, et al., 2008; Skudlarski, et al., 2008). However, because of the inherent difficulty associated with recording neuronal activity from multiple spatially distinct sites, no studies have explicitly established the link between spontaneous fluctuations of the BOLD signal associated with the resting-state signal and neural activity.

Another problem is that although subjects are asked to lie still and not think of anything in particular, it is likely that periods of rest actually possess frequent states of unrest, such as

transient cognitive processes and inner monologues. These states interfere with the accurate determination of resting-state networks, especially those that involve the frontal cortices (Squire & Stark, 2001; McKiernan, et al., 2006). Indeed, it is impossible to achieve a state of “language rest”. However, as we will demonstrate later in this chapter, this disadvantage can actually be exploited for the purposes of presurgical mapping of language processing.

Unless a seed region for resting-state analysis can be defined easily using an anatomical atlas, like motor cortex (Yousry, et al., 1995), an appropriate task-based experiment designed to activate a particular area of the brain is still required. This becomes more difficult if resting-state maps of higher cognitive functions are desired. A recent study, however, has demonstrated that ROIs can be defined using the resting-state data by selecting the voxels that exhibit the greatest inter-voxel cross-correlation (Goodyear & Golestani, 2011), thus removing the need for the task-based scan.

Of course, there are several disadvantages to fMRI in general. Compared to other brain imaging techniques such as EEG, fMRI possesses relatively low temporal resolution. This is because the hemodynamic response takes approximately two seconds to initiate, 6 to 8 seconds to reach its peak, and tens of seconds to return to baseline. In addition, because the BOLD signal is dependent on blood oxygenation and blood flow, there are many factors that can influence the generated signal such as age, brain pathology, and medications (Haller & Bartsch, 2009).

4. Resting-state fMRI for presurgical mapping

The downside to using any functional MRI technique for presurgical mapping, however, is that the brain shifts following tissue resection due to gravity, brain swelling and cerebrospinal fluid drainage (Nimsky, et al., 2000). This complicates the interpretation of functional localization post-surgically. Inaccuracy in brain function localization associated with this brain shift can be avoided using intraoperative MRI to assist in anatomical registration of fMRI data (Nimsky, Ganslandt, Hastreiter, & Fahlbusch, 2001). However, brain shift remains a problem for centers that do not have access to intraoperative MR scanners.

As noted above, resting-state fMRI circumvents the limitations associated with task-based fMRI: no task is necessary to isolate a specific brain region, it can be used on any patient regardless of their level of impairment, and multiple maps can be created from one short scan. This technique may also provide an easy means to track plasticity or recruitment of brain function that may occur following surgery. One advantage specific to epilepsy research is that resting-state fMRI can be used to study epileptogenic networks and foci, potentially assisting presurgical planning (Guye, et al., 2010; Moeller, et al., 2011).

To date, very few studies have investigated resting-state fMRI for the purposes of presurgical mapping. Therefore, its feasibility and effectiveness as a presurgical tool is yet to be determined. For resting-state fMRI to become a clinically useful tool, it must provide reliable information on a single subject level. One study demonstrated good concordance between

resting-state fMRI and ICS of patients with sensorimotor tumors, in terms of the identification of sensorimotor cortex (Zhang, et al., 2009). Another study demonstrated similar findings in patients with tumors or epileptic foci near the motor cortex. The patients that underwent surgery following fMRI mapping showed no new neurological deficits post-surgery (Liu, et al., 2009). Together, these studies provide the necessary framework to help move presurgical planning using resting-state fMRI from research into practice. However, before clinical application can be realized, studies are needed to validate resting-state techniques for presurgical mapping in terms of the brain regions that are identified and the dependence statistical threshold on deciding if brain regions are indeed significantly connected.

5. Clinical cases of resting-state fMRI

As an example of a typical case for presurgical motor fMRI, a patient with a right-hemisphere frontal lobe glioma in proximity to the motor cortex was referred to our centre for clinical fMRI. The clinical question was whether the patient exhibited a normal pattern of predominantly right-hemisphere motor activity in response to left hand movements and whether this activity was in close proximity or abutting the glioma. The motor task consisted of sequential finger tapping at a self-regulated pace of approximately 2 Hz. This task is performed easily by most patients and is effective in reliably activating sensorimotor regions, including contralateral primary somatosensory, premotor, and supplementary motor regions and the ipsilateral cerebellum (Gountouna et al., 2009; Yoo et al., 2005). The task was designed as twelve 30-sec blocks alternating between three visually cued conditions, right hand, left hand, and rest. The patient also underwent a 7-minute resting-state scan while staring at a fixation cross.

The results of the task-based fMRI and resting-state fMRI are shown in Figure 6. In response to left hand movement task, a typical pattern of brain activity was observed. A predominance of right hemisphere motor activity was observed within motor and sensorimotor cortices, like that for healthy control subjects. Bilateral premotor activity, however, was also present, and frontal activity associated with the cognitive components of the task was also observed. The conclusions drawn from this clinical fMRI study were that the patient exhibited a normal pattern of motor and sensorimotor activity, with an atypical distribution of bilateral premotor activity, possibly the result of functional compensation in response to the impinging glioma. It was advised that any resection should attempt to avoid the premotor regions lateral to the glioma.

A contralateral pattern of motor activity is associated with strong interhemispheric resting-state correlations in healthy subjects (Damoiseaux, et al., 2006). This was also the case for this patient (Figure 6). Strong intra-and inter-hemispheric correlations were observed, as well as strong correlations with the supplementary motor area (SMA) along the midline. The SMA is associated with the coordination of bimanual and complex movements (Sadato, Yonekura, Waki, Yamada, & Ishii, 1997; Wu, Wang, Hallett, Li, & Chan). Activity within the SMA was not observed for the simple hand movement task. In this case, the conclusions were that the interhemispheric resting-state connections are intact and that care must be taken during

resection to avoid the SMA along the medial edge of the glioma. This clinical case is a clear example where task-based fMRI and resting-state fMRI provide complementary and clinically relevant information for the purposes of presurgical planning.

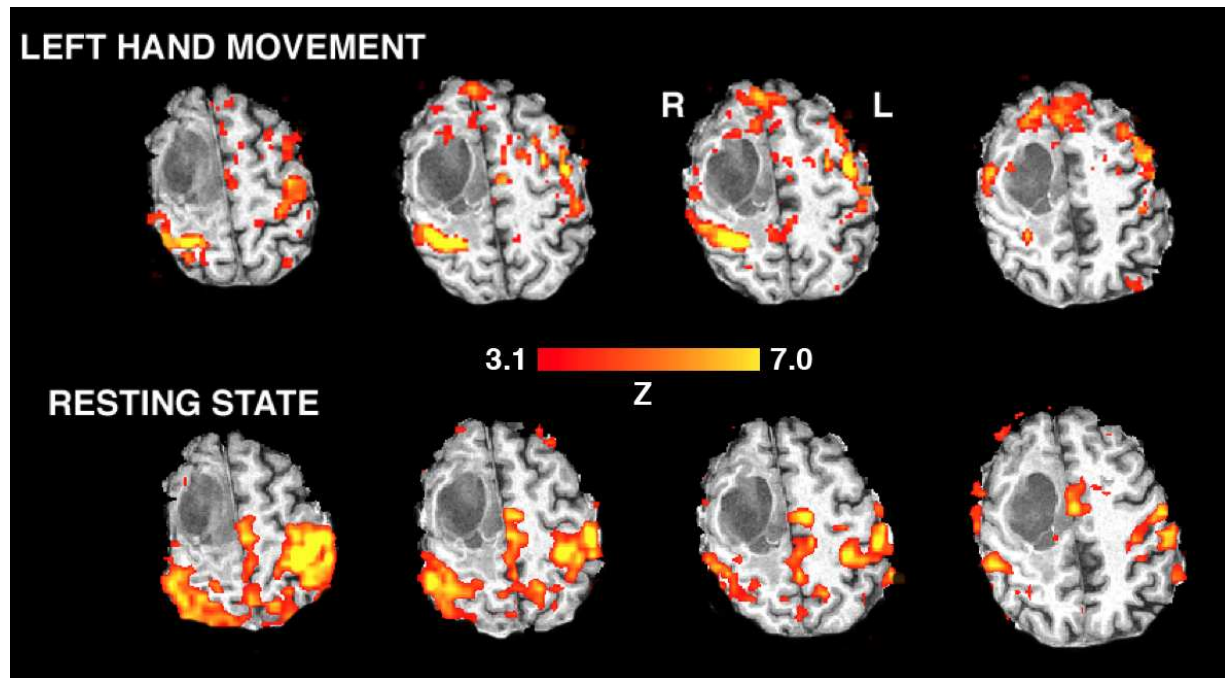


Figure 6. Motor task fMRI and resting-state fMRI data from a presurgical patient with a right frontal lobe glioma (clusters corrected to a significance level of $\alpha=0.05$, using Gaussian Random Fields theory). For the motor task (left hand movement), a typical predominance of brain activity was observed within the right motor and sensorimotor cortices. Some prefrontal and frontal activity was also observed, likely associated with the cognitive components of the task (e.g., self-pacing of movement). In this case, it was concluded that motor activity is not in close proximity to the glioma. Resting-state fMRI using the right motor cortex as the seed region revealed strong correlations with left motor cortex as well as with supplementary motor cortex along the midline in close proximity to the glioma. Red-to-yellow indicates the increasing relative strength of brain activity (for the task) or resting-state correlation (both expressed as a statistical Z-score).

As examples of typical cases for presurgical language fMRI, two patients with left temporal lobe epilepsy were referred to our centre for clinical fMRI. The clinical question was whether the patient exhibited a normal pattern of predominantly left-hemisphere inferior frontal gyrus (i.e., Broca's area) activity in response to language processing. The language task consisted of the SWD task described earlier. The patients also underwent a 5-minute resting-state scan while staring at a fixation cross. Patients were not instructed to try to suppress any internal dialogue, but rather to just let their mind wander.

The results of the task-based fMRI and resting-state fMRI for the first patient are shown in Figure 7. In response to the language tasks, bilateral activity was observed within the inferior frontal gyrus (i.e., Broca's area). It was concluded from the task-related fMRI study that there was an atypical bilateral representation of language processing in this patient. A number of other brain regions were also activated by these tasks, which involved significant cognitive

components. Of interest, however, was the lack of left-hemisphere Wernicke's area activity in response to these tasks.

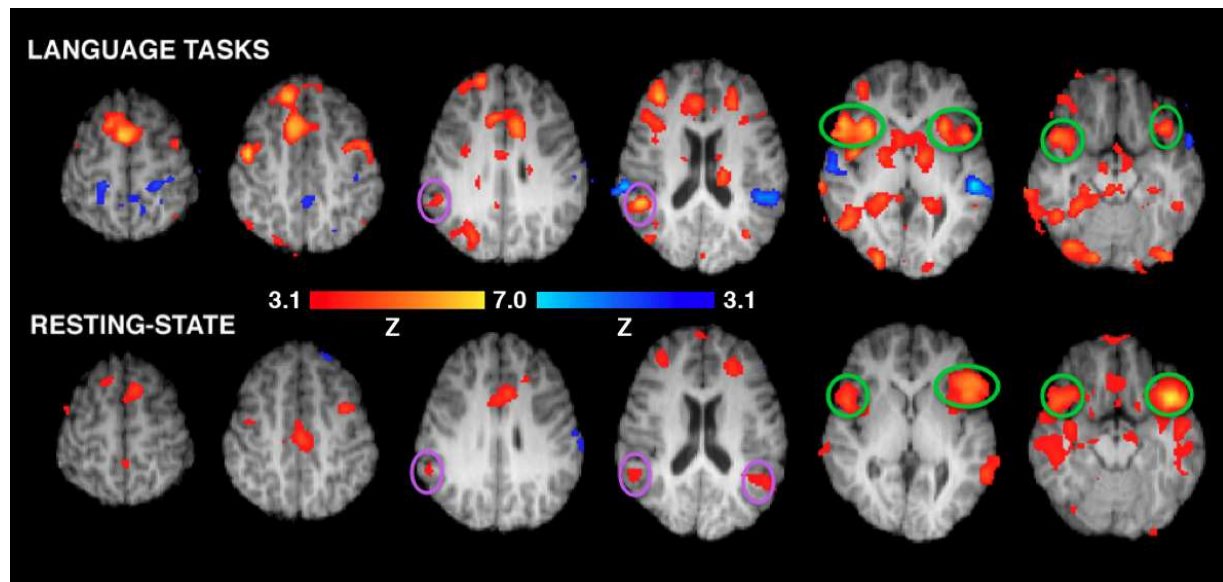


Figure 7. Language task fMRI and resting-state fMRI data from a presurgical patient with left temporal lobe epilepsy (clusters corrected to a significance level of $\alpha=0.05$, using Gaussian Random Fields theory). For the language tasks (verb generation and lexical retrieval), significant bilateral activity within the inferior frontal gyri (green circles) was observed. Other cognitive areas associated with the task were also observed, including the anterior cingulate, caudate, and prefrontal cortex. Language processing was represented bilaterally. Resting-state fMRI using the left inferior frontal gyrus as the seed region demonstrated strong correlations with right inferior frontal gyri as well as bilateral Wernicke's area (purple circles). In this case, the conclusion was also a bilateral representation of language processing. Red-to-yellow indicates the increasing relative strength of brain activity (for the task) or resting-state correlation. Blue-to-light blue indicates the increasing relative strength of negative brain activity (for the task) or negative resting-state correlation (both expressed as a statistical Z-score).

The resting-state fMRI map revealed strong similarities to the language task fMRI; strong inter-hemispheric correlations were observed between the inferior frontal gyri, as well as between left and right Wernicke's areas. These identified regions suggest that the patient was indeed not in a resting-state for language, and in fact these results further suggest that internal dialogue during rest may be sufficient to determine the contribution of each hemisphere to language processing.

The results of the task-based fMRI and resting-state fMRI for the second patient are shown in Figure 8. In response to the language tasks, activity was observed predominantly within the left inferior frontal gyrus. It was concluded from the task-related fMRI study that there was a typical left-hemisphere dominant representation of language processing in this patient. A number of other brain regions were also activated by these tasks, which involved significant cognitive components.

As with the other clinical case, the resting-state fMRI map was similar to the language task fMRI map; weak or absent inter-hemispheric correlations were observed between the inferior frontal gyri, as well as between left and right Wernicke's areas. These results also suggest that

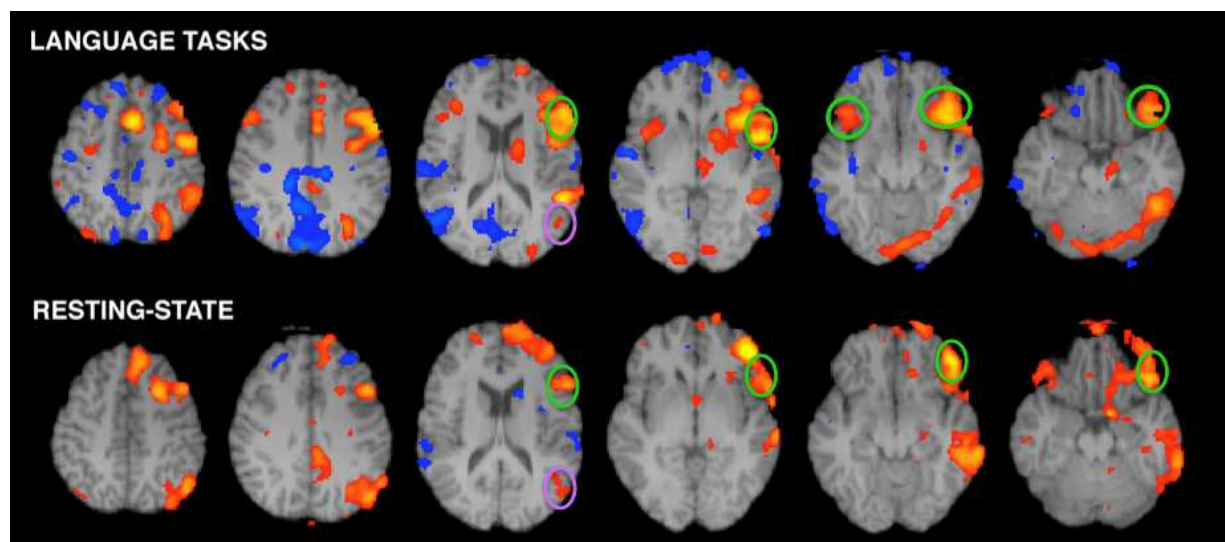


Figure 8. Language task fMRI and resting-state fMRI data from another presurgical patient with left temporal lobe epilepsy. For the language tasks (verb generation and lexical retrieval), significant left hemisphere dominant activity within the inferior frontal gyrus (green circles) was observed. Other cognitive areas associated with the task were also observed. In this case, the conclusion was a left hemisphere dominant representation of language processing. Resting-state fMRI using left inferior frontal gyrus as the seed region demonstrated strong correlations only within hemisphere, including left Wernicke's area (purple circles). In this case, the conclusion was also a left hemisphere dominant representation of language processing. Red-to-yellow indicates the increasing relative strength of brain activity (for the task) or resting-state correlation. Blue-to-light blue indicates the increasing relative strength of negative brain activity (for the task) or negative resting-state correlation.

internal dialogue may be sufficient to determine the contribution of each hemisphere to language processing.

6. Conclusions

In task-based fMRI, task selection has a critical impact on the resulting maps and their interpretation. In this chapter, we have shown that an important advantage of the semantic word decision and definition naming tasks over the commonly used silent word generation task is that the former tasks activate the angular gyrus with high sensitivity and specificity, allowing for more reliable estimation of hemispheric dominance in semantic processing. In contrast, the silent word generation task activates the inferior frontal gyrus with high specificity, such that estimation of lateralization patterns in this area is more robust with this task. Thus, a comprehensive set of paradigms for presurgical language mapping would consist of a combination of tasks targeting both phonological and semantic processing.

Resting-state fMRI provides a potential alternative to task-based fMRI in cases where patients are unable to comply with task instructions. As we have demonstrated in this chapter, resting-state fMRI of the motor network of individual patients provides important clinically relevant information complementary to task-based fMRI related to motor activity. We have also demonstrated that resting-state fMRI of the language network can also elucidate the laterality of language processing.

In summary, active or passive fMRI can provide a comprehensive delineation (and perhaps overestimation) of somatomotor and language regions surrounding a lesion, and this information can assist in assessing the risks of a surgery and the potential benefit of intrasurgical functional mapping. If the functional regions identified by fMRI are found to be distant from the lesion, this can facilitate a decision for radical tumor resection. If fMRI activation associated with vital sensory, motor or cognitive functions is demonstrated near the radiological tumor boundary and partial resection is suggested, ICS mapping can be used to identify the precise resection margin during the surgery itself. In this case, the presurgical information can be useful in speeding up the ICS procedure and in guiding the extent of the craniotomy (Bartos, et al., 2009; Rutten, et al., 2002).

Author details

Victoria A.L. Mosher¹, Einat Liebenthal^{1,3} and Bradley G. Goodyear¹

¹ University of Calgary, Canada

University of Manitoba, Canada

² Medical College of Wisconsin, USA

References

- [1] Acharya, J. N., Dinner, D. S. (1997). Use of the intracarotid amobarbital procedure in the evaluation of memory. *J Clin Neurophysiol*, 14(4), 311-325.
- [2] Bandettini, P. A., Wong, E. C., Hinks, R. S., Tikofsky, R. S., & Hyde, J. S. (1992). Time course EPI of human brain function during task activation. *Magn Reson Med*, 25(2), 390-397.
- [3] Bartos, R., Jech, R., Vymazal, J., Petrovicky, P., Vachata, P., Hejcl, A., et al. (2009). Validity of primary motor area localization with fMRI versus electric cortical stimulation: a comparative study. *Acta Neurochir (Wien)*, 151(9), 1071-1080.
- [4] Binder, J. R., Frost, J. A., Hammeke, T. A., Cox, R. W., Rao, S. M., & Prieto, T. (1997). Human brain language areas identified by functional magnetic resonance imaging. *J Neurosci*, 17(1), 353-362.
- [5] Binder, J. R., Sabsevitz, D. S., Swanson, S. J., Hammeke, T. A., Raghavan, M., & Mueller, W. M. (2008). Use of preoperative functional MRI to predict verbal memory decline after temporal lobe epilepsy surgery. *Epilepsia*, 49(8), 1377-1394.

- [6] Binder, J. R., Swanson, S. J., Hammeke, T. A., Morris, G. L., Mueller, W. M., Fischer, M., et al. (1996). Determination of language dominance using functional MRI: a comparison with the Wada test. *Neurology*, 46(4), 978-984.
- [7] Binder, J. R., Swanson, S. J., Hammeke, T. A., & Sabsevitz, D. S. (2008). A comparison of five fMRI protocols for mapping speech comprehension systems. *Epilepsia*, 49(12), 1980-1997.
- [8] Binder, J. R. (2011). Functional MRI is a valid noninvasive alternative to Wada testing. *Epilepsy Behav*, 20(2), 214-222.
- [9] Biswal, B., Hudetz, A. G., Yetkin, F. Z., Haughton, V. M., & Hyde, J. S. (1997). Hypercapnia reversibly suppresses low-frequency fluctuations in the human motor cortex during rest using echo-planar MRI. *J Cereb Blood Flow Metab*, 17(3), 301-308.
- [10] Biswal, B., Yetkin, F. Z., Haughton, V. M., & Hyde, J. S. (1995). Functional connectivity in the motor cortex of resting human brain using echo-planar MRI. *Magn Reson Med*, 34(4), 537-541.
- [11] Bookheimer, S. (2007). Pre-surgical language mapping with functional magnetic resonance imaging. *Neuropsychology Review*, 17(2), 145-155.
- [12] Buma, F. E., Lindeman, E., Ramsey, N. F., & Kwakkel, G. (2010). Functional neuroimaging studies of early upper limb recovery after stroke: a systematic review of the literature. *Neurorehabil Neural Repair*, 24(7), 589-608.
- [13] Calautti, C., & Baron, J. C. (2003). Functional neuroimaging studies of motor recovery after stroke in adults: a review. *Stroke*, 34(6), 1553-1566.
- [14] Craddock, R. C., Holtzheimer, P. E., Hu, X. P. P., & Mayberg, H. S. (2009). Disease State Prediction From Resting State Functional Connectivity. *Magnetic Resonance in Medicine*, 62(6), 1619-1628.
- [15] Damoiseaux, J. S., Rombouts, S. A., Barkhof, F., Scheltens, P., Stam, C. J., Smith, S. M., et al. (2006). Consistent resting-state networks across healthy subjects. *Proc Natl Acad Sci U S A*, 103(37), 13848-13853.
- [16] De Luca, M., Beckmann, C. F., De Stefano, N., Matthews, P. M., & Smith, S. M. (2006). fMRI resting state networks define distinct modes of long-distance interactions in the human brain. *Neuroimage*, 29(4), 1359-1367.
- [17] De Luca, M., Beckmann, C. F., De Stefano, N., Matthews, P. M., & Smith, S. M. (2006). fMRI resting state networks define distinct modes of long-distance interactions in the human brain. *Neuroimage*, 29(4), 1359-1367.
- [18] Demonet, J. F., Chollet, F., Ramsay, S., Cardebat, D., Nespoulous, J. L., Wise, R., et al. (1992). The anatomy of phonological and semantic processing in normal subjects. *Brain*, 115 (Pt 6), 1753-1768.

- [19] Desmond, J. E., & Annabel Chen, S. H. (2002). Ethical issues in the clinical application of fMRI: factors affecting the validity and interpretation of activations. *Brain Cogn*, 50(3), 482-497.
- [20] Eickhoff, S. B., Stephan, K. E., Mohlberg, H., Grefkes, C., Fink, G. R., Amunts, K., et al. (2005). A new SPM toolbox for combining probabilistic cytoarchitectonic maps and functional imaging data. *Neuroimage*, 25(4), 1325-1335.
- [21] Fernandez, G., Specht, K., Weis, S., Tendolkar, I., Reuber, M., Fell, J. (2003). Intrasubject reproducibility of presurgical language lateralization and mapping using fMRI. *Neurology*, 60, 969-975.
- [22] FitzGerald, D. B., Cosgrove, G. R., Ronner, S., Jiang, H., Buchbinder, B. R., Belliveau, J. W., et al. (1997). Location of language in the cortex: a comparison between functional MR imaging and electrocortical stimulation. *AJNR Am J Neuroradiol*, 18(8), 1529-1539.
- [23] Freilich, E. R., Gaillard, W. D. (2010). Utility of functional MRI in pediatric neurology. *Curr Neurol Neurosci Rep*, 10(1), 40-46.
- [24] Glover, G. H., Li, T. Q., & Ress, D. (2000). Image-based method for retrospective correction of physiological motion effects in fMRI: RETROICOR. *Magn Reson Med*, 44(1), 162-167.
- [25] Goodyear, B. G., & Golestani, A. M. (2011). Regions of interest for resting-state fMRI analysis determined by inter-voxel cross-correlation. *Neuroimage*, 56(1), 246-251.
- [26] Greicius, M. D., Supekar, K., Menon, V., & Dougherty, R. F. (2009). Resting-State Functional Connectivity Reflects Structural Connectivity in the Default Mode Network. *Cerebral Cortex*, 19(1), 72-78.
- [27] Guye, M., Bettus, G., Bartolomei, F., Confort-Gouny, S., Guedj, E., Chauvel, P., et al. (2010). Role of resting state functional connectivity MRI in presurgical investigation of mesial temporal lobe epilepsy. *Journal of Neurology Neurosurgery and Psychiatry*, 81(10), 1147-1154.
- [28] Haberg, A., Kvistad, K. A., Unsgard, G., & Haraldseth, O. (2004). Preoperative blood oxygen level-dependent functional magnetic resonance imaging in patients with primary brain tumors: Clinical application and outcome. *Neurosurgery*, 54(4), 902-914.
- [29] Hall, W. A., & Truwit, C. L. (2008). Intraoperative MR-guided neurosurgery. *J Magn Reson Imaging*, 27(2), 368-375.
- [30] Haller, S., & Bartsch, A. J. (2009). Pitfalls in FMRI. *Eur Radiol*, 19(11), 2689-2706.
- [31] Hamberger, M. J., & Seidel, W. T. (2003). Auditory and visual naming tests: normative and patient data for accuracy, response time, and tip-of-the-tongue. *J Int Neuropsychol Soc*, 9(3), 479-489.

- [32] Harrington, G. S., Buonocore, M. H., & Farias, S. T. (2006). Intrasubject reproducibility of functional MR imaging activation in language tasks. *AJNR Am J Neuroradiol*, 27(4), 938-944.
- [33] Hirsch, J., Ruge, M. I., Kim, K. H., Correa, D. D., Victor, J. D., Relkin, N. R., et al. (2000). An integrated functional magnetic resonance imaging procedure for preoperative mapping of cortical areas associated with tactile, motor, language, and visual functions. *Neurosurgery*, 47(3), 711-721; discussion 721-712.
- [34] Holodny, A. I., Schulder, M., Liu, W. C., Wolko, J., Maldjian, J. A., & Kalnin, A. J. (2000). The effect of brain tumors on BOLD functional MR imaging activation in the adjacent motor cortex: implications for image-guided neurosurgery. *AJNR Am J Neuroradiol*, 21(8), 1415-1422.
- [35] Hu, X. P., Yang, Z., LaConte, S., & Weng, X. C. (2008). Ranking and averaging independent component analysis by reproducibility (RAICAR). *Human Brain Mapping*, 29(6), 711-725.
- [36] Jack, C. R., Jr., Thompson, R. M., Butts, R. K., Sharbrough, F. W., Kelly, P. J., Hanson, D. P., et al. (1994). Sensory motor cortex: correlation of presurgical mapping with functional MR imaging and invasive cortical mapping. *Radiology*, 190(1), 85-92.
- [37] Jansen, A., Deppe, M., Schwindt, W., Mohammadi, S., Sehlmeier, C., Knecht, S. (2006). Interhemispheric dissociation of language regions in a healthy subject. *Arch Neurol*, 63, 1344-1346.
- [38] Jiang, T. Z., Wang, L., Zang, Y. F., He, Y., Liang, M., Zhang, X. Q., et al. (2006). Changes in hippocampal connectivity in the early stages of Alzheimer's disease: Evidence from resting state fMRI. *Neuroimage*, 31(2), 496-504.
- [39] Joel, S. E., Caffo, B. S., van Zijl, P. C., & Pekar, J. J. (2011). On the relationship between seed-based and ICA-based measures of functional connectivity. *Magn Reson Med*.
- [40] Kenet, T., Bibitchkov, D., Tsodyks, M., Grinvald, A., & Arieli, A. (2003). Spontaneously emerging cortical representations of visual attributes. *Nature*, 425(6961), 954-956.
- [41] Kiviniemi, V., Starck, T., Remes, J., Long, X., Nikkinen, J., Haapea, M., et al. (2009). Functional segmentation of the brain cortex using high model order group PICA. *Hum Brain Mapp*, 30(12), 3865-3886.
- [42] Krings, T., Reinges, M. H., Erberich, S., Kemeny, S., Rohde, V., Spetzger, U., et al. (2001). Functional MRI for presurgical planning: problems, artefacts, and solution strategies. *J Neurol Neurosurg Psychiatry*, 70(6), 749-760.
- [43] Krishnan, R., Raabe, A., Hattingen, E., Szelenyi, A., Yahya, H., Hermann, E., et al. (2004). Functional magnetic resonance imaging-integrated neuronavigation: correlation between lesion-to-motor cortex distance and outcome. *Neurosurgery*, 55(4), 904-914; discussion 914-905.

- [44] Kwong, K. K., Belliveau, J. W., Chesler, D. A., Goldberg, I. E., Weisskoff, R. M., Poncelet, B. P., et al. (1992). Dynamic magnetic resonance imaging of human brain activity during primary sensory stimulation. *Proc Natl Acad Sci U S A*, 89(12), 5675-5679.
- [45] Laufs, H., Krakow, K., Sterzer, P., Eger, E., Beyerle, A., Salek-Haddadi, A., et al. (2003). Electroencephalographic signatures of attentional and cognitive default modes in spontaneous brain activity fluctuations at rest. *Proc Natl Acad Sci U S A*, 100(19), 11053-11058.
- [46] Lee, C. C., Jack, C. R., Jr., & Riederer, S. J. (1998). Mapping of the central sulcus with functional MR: active versus passive activation tasks. *AJNR Am J Neuroradiol*, 19(5), 847-852.
- [47] Lee, C. C., Ward, H. A., Sharbrough, F. W., Meyer, F. B., Marsh, W. R., Raffel, C., et al. (1999). Assessment of functional MR imaging in neurosurgical planning. *AJNR Am J Neuroradiol*, 20(8), 1511-1519.
- [48] Lehericy, S., Cohen, L., Bazin, B., Samson, S., Giacomini, E., Rougetet, R., et al. (2000). Functional MR evaluation of temporal and frontal language dominance compared with the Wada test. *Neurology*, 54(8), 1625-1633.
- [49] Lehericy, S., Duffau, H., Cornu, P., Capelle, L., Pidoux, B., Carpentier, A., et al. (2000). Correspondence between functional magnetic resonance imaging somatotopy and individual brain anatomy of the central region: comparison with intraoperative stimulation in patients with brain tumors. *J Neurosurg*, 92(4), 589-598.
- [50] Leopold, D. A., Murayama, Y., & Logothetis, N. K. (2003). Very slow activity fluctuations in monkey visual cortex: implications for functional brain imaging. *Cereb Cortex*, 13(4), 422-433.
- [51] Liebenthal, E. (2011). Introduction to Brain Imaging. In: Biomechanics of the brain (Miller K, ed), pp 41-68. Springer Science+Business Media, LLC.
- [52] Liegeois, F., Connelly, A., Salmond, C. H., Gadian, D. G., Vargha-Khadem, F., & Baldeweg, T. (2002). A direct test for lateralization of language activation using fMRI: comparison with invasive assessments in children with epilepsy. *Neuroimage*, 17(4), 1861-1867.
- [53] Liu, H., Buckner, R. L., Talukdar, T., Tanaka, N., Madsen, J. R., & Stufflebeam, S. M. (2009). Task-free presurgical mapping using functional magnetic resonance imaging intrinsic activity. *J Neurosurg*, 111(4), 746-754.
- [54] Liu, Z. N., Zhou, Y., Liang, M., Tian, L. X., Wang, K., Hao, Y. H., et al. (2007). Functional disintegration in paranoid schizophrenia using resting-state fMRI. *Schizophrenia Research*, 97(1-3), 194-205.
- [55] Lowe, M. J. (2010). A historical perspective on the evolution of resting-state functional connectivity with MRI. *MAGMA*, 23(5-6), 279-288.

- [56] Lowe, M. J., Beall, E. B., Sakaie, K. E., Koenig, K. A., Stone, L., Marrie, R. A., et al. (2008). Resting state sensorimotor functional connectivity in multiple sclerosis inversely correlates with transcallosal motor pathway transverse diffusivity. *Hum Brain Mapp*, 29(7), 818-827.
- [57] Mantini, D., Perrucci, M. G., Del Gratta, C., Romani, G. L., & Corbetta, M. (2007). Electrophysiological signatures of resting state networks in the human brain. *Proc Natl Acad Sci U S A*, 104(32), 13170-13175.
- [58] Margulies, D. S., Bottger, J., Long, X., Lv, Y., Kelly, C., Schafer, A., et al. (2010). Resting developments: a review of fMRI post-processing methodologies for spontaneous brain activity. *MAGMA*, 23(5-6), 289-307.
- [59] McKiernan, K. A., D'Angelo, B. R., Kaufman, J. N., & Binder, J. R. (2006). Interrupting the "stream of consciousness": an fMRI investigation. *Neuroimage*, 29(4), 1185-1191.
- [60] Medina, L., Aguirre, E., Bernal, B., Altman, N. R. (2004). Functional MR inaging versus Wada test for evaulation of language laterlaization: cost analysis. *Radiology*, 230, 49-54.
- [61] Moeller, F., Maneshi, M., Pittau, F., Gholipour, T., Bellec, P., Dubeau, F., et al. (2011). Functional connectivity in patients with idiopathic generalized epilepsy. *Epilepsia*, 52(3), 515-522.
- [62] Murphy, K., Birn, R. M., Handwerker, D. A., Jones, T. B., & Bandettini, P. A. (2009). The impact of global signal regression on resting state correlations: are anti-correlated networks introduced? *Neuroimage*, 44(3), 893-905.
- [63] Nelles, G., Cramer, S. C., Schaechter, J. D., Kaplan, J. D., Finklestein, S. P. (1998). Quantitative assessment of mirroe movements after stroke. *Stroke*, 29(6), 1187-1187.
- [64] Nimsy, C., Ganslandt, O., Cerny, S., Hastreiter, P., Greiner, G., & Fahlbusch, R. (2000). Quantification of, visualization of, and compensation for brain shift using intraoperative magnetic resonance imaging. *Neurosurgery*, 47(5), 1070-1079.
- [65] Nimsy, C., Ganslandt, O., Hastreiter, P., & Fahlbusch, R. (2001). Intraoperative compensation for brain shift. *Surgical Neurology*, 56(6), 357-364.
- [66] Ogawa, S., Lee, T. M., Kay, A. R., & Tank, D. W. (1990). Brain magnetic resonance imaging with contrast dependent on blood oxygenation. *Proc Natl Acad Sci U S A*, 87(24), 9868-9872.
- [67] Okada, K., & Hickok, G. (2006). Identification of lexical-phonological networks in the superior temporal sulcus using functional magnetic resonance imaging. *Neuroreport*, 17(12), 1293-1296.
- [68] Park, C. H., Chang, W. H., Ohn, S. H., Kim, S. T., Bang, O. Y., Pascual-Leone, A., et al. (2011). Longitudinal changes of resting-state functional connectivity during motor recovery after stroke. *Stroke*, 42(5), 1357-1362.

- [69] Pouratian, N., Bookheimer, S. Y., Rex, D. E., Martin, N. A., & Toga, A. W. (2002). Utility of preoperative functional magnetic resonance imaging for identifying language cortices in patients with vascular malformations. *J Neurosurg*, 97(1), 21-32.
- [70] Pujol, J., Conesa, G., Deus, J., Vendrell, P., Isamat, F., Zannoli, G., et al. (1996). Presurgical identification of the primary sensorimotor cortex by functional magnetic resonance imaging. *J Neurosurg*, 84(1), 7-13.
- [71] Rutten, G. J., Ramsey, N. F., van Rijen, P. C., Noordmans, H. J., & van Veelen, C. W. (2002). Development of a functional magnetic resonance imaging protocol for intraoperative localization of critical temporoparietal language areas. *Ann Neurol*, 51(3), 350-360.
- [72] Sabsevitz, D. S., Swanson, S. J., Hammeke, T. A., Spanaki, M. V., Possing, E. T., Morris, G. L., 3rd, et al. (2003). Use of preoperative functional neuroimaging to predict language deficits from epilepsy surgery. *Neurology*, 60(11), 1788-1792.
- [73] Sadato, N., Yonekura, Y., Waki, A., Yamada, H., & Ishii, Y. (1997). Role of the supplementary motor area and the right premotor cortex in the coordination of bimanual finger movements. *J Neurosci*, 17(24), 9667-9674.
- [74] Sakoglu, U., Upadhyay, J., Chin, C. L., Chandran, P., Baker, S. J., Cole, T. B., Fox, G. B., Day, M., Luo, F. (2011). *Biochem Pharmacol*, 81(12), 1374-1387.
- [75] Skudlarski, P., Jagannathan, K., Calhoun, V. D., Hampson, M., Skudlarska, B. A., & Pearlson, G. (2008). Measuring brain connectivity: Diffusion tensor imaging validates resting state temporal correlations. *Neuroimage*, 43(3), 554-561.
- [76] Squire, L. R., & Stark, C. E. L. (2001). When zero is not zero: The problem of ambiguous baseline conditions in fMRI. *Proceedings of the National Academy of Sciences of the United States of America*, 98(22), 12760-12765.
- [77] Stark, C. E., & Squire, L. R. (2001). When zero is not zero: the problem of ambiguous baseline conditions in fMRI. *Proc Natl Acad Sci U S A*, 98(22), 12760-12766.
- [78] Talairach, J., Tournoux, P. (1998). Co-planar stereotaxic atals of the human brain. New York: Thieme Medical Publishers,
- [79] Tomaszewski Farias, S., Harrington, G., Broomand, C., & Seyal, M. (2005). Differences in functional MR imaging activation patterns associated with confrontation naming and responsive naming. *AJNR Am J Neuroradiol*, 26(10), 2492-2499.
- [80] van den Heuvel, M. P., & Hulshoff Pol, H. E. (2010). Exploring the brain network: a review on resting-state fMRI functional connectivity. *Eur Neuropsychopharmacol*, 20(8), 519-534.
- [81] Van Westen, D., Skagerberg, G., Olsrud, J., Fransson, P., & Larsson, E. M. (2005). Functional magnetic resonance imaging at 3T as a clinical tool in patients with intracranial tumors. *Acta Radiol*, 46(6), 599-609.

- [82] Voyvodic, J. T. (2006). Activation mapping as a percentage of local excitation: fMRI stability within scans, between scans and across field strengths. *Magn Reson Imaging*, 24(9), 1249-1261.
- [83] Voyvodic, J. T., Petrella, J. R., Friedman, A. H. (2009). fMRI activation mapping as a percentage of local excitation: consistent presurgical motor maps without threshold adjustment. *J Magn Reson Imaging*, 29, 751-759.
- [84] Wada, J., Rasmussen, T. (1960). Intracarotid injection of Sodium Amytal for the lateralization of cerebral speech dominance. Experimental and clinical observations. *J Neurosurg*, 17, 266-282.
- [85] Wang, Z., Liang, P., Jia, X., Qi, Z., Yu, L., Yang, Y., et al. (2011). Baseline and longitudinal patterns of hippocampal connectivity in mild cognitive impairment: Evidence from resting state fMRI. *J Neurol Sci*, 309, 79-85.
- [86] Wu, T., Wang, L., Hallett, M., Li, K., & Chan, P. Neural correlates of bimanual anti-phase and in-phase movements in Parkinson's disease. *Brain*, 133(Pt 8), 2394-2409.
- [87] Yan, C., Liu, D., He, Y., Zou, Q., Zhu, C., Zuo, X., et al. (2009). Spontaneous brain activity in the default mode network is sensitive to different resting-state conditions with limited cognitive load. *PLoS One*, 4(5), e5743.
- [88] Yetkin, F. Z., Mueller, W. M., Morris, G. L., McAuliffe, T. L., Ulmer, J. L., Cox, R. W., et al. (1997). Functional MR activation correlated with intraoperative cortical mapping. *AJNR Am J Neuroradiol*, 18(7), 1311-1315.
- [89] Yousry, T. A., Schmid, U. D., Jassoy, A. G., Schmidt, D., Eisner, W. E., Reulen, H. J., et al. (1995). Topography of the cortical motor hand area: prospective study with functional MR imaging and direct motor mapping at surgery. *Radiology*, 195(1), 23-29.
- [90] Zhang, D. Y., Johnston, J. M., Fox, M. D., Leuthardt, E. C., Grubb, R. L., Chicoine, M. R., et al. (2009). Preoperative Sensorimotor Mapping in Brain Tumor Patients Using Spontaneous Fluctuations in Neuronal Activity Imaged with Functional Magnetic Resonance Imaging: Initial Experience. *Neurosurgery*, 65(6), 226-236.
- [91] Zou, Q., Long, X., Zuo, X., Yan, C., Zhu, C., Yang, Y., et al. (2009). Functional connectivity between the thalamus and visual cortex under eyes closed and eyes open conditions: a resting-state fMRI study. *Hum Brain Mapp*, 30(9), 3066-3078.

