

We are IntechOpen, the world's leading publisher of Open Access books Built by scientists, for scientists

6,900

Open access books available

186,000

International authors and editors

200M

Downloads

Our authors are among the

154

Countries delivered to

TOP 1%

most cited scientists

12.2%

Contributors from top 500 universities



WEB OF SCIENCE™

Selection of our books indexed in the Book Citation Index
in Web of Science™ Core Collection (BKCI)

Interested in publishing with us?
Contact book.department@intechopen.com

Numbers displayed above are based on latest data collected.
For more information visit www.intechopen.com



Structural and Functional Magnetic Resonance Imaging in Hepatic Encephalopathy

Long Jiang Zhang, Guang Ming Lu and Hui Mao

Additional information is available at the end of the chapter

<http://dx.doi.org/10.5772/29563>

1. Introduction

Hepatic encephalopathy (HE) is a neuropsychiatric syndrome that develops in patients with severe liver diseases and/or portal-systemic shunting. HE is characterized by a wide spectrum of clinical manifestations, ranging from alterations of psychometric performance to stupor and coma (Rovira et al., 2008; Cordoba J., 2011). Several non-invasive neuroimaging techniques, such as particularly magnetic resonance imaging (MRI) and magnetic resonance spectroscopy (MRS), are used for the diagnosis and prognosis of HE. These MR techniques can identify and measure the abnormal accumulation and increase of metabolite, such as glutamine and glutamate (Glx) as a result of HE in the central nervous system (CNS). Under normal circumstances, these substances are efficiently metabolized by the liver. This chapter will review the pathophysiology of HE and its conventional MRI, MRS and functional MRI findings.

2. Pathophysiology of hepatic encephalopathy

Various hypotheses have been proposed to explain the complex neuropsychiatric syndrome seen in HE. Imbalance between inhibitory and excitatory neurotransmission and hyperammonemia is the primary and most widely accepted hypothesis for HE (Rovira et al., 2008; Butterth et al., 2003; Cordoba J., 2011; Cordoba & Minguczb., 2008). Downregulation of glutamate receptors and an increase in inhibitory neurotransmission result in clinical manifestations of HE. In addition, patients with liver failure or portal-systemic shunt surgery have elevated levels of circulating ammonia, which enters the brain through the blood-brain barrier, and increases the ammonia concentration in the cerebral blood up to

four fold (normally in the order of two) in liver failure. Hyperammonemia disease leads to profound astrocyte changes, including astrocyte swelling in acute HE and Alzheimer type II astrocyte changes in chronic HE (Matsusue et al., 2005).

3. Clinical features of hepatic encephalopathy

The Working Party at the 11th World Congresses of Gastroenterology, held in Vienna in 1998, recommended the nomenclature and types of HE (Table 1) (Ferenci et al., 2002). The West Haven criteria for semi-quantitative grading of HE are summarized in Table 2. HE can be classified in three main groups: episodic, chronic, and minimal, based on duration and characteristics of the clinical manifestations. Episodic HE is characterized by the development of an impaired mental state, neuromuscular abnormalities, asterixis (tremor, jerking movement of the wrist), fetor hepaticus (metcarpans pass into the lungs resulting in the presence of ammonia and ketones in the breath), and hyperventilation, which develops during a short period of time and fluctuates in severity. Chronic HE can be further classified into subgroups: relapsing HE and persistent HE. Relapsing HE manifests itself as frequent episodes of acute HE, while persistent HE refers to manifestations that do not reverse despite adequate treatment. Characteristic manifestations of severe persistent HE are dementia, Parkinsonism, or myelopathy in combination with neurologic involvement, such as ataxia, gait abnormalities, tremor (Rovira et al., 2008). Minimal HE refers to those patients HE type with cirrhosis or portal-systemic shunts who have subtly abnormal cognitive and/or neurophysiologic functions. These abnormalities cannot be detected by the standard clinical examination and can only be determined by a detailed assessment of the patient's history and a comprehensive neurologic evaluation of cognitive performance and motor functions. The neuropsychological features of the minimal HE type include abnormalities in executive functions, particularly in selective attention and psychomotor speed (Amodio et al., 2004). However, other abnormalities, such as memory impairments, are also seen (Amodio et al., 2004). A complete psychometric assessment by a neuropsychologist is the best way to determine the extent of the attention-related cognitive impairment of a HE patient. A large number of neuropsychologic tests, such as the number connection test (NCT), the line-tracing, and inhibitory control test have been developed and are applied to describe cognitive abnormalities in patients without any clinical evidence of HE (Ferenci et al., 2002; Amodio et al., 2010). Testing across various neuropsychological domains is probably the optimal approach in order to identify cognitive and motor system abnormalities, such as attention and fine motion control. A standardized test battery, including the NCT type A and NCT type B, the line-tracing, the serial-dotting, and the digit-symbol tests (PSE-Syndrome-Test) has a high specificity for HE as compared with other metabolic encephalopathies (Ferenci et al., 2002). Changes in EEG/evoked responses and neuroimaging findings are non-specific and may not be able to provide sufficient information for the diagnosis of minimal HE.

HE type	Nomenclature	Subcategory	Subdivisions
A	Encephalopathy associated with acute liver failure		
B	Encephalopathy associated with portal-systemic bypass and no intrinsic hepatocellular disease		
C	Encephalopathy associated with cirrhosis and portal cirrhosis and portal hypertension/ or portal-systemic shunts	Episodic HE	Precipitated, spontaneous, recurrent
		Persistent HE	Mild, severe, treatment-dependent
		Minimal HE	

Table 1. The nomenclature of HE

Grade	Criteria
1	Trivial lack of awareness, euphoria or anxiety, shortened attention span, impaired performance of addition
2	Lethargy or apathy, minimal disorientation for time or place, subtle personality change, inappropriate behaviour, impaired performance of subtraction
3	Somnolence to semi stupor, but responsive to verbal stimuli; confusion; gross disorientation
4	Coma (unresponsive to verbal or noxious stimuli)

Table 2. West Haven criteria for semiquantitative grading of HE

4. Conventional MRI findings

In MRI exam of HE, bilateral hyperintensities at basal ganglia in T1 weighted images but without the corresponding abnormal T2 weighted signal intensity is a typical imaging feature of HE (Figure 1A). This imaging characteristic is attributed to hypermanganesemia (Gover et al., 2006; Mcphail & Taylor-Robinson., 2010).

The observed hyperintensities in bilateral basal ganglia on T1 weighted images can be reduced, or even disappear, after liver transplantation (Figure 1B and 1C) (Naegel et al., 2000; Cordoba et al., 2001; Long et al., 2009). However, no correlation between signal intensities on T2 weighted images in basal ganglia and the clinical encephalopathy or neuropsychological test performance was found, after a number of studies (Spahr et al., 2002; Thuluvath et al., 1995). Although mild brain oedema has been reported in the studies using other advanced MR sequences, no mild abnormalities can be detected in the conventional T1 and T2 weighted images, in addition to basal ganglia hyperintensity. Some studies reported high signal intensity at the centrum semiovale or corticospinal tract (along the hemispheric white matter in or around the corticospinal tract) on fast fluid attenuated inversion recovery (FLAIR) T2-

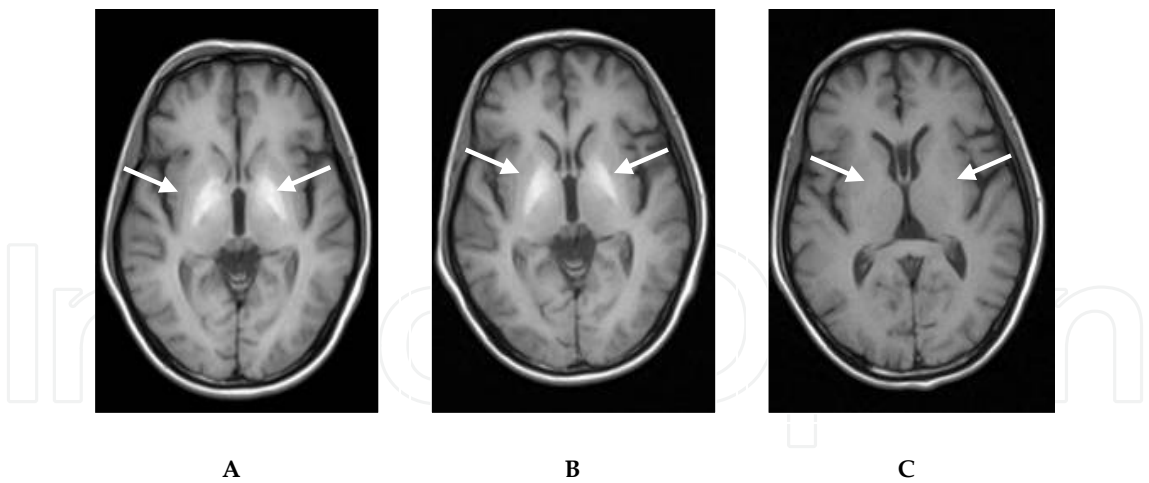


Figure 1. T1 weighted spin echo images of a selected axial brain section from a patient before and after receiving liver transplantation A) An axial T1 weighted image shows the symmetrical areas with high intensity in bilateral basal ganglia (arrows) before liver transplantation; B) 1 week after liver transplantation; and C) 4 months after liver transplantation, noticing that the symmetrical high intensity in bilateral basal ganglia shown in A, B, has disappeared.

weighted images (Figure 2) (Mínguez et al., 2007; Rovira et al., 2008). This is strikingly similar to signalintensity abnormalities noted in cases of amyotrophic lateral sclerosis, a neurodegenerative disease that affects motor neurons. The progressive normalization of the abnormal high signal-intensity in patients with cirrhosis can be found after the successful liver transplantation or effective treatment (Mínguez et al., 2007; Rovira et al., 2008). Therefore, observation of FLAIR white matter hyperintensities without additional imaging sequences, such as T2 weighted images cannot be used to diagnose HE.

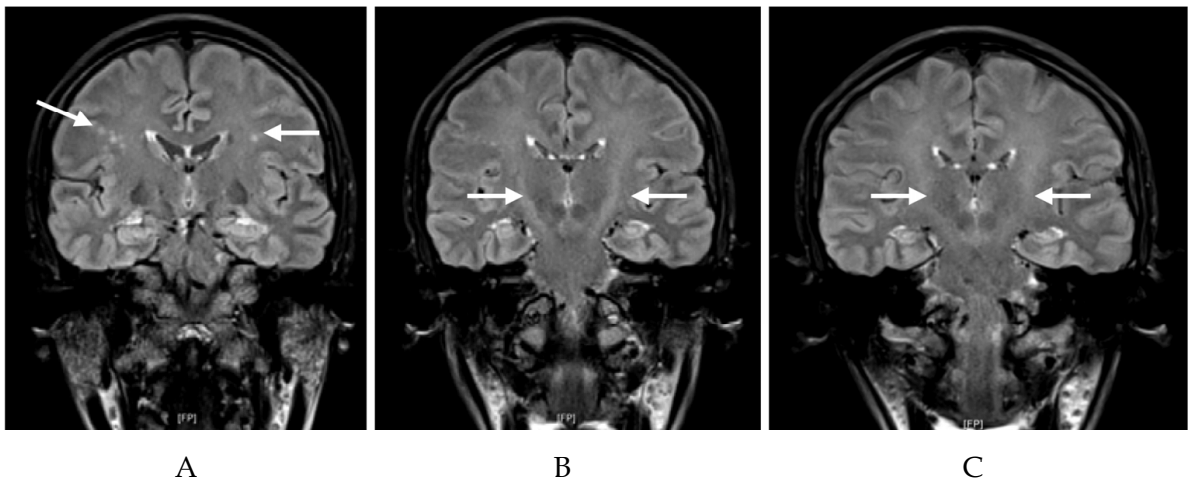


Figure 2. Coronal FLAIR images of a cirrhotic patient A to C. Coronal FLAIR images show the areas with abnormal high signal intensity in or around the corticospinal tract (arrows).

5. Magnetic transfer imaging (MTI)

Magnetic transfer imaging (MTI) is a singular MRI technique that has been shown to be useful in the diagnosis of HE. It is mainly based on the interaction (cross-relaxation) between protons in a relatively free environment and those in which motion is restricted (immobile water). Exchange of the saturated magnetization with free water reduces the signal intensity observed in the subsequent MR images. The degree of the signal-intensity loss depends on the attenuation of the macromolecules in a given tissue. MTI allows the measurement of magnetic transfer ratios (MTR), which reflect brain parenchymal changes that may not be visible using the standard MR techniques (Mcphail & Taylor-Robinson., 2010; Grover et al., 2006). Lower MTR can be the result of pathologies that alter the structural integrity and the relative macromolecular-water composition of brain parenchyma, such as in multiple sclerosis plaques (Rovira et al., 1999) or in end-stage cirrhosis (Rovira et al., 2001). Severe MTR decrease may be attributed to the demyelination and axonal loss, but a less severe decrease can be the result of inflammation and moderate demyelination.

All studies using MTI in HE found reduced MTR values in the examined brain regions of HE patients compared to those of controls (Miese et al., 2006; Miese et al., 2009; Poveda et al., 2010). Observed MTR decrease is mild (approximately 10%) and is not accompanied by significant abnormalities on conventional T1-and T2-weighted images, compared with the other metabolic and neurodegenerative diseases, such as experimental autoimmune encephalomyelitis, toxic demyelination, progressive multifocal leukoencephalopathy, human immunodeficiency virus encephalitis, and multiple sclerosis. The MTR reduction seems to have a temporal process in HE, an early involvement of basal ganglia and white matter has been shown (Miese et al., 2009). The MTR decrease almost returns to normal values after liver transplantation, thus supporting the hypothesis that the reduced MTR values reflect mild reversible brain edema.

6. Diffusion weighted imaging and diffusion tensor imaging

Diffusion weighted imaging (DWI) is an MRI method that generates brain images based on the image contrast that is dependent on the mobility of H₂O molecules in the different tissue compartments (Thoeny & De Keyzer, 2011). Water molecule motion follows the principles of Brownian motion (Provenzale et al., 2006). In a container of water, molecules undergo free, thermally agitated diffusion, which is also called isotropic (means equal in all directions). However, limited diffusion is observed since the movement of water molecules is restricted by their interactions with cell membranes and macromolecules, causing the directional specific motion of water molecules in environments, which is called anisotropic diffusion (Figure 3). DWI derives its image contrast on the basis of differences in the mobility of protons (primarily associated with water) between tissues (Thoeny & De Keyzer., 2011). Apparent diffusion coefficient (ADC) is a measurement obtained from DWI that provides estimation of water motion. DWI has a potential to locate the compartment where the increase of mobility of water

molecules is more prominent. Therefore, it can be applied to differentiate cytotoxic oedema from vasogenic oedema in HE patients (Lodi et al., 2004; Mies et al., 2006; Sugimoto et al., 2008). Brain oedema refers to excess water accumulation in the intracellular and extracellular spaces of the brain. In cytotoxic oedema, there is shift of water from extracellular to intracellular compartments producing cellular swelling expressing low ADC, while in vasogenic oedema the reverse happens, producing increased ADC (Schaefer et al., 2000). Recent studies on the application of mean diffusivity measurements within normal-appearing white matter of chronic cirrhotic patients have shown significant increase in brain water diffusivity, which is more pronounced with increased severity of HE (Lodi et al., 2004). These diffusivity values correlated with neuropsychological impairment (Kumar et al., 2008) and increased venous ammonia (Lodi et al., 2004). These findings suggest an accumulation of water in the extracellular compartment and a hypothesis of cortical astrocytic swelling is not supported, but rather increased interstitial fluid or chronic demyelination (Lodi et al., 2004; Sugimoto et al., 2008; Miese et al., 2006) due to glutamine accumulation is cited as the cause of diffuse brain oedema in chronic liver failure (Lodi et al., 2004; Sugimoto et al., 2008; Miese et al., 2006).

On the other hand, the morphology and structure of tissues vary in different organs and pathologic states. Water motion occurs preferentially in some directions in certain tissues due to the presence of obstacles that limit molecular movement in some directions. Diffusion-tensor imaging (DTI) can be used to obtain anisotropy information about water diffusion in tissues when specific diffusion weighted gradients in at least six directions are applied. The most commonly used invariant indices for the measurement of anisotropic diffusions by DTI are; the relative anisotropy (RA), the fractional anisotropy (FA), and the volume ratio (VR) indices (Figure 4A). In brain imaging applications, these indices provide a quantitative measurement of the changes of white matter integrity in different brain regions that are affected by HE. Using DTI together with advanced fibre-tracking algorithms based on the obtained diffusion tensors, white matter tractography can be derived from DTI data. Therefore, it is possible to noninvasively construct 3D trajectories of neural tracts, allowing the modelling of white matter neural connectivity (Figure 4B) (Mukherjee et al., 2008a; Mukherjee et al., 2008).

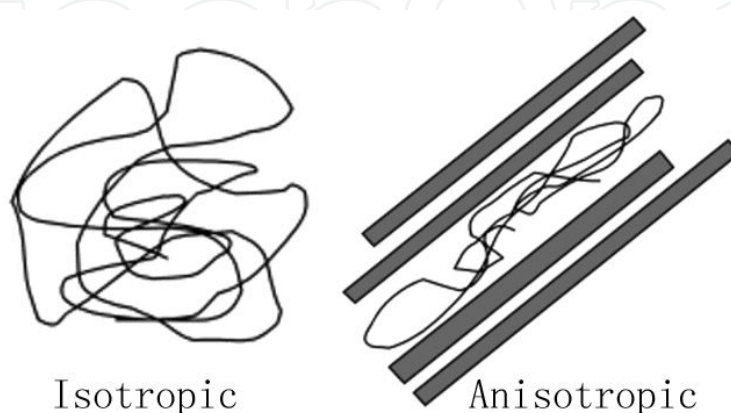


Figure 3. Schematic illustrations describe the isotropic diffusion and anisotropic restricted diffusion

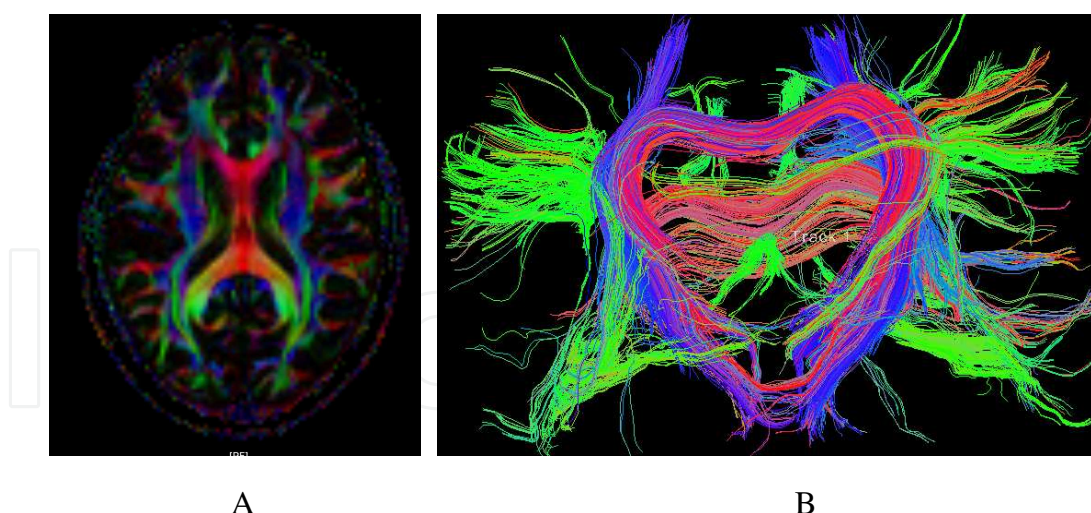


Figure 4. Presentations of diffusion tensor images of a cirrhotic patient acquired at a 3T MR scanner A. FA image, B. tractography of the brain derived from diffusion tensor imaging

FA, an index reflecting the white matter integrity, shows no significant changes in patients with chronic HE compared with normal subjects, indicating an absence of microstructural damage in these patients (Kale et al., 2006). Recently, a study by Chavarria et al. (Chavarria et al., 2010) into a rat model of acute liver failure provided experimental evidence to support the cytotoxic origin of brain oedema. Their results suggested that the metabolism of ammonia in astrocytes induces an increase of glutamine and lactate, which may mediate cortical cellular swelling. Saksena et al. (Saksena et al., 2007) also found decreased mean diffusivity values in patients with acute liver failure, suggesting an increase in the intracellular brain water content. Other studies also found decreased ADC value and high cortical signal intensity in patients with acute HE (McKinney et al., 2010; Toru et al., 2011). Therefore, it appears that two different types of brain oedema, intracellular in acute forms and probably interstitial in chronic forms, may exist in liver failure.

7. Magnetic Resonance Spectroscopy (MRS)

MRS is a non-invasive analytical method for analysing brain metabolites, often accompanied by MRI in neuroradiology practices. MR spectroscopic analysis offers a tool to interrogate the molecular process within body tissue and fluids in vivo and in vitro. In clinical application, MRS is capable of identifying and measuring the individual chemicals in the brain regions localized and sampled from MR images. ^1H MRS can provide information about brain metabolites such as choline (Cho), creatine (Cr), N-acetyl aspartate (NAA), glutamine and glutamate (Glx), as well as osmolytes, such as myoinositol (mI) and taurine (Ross et al., 1994; Kreis R et al., 1992; Cordoba et al., 2002; Mcphail & Taylor-Robinson, 2010). NAA is a derivative of an amino acid found mostly in neurons; therefore, it is commonly considered as a measure of neuronal density. The peak at 3.19-3.24 ppm of MR spectra obtained in vivo represents a total Cho, including soluble membrane phospholipids: phosphorylcholine (PCho), glycerol-

phosphocholine (GPC) and a relatively small amount of free choline. PCho is involved in the synthesis of the insoluble membrane phospholipids (Vance DE, 1996), while GPC is a product of membrane degradation and free choline is involved in synthesis of the neurotransmitter, acetylcholine, as well as of membrane synthesis (Michel et al., 2006). An increase in the total Cho peak is associated with an increase in membrane breakdown or turnover, myelination or inflammation (Astley et al., 2009). The peak of Cr spectrum is assigned at 3.02 ppm. This peak represents a combination of molecules containing creatine and phosphocreatine. When energy supply is insufficient from the Krebs's cycle, ATP is produced from adenosine diphosphate (ADP) instead of glucose. This reaction is buffered by the phosphocreatine–creatine (PCr–Cr) system, where PCr donates a phosphate group to become Cr. It is assumed that the Cr peak reflects energy use. Glutamine and glutamate (Glx) are amino acids. Glutamate is the most abundant amino acid in the brain and is released by approximately 90% of excitatory neurons. The spectral peaks of these molecules are often grouped together as Glx in the spectra obtained at the low field, because their overlap makes it hard to resolve them separately. Two compounds become increasingly separated in the higher magnetic fields; therefore, with the increasing clinical availability of stronger magnets, there is growing importance and interests in studying these compounds. Myo-inositol (mI), a simple sugar-alcohol compound, and precursor for inositol lipid synthesis, is a putative glial cell marker because it is located primarily in glial cells and not in neurons. Astrocytes, microglia, and macrophages have been shown to increase their levels of the Na⁺/mI cotransporter (SMIT) in response to stress or injury and an accumulation of mI, suggesting a role of this compound in inflammation and a marker for astrogliosis and microglia activity (Gupta et al., 2010).

¹H MRS has been extensively used in HE studies and has consensus findings on the intracellular metabolite changes in HE. Typical ¹H MRS findings of HE include: lower Cho/Cr and mI/Cr and higher Glx/Cr in all examined brain regions compared with controls (Figure 5) (Taraow et al., 2003; Weissenborn et al., 2004; Stewart et al., 2005; Mechtcheriakov et al., 2005; Miese et al., 2006; Weissenborn et al., 2007; Verma et al., 2008). Ammonia plays an important role in the series of metabolite changes in patients with cirrhosis. The increase in brain glutamine during HE increases intracellular osmolality. To maintain osmotic equilibrium, the astrocytes lose osmolytes such as mI and Cho, and a large amount of water enters the astrocyte and results in cellular swelling and impairment of cellular metabolism, further influencing neuronal and astrocyte function and the interaction between them. MRS measurable metabolite changes have been shown to correlate with improved psychometric performance (Binesh et al., 2006) following treatment (Haseler et al., 1998) and following liver transplantation (Naegel et al., 2000; Córdoba et al., 2001; Long et al., 2009). Recent pilot studies on in vitro ¹H MRS of human blood or urine in acute liver failure have demonstrated significant metabolite abnormalities between survivors and nonsurvivors (Saxena et al., 2006). They found glutamine in serum and the urine glutamine: creatinine ratio was higher in non-surviving patients compared with surviving patients [serum glutamine, 3.08 (1.68–7.11) vs. 0.56 (0.34–0.99) mM, median and range; $P=0.0001$ and urine glutamine:creatinine ratio, 1.72 (0.24–7.76) vs. 0.39 (0.1–0.84), $P=0.1$], and urine urea:creatinine ratio was higher in surviving patients compared with non-surviving patients [10.83 (0.2–22.6) vs. 2.09 (0.96–4.0), $P=0.002$]. Their study indicated MRS had a potential use for clinical decision making about the need for advanced therapeutic

intervention, such as artificial liver support or emergency liver transplantation in acute liver failure. Of these available MRS measurements, mI seems to be a more sensitive biomarker than Cho to detect HE. mI levels were negatively related to the Child-Pugh score and degree of HE (Lee et al., 1999; Zhang et al., 2010). However, values in a normal range have not been established and the diagnostic accuracy of 1H-MRS remains uncertain.

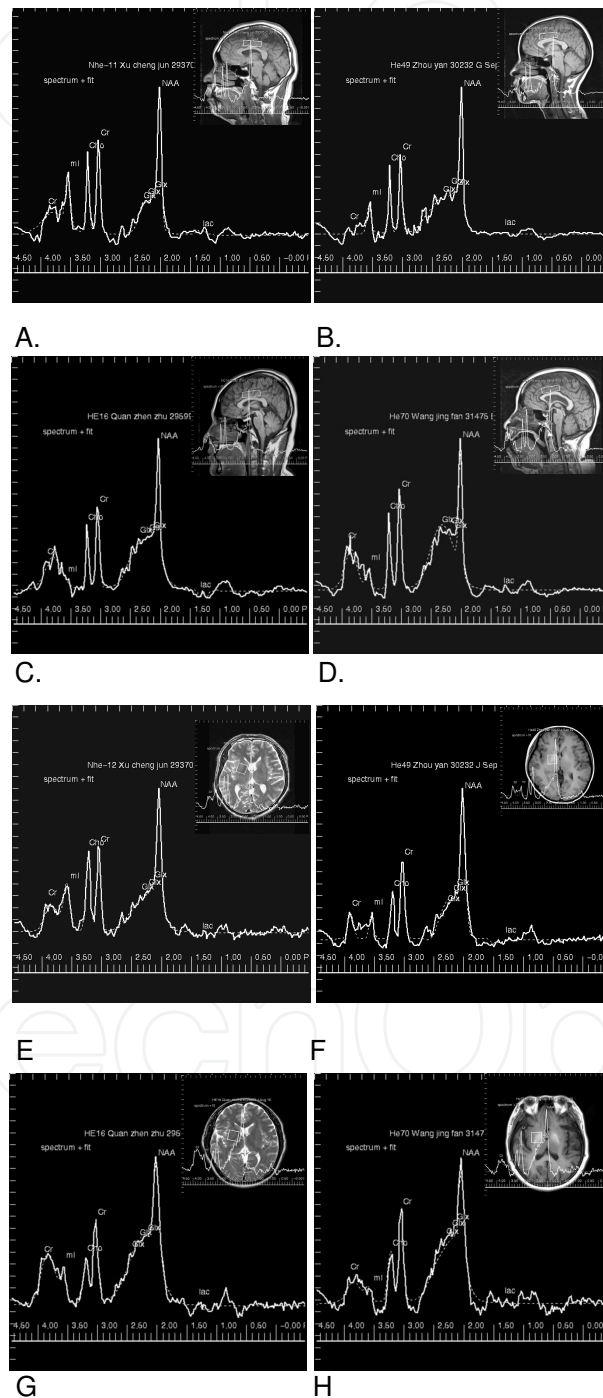


Figure 5. A set of brain MR spectra of HE patients and normal control A) A MRS spectrum obtained from the anterior cingulate cortex (ACC) of a healthy adult. B) A MRS spectrum of the anterior cingulate cortex from a 25-year-old fe-

male cirrhotic patient. C) MRS of the anterior cingulate cortex of a 44-year-old minimal hepatic encephalopathy (MHE) patient shows decreased ml and increased Glx. D) MRS of anterior cingulate cortex of a 70-year-old HE patient shows decreased ml and Cho and increased Glx. E) MRS of right basal ganglia of the same subject as in A). F) MRS of right basal ganglia in the same patient as in B) shows decreased ml and Cho. G) MRS of right basal ganglia of the same patient as in (C) shows decreased ml and Cho and increased Glx. H) MRS of right basal ganglia of the same patient in (D) shows decreased ml and Cho and increased Glx. The spectra were collected using single voxel PRESS sequence at 1.5T scanner.

In clinical practice, accurately differentiating some metabolites, such as Glx and taurine, can be challenging with the clinical MR scanners currently available. Two-dimensional MR spectroscopy may enhance the spectral resolution to distinguish metabolites based on J coupling patterns of individual molecules. On the other hand, more sophisticated statistical techniques, such as principal components analysis (PCA), enable assessment of the variation in individual metabolites based on the data obtained from MRS measurements (Barba et al., 2008; Singhal et al., 2010). These techniques can provide quantitative information of metabolic processes and changes in the diseased tissue, and therefore can be helpful in the understanding of HE pathogenesis. Wide availability of 3 Tesla MR scanners, as well as short TE acquisition, can improve the spectral resolution and thus, allow the differentiation of Glx from NAA (Sawara et al., 2004).

8. Blood oxygen level dependent functional MRI

Functional magnetic resonance imaging (fMRI) detects blood oxygen level-dependent (BOLD) changes in MRI signal that arise when changes in neuronal activity occur in a region of the brain after responding to a stimulus or performing a specific task (Ogawa et al., 1992). The BOLD signal is the ratio of oxy-haemoglobin to deoxy-haemoglobin during brain activation (Gore JC., 2003).

According to experimental paradigms, fMRI can be classified to task-related and resting state fMRI. In task-related fMRI design, a subject is placed in the magnet of an MRI machine, where various different kinds of stimulus are administered in a controlled fashion. Two main experimental paradigms are commonly used in task-related fMRI studies: block design and event-related paradigms (Gore JC., 2003). In resting state fMRI, the participants are required to rest in the absence of any external stimulation as well as guided to avoid reiterating any goal-directed thought pattern in their heads (Damoiseaux et al., 2006).

Many behavioural studies have claimed the existence of attention alterations in cirrhotic patients without overt HE (Zhang et al., 2007a; Randolph et al., 2009; Bajaj et al., 2009). There are only a few fMRI studies into HE. Zafiris et al. (Zafiris et al., 2004) first analysed the pathologically impaired neural mechanisms of cirrhotic patients using fMRI. Nine subjects with minimal HE (MHE) and 10 controls underwent scanning while they indicated the apparent transition from a steady light to the onset of a flicker light. Judgment-related BOLD activation was decreased in MHE patients compared to controls in the right inferior parietal cortex (IPL). Impaired neural interaction between the IPL and the parietooccipital cortex (Poc), the intraparietal sulcus, the anterior cingulate cortex (ACC), the right

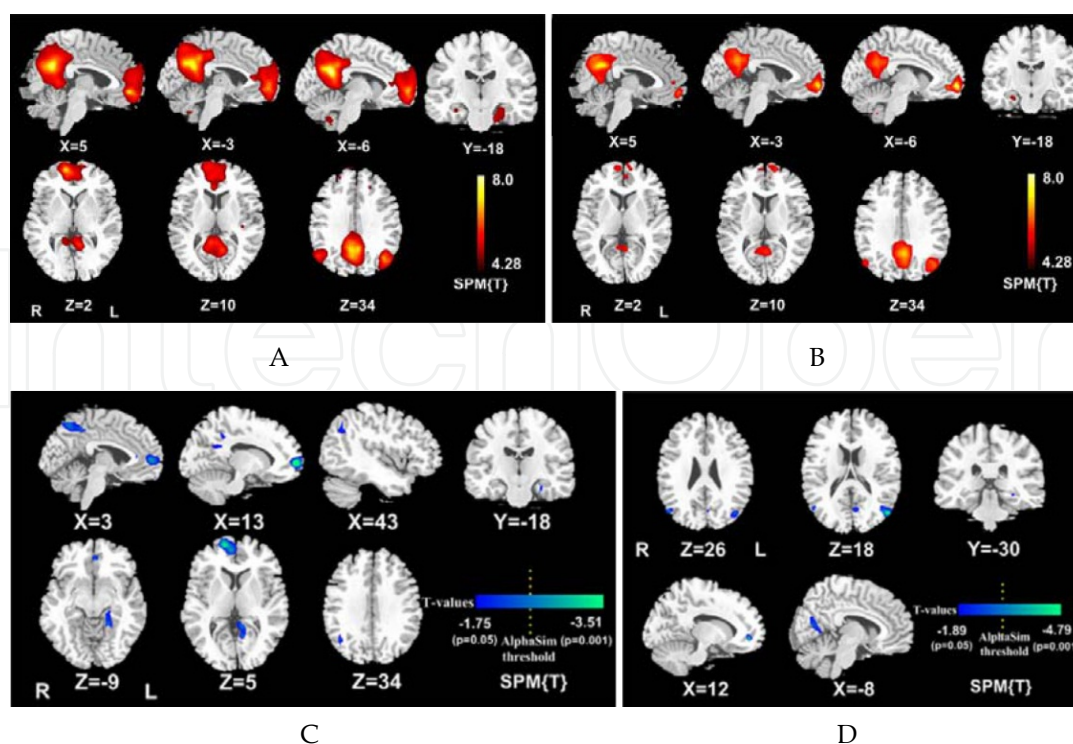


Figure 6. Default mode network changes of HE patients A) DMN of the controls consists of bilateral precuneus/posterior cingulate cortex, medial prefrontal cortex, anterior cingulate cortex, angular gyri, and temporal pole ($P < 0.05$, FDR corrected). B) DMN of HE patients consists of bilateral precuneus/posterior cingulate cortex, medial prefrontal cortex, anterior cingulate cortex, angular gyri, and temporal pole ($P < 0.05$, FDR corrected). Patterns in the HE patients are similar but with a reduced size compared to the ones of normal subjects in (A). C) Differences between the DMN of the HE patients and the controls are noted in the left posterior cingulate cortex and bilateral precuneus, right angular gyrus, bilateral middle frontal cortex, and left parahippocampus ($P < 0.05$ for all, uncorrected) and in the right middle frontal gyrus and left posterior cingulate cortex ($P < 0.05$ corrected, combined height threshold $P < 0.01$ and a minimum cluster size of 24 voxels). D) Statistical t-maps of the venous blood ammonia against z-scores in ICA in the HE group. The right middle frontal gyrus, left posterior cingulate cortex, left parahippocampus, bilateral angular gyri ($P < 0.05$ for all, uncorrected) and the left angular gyrus colour-coded bright blue ($P < 0.05$ corrected, combined height threshold $P < 0.01$ and a minimum cluster size of 24 voxels) had a negative correlation with venous blood ammonia. From Zhang et al., Brain default-mode network abnormalities in hepatic encephalopathy: a resting-state functional MRI study. Hum Brain Mapp, 2011, DOI:10.1002/hbm.21295, with permission

prefrontal cortex (PFC), the medial temporal lobe, and the extrastriate cortex V5 and an enhanced coupling between IPL and the postcentral cortex were found in MHE patients. This study demonstrated an impaired and compensatory neural mechanism during visual judgment in the earliest stages of HE. Zhang et al. (Zhang et al., 2007a) used a Chinese character Stroop task as the target stimulus to investigate the neural mechanism of the cognitive control impairment in cirrhotic patients using fMRI. This study showed that simple tasks (incongruous word-reading tasks) increased the activity of the precentral and postcentral gyri in cirrhotic patients, and harder tasks (incongruous colour-naming tasks) decrease the activity of bilateral superior frontal gyrus, middle frontal gyrus, inferior frontal gyrus, medial wall frontal gyrus, ACC, temporal cortex, and parietal cortex. This study provides suggests that the abnormal anterior cingulate cortex–prefrontal cortex–parietal “fusiform” cortex circuit could be the neural substrate responsible for this impaired

cognitive control. However, the task-induced fMRI is better suited to the patients with low-grade or MHE who can perform the test tasks (Mcphail and Taylor-Robinson, 2010).

Recently, increasing attention has been given to detecting brain activities during resting state (Greicius et al., 2003; Greicius et al., 2004; Zhang et al., 2007b; Zhang et al., 2011). Most reported resting-state network components include; the default mode network (DMN), the sensorimotor component, the executive control component, up to three visual components, two lateralized fronto-parietal components, the auditory component and the temporoparietal component (Rosazza & Minati, 2011). As already reported, these resting-state networks consist of anatomically distinct, but functionally connected regions, which display a high level of correlated BOLD signal activity. Nowadays the DMN is the most studied network in comparison to task-induced brain networks. DMN includes the medial prefrontal cortex, rostral anterior cingulate, posterior cingulate cortex (PCC), and precuneus (Greicius et al., 2003; Greicius et al., 2004). The DMN is described by increased activity during rest, while decreased activation suppressed during cognitively demanding tasks, such as visual and auditory attention, language processing, memory, and motor activities. Abnormal default function network has been known to relate to Alzheimer disease (AD), autism, attention deficit hyperactivity disorder, schizophrenia, epilepsy, and other diseases (et al., 2005; Rombouts et al., 2005; Kennedy et al., 2006; Liang M, et al., 2006; Tian et al., 2006).

In a study by Zhang et al. (Zhang et al., 2007), the DMN of the cirrhotic patients was investigated using a block-design in which a modified Chinese Stroop task was used as the target stimulus. In this study, a subtraction method was used to study the resting-state network in patients with hepatic cirrhosis. The functional data suggest that cirrhotic patients may have a deactivated DMN. The absence of deactivation in the PCC and precuneus may be a sensitive, rather than specific, marker in patients with hepatic cirrhosis. Recently, in a resting state fMRI study (Zhang et al., 2011), a significantly reduced functional connectivity in the right middle frontal gyrus, left precuneus, and left PCC in the HE patients was observed when compared to the controls. A negative correlation was shown between left angular gyrus and left PCC activation and venous blood ammonia levels, suggesting this can be an important biomarker for HE (Figure 6).

9. Conclusion

In conclusion, HE appears as diffuse mild brain oedema, and is associated with cognition functional changes such as attention, and functional brain area changes, such as default mode brain areas. HE-associated functional and physiological abnormalities have been demonstrated by a variety of MR techniques. MRI offers a range of capabilities for investigating HE in clinical diagnosis. The recent development of fMRI and MRS expands the applications of the study of HE with the capability of assessing functional changes in brain affected by HE. These advances opens up the opportunities to better understand the pathopsychological mechanisms of HE.

Acknowledgements

We express our thanks for the grants from Natural Scientific Foundation of China (81322020, 81230032, and 81171313 to L.Z.) and the Program for New Century Excellent Talents in the University (NCET-12-0260 for L.Z.).

Author details

Long Jiang Zhang¹, Guang Ming Lu¹ and Hui Mao²

¹ Department of Medical Imaging, Jinling Hospital, Medical School of Nanjing University, Nanjing, China

² Department of Radiology, Emory University School of Medicine, Atlanta, Georgia, USA

References

- [1] Amodio P, Montagnese S, Gatta A, Morgan MY (2004) Characteristics of minimal hepatic encephalopathy. *Metab Brain Dis* 19:253-26
- [2] Amodio P, Ridola L, Schiff S, et al. (2010) Improving the inhibitory control task to detect minimal hepatic encephalopathy. *Gastroenterology* 139:510-51
- [3] Astley SJ, Richards T, Aylward EH, et al. (2009) Magnetic resonance spectroscopy outcomes from a comprehensive magnetic resonance study of children with fetal alcohol spectrum disorders. *Magn Reson Imaging* 27:760-77
- [4] Bajaj JS, Wade JB, Sanyal AJ (2009) Spectrum of neurocognitive impairment in cirrhosis: Implications for the assessment of hepatic encephalopathy. *Hepatology* 50:2014-202
- [5] Barba I, Chatauret N, Garcia-Dorado D, Cordoba J (2008) A ¹H nuclear magnetic resonance-based metabonomic approach for grading hepatic encephalopathy and monitoring the effects of therapeutic hypothermia in rats. *Liver Int* 28:1141-114
- [6] Binesh N, Huda A, Thomas MA, et al. (2006) Hepatic encephalopathy: a neurochemical, neuroanatomical, and neuropsychological study. *J Appl Clin Med Phys* 7:86-9
- [7] Butterworth RF (2003) Pathogenesis of hepatic encephalopathy: new insights from neuroimaging and molecular studies. *J Hepatol* 39:278-28
- [8] Chavarria L, Oria M, Romero-Gimenez J, Alonso J, Lope-Piedrafita S, Cordoba J (2010) Diffusion tensor imaging supports the cytotoxic origin of brain edema in a rat model of acute liver failure. *Gastroenterology* 138:1566-157

- [9] Córdoba J (2011) New assessment of hepatic encephalopathy. *J Hepatol* 54:1030-104
- [10] Córdoba J, Alonso J, Rovira A, et al. (2001) The development of low-grade cerebral edema in cirrhosis is supported by the evolution of (1)H-magnetic resonance abnormalities after liver transplantation. *J Hepatol* 35:598-60
- [11] Córdoba J, Mínguez B (2008) Hepatic encephalopathy. *Semin Liver Dis* 28:70-8
- [12] Córdoba J, Sanpedro F, Alonso J, Rovira A (2002) 1H magnetic resonance in the study of hepatic encephalopathy in humans. *Metab Brain Dis* 17:415-42
- [13] Damoiseaux JS, Rombouts SA, Barkhof F, et al. (2006) Consistent resting-state networks across healthy subjects. *Proc Natl Acad Sci U S A* 103:13848-1385
- [14] Dupont S, Duron E, Samson S, et al. (2010) Functional MR imaging or Wada test: which is the better predictor of individual postoperative memory outcome? *Radiology* 255:128-13
- [15] Ferenci P, Lockwood A, Mullen K, Tarter R, Weissenborn K, Blei AT (2002) Hepatic encephalopathy--definition, nomenclature, diagnosis, and quantification: final report of the working party at the 11th World Congresses of Gastroenterology, Vienna, 1998. *Hepatology* 35:716-72
- [16] Gore JC (2003) Principles and practice of functional MRI of the human brain. *J Clin Invest* 112:4–
- [17] Gotman J, Grova C, Bagshaw A, Kobayashi E, Aghakhani Y, Dubeau F (2005) Generalized epileptic discharges show thalamocortical activation and suspension of the default state of the brain. *Proc Natl Acad Sci U S A* 102:15236–1524
- [18] Greicius MD, Krasnow B, Reiss AL, Menon V (2003) Functional connectivity in the resting brain: a network analysis of the default mode hypothesis. *Proc Natl Acad Sci U S A* 100:253-25
- [19] Greicius MD, Srivastava G, Reiss AL, Menon V (2004) Default-mode network activity distinguishes Alzheimer's disease from healthy aging: evidence from functional MRI. *Proc Natl Acad Sci U S A* 101:4637-464
- [20] Grover VP, Dresner MA, Forton DM, et al. (2006) Current and future applications of magnetic resonance imaging and spectroscopy of the brain in hepatic encephalopathy. *World J Gastroenterol* 12:2969-297
- [21] Gupta RK, Yadav SK, Rangan M, et al. (2010) Serum proinflammatory cytokines correlate with diffusion tensor imaging derived metrics and (1)H-MR spectroscopy in patients with acute liver failure. *Metab Brain Dis* 25:355-36
- [22] Haseler LJ, Sibbitt WL Jr, Mojtahedzadeh HN, Reddy S, Agarwal VP, McCarthy DM (1998) Proton MR spectroscopic measurement of neurometabolites in hepatic encephalopathy during oral lactulose therapy. *AJNR Am J Neuroradiol* 19:1681- 168

- [23] Kale RA, Gupta RK, Saraswat VA, et al. (2006) Demonstration of interstitial cerebral edema with diffusion tensor MR imaging in type C hepatic encephalopathy. *Hepatology* 43:698-70
- [24] Kennedy DP, Redcay E, Courchesne E (2006) Failing to deactivate: resting functional abnormalities in autism. *Proc Natl Acad Sci U S A* 103:8275–828
- [25] Kreis R, Ross BD, Farrow NA, Ackerman Z (1992) Metabolic disorders of the brain in chronic hepatic encephalopathy detected with H-1 MR spectroscopy. *Radiology* 182:19-2
- [26] Kumar R, Gupta RK, Elderkin-Thompson V, et al. (2008) Voxel-based diffusion tensor magnetic resonance imaging evaluation of low-grade hepatic encephalopathy. *J Magn Reson Imaging* 27:1061-106
- [27] Lee JH, Seo DW, Lee YS, et al. (1999) Proton magnetic resonance spectroscopy (1H-MRS) findings for the brain in patients with liver cirrhosis reflect the hepatic functional reserve. *Am J Gastroenterol* 94:2206-221
- [28] Liang M, Zhou Y, Jiang T, et al. (2006) Widespread functional disconnectivity in schizophrenia with resting-state functional magnetic resonance imaging. *Neuroreport* 17:209–21
- [29] Lodi R, Tonon C, Stracciari A, et al. (2004) Diffusion MRI shows increased water apparent diffusion coefficient in the brains of cirrhotics. *Neurology* 62:762-76
- [30] Long LL, Li XR, Huang ZK, Jiang YM, Fu SX, Zheng W (2009) Relationship between changes in brain MRI and (1)H-MRS, severity of chronic liver damage, and recovery after liver transplantation. *Exp Biol Med (Maywood)* 234:1075-108
- [31] Matsusue E, Kinoshita T, Ohama E, Ogawa T (2005) Cerebral cortical and white matter lesions in chronic hepatic encephalopathy: MR-pathologic correlations. *AJNR Am J Neuroradiol* 26:347-35
- [32] McKinney AM, Lohman BD, Sarikaya B, et al. (2010) Acute hepatic encephalopathy: diffusion-weighted and fluid-attenuated inversion recovery findings, and correlation with plasma ammonia level and clinical outcome. *AJNR Am J Neuroradiol* 31:1471-147
- [33] McPhail MJ, Taylor-Robinson SD (2010) The role of magnetic resonance imaging and spectroscopy in hepatic encephalopathy. *Metab Brain Dis* 25:65-7
- [34] Mechtcheriakov S, Schocke M, Kugener A, et al. (2005) Chemical shift magnetic resonance spectroscopy of cingulate grey matter in patients with minimal hepatic encephalopathy. *Neuroradiology* 47:27-3
- [35] Michel V, Yuan Z, Ramsbair S, Bakovic M (2006) Choline transport for phospholipid synthesis. *Exp Biol Med (Maywood)* 231:490-50

- [36] Miese F, Kircheis G, Wittsack HJ, et al. (2006) ¹H-MR spectroscopy, magnetization transfer, and diffusion-weighted imaging in alcoholic and nonalcoholic patients with cirrhosis with hepatic encephalopathy. *AJNR Am J Neuroradiol* 27:1019-102
- [37] Miese FR, Wittsack HJ, Kircheis G, et al. (2009) Voxel-based analyses of magnetization transfer imaging of the brain in hepatic encephalopathy. *World J Gastroenterol* 15:5157-516
- [38] Mínguez B, Rovira A, Alonso J, Córdoba J (2007) Decrease in the volume of white matter lesions with improvement of hepatic encephalopathy. *AJNR Am J Neuroradiol* 28:1499-50
- [39] Mukherjee P, Berman JL, Chung SW, Hess CP, Henry RG (2008) Diffusion tensor MR imaging and fiber tractography: theoretic underpinnings. *AJNR Am J Neuroradiol* 29:632-64
- [40] Mukherjee P, Chung SW, Berman JL, Hess CP, Henry RG (2008) Diffusion tensor MR imaging and fiber tractography: technical considerations. *AJNR Am J Neuroradiol* 29:843-85
- [41] Naegelé T, Grodd W, Viebahn R, et al. (2000) MR imaging and (1)H spectroscopy of brain metabolites in hepatic encephalopathy: time-course of renormalization after liver transplantation. *Radiology* 216:683-69
- [42] Ogawa S, Tank DW, Menon R, et al. (1992) Intrinsic signal changes accompanying sensory stimulation: functional brain mapping with magnetic resonance imaging. *Proc Natl Acad Sci U S A* 89:5951–595
- [43] Poveda MJ, Bernabeu A, Concepción L, et al. (2010) Brain edema dynamics in patients with overt hepatic encephalopathy A magnetic resonance imaging study. *Neuroimage* 52:481-48
- [44] Provenzale JM, Mukundan S, Barboriak DP (2006) Diffusion-weighted and perfusion MR imaging for brain tumor characterization and assessment of treatment response. *Radiology* 239:632-64
- [45] Randolph C, Hilsabeck R, Kato A, et al. (2009) Neuropsychological assessment of hepatic encephalopathy: ISHEN practice guidelines. *Liver Int* 29:629-63
- [46] Rombouts SA, Barkhof F, Goekoop R, Stam CJ, Scheltens P (2005) Altered resting state networks in mild cognitive impairment and mild Alzheimer's disease: an fMRI study. *Hum Brain Mapp* 26:231–23
- [47] Rosazza C, Minati L (2011) Resting-state brain networks: literature review and clinical applications. *Neurol Sci* 2011; DOI 10.1007/s10072-011-0636-y
- [48] Ross BD, Jacobson S, Villamil F, et al. (1994) Subclinical hepatic encephalopathy: proton MR spectroscopic abnormalities. *Radiology* 193:457-46

- [49] Rovira A, Alonso J, Cordoba J (2008) MR imaging findings in hepatic encephalopathy. *AJNR Am J Neuroradiol* 29:1612–162
- [50] Rovira A, Alonso J, Cucurella G, et al. (1999) Evolution of multiple sclerosis lesions on serial contrast-enhanced T1-weighted and magnetization-transfer MR images. *AJNR Am J Neuroradiol* 20:1939–4
- [51] Rovira A, Grive' E, Pedraza S, et al. (2001) Magnetization transfer ratio values and proton MR spectroscopy of normal-appearing cerebral white matter in patients with liver cirrhosis. *AJNR Am J Neuroradiol* 22:1137–114
- [52] Rovira A, Mínguez B, Aymerich FX, et al. (2007) Decreased white matter lesion volume and improved cognitive function after liver transplantation. *Hepatology* 46:1485-149
- [53] Saksena S, Rai V, Saraswat VA, et al. (2008) Cerebral diffusion tensor imaging and in vivo proton magnetic resonance spectroscopy in patients with fulminant hepatic failure. *J Gastroenterol Hepatol* 23:e111-11
- [54] Sawara K, Kato A, Yoshioka Y, Suzuki K (2004) Brain glutamine and glutamate levels in patients with liver cirrhosis: assessed by 3.0-T MRS. *Hepatol Res* 30:18-2
- [55] Saxena V, Gupta A, Nagana Gowda GA, Saxena R, Yachha SK, Khetrapal CL (2006) ¹H NMR spectroscopy for the prediction of therapeutic outcome in patients with fulminant hepatic failure. *NMR Biomed* 19:521–52
- [56] Schaefer PW, Grant PE, Gonzalez RG (2000) Diffusion-weighted MR imaging of the brain. *Radiology* 217:331-34
- [57] Singhal A, Nagarajan R, Hinkin CH, et al. (2010) Two-dimensional MR spectroscopy of minimal hepatic encephalopathy and neuropsychological correlates in vivo. *J Magn Reson Imaging* 32:35-4
- [58] Spahr L, Burkhard PR, Gröttsch H, Hadengue A (2002) Clinical significance of basal ganglia alterations at brain MRI and ¹H MRS in cirrhosis and role in the pathogenesis of hepatic encephalopathy. *Metab Brain Dis* 17:399-41
- [59] Stewart CA, Reivich M, Lucey MR, Gores GJ (2005) Neuroimaging in hepatic encephalopathy. *Clin Gastroenterol Hepatol* 3:197-20
- [60] Sugimoto R, Iwasa M, Maeda M, et al. (2008) Value of the apparent diffusion coefficient for quantification of low-grade hepatic encephalopathy. *Am J Gastroenterol* 103:1413-142
- [61] Tarasów E, Panasiuk A, Siergiejczyk L, et al. (2003) MR and ¹H MR spectroscopy of the brain in patients with liver cirrhosis and early stages of hepatic encephalopathy. *Hepatogastroenterology* 50:2149-215
- [62] Thoeny HC, De Keyzer F (2011) Diffusion-weighted MR imaging of native and transplanted kidneys. *Radiology* 259:25-3

- [63] Thuluvath PJ, Edwin D, Yue NC, deVilliers C, Hochman S, Klein A (1995) Increased signals seen in globus pallidus in T1-weighted magnetic resonance imaging in cirrhotics are not suggestive of chronic hepatic encephalopathy. *Hepatology* 21:440-44
- [64] Tian L, Jiang T, Wang Y, et al. (2006) Altered resting-state functional connectivity patterns of anterior cingulate cortex in adolescents with attention deficit hyperactivity disorder. *Neurosci Letters* 400:39-4
- [65] Toru S, Matumura K, Kawaguchi R, Kobayashi T, Irie T (2011) Widespread cortical lesions on diffusion-weighted imaging in acute portal systemic shunt encephalopathy caused by primary biliary cirrhosis. *AJNR Am J Neuroradiol* 32:E55-5
- [66] Vance DE: Phospholipid biosynthesis. In: *Biochemistry of Lipids, Lipoproteins and Membranes*. Vance DE and Vance J (eds.). Amsterdam, Elsevier Science Publishers B. V., pp. 153-181, 199
- [67] Verma A, Saraswat VA, Radha Krishna Y, Nath K, Thomas MA, Gupta RK (2008). In vivo ¹H magnetic resonance spectroscopy-derived metabolite variations between acute-on- chronic liver failure and acute liver failure. *Liver Int* 28:1095-110
- [68] Weissenborn K, Ahl B, Fischer-Wasels D, et al. (2007) Correlations between magnetic resonance spectroscopy alterations and cerebral ammonia and glucose metabolism in cirrhotic patients with and without hepatic encephalopathy. *Gut* 56:1736-174
- [69] Weissenborn K, Bokemeyer M, Ahl B, et al. (2004) Functional imaging of the brain in patients with liver cirrhosis. *Metab Brain Dis* 19:269-28
- [70] Zafiris O, Kircheis G, Rood HA, Boers F, Haussinger D, Zilles K (2004) Neural mechanism underlying impaired visual judgement in the dysmetabolic brain: an fMRI study. *Neuroimage* 22:541-55
- [71] Zhang L, Qi R, Wu SY, et al. (2011) Brain default-mode network abnormalities in hepatic encephalopathy: a resting-state functional MRI study. *Human Brain Mapping* DOI: 10.1002/hbm.2129
- [72] Zhang LJ, Yang G, Yin J, Liu Y, Qi J (2007a) Neural mechanism of cognitive control impairment in patients with hepatic cirrhosis: a functional magnetic resonance imaging study. *Acta Radiol* 48:577-58
- [73] Zhang LJ, Yang G, Yin J, Liu Y, Qi J (2007b) Abnormal default-mode network activation in cirrhotic patients: a functional magnetic resonance imaging study. *Acta Radiol* 48:781-78
- [74] Zhang LJ, Yin JZ, Qi J, Lu GM (2010) Metabolic changes of anterior cingulate cortex in patients with hepatic cirrhosis: a magnetic resonance spectroscopy study. *Hepatol Res* 40:777-78