

We are IntechOpen, the world's leading publisher of Open Access books Built by scientists, for scientists

6,900

Open access books available

186,000

International authors and editors

200M

Downloads

Our authors are among the

154

Countries delivered to

TOP 1%

most cited scientists

12.2%

Contributors from top 500 universities



WEB OF SCIENCE™

Selection of our books indexed in the Book Citation Index
in Web of Science™ Core Collection (BKCI)

Interested in publishing with us?
Contact book.department@intechopen.com

Numbers displayed above are based on latest data collected.
For more information visit www.intechopen.com



35 Years in Research on Spinal Cord Lesions and Repair

Giorgio Brunelli

Additional information is available at the end of the chapter

<http://dx.doi.org/10.5772/56988>

1. Introduction

Paraplegia by spinal cord lesion is a severe condition which cannot be cured.

It is known since the ancient times as figured in the Ninive basrelief (fig 1) and described in the Smith papyrus (fig 2). Since those times it is known that the spinal cord, after severance does not allow healing.



Figure 1. Dying lioness with paraplegia (Ninive bas relief)



Figure 2. Smith papyrus describing the symptoms of cord lesion

It is due to the *nonpermissiveness* of the cord for the advancement of the axons that regrow from the brain neurons.

Not only walking is hindered but there is compromission of all the vegetative function and pression sores (fig 3) not to say the psicological damage of the patient and of his/her relatives and the social heavy burden for assistance and architectural modifications.

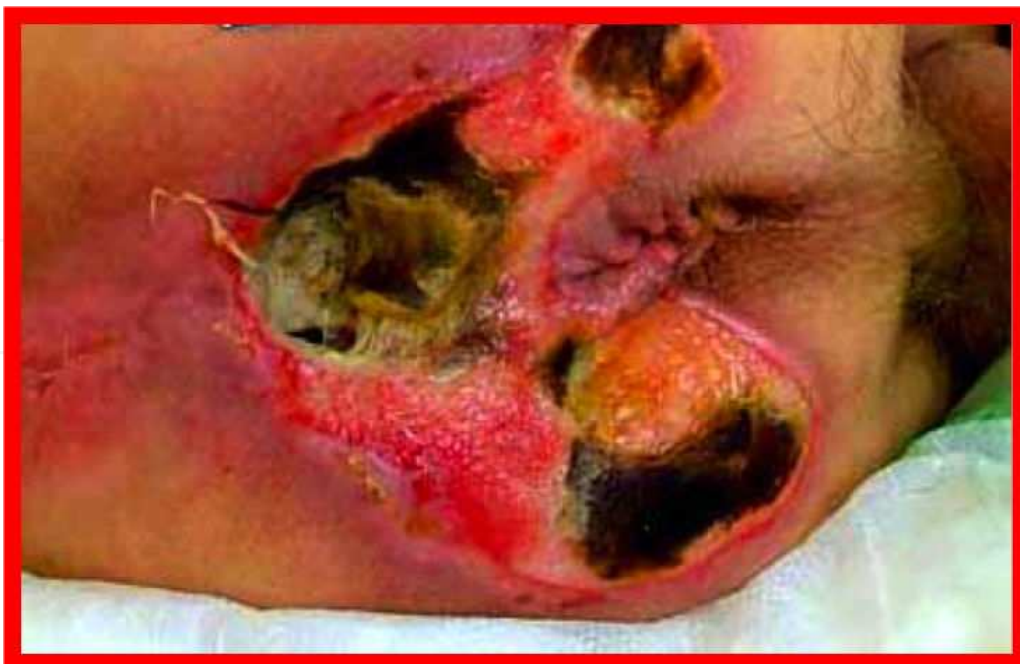

Figure 3. Ppressure sores in a paraplegic

Paraplegia by S.pinal Cord Injury is a very heavy burden:

- a. for patients who at the age of their most productive capacity are put in a wheelchair for life and undergo severe physical, economical and psychological problems.

(More than 2000 new cases a year occur in Italy and 18/20 cases every milion of inhabitants in the world),

2. for the families which must assist their relative from the economical, physical and psychological point of view and
3. for society and the country which have to supply medical assistance, economical support and architectural facilities.

Non permissiveness and incurability of paraplegia are a DOGMA.

Various explanations of this dogma have been tried without solution.

My research on spinal cord started in 1978 when, thinking that microsurgery had solved almost all the problems related to peripheral nerves lesions, I wondered why no surgical treatment was able to help regeneration of the spinal cord.

One of the hypotetical reason (besides the scar formation) was the lack (in the cord) of Schwann cells which support the regeneration of the nerve fibres in peripheral nerves.

This simplicistic idea pushed me to resect one centimeter of cord in rats and to put in the resulting gap several grafts of peripheral nerves (sciatic n.) which contain Schwann cells. (fig.4)

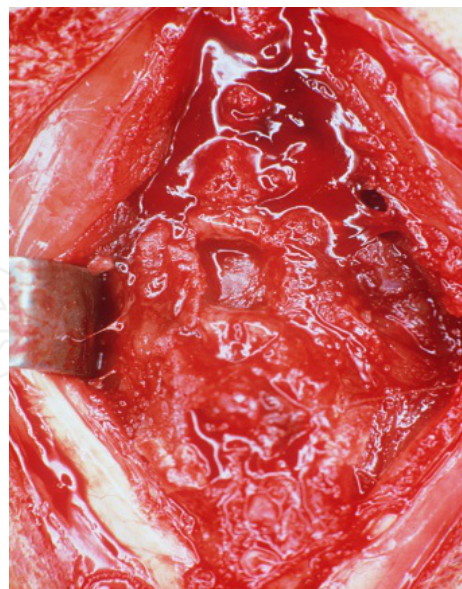


Figure 4. Removal of 1 cm of spinal cord in a rat

As a result I found that the grafts were reinhabited by the axons descending from the brain but that at the very end of the grafts the axons stopped progressing. (fig 5 and 6)

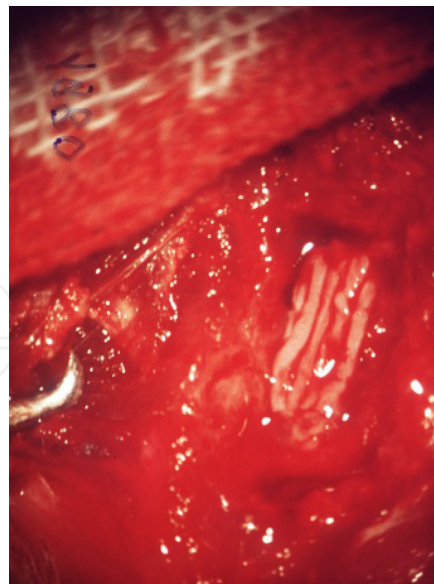


Figure 5. Grafts of sciatic nerve put in the cord of a rat after removal of 1 cm of cord.

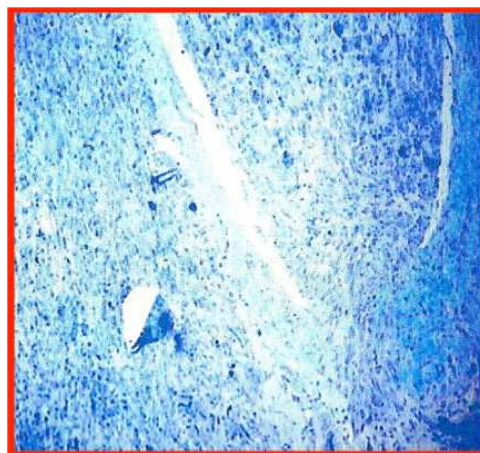

Figure 6. The graft has been reinhabited by the axons regrowing from the upper neurons but axons stopped progressing as soon as in contact again with the C.N.S. (cord). Only a few micron of progression was observed due to the exit of Schwann cells.

This fact confirmed the idea that the central nervous system (C.N.S. of which the cord is part) is “non permissive” for the regrowing axons progression inside it (perhaps due to specific “no-go” molecules).

Also I took part in the C.A.L.I.E.S. (Computer Assisted Locomotion by means of Implanted Electrical Stimulation) and S.U.A.W (Stand Up And Walk) (European programs intended to obtain walking by means of implanted electrical stimulation of muscles). (fig. 7) The electrical stimulation of the muscles was given by electrodes implanted in 8 muscles of each inferior limb by means of a control-unit implanted under the abdominal skin that received impulses from a computer through a transcutaneous antenna. (fig 8)



Figure 7. The team of the C.A.L.I.E.S program in Montpellier: VW: Von Wild, R: Rabishong, B: Brunelli

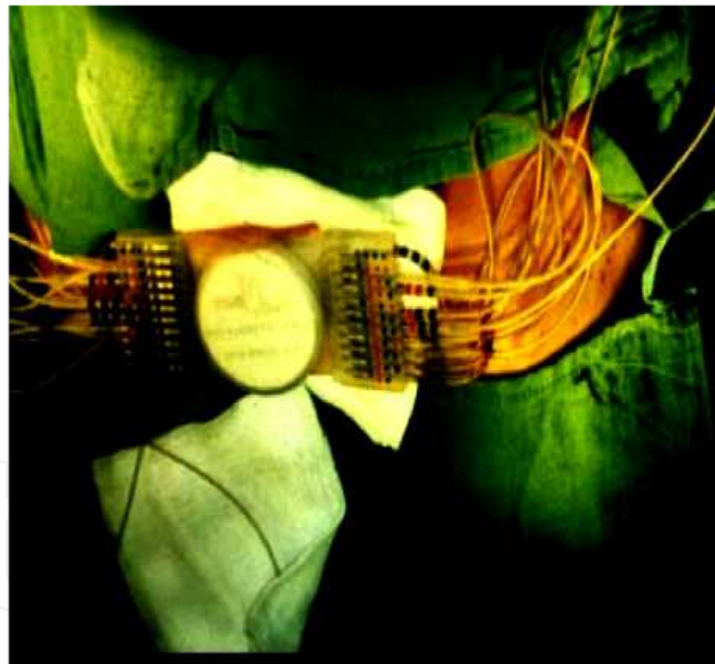


Figure 8. The multichannel control unit of the CALIES, to be implanted under the skin of the abdomen, connected with 8 muscles of the legs and stimulated transcutaneously by an antenna connected with the computer for stimulation of the muscles.

These experimental operations had to be abandoned due to the high cost of the electronic devices (not to say to the necessity for the paraplegics to pull a trolley with batteries and the computerized program that had been studied by means of a meticulous gait analysis that could not anyway change the recorded program of the computer in front of unanticipated obstacles).

My second step (1981) was the connection of the above the lesion cord (by means of a graft of peripheral nerve) to peripheral nerves and muscles. (fig 9 and 10).




Figure 9. Connection of the C.S.T. to peripheral nerves

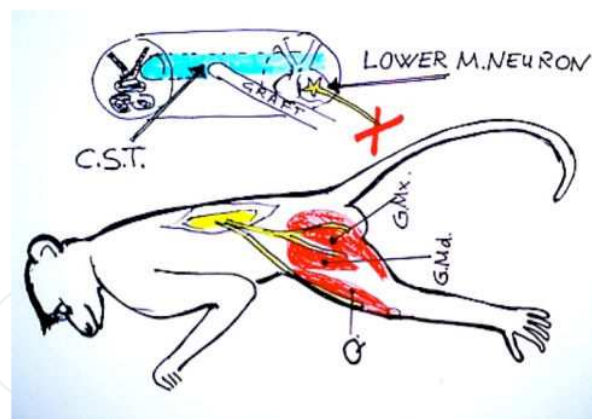


Figure 10. Sketch of the connection.

The regrowing axons elongated up to the muscle forming new motor end-plates and functional connections. (fig 11).

By this connection the result was effective and rats could walk, even if, of course, with some limitation. The presentation of these results at an international meeting (in San Antonio) stirred up a lot of skepticism: *"rats could walk even without any attempt of repairing the cord"* (which is not true).

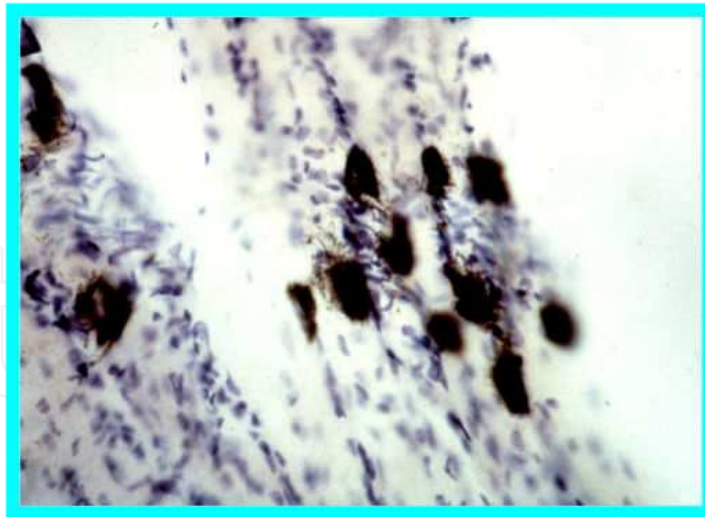


Figure 11. Motor-end plates newly formed at the contact of the graft with the muscle.

The advise was: go to primates. At that time I had not the facilities nor the permission for operating monkeys in Italy. Therefore I was compelled to go abroad and I found the friendly help of dr Carlstedt who hosted me in the primatology institute of the Karolinska Institutet in Solna (Stockolm). I and my staff operated on, over there, 20 “macaca fascicularis” connecting the above the lesion cord with peripheral nerves by means of autologous grafts and checking the results by means of clinical observation, electromyography, magnetic stimulation of both the nerve going to muscles and of the brain (after craniotomy) and histology of the cord and of the graft. (Fig 12,13, 14). Magnetic stimulation of the brain, external and after craniotomy as well as E.M.G. of the grafts and the muscles showed good muscle responses with different latency times according to the distance from the recording electrode (fig 15) The monkeys were able to move the reinnervated muscles.

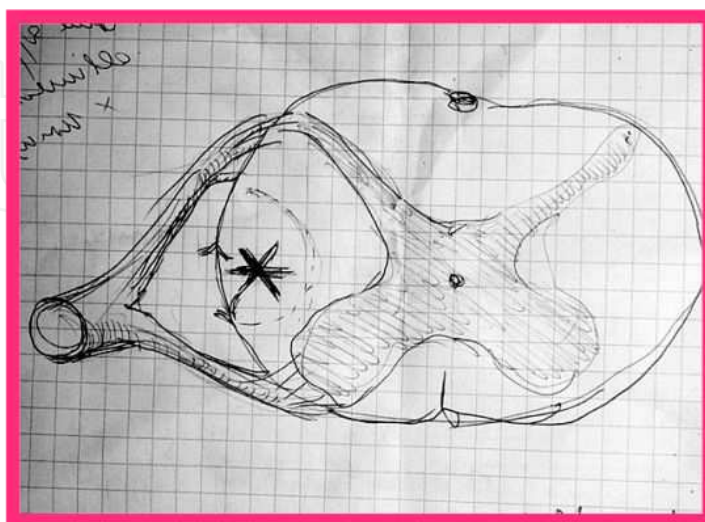


Figure 12. Sketch of the place where the graft is inserted.



Figure 13. An operated monkey grasping the bars of its cage with its foot

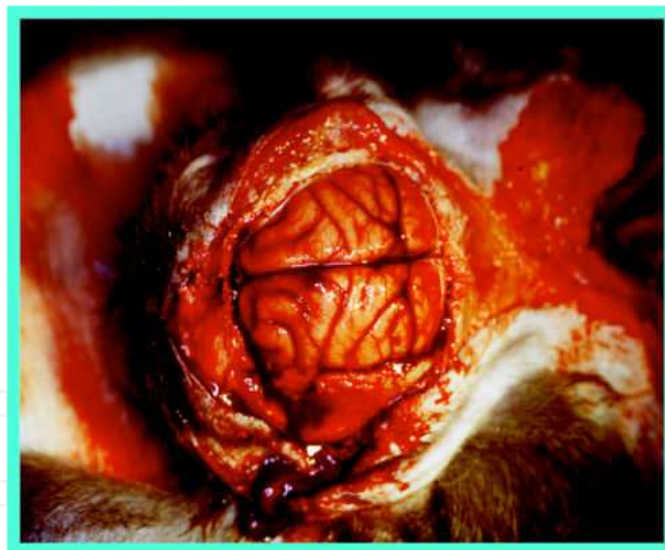

Figure 14. Craniotomy done for magnetography of the graft and muscles.

As at that time we had no effective treatment for spinal cord injury (S.C.I.) I thought, (and the Ethical Committee of the Italian Health Organisation agreed) that it could be ethically justified to operate on *fully informed volunteer patients* by means of surgical procedures already in current use, tried and checked in animals and human beings as, for instance, the transfer of nerves (ulnar nerves from upper to lower limbs, fig 16 and 16 bis) or the grafting from the corticospinal tract of the cord to peripheral nerves of the lower limbs by means of autologous nerve-grafts.

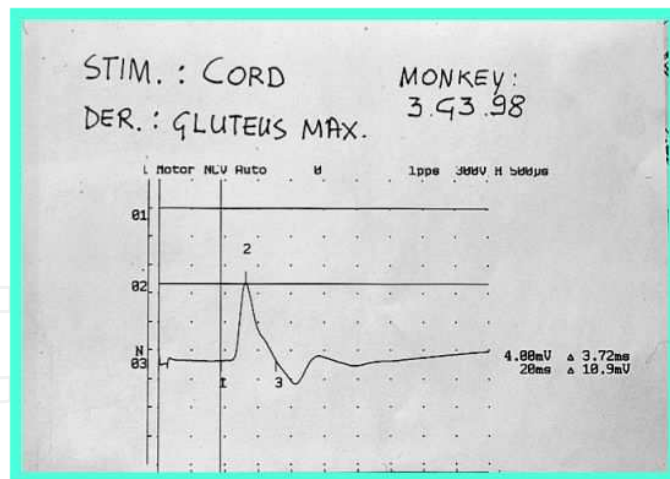


Figure 15. Emg: different latencies according to the distance of the recording electrode.

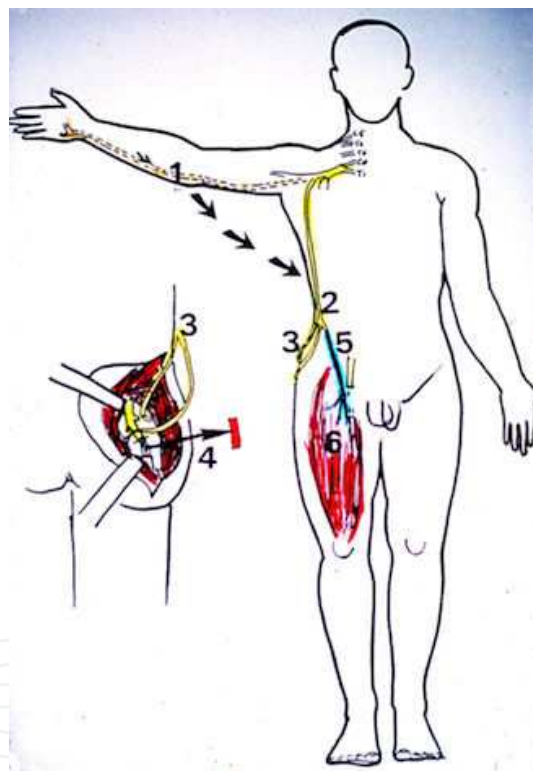


Figure 16. Sketch of the transfer of the ulnar nerve from the upper to the lower limb.

(The damage at the donor hands due to ulnar nerve removal, was repaired by the S.Bunnell and D.Smith procedures. (fig 17) which are well-known procedures of tendon transfers for palsies of the hand).

Later on in my own laboratories (in the private hospital “saint Rocco of Franciacorta” in Ome), in the following four groups of monkeys operated on with immobilisation in plaster and resuscitation, I got better survival rate and functional results.

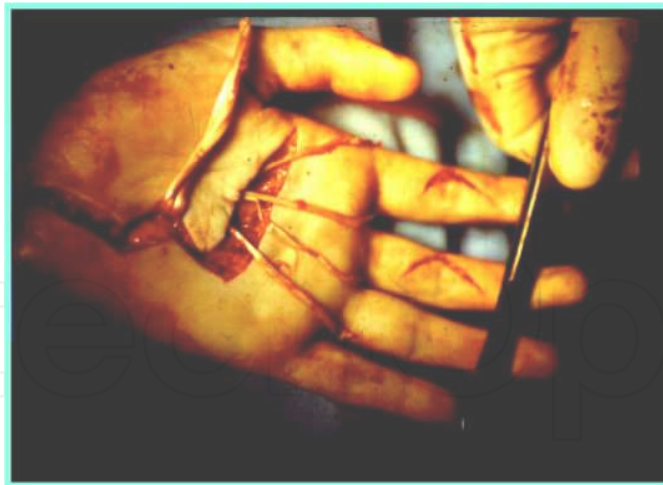

Figure 17. Repair of the damage done at the hands by means of Bunnel and Smith operations

Muscles were first completely disconnected from central nervous system (C.N.S.) and then reconnected to it by means of an autologous nerve graft inserted into the cortico spinal tract (C.S.T.), with exclusion of the lower motoneuron (fig 18).

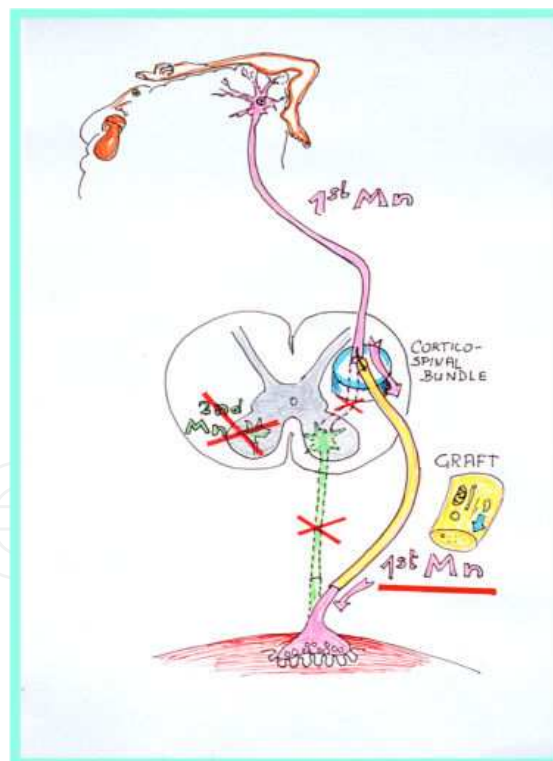


Figure 18. Through this operation the muscle receives innervation by the upper motoneurons and by glutamate instead of acetylcholine

A question arose: how could the muscles (the receptors of which normally respond to acetylcholine) respond to a different neurotransmitter, i.e. glutamate?

In order to understand how this was possible a multidisciplinary research with various institutes of the University of Brescia has been done, in rats, to check which neurotransmitter was really responsible for the muscle response:

Vecuronium (nicotinic receptors antagonist) was injected i.v. in the saphen vein (after tracheostomy for artificial ventilation) obtaining the palsy of all the muscles except the reinnervated one. Then GYKY 52466 (antagonist of the glutamate receptors) was injected intraperitoneally obtaining the disappearance of the response of the reinnervated muscle.

Immunoblot analysis of Choline acetyltransferase, Vesicular acetylcholine transporter and vesicular glutamate transporter, demonstrated that the markers for Acetylcholine were present in controls whereas those for Glut were present in the reinnervated muscle. (fig 19).

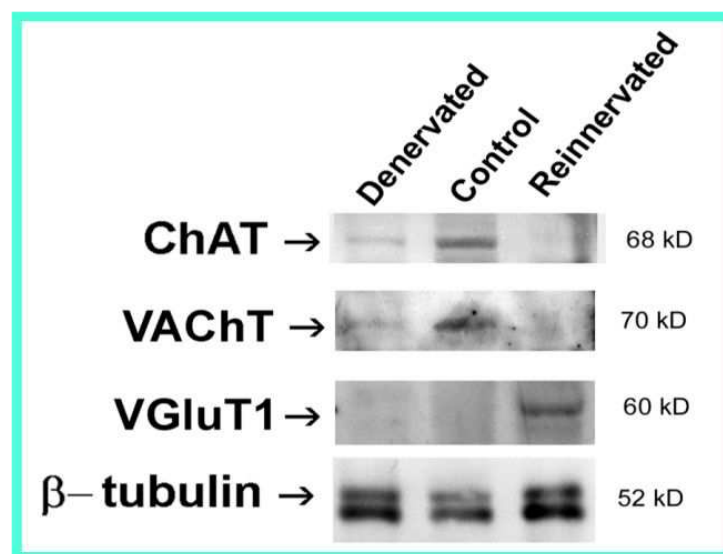


Figure 19. Immunoblot demonstrating that in control muscles are present the markers for ACh whereas in the reinnervated muscles the Glut markers are present.

CTB retrograde tracing of reticular formation and red nucleus neurons was positive.

This research was able to demonstrate that the receptors of the motor end plates, stimulated by the presynaptic nerve fibres (glutamatergic) were able to change one of the molecules of their ionic channels so accepting the glutamate transmitter (Proceeding of the National Academy of Science - P.N.S.A).

Going back to the operation of connecting the muscles to the cortico spinal tract by means of autologous nerve grafts, the peroneal component of the sciatic nerve (bilaterally) was used to graft from the C.S.T. of the cord to the muscles (glutei and quadriceps) (fig).

Two teams of microsurgeons, anesthesiologists and nurses were at work for 12 hours.

The operated patients stayed 4 to 6 days in the intensive care unit and then started a long program of re-education.

After 5 months the first voluntary movements appeared which became functional after one year (fig.20 and 21).

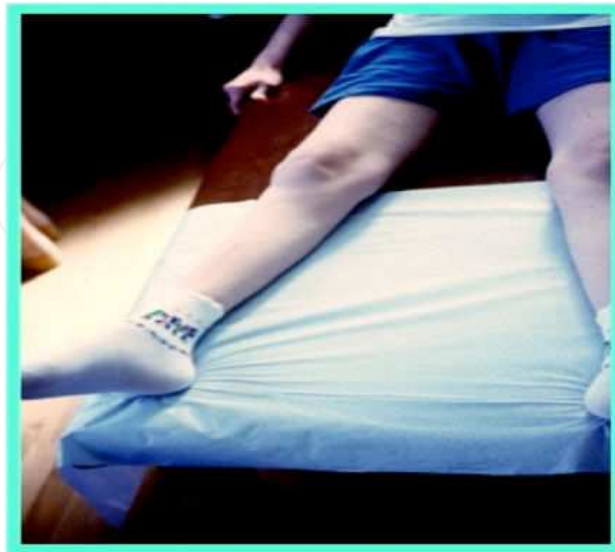

Figure 20. Active abduction

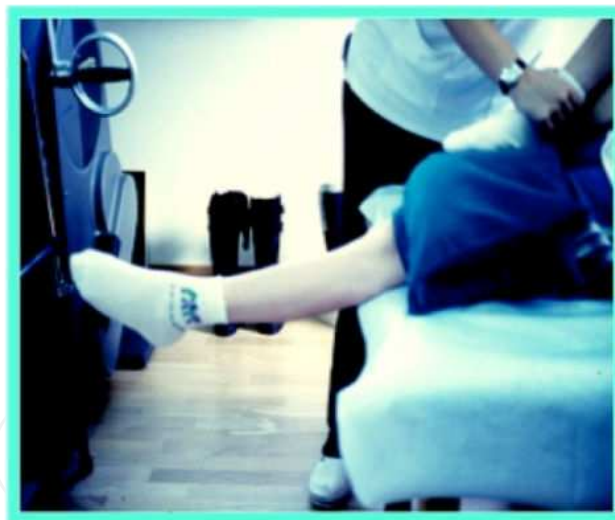

Figure 21. Active extension of the knee without co-contractions

Soon after the patient was able to walk with the help of an ambulator or of quadripode sticks. (fig.22) (cortico spinal tract) by means of nerve grafts, the peroneal nerve (bilaterally) was used to graft from the cortico spinal tract of the cord to the muscles.

Through this operation the muscles receive the innervation by the presynaptic neurons by means of glutamate transmitter (fig 18).

This result has been published in 2006 in the P.N.A.S.



Figure 22. The patient walking with the help of an ambulator. (She had undergone a guillotine severance of the cord at T8 and grafts from the C.S.T. to the glutei and quadriceps).

This occurs probably due to a partial remodelling of the molecules of the trans-membrane channels of the motor end-plates which go back to an embrionic type of channels changing one of their 5 molecular constituents.

Our research demonstrated 5 novelties:

1. the upper motoneuron can build up a cytoskeleton longer than that of the lower motoneuron (up to the muscles)
2. functional connection with muscles occurs,
3. also selective voluntary activation of the muscles occurs,
4. alteration of the motor end-plates from cholinergic to glutamatergic takes place
5. brain plasticity by multiple single neurons, (not only by cortical areas) is demonstrated

But once explained this mystery, one more mystery became evident:

The connection of the graft was inevitably random with the descending axons of the lateral bundle of the cord: the cortico-spinal-tract.

In the C.S.T. thousands and thousands of motor axons run coming from neurons of different areas of the brain cortex having different functions, destined to different muscles having different and even contrasting movements.

The least we could expect should have been co-contractions with severe hindrance of function. All the muscles connected with the C.S.T. should contract contemporarily with no useful function.

On the contrary only the muscles that the patient wanted to move were active. The explanation may be that there must be some until now unknown mechanism of feed back by which the mental command coming from the frontal lobe is able to activate only those neurons that at the periphery have been connected to the wanted muscles.

This means that the single and selective movements depend on the activation of million of single motoneurons scattered in various areas of the cortex and not on neurons of a given cortical area.

This means that there is a brain plasticity by multiple (millions) single neurons scattered in different places of the brain cortex that fire simultaneously under the mind command for the desired movement due to their peripheral connection even if their previous function was different. (fig 22)

Connections of the cord with peripheral nerves have been tried also with other different surgical protocols with the aim of correcting other types of palsies as, for instance, those due to total brachial plexus avulsions in paraplegics.

Total avulsions of the roots of the brachial plexus cannot be repaired by sutures or nerve grafts but can only be treated by extraplexal neurotisations i.e. transfers of extraplexal donor nerves.

In rare cases these lesions occur simultaneously with traumatic paraplegia (or in patients with previous paraplegia) (3 to 5 %).

With the aim of restoring function to the paralyzed arm in paraplegics I have set up a research in rats by cutting the radial nerve at the armpit and connecting it by means of an autologous graft to the cortico-spinal tract of the spinal cord at level of T3 – T4. (fig 23, 24 and 25)



Figure 23. Sketch of the experimental connection of the C.S.T. of the cord below T3 with the radial nerve at the armpit to re-innervate the brachial plexus in paraplegics.

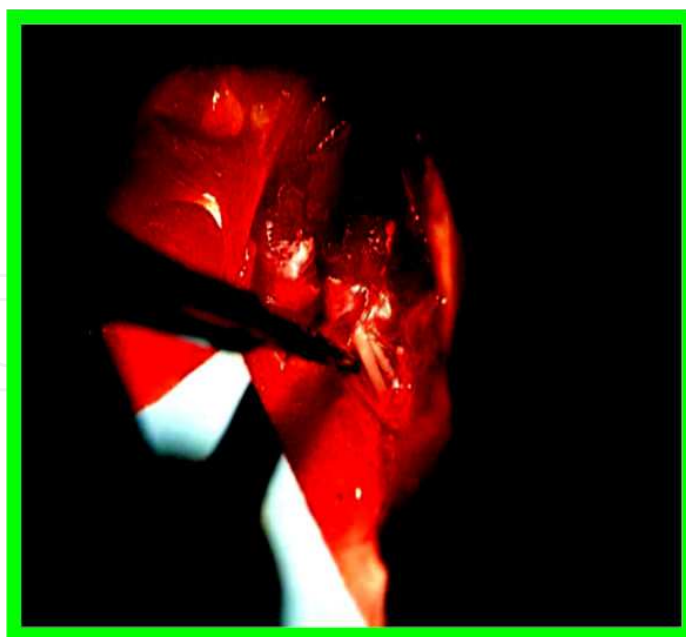


Figure 24. Connection of the brachial plexus of a rat to the c.s.t.

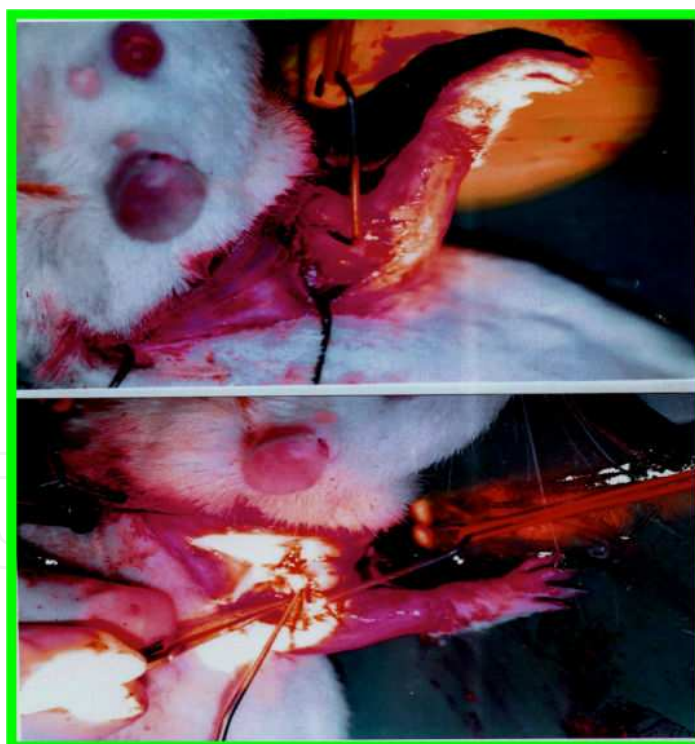


Figure 25. Extension of the elbow, wrist and fingers after connection of the radial nerve to the C.S.T.

After 5 months the extension of the wrist and of the digits was recovered.

In human beings with paraplegia no additional damage at the lower limbs can occur.

Author details

Giorgio Brunelli*

Address all correspondence to: giorgio.brunelli@midollospinale.com

Medical School of the University of Brescia, Italy

References

- [1] Brunelli: 1983, Innesti sperimentali per lesioni del midollo spinale:G.I.O.T, 9, 53-57.
- [2] Aguayo A, 1981.Mc Gill, Montreal. Non permissiveness for regrowing axons in the central nervous sistem.
- [3] Brunelli: 1983, Studio sperimentale sulla rigenerazione assonale nel midollo.Policlinico, 90,1334-1336.
- [4] Chiasserini: 1944, Compendio di traumatologia del sistema nervoso. Ed Humanitas Nova, Roma.
- [5] Brunelli: 1984, Acquisizioni recenti sulle possibilità di riparazione chirurgica delle lesioni midollari.ATTI II° SIMP.intern. pietra Ligure
- [6] Brunelli: 1988, Experimental spinal cord repair. In Textbook of microsurgery. Ed Brunelli, Masson ed, 547-554.
- [7] Brunelli: 1988, Experimental repair of spinal cord lesions by grafting from C.N.S. to P.N.S. jour, recstr. microsurg.4, 2455-250
- [8] Brunelli: 1996 Results in experimental spinal cord repair. Proc 12th Symposium I.S.R.M., Singapore, 3-6.
- [9] Brunelli: 1996, Experimental surgery in spinal cord lesions by connecting upper motoneurons directly to peripheral targets. J.periph.nerv.system 1, 111-118.
- [10] Brunelli et al: 1996, Sperimentazione sulla possibile riparazione delle lesioni del midollo spinale: gli innesti dal SNC al SNP producono connessioni funzionali. Monograph, Delfo,Brescia 1-56.
- [11] Brunelli: 1997: Experimental spinal cord repair.Surgical tecnology 391-395.
- [12] Brunelli: 1999: Restoration of walking in paraplegia by transferring the ulnar nerve to the hip. Microsurgery,223-226
- [13] Brunelli: 2002: The future: surgery of the spinal cord?. Hand clinic: 18,541-546.

- [14] Brunelli et al: 2005: Glutamatergic reinnervation through peripheral nerve grafts dictates assembly of glutamatergic synapses at rat skeletal muscle. P.N.A.S. 102,8752-8757.
- [15] Brunelli: 2005: Les reparations chirurgicales des lesions de la moelle epiniere. Bull, Acad.Natlle med, Paris, 189.n.6.1135-1149.
- [16] Pizzi M., Brunelli G.A. et al: 2006: Glutamatergic innervation of rat skeletal muscles by supraspinal neurons. Current Opinion neurobiol 16,323-328
- [17] von Wild K.R., Brunelli G.A.: 2003: restoration of locomotion in paraplegics with aid of autologous bypass grafts for direct neurotisation of muscles by upper motoneuron. The future surgery of the spinal cord?. Acta Neurochir suppl. 87, 107-112.
- [18] Brunelli G and von Wild K: Unsuspected plasticity of single neurons after connection of the C.S.T.with peripheral nerves in spinal cord lesion. J.Korean neurosurg.society, 46, 1, 1-4.

