

We are IntechOpen, the world's leading publisher of Open Access books Built by scientists, for scientists

6,900

Open access books available

186,000

International authors and editors

200M

Downloads

Our authors are among the

154

Countries delivered to

TOP 1%

most cited scientists

12.2%

Contributors from top 500 universities



WEB OF SCIENCE™

Selection of our books indexed in the Book Citation Index
in Web of Science™ Core Collection (BKCI)

Interested in publishing with us?
Contact book.department@intechopen.com

Numbers displayed above are based on latest data collected.
For more information visit www.intechopen.com



Heterotopic Ossification after Traumatic Brain Injury

Jesús Moreta and José Luis Martínez-de los Mozos

Additional information is available at the end of the chapter

<http://dx.doi.org/10.5772/57343>

1. Introduction

Heterotopic ossification is defined as the formation of bone within soft tissues, most frequently muscle tissue. The heterotopic ossification of muscles, ligaments and tendons is a potential complication following trauma, elective orthopaedic surgery, severe burns and neurological injury. It should not be confused with metastatic calcification associated to hypercalcaemia or dystrophic calcification related to tumours. Although there is an uncommon hereditary disease, called fibrodysplasia ossificans progressiva, most cases result from a local trauma (major local surgery, muscular trauma, fractures) or a neurological injury. The first description of heterotopic ossification after neurological injury was by Dejerne and Ceillier [1] in 1918, in soldiers with spinal cord injuries during World War I. Fifty years later, Roberts [2] described heterotopic ossifications in the elbow after brain injury. Since these articles, several studies have been published to provide information about causes, diagnosis and treatment of this complex entity.

This chapter is meant to serve as a review and an update on the literature regarding aetiology, diagnosis and management of this severe complication after a traumatic brain injury.

2. Epidemiology, aetiology and risk factors

The true incidence rate following neurological injury is difficult to establish clearly. After spinal cord injury, the percentage varies between 16% and 53% [3-6], and after traumatic brain injury has been reported to vary between 11% and 22% [7, 8]. A genetic predisposition has been suggested due to the relationship between neurogenic heterotopic ossifications (NHO) and fibrodysplasia (or myositis) ossificans progressiva [8]. The preferred locations in both cases are the proximal limbs and axial musculature. Moreover, a local trauma could predispose

an individual to developing a bony formation. The influence of an association between human leukocyte antigens (HLA) and NHO is not clear. Some authors suggest a high prevalence of HLA-B18 and HLA-B27 in patients with heterotopic ossifications, but these findings should be confirmed [9].

It has been suggested that there is a higher prevalence in younger patients (20-30 years old), which may be because neurological injuries are most frequent in this patients [10, 11]. The incidence rate in relation to gender varies in the literature and the relationship has not been shown clearly.

The development of bone in soft tissues in orthopaedic surgery is a well-known complication. This complication has been associated with total hip arthroplasty, fractures or joint dislocations (mainly in the acetabulum or the elbow) and muscular trauma. For this reason, a relationship seems to exist between local trauma and the development of heterotopic ossifications.

Although the presence of traumatic brain injury alone could be associated with the development of heterotopic bone, it is not an established predictor. Brain trauma is a constant cause but there are specific risk factors implicated, such as spasticity, diffuse axonal injury, decerebrate posture, respiratory ventilation or prolonged immobilization. In a study of patients with NHO after traumatic brain injury, Garland [11] showed that 89% of joints were in spastic limbs. Moreover, diffuse axonal injury seems to be more related than focal brain injury [12]. Therefore, the extent of neurological damage must be taken into account, due to the fact that the risk is correlated with the severity of the brain injury. Flin et al. [13] evaluated patients who suffered from comas after traumatic brain injury in an acute rehabilitation unit. They founded that decerebrate posture could predispose an individual to NHO.

Ectopic bone after a neurological injury could develop spontaneously, but there is a higher risk if a local trauma is involved [14]. In general, prolonged immobility during patients' illnesses, such as multiple fractures, burn injuries or a coma, may contribute to the formation of heterotopic ossifications. In patients with brain injuries, a relatively long period of immobilization is frequent and there is therefore an association with the formation of ectopic bone [15].

3. Pathophysiology

Early in the formation of HO, oedema with exudative infiltrate is present, followed by fibroblastic proliferation and immature connective tissue formation. Posteriorly, osteoid formation is seen with the subsequent deposition of bone matrix. Primitive osteoid is deposited as small masses in the periphery early (within the first two weeks) and osteoblasts are noted, located irregularly. Osteoblasts produce tropocollagen, which polymerizes to form collagen and secrete alkaline phosphatase, which allows calcium to precipitate and the mineralization of bone matrix. As mineralization progresses, amorphous calcium phosphate is progressively replaced by hydroxyapatite crystals. During the following weeks, the lesion matures with a centripetal pattern, and after 6-12 months an appearance of true bone is noted. The new bone is always extra-articular and can be contiguous with the skeleton but generally does not involve the periosteum [16].

Many hypotheses about the physiopathology of neurogenic myositis ossificans have been proposed. Different authors have suggested vasomotor and metabolic disorders induced by immobility, the venous stasis or the induction of enchondral ossification from muscular microtrauma. The cellular mechanism of heterotopic ossification remains unclear. It has been postulated that three conditions must be met to achieve heterotopic bone formation [10]: a stimulating event, oestrogenic precursor cells and a proper environment.

Mesenchymal stem cells are pluripotent progenitor cells with the ability to generate cartilage, muscle, tendon, fat and bone. These cells are ubiquitous in soft tissues and may be induced to differentiate into oestrogenic stem cells capable of producing osteoid. Although they play a key role, these cells alone cannot produce ossification and stimulating factors are necessary. Growth factors, such as bone morphogenetic protein, could cause the differentiation of mesenchymal stem cells in a correct environment. Overexpression of bone morphogenetic protein-4 (BMP-4) has been shown to occur in fibrous dysplasia ossificans progressiva, a genetic form of heterotopic ossification mentioned before [17]. Related to this, inhibition of BMP-4 has shown to prevent ossifications in three separate experimental models [18]. Other stimulating factors such as interleukin-1, growth hormone, prolactin, prostaglandin E-2, basic fibroblast growth factor and insulin-like growth factor type-1 have been recognized in the formation of ectopic bone after neurological injury [19-21]. After a brain injury, it has been suggested that circulating factors in the blood stimulate heterotopic ossification, but the specific mechanism remains unclear [22-23].

As has been mentioned before, the local environment has been shown to be important. Angiogenesis plays a role through the release of angiogenesis factors and differentiation of pericytes into osteoprogenitor cells [24]. Urist et al. [19] discovered that demineralized bone matrix could cause bone formation in vascular tissue. Otherwise, when they cultured this substance in an avascular system they found the development of cartilage. Other contributing factors in the local environment include hypercalcaemia, tissue hypoxia, pH changes (alkalosis) or prolonged immobilization.

It has also been suggested that there is a relationship between the nervous system and bone metabolism. Several neuropeptides and neurotransmitters have been found in the bone tissue. Glutamate, substance P, leptin, vasoactive intestinal peptide (VIP) and catecholamines have been shown to modify osteoblastic and osteoclastic activity [25-27].

In summary, there is an interaction of systemic and local factors on mesenchymal stem cells resulting in their differentiation into osteoblasts and the formation of heterotopic ossification.

4. Location

In patients who have suffered from a spinal injury, NHO develops in sites distal to the level of the spinal cord damage. After a traumatic brain injury, a considerable percentage of patients (between 10% and 20%) could develop ossifications around different joints. In all joints, the development of NHO is typically extra-articular and occurs in the connective tissue between

the muscle planes and not within the muscle itself [28]. Clinically, an NHO is defined by a limited decreased range of movement, usually accompanied with pain.

Although upper and lower extremities could be affected, the most commonly affected joint is the hip. In these patients, the most common location is inferomedial and it seems to be a role of adductor spasticity. The ossified tissues extend from the pubic symphysis to the medial or anteromedial femoral shaft and usually the femoral neurovascular bundle lies anteriorly. Other locations around the hip are the posterior part and the anterior aspect of the joint, below the anterior superior iliac spine [11]. When the location is posterior, the sciatic nerve could be involved and if the ossification develops anteriorly it may involve the femoral neurovascular structure. Gartland et al. have suggested that the anteromedial location is most frequent after spinal cord injury, whereas inferomedial, lateral and posterior planes are usually affected after brain injuries [11, 29].

The next most common sites of involvement in patients with traumatic brain injuries are the shoulders and elbows, with the knees rarely being affected. Nevertheless, knees are frequently involved in patients with spinal cord injuries. After a head injury, the ectopic bone about the elbow usually develops posteriorly from the humerus to the olecranon, and could cause ankylosis of this joint. The ulnar nerve could be affected, due to its close location [30]. Although the knee is a common location after a spinal cord injury, it is uncommon in patients with brain damage. In this case, the ectopic bone may occur in any plane, but the inferomedial aspect of the distal femur seems to be the most frequent [29, 30].

5. Diagnosis

5.1. Clinical presentation

The mean time from injury to development of HO is two or three months, but some studies have reported numbers from two weeks up to one year [31]. Thorough physical examination should be performed because this is a critical point for obtaining an early diagnosis. The onset of a heterotopic ossification may simulate an infection with erythema, warmth and swelling. Lower limb swelling may mimic deep venous thrombosis (DVT), so this entity should be ruled out. Differentiating early heterotopic ossification from lower extremity DVT is sometimes difficult, because the two entities have similar clinical presentation. Furthermore, they also can occur at the same time due to the mass effect of the ectopic bone, inciting venous compression and finally phlebitis and thrombus development.

When the passive mobility is examined there is a decreased range of motion. The examiner may identify a painful joint if the patient is conscious, but the findings described before should be checked, especially if the patient is in a coma.

Although there is no total agreement, accelerated bone healing has been reported [32]. In patients with brain injuries, it could be more callus formation but there is a different histological pattern. For this reason, some authors have suggested that this new bone may be a

heterotopic ossification, because its maturation is performed from the periphery. Callus maturation after a fracture occurs from the central area [33].

5.2. Laboratory tests

The serum alkaline phosphatase level reflects osteoblastic activity and is useful for obtaining an early diagnosis, especially in patients who cannot report pain or for whom a physical examination is difficult. This marker begins to rise two or three weeks after the brain injury, and values return to normal at approximately four months [34]. A clinical judgement of this test should be done, because liver disease or associated fractures also could increase the levels. Furthermore, alkaline phosphatase titres do not correlate with peak activity or maturation of HO, so they cannot be used to get information about the evolution of the ectopic bone [35]. Nevertheless, this is a cheap and easy screening tool to detect early HO and begin with treatment. Garland (ref de libro) recommends initiating medical prophylaxis on the basis of serum alkaline phosphatase elevation if there are no fractures associated.

In a study of patients after acute spinal cord injury, the 24-hour urinary excretion of prostaglandin E₂ (PGE₂) showed an increase until the maturation of the HO [37]. In patients with brain injuries, it could also be a valuable indicator before the ectopic bone is established. Indomethacin is a PGE₂- blocking agent, which is a useful medication to prevent this [38].

5.3. Radiography

Plain radiographs are an easy and cheap method to recognize a neurogenic heterotopic ossification but it may take up to six weeks for ossification to be evident. In some cases, the HO could develop in several months (Figure 1). Anteroposterior (AP) and lateral radiographs provide enough information to establish the relationship of the HO to the joint, but further radiological techniques (CT-Scan, MTI) should be performed to get more information on the anatomy and the condition of the joint. The typical radiographic appearance of the ectopic bone is a circumferential ossification with a lucent centre [39].

In the hip, the Brooker classification could be useful, which is commonly used to describe the pattern and extent of ossification around a total hip arthroplasty. The extent of the ectopic bone correlates with the degree of functional impairment. According to this classification, there are four types:

- Type I: Islands of bone within the soft tissues.
- Type II: Bone spurs arising from the pelvis or proximal femur with 1cm or less between adjacent bone surfaces.
- Type III: Bone spurs arising from the pelvis or proximal femur with more than 1cm between adjacent bone surfaces.
- Type IV: Confluent bone bridging the pelvis and proximal femur with apparent ankylosis of the hip.

A recent classification has been introduced by Mavrogenis et al. [40] according to the anatomical location of neurogenic HO in the hip: type 1, anterior; type 2, posterior; type 3, anteromedial; type 4, circumferential. These authors suggested that this classification provides better evaluation of the prognosis after surgical excision than the Brooker classification and they found higher blood loss for patients with anteromedial (type 3) or circumferential (type 4) neurogenic ossifications. They also showed a higher risk of recurrence in patients with brain injuries.

5.4. Bone scans

Bone scans or scintigraphy are considered the most sensitive method of providing early detection of HO, with detection as early as two weeks after the onset of symptoms [39].

Bone scintigraphy using ^{99m}Tc -methylene diphosphonate provides imaging in three phases: Phase I (dynamic blood flow study), Phase II (Static study for blood pool) and Phase III (amount of radionuclide in bone). The first two phases allow early detection of incipient ossification at two or three weeks. In Phase III, this test occurs approximately one week later. The level of activity on delayed bone scans usually peaks at two months and then it decreases progressively. Scintigraphy activity returns to normal after approximately 12 months, but it may remain positive even when the ossification has become mature.

5.5. Ultrasonography (US)

This technique has been used in the early diagnosis of HO about the hip joints, showing a chaotic disruption of the normal structure of the muscle in the first stages [41]. Later, a peripherally echogenic and centrally hypoechoic finding can be identified. US has the advantage of the possibility of bedside application and it requires no radiation. Ultrasonography is also a fast and useful tool for diagnosis of DVT, which is associated with patients with spinal cord injury as we mentioned before. Nevertheless, ultrasonography is a difficult technique, which depends on the skills of the examiner.

5.6. Magnetic resonance imaging (MRI) and volumetric computed tomography (CT-Scan)

Although bone scans are considered the most sensitive method for early detection of neurogenic HO, magnetic resonance imaging (MRI) suggests changes compatible with ectopic bone formation, as soon as two days after clinical presentation, especially in the knee [42]. In this joint, MRI findings are joint effusion, thickening of the intermuscular septa and a “lacy-pattern” of the muscles vastus lateralis and medialis in fast spin-echo short time inversion-recovery (STIR) images.

Evaluation with computed tomography (CT) combined with two and three-dimensional surface reconstructions provides good differentiation and the extent of the ectopic bone. Moreover, this technique shows the relationship with the joint, determines the mineral density of the bone and can predict several intra-articular lesions. In a study performed by Carlier et

al. [43], they compared the density of the HO around the hip with the iliac wing. Bone mineralisation was classified in four categories: normal (M1), mild demineralisation (M2), significant demineralisation with risk of fracture (M3) and evanescent bone with a high risk of fracture (M4). They correlated these features with surgical findings, so this is an important issue because osteoporosis underlying the ankylosis can lead to fractures, which are a difficult challenge in these patients.

If surgical treatment is required, a thorough vascular assessment should be done, because there is a relationship between the HO and surrounding neurovascular structures (femoral bundle in the hip). Therefore, helical-CT with intravenous contrast or MRI with contrast (Figure 1) should be one of the requirements of the preoperative assessment in patients undergoing surgical excision of HO.

6. Treatment and prevention

The prevention of heterotopic ossification is focused on three basic principles: disrupting the inductive signalling pathways, altering the osteoprogenitor cells or modifying the environment. Although some targets are defined in some diseases such as Progressive Osseous Heteroplasia, the target cell or target tissue in NHO remains unknown [44]. Maintaining joint motion by treating spasticity and gentle physical therapy is the goal of early treatment. When a neurogenic heterotopic ossification is suspected, the treatment should start with medical treatment and when the ectopic bone is established and symptomatic surgical resection should be considered carefully. In Figure 2, there is an algorithm, which could be useful to diagnose and treat this entity.

6.1. Physiotherapy and rehabilitation

Prevention should start with early joint mobilisation. Once the diagnosis of early ossifications is suspected, physical therapy with the help of passive exercises should be done [45]. If the patient is conscious, physiotherapy should involve an assisted range of movement exercises with gentle stretch and terminal resistance training. It is crucial to achieve a good range of motion without generating pain. Although forceful manipulation, even under anaesthesia, could be beneficial, it is advisable to avoid aggressive range-of-motion exercises because they carry the risk of causing more bone formation. This may be due to the effect of repetitive microtrauma to the joint [46].

The treatment of HO by extracorporeal shock wave has been reported. Brissot et al. [47] showed less pain and better range of motion and walking distance with this treatment. If the patient is not a suitable candidate for surgical treatment because of medical comorbidities, shock wave therapy could also be a good alternative [48].

In conclusion, physical therapy aims to preserve movement and good function, avoiding or decreasing the risk of ankylosis of the joint.

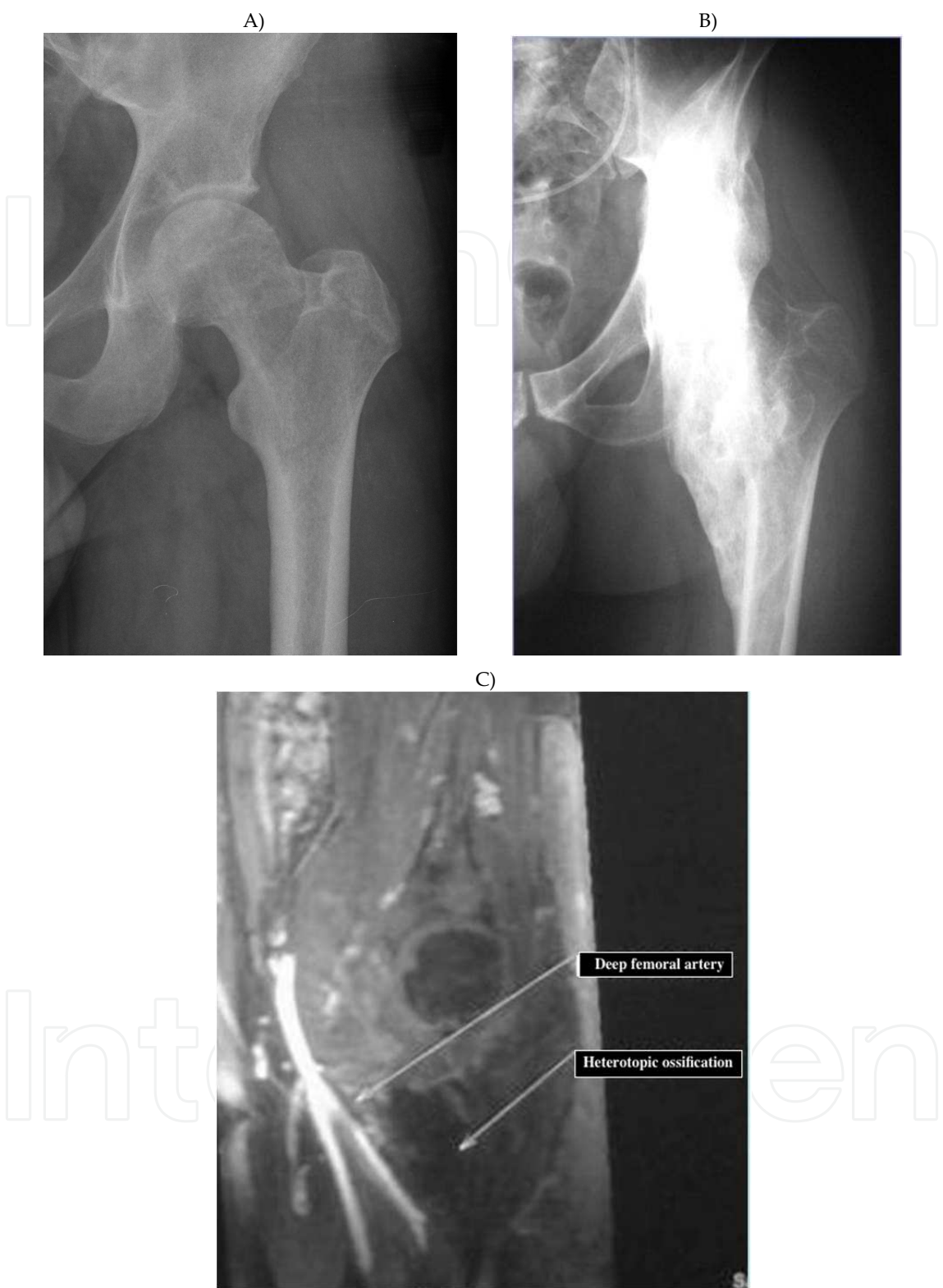

Figure 1. Neurogenic ossification in the hip in a patient after a traumatic brain injury. A) Radiograph of the left hip six months after the brain injury. B) Radiograph showing an anteromedial ossification around the hip causing severe ankylosis, 14 months after the initial injury. C) MRI enhanced with contrast showing a close relationship between the ossification and the deep femoral artery.

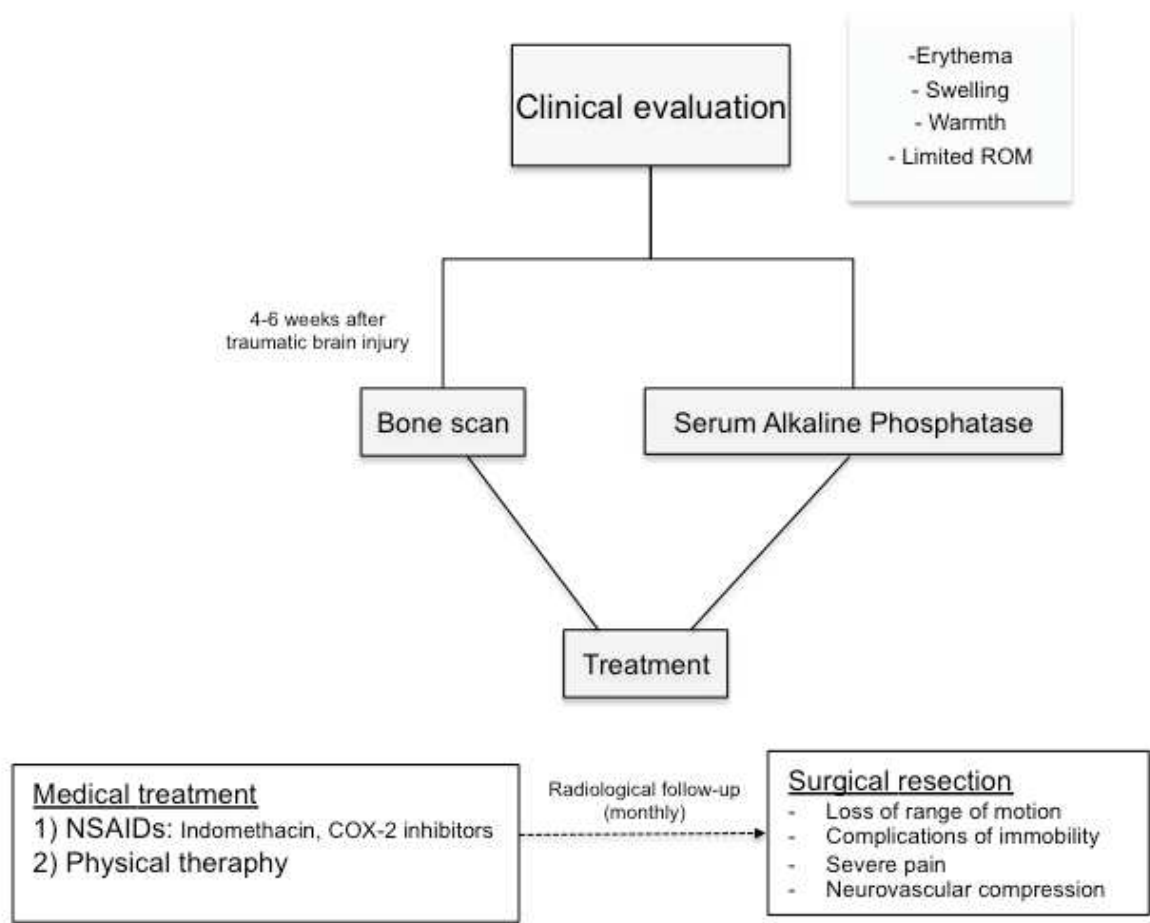


Figure 2. Diagnosis and treatment of neurogenic heterotopic ossifications

6.2. Medical treatment

Medical treatment aims to prevent the formation of HO following brain injury and to avoid recurrence if surgical excision is needed. Due to the fact that the development of HO can occur within one to two months of the initial injury, the prophylaxis should begin relatively early. Although there is no consensus on which medication should be used and when treatment should begin, several drugs have successfully been used.

Nonsteroidal anti-inflammatory drugs (NSAIDs)

These drugs have demonstrated good results in preventing heterotopic ossification after total hip arthroplasty and several studies support their use following traumatic neurological injury [49-51]. A Cochrane Review of HO formation after hip replacements performed in 2004, showed the effectiveness of prevention using NSAIDs perioperatively [52]. A direct effect of NSAIDs on the formation of heterotopic ossification has been described, due to the inhibition of the differentiation of mesenchymal cells into oestrogenic cells. There is also an indirect effect,

which refers to the inhibition of bone remodelling by suppression of the prostaglandin-mediated inflammatory response (specifically PGE-2) [38].

Indomethacin has been considered a useful medication for heterotopic ossification prophylaxis following total hip replacement. In a randomized controlled trial, Banovac et al. [50] showed a lower incidence of early and late HO in the indomethacin group. This drug prescribed for three to six weeks in a dose of 75mg/day, within two months of the injury, may reduce the incidence of heterotopic ossification by two to three times. These same authors performed a trial to determine the effect of COX-2 selective inhibitor rofecoxib on the prevention of HO after spinal cord injury [51]. They concluded that there was a 2.5 times lower risk of developing ectopic bone. COX-2 selective inhibitors could be an attractive option because of less gastrointestinal side effects; however, rofecoxib was taken off the USA market due to elevation of cardiovascular risk. In addition, celecoxib, another selective COX-2 inhibitor, showed the same efficacy as indomethacin in the prevention of HO, but in patients with cardiovascular problems should be used cautiously. Another COX-2 inhibitor, meloxicam, did not reduce the incidence of ossification after total hip replacement compared to indomethacin [53, 54].

In conclusion, indomethacin remains the gold standard for pharmacological prevention of HO, because it is a simple and low cost option. Celecoxib could be a reasonable option in patients without cardiovascular diseases because it has shown good results with fewer gastrointestinal effects.

Bisphosphonates

Bisphosphonates have also been used in the prevention of HO. Etidronate disodium is a well-studied bisphosphonate and it seems to be effective for early ossifications [55, 56] and later phases of this disease. This medication inhibits precipitation of calcium phosphate and blocks the aggregation and mineralisation of hydroxyapatite crystals. In primary prevention, Banovac et al. [56] have suggested that the treatment should begin as soon as elevated alkaline phosphatase is diagnosed or positive findings in ultrasonography or bone scans are shown. In addition, bisphosphonates could have long-term effects on prevention when the treatment is finished.

In spite of these results, some authors do not recommend bisphosphonates routinely, because additional fractures are often associated with neurological injuries and the use of bisphosphonates could impede fracture healing [57].

6.3. Radiotherapy

Radiotherapy seems to work by preventing the differentiation of mesenchymal cells into osteoblasts, which could begin the bone formation. This method has been used successfully to prevent heterotopic ossification after hip replacements [58, 59]. In a prospective, randomized study of HO after hip arthroplasty, Knelles et al. found that the best results were obtained with indomethacin and a single irradiation of 7 Gy or four sessions of 3 Gy. These and other authors have suggested that a single irradiation of 7 Gy should be useful in patients at risk, especially if administration of indomethacin is contraindicated [60].

In patients with a traumatic brain injury, radiation therapy may be given as primary (patients with high risk of developing HO) or secondary prophylaxis (those who have been diagnosed with HO and need surgical resection). Sautter-Bihl et al. [62] studied prophylaxis with radiotherapy in 36 patients with spinal cord injuries. These authors used radiotherapy as primary prophylaxis in 27 patients and as secondary prevention (after surgical resection) in 11 patients. With an average follow-up of 23.6 months, 30 of the 36 patients showed no progression of HO and improvements in rehabilitation. It has also been suggested that radiotherapy provides pain relief and decreased serum alkaline phosphatase level in a case report of a patient with HO in both hips and thighs after a brain injury [63]. In this case, the symptoms were refractory to indomethacin, so a dose of 20 Gy in ten fractions was performed.

Like other pharmacological methods of treatment, radiation therapy could affect bone healing. A study focused on HO after elbow trauma has shown that single-fraction therapy leads to an increase risk of non-union [64]. In addition, the location of HO after a total hip arthroplasty is predictable, whereas that after brain injury is difficult to predict accurately where the ectopic bone will develop [65]. For this reason, we do not recommend the routine use of radiation therapy for primary prevention of neurogenic HO, whereas it could be a good method for secondary prophylaxis.

6.4. Surgery

Surgical resection of established ossifications is the treatment of choice to facilitate rehabilitation and is the only effective procedure when the ossification is mature.

The surgery is necessary in patients with symptomatic HO and unsuccessful medical treatment, such as:

- Loss of range of motion and ankylosis with associated functional disability, such as sitting difficulties
- Complications of immobility such as pressure ulcers
- Facilitate rehabilitation and recovery of muscular atrophy secondary to prolonged immobilisation
- Difficulties of appropriate hygiene because access to the perineum or bladder care is needed
- Severe pain refractory to analgesia
- Vascular and/or nerve compression

A careful preoperative assessment is mandatory in order to avoid complications. A CT-Scan is really useful to show intra-articular pathology and the degree of osteoporosis. In addition, a CT-Scan or MRI with contrast describes the relationship with important neurovascular structures.

The timing of operative excision is controversial. Some authors recommend timetables for the best moment to remove these ossifications, but these indications have changed in recent years. Gartland recommended surgery after six months following traumatic heterotopic ossification,

one year following spinal cord injury and 18 months after head injury. Another factor to take into account is the neurological condition of the patient. Severe cognitive and physical impairment have poor results from surgery with a high rate of recurrence. However, patients with good neuromuscular control before the surgical procedure have a better functional outcome [65, 66]. In the past, waiting until maturity in order to minimize the rate of recurrence after the surgical treatment was recommended. Nevertheless, recent studies do not confirm a higher rate of recurrence when the HO is excised in an earlier phase [49, 67]. In addition, a long delay before surgery leads to ankylosis, a high degree of osteoporosis and more extensive intra-articular injuries. These findings are associated with bad functional results and potential complications.

Stover et al. [5] showed that the risk of fracture was secondary to osteopenia and this complication increased with the delay in surgical treatment. Perioperative fractures are associated with grade 3 and 4 of osteopenia, according to the classification described by Carlier et al. [43], so therefore this complication could take into account with a preoperative CT-Scan. In a study of HO in 183 hips (143 patients), performed by Genet et al. [49], found 25 perioperative fractures of the femoral neck, all of which occurred in patients with ankylosed hips.

Intra-articular lesions are associated with a smaller range of motion and ankylosis. Some authors considered it to be neurotrophic arthropathy [68], but more recently Genet et al. [49] suggested that it is only ankylosis, which induces articular degradation. In addition, these authors showed that the presence of intra-articular lesions is a cause of worsening of the final results.

In general, the surgical goal is resection of a large enough amount of bone to allow improvement of the range of motion and trying to preserve the joint [49, 69]. A good knowledge of the anatomy is paramount and adequate exposure should be performed with identification of the relationship with neurovascular structures. Intraoperative neurologic monitoring with use of electromyography or somatosensory evoked potentials may be useful, especially in the hip. We use osteotomes and high-speed burrs to remove the ossifications and we frequently use fluoroscopy to check the bone removal (Figure 3). Intraoperative blood loss can be substantial so careful bleeding control should be performed and we recommend that local haemostatic agents should be available, such as bone wax and gelatine-based products. Much of the bleeding is from the osteotomized bone surfaces and is difficult to control with electrocautery. Furthermore, meticulous haemostasis and elimination of dead space decrease the risk of infection.

Wide exposure and identification of major vessels and nerves is extremely important. In many cases, the ossifications have a close relationship with important neurovascular structures and there is distortion of the normal anatomy. Therefore, there is a relatively high risk of iatrogenic injury. Especially in the hip, this complication is extremely important and sometimes life threatening, so therefore we recommend performing this surgical procedure with the assistance of a vascular surgeon [69].

There is a significant risk of recurrence and we recommend prophylaxis methods, such as physical therapy and the administration of indomethacin for two or four weeks. Although no

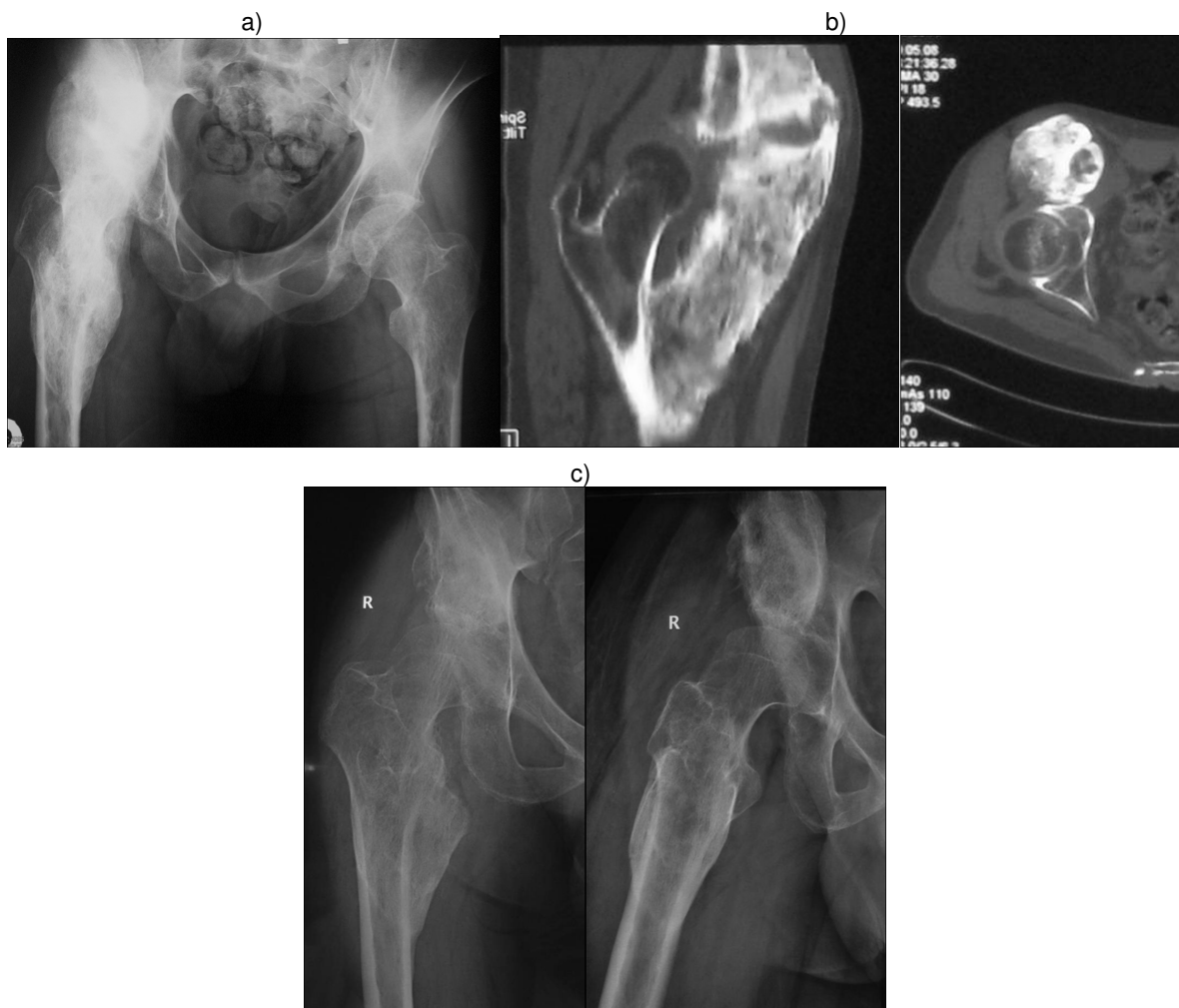

Figure 3. Heterotopic ossification in the right hip causing severe ankylosis. a) Preoperative imaging showing a huge HO from the lesser trochanter to the ilium. b) Preoperative CT-Scan showing involvement of the muscles iliopsoas, vastus medialis and vastus intermedius. c) Radiograph 12 months after surgery.

data have shown the benefit of radiotherapy or medical treatment when ossifications are mature, it is reasonable to use prophylactic treatment postoperatively aiming to prevent recurrence. [66].

7. Conclusion

Heterotopic ossifications after a brain injury present multiple challenges because of the difficult management of this disease. Although it is difficult to predict the development of NHO, it is correlated with the severity of brain damage and several risk factors have been reported. The hip is the most commonly involved joint and the clinical presentation could mimic a septic arthritis or phlebitis in the early stage (3-12 weeks after the neurological injury). Later, although the NHO could be asymptomatic, it can lead to limited range of motion and

ankylosis of the affected joint. Early detection and prevention with physical therapy, NSAIDs or bisphosphonates have shown good results. Surgery is recommended when the functional status is affected and thorough preoperative planning should be done to avoid further complications. Although, there is controversy in deciding the timing of surgery, recent articles have suggested that early surgical excision decreases the likelihood of developing osteopenia and intra-articular lesions.

This entity remains a poorly understood condition, so further research in neurogenic heterotopic ossifications should help in continuing to understand pathophysiology, identify pathways and target cells and tissues to find better methods of prevention and treatment.

Acknowledgements

We gratefully acknowledge Dr. O. Sáez de Ugarte and Dr. I. Jauregui for their assistance in the preparation of the manuscript.

Author details

Jesús Moreta* and José Luis Martínez-de los Mozos

*Address all correspondence to: chusmoreta2@hotmail.com

Department of Orthopaedic Surgery and Trauma, Hospital de Galdakao-Usansolo, Galdakao, Spain

References

- [1] Dejerne A, Ceillier A. Para-osteo-arthropathies des paraplegiques par lesion medullaire; etude clinique et radiographique. *Ann Med* 1918;5:497.
- [2] Roberts P. Heterotopic ossification complicating paralysis of intracranial origin. *J Bone Joint Surg Br* 1968;50-B:70-7.
- [3] Dai L. Heterotopic ossification of the hip after spinal cord injury. *Chin Med J (Engl)* 1998;111:1099-101.
- [4] Lal S, Hamilton BB, Heinemann A, Betts HB. Risk factors for heterotopic ossification in spinal cord injury. *Arch Phys Med Rehabil* 1989;70:387-90.
- [5] Stover SL, Niemann KM, Tulloss JR. Experience with surgical resection of heterotopic bone in spinal cord injury patients. *Clin Orthop*. 1991;263:71-7.

- [6] Wittenberg RH, Peschke U, Bötzel U. Heterotopic ossification after spinal cord injury: epidemiology and risk factors. *J Bone Joint Surg (Br)*. 1992;74-B:215-8.
- [7] Citta-Pietrolungo TJ, Alexander MA, Seg NL. Early detection of heterotopic ossification in young patients with traumatic brain injury. *Arch Phys Med Rehabil* 1992;73:258-62.
- [8] Connor JM, Evan DA. Fibrodysplasia ossificans progressiva: the clinical features and natural history of 34 patients. *J Bone Joint Surg Br* 1982;64:76-83.
- [9] Minare P. Neurologic injuries, paraosteoarthritis and human leukocyte antigens. *Arch Phys Med Rehabil*. 1984;65:5531.
- [10] Genet F, Jourdan C, Lautridou C, et al. The impact of preoperative hip heterotopic ossification extent on recurrence in patients with head and spinal cord injury: a case control study. *PloS One* 2011;6:23129.
- [11] Garland DE. Clinical observations on fractures and heterotopic ossification in the spinal cord and traumatic brain injured populations. *Clin Orthop* 1988;233:86-101.
- [12] Gennarelli TA. Heterotopic ossification. *Brain Inj* 1988;2:175-8.
- [13] Flin C, Curalucci H, Duvovelle A, Viton JM. Heterotopic ossification and brain injury. *Ann Readapt Med Phys* 2002;45:517-20.
- [14] Ebinger T, Roesch M, Kiefer H, Kinzl L, Schulte M. Influence of etiology in heterotopic bone formation of the hip. *J Trauma* 2000;48:1058-62.
- [15] Mielants H, Vanhove E, de Neels J, Veys E. Clinical survey of and pathogenic approach to para-articular ossifications in long-term coma. *Acta Orthop Scand* 1975;46:190-8.
- [16] van Kuijk AA, Geurts AC, van Kuppevelt HJ. Neurogenic heterotopic ossification in spinal cord injury. *Spinal Cord* 2002;40:313-26.
- [17] Hannallah D, Peng H, Young B, Usas A, Gearhart B, Huard J. Retroviral delivery of Noggin inhibits the formation of heterotopic ossification induced by BMP-4, demineralized bone matrix, and trauma in an animal model. *J Bone Joint Surg Am* 2004;86-A:80-91.
- [18] Ahrengart L, Lindgren U, Reinholt FP. Comparative study of the effects of radiation, indomethacin, prednisilone and ethane-1-hydroxy-1, 1-disphosphate (EHDP) in the prevention of ectopic bone formation. *Clin Orthop* 1988;229:265-73.
- [19] Urist MR, Nakagawa M, Nakata N, Nogami H. Experimental myositis ossificans: cartilage and bone formation in muscle in response to diffusible bone matrix derived morphogen. *Arch Pathol Lab Med*. 1978;102:312-6.

- [20] Mahy PR, Urist MR. Experimental heterotopic bone formation induced by bone morphogenetic protein and recombinant human interleukin-1B. *Clin Orthop* 1988;237:236-44.
- [21] Wildburger R, Zarkovic N, Egger G, et al. Comparison of the values of basic fibroblast growth factor determined by an immunoassay in the sera of patients with traumatic brain injury and enhanced osteogenesis and the effects of the same sera on the fibroblast growth in vitro. *Eur J Clin Chem Biochem* 1995;33:693-8.
- [22] Cadosch D, Toffoli AM, Gautschi OP, et al. Serum after traumatic brain injury increases proliferation and supports expression of osteoblast markers in muscle cells. *J Bone Joint Surg Am* 2010;92-A:645-53.
- [23] Bidner SM, Rubins IM, Desjardins JV, Zukor DJ, Goltzman D. Evidence for a humoral mechanism for enhanced osteogenesis after head injury. *J Bone Joint Surg Am* 1990;72-A:1144-9.
- [24] Collett GDM, Canfield AE. Angiogenesis and pericytes in the initiation of ectopic calcification. *Circ Res* 2005;96:930-8.
- [25] Wang L, Tang X, Zhang H, Yuan J, Ding H, Wei Y. Elevated leptin expression in rat model of traumatic spinal cord injury and femoral fracture. *J Spinal Cord Med* 2011;34:501-9.
- [26] Hohmann EL, Elde RP, Rysavy JA, Einzig S, Gebhard RL. Innervation of periosteum and bone by sympathetic vasoactive intestinal peptide-containing nerve fibers. *Science* 1986;232:868-71.
- [27] Jones KB, Mollano AV, Morcuende JA, Cooper RR, Saltzman CL. Bone and brain: a review of neural, hormonal, and musculoskeletal connections. *Iowa Orthop J* 2004;24:123-32.
- [28] Jensen LL, Halar E, Little J, Brooke MM. Neurogenic heterotopic ossification. *Am J Phys Med Rehabil* 1987;66:351-63.
- [29] Garland DE. A clinical perspective on common forms of acquired heterotopic ossification. *Clin Orthop* 1991;263:13-29.
- [30] Garland DE, Blum CE, Waters RL. Periarticular heterotopic ossification in head-injured adults: incidence and location. *J Bone Joint Surg Am* 1980;62-A:1143-6.
- [31] Cipriano CA, Pill SG, Keenan MA. Heterotopic ossification following traumatic brain injury and spinal cord injury. *J Am Acad Orthop Surg* 2009;17:689-97.
- [32] Pape HC, Lehmann U, van Griensven M, Gänsslen A, von Glinski S, Krettek C. Heterotopic ossifications in patients after severe blunt trauma with and without head trauma: incidence and patterns of distribution. *J Orthop Trauma* 2001;15:229-37.
- [33] Spencer RF. The effect of head injury on fracture healing: a quantitative assessment. *J Bone Joint Surg Br* 1987;69-B:525-8.

- [34] Orzel JA, Rudd TG. Heterotopic bone formation: clinical, laboratory and imaging correlation. *J Nucl Med* 1985;26:125-32.
- [35] van Kuijk AA, Geurts AC, van Kuppevelt HJ. Neurogenic heterotopic ossification in spinal cord injury. *Spinal Cord* 2002;40:313-26.
- [36] Garland DE, Varpetian A. Heterotopic Ossification in Traumatic Brain Injury. In: Ashley MJ (ed.) *Traumatic Brain Injury. Rehabilitation, Treatment, and Case Management*. CRC Press; 2004:119-34
- [37] Schurch B, Capaul M, Vallotton MB, Rossier AB. Prostaglandin E2 measurements: their value in the early diagnosis of heterotopic ossification in spinal cord injury patients. *Arch Phys Med Rehabil*. 1997;78:687-91.
- [38] Ho SSW, Stern PJ, Bruno LP, et al. Pharmacological inhibition of prostaglandin E-2 in bone and its effect on pathological new bone formation in a rat brain model. *Trans Orthop Res Soc*. 1988;13:536.
- [39] Shehab D, Elgazzar AH, Collier BD. Heterotopic ossification. *J Nucl Med* 2002;43:346-53.
- [40] Mavrogenis AF, Guerra G, Staals EL, Bianchi G, Ruggieri P. A classification method for neurogenic heterotopic ossification of the hip. *J Orthopaed Traumatol* 2012 13:69-78.
- [41] Falsetti P, Acciai C, Palilla R, Carpinteri F, Patrizio C, Lenzi L. Bedside ultrasound in early diagnosis of neurogenic heterotopic ossification in patients with acquired brain injury. *Clin Neurol Neurosurg* 2011; 113(1):22-7.
- [42] Argyropoulou MI, Kostandi E, Kosta P, Zikou AK, Kastani D, Galiatsou E, Kitsakos A, Nakos G. Heterotopic ossification of the knee joint in intensive care unit patients: early diagnosis with magnetic resonance imaging. *Crit Care* 2006;10:R152.
- [43] Carlier RY, Safa DM, Parva P, Mompoin D, Judet T, Denormandie P, Vallée CA. Ankylosing neurogenic myositis ossificans of the hip: an enhanced volumetric CT study. *J Bone Joint Surg Br* 2005;87-B:301-5.
- [44] Kaplan FS, Glaser DL, Hebel N, Shore EM. Heterotopic ossification. *J Am Acad Orthop Surg*. 2004;12:116-25.
- [45] Stover SL, Hataway CJ, Zeiger HE. Heterotopic ossification in spinal cord injured patients. *Arch Phys Med Rehabil*. 1975;56:199-204.
- [46] Garland DE, Razza BE, Waters RL. Forceful joint manipulation in head-injured adults with heterotopic ossification. *Clin Orthop* 1982;169:133-8.
- [47] Brissot R, Lassalle A, Vincendeau S, et al. Treatment of heterotopic ossification by extracorporeal shock wave: 26 patients. *Ann Readapt Med Phys* 2005;48:581-9.

- [48] Reznik JE, Gordon SJ, Barker RN, Keren O, Arama Y, Galea MP. Extracorporeal shock wave therapy (ESWT) as a treatment for recurrent neurogenic heterotopic ossification (NHO). *Brain Inj.* 2013;27(2):242-7.
- [49] Genet F, Marmorat JL, Lautridou C, Schnitzler A, Mailhan L, Denormandie P. Impact of late surgical intervention on heterotopic ossification of the hip after traumatic neurological injury. *J Bone Joint Surg Br* 2009;91-B:1493-8.
- [50] Banovac K, Williams JM, Patrick LD, Haniff YM. Prevention of heterotopic ossification after spinal cord injury with indomethacin. *Spinal Cord* 2001;39:370-4.
- [51] Banovac K, Williams JM, Patrick LD, Levi A. Prevention of heterotopic ossification after spinal cord injury with COX-2 selective inhibitor (rofecoxib). *Spinal Cord* 2004;42:707-10.
- [52] Fransen M, Neal B. Non-steroidal anti-inflammatory drugs for preventing heterotopic bone formation after hip arthroplasty. *Cochrane Database Syst Rev* 2004, CD001160.
- [53] Legenstein R, Bosch P, Ungersbock A. Indomethacin versus meloxicam for prevention of heterotopic ossification after total hip arthroplasty. *Arch Orthop Trauma Surg* 2003;123:91-4.
- [54] Barthel T, Baumann B, Noth U, Eulert J. Prophylaxis of heterotopic ossification after total hip arthroplasty: a prospective randomized study comparing indomethacin and meloxicam. *Acta Orthop Scand* 2002;73:611-14.
- [55] Banovac K, Gonzalez F, Wade N, Bowker JJ. Intravenous disodium etidronate therapy in spinal cord injury patients with heterotopic ossification. *Paraplegia* 1993;31:660-666.
- [56] Banovac K. The effect of etidronate on late development of heterotopic ossification after spinal cord injury. *J Spinal Cord Med* 2000;23:40-44.
- [57] Sullivan MP, Torres SJ, Mehta S, Ahn J. Heterotopic ossification after central nervous system trauma. A current review. *Bone Joint Res* 2013;2:51-7.
- [58] Coventry MB, Scanlon PW. The use of radiation to discourage ectopic bone: a nine-year study in surgery about the hip. *J Bone Joint Surg Am* 1981;63-A:201-8.
- [59] Knelles D, Barthel T, Karrer A, Eulert J, Kölbl O. Prevention of heterotopic ossification after total hip replacement: a prospective, randomised study using acetylsalicylic acid, indomethacin and fractional or single-dose irradiation. *J Bone Joint Surg Br* 1997;79-B:596-602.
- [60] Lo TC. Radiation therapy for heterotopic ossification. *Semin Radiat Oncol.* 1999;9(2): 163-70.

- [61] Sautter-Bihl ML, Huoltenschmidt B, Liebermeister E, Nanassy A. Fractionated and single-dose radiotherapy for heterotopic bone formation in patients with spinal cord injury: a phase-I/II study. *Strahlenther Onkol* 2001;177:200-5.
- [62] Jang SH, Shin SW, Ahn SH, Cho IH, Kim SH. Radiation therapy for heterotopic ossification in a patient with traumatic brain injury. *Yonsei Med J* 2000;41:536-9.
- [63] Hamid N, Ashraf N, Bosse MJ, Connor PM, Kellam JF, Sims SH, Stull DE, Jeray KJ, Hymes RA, Lowe TJ. Radiation therapy for heterotopic ossification prophylaxis acutely after elbow trauma: a prospective randomized study. *J Bone Joint Surg Am* 2010;92-A:2032-8.
- [64] Pape HC, Marsch S, Morley JR, Krettek, Giannoudis PV. Current concepts in the development of heterotopic ossification. *J Bone Joint Surg Br* 2004;86-B:783-7.
- [65] Garland DE, Hanscom DE, Keenan MA, Smith C, Moore T. Resection of heterotopic ossification in the adult with head trauma. *J Bone Joint Surg Am* 1985;67(8):1261-9.
- [66] Ippolito E, Formisano R, Farsetti P, Caterini R, Penta F. Excision for the treatment of periarticular ossification of the knee in patients who have a traumatic brain injury. *J Bone Joint Surg Am* 1999;81-A:783-9.
- [67] Freebourn TM, Barber DB, Able AC. The treatment of immature heterotopic ossification in spinal cord injury with combination surgery, radiation therapy and NSAID. *Spinal Cord* 1999;37:50-3.
- [68] Gacon G, Deider Ch, Rhenter J-L, Minaire P. Ectopic bone formation in neurological lesions. *Rev Chir Orthop Reparatrice Appar Mot* 1978;64:375-90.
- [69] Moreta-Suárez J, Sáez de Ugarte-Sobrón O, Martínez-de los Mozos JL. Osificaciones heterotópicas neurogénicas de cadera. A propósito de 2 casos. *Rev esp cir ortop traumatol* 2011;55:292-7.

IntechOpen

