

We are IntechOpen, the world's leading publisher of Open Access books Built by scientists, for scientists

6,900

Open access books available

185,000

International authors and editors

200M

Downloads

Our authors are among the

154

Countries delivered to

TOP 1%

most cited scientists

12.2%

Contributors from top 500 universities



WEB OF SCIENCE™

Selection of our books indexed in the Book Citation Index
in Web of Science™ Core Collection (BKCI)

Interested in publishing with us?
Contact book.department@intechopen.com

Numbers displayed above are based on latest data collected.
For more information visit www.intechopen.com



Surgical Repair of Stenotic Pulmonary Arteries in Tetralogy of Fallot

Vinicius José da Silva Nina

Additional information is available at the end of the chapter

<http://dx.doi.org/10.5772/57111>

1. Introduction

Tetralogy of Fallot (TOF), primarily named La Maladie Bleue by Louis Arthur Etienne Fallot in 1888, is the clinical description of the physiology created by a combination of anatomic malformations that consists of an interventricular communication, or ventricular septal defect, biventricular connection of the aortic root, which overrides the muscular ventricular septum, obstruction of the right ventricular outflow tract, and right ventricular hypertrophy. This cyanotic malformation belongs to a family of diseases characterized by a similar intracardiac anatomy but highly variable in terms of pulmonary artery anatomy, associated abnormalities, and outcomes; once each component can vary in its severity, with the variation directly affecting the manifestation and management of the disease.

Although the stenosis of the pulmonary trunk and its bifurcation is uncommon, the right and left pulmonary arteries are stenotic to some degree in 30% of infants with Tetralogy of Fallot presenting in the first year of life [1-3].

Based on this premise, here we focus on pulmonary artery anatomy which is one of the most challenging components of Tetralogy of Fallot especially regarding the complexity of its surgical repair and the selection of materials to accomplish such repair. Decision making, timing and techniques for repairing each of these pulmonary artery variants are emphasized in this chapter according to the authors experience and also based on the best evidence in the literature.

2. Morphologic categories of pulmonary artery anatomy in Tetralogy of Fallot

Size and configuration of the pulmonary arteries have been thought to be important determinants of postoperative right ventricular function after complete repair of tetralogy of Fallot. As such, they may affect the result of repair when the pulmonary arteries are hypoplastic or stenotic [1].

Hypoplasia or narrowness, in the arterial pathways in patients having TOF with pulmonary stenosis is most marked centrally in the RV infundibulum and pulmonary trunk. On average, the RPA and LPA and their branches are not abnormally small. This does not deny the occasional existence of severe narrowing at the origin of the LPA or RPA. Elzenga et al [5] found juxtaductal proximal stenosis of the LPA in 10% of patients having TOF with pulmonary stenosis; about 90% are free of these severe finding [4, 6].

The nearly infinitely variable spectrum of pulmonary artery obstruction in TOF can be conveniently categorized in a way that is surgically useful because it relates to difficulty in obtaining good relief of the pulmonary stenosis and therefore to surgical techniques and mortality. Because of this great variability in the dimensions of the pulmonary arteries, their careful pre-repair study is very important. In this regard we have didactically separated the pulmonary artery tree into three anatomical segments:

- pulmonary trunk;
- pulmonary trunk bifurcation and;
- pulmonary branches (right and left pulmonary arteries).

3. Pulmonary trunk

In TOF, the pulmonary trunk is nearly always smaller than the aorta. Reduction is most marked when there is a diffuse RV outflow hypoplasia. In this case, the pulmonary trunk is less than half the aortic diameter and is short, directed sharply posterior to its bifurcation. It is largely hidden from view at operation by the prominent aorta, which also displaces the origin of the trunk leftward and posteriorly [4].

When the pulmonary valve is markedly dysplastic, the pulmonary trunk is also stenotic or corseted at its commissural attachments, and it may be very angulated or kinked at this point. This is the usual mechanism of supralvalvar narrowing, and it is not associated with wall thickening. Rarely, however, there may be a discrete supralvalvar narrowing beyond commissural level with diffuse wall thickening [1, 6].

4. Pulmonary trunk bifurcation

The left pulmonary artery (LPA) is usually a direct continuation of the pulmonary trunk; with the right pulmonary artery (RPA) arising almost at right angles and close to it, but this pattern varies. In TOF is uncommon to have the distal pulmonary trunk and origin of RPA and LPA being moderately or severely narrowed (bifurcation stenosis), and in this situation the bifurcation may have a Y shape [7] (Fig.1)

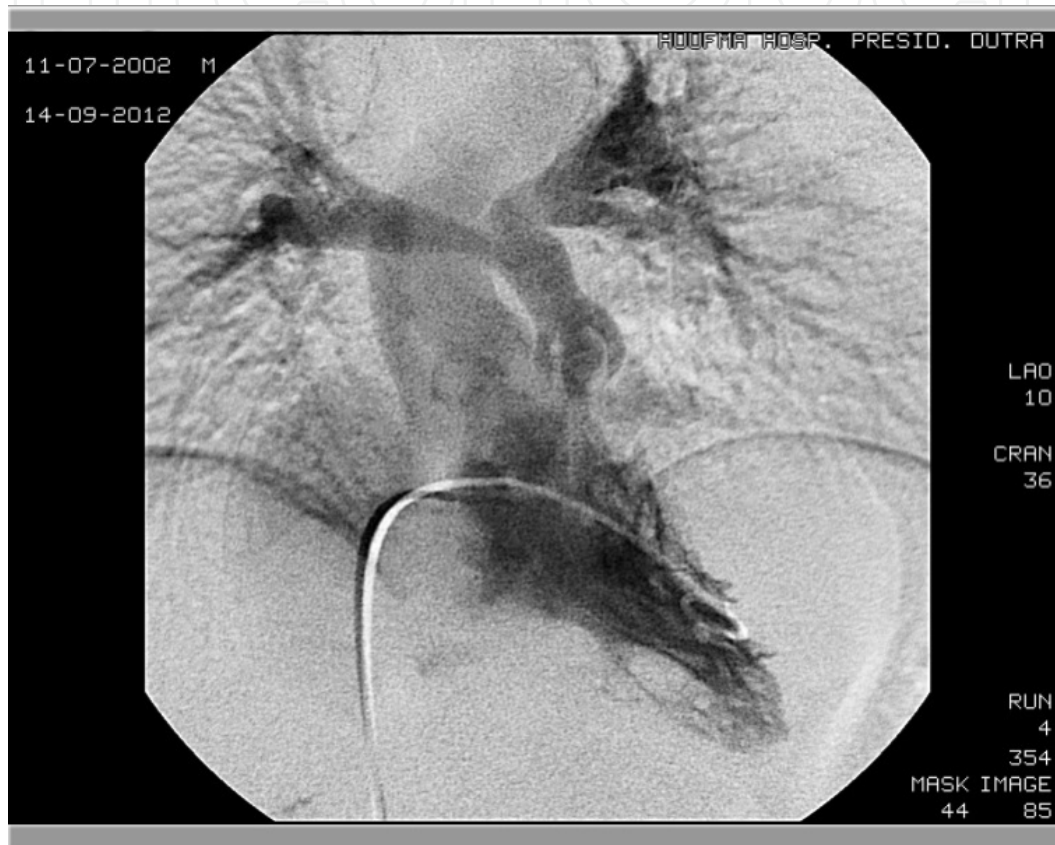

Figure 1. Angiogram showing stenosis of distal pulmonary trunk. Note that the LPA is a continuation of the pulmonary trunk.

5. Right and left pulmonary arteries

Although anomalies of the RPA and LPA are more common in TOF with pulmonary atresia rather than stenosis, Fellows et al found pulmonary artery anomalies in 30% of infants having TOF with pulmonary stenosis presenting in the first year of life [4,8].

The more severe the hypoplasia of the infundibulum and pulmonary trunk, the more severe is the narrowing of the first part of the right and left pulmonary arteries, although the Z values of these structures are usually larger than those of the pulmonary trunk [6]. (Fig.2)

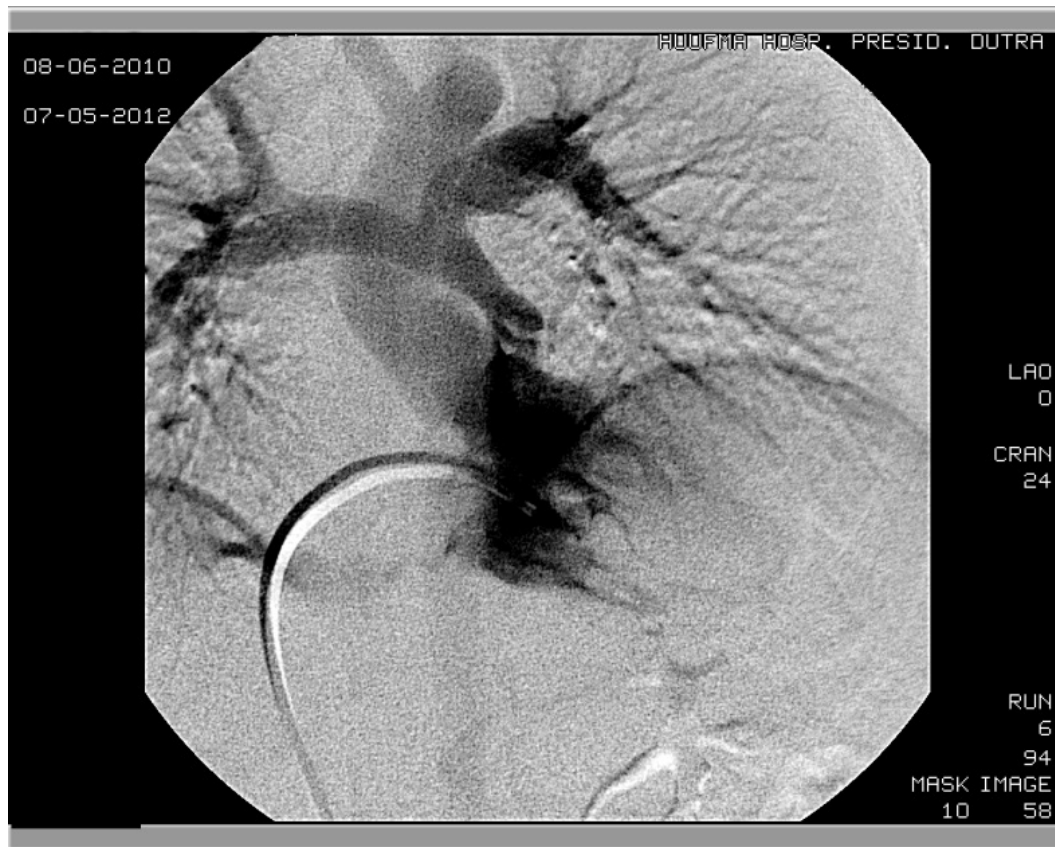

Figure 2. Angiogram showing stenosis of pulmonary trunk bifurcation. Note the Y shape of the pulmonary trunk bifurcation.

6. Surgical approach over the pulmonary trunk and branches

Pulmonary artery branch stenoses are widely known congenital anomalies especially in children with TOF. Many authors have reported hypoplastic or stenotic pulmonary artery branches to be a major obstacle to successful operative correction of TOF [7,9-13].

In this section we present different techniques and materials that can be used to repair such diseased pulmonary arteries according to their location, size and anatomical configuration.

7. Pulmonary trunk stenosis

In cases of pulmonary trunk stenosis some steps must be followed in order to obtain a successful surgical repair:

1. Sizing the pulmonary trunk

If the pulmonary valve annulus is hypoplastic, the infundibulotomy incision is extended across the annulus between the valve commissures as far as needed (up to the bifurcation or up to

the left or right pulmonary artery). The size of the pulmonary trunk and of the left and right pulmonary arteries is measured by Hegar probes, and then those arteries are calibrated to fit a normal diameter, adjusted to the child's body surface area [14-16].(Table 1)

BSA (m ²)	Pulmonary Annulus
0.25	8.4
0.30	9.3
0.35	10.1
0.40	10.7
0.45	11.3
0.50	11.9
0.60	12.8
0.70	13.5
0.80	14.2
0.90	14.8
1.0	15.3
1.2	16.2
1.4	17.0
1.6	17.6
1.8	18.2
2.0	19.0

Data from Rowlatt et al. ¹⁴

Table 1. Mean normal diameter of pulmonary valve

In some patients the distal pulmonary trunk is narrower than the annulus; in these cases the incision is extended into the LPA, which usually continues in the same general direction as the pulmonary trunk and is usually proportionally larger than the distal pulmonary trunk. If the origin of the LPA is proportionally no larger than the distal pulmonary trunk, then the incision and patch reconstruction should be carried into the mid portion of the LPA, which is nearly always wider than the origin [1,4,6].

2. Measuring the patch

Generally, a transannular patch should not be placed when the Z value is larger than -3. Otherwise, the incision is carried across the annulus, the pulmonary valve excised, and the patch inserted.

The length of the patch can be determined by measuring length of the incision from the RV to the pulmonary artery, and its maximum width is determined visually by holding the edges of

the incision open at valve level and judging the size of the roof required to create a new pulmonary annulus whose diameter is no larger than three fourths the diameter of the ascending aorta [4,17] (Fig. 3).

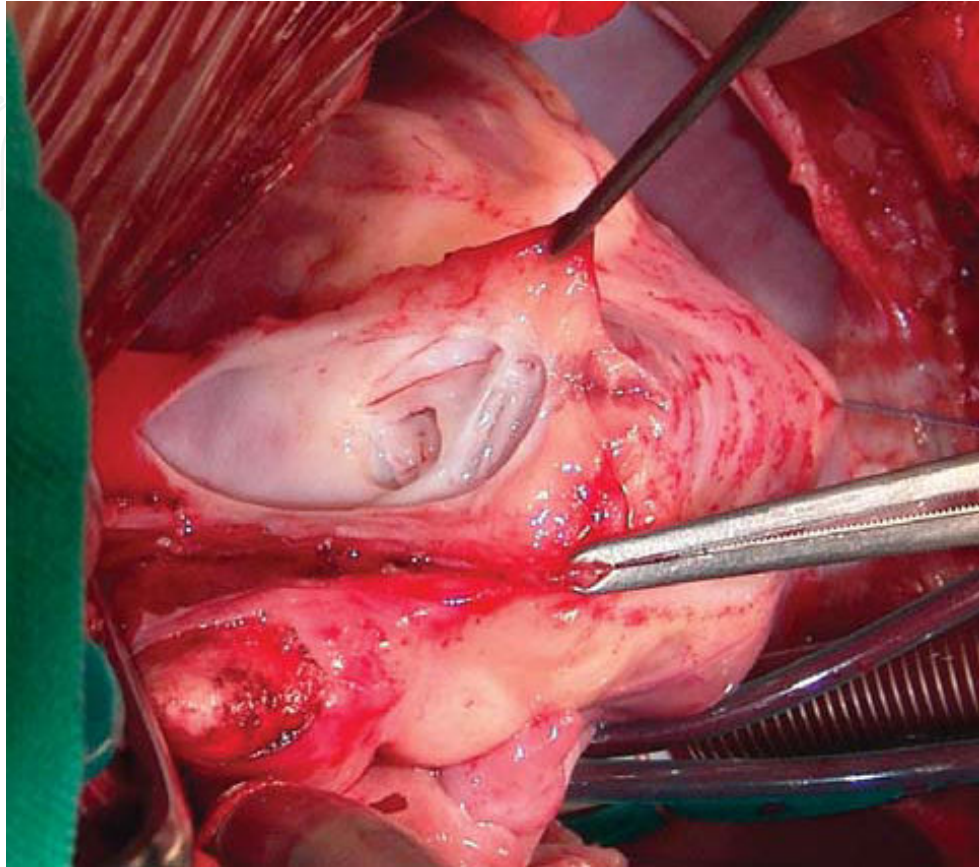


Figure 3. Measuring the patch. Pulmonary trunk opened with a dysplastic pulmonary valve (From Jacob M F F B et al [17] with permission)

Alternatively a Hegar dilator can be placed through the divided annulus and the width of the patch required to complete the roof over it measured. Usually, the patch is about 50mm long and 15mm wide at its center. Both ends are cut almost transversely to create a blunt patch. When a transannular patch is used, a major consideration is the distal extent of the incision in the pulmonary trunk, because this must be into an area of distinctly greater diameter than that of the annulus, which is usually the narrowest area [4,17] (Fig. 4)

3. Selecting the patch

The transannular patch may be of glutaraldehyde-treated or untreated pericardium. Glutaraldehyde-treated pericardium is advantageous because it facilitates precise sizing of the patch, and when properly trimmed, its convexity is ensured, as is a relatively square cut of its distal end. Thus, when it is inserted, it forms a roof that is convex in all directions relieving the transpulmonary gradient. Although technically more demanding; untreated, especially pedicled pericardium has the potential advantage of growing as the child grows [9,10,17,18].

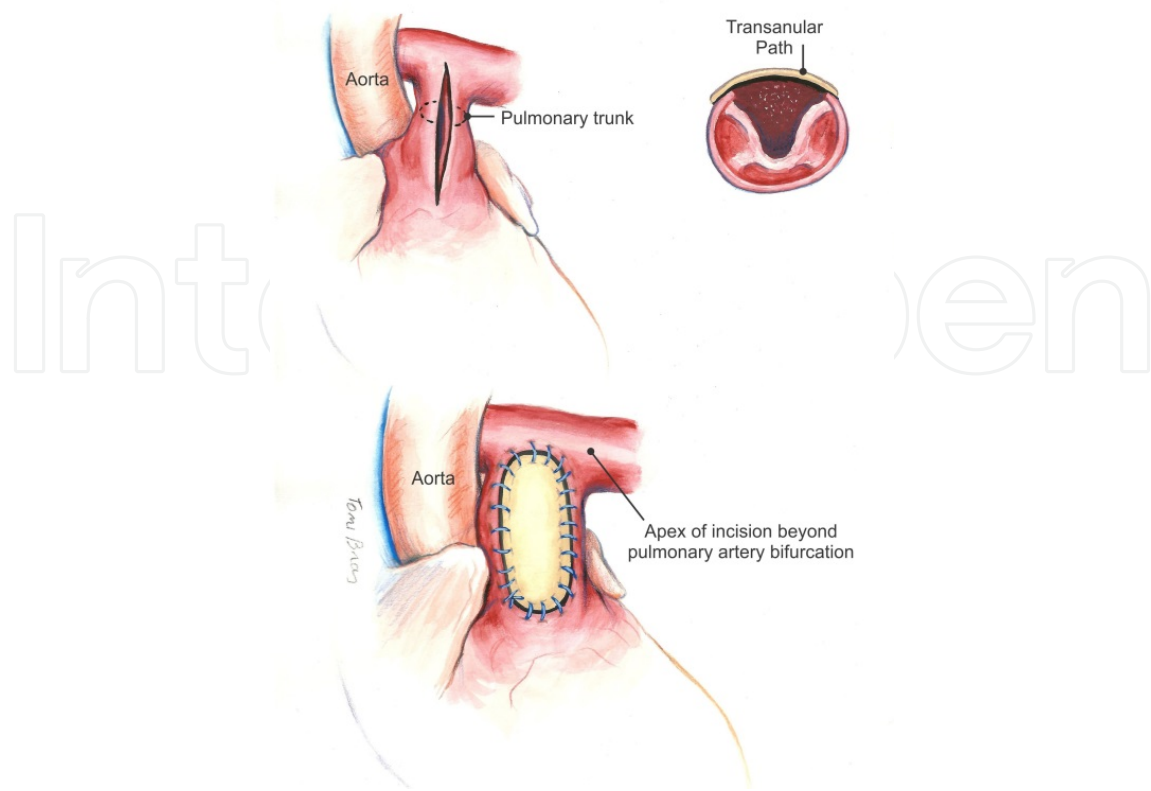


Figure 4. Transannular patch repair of TOF with pulmonary stenosis. Note the pericardial roofing to enlarge the valve annulus and proximal pulmonary trunk..

4. Inserting the patch

a. Glutaraldehyde-treated pericardium

The patch is positioned using continuous 5-0 polypropylene sutures, commencing at the distal end of the incision. The suture is mattressed at the end and over and over elsewhere, placing the first two or three throws along each side before pulling the pericardial patch into position as the suture is tightened. Suturing is continued down each side to annulus level; then the remainder of the right ventriculotomy is closed by incorporating the pericardial patch into it with continuous sutures. Deep bites of muscle are taken down each side and at the angle [17] (Fig 5).

b. Untrated pedicled pericardium

- Preparation and tailoring of the pericardial flap:

The broadly based pericardial flaps are tailored before cardiopulmonary bypass begins. The pericardial sac is usually opened transversely in the midline near the diaphragm. The incision is extended along the diaphragm toward both phrenic nerves and then goes cephalad, paralleling the right phrenic nerve closely, until the flap can be rotated in front of the pulmonary arterial segment needed to be repaired. The pericardium usually remained normally attached on the left side with the left phrenic nerve along its base [18,19] (Fig. 6).

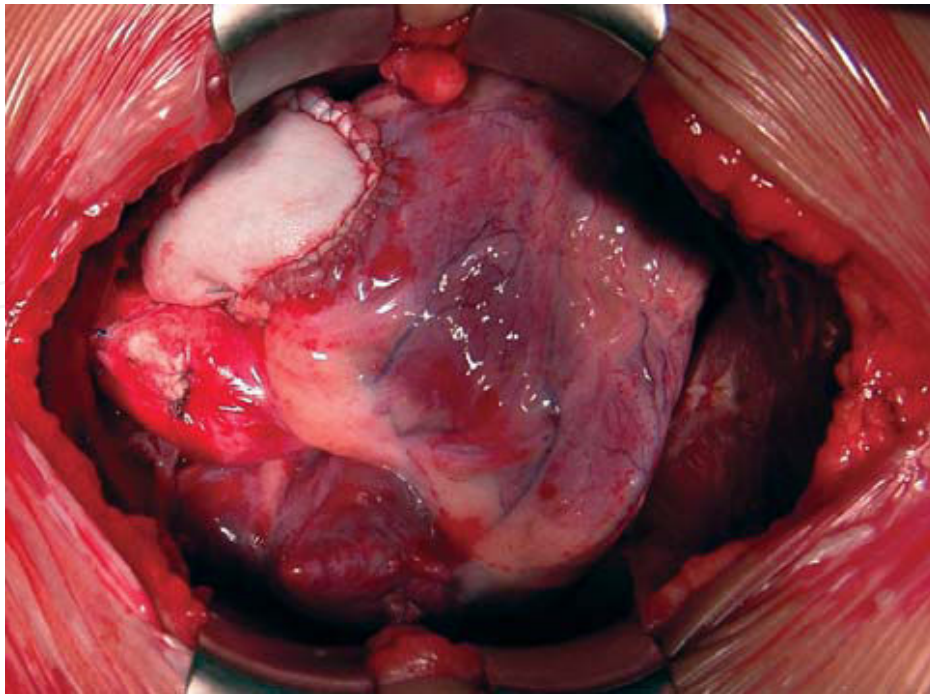


Figure 5. Enlargement of the right ventricular outflow tract with bovine pericardium patch. (From Jacob M F F B et al [17] with permission)

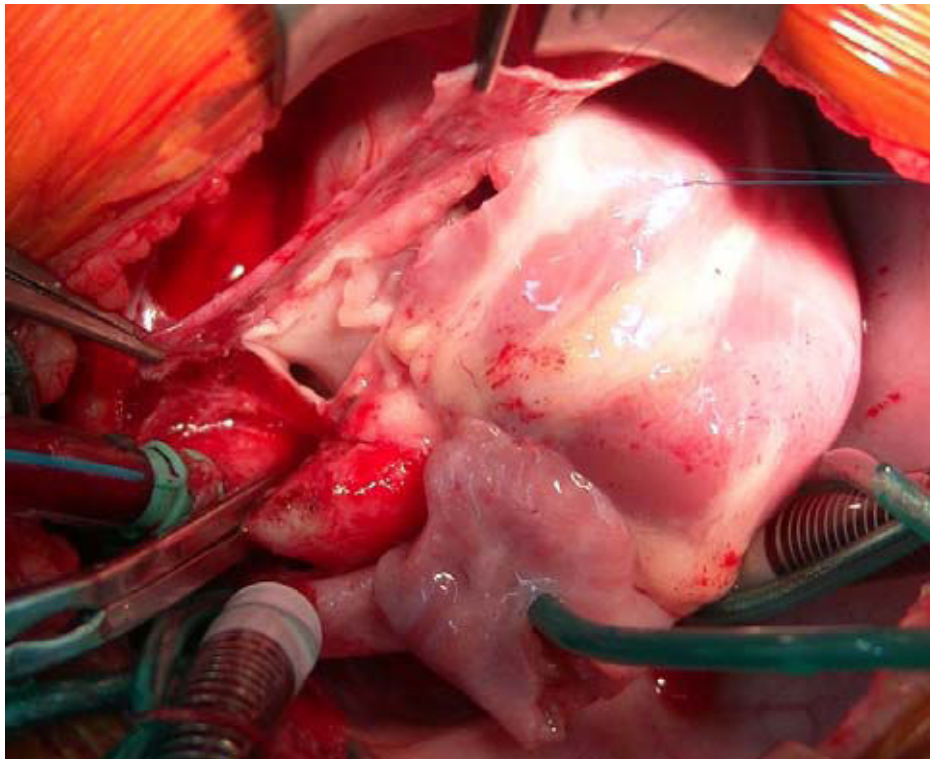


Figure 6. Surgical aspect of the pedicled autologous pericardium (tweezers) before enlargement. The anterior side of the right ventricular outflow tract, valve ring and pulmonary trunk can also be observed. (From Croti, UA et al [18] with permission)

- Inserting the pedicled pericardium patch

After incising the anterior aspect of the pulmonary trunk, pulmonary valve ring and right ventricular outflow tract, the valve ring is measured using Hegar dilator according to the body surface area as previously described, then the suture of the pericardium is begun at the lateral edge by implanting the patch on a tile-shaped using 6-0 polydioxanone thread throughout the suture.

The aim of this approach is to allow for growth and to avoid future calcification, among other known problems existing with several materials that can be used for this purpose [19] (Fig.7).

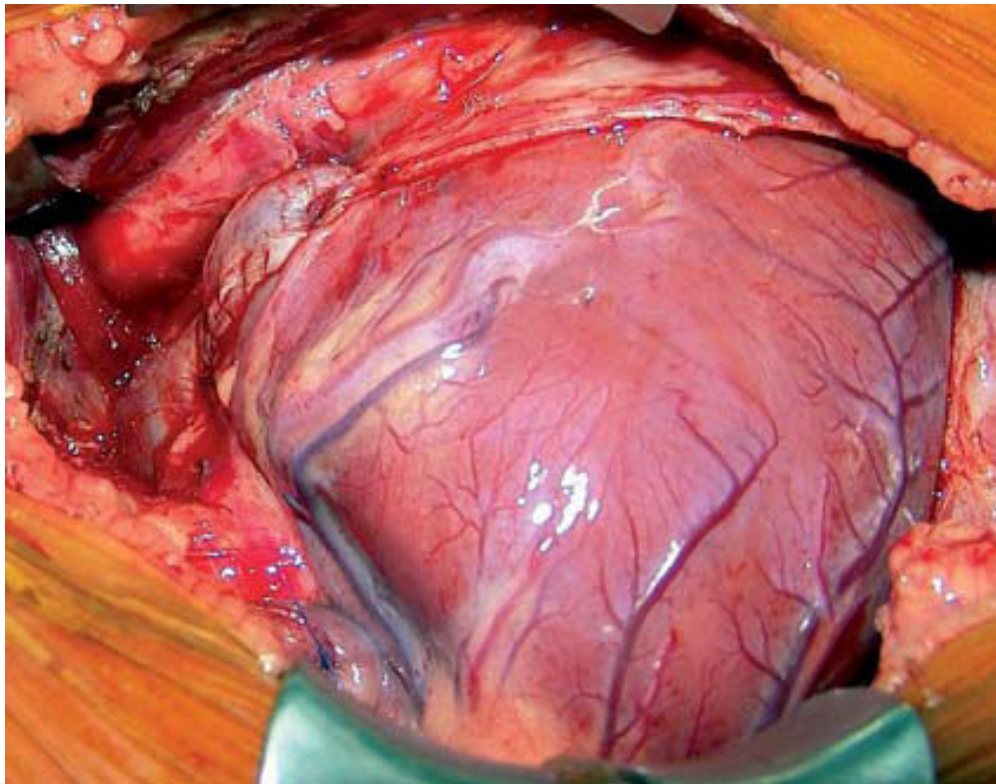


Figure 7. Final aspect after pedicled autologous pericardium implantation to enlarge the right ventricular outflow tract, valve ring and pulmonary trunk (From Croti, UA et al [18] with permission)

- Using a valved patch

If it is anticipated that a too large transannular patch will be required, a monocusp may be attached to the pericardial roofing patch to prevent increasing postoperative pulmonary regurgitation. The cusp diameter is fashioned somewhat larger than the planned roofed RV outflow. It is cut more or less circular and sutured to the patch when the latter suturing from distally reaches the valve annulus. Numerous materials, such as polytetrafluoroethylene, porcine heterografts, allografts and others can also be used to repair the pulmonary trunk in this situation [21,22](Fig.8).

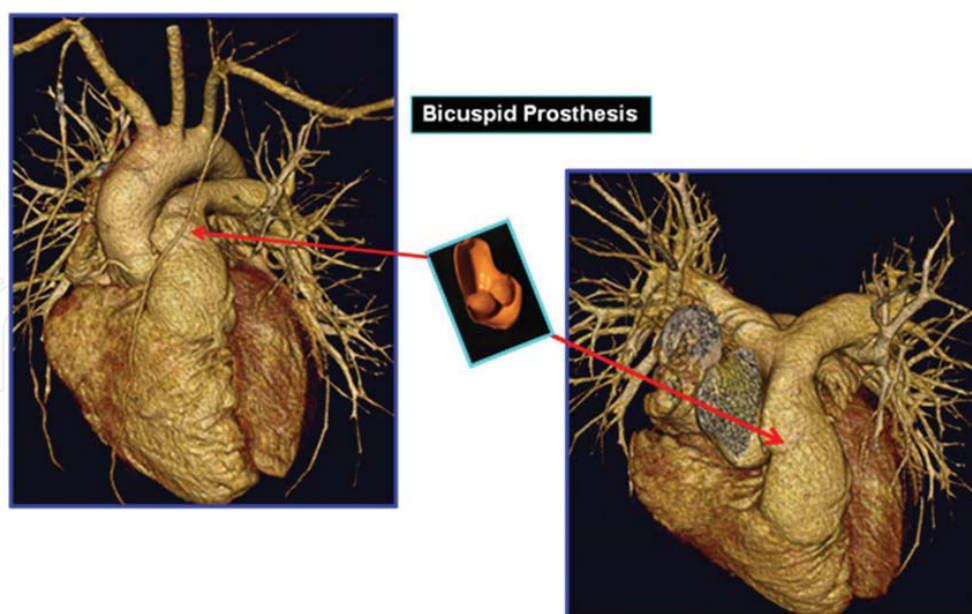


Figure 8. Computerized tomography in a patient with tetralogy of Fallot submitted to surgical repair of the right ventricular outflow tract with an implant of a preserved porcine pulmonary bicuspid prosthesis (inset). (From Maluf MA et al [21] with permission)

If the surgeon's preference is for a monocusp allograft and, considering that only one cusp will be used and that the size of aortic or pulmonary cusps in adults can vary by only a few millimeters, a graft between 17mm and 23mm in diameter is chosen according to the ring size based on the body surface area as it has already been described above [22] (Fig.9).

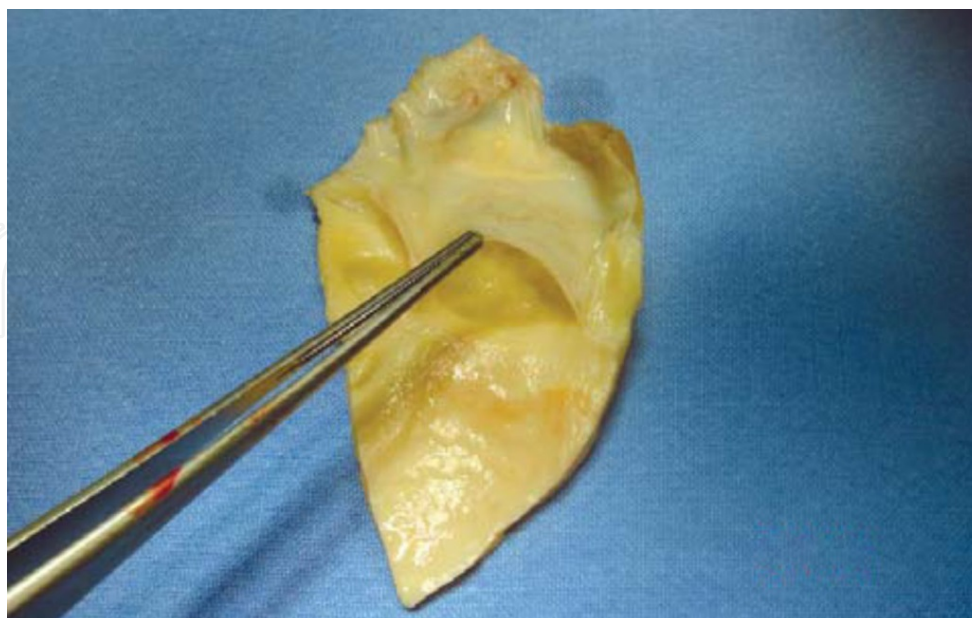


Figure 9. Aortic monocusp allograft with the anterior leaflet of the mitral valve (From Mulinari L A et al [22] with permission)

Technique of implantation: after inspecting the graft, one of the larger cusps is selected. Then, the graft is cut to fit a segment of the aortic or pulmonary wall that is distal to this cusp. Using a N° 5-0 polypropylene suture, the procedure is done in such way that the cusp edge can be at the same level of the edges of the native pulmonary valve [22] (Fig 10).

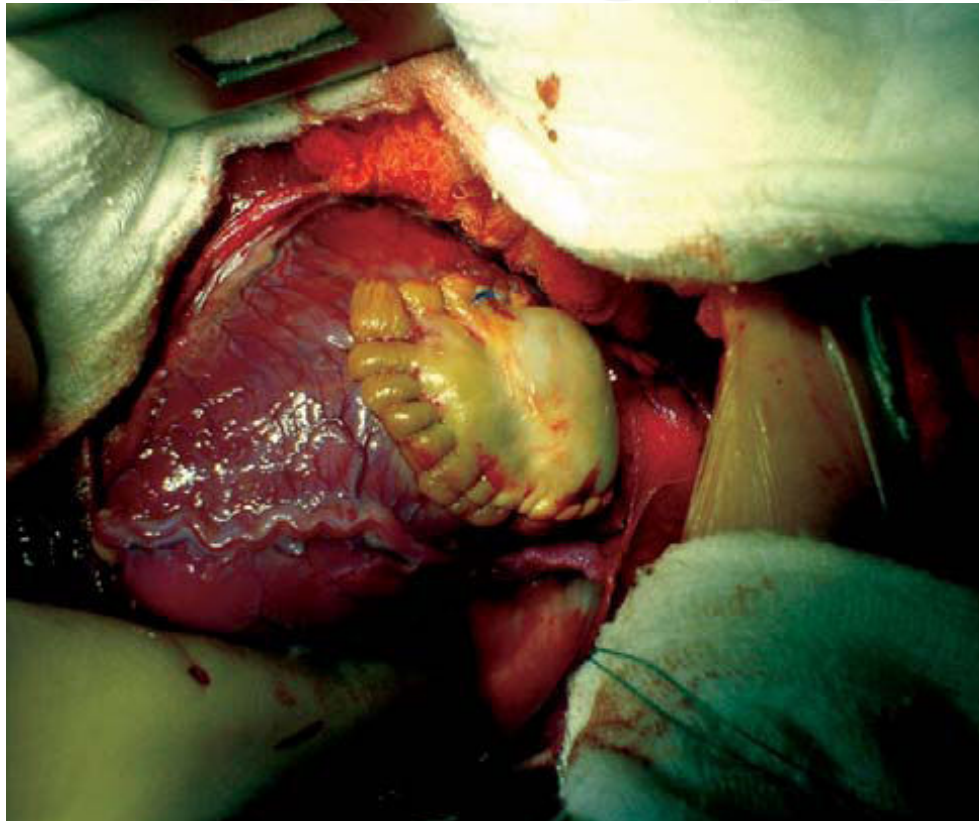


Figure 10. Pulmonary monocusp allograft implantation (From Mulinari L A et al [22] with permission)

8. Left pulmonary artery stenosis

As postulated by Kalangos et al [23] only one of the pulmonary artery branches has the same anatomical direction as the main stem of the PA, either the right or the left pulmonary artery. This particular feature is important because it can directly affect the surgical outcome; therefore, the patch enlargement technique must be performed in accordance to the anatomy of the pulmonary arch in each individual case (Fig. 11)

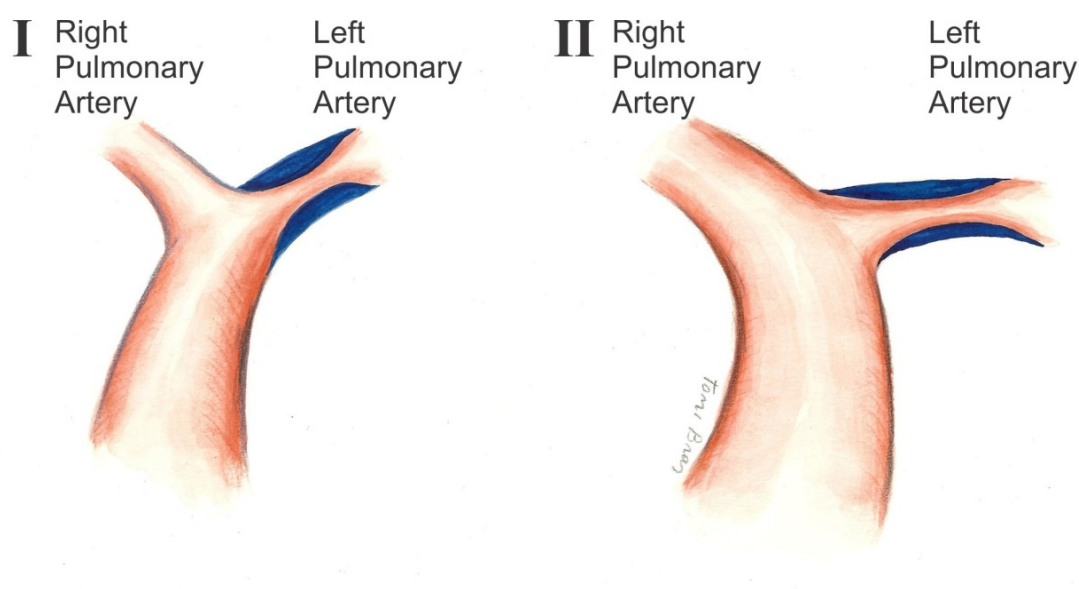


Figure 11. The pulmonary arch morphology. Please note that only one of the pulmonary artery (PA) branches has the same flow direction as the main stem of the PA, either the left PA (I) or the right PA (II) (From Kalangos A et al [23] with permission).

In most of the cases a single transannular patch enlargement extending into the LPA is sufficient to repair stenosis of the origin of the LPA when it has the same axis as the main PA (Fig. 12)

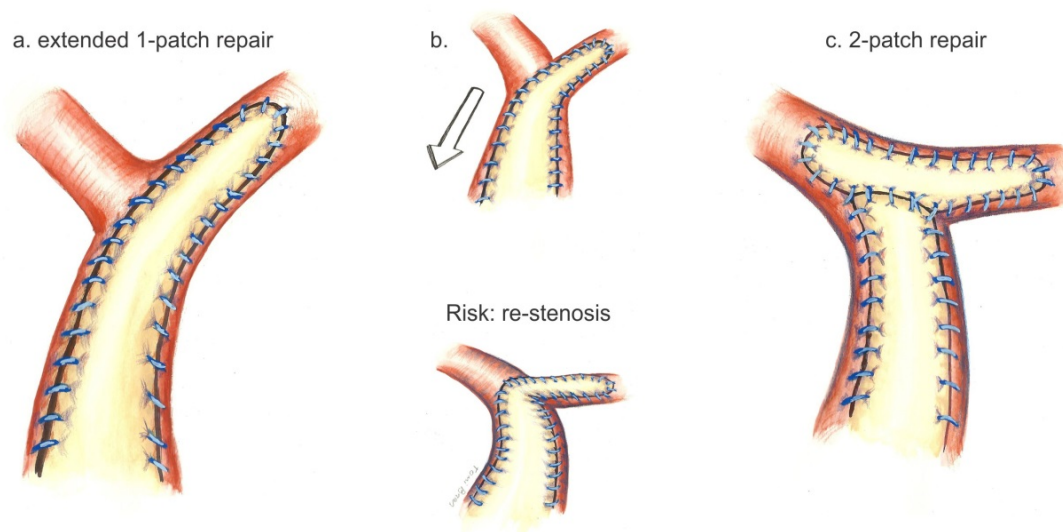


Figure 12. Reconstruction of the origin of the pulmonary artery (PA) branches for patients with left PA stenosis. (a) The left PA has the same axis as the main PA; Surgical technique: 1-patch enlargement extending into the left PA. If the right PA is the branch with the same axis as the main PA: (b) 1-patch extending into the left PA is not a suitable technique because of later risk of "kinking" which will lead to restenosis; (c) A 2-patch enlargement technique avoids the risk of "kinking" and will reduce the risk for later restenosis. (From Kalangos A et al [23] with permission).

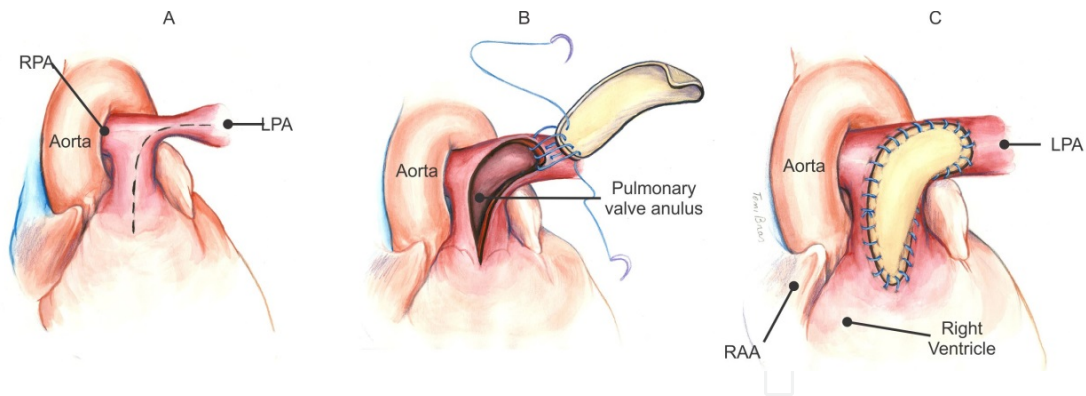


Figure 13. A- Stenosis of LPA. Dashed line indicates extent of incision. B- Single-patch repair of stenosis of LPA. C- Complete repair. Note that LPA has the same axis as the pulmonary trunk. LPA - Left pulmonary artery RPA - Right pulmonary artery

As the LPA is usually an extension of the pulmonary trunk, isolated stenosis at origin of LPA is uncommon. In these uncommon situations in which a transannular patch is not needed, an incision is made across the stenosis in the origin of the LPA and a rectangular patch of pericardium is trimmed and sewn in to place using N° 6-0 polypropylene sutures [4,23] (Fig. 14)

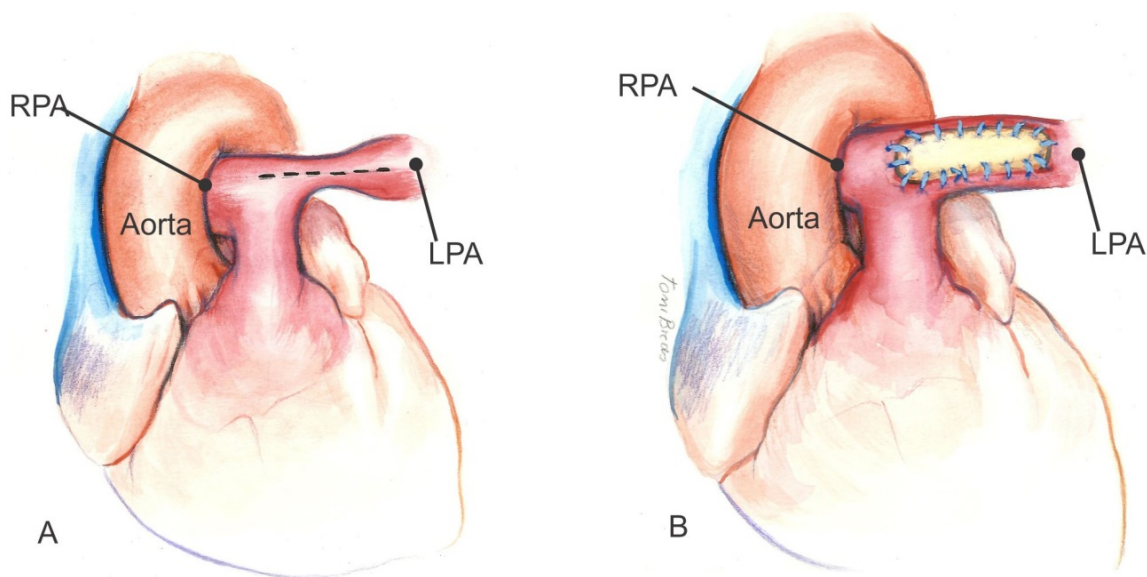


Figure 14. A- Isolated stenosis at origin of LPA. Dashed line indicates extent of incision. B- Single-patch repair at origin of LPA. LPA - Left pulmonary artery RPA - Right pulmonary artery

9. Right pulmonary artery stenosis

The RPA is usually not an extension of the pulmonary trunk but comes off its side at a right angle requiring a more complex repair than that used for stenosis of the LPA [1,15,23].

After mobilizing the aorta, the pulmonary trunk and the left and right pulmonary branches, the origin of the RPA is disconnected from the pulmonary trunk. Lateral incisions are made to enlarge the orifice in the side of the pulmonary trunk. The RPA is incised from its narrow orifice back into its wide portion. A rectangular piece of pericardium is trimmed and sewn to the RPA to make a markedly enlarged proximal RPA. The proximal end of the reconstructed RPA is then sutured to the enlarged orifice in the side of the pulmonary trunk using N° 6-0 polypropylene sutures and closely placed sutures, while taking care to avoid any purse-string effect [4,23] (Fig.15)

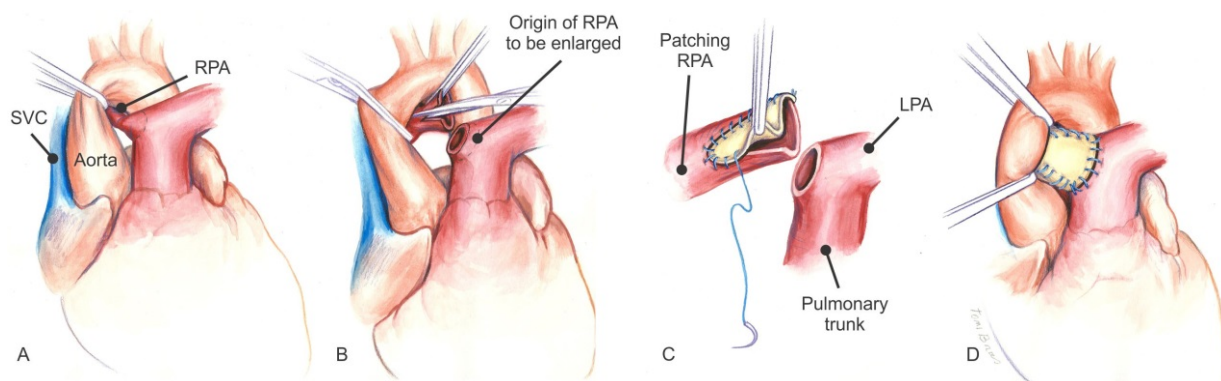


Figure 15. A- Exposure of RPA by mobilizing the aorta. B- RPA is disconnected from the pulmonary trunk. Dashed line indicates extent of incision. C- Single-patch repair of the anterior aspect of RPA. D- Re-anastomosis of the enlarged RPA to the pulmonary trunk. LPA - Left pulmonary artery RPA - Right pulmonary artery. SVC – Superior Vena Cava.

Another alternative is to suture the posterior edge of the opened RPA to the back wall of the opened pulmonary trunk. A rectangular piece of pericardium is then sewn to the remaining opening to widen it further; however, this technique is more demanding and may generate tension on the anastomosis.

Transection of the ascending aorta may improve exposure in cases of stenosis of the proximal RPA as described by Singh et al [24] (Fig.16)

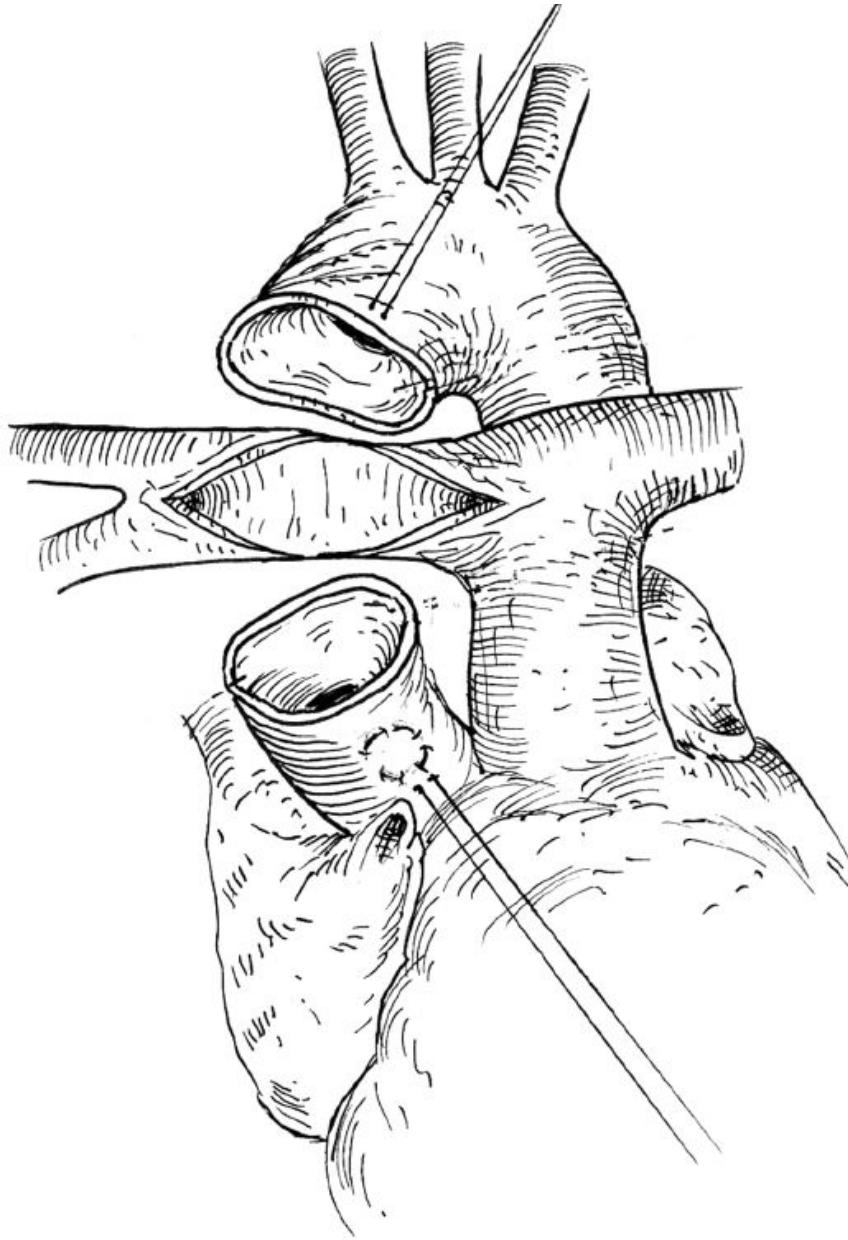


Figure 16. The ends of the transected ascending aorta retracted to expose the proximal right pulmonary artery (From Singh et al [24] with permission)

As shown in the figure above, the aortic transection facilitates exposure of the distal main PA, confluence and branches up to the hilum, especially in patients with difficult anatomy and sternal re-entry. This maneuver is recommended in patients requiring exposure of the main PA, its bifurcation, and branches during surgery for congenital heart disease, especially if adequate exposure is critical for successful repair (Fig. 17).

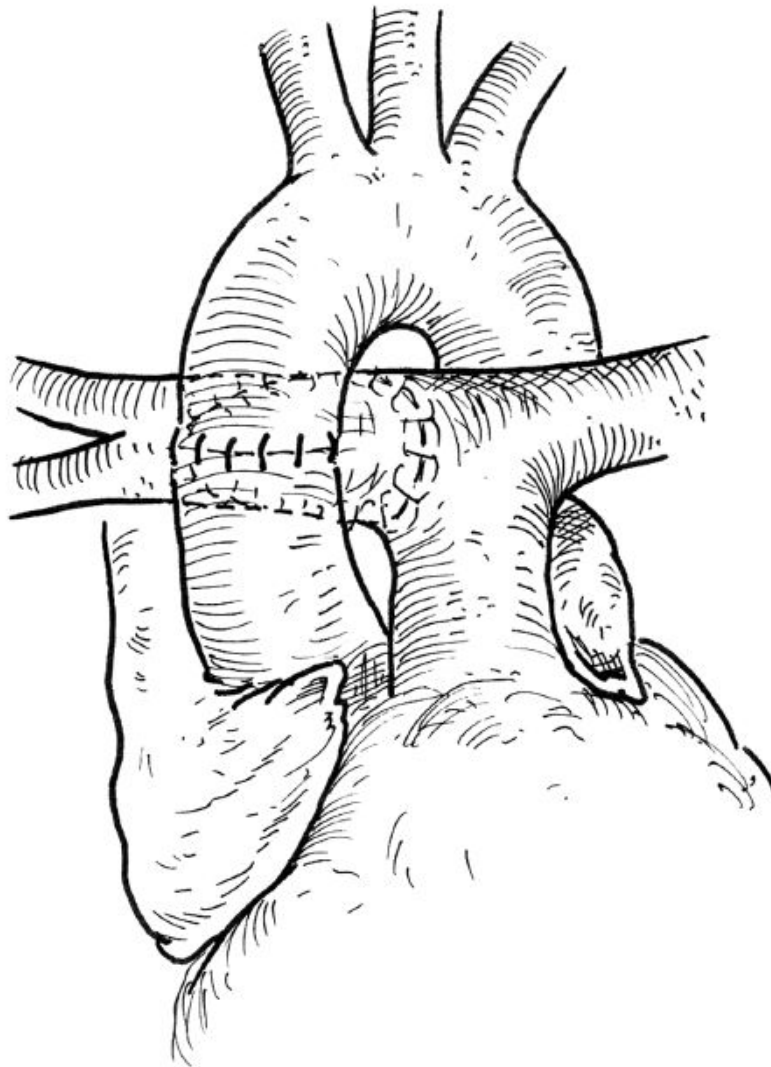


Figure 17. Completed reconstruction of the proximal right pulmonary artery and the aortic anastomosis (From Singh et al [24] with permission)

10. Bifurcation stenosis of the pulmonary trunk

The most common location of recurrent RVOT obstruction is at the pulmonary bifurcation or at the origin of the pulmonary artery branches [7,25].

Bifurcation stenosis is characterized by both LPA and RPA ostia stenosis to a similar degree and over a short distance (<15 mm) with the distal pulmonary trunk similarly narrowed making the bifurcation more Y shape than usual. However, repair of bifurcation stenosis is indicated only when the stenosis is severe [1,4,6,7,16].

The first option for infants is repair rather than replacement; however, in children age 5 years or older, the optimal procedure may be to replace the pulmonary valve, trunk, bifurcation, and proximal RPA and LPA with a pulmonary allograft [22,26,27].

Selecting the graft:

A 22- to 25-mm-diameter allograft can provide a good hemodynamic result in this complex situation. There is a trend towards the RVOT enlargement using a homologous and decellularized allograft putting forward a theoretical attempt of a graft with greater durability potential than those currently available. Decellularized grafts may be related to a lower immune response when compared with cryopreserved grafts [22, 27-32].(Fig. 18)

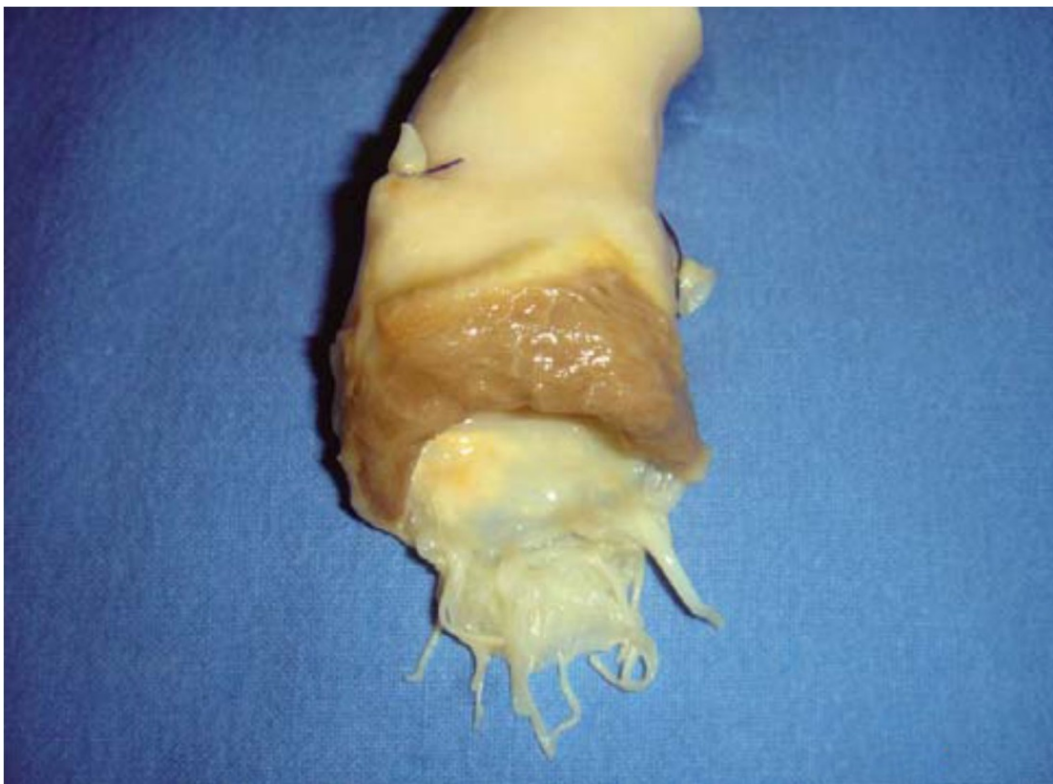

Figure 18. Decellularized aortic allograft(From Mulinari L A et al [22] with permission)

11. Surgical technique

a. Repair (for children < 5 years old)

The aortopulmonary septum is dissected and the ascending aorta is freed completely from the main PA and its branches, and then mobilized. A resection of the anterior aspect of the entire bifurcation is performed in a Y-shape fashion. The defect is repaired with a Y-shaped patch (pericardium, PTFE or allograft) using 6-0 or 7-0 absorbable sutures. (Fig. 19)

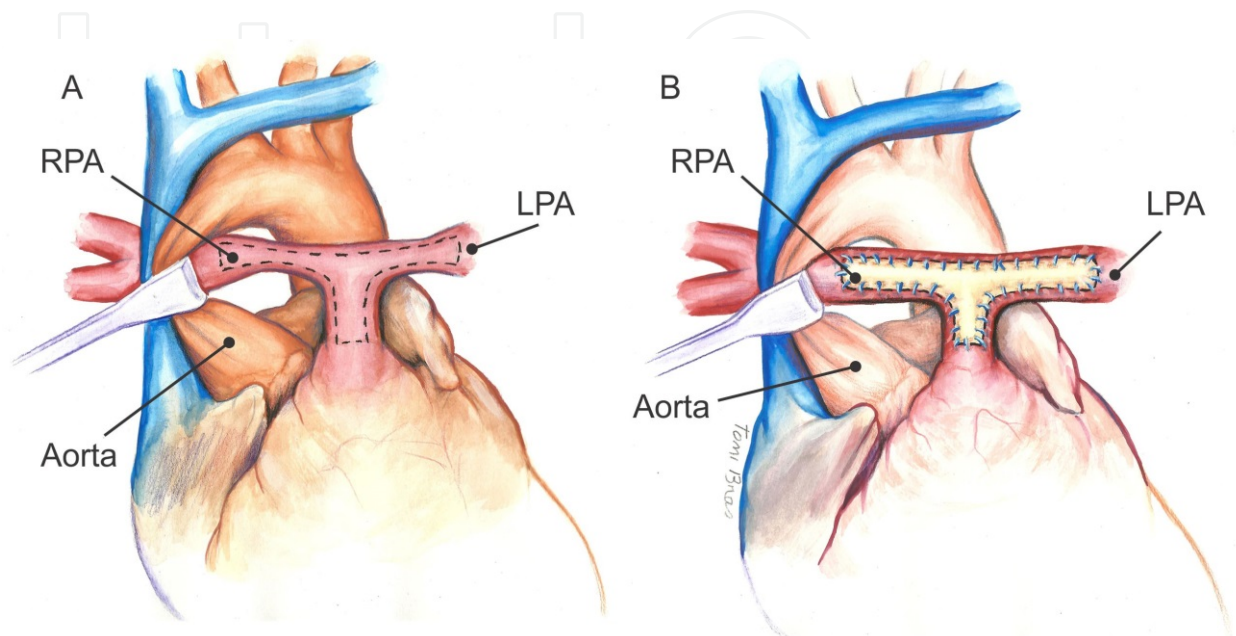


Figure 19. A- Pulmonary trunk and bifurcation stenosis. Dashed line indicates extent of incision. B- Single-Y-shape-patch repair of pulmonary artery bifurcation. LPA - Left pulmonary artery RPA - Right pulmonary artery.

b. Replacement (for children ≥ 5 years old)

The entire ascending aorta is completely freed from its posterior connections and from pulmonary trunk and its bifurcation. At this time, the ascending aorta may be divided if required [23]. The superior vena cava is completely mobilized and the RPA and LPA are dissected to the point where the first branch is visualized and subsequently transected beyond the narrow areas. A vertical ventriculotomy is carried across the annulus into the pulmonary trunk which is ultimately transected.

A 22- to 25-mm-diameter allograft can provide a good hemodynamic result in this complex situation.

Distal anastomoses are made first with continuous N° 5-0 or 6-0 polypropylene suture. The proximal conduit anastomosis is made by commencing the suturing posteriorly where the allograft is opposed to the superior margin of the ventriculotomy using an N° 4-0 polypropylene suture. The suture line is continued from the midline along both sides around about half the circumference of the conduit, and the sutures are held. A patch of pericardium 2 to 5 mm larger than the diameter of the allograft valve annulus is cut to an approximate semilunar shape and sutured into place to complete the anterior half of the anastomosis serving as a roof on the ventriculotomy incision and preventing the graft distortion. [4,22,32] (Fig. 20)

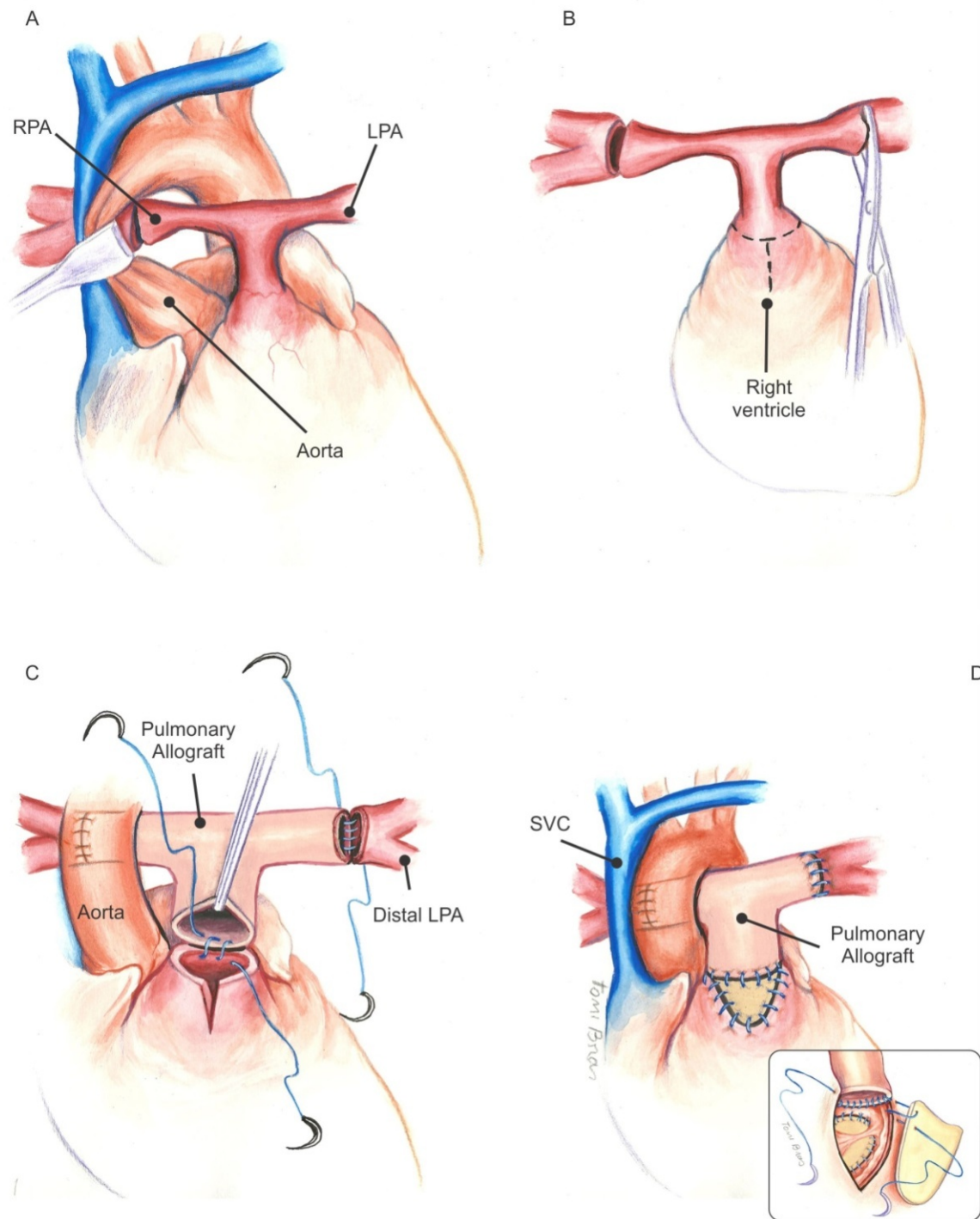


Figure 20. A- Pulmonary trunk and bifurcation stenosis. B- Resection of pulmonary trunk and its bifurcation. Dashed line indicates extent of resection. C- Replacement of pulmonary bifurcation with interposition of a pulmonary allograft. D- Completion of the replacement. Note the insertion of a pericardial roof on the ventriculotomy to prevent allograft distortion (inlet). LPA - Left pulmonary artery RPA - Right pulmonary artery. SVC – Superior Vena Cava.

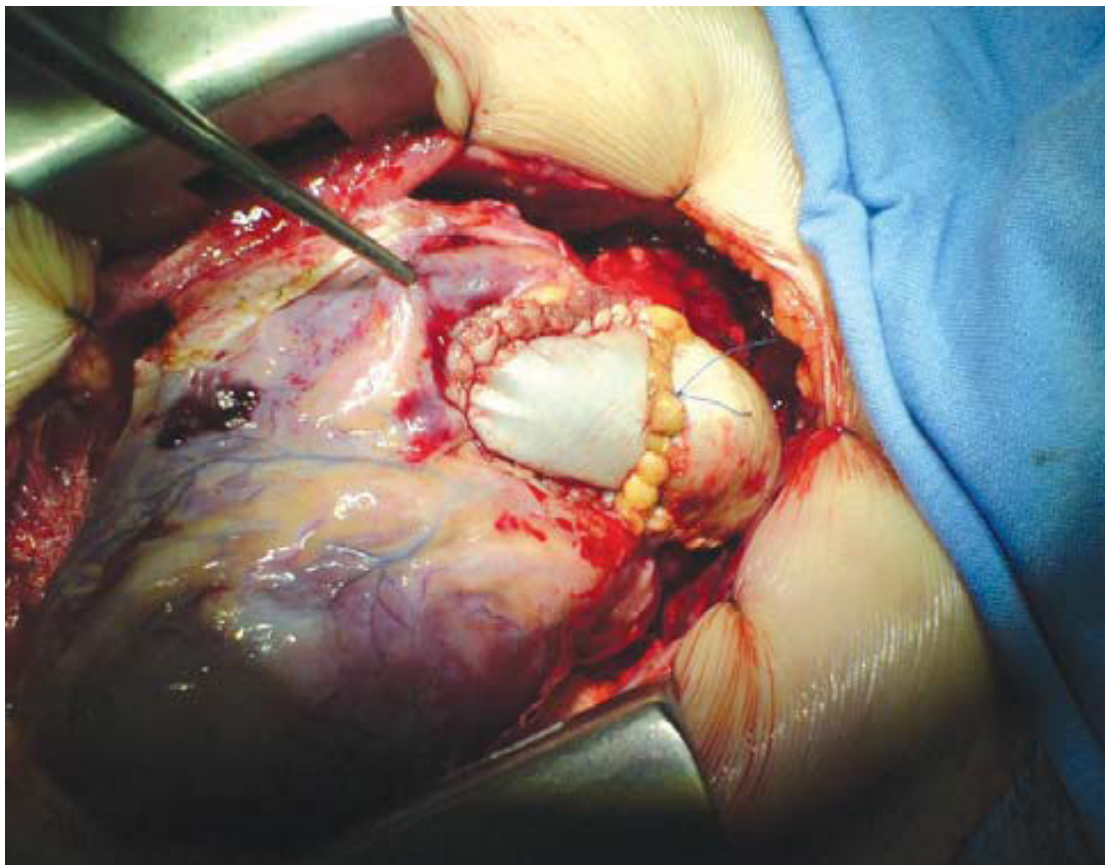


Figure 21. Pulmonary allograft implantation with bovine pericardium extension (From Mulinari L A et al [22] with permission)

12. Special remarks

- Isolated LPA and RPA stenosis in TOF requires distinct surgical repair otherwise a residual stenosis or arterial kinking may occur.
- Replacement of the entire pulmonary bifurcation must be reserved for children 5 years of age and over with severe bifurcation stenosis for whom allograft insertion seems to be the best option.
- Decellularized allograft for patching and also as a conduit is a promising alternative for reconstruction of the pulmonary trunk and its branches in TOF
- If a conduit insertion is required, care must be taken to position it nearly in the same position as a normal pulmonary artery by directing it toward the patient's left shoulder as it come off the right ventriculotomy in order to prevent compression by the sternum.
- Although the growth potential of pedicled pericardium has not been clearly demonstrated, it is a very attractive alternative for enlargement of small pulmonary arteries or the RVOT in TOF or pulmonary atresia because it maintains its native vascular and neural supply

which may avoid further reoperations to replace the pulmonary arterial trunk with an extracardiac conduit after growth of the child.

- Postoperative RV/LV ratio ≥ 0.9 indicates residual obstruction either muscular or arterial, which must be promptly surgically removed or ameliorated by percutaneous balloon dilatation, if possible.

Author details

Vinicius José da Silva Nina

Cardiac Surgery Unit, University Hospital of the Federal University of Maranhão, Brazil

References

- [1] Anderson RH, Weinberg PM: *The clinical anatomy of tetralogy of Fallot*. Cardiology in the Young 2005, 15 (Suppl 1):38-47.
- [2] Bailliard F, Anderson R H. *Tetralogy of Fallot: Review*. Orphanet Journal of Rare Diseases 2009, 4:2
- [3] Apitz C, Webb G D, Redington A N. *Tetralogy of Fallot: Seminar*. Lancet 2009; 374: 1462-71.
- [4] Kouchoukos NT, Blackstone EH, Doty DB, Hanley FL, Karp RB. *Ventricular septal defect with pulmonary stenosis or atresia*. In: Kirklin/Barratt-Boyes cardiac surgery: morphology, diagnostic criteria, natural history, techniques, results, and indications. Churchill Livingstone, 3rd edition, 2003, pp: 946-1073.
- [5] Elzenga NJ, von Suylen RJ, Froh-Mulder I, Essed CE, Bos E, Quaegebeur JM. *Juxta-ductal pulmonary artery coarctation. An underestimated cause of branch pulmonary artery stenosis in patients with pulmonary atresia or stenosis and a ventricular septal defect*. J Thorac Cardiovasc Surg 1990; 100: 416-24.
- [6] Shimazaki Y, Blackstone EH, Kirklin JW, Jonas RA, Mandell V, Colvin EV. *The dimensions of the right ventricular outflow tract and pulmonary arteries in tetralogy of Fallot and pulmonary stenosis*. J Thorac Cardiovasc Surg 1992; 103: 692-705.
- [7] Fraser Jr C D, Latson L A, Mee R B B. *Surgical repair of severe bilateral branch pulmonary artery stenosis*. Ann Thorac Surg 1995;59:738-40.
- [8] Fellows KE, Smith J, Keane JF. *Preoperative angiocardiology in infants with tetrad of Fallot. Review of 36 cases*. Am J Cardiol 1981; 47: 1279-85.

- [9] Hoohenkerk GJ, Schoof PH, Bruggemans EF, Rijlaarsdam M, Hazekamp MG: 28 years' experience with transatrial-transpulmonary repair of atrioventricular septal defect with tetralogy of Fallot. *Ann Thorac Surg* 2008, 85(5):1686-1689.
- [10] Stewart RD, Backer CL, Young L, Mavroudis C: Tetralogy of Fallot: Results of a pulmonary valve-sparing strategy. *Ann Thorac Surg* 2005; 80:1431-1439.
- [11] Agnoletti G, Boudjemline Y, Bonnet D, Sidi D, Vouhé P. Surgical reconstruction of occluded pulmonary arteries in patients with congenital heart disease: effects on pulmonary artery growth. *Circulation* 2004;109:2314 - 2318.
- [12] Shinkawa T, Yamagishi M, Shuntoh K, Miyazaki T, Hisaoka T, Yaku H. Pulmonary arterial reconstruction for pulmonary coarctation in early infancy. *Ann Thorac Surg* 2007; 83:188-92.
- [13] Kaneko Y, Okabe H, Nagata N, Ohuchi H, Kobayashi J, Kanemoto S, Itoh K. Lay-open pulmonary arterioplasty for postoperative hilar pulmonary artery stenosis. *J Thorac Cardiovasc Surg* 1997;114:406-12.
- [14] Rowlatt UF, Rimoldi HJA, Lev M *The quantitative anatomy of the normal child's heart.* *Pediatr Clin North Am* 1963; 10: 499-588.
- [15] De la Cruz MV, Anselmi G, Romero A, Monroy GA *A qualitative and quantitative study of the ventricles and great vessels of normal children.* *Am Heart J* 1960; 60: 675-690.
- [16] Capps SB, Elkins RC, Fronk DM. *Body surface area as a predictor of aortic and pulmonary valve diameter.* *J Thorac Cardiovasc Surg.* 2000;119(5):975-82.
- [17] Jacob M F F B, De Marchi C H, Croti U A, Braile DM *Atrioventricular septal defect with tetralogy of Fallot in patient with Down's syndrome.* *Rev Bras Cir Cardiovasc* 2009; 24(3): 422-424
- [18] Croti UA, Braile D M, Moscardini A C, Kozak M F. *Enlargement of the right ventricular outflow tract using autologous pediculated pericardium in the tetralogy of fallot treatment.* *Rev Bras Cir Cardiovasc* 2008; 23(4): 583-585
- [19] Khoury W, Lang-Lazdunski L, Vernant F, Thibert M, Leca F. *Pedicled pericardium for repair of right ventricular outflow tract and pulmonary arterial stenoses in tetralogy of Fallot: a six-year experience.* *J Thorac Cardiovasc Surg* 1996;112:424-32.
- [20] Lukács L, Záborszky B, Sárközy K, Árvay A. *Reconstruction of the right ventricular outflow tract with bovine pericardial monocusp patch.* *Tex Heart Inst J* 1984; 11(3): 234-237.
- [21] Maluf M A. *Late outcome of right ventricular outflow tract repair using bicuspid pulmonary prosthesis in tetralogy of Fallot surgery repair: case report.* *Rev Bras Cir Cardiovasc* 2009; 24(4): 574-577
- [22] Mulinari L A, Navarro F B, Pimentel G K, Miyazaki S M, Binotto C N, Pelissari E C, Miyague N I, Da Costa F D A. *The use and midium-term evaluation of decellularized allog-*

raft cusp in the surgical treatment of the Tetralogy of Fallot. Rev Bras Cir Cardiovasc 2008; 23(2): 197-203

- [23] Faidutti B, Christenson J T, Beghetti M, Friedli B, Kalangos A. *How to diminish reoperation rates after initial repair of tetralogy of Fallot?* *Ann Thorac Surg* 2002;73:96 –101
- [24] Singh A, Krishnan G S, Agarwal R, Dave D, Kotturathu M. *Ascending Aortic Transection: Useful Adjunct in Pulmonary Artery Reconstruction. Asian Cardiovasc Thorac Ann* 2008;16:254–5
- [25] Oechslin EN, Harisson DA, Harris L, *et al.* *Reoperation in adults with repair of tetralogy of Fallot: indications and outcomes.* *J Thorac Cardiovasc Surg* 1999;118:245–51.
- [26] Burczynski PL, McKay R, Arnold R, Mitchell DR, Sabino GP. *Homograft replacement of the pulmonary artery bifurcation.* *J Thorac Cardiovasc Surg* 1989; 98:623-31.
- [27] Clarke DR, Campbell DN, Pappas G. *Pulmonary allograft conduit repair of tetralogy of Fallot. An alternative to transannular patch repair.* *J Thorac Cardiovasc Surg* 1989; 98:730-6; discussion 736-7.
- [28] Hopkins RA, Jones AL, Wolfinbarger L, Moore MA, Bert AA, Lofland GK. *Decellularization reduces calcification while improving both durability and 1-year functional results of pulmonary homograft valves in juvenile sheep.* *J Thorac Cardiovasc Surg.* 2009;137(4): 907-13.
- [29] Bechtel JF, Müller-Steinhardt M, Schmidtke C, Brunswik A, Stierle U, Sievers HH. *Evaluation of the decellularized pulmonary valve homograft (SynerGraft).* *J Heart Valve Dis.*2003;12(6):734-9.
- [30] Hawkins JA, Hillman ND, Lambert LM, Jones J, Di Russo GB, Profaizer T, *et al.* *Immunogenicity of decellularized cryopreserved allografts in pediatric cardiac surgery: comparison with standard cryopreserved allografts.* *J Thorac Cardiovasc Surg.* 2003;126(1):247-52.
- [31] da Costa FD, Dohmen PM, Duarte D, von Glenn C, Lopes SV, Haggi Filho H, *et al.* *Immunological and echocardiographic evaluation of decellularized versus cryopreserved allografts during the Ross operation.* *Eur J Cardiothorac Surg.* 2005;27(4):572-8.
- [32] Costa F, Fornazari DF, Matsuda CN, Torres RA, Sardetto E, Ferreira ADA, *et al.* *Ten years experience of aortic valve replacement with aortic homograft root replacement.* *Rev Bras Cir Cardiovasc.* 2006;21(2):155-64.

