

We are IntechOpen, the world's leading publisher of Open Access books Built by scientists, for scientists

6,900

Open access books available

186,000

International authors and editors

200M

Downloads

Our authors are among the

154

Countries delivered to

TOP 1%

most cited scientists

12.2%

Contributors from top 500 universities



WEB OF SCIENCE™

Selection of our books indexed in the Book Citation Index
in Web of Science™ Core Collection (BKCI)

Interested in publishing with us?
Contact book.department@intechopen.com

Numbers displayed above are based on latest data collected.
For more information visit www.intechopen.com



Serdev Sutures® in Middle Face

Nikolay Serdev

Additional information is available at the end of the chapter

<http://dx.doi.org/10.5772/55674>

1. Introduction

Scarless, closed approach Serdev Suture® liftings, suspensions and tissue volumising in middle face present skeletal fixation with skin punctures, without incisions. They are a first and in many cases -superior alternative to classic excision lifts, implants etc. Author's contribution is that his closed approach suture techniques can be used in areas, where access is difficult or impossible for other surgeries; they lift SMAS and fascias without traditional incisions; cheekbone augmentation and lifting is possible without implants and transplants. Operations are ambulatory, with excellent results, as reported by the patients. Trauma is minimal and the follow-up period is not longer than a few hours to 3 days with fast, sometimes immediate return to work and social life. There are no visible scars, only needle perforations on the skin, which disappear within 2-3 days. The techniques consist of passing closed sutures, by needle perforations only, to lift movable fascias and fix them to non-movable skeletal structures in several mid-facial areas.

2. Cheekbone lift

2.1. Introduction

Scarless, closed approach Serdev Suture® techniques for augmentation and lifting of cheekbones were introduced by the author in 1994. They use the **mobile cheek SMAS flap** or **fascial tube of the buccal fat pad** (also called Bichat's fat pad) to elevate and attach it to the **immobile, stable zygoma periosteum**, and in selected rare cases - to the **orbital rim periosteum**, or **temporoparietal tendon insertion and underlying periosteum**, or the **upper temporal line periosteum and temporal fascia**. The idea is to lift the SMAS and fat pad via its fascial tube at the level of the zygomatic bone; restore cheekbone fullness; volumize and elevate the cheekbone; eliminate the tear trough fold; improve facial expression; and achieve a youthful elongation of the so-called "beauty triangle". To achieve the cheekbone lift, the author uses special semi-blunt and semi-elastic curved needles with lengths of 50 mm, 60

mm, 100 mm, and 140 mm with an eye at the tip, and prefers semi-elastic Bulgarian polycapromide (Polycon) USP 2 sutures with prolonged resorption (2-3 years). The Serdev Suture® lifting techniques are ambulatory, performed under local anesthesia, very well tolerated by patients, produce immediate results, with an extremely short post operative period, fast recovery and nearly immediate return to social life. Complications are under 0,1% and patient satisfaction is high, especially in the aesthetic aspects of rejuvenation and beautification.

There were no known specific surgical methods for simultaneous direct cheekbone lifting, enhancement and volumising without the use of implants or transplants before 1994. The superficial muscle-aponeurotic system, or SMAS, was described by Mitz and Peyronie in 1976 and the SMAS facelift became the gold standard. Earlier procedures developed into a large rotation-advancement skin flap for indirect lifting of this area. Classic rhytidectomy progressed into sub-fascial, tri-plane, deep-plane, composite, subperiosteal, multiplane, “en-bloc” and other extended surgical methods, with a progressively increasing rate of complications and downtime. Nowadays, minor operations with reduced risks and faster recovery time have become more common, but the SMAS lifts without undermining remain the best long-term suspension, affecting the overlying skin. Later techniques, such as barbed “thread lifts”, are placed subdermally and naturally cannot include the SMAS in the lift. They are free floating, not sutured, nor stabilized by attachment to immobile anatomical structures. Therefore, in the author’s opinion, they are different from suture lifts and cannot guarantee a safe prolonged outcome.

2.2. Procedure

Anesthesia

Only local anaesthesia, or in combination with i.v. sedation, is used. It is preferable to general anaesthesia, due to the benefits of decreased intervention time and for preferences expressed by the surgeon and patient.

Anatomical guidelines

A “**Fascial tube**” was found by the author to envelop the Bichat’s fat pad at the nasolabial fold. He captures this mobile fascial tube and uses it to lift the included fat pad to the zygoma periosteum, for a cheekbone lift.

A “**Danger area**” is described by the author, where the frontal branch of the facial nerve is believed to cross the zygomatic bone, traveling along a line that connects the tragus base to a point 1.5 cm above the eyebrow. The topographical anatomy forms a square – 3 cm anterior to the tragus and 3 cm above the zygomatic bone (danger area). **NB!** Needle perforation and attachment to the zygoma in a cheekbone lift should not be performed in this area! Do not perforate the zygoma periosteum in the first 3 cm anterior to the tragus! When performing a cheekbone lift in this zone, the needle must be in a superficial, subgaleal mobile plane. If the needle gets blocked in the “danger area”, it means that it has perforated the deeper non-mobile lamina superficialis of the temporal fascia, which is a potentially dangerous situation (see the

anatomical description in “Temporal face lift”), because of possible vessel perforation. In such case, prolonged direct pressure is described to stop bleeding in this area.

The temporoparietal tendon is attached to and above the spina suprameatica of the meatus acusticus externus. Its insertions, together with the underlying periosteum are stable, immobile and in rare cases are used by the author for mid-face lift. **NB!** Temporalis fascia and tendon fibers are directed downwards and aren't suitable for attachment in middle face lift, nor for a temporal lift (Fig. 1).

The SMAS has a fascial extension, attached to the zygoma (called zygomatic SMAS exptension), which can move up and down, permitting facial movement and flaccidity. The author captures and stretches this mobile extension in a temporoparietal direction, thus lifting the mid and lower face SMAS.

The cheekbone lift, using a transcutaneous closed suture approach, without excision of skin, was created initially (1990-1993) due to an increasing demand by young (as well as elderly) patients, who declined classic scarring lifts, associated with a month-lasting recovery, and also by people who could not afford to skip their work for a long time. Exploring topographic anatomy, designing new instruments and semi-elastic sutures allowed the author to lift loose SMAS and fat pads, using patients' own fascial structures, and attach them to stable, immobile anatomical structures, zygomatic periosteum and in rare cases – to temporoparietal tendon insertion and underlying periosteum, or upper temporal line periosteum with temporal fascia. To achieve the objective of scarless lifting, the author uses needle perforations only. In order to attach the different subdermal fascial layers, he has created special curved, semi-blunt and semi-elastic needles with different lengths. For the cheekbone lift, 50 mm, 60 mm, 100 mm or 140 mm Serdev® needles are used. They can

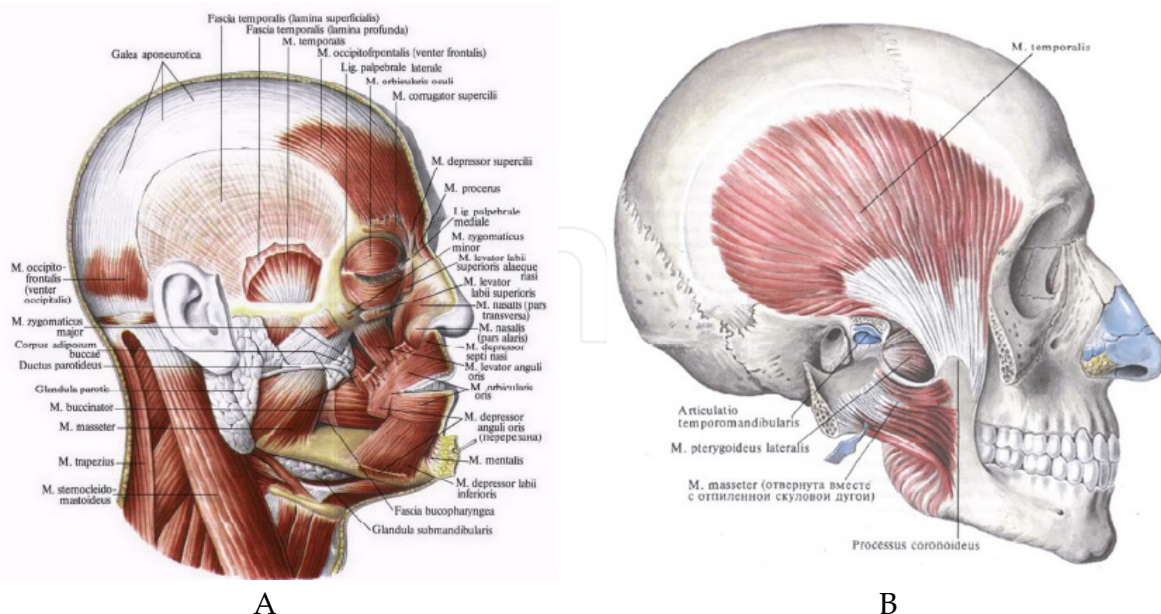


Figure 1. A, B. Temporal tendon and fascia are not suitable for mid-face fixation and lifting, because of their direction. Sutures slide down due to distal fibers direction. *Anatomy figures from Sinelnikov - Atlas Of Human Anatomy, GIML, Moscow, 1963

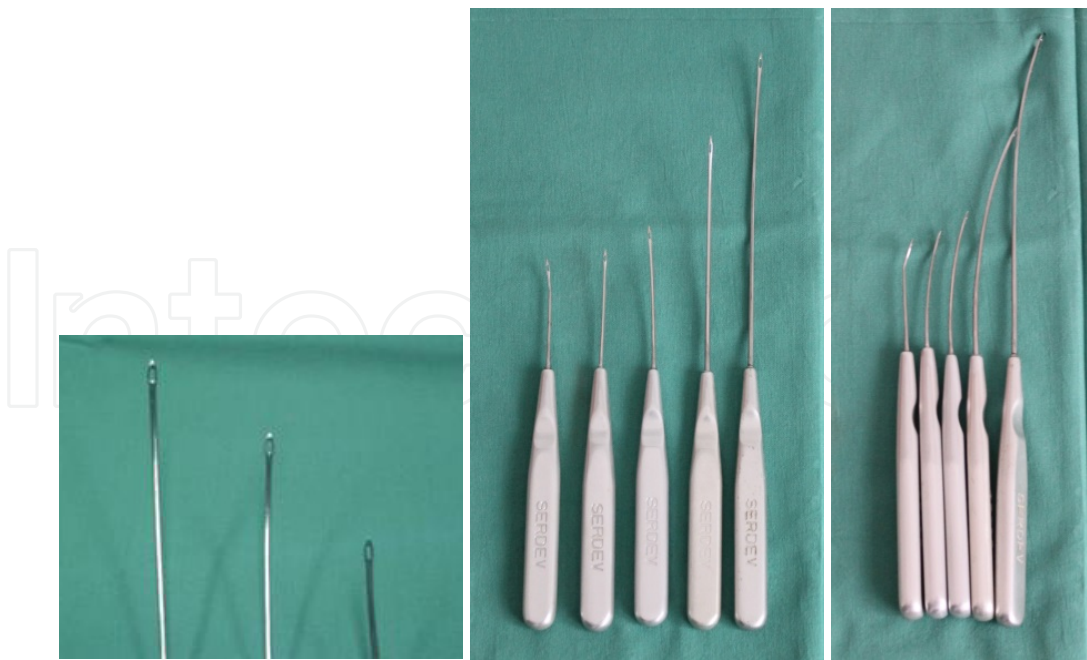


Figure 2. Curved, semi-blunt and semi-elastic needles, with lengths of 50 mm, 60 mm, 100 mm and 140 mm and hollow tip.

introduce long-term absorbable (in 2-3 years), semi-elastic Polycon USP 2 surgical sutures, for suturing the fat pad fascial tube and attaching it to the stable zygomatic periosteum. Suture selection is the surgeon’s responsibility; nevertheless, a proper diameter semi-elastic surgical suture is recommended to obtain long-term results. Sutures with a diameter of 3/0 and 2/0 are too thin for the middle and lower face heaviness and act like a scalpel (cutting through the tissues) and fail to securely immobilize facial tissue. They are not acceptable or appropriate for satisfactory and stable results.



Figure 3. Long-term absorbable (in 2-3 years), semi-elastic, braided, antimicrobial Bulgarian polycaproatamide (Polycon) USP 2 surgical sutures for suture cheekbone lift.

Surgical methods

For any of the cheekbone lifts described below, the author uses 2 or 3 skin perforations to introduce the needle and place the suture at the desired anatomical level.

Most important attachments:

- **immobile attachment:** to the zygomatic periosteum; or the temporoparietal tendon insertion and the periosteum underneath; orbital rim periosteum; upper temporal line periosteum and temporal fascia.
- **attachment of mobile** Bichat's fat pad fascial tube, cheek SMAS and zygomatic SMAS extension to be lifted to an immobile attachment. The author has found a fascial tube to envelop the Bichat's fat pad.

Skin perforation point A:

The skin perforation point A can be positioned differently in young and in elderly patients, in order to obtain a secure attachment of the suture to the zygoma periosteum or the temporoparietal tendon insertion and periosteum below, or the upper temporal line and temporal fascia, or the border of the orbit.

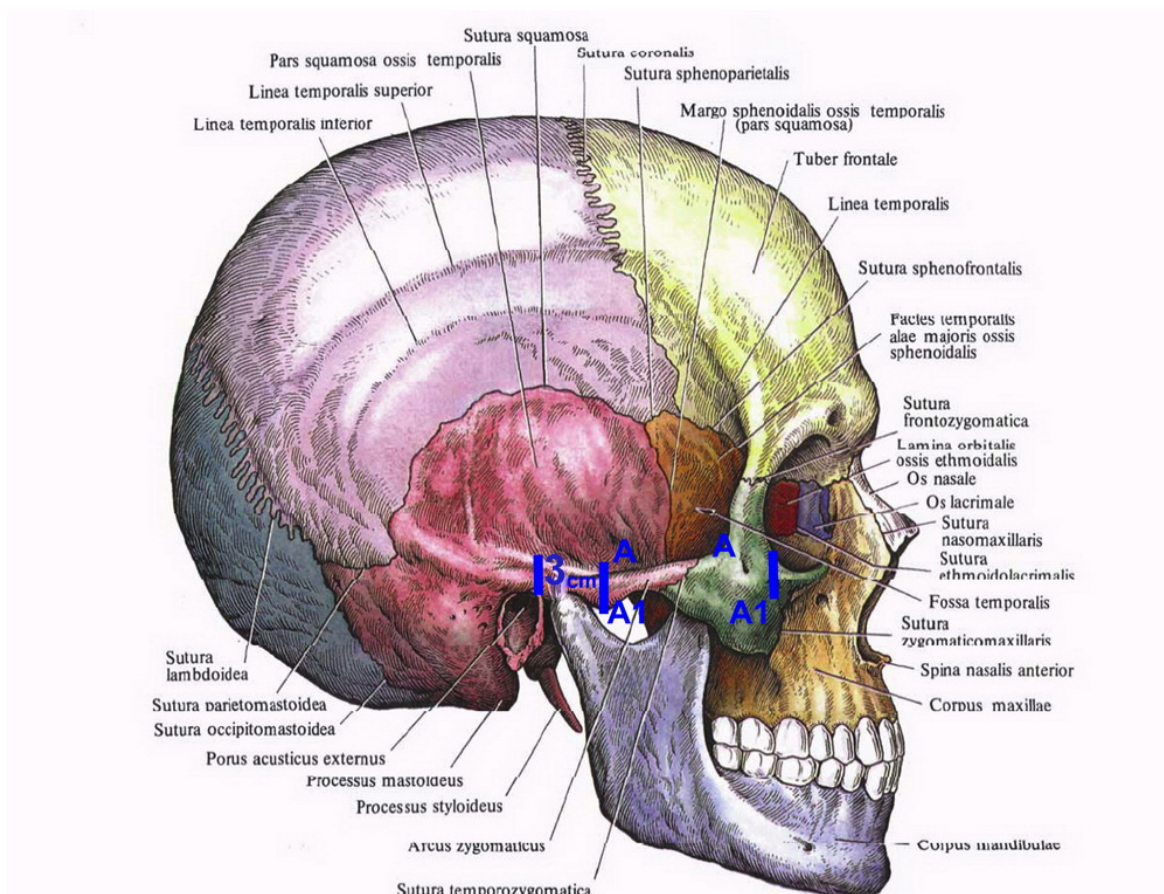


Figure 4. The main suture fixation is to zygoma periosteum. There is a limitation for perforation of the zygoma periosteum in the “danger area” – the first 3 cm in front of the tragus. **Anatomy figures from Sinelnikov - Atlas Of Human Anatomy, GIML, Moscow, 1963.**

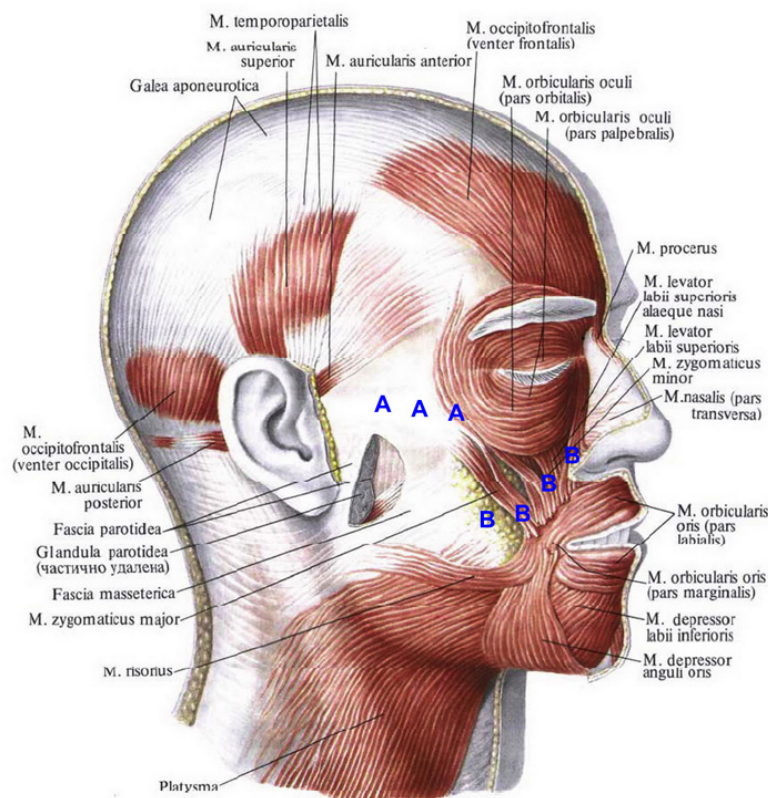


Figure 5. Skin Perforation Point A can be located along the length of the zygoma, except in the danger area - the first 3 cm in front of the tragus. Perforation point B is located about 3 mm laterally to the nasolabial fold. This allows the nasolabial fold to be stretched and flattened. Point B could be planned at any point along the length of the nasolabial fold, from the nasolabial angle up to the oral commissure and smiling point. The smiling dimple location is at the intersection of the following lines: 1. The line, connecting the oral commissure and the tragus; 2. The lateral canthus line. *Anatomy figures from Sinelnikov - Atlas Of Human Anatomy, GIML, Moscow, 1963

1. At the zygoma

Point A can be located along the length of the zygoma, except in the danger area, which is the first 3 cm anterior to the tragus and should not be used to attach the sutures.

- **In young and middle aged patients: At the intersection of the lateral canthus line with the upper zygoma line.** This is the preferred point to catch the zygoma periosteum. Young people do not have a large quantity of tissue to enhance the cheekbones, but many of them have a marked tear trough fold. Higher cheekbones are always nice, giving a young and attractive appearance.
- **In elderly the aim is to gather more tissue inside the suture, flatten the tear trough fold and lift marionette and jaw lines. Perforation point A can be at a lower, anterior angle of the sideburn hairline.** This point has to be 1 cm anterior to the presumed path of the frontal branch of the facial nerve, i.e. minimum 3 cm anterior to the tragus.

2. Other rare anatomical immobile fixations (point A)

- **at the temporo-auricular angle - in bald patients,** to catch the temporoparietal tendon insertion and the periosteum underneath.

- **at the upper temporal line - in selected cases, mostly in open surgery.**
- **at the orbital rim - in selected cases, mostly in open surgery.**

Skin perforation point B. Attachment of Bichat's fat pad fascial tube and/or the cheek SMAS:

Point B is located about 3 mm lateral to the nasolabial fold. This allows the nasolabial fold to be stretched and flattened. It can be placed at any point along the length of the nasolabial fold – from the nasolabial angle to the oral commissure and smiling point. The smiling point is located at the intersection of lines: 1. connecting the oral commissure and the tragus and 2. the lateral canthus line.

- **at the nasolabial angle** - in young patients: 2 variations:
 - **Skin perforation** at 3 mm laterally from the nasolabial fold, or
 - **Transmucosal in the nostril** (Fig. 7). **NB!** To protect the suture and needle from the nostril mucosa, the author uses plastic cannulas with openings at both ends. They are easily made from needle caps, by cutting the closed end.
- **at the mid point of the nasolabial fold** - in middle aged or elderly patients: 3mm laterally from the nasolabial fold
- **at the lower point of the nasolabial fold** - in elderly patients with a pronounced nasolabial fold, 3mm laterally from the nasolabial fold in 2 variations:
 - **Skin perforation** at 3 mm laterally from the nasolabial fold, or
 - **Transmucosal in the oral cavity.** **NB!** To protect the suture and needle from the oral mucosa, use plastic cannulas with 2 open ends.
- **at the smiling point – in elderly patients**, for cephalic traction of “hanging” jowls and fat pads in elderly patients to gather more soft tissue and correct marionette and jaw lines. **NB!** In all variations, the Bichat's fat pad fascial tube has to be captured along its entire length using one or two skin perforation points. If two skin perforation points at B are used, their location should be: 1. at the nasolabial angle and 2. at the level of the oral commissure, 3 mm lateral to the nasolabial folds or at the smiling point.

The traction vector is in a cephalic or temporoparietal direction.

2.3. Medial cheekbone projection. Mostly using 2 perforation points

1. **Fixation at anterior zygoma.** Perforation Point A at the lateral canthus line, 1 cm lower than lateral canthus, Point B at nasolabial angle in 2 variants: Perforation point B through skin or through nasal mucosa

Option 1. Lifting of buccal fat pad fascial tube

Video: <http://www.youtube.com/watch?v=jbi3hHxUdcw>

First pass: After local infiltration, the skin perforation points are punctured using a No. 11 scalpel blade and widened with the tip of mosquito clamp. **NB!** The superficial fascia should be perforated as well, otherwise the suture will involve it in traction, forming dimples.

Using skin perforations:

A semi-blunt, curved 50 mm or 60 mm Serdev® needle is introduced at point A at the lateral canthus line, 1 cm below the lateral canthus on the cheekbone prominence; the pass is first made subperiosteally, engaging the anterior zygoma periosteum. **NB!** At that stage, check whether the needle is locked under the periosteum. If positioned subperiosteally, the needle can lift the entire head, due to the strength of the zygoma periosteum. If the needle moves freely, it means the needle is not inserted at the sub-periosteal level. This is a common beginner's error and the needle should be repositioned deeper, under the periosteum. Then, the needle passes deep in the soft tissue flap, following the lower cheek line. When it arrives at the distal end of the nasolabial fold, distal to perforation point B, it should perforate the fascial tube of buccal Bichat's fat pad. After changing direction (while still inside the fat pad fascial tube), the needle tip arrives under point B. Turn the tip upward towards the opening B, then fold the skin against the needle tip at a 90° angle and move the needle upwards with a gentle twisting movement until it exits from point B. The specially designed needle surface prevents cutting the periosteum in line A-A1 and allows all subsequent movements. **NB!** Avoid catching the dermis as you enter or exit through the skin perforation points, in order to prevent skin dimpling. If you feel that the needle is encountering resistance, it means that the needle has caught the dermis. Twist the needle, while withdrawing it, and repeat the maneuver. Do not push or pull – twist the needle gently forwards or backwards.

The suture is then introduced in the needle eye and the first suture end is pulled out through line A-B (Fig.6).

Transmucosal perforation point B: Perforation point B could be done inside the lateral nostril. The surgical suture and needle should be protected from nostril mucosa (using a cannula), in order to prevent contamination. The author uses needle caps with a cut dead end (Fig. 7).

Second pass: It is performed above the zygoma, mid-deep in the soft tissue (do not touch zygoma periosteum): The needle is introduced through point A. It passes medium deep in the soft tissue flap, just above the upper zygoma line. **NB!** This pass is made in mobile tissue. Avoid making this pass too deep – the needle can become blocked in the supraperiosteal fibrotic tissue. After perforation of the fat pad fascial tube at its upper part, the needle direction is changed (while still inside the fat pad fascial tube) and exits at point B (in skin perforation or trans-mucosal). The second suture end is introduced in the needle eye and pulled out through the second needle pass A-B. The suture circle is now completed, attaching the buccal fat pad fascia to the zygoma periosteum, and a knot is tied under medium tension. **NB!** Making the knot too tight can damage the involved tissue. Dimpling is released by pulling the suture ends upwards and the skin in perforation point B downwards, using the tip of a mosquito clamp.

Medial cheekbone lift in cephalic direction solves emptiness below the eyes in Asians, hollow eyes, tear through fold, gives volume, projects and lifts cheekbone medially (important in Asians). Soft tissue amount inside the suture provides cheekbone volume and prominence.

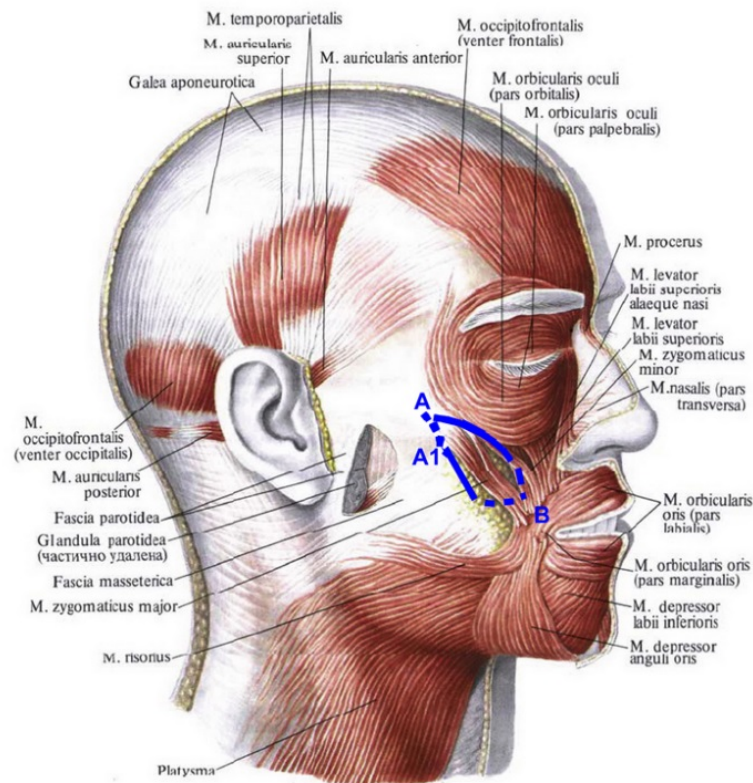


Figure 6. Traction on Bichat's fat pad fascial tube. In young, middle aged patients and Asians, to obtain medial cheekbone projection. The dotted A-A1 pass is subperiosteal. Point A1 is only a mark, not a perforation. Dotted line B marks the pass inside the fascial tube of Bichat's fat pad. *Anatomy figures from Sinelnikov - Atlas Of Human Anatomy, GIML, Moscow, 1963

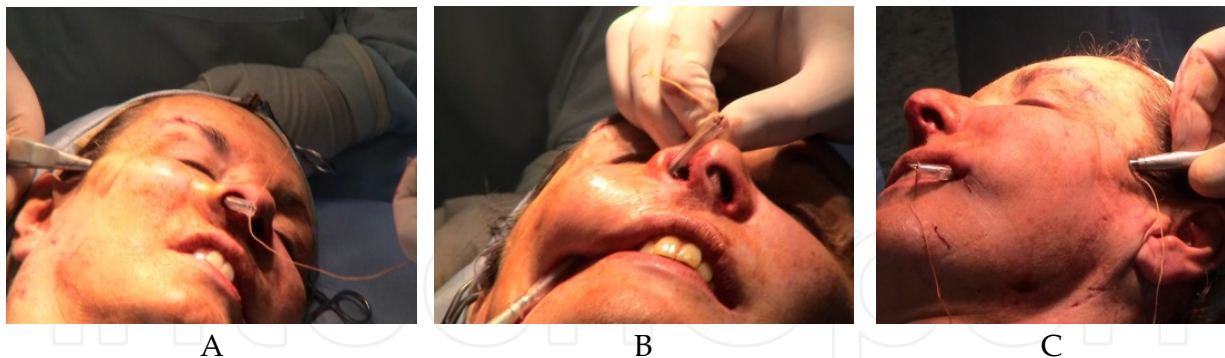

Figure 7. Transmucosal cheekbone lift. Protection of needle and suture contamination using plastic cannula from a needle cap.

Option 2: Lifting of muscle-cheek SMAS flap (Fig 8):

First (deep) pass A-B

After local anesthesia, skin perforations are made, using a No. 11 scalpel blade. A 60 mm Serdev® needle is introduced through point A, biting into the anterior zygoma periosteum, then continuing directly to point B, deep into the cheek SMAS. The needle passes through

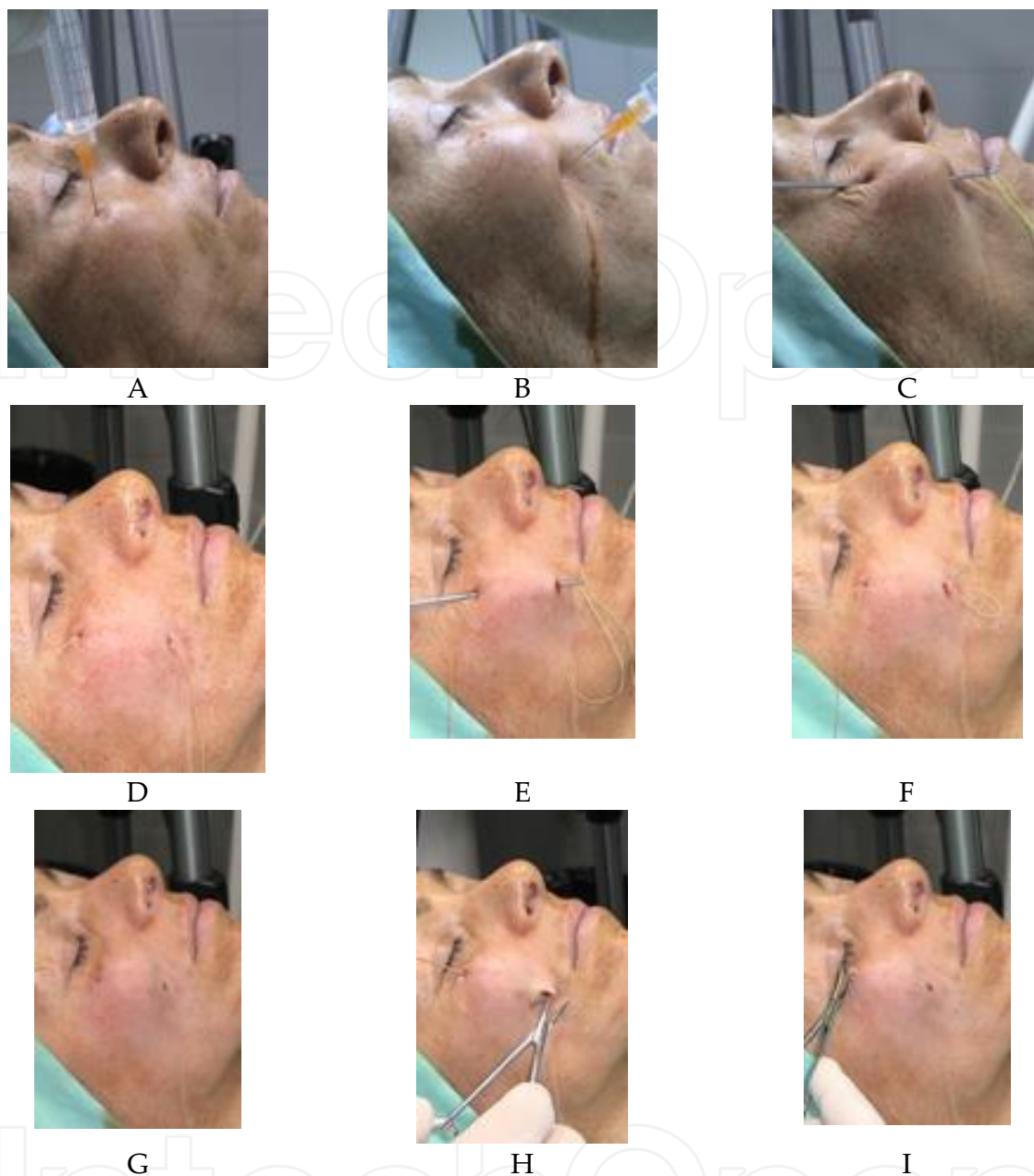


Figure 8. Lifting of muscle-cheek SMAS flap using 2 perforation points. Steps: A., B. intradermal infiltration at skin perforation points A and B; subdermal infiltration in deep and middle deep lines A-B; skin perforations made with a No. 11 blade; widening of the perforations using the tip of a mosquito clamp; C. Serdev® needle is introduced through 1. perforation point A, 2. anterior zygoma periosteum, 3. deeper cheek SMAS flap, 4. the buccal fat pad fascial tube; exits through point B. The needle is threaded; D. Semi-elastic Polycon suture is introduced through the first needle pass A-B; E. Second needle pass A-B is more superficial, but deep enough not to form dimpling on the skin surface, the needle is treaded at point B; F. The second end of the suture is introduced in the second, more superficial needle pass A-B; G. The suture circle is completed and knotted. The lifting and volumising of the cheekbone is immediately visible; H. Any skin dimpling is removed using the tip of a mosquito clamp instrument. Suture and skin perforation are pulled in opposed directions; I. Any dimpling in perforation point A should also be removed using a mosquito clamp.

the buccal fat pad fascial tube, point B, and is treaded. Then, it is introduced through the first (deep) needle pass A-B.

Second (more superficial) pass A-B

The second needle pass A-B is more superficial (again directed from A to B). **NB!** Avoid a too superficial pass. If dimples appear on the skin surface above the needle position, it means that it is located too superficially and should be introduced deeper.

In point B, the needle is threaded and the second suture end is introduced in the more superficial needle pass A-B. The suture circle is completed. Both suture ends at point A and the skin perforation B are pulled in opposite directions to remove any skin dimpling. Remove any dimpling at perforation point A as well.

In both options the zygomatic SMAS extension is also included in the lift.

Medial cheekbone lifting in cephalic direction resolves the flat emptiness below the eyes in Asians, hollow eyes, tear trough folds; adds volume, projects and lifts the cheekbone medially. The amount of soft tissue inside the suture provides cheekbone volume and prominence, without implants and transplants. In Asians the procedures for medial cheekbone lift can remarkably reduce lateral bulging of the zygoma, soften the facial oval and give a Caucasian type appearance.

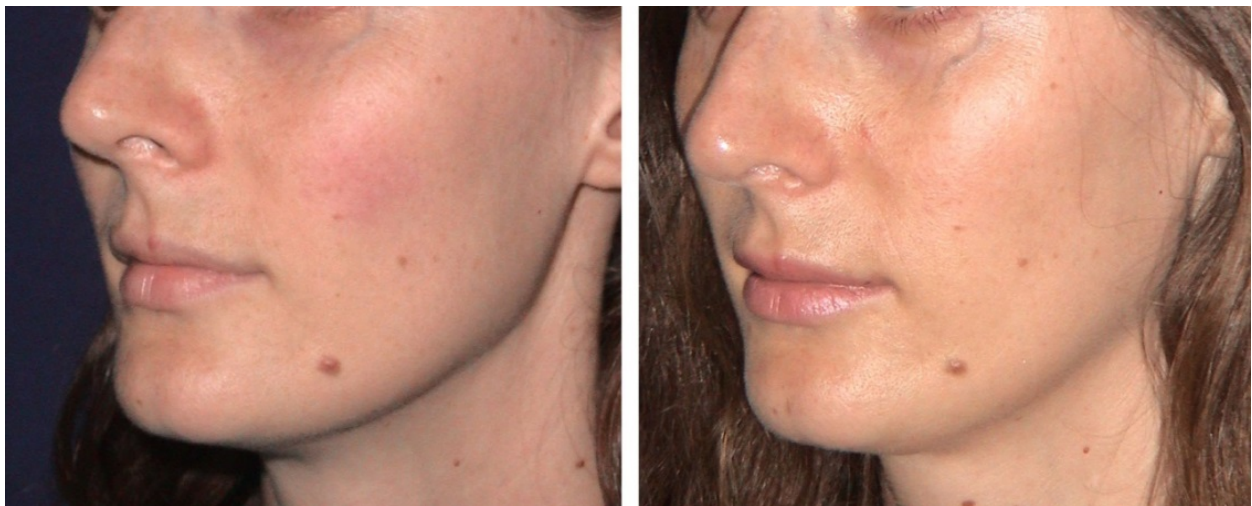

Figure 9. Medial cheekbone lift to fulfill the emptiness below the eyes. Better definition of the beauty triangle.

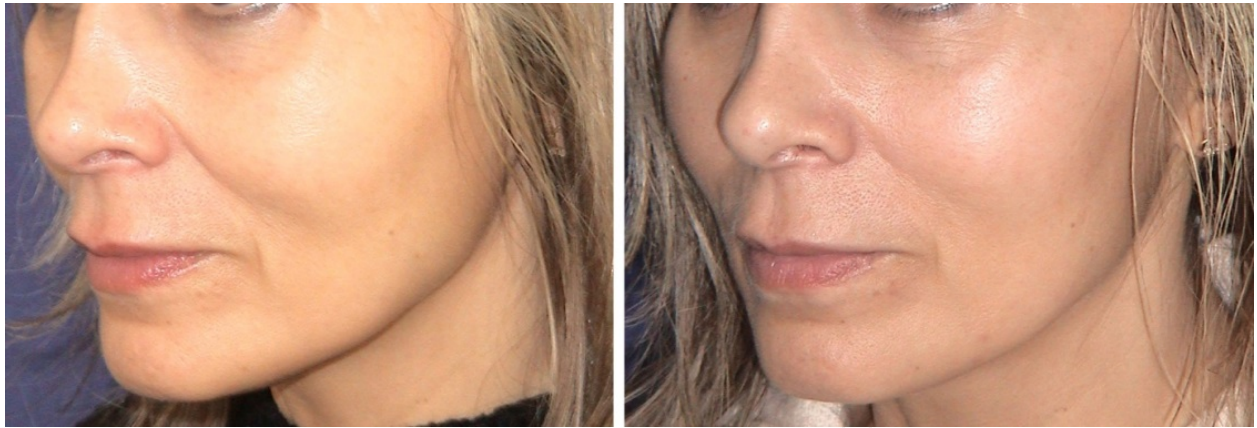

Figure 10. Medial cheekbone lift. Higher cheekbones and better definition of the beauty triangle

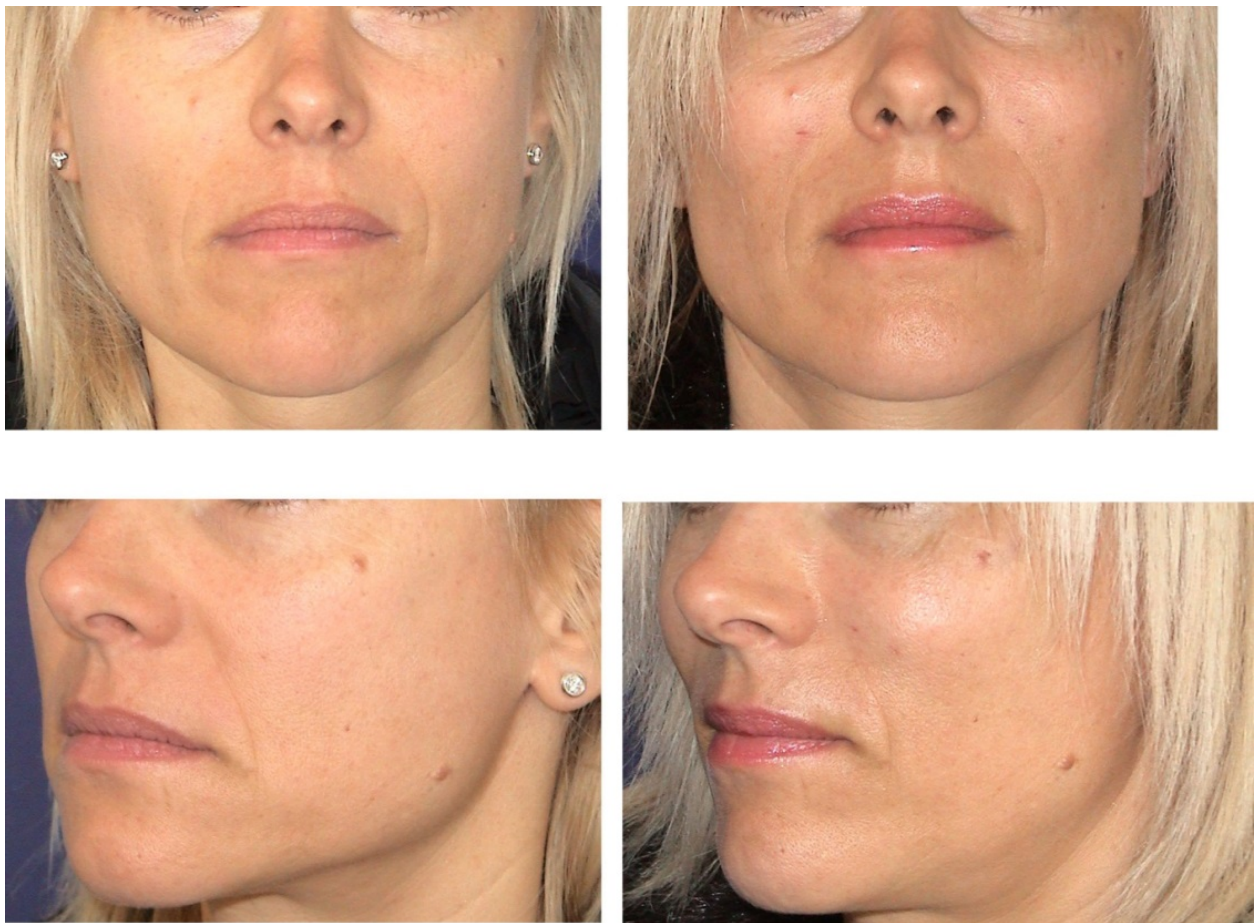

Figure 11. Before and after simultaneous cheekbone SMAS lift and chin enhancement by suture to obtain the “beauty triangle”. Lifting of muscle-cheek SMAS flap, using 2 perforation points in a 49 y.o. patient.




Figure 12. Cheekbone augmentation and lifting. **A.** Before; **B.** After cheekbone lift and simultaneous brow lift by suture.

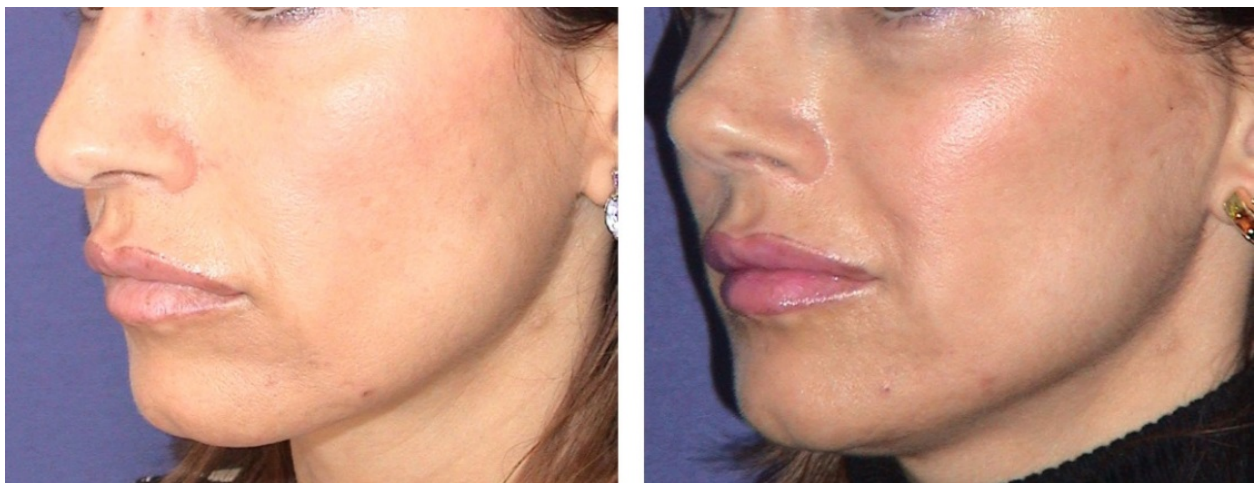

Figure 13. Medial cheekbone lift in a 45 y.o. patient to fulfill the tear trough fold, lift and volumize the cheekbones. Better definition of the beauty triangle. Simultaneous nasal tip rotation by suture aligns the tip at the line of the cheekbones (part of beauty triangle).

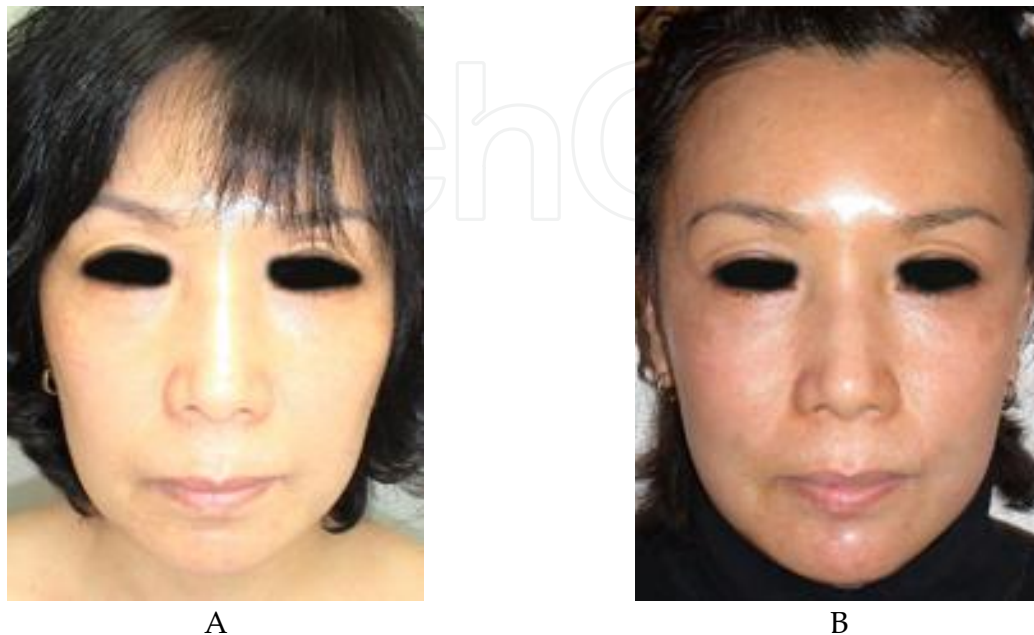

Figure 14. Medial cheekbone lift in an Asian patient, **A.** Before, **B.** After. Medial cheekbone enhancement and simultaneous chin down lift (moving the chin down) for proportion correction by suture change Asian face into a Caucasian oval appearance.

2. Another possibility for medial cheekbone lifting is the **fixation at orbital rim periosteum**. Skin perforation point A at desired orbital rim position, Point B at any point of the nasolabial fold, 3 mm lateral from it, or at smiling point:

The technique is the same as the one described above, in 2 variants: lifting of muscle-cheek SMAS flap or facial tube of buccal fat pad. In both variations, the zygomatic SMAS extension is also included in the lift. The older and more flabby the patient, the lower the point B. It is advisable to include Bichat's fat pad fascial tube in the suture in both variants. This is a very rarely used modification, only in cases where higher fixation is needed, usually in cases with smaller lower face proportion and mostly in open surgery, combined with blepharoplasty. For cases of facial disproportions in the lower face and especially in microgenia and retrogenia, the author has in his hands the suture method to elongate and enhance the chin (see Fig. 14 and Serdev Sutures® in Lower Face) that is a better technique to adapt proportions.

2.4. Lateral cheekbone projection

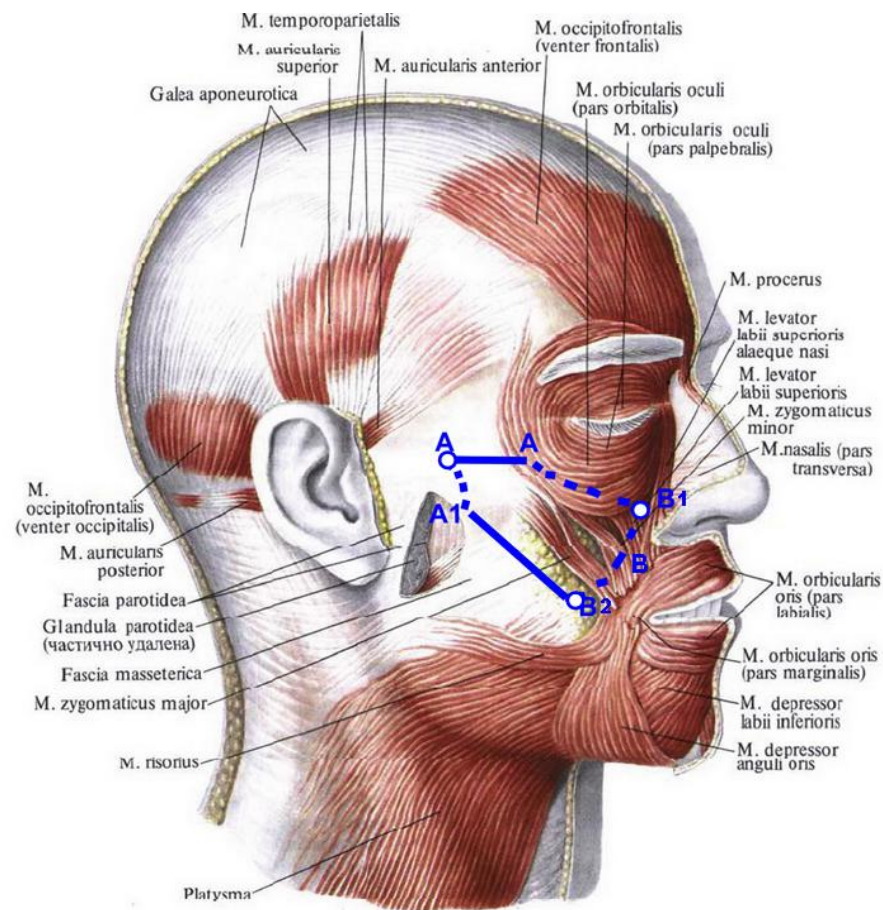


Figure 15. Skin perforation point A is located at lower, anterior sideburn hairline angle. Using 1 or 2 perforation points B. A) In elderly patients two B points are used to collect more soft tissue and to obtain the lateral cheekbone projection. Pass A-A1 is subperiosteal. A1 is only a mark, not a skin perforation point. All the B perforation points are 3mm lateral to the nasolabial fold. The dotted A-B1 line is located in deep soft tissue, below the lower lid. The dotted B1-B2 line is located inside the fascial tube of Bichat's fat pad. B) If only one perforation point B is used, points B1 and B2 are only marks (not perforated). *Anatomy figures from Sinelnikov - Atlas Of Human Anatomy, GIML, Moscow, 1963

1. Fixation to posterior zygoma periosteum. Using 2 perforation points. Skin perforation point A at lower anterior sideburn hair line angle, point B at any point at nasolabial fold, 3 mm lateral from it or at smiling point (Fig.15).

The older and more flacid the patient, the lower point B should be located. Bichat's fat pad fascial tube should be included in the suture. At the lower part of the nasolabial fold, perforation point B can be made through the skin or the oral mucosa. This suture presents: Combined traction on SMAS zygomatic extension and fat pad fascias; Collection of all the cheekbone soft tissue.

First Pass A-(A1)-(B2)-B – deep in the tissue flap (see Fig.15)

Variation 1 - Perforation point B through the skin: a 140 mm Serdev® needle is introduced in point A, at the lower anterior sideburn hairline angle; at the start the pass is subperiosteal, biting anterior zygoma periosteum (line A-A1). Point A1 is only a mark, not a perforation point. **NB!** At that point check whether the needle is locked under the periosteum. If it moves freely, it is not inserted at the subperiosteal level and should be repositioned deeper, under the periosteum. After that, the needle passes deep in the soft tissue, following the lower cheek line. When the fascial tube of Bichat's fat pad is reached, it should be perforated at the distal part (marked, but no skin perforation at point B2). Subsequently, the direction of the needle is changed toward point B (while still inside the fat pad fascial tube). Fold the skin against the needle tip at a 90° angle and with a gentle twisting motion move the needle upward until it exits from point B. **NB!** Try to avoid engaging the dermis as you enter or exit through the perforation points, in order to prevent creation of skin dimpling. If you feel the needle facing any resistance it means that the needle has caught the dermis. In such case, pull the needle backwards by twisting it, and repeat the maneuver. Do not push or pull – twist the needle gently forwards or backwards. The needle is threaded and the first suture end is pulled out through the A-B needle pass.

Variation 2 - Transmucosal perforation point B: At the lower nasolabial fold, point B is made through the oral mucosa. The needle and suture should be protected from the mucosa with a cannula (cut needle cap), to prevent contamination.

Second pass A-(A)-(B1)-B

The needle is introduced through point A, without catching periosteum, and continues in a medium deep level above the zygoma to the lateral canthus line (line A-A). If a dimple appears on the skin surface above the needle position, it means that the needle is located too superficially and should be repositioned deeper. At the lateral canthus line, the needle changes direction below the lower lid and perforates the fascial tube of Bichat's fat pad at its upper point B1 (B1 is only a mark). Then, the needle direction is changed (while still inside the fat pad fascial tube) and exits at perforation point B (through the skin or transmucosal). The second suture end is threaded and pulled out through the needle pass A-B (A-(A)-(B1)-B). This completes the suture circle, attaching the buccal fat pad fascia to the zygomatic periosteum. A knot is tied under medium tension (suturing too tightly damages the tissue). The vector is in a temporoparietal direction. The zygomatic SMAS extension is engaged in the suture. This corrects the tear trough fold, gives optimum volume while projecting and lifting the lateral cheekbone. The soft tissue inside the suture gives cheekbone volume and prominence, without using implants or transplants. Dimpling at perforation point B is released by pulling the skin at this point with a mosquito clamp and the suture ends at A in opposite directions. Eventual dimpling at point A should be removed as well.

2. Fixation at posterior zygoma. Using 3 perforation points. Perforation Point A is at sideburn lower anterior hairline angle. Point B1 at nasolabial angle, Point B2 at lower nasolabial fold or at smiling point. Perforation point B2 could be through skin or oral mucosa. **TYPE: Combined traction on SMAS zygomatic extension and fat pad fascias.** Collection of whole cheekbone soft tissue in elderly or in cases of overly regressed cheekbone soft tissue (Fig 15).

The surgical technique is the same as the one described above.

The author uses skin or mucosal perforation point B1, and skin or mucosal perforation point B2.

The pass between the B1 and B2 must be located in the fat pad fascial tube (Fig. 16). Otherwise, traction will occur on unstable fat and soft tissue.

Using trans-mucosal perforation points: When perforation points B1 and B2 are trans-mucosal (intra-nasal at nasolabial angle or in oral mucosa at lower nasolabial fold area and smiling point), needle and suture should be protected using a cannula (Fig. 7). All collected soft tissue included in the suture is tractioned in temporoparietal direction. Skin and tissue impressions at perforation points should be managed using a mosquito clamp.

Cheeks will be augmented laterally, which is recommendable mostly in Caucasians. Vice versa, Asians have laterally projected cheekbones but their faces are more flat medially and hollow below their eyes. In Asians, the author recommends medial cheekbone enhancement.

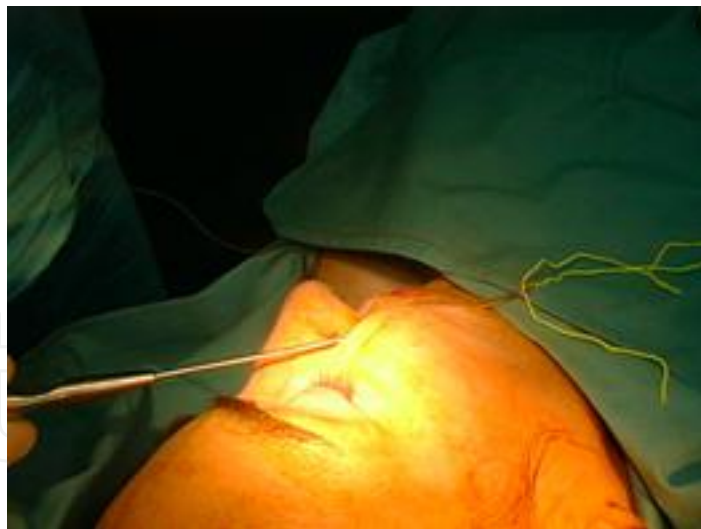

Figure 16. Pass between perforation point B1 and B2 is located inside of fat pad fascial tube.

3. Fixation at temporoparietal tendon and underlying periosteum. Perforation Point A at temporoauricular angle to fix the suture to immobile temporoparietal tendon insertion and periosteum below it. Point B1 at nasolabial angle, Point B2 at lower nasolabial fold or at smiling point. Perforation points B1 and B2 could be through skin or mucosa. **TYPE: Combined traction on SMAS zygomatic extension and fat pad fascias.** Collection of whole cheek-bone soft tissue in elderly or in cases of overly regressed cheek-bone soft tissue. Used

mostly in bald male patients to prevent from scaring in the lateral cheekbone area. It is a very rarely used modification.

4. Fixation to upper temporal line and temporal fascia. 2 or 3 perforation points in selected cases. Perforation Point A at upper temporal line just above intersection point between: 1. Upper temporal line and 2. Coronal line. **Perforation point A1 may exist about 1-2cm lateral and lower than lateral canthus to facilitate the long pass.** Skilled surgeons may surpass this perforation point. TYPE: Combined traction on cheekbone lateral canthus and temporal region. It is a very rarely used modification in closed technique. The author has used it in open techniques of face and mid-face lift. We train plastic surgeons using open techniques to use it to prevent wide dissections.

Clinical cases

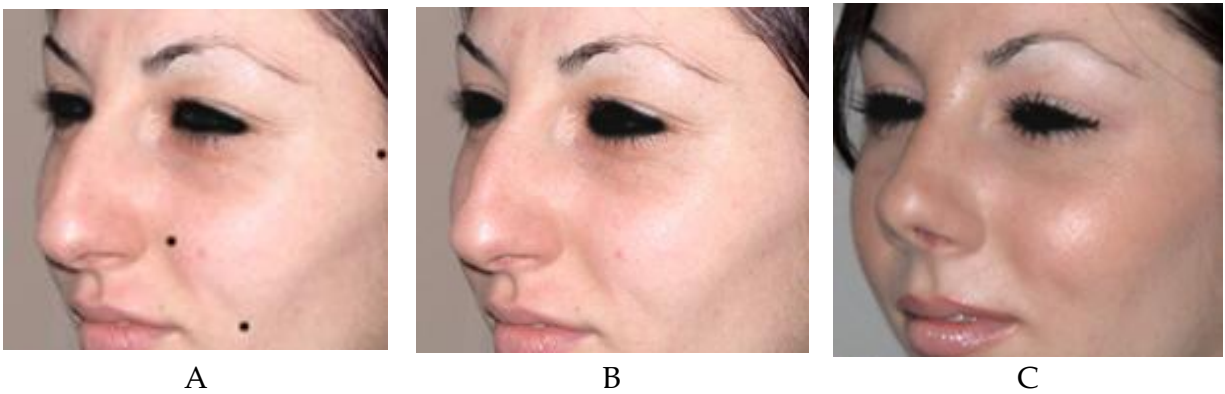

Figure 17. Lateral cheekbone lift. Fixation at posterior zygoma. Combined traction on SMAS zygomatic extension and fat pad fascias using 3 perforation points with trans-nasal, trans-mucosal perforation point B1, and trans-dermal B2; **A.** Perforation points, **B.** Before, **C.** After simultaneous cheekbone lift and beautification rhinoplasty to place the tip at the cheekbone line and produce 3 equal facial proportions.

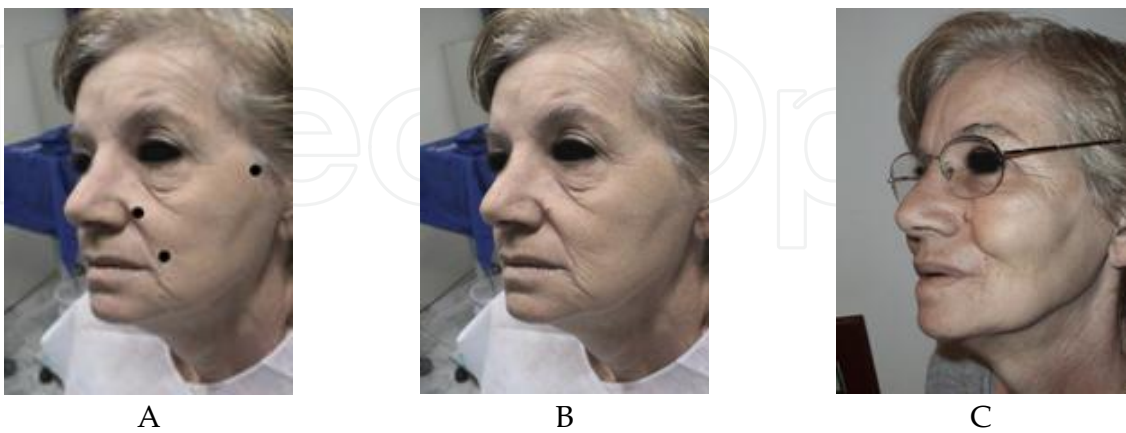

Figure 18. Lateral cheekbone lift. Fixation at posterior zygoma. Using 3 perforation points. Combined traction on SMAS zygomatic extension and fat pad fascias. **A.** Perforation points, **B.** Before, **C.** After cheekbone lift. Collected tissue gives a new cheekbone volume; nasolabial, tear through and marionette folds are managed; lower lid is changed – orbital fat is located under the lifted cheekbone flap.

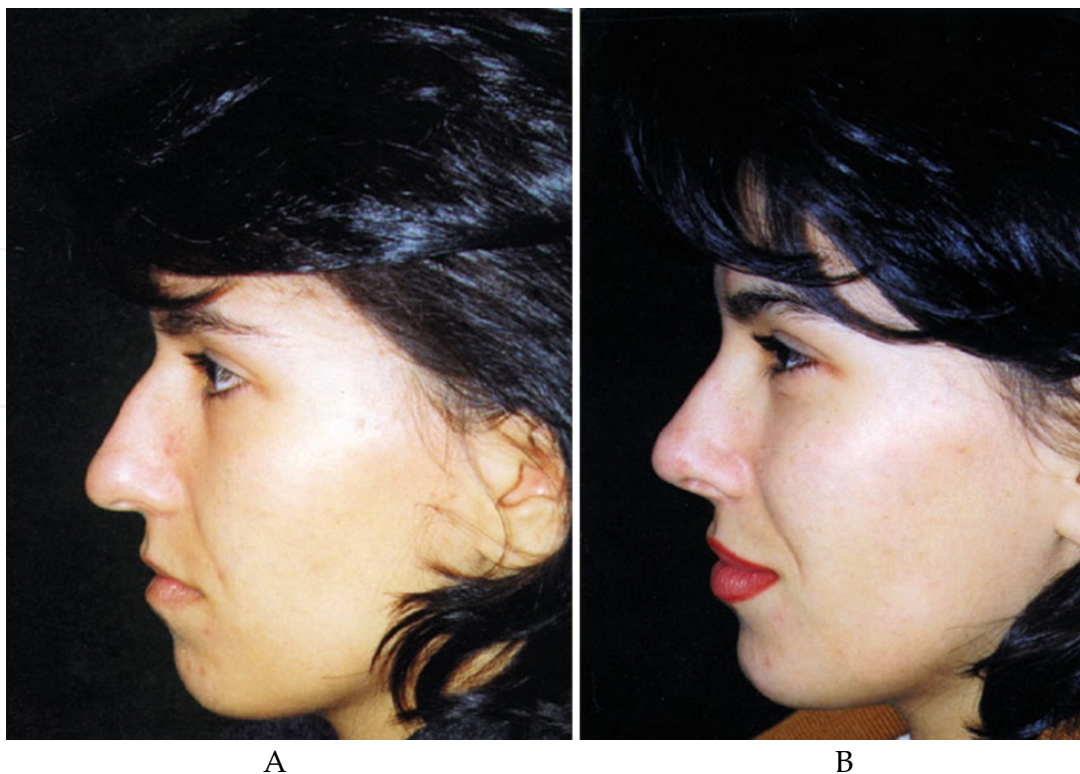

Figure 19. Medial cheekbone lift. Fixation to anterior zygoma, using 2 perforation points. **A.** Before, **B.** After simultaneous temporal cheekbone SMAS lift, rhinoplasty, chin enhancement by suture, and WY lip augmentation.

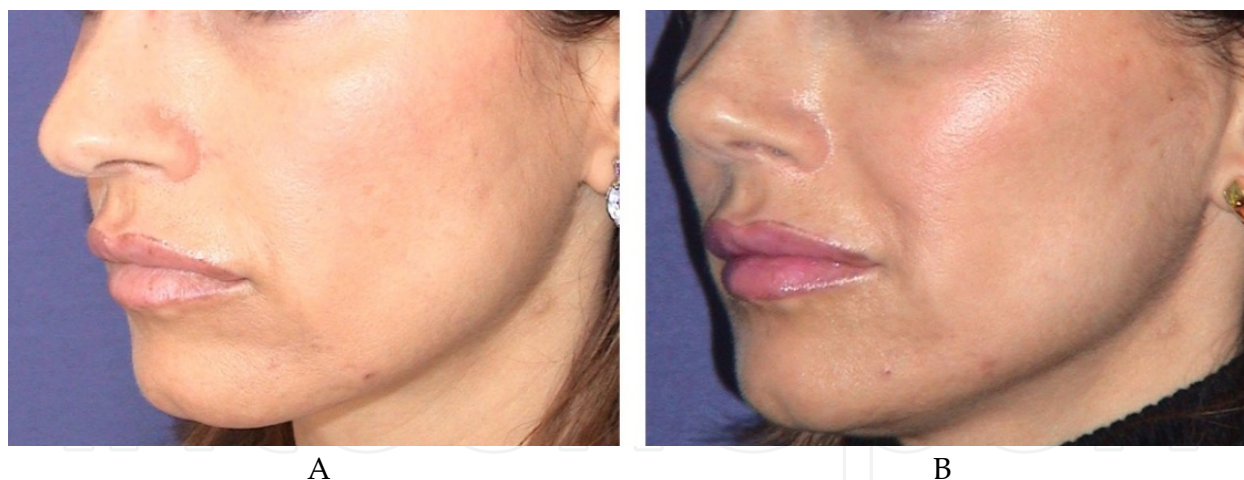

Figure 20. Medial cheekbone lift to eliminate the tear through fold. Fixation to anterior zygoma, using 2 perforation points. **A.** Before, **B.** After simultaneous temporal cheekbone SMAS lift, rhinoplasty, chin enhancement by suture.

2.5. Cheek dimple formation

1. In combination with cheekbone lift. Using 2 or 3 perforation points. Point A - fixation at the zygomatic arch, at desired point, Point B at smiling point with biting and engaging dermis.

Formation of cheek dimple at smiling point is easy, engaging dermis in the suture at skin perforation point B, located at the smiling point (Fig 21).

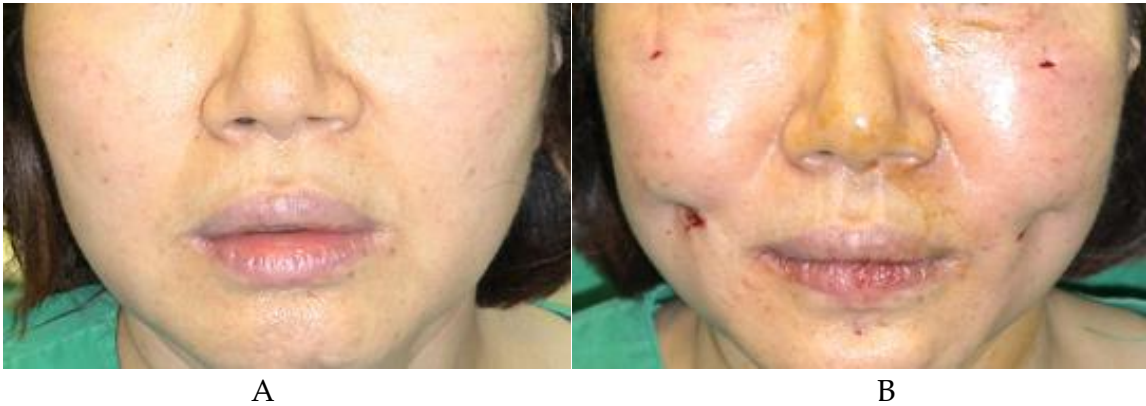

Figure 21. Cheekbone lift with cheek dimple. Using 2 points in an elderly patient. **A.** Before, **B.** immediately after operation

2. Cheek dimple only. Using 2 perforation points: Skin perforation point A at anterior zygoma. Perforation point B at smiling point (Fig. 22).

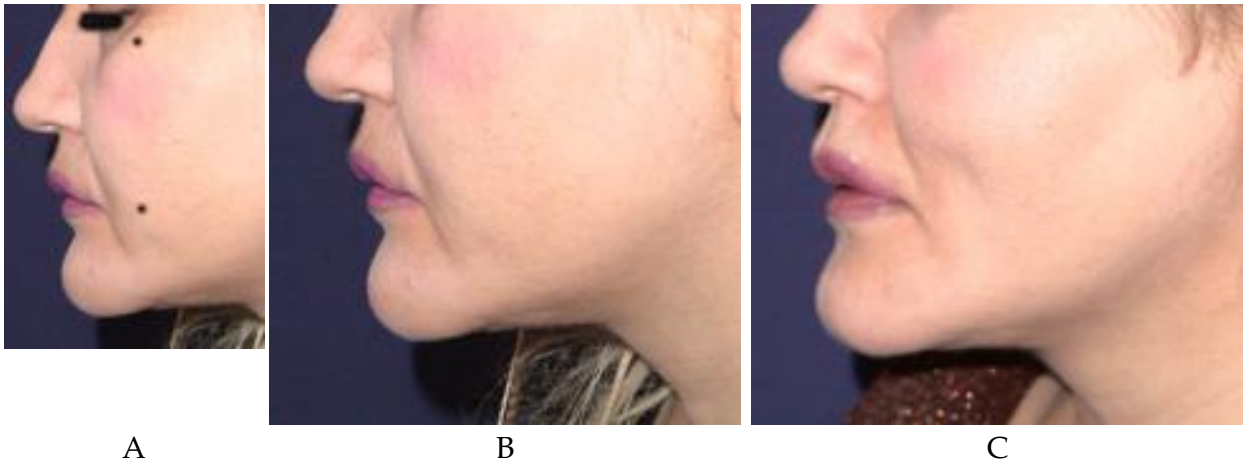

Figure 22. Traction on dermis at smiling point, which forms cheek dimple. Using 2 points in an elderly patient. **A.** Perforation points, **B.** Before, **C.** After.

2.6. Results

1280 patients with suture cheekbone lifts were followed from 3 to 18 years. The procedures took place during the period between 1993 and December 2012 to enhance, lift and improve the cheekbones, as well as to solve problems of an ageing face, such as nasolabial folds, tear trough folds, marionette folds, hollow area, skin wrinkling etc. 92% of these patients had simultaneous suture lifts and other treatments of face or body. In the face, the author combines the cheekbone lift mostly with temporal lift, brow lift, lower SMAS-platysma lift, chin enhancement and beautification rhinoplasties. Early and late results are mostly satisfactory to excellent. Patient satisfaction, apart from consideration of rejuvenation and beautification outcomes, is mostly connected to local anesthesia, absence of pain, short

operation time, immediate or very rapid recovery and fast return to social activities and work. Patients' aesthetic satisfaction goes beyond pre-operative expectations. In the first 7-10 days an expected sensation of tension in the operated area is present, which is normal. In fact, most patients love this "lifting sensation" and describe it as pleasant and expected.

2.7. Complications

In 1 patient, after cheekbone lifting with dimple formation, the dimple on the left cheek had disappeared 3 days after the operation, due to pillow pressure. Immediate re-suturing was performed, which successfully reconstructed the symmetry and the smiling dimple.

Four patients had post-operative bruising at the lower lid.

The author has had no nerve injuries, no hematomas, no seromas, and no infections in the follow-up clinical cases.

In 2 patients, on the first post-operative day, an additional pull on the skin was performed to obtain lifting-level symmetry on both sides. The correction was performed under local anesthesia.

In the first 3-4 days, five patients complained about having a perception of an overcorrection or an exceedingly high lift and projection of the cheek-bones. This is normal during the maximum swelling period. These complaints disappeared in 5 to 10 days. One Asian patient did not feel comfortable with the new cheekbones and the sutures were removed 30 min after operation. **NB!** The sutures are easy to remove – the knot is at the point of the stable immobile attachment at the periosteum in skin perforation point A. A mosquito clamp is introduced in the opening at point A, the knot is pulled outside of the skin, the suture is cut and removed.

Serdev Sutures® can be placed, removed and replaced at any time with nearly no down time.

There were 12 cases of late secondary repetition after 5 to 12 years, as part of a total face maintainance, combined with suture lifts in neighboring facial areas.

2.8. Discussion

Except lifting and augmentation, the cheekbone lift forms nice, young looking "hungry" cheeks. In elderly patients, the cheekbone lift gathers tissue, resolves the tear trough fold, projects and lifts the cheekbone (as part of beauty triangle), lifts, flattens nasolabial and marionette folds, and stretches the jaw line. In young patients it projects, enhances and elevates cheekbones. Cheekbone volumizing is part of the beauty triangle formation (projected cheekbones and chin). Additional chin enhancement using sutures is always advisable if the chin is not projected enough. Patient satisfaction is closely related to the individual possibility of obtaining correct proportions, volumes and angles of the face, including cheekbones.

To date, there are not many methods for cheekbone lifting and volumizing without implants and transplants. Classic rhytidectomies do not correct volume and do not change proportions even with modern endoscopic methods. Simultaneous suture SMAS lifts, even in open surgery during rhytidectomy, can improve the cheekbones, lower face and jowls. This method, especially the suture tissue volumizing without the use of implants or transplants is unique. Classic rhytidectomies cannot lift cheekbones in a medial direction and most of the time use implants. This also demonstrates the pre-eminence of the author's method. Complications in scarless closed approach suture techniques are rare (less than 0,1%). In other invasive surgeries, the rate increases with the extension of the surgery.

Cheekbone lift using the scarless, transcutaneous, closed approach Serdev Suture® method is ambulatory, very well tolerated by patients, with immediate effect. The recovery period is very short and patients can return to their social life and work almost immediately. Complications are less than 0,1% and patient satisfaction is extremely high, especially with regards to aesthetics. A particularly positive advantage in suture lifts is the possibility to select the position, volume and level of cheekbone enhancement and lifting. Patients prefer the possibility of total facial improvement, in combination with neighboring facial areas, as part of the mini-invasive procedure.

3. Mid-face lift

In the face, Serdev Suture® techniques lift the mobile SMAS and fix it to stable immobile anatomical structures. Scarless Serdev Suture® mid-face lift sutures loose zygomatic SMAS extension to firm temporoparietal tendon insertion and underlying temporal periosteum. Such a lift results in lifting the mid and lower SMAS, restoring cheekbone into a higher position, resolving the tear trough, nasolabial and marionette folds, stretching mid-face SMAS and attached skin in a temporoparietal direction. Lower face and neck are also improved. Serdev Suture® lifting techniques are ambulatory, performed under local anesthesia, very well tolerated by patients, with an immediate effect, with an extremely short post operative period, fast recovery and nearly immediate return to social life. Complications are about 0% and patient satisfaction is very high, especially in the aspect of aesthetics.

The concept of a mid-face lift by sutures, without skin incisions and excisions, is to lift loose zygomatic SMAS extension and fix it to stable temporoparietal tendon, it's insertion and underlying temporal periosteum. For the purpose of scarless lifting the author has created an innovative design that uses needle perforations only.

The author has created special, curved, semi-blunt and semi-elastic needles of different lengths, with an eye at the tip (Fig. 23). For mid-face lift, needles with lengths of 50 mm, 60 mm, and 100 mm are used to introduce long-term absorbable (in 2-3 years), semi-elastic Polycon surgical sutures USP 2 and 4.

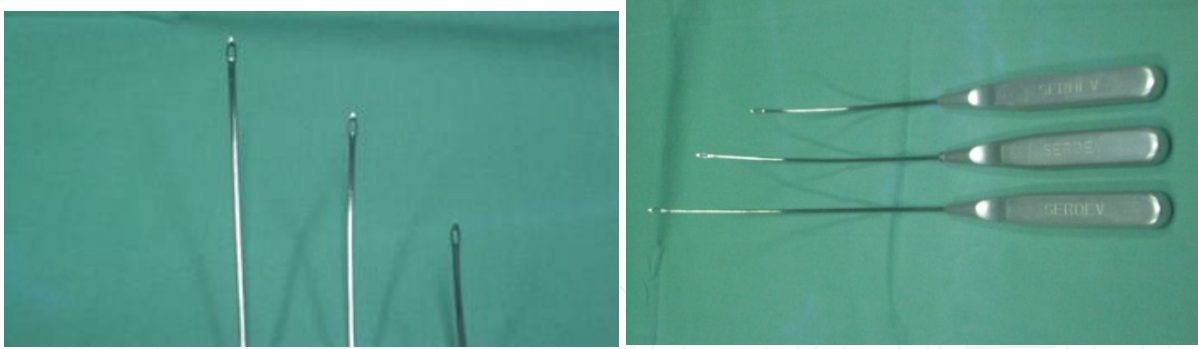


Figure 23. Curved, semi-blunt and semi-elastic needles with different lengths of 50 mm, 60 mm, and 100 mm and an eye at the tip.

Anesthesia

Local anaesthesia with i.v. sedation is used instead of general anaesthesia, in order to shorten intervention time, along with both surgeon and patient preference.

Important fixation lines:

A-B – stable fixation to immobile temporoparietal tendon insertion and underlying periosteum.

A1-B1 – fixation of mobile zygomatic SMAS extension.

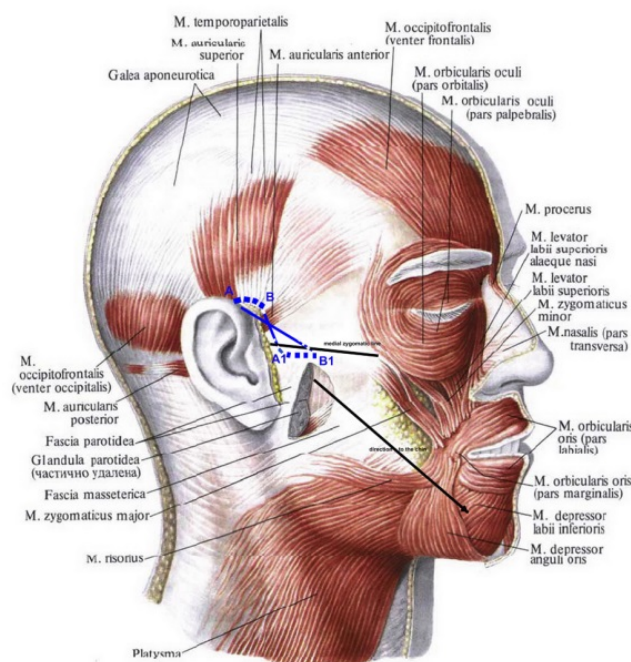


Figure 24. Scheme of mid-face lifting – fixation of zygomatic extension of SMAS (line A1-B1 below zygoma) to temporoparietal tendon and temporal periosteum (line A-B), just above the ear at temporoauricular angle. The vector is from chin to temporoparietal tendon - in temporoparietal direction. Thus, the mid-face SMAS and marionette lines will be stretched. Connection lines A-B1 and B-A1 are crossed to reduce bulging. *Anatomy figures from Sinelnikov - Atlas Of Human Anatomy, GIML, Moscow, 1963

Anatomy guidelines

The fibro-muscular layer, described as Superficial Muscle Aponeurotic System (SMAS), connects the vertex and platysma and acts as suspension for the overlying facial skin. SMAS is fixed to the zygoma by the zygomatic SMAS extension that permits movement of the lower SMAS. In direction towards the zygoma, at the superior orbital rim level, the immobile temporalis fascia (or deep temporalis fascia in some textbooks) splits in two immobile layers: superficial and deep layer. These two immobile fascial layers enclose an intermediate fat pad and within - frontal branches of facial nerve, artery and vein. The frontal branch of the facial nerve is considered to cross the zygomatic bone, traveling along a line, connecting the tragus base to a point 1.5 cm above the eyebrow.

So, the anatomic topography forms a square - 3 cm front of the tragus and 3 cm above the zygomatic bone that is described by the author as a “**danger area**”. There, the frontal branch of the facial nerve is considered to cross the zygomatic bone at about 1.5 cm anterior to the tragus. **NB!** Fixation to zygoma in cheekbone suture lift should not be done in the danger area – do not perforate zygoma periosteum in the first 2-3 cm in front of the tragus.

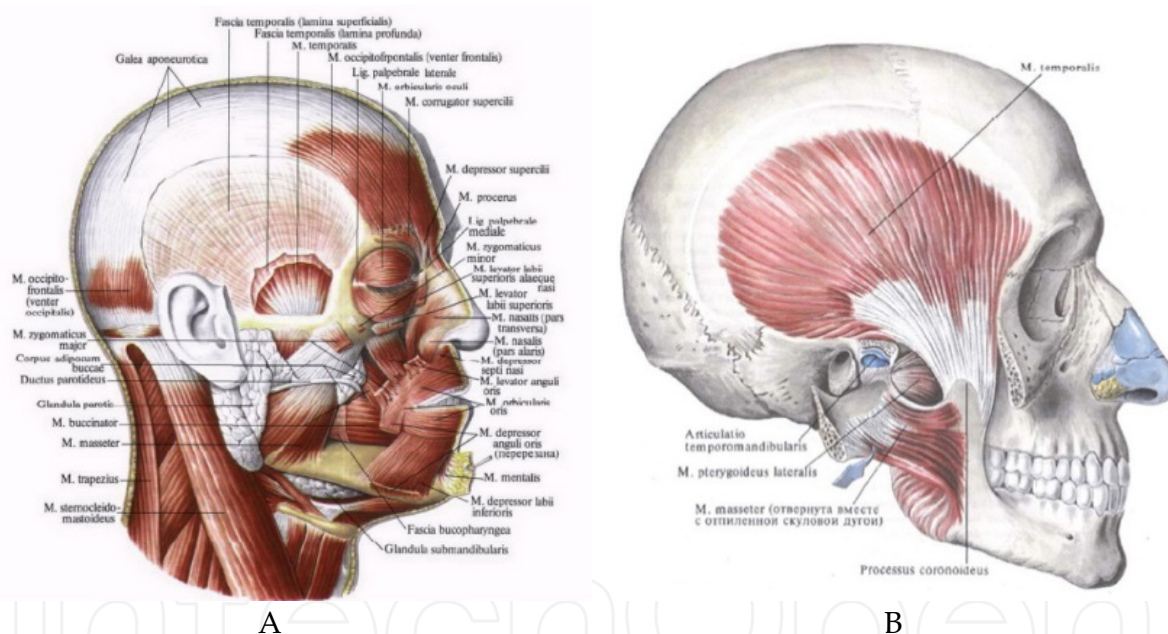


Figure 25. A, B. Temporal tendon and fascia are not suitable for mid-face fixation and lift, because of their direction. Sutures slide down due to fibers' distal direction. *Anatomy figures from Sinelnikov - Atlas Of Human Anatomy, GIML, Moscow, 1963

Temporoparietalis muscle tendon is fixed to spina suprameatica of meatus acusticus externus. It is stable, immobile and is used by the author for firm cephalic fixation of the suture in mid-face lift. **NB!** Temporalis fascia and tendon directions are not suitable for this particular fixation (Fig. 25A, B). If fixed to the temporalis fascia, the suture will slide down and loosen.

SMAS zygomatic extension is a mobile fascia which is used by the author to lift mid and lower SMAS.

The mobile A1-B1 SMAS fixation to zygoma will be lifted to the immobile A-B line at the temporoparietal tendon insertion and underlying temporal periosteum. **NB!** In the “**danger area**” (connecting lines B-A1 and A-B1) the needle should pass carefully (superficially), just below the mobile tissue (skin and galea aponeurotica, fixed together). If the needle becomes fixed, it has perforated deeper immobile superficial layer (lamina superficialis) of temporal fascia that is dangerous, because of possible vessel perforation. Prolonged pressure in such cases can stop bleeding in the “danger area”.

Directions

Pass B-(A1)-B1. Point A1 is only a mark. It should be drawn for orientation and should not be perforated. **NB!** Needle pass B-A1 is in the “danger area” – it should be superficial, just below galea and skin, i.e. supratemporal. Passing below the lower line of zygoma, the needle catches the mobile zygomatic SMAS extension.

Pass A-B1 is a connecting pass, located in “danger area”. The needle should pass superficially/subgaleally i.e. supratemporally, to take the suture from point B1 to A.

Pass A-B is the stable fixation under temporoparietal tendon insertion and underlying temporal periosteum.

Vectors: 2 vectors are effective with this lift:

- Temporoparietal direction from chin to temporoauricular angle - point A, with strong effect of traction on cheek SMAS, on the marionette folds and additional effect on the nasolabial folds,
- Dorsal direction from cheekbone to point A, with strong effect on the nasolabial and tear trough folds and additional effect on marionette folds.

Video: <http://www.youtube.com/watch?v=S51JZOCfLfg>

FIRST SUTURE PASS: consists of connecting line B-A1 and movable zygomatic SMAS fixation at line A1-B1

Mark perforation points A, B and B1 for skin perforations. Entry point A is placed just above the ear, in the temporoparietal angle, and point B - approximately anteriorly to A, at the hairline. Point A1 is only a mark and should be not perforated. Point A1, line A1-B1 and point B1 should be below the lower line of zygomatic arch, i.e. lower than the mobile SMAS zygomatic extension. Perforation point B1 is placed at intersection point of chin to temporoauricular angle line and lower zygomatic line.

Line A-B is the subperiosteal immobile fixation to temporoparietal tendon insertion and underlying temporal periosteum. A1-B1 is the line of fixation below mobile SMAS zygomatic extension.

Local anesthetic is introduced intradermally at points A and B, then subperiosteally at the line A-B, just subdermally in connection lines B-A1 and A-B1, and deeper subdermally in line A1-B1. Use only a small amount of anesthetic – a few drops per line. Larger amounts will result in visible post-op swelling. **NB!** In the “danger area” (connection lines

B-A1 and A-B1), the needle should be supratemporal, just below skin and galea aponeurotica.

The skin is perforated with a No. 11 scalpel blade in points A, B, and B1 (respect Langer lines) and then, using the thin tip of a mosquito clamp, the skin perforations at point B1 will be widened and deepened. **NB!** If superficial fascia is not perforated at point B, it could produce dimpling when engaged and lifted with the suture.

Introduce a “mini” 60 mm Serdev® needle in a perpendicular fashion through point B (do not engage dermal tissue), then slide it strictly subgaleally/supratemporally in direction to point A1, then rotate it toward B1. When the needle tip reaches a position below point B1, direct the tip upward toward opening B1, then fold the skin against the needle tip at a 90° angle and with a gentle twisting movement direct needle upward, until it exits from point B1. Try to avoid engaging dermis as you are exiting, in order to prevent creation of skin dimples. **NB!** If at point B1 the needle is facing any resistance, this means that it has caught dermis, in which case twist the needle backwards and repeat the maneuver. Do not push or pull – twist needle forwards and backwards.

After the needle is threaded at point B1, it is pulled back until it exits through point B, bringing the suture with it. This represents the pass, which fixes the movable SMAS zygomatic extension.

SECOND SUTURE PASS: supratemporal A-B1 connecting line. Connection lines A-B1 and B-A1 are crossed to reduce bulging.

The second needle pass is subdermal, between points **A** and **B1**. Avoid deeper perforation of superficial layer of temporal fascia. To facilitate needle advancing, locate the needle laterally and use a gentle twisting movement, until you reach point B1 (exit point).

After exiting perpendicularly through point **B1**, the free end of suture is threaded through the needle eye and pulled backward to exit through point A.

Important! At this stage, take both ends of the suture, pull them in temporoparietal direction and at the same time pull the dermis in perforation point B1 in opposite direction to the chin, using a mosquito clamp, until any dimpling is released. You could feel a “click” when releasing the suture from the trabecular attachments and dimpling will disappear. If dermis at point B1 is attached to the suture through carelessness, it will not be possible to release the dimpling. Then the suture has to be removed and previous steps - repeated.

THIRD SUTURE PASS: Line A-B - Subperiosteal fixation at temporoparietal tendon insertion

Introduce a specially bended “mini mini” 50 mm Serdev® needle in a perpendicular fashion through point A (do not touch or engage dermal tissue!). Once the needle touches the bone, slide it subperiosteally to point B. **NB!** Check whether the needle is locked under periosteum. If it moves freely laterally, it means that it is not inserted at sub-periosteal level. This is a common beginner’s mistake. If locked under periosteum, the tissue is so stable that

it is possible to lift the patient's entire head with the needle. If movable, it should be repositioned deeper under periosteum.

When the needle tip reaches a position below point B, direct the tip upward towards opening B, then fold the skin against the needle tip at a 90° angle and with gentle twisting movements direct needle upward until it exits from point B. Avoid engaging dermis as you are exiting, in order to prevent creation of skin dimpling. If you feel that the needle is facing any resistance, it means that the needle has caught the dermis, in which case move the needle backwards and repeat the maneuver.

NB! Do not push or pull – gently twist needle forwards or backwards.

After threading the needle at point B, it is pulled back towards point A until it exits, bringing the suture with it. This will complete the suture circle formation and a surgical knot is performed, using optimum tension. Use one branch of a mosquito clamp to release dimpling at the perforation points.

The author does not use stitches to close perforation points A, B or B1. They are taped for overnight. On the next day, patients should take a shower with shampoo to remove blood residuum at the perforation points. Multiple disinfections are applied by the patient on a daily basis, for 3-4 days. Some swelling (like soft bulging) in the area can be visible for 3-4 weeks and then disappears. Patients usually cover it with their hair.

3.1. Results

520 patients were followed up from 3 to 18 years, starting in 1993. In 95% of the cases, patients had simultaneous treatment in other face and/or body areas. In the face, combinations were mostly with temporal, brow lift, lower SMAS-platysma lift, chin enhancement and beautification rhinoplasties.

Results were excellent in 96% of all cases, as reported by our patients. Patients' satisfaction is mostly connected to the immediate aesthetic result and visible rejuvenation of the medial and lower face, local anesthesia, short operation time, lack of pain, immediate or rapid recovery and speedy return to social activities or work. There is an almost complete correlation between aesthetic outcomes with pre-operative patient expectations.

In the first 7-10 days patients experience a traction sensation. Most patients find this sensation desirable and are attracted to it. Some pain was reported when pressure is applied to the area, which is considered normal.

After three years, results are reported to remain satisfactory in 85% and good in 12% of the cases.

In five years, 52% of the patients report satisfaction and 37% consider results as good.

Only in 3 cases the mid-face lift has been repeated after 4, 6 and 8 years. Such additional suture lifts and enhancements have mostly been performed to complete or maintain a good status.

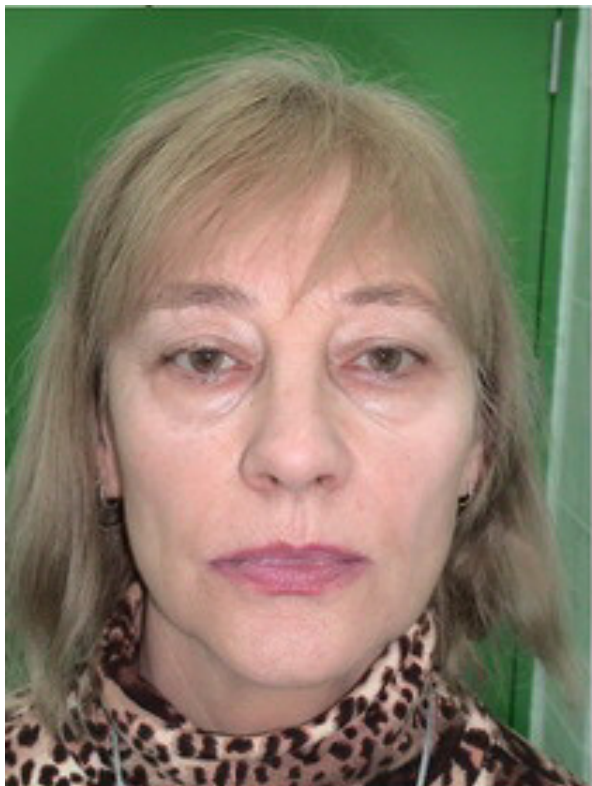
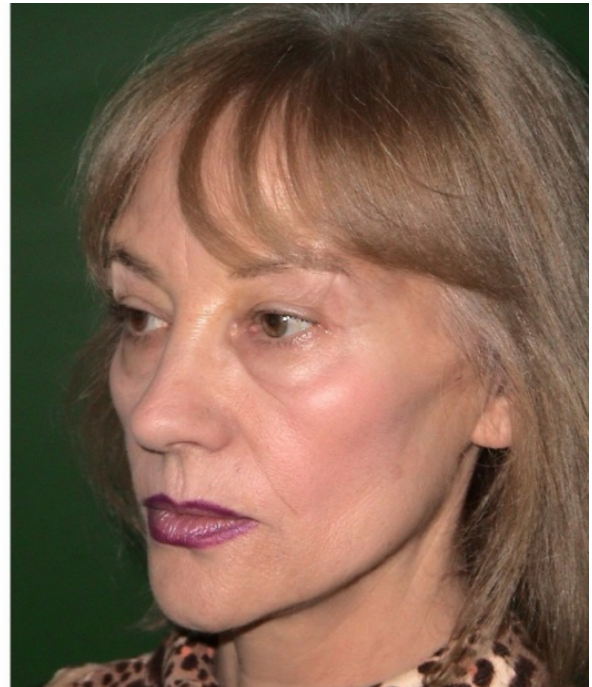
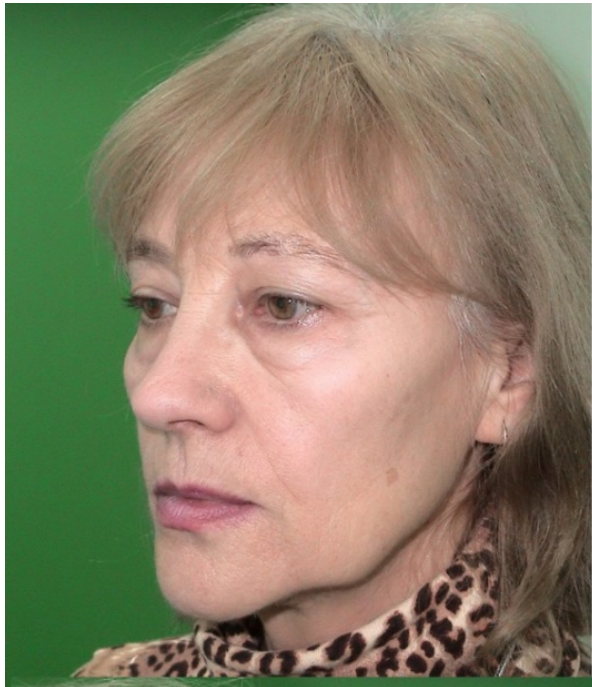
Figure 26. Before and after mid-face lift and simultaneous brow lift using Serdev Sutures®. Better cheekbone position, and jaw line, formation of so-called “hungry cheeks”. Face is tightened and changed from “square” to oval.

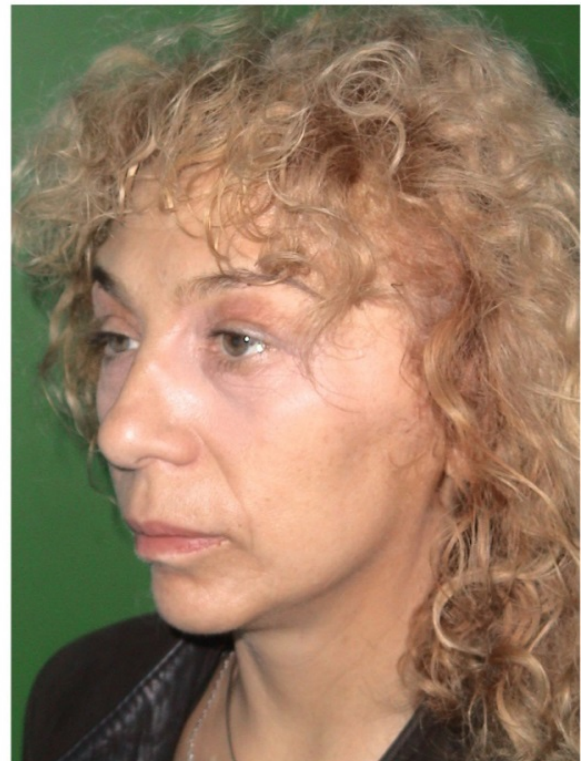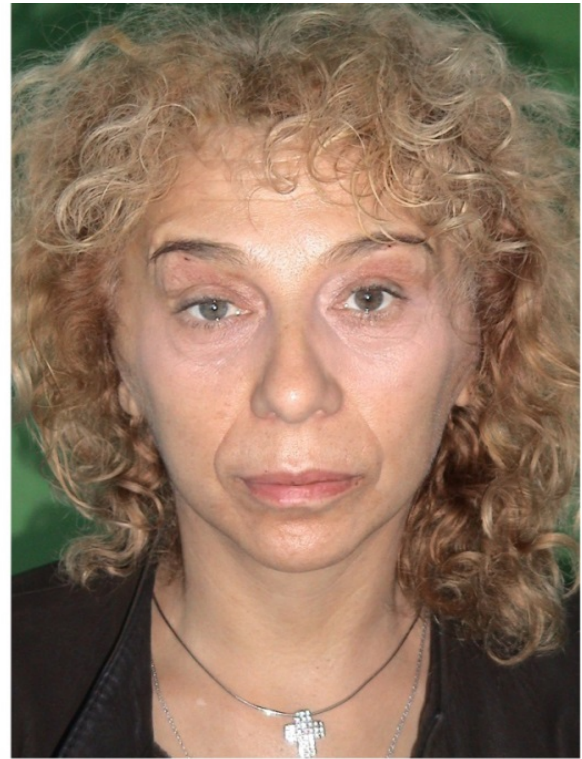

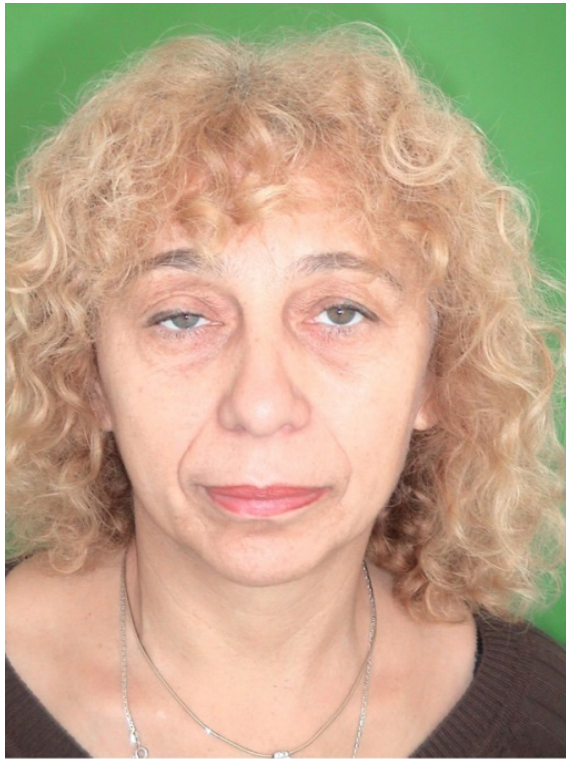
Figure 27. Before and after mid-face lift and simultaneous brow lift using Serdev Sutures®. Better cheekbone position, and jaw line. Face is changed from “square” to oval.

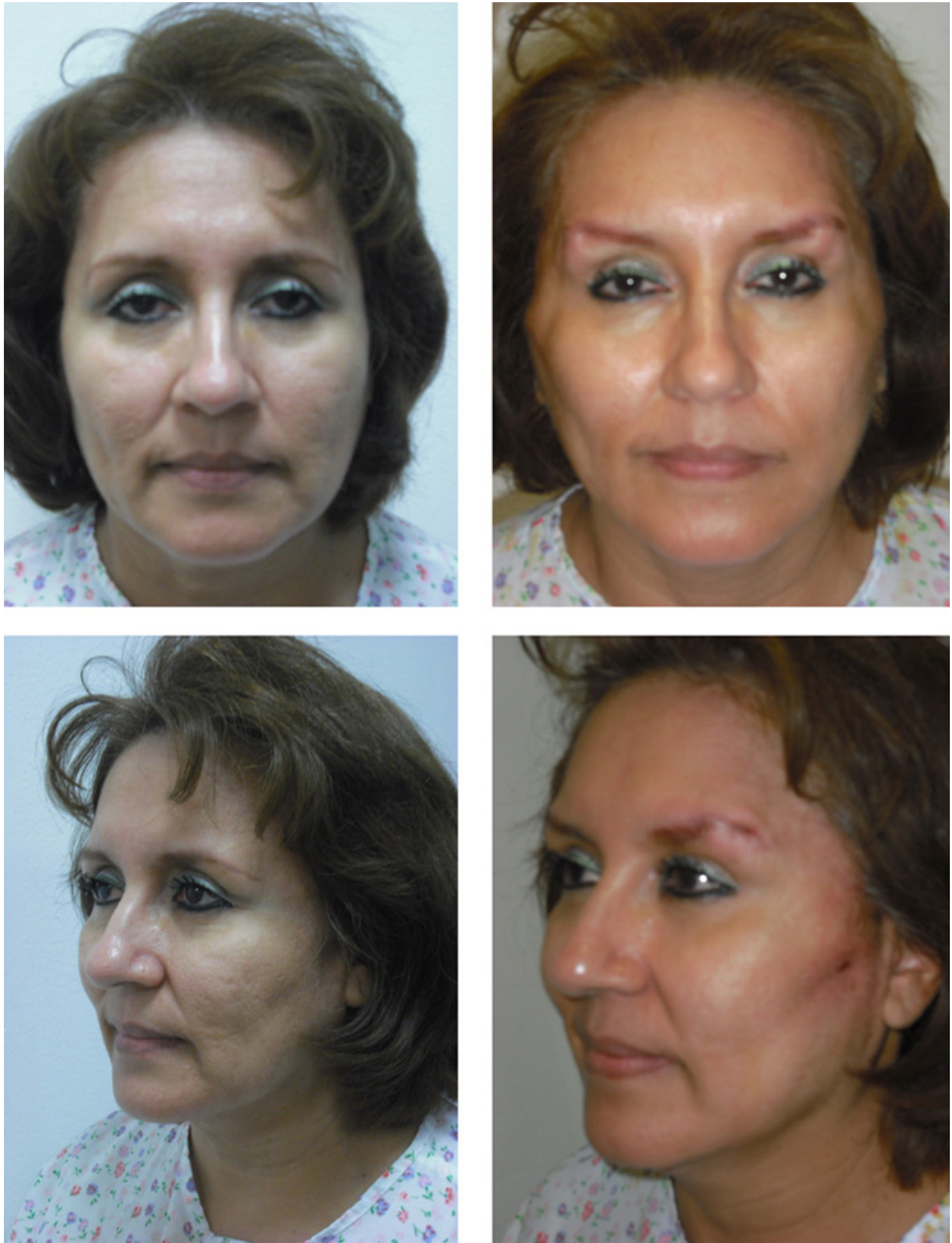

Figure 28. Before and immediately after mid-face lift and simultaneous brow lift using Serdev Sutures®. Better cheekbone position and jaw line. Face is tightened, refreshed and changed from “square” to oval.

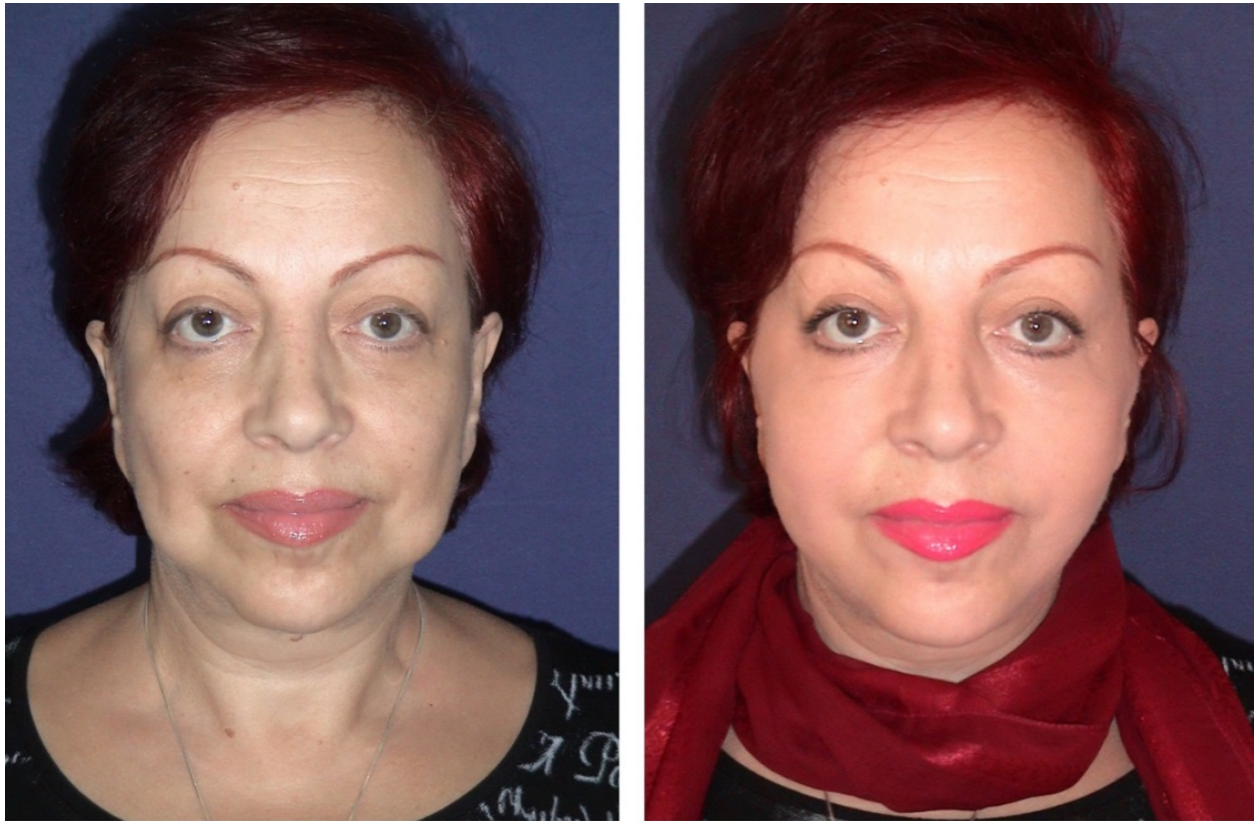

Figure 29. Before and after mid-face lift using Serdev Sutures® and simultaneous ultrasonic assisted liposculpture of buccal fat. Better cheekbone position and jawline. Face is tightened, totally refreshed and changed from “square” to oval.

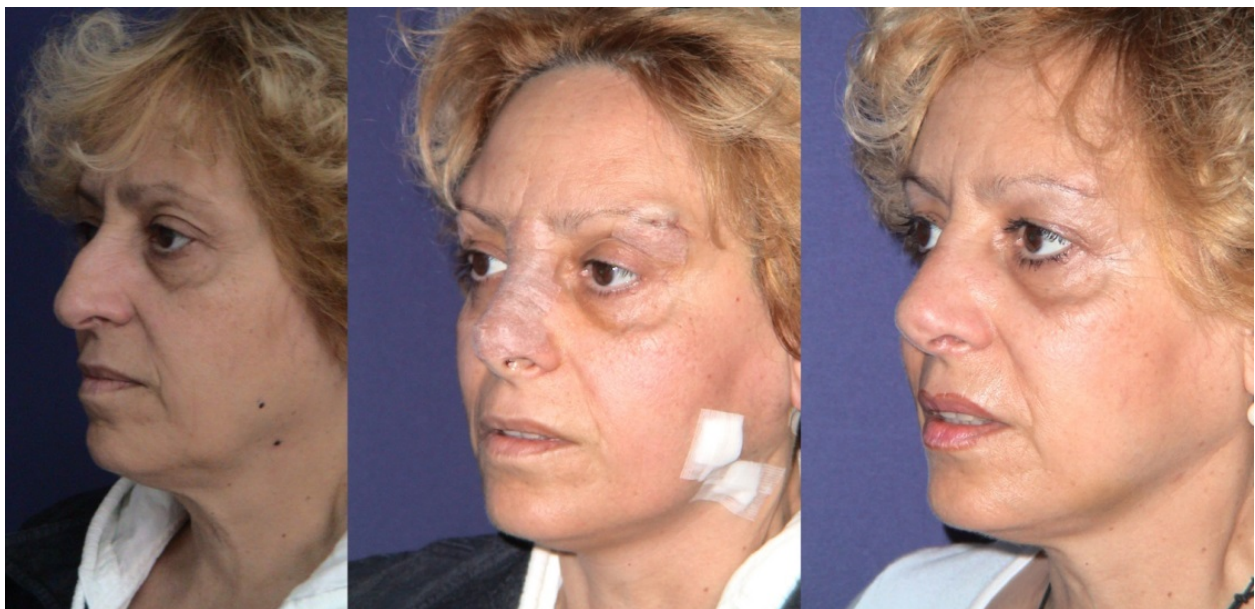

Figure 30. Before, immediately after and 4 years after mid-face lift and simultaneous temporal, brow, lower face and neck lift using Serdev Sutures®, and rhinoplasty.

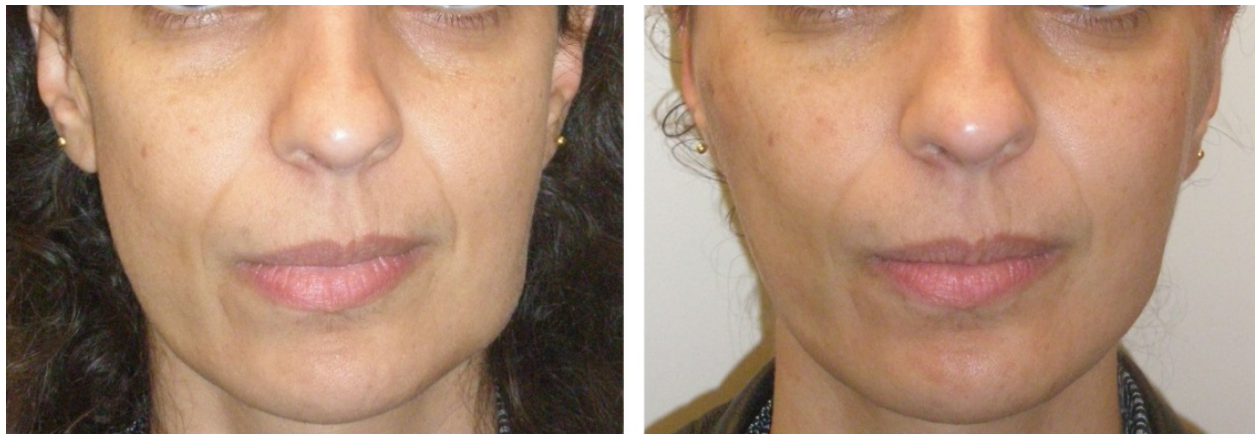

Figure 31. Before and immediately after mid-face lift to equalize both sides in a case of facial paralysis.

There was no case of secondary correction after mid-face lift except the three reported in a late stage. In one case, during hands-on training, a growing swelling was marked in a unilateral “danger area”. Having in mind a possible trauma, pressure was applied for 10 minutes. This swelling successfully flattened and the operation was finalized. No bleeding, hematoma or bruising in the area was observed in the early post-operative period.

The author has had no infection, hematoma, seroma, or nerve injury after suture mid-face lifts.

3.2. Discussion

Skin lifting in classic subdermal and deep rhytidectomies does not significantly improve nasolabial and marionette folds. Flattening of marionette and nasolabial folds with the suture technique demonstrates its superiority over invasive lifting methods, where complication rates rise with extensive surgery.

Mid-face lift using Serdev Suture® methods is ambulatory, very well tolerated by patients, with immediate effect, with an extremely short post operative period, fast recovery and nearly immediate return to social life. Complications are near 0% and patient satisfaction is very high, confirming the longevity of results.

The advantages of the suture lifts include the possibility to correct and improve anatomy at any time, with nearly no down time, no trauma, and high patient satisfaction.

4. Beautification rhinoplasty – tip rotation and refinement, alar base narrowing

The author describes his experience and methods in different aesthetic disproportions of the external nose and in secondary cases.

Rhinoplasty is a part of the beautification process and has to follow anatomical proportions and beauty principles. Nose length has to occupy the middle 1/3 of the face, according to the proportions of the “golden section” rule of 3 equal thirds.

Proper nose **proportions, angles and volumes** should guide the cosmetic surgeon.

Proportional nose is one that occupies 1/3 of the face (golden dividing rule). Proper volumes are: thin dorsum, thin tip, narrow allar base. The tip of the nose prominence gives volume to the central face and its position should be in harmony with the beauty triangle (projected cheekbones and chin). The tip should be in the line of the cheekbone prominences. The nasal dorsum should be straight or slightly concave. Best angles are: 90° angle at the tip, 110° nasolabial angle, 30° angle of nostrils to columella, 30° dorsum to profile line.

The aim of Serdev Suture® techniques in beautification rhinoplasty is to improve the above mentioned aesthetic proportions, volumes and angles not only of the nose but adapted to the face as a whole. Serdev Sutures® include tip refinement, tip rotation, and allar base narrowing.

4.1. TIP REFINEMENT SUTURE TECHNIQUES on greater alar cartilages:

- 1. Transcutaneous domal suture of all four crura to refine bulbosity,**
- 2. Transmucosal suture of the domal segment of the medial crura.**

Earlier nasal tip techniques were based on cartilage removal that can destabilize the nasal framework and nasal tip support. Later, radical cartilage resections have been replaced by reshaping and reorienting of the nasal tip components. Suture techniques of the nasal tip in open surgery became popular with McCollough and English double-dome unit procedure to increase tip projection and refinement, using a horizontal mattress suture through all 4 crura just beneath the domes; with Goldman tip procedure for the wide or bulbous lobule, with Daniel domal creation suture, a horizontally placed mattress suture, which shaped separately each dome. Numerous suturing techniques appear in the open technique rhinoplasty literature. All suture techniques are used in open surgery.

Serdev Sutures® tip refinement techniques represent scarless **closed approach** techniques. They are: 1. transdermal methods to suture all 4 crura beneath the domes, or 2. transmucosal medial crura mattress suture.

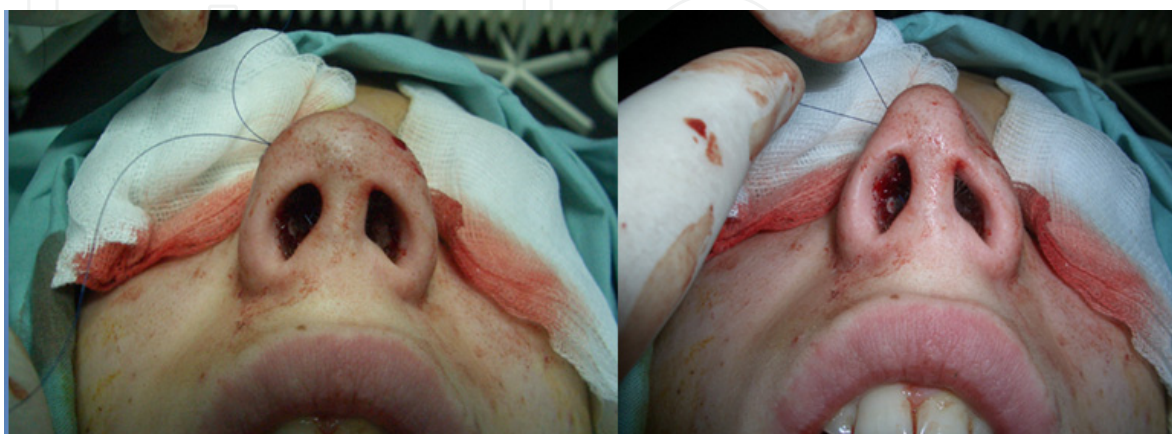


Figure 32. The suture is made through the domal part of the lower alar cartilages. The traction during knotting the suture is visibly tractioning the tip by the side. Be careful not to enter through the nostril as this will cause suture contamination.

4.1.1. Transdermal suture - all 4 crura domal fixation

The suture consists of 2 needle passes, using 2 skin perforations, without engaging skin. Each needle pass uses a different but parallel path through the cartilages. The transdermal suture is diving, buried below the skin, attaching only cartilages, without including skin in the suture. Skin perforations can be moved per side with each pass, in order to obtain parallel passes with a 2-3mm distance between. Both needle passes have to be placed in the domal area, without perforating the nostril, in order to prevent contamination and compromising the result.

4.1.2. Transmucosal suture – domal medial crura fixation

This method is usually combined with other author's closed rhinoplasty techniques, such as T-excision and columella sliding. The suture should be placed as high as possible to fix the domal medial crura. There is no need for this suture to be buried below the nasal mucosa, as the latter is involved on each side. Using absorbable sutures, the fibrosis stabilizes the effect after the first 3 - 4 weeks. If suture is not absorbable, it has to be removed after 3 weeks.

Both transdermal and transmucosal sutures give good refining definition and at the same time a projection effect. In cases of bulbous tip, transdermal suture of all 4 crura is preferable. Both sutures can be used separately, combined, or as a part of a rhinoplasty.

4.2. Tip Rotation – lifting of the greater alar cartilage medial crura with fixation to the periosteum of the nasal bones –

Video: <http://www.youtube.com/watch?v=nRh8NDSgDck>

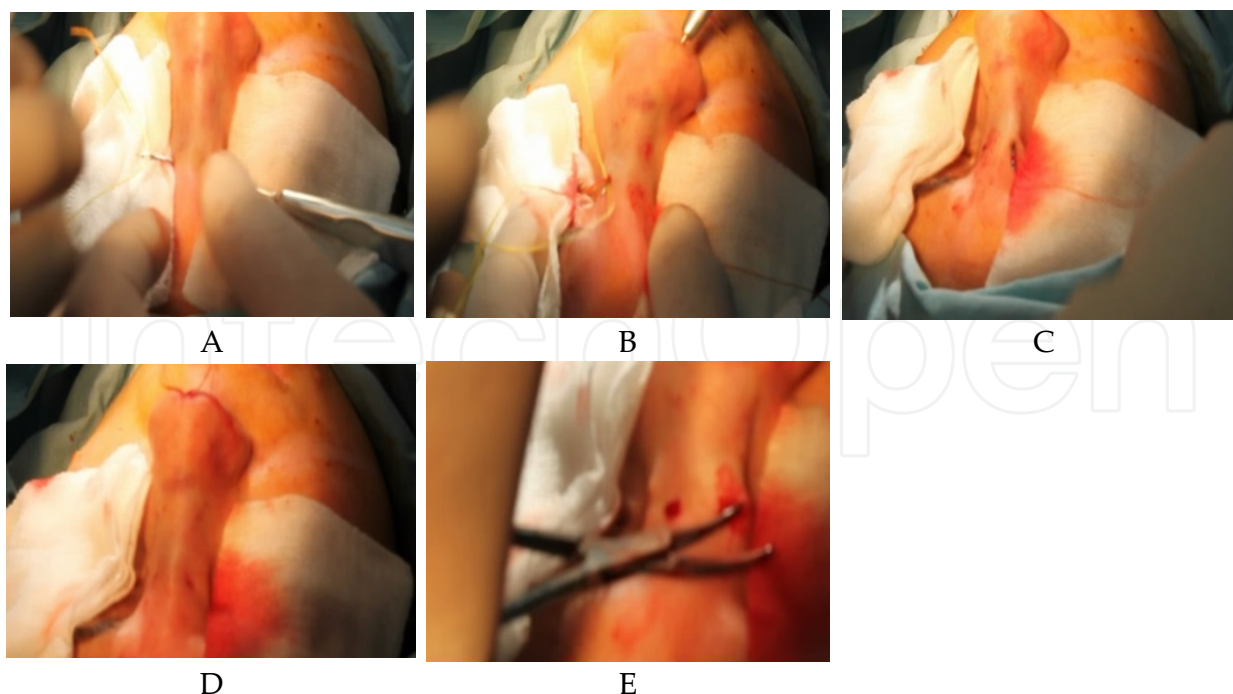


Figure 33. B. fixation to medial crus of the right greater alar cartilage and taking the suture from the right side, C. fixation to medial crus of the left greater alar cartilage and taking the suture from the left side, D. Suture is tied. E. removal of dimpling -<http://www.youtube.com/watch?v=nRh8NDSgDck>

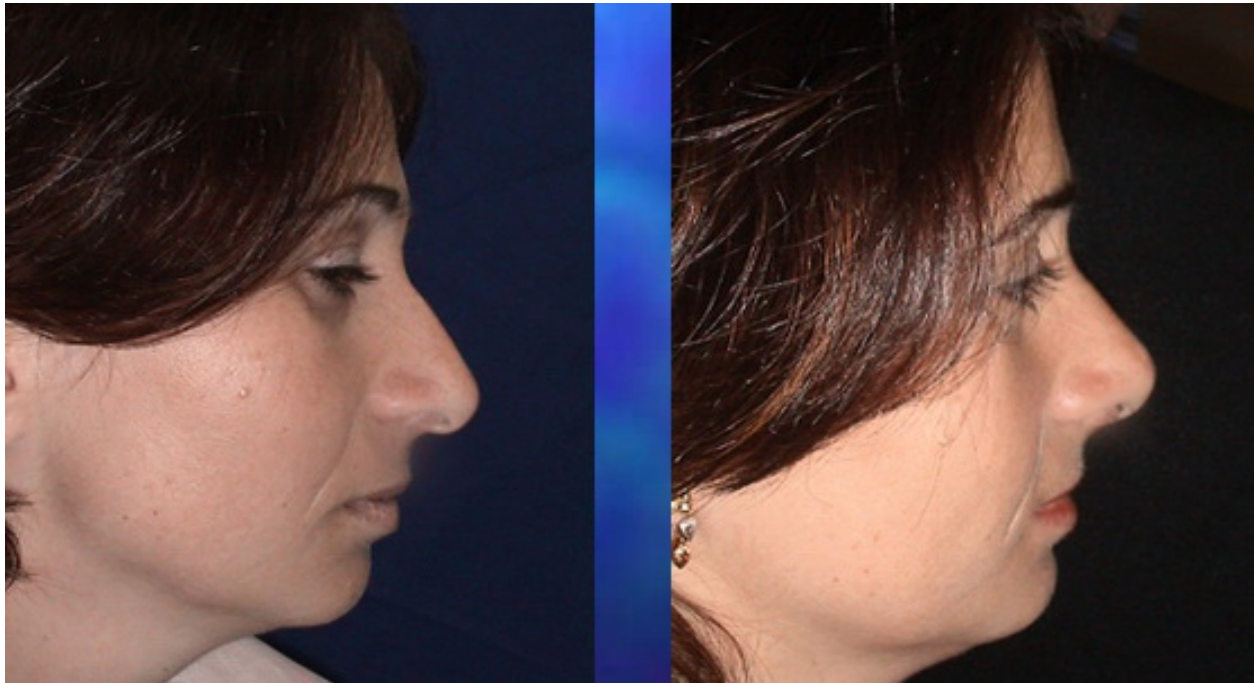

Figure 34. Nasal tip rotation in a Caucasian patient with properly sized septum and excess of skin at the tip.

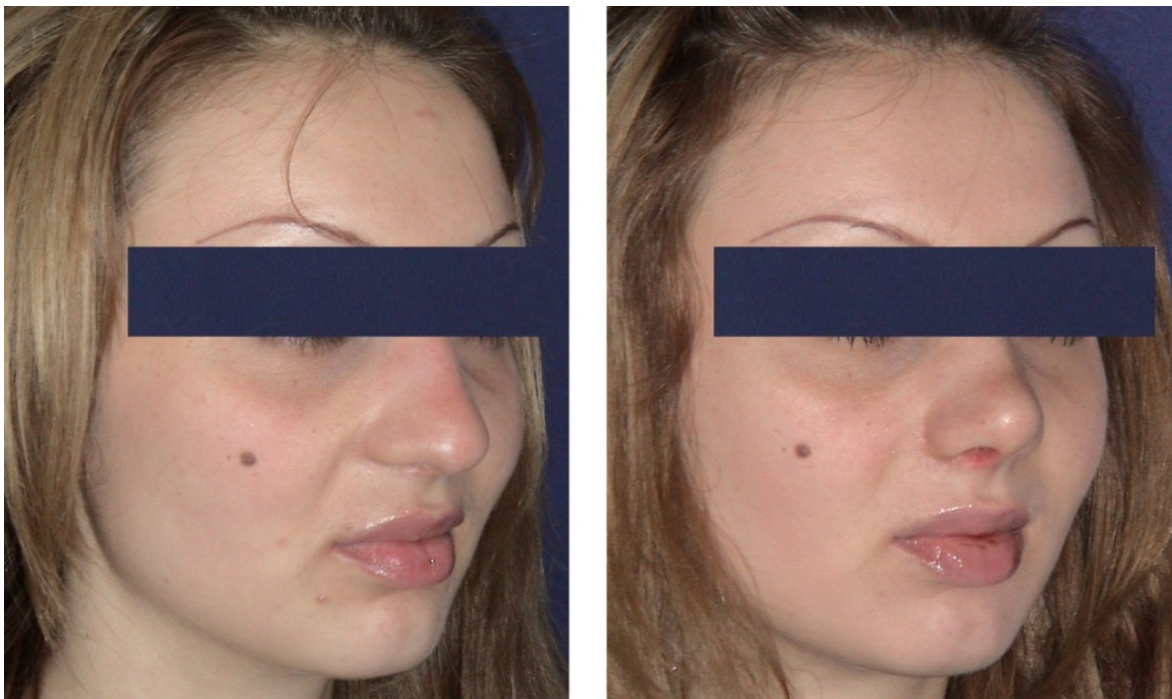

Figure 35. Nasal tip rotation for proportional beautification in a young patient. Nasal tip at the line of the cheekbones results in beautification

Two lines of the suture are important: the nasal bone subperiosteal pass that represents the immobile fixation and the subdermal pass in columella, fixing the mobile medial crura of the greater alar cartilages. Using 2 subdermal connecting passes, the circle of the suture is fulfilled and knotted. In each skin perforation point, the suture dives without engaging skin.

Nasal tip rotation by suture is mostly useful in Asians and Afro-Americans, having softer septum and unstable columella. In Caucasians, such suture lift is possible if the soft tissue is hanging over a normal length septum. In cases with a hard and elongated septum the tip cannot be lifted by suture and another author's technique is performed – the T-excision and columella sliding, which could be supported by that suture. This suture is very helpful to align the dorsum, especially in irregular dorsum and secondary rhinoplasties.

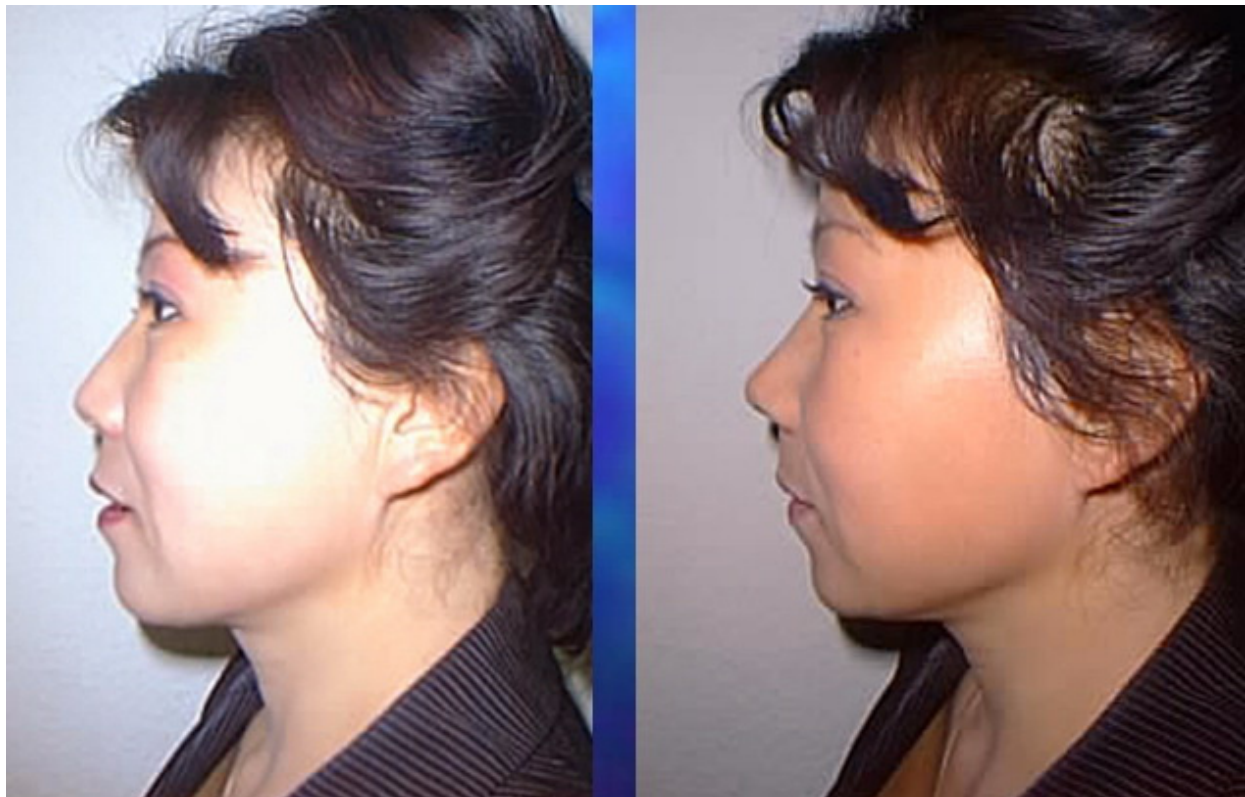

Figure 36. Nasal tip rotation for projection in an Asian patient with unstable septum columella.

4.3. Alar base narrowing

The suture represents 2 parallel passes (1-2 mm distance between them), using 2 skin punctures at both nasolabial angles. The cartilages are engaged to stabilize the suture on both sides. The suture lines should pass subdermally, exactly below the nostrils and nasal spine. **NB!** Do not perforate into the nostrils to avoid contamination.

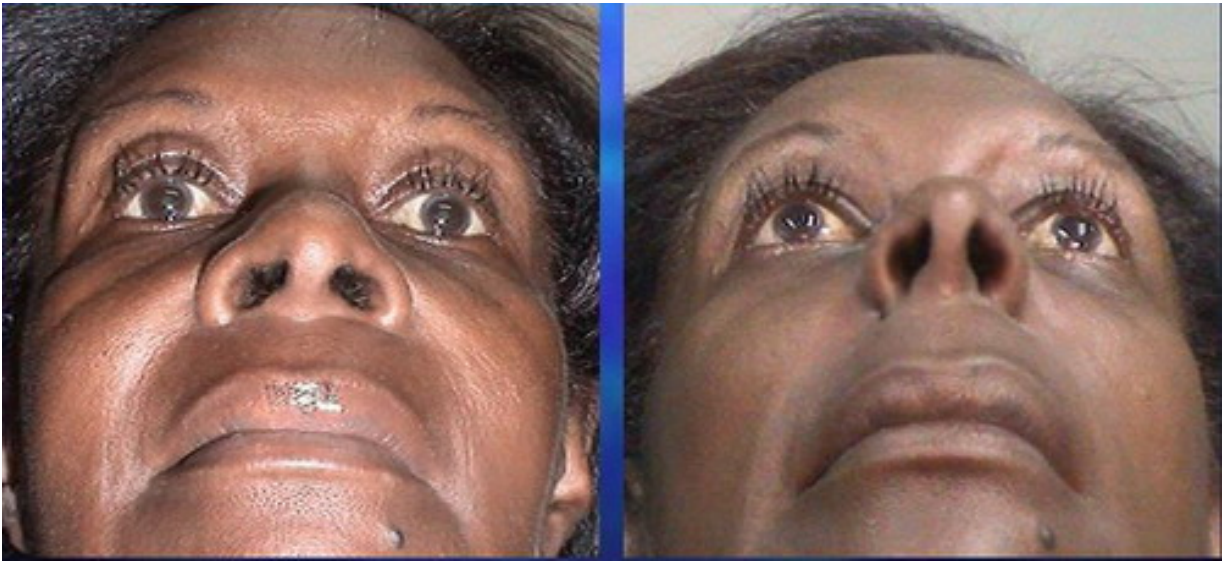

Figure 37. Before and after alar base narrowing in an Afro-American patient.

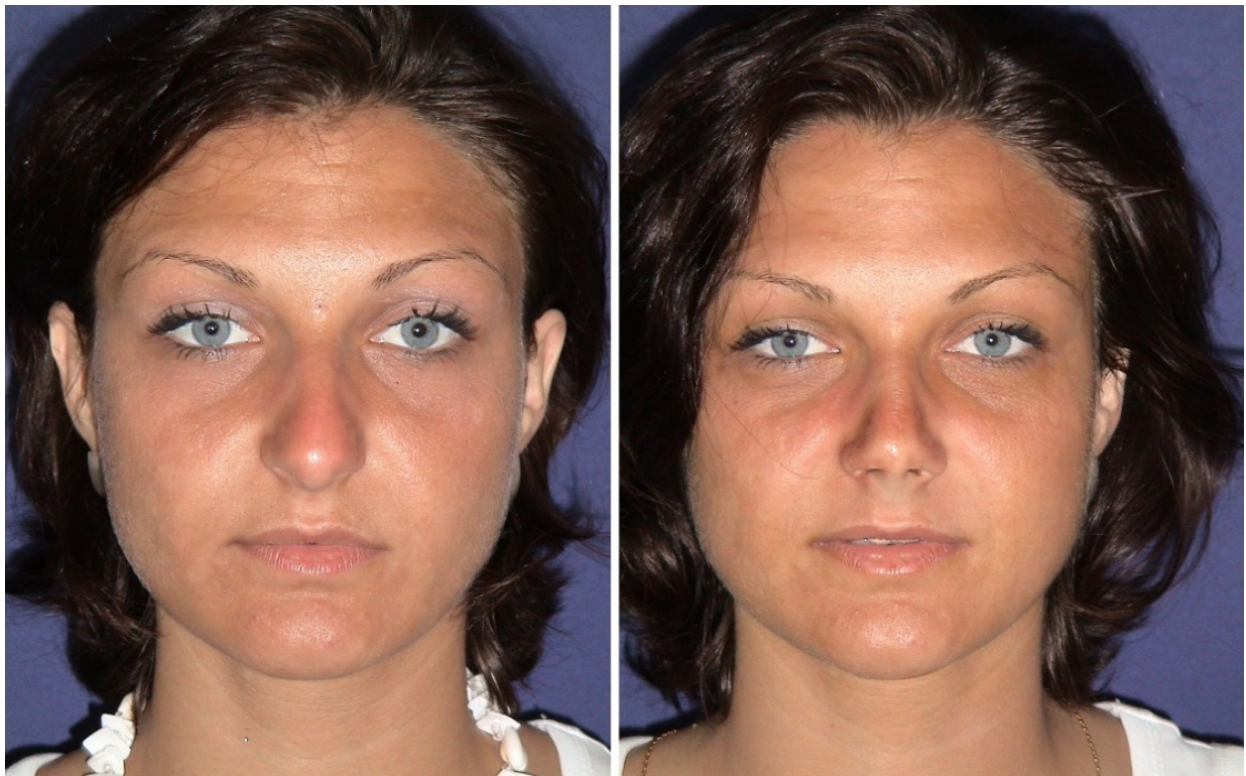

Figure 38. Tip rotation using T-excision and Columella sliding in a young Caucasian female to form the golden section rule (3 equal parts of the face) and obtain beautification. Tip refinement by suture is performed to reduce the volume of the tip.

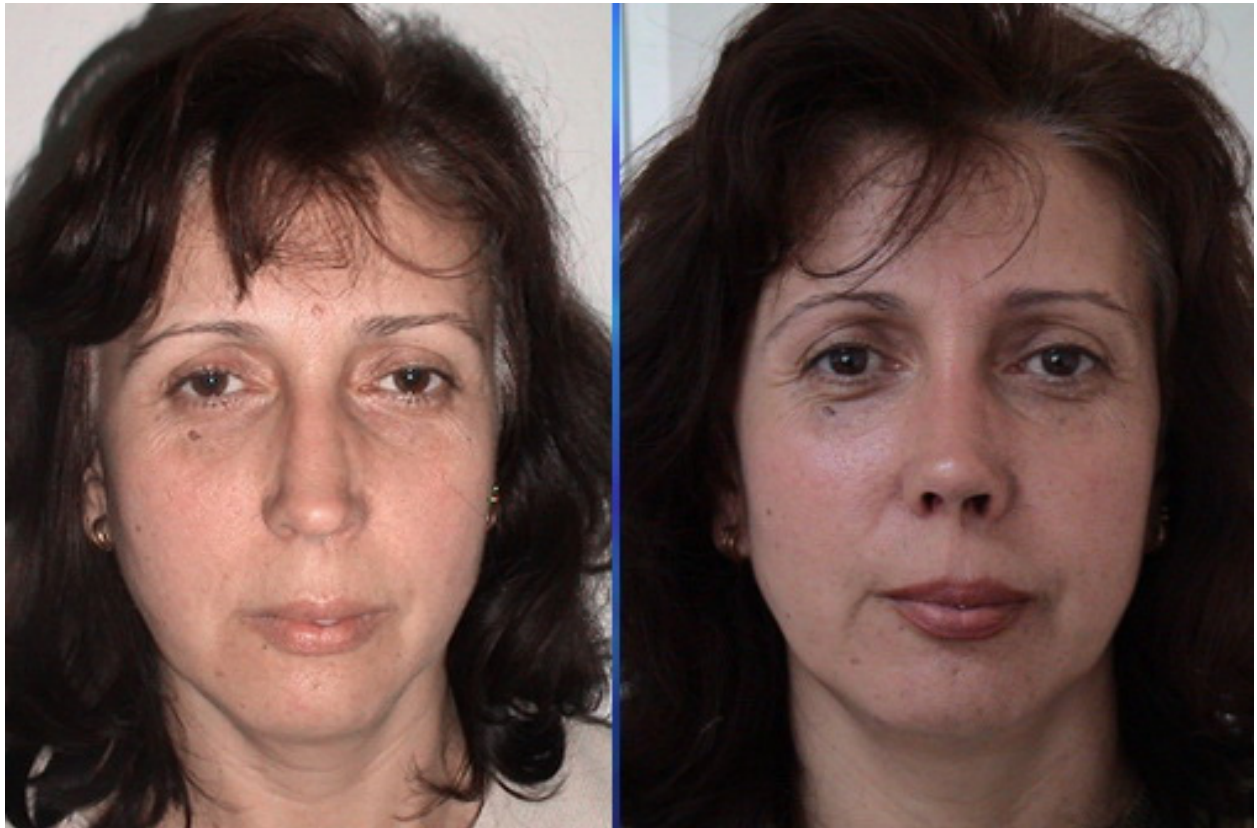

Figure 39. Tip Rotation and refinement by suture.

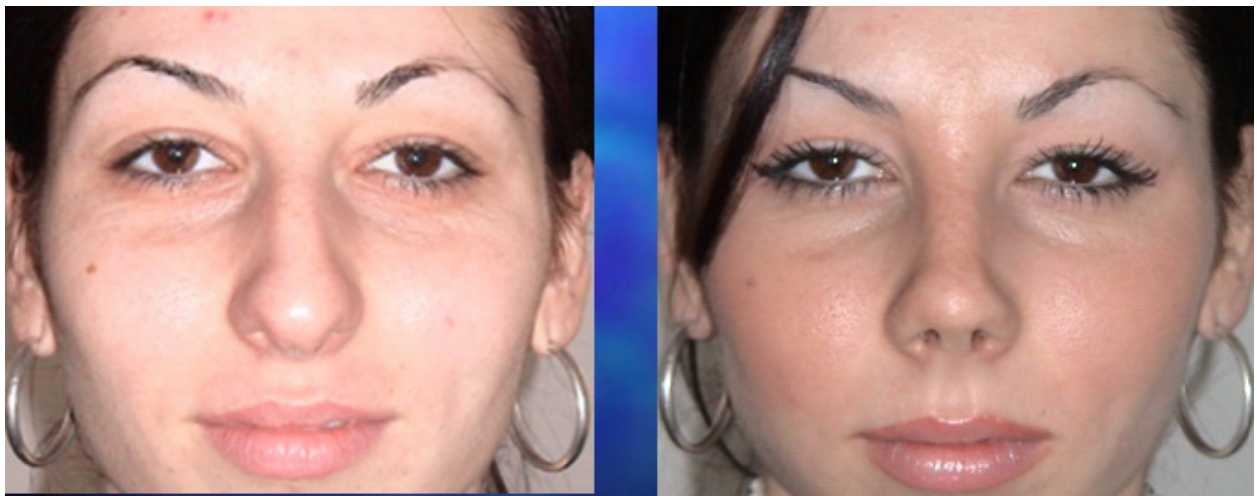

Figure 40. Nasal tip rotation, tip refinement and cheekbone lift. The nasal tip should be at the line of the cheekbones, otherwise it destroys the beauty triangle.

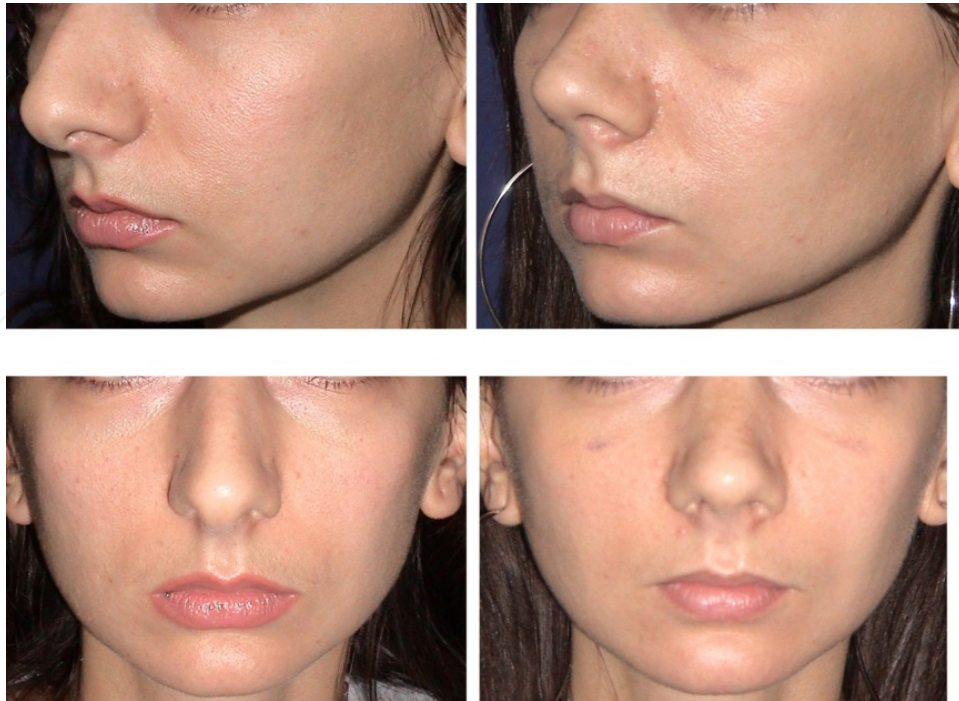

Figure 41. Nasal tip rotation for proportional beautification in a young patient. The hanging soft tissue and a shorter septum permits the tip lifting by suture.

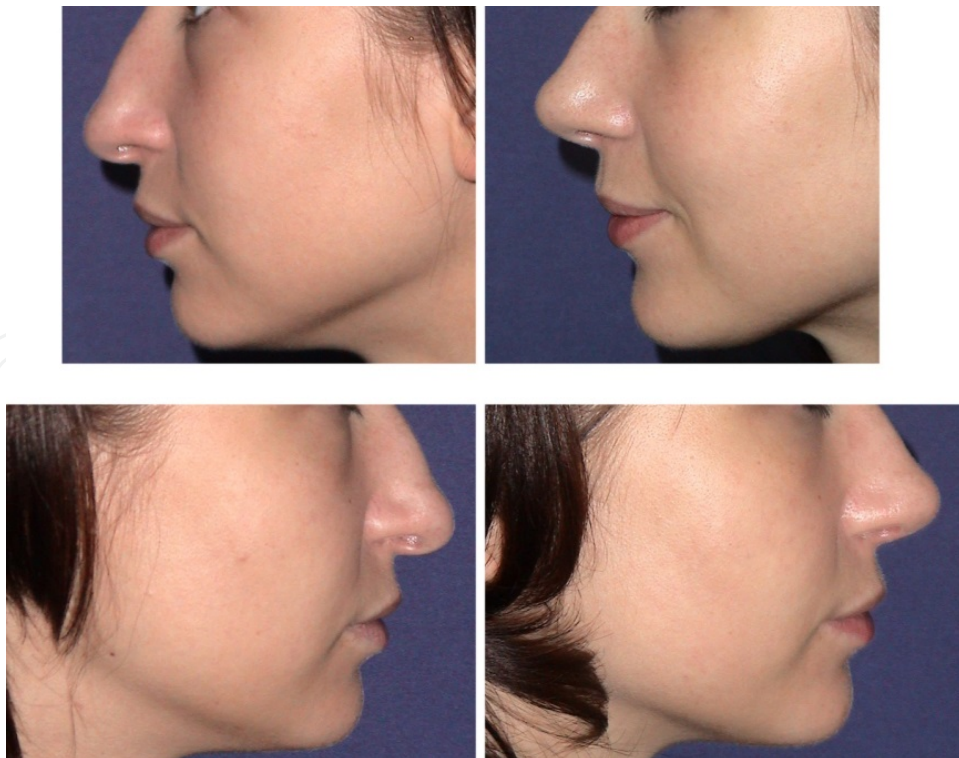

Figure 42. Nasal tip rotation for proportional beautification in a young patient. Location of the nasal tip at the line of the cheekbones.

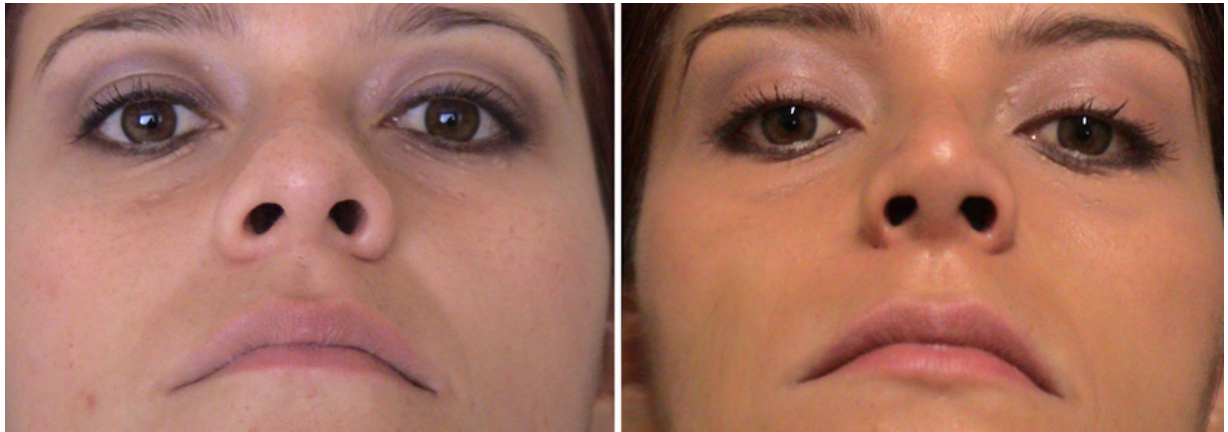

Figure 43. Before and after tip refinement and alar base narrowing in a Caucasian patient. Additional brow lift designs the brow.

Serdey Suture® techniques in rhinoplasty are time-saving, preventing trauma, with immediate results. The post-operative period is short, with no downtime, no or minimal bruising, immediate or prompt return to work and social life. No bandages are necessary.

Alar base narrowing is very important beautification in Afro-Americans and Asians. It provides refinement in Caucasian faces.

5. Scarless Serdev Suture® method in prominent ears

Various techniques have been proposed to correct prominent ears. The author presents a simplified method of auriculoplasty with sutures, by needle perforations only, without incisions. The key point of the operation is a line of sutures along the planed antihelix fold to transfix the fold at the antihelix tail, bending the scapha over the conchal cartilage to make the earlobe fall into place. The results are satisfactory, with a naturally looking antihelical fold.

This surgery is usually done to set prominent ears back, closer to the head, or to reduce the size of the visibly large ears. Prominent ears usually concern children from 4 to 14 years of age, but also adults. Non-suture techniques usually take about two to three hours, although complicated procedures may take longer. Most of the methods use incisions in the back of the ear. The cartilage is then sculpted. Occasionally, a piece of cartilage could be removed to provide a more natural-looking fold. Non-removable stitches are mostly used to help maintain the desired shape and position of the ear. Other techniques involve a similar incision in the back of the ear. Skin is removed and stitches are used to fold the cartilage back on itself to reshape the ear without removing cartilage.

Author's sutures without incisions offers a simplified method to suture cartilage on both sides from the desired fold, without the need to incise or excise skin or cartilage.

Anatomy

The most common deformity of the ear is the uni- or bilateral prominent ear. This deformity is caused by the lack of formation of the natural fold along the antihelix, a hypertrophied

concha or a combination of both. The auriculo-mastoid angle is normally 20–30° from the skull. The helical rim lies about 17–20 mm from the skull. The scapho-conchal angle is 90°, and if this angle is flattened, the ear appears protruding. The size and depth of the concha affect the deformity and the surgical technique for correction.

Aim

To pin the ears closer to the head, bring the ear elements into harmony, refine ear shape and reduce large elements.

Indications

Inferiority Complex, Personal Aesthetic Requirements and Needs.

Preliminary preparations and evaluation

Surgeon and parents should never insist on surgery until the child wants the change. Pre-operative evaluation includes clinical and photographical examination. Pre-operative photographs assist in the study and evaluation of the deformities and in making appropriate decisions. Photographs demonstrate the problem from many angles. Surgery on both ears could be suggested for balance, even if only one ear appears prominent.

Anesthesia

In all cases, the author uses local anesthesia in combination with i.v. sedation

Material and method

Twenty-five patients with prominent ears (without necessity of excision of a strip of the deep concha) were included in this study: 13 patients with unilateral protruding ears and 12 cases with bilateral prominent ears. Ages ranged between 5 and 35 years (15 females and 10 males).

Ear surgery was performed as an outpatient procedure. All the cases were operated under local anesthesia with adrenaline 1/1 000 000 injection of the posterior surface of the auricle. If anterior approach is necessary, local anesthesia is used subcutaneously in the specific area.

5.1. Surgical technique

The suture method aims to suture the cartilage on both sides of the desired antihelix fold, using skin punctures only.

The sutures were performed starting from the upper part of the tail to the lower end of the antitragus in order to disrupt the strongest point where the helix, antihelix and antitragus join.

Two 0,7-0,8 cm long parallel lines are marked on both sides of the planed antihelix fold - for example: A-B and A1-B1. If necessary, a row of additional sutures is planned, such as B-C and B1-C1, C-D and C1-D1 etc. In most Asians, Afro-Americans, Latino-Americans who have soft cartilages, as well as in some Caucasian kids, less sutures could be enough, but in stronger cartilages 3 and more sutures are usually necessary to bend the cartilage and form the desired fold. The lines A-B and A1-B1, B-C and B1-C1, C-D and C1-D1 etc. mark the

parallel subperihondreal transcartilagenous passes. The connecting lines between A-A1, B-B1, C-C1 and D-D1 are only subcutaneous to connect the transcartilagenous passes and bring them together. The length of the parallel transcartilagenous and connecting subdermal lines are pre-planned in respect of ear size and the desired result. Subcutaneous dissection in the area of the sutures can be done through the skin perforations, using Serdev® needles. To perform the technique, the author uses a Serdev® “mini-mini” needle, a USP 3/0 surgical suture and 4 skin perforations per suture in the posterior or anterior ear surface. The order of the passes depends on the surgeon (left or right handed), ear side, and surgeon skills. The author starts with a transcartilagenous needle pass - for example A-B, takes the suture end and positions the suture through the needle pass. After that he makes the 2 subcutaneous connecting passes to introduce both suture ends subcutaneously. Then, the second transcartilagenous pass A1-B1 is made at the other side to finalize the suture. When all sutures are done, the tightening of the knot should be done under elastic medium tension to adapt, but not to squeeze, cut or traumatize the cartilages.

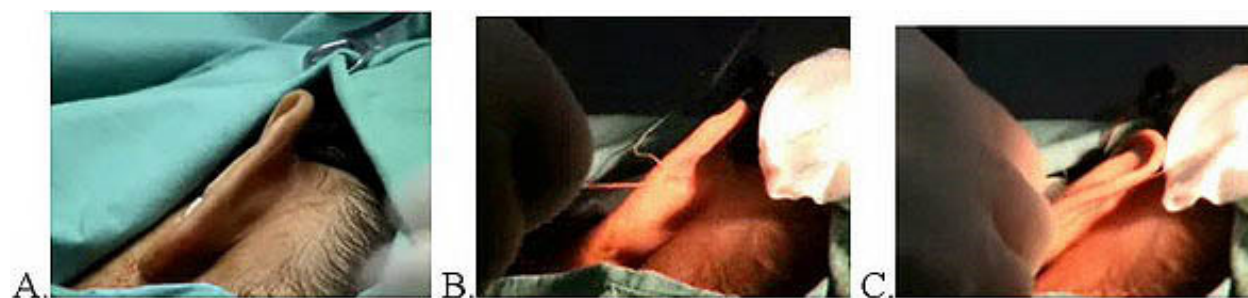

Figure 44. A. Before, B. The suture before being knotted, C. Knot is done under elastic tension and helix is rotated. The ear is pinned and the antihelix fold is now present.

Video: <http://www.youtube.com/watch?v=P73OgGYhzDQ>

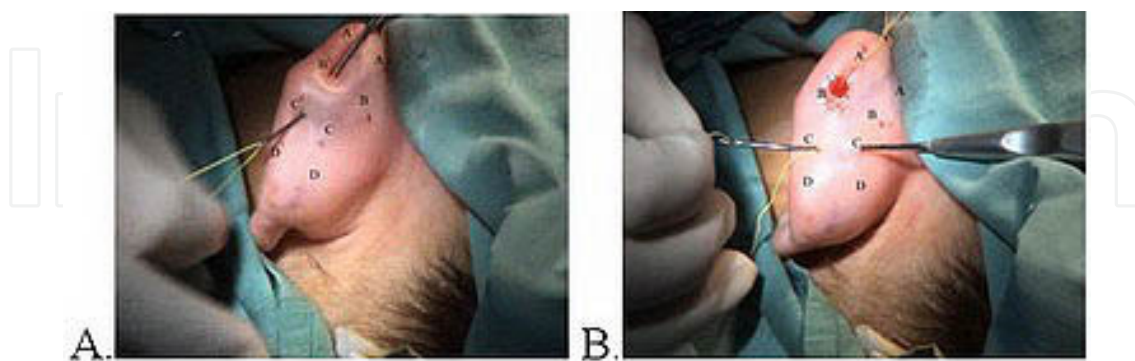
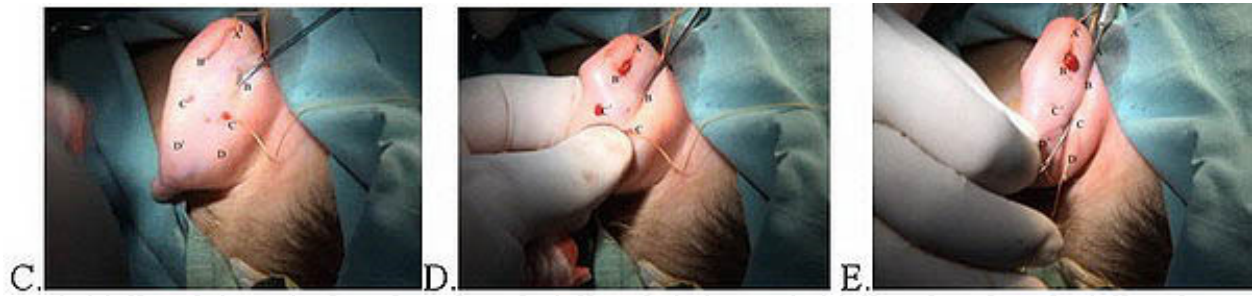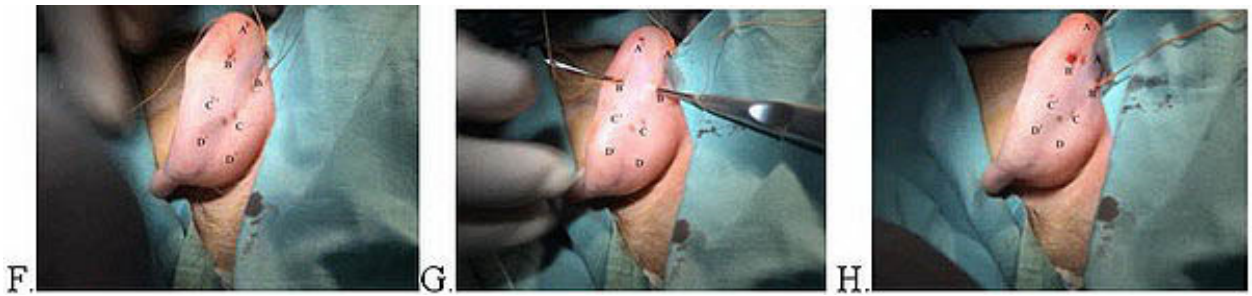


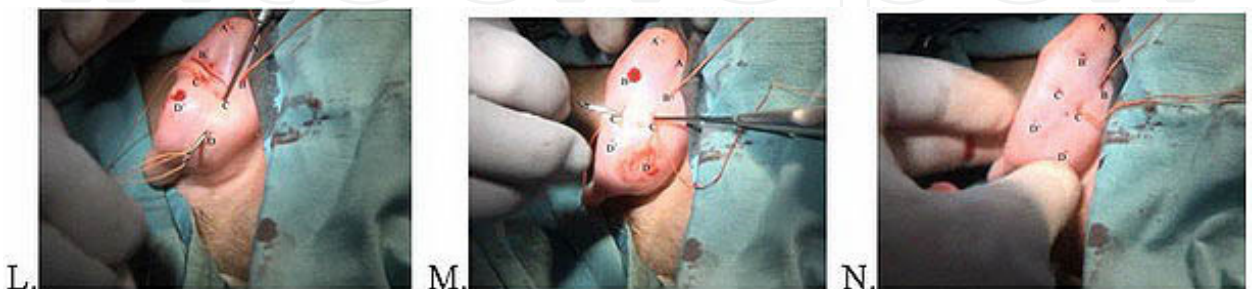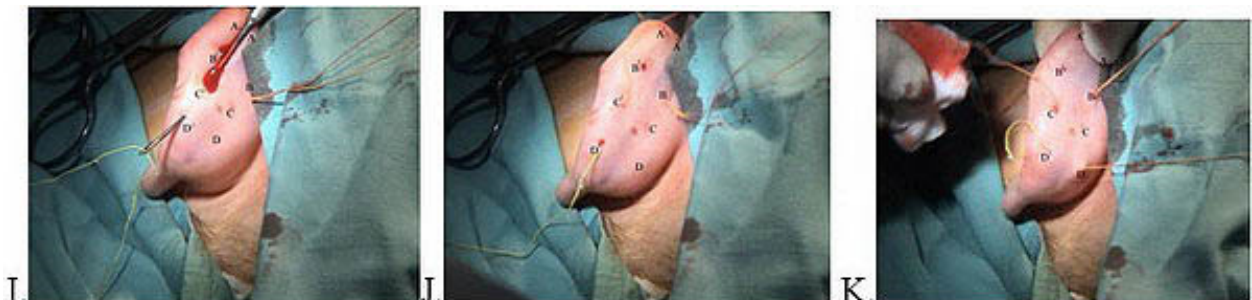Figure 45. A. The first suture A-A1(subdermal) - A1-B1(transcartilagenous) - B1-B (subdermal) – B-A (transcartilagenous) is finished and the suture ends are located at point A. The knot will be done when all sutures are finalized! The needle is located intracartilagenously in B1-C1, parallel to the future antihelix fold and the suture end is in the needle eye; B. The suture is introduced in the B1-C1 intracartilagenous plane and the needle is in the subdermal connecting line C-C1, in order to take the suture end;



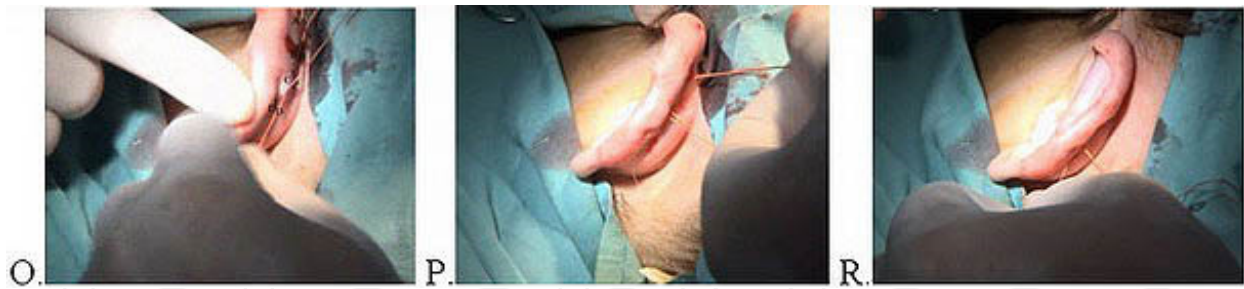C, D, E. The suture is introduced in the connecting subdermal line C1-C, and the next transcartilagenous B-C pass is done; C-B line;



F. The suture is introduced in the intracartilagenous line B-C, G. The needle is introduced in the subdermal connecting line B-B1; H. The suture end is taken in the connecting subdermal line B-B1 and the full circle of the suture – B-B1(subdermal), B1-C1(transcartilagenous), C1-C(subdermal), C-B(transcartilagenous) – is ready. Both suture ends are at point B.



I, J, K, L, M, N. Making the 3rd suture circle C-C1 (subdermal), C1-D1 (transcartilagenous), D1-D (subdermal), D-C (transcartilagenous)



O, P, R. All 3 suture circles are tightened under elastic tension, the anthelix fold is created, and the ear is pinned.

When all necessary sutures are done and tightened on both ears, symmetry is checked. Symmetry is usually obtained by the method itself. In 3 cases symmetry was perfected with additional suture on one side and in 2 cases with additional sutures on both sides. The prominent ears were corrected without incision or excision of skin from its posterior surface and without excision of cartilage. The anthelix was weakened by the line of sutures on its posterior surface and the anthelix fold was obtained successfully by the sutures only.

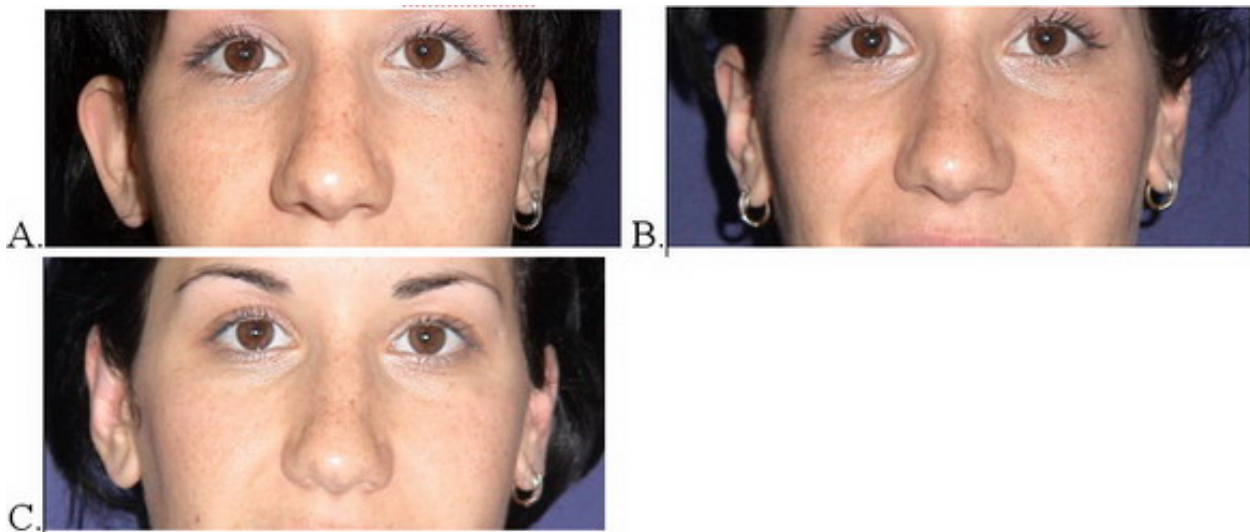


Figure 46. Before, B. Immediate result, C. Result after 2 years

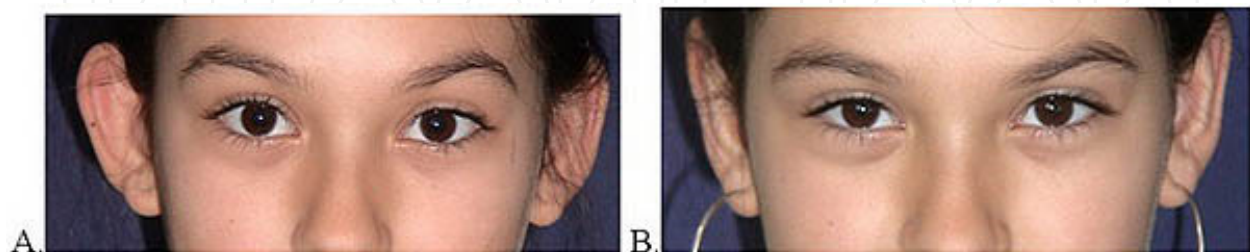


Figure 47. Before, B. Result after 30 months

All patients had no need or have refused excision of the concha. In 5 cases, where lowering of the concha was necessary, the author has performed sutures of the concha cartilages to the occipital periosteum or mastoid with a good result.

Anterior surface sutures were used in 6 easier cases, when patients asked for minimal corrections, in 2 cases of difficulties with the equality and in 2 cases of secondary corrections.

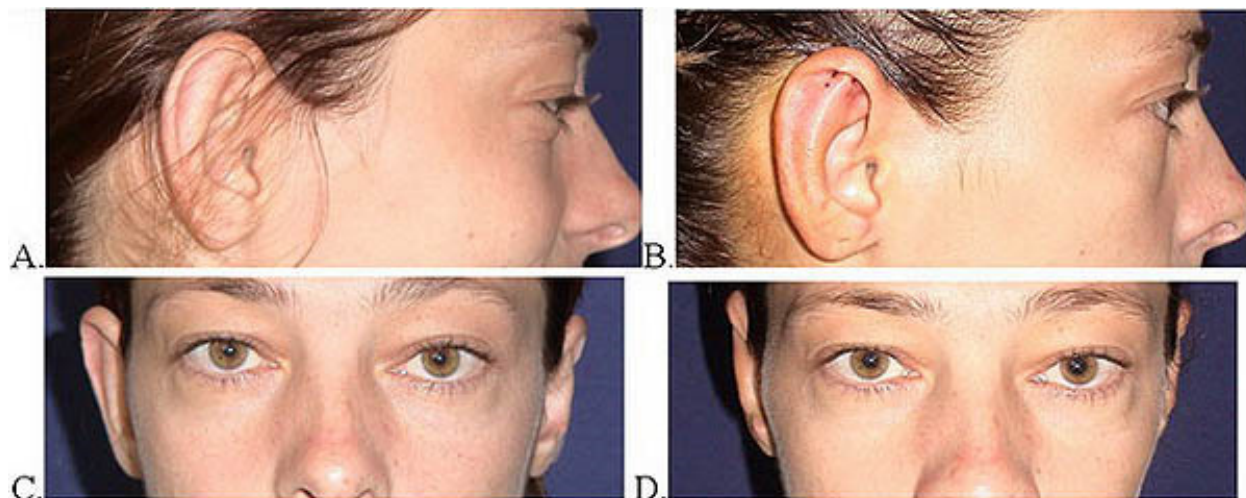


Figure 48. A suture is done on the right ear, on the anterior surface. A., C. Before, B., D. Result after 3 years.

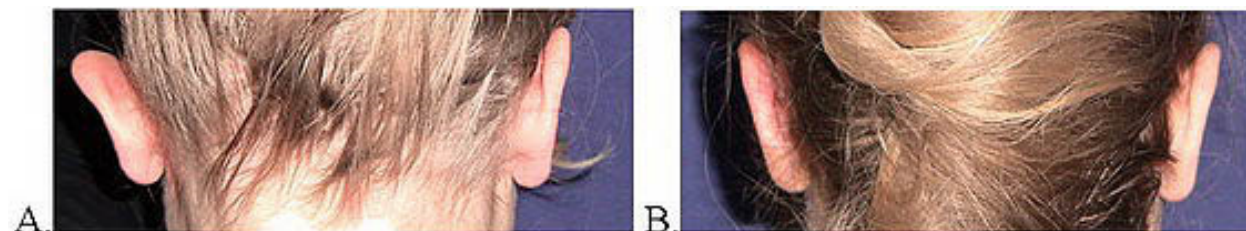


Figure 49. A. Before, B. Immediate result after suture. No wounds. Bandages can be used overnight. Patients are advised to carry an elastic band for a month.

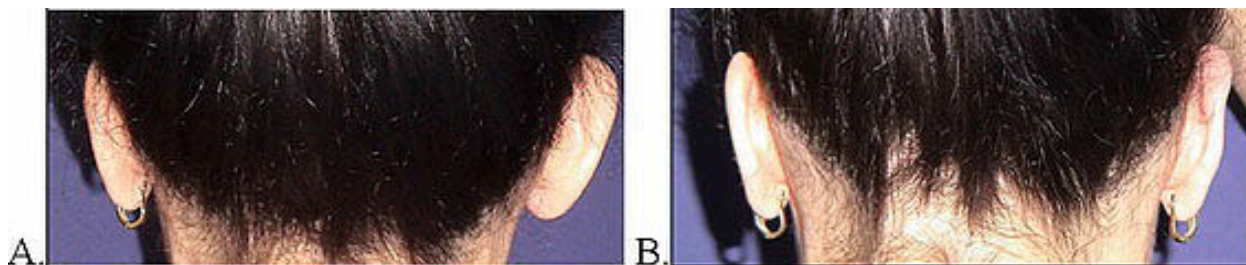


Figure 50. A. Before, B. Immediate result after suture. No wounds. Bandages can be used overnight. Patients are advised to carry an elastic band for a month.

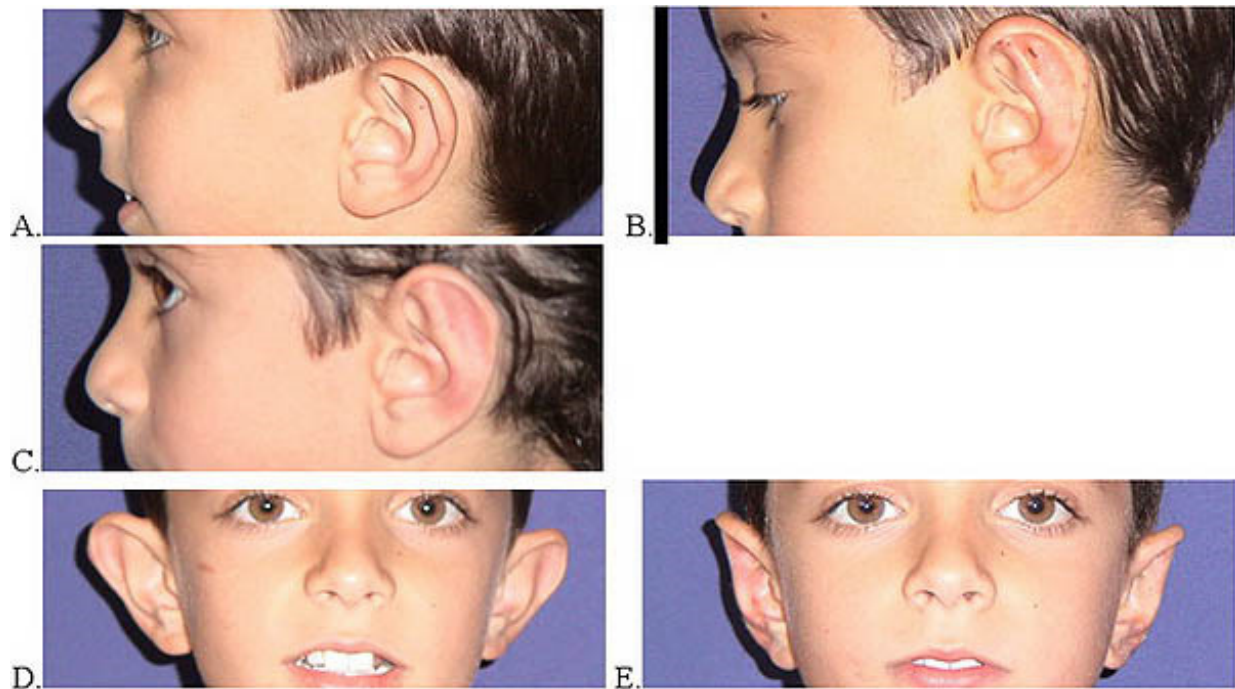


Figure 51. A, D. Before. B. Immediate result. An additional suture is done on the left ear from the anterior surface to fulfill equality of both ears. C, E. Result after 18 months

5.2. Results

Adults and children are usually up and around within half an hour after surgery.

Any activity in which the ear might be bent should be avoided for a month or so. Most adults can go back to work on the day after surgery. Children can return to school activities 2 to 3 days after the operation, if they are motivated and careful about playground activity.

The procedure was accepted very well both by children and adults and the results were described as very satisfying.

5.3. Complications

Complications are infrequent and usually minor. Nevertheless, as with any operation, there are risks associated with surgery and specific complications associated with this procedure. Incomplete correction of prominent ears is probably the most common and undesirable outcome in otoplasty. Hematomas or seromas can complicate recovery and should be managed as soon as possible. Hypertrophic scars or keloids may form along the incision line.

In his patients, the author has not observed hypertrophic scars or keloids. There were no seromas, no infection or blood collection.

Additional unilateral sutures (to complete aesthetic desire) were added in 3 patients, 4-6 months after the primary surgery. There have been no overcorrection or chondritis.

Additional sutures can be done at any time, with no downtime or loss of social contact and work time.

5.4. Discussion

The goal of the suture technique in auriculoplasty is improvement and beautification, but not perfection. Perfect symmetry is unlikely and unnatural in human body, including the ears. Both ears never match perfectly (Fig. 52, 53). Patient and parent expectations should be discussed before the operation.

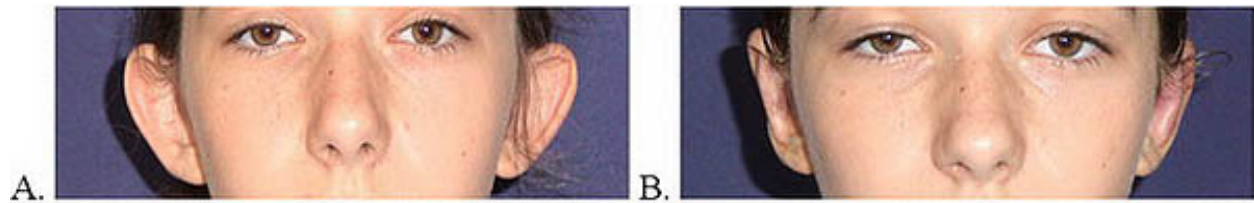


Figure 52. A. Before, B. Results after 3 years.

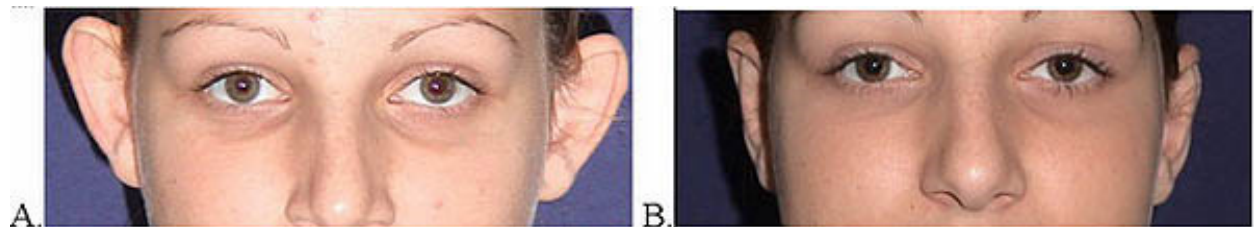


Figure 53. A. Before, B. Results after 3 years.

If the child is young, some surgeons may recommend general anesthesia, (the author uses local). For older children or adults, surgeons may prefer to use local anesthesia. Children who want the surgery and are motivated, cooperate better during the operation. The author has used local anesthesia, combined with intravenous sedation in all cases, and children do not remember the operation time.

The operation is mostly performed on children between the ages of four and fourteen. Ears are almost fully grown by age four. Ear surgery on adults is also possible and there are generally no additional risks. Discussion on state of the art techniques is always necessary like descriptions of the techniques such as Zplasty and Sandwich methods. In cases of inferiorly bulging concha an open surgery is suggested to correct the lobule and to maintain it posteriorly. In different techniques the auricle can be attached to the skull around the external meatus. Other authors use removal of cartilage where it is attached to the mastoid, with the aim of preventing the spring action of the auricle on the skull bone. The size of the concha will be taken into consideration for its correction and the proper evaluated size of cartilage to be excised.

Proper pre-operative evaluation is an essential step for satisfactory results. Not deviating from the decisions taken before the operation will avoid unnecessary excision that cannot be corrected later.

Good otoplasty makes the ears more proportional to the size and shape of the head and face.

The main function of the ear is hearing. Cosmetic ear surgery can reshape deformed or protruding ears and restore proportions.

Author details

Nikolay Serdev

New Bulgarian University, Sofia, Bulgaria

6. References

- [1] Serdev, N.P. Year 1994, Suture Suspensions For Lifting Or Volume Augmentation In Face And Body (English version), 2nd Annual Meeting of the National Bulgarian Society for Aesthetic Surgery and Aesthetic Medicine, Sofia, 18 March 1994, Int J Aesth Cosm, 2001,1:1, 2561-2568
- [2] Serdev, N.P. Forehead Subperiosteal Masklift in Combination with McIndoe Facelift Technique and Profile Correction. The 7th IPRAS Congress European Section, Berlin, Germany, June 2-5, 1993.
- [3] Serdev N.P. Temporal SMAS lift without skin excision In: Lip Augmentation During Mask and SMAS Lift Procedure, AAARS Annual Meeting, New Orleans, USA, October 5-9, 1994
- [4] Serdev, N.P. Temporal SMAS Lifting of the Face. Life Surgery Workshop. Unidad Medica Clinica Del Country, Bogota D.C., Colombia, November 8-10, 1999
- [5] Serdev, N.P. SMAS Lifting of the Face by Minimal Incisions – the Serdev Technique. Life Surgery Workshop, International Academy of Cosmetic surgery and the Balkan Academy of Cosmetic Surgery, Krilig Clinic in Caracas, Venezuela, November 12-18, 1999.

- [6] Serdev, N.P. Principles of Face Beautification, Ier Congresso Internacional de Cirurgia Cosmetica, Buenos Ares Argentina, 31 Octubre – 1 de Noviembre 1999
- [7] Serdev, N.P. Temporal SMAS lift, Lecture and Life surgery Workshop, 1st World Congress of Cosmetic Surgery with Life Demonstrations, Edsa Shangri-La Manila and Quezon City Medical Center, February 25-27, 2000.
<http://www.mpint.co.jp/apacs/Congress2000/con007.htm>
- [8] Serdev, N.P. Temporal SMAS Lifting of the Face, Combined with Liposuction and Chin Augmentation Using Suture. Life Surgery Workshop, Tel Aviv, Israel, April 20-24, 2000.
- [9] Serdev, N. P. Principles of face beautification, The 3-rd World Congress of ISAS, Tokyo, April 8-10, 2000, 9W58
- [10] Serdev, N.P. Lifting del SMAS con Una Pequenna Incision Temporal, VIIIas Journadas Mediterraneas de Confrontaciones Terapeuticasen Medicina y Cirurgia Cosmetica, Sitges, Barcelona, March 16-19, 2000
- [11] Serdev, N.P. Facial Rejuvenation by Minimal Skin Incisions, International Congress "Refinements in Aesthetic Surgery" Oradea, Romania, June 22-24, 2000
- [12] Serdev, N.P. Ambulatory Temporal Smas Lift By Minimal Hidden Incisions, Int J. Cosm. Surg.2001;1 (2):20 - 27
- [13] Mittelman H, Newman J. Smasectomy and imbrication in face lift surgery. Facial Plast Surg 2000 May; 2: 173-82.
- [14] De la Fuente A, Santamaria AB Endoscopic subcutaneous and SMAS facelift without preauricular scars.Aesthetic Plast Surg1999 Mar-Apr; 23: 119-24.
- [15] Maloney BP, Schiebelhoffer J. Minimal-incision endoscopic face-lift. Arch Facial Plast Surg 2000 Oct-Dec; 4: 274-8.
- [16] Hagerty RC, Scioscia PJThe medial SMAS lift with aggressive temporal skin takeout. Plast Reconstr Surg 1998 May; 101 (6):1650-6
- [17] Mitz, V, Peyronie M. The superficial musculoaponeurotic system (SMAS) in the parotid and cheek area. Plast. Reconstr. Surg. 1976; 58: 80.
- [18] Cardoso de Castro, C. The role of the superficial musculoaponeurotic system in face lift. Ann. Plast. Surg. 1986; 16: 276.
- [19] Kameer FM, Frankel SMAS rhytidectomy versus deep plane rhytidectomy: an objective comparison.ASPlast Reconstr Surg 1998 Sep; 102 (3): 878-81.
- [20] Hamra ST. The tri-plane face lift dissection. Ann Plast Surg 1984 Mar; 12 (3): 268-74.
- [21] Hamra ST. The deep-plane rhytidectomy. Plast Reconstr Surg 1990 Jul; 86 (1):53-61.
- [22] Hamra ST, Composite rhytidectomy.Plast Reconstr Surg, 1992 Jul; 90 (1): 1-13.26.
- [23] Mitz V, Use of deep planes in surgery of rejuvenation of the face Chirurgie 1991; 117 (4): 278-86.
- [24] Ramirez OM, Maillard GF, Musolas A. The extended Subperiosteal Face lift: A definitive Soft-tissue Remodeling for Facial Rejuvenation. Plast Reconstr Surg 1991; 88:227-36.
- [25] Bonnefon A Deep "en bloc" facial lift" Ann Chir Plast Esthet 1992 Jan; 37 (1), 85-94

- [26] Bonnefon A. Deep vertical lift and its development regarding the central facial area and lower two-thirds of the neck. Our technique, *Ann Chir Plast Esthet*, 1999 Dec: 609-16.
- [27] Teimourian B, Delia S, Wahrman A, The multiplane face lift. *Plast Reconstr Surg* 1994 Jan 93; 1: 78-85.
- [28] Stuzin, J. M., Baker, T. J., Gordon, H. L., and Baker, T. M. Extended SMAS dissection as an approach to midface rejuvenation. *Clin. Plast. Surg.* 1995; 22: 295.
- [29] Quatela VC, Sabini P. Techniques in deep plane face lifting. *Facial Plast Surg* 2000 May; 2: 193-209.
- [30] Bosse, J. P., and Papillon, J. Surgical Anatomy of the SMAS at the Malar Region. In *Transactions of the 9th International Congress of Plastic and Reconstructive Surgery*. New York: McGraw-Hill, 1987: 348.
- [31] Miura Y, Moura PD, Ramasastry S, Hochberg J. Can we simplify the nomenclature of the fascial layers of the temporo parietal region? *Online J Plast Reconstr Surg*, Nov 1997;1: 1.
- [32] Stuzin JM, Wagstrom L, Kawamoto HK, Wolfe SA. Anatomy of the frontal branch of the facial nerve: The Significance of the Temporal Fat Pad. *Plast Reconstr Surg* 1989; 83: 265-71.
- [33] Hochberg J, Kaufman H, Ardenghy M. Saving The Frontal Branch during a Low Fronto-orbital Approach. *Aesth Plast Surg* 1995; 19: 161-163.
- [34] Barton, F. E., Jr. The SMAS and the nasolabial fold. *Plast. Reconstr. Surg.* 1992; 89: 1054.
- [35] Serdev N. Auriculoplasty Serdev Suture, *Int J Cosm Surg* 2000, Video time: 24:30 min. | Screen Size: 320 x 240 | File size: 36.2 | File Name: auriculoplasty_serdev_suture.wmv
- [36] Serdev N., Auriculoplasty for beautification – a post-congress workshop, Asia Pacific Craniofacial Association. Third Conference, Shanghai, P.R. China, Oct. 30th – Nov. 1st, 2000
- [37] Serdev N. Principles of Face Beautification, *XIas Jornadas Mediterraneas De Confrontaciones Terapeuticas En Medicina y Cirugia Cosmetica*, 21-25. 03. 2001,
- [38] Serdev, N.P. Scarless Serdev Suture Method In Prominent Ears (Bulgarian), Original Papers, *Int J Aesth Cosm* 2009, 9:4, 1-9
- [39] Barcelona 1. A.J. McDowell, Goals in otoplasty for protruding ears, *Plast. Reconstr. Surg.* 41 (1968) 17.
- [40] Madzharov, M.M. A new method auriculoplasty for protruding ears, *Br. J. Plast. Surg.* 42(285) (1989) 290.
- [41] Davis, J, *Otoplasty: Aesthetic and Reconstructive Techniques*, Springer-Verlag New York, Incorporated, 1997/05
- [42] Sainz Arregui1 J., R. Gaviria1, R. San Sebastian1, F. Ezquerro1 and M. Berrazueta1. Aesthetic otoplasty: the key point
- [43] Hoda Saleh, Hassan Mostafa. Otoplasty for the prominent ear. *Plastic and reconstructive surgery International Congress Series* 1240 (2003) 603–605
- [44] Ely ET: An operation for prominence of the auricles. *Arch Otol* 1881;10:97-99.

- [45] Luckett WH: A new operation for prominent ears based on the anatomy of the deformity. *Surg Gynecol Obst* 1910;10:635-637.
- [46] Mustarde JC: The correction of prominent ears using simple mattress sutures. *Br J Plast Surg* 1963 Apr; 16: 170-8[Medline].
- [47] Sternstroem SJ: A "natural" technique for correction of congenitally prominent ears. *Plast Reconstr Surg* 1963 Nov; 32: 509-18[Medline].
- [48] Wright WK: Otoplasty goals and principles. *Arch Otolaryngol* 1970 Dec; 92(6): 568-72[Medline].
- [49] Furnas DW: Correction of prominent ears with multiple sutures. *Clin Plast Surg* 1978 Jul; 5(3): 491-5[Medline].
- [50] Romo T 3rd, Sclafani AP, Shapiro AL: Otoplasty using the postauricular skin flap technique. *Arch Otolaryngol Head Neck Surg* 1994 Oct; 120(10): 1146-50[Medline]. 13. Adamson PA, Strecker HD: Otoplasty techniques. *Facial Plastic Surgery* 1995; 11: 284-300.
- [51] Janis JE, Rohrich RJ, Gutowski KA: Otoplasty. *Plastic and Reconstructive Surgery* 2005; 115: 60e-72e[Medline].
- [52] Serdev N. Auriculoplasty Serdev Suture, *Int J Cosm Surg* 2000, Video time: 24:30 min. | Screen Size: 320 x 240 | File size: 36.2 | File Name: auriculoplasty_serdev_suture.wmv
- [53] Behmand RA, Ghavami A, Guyuron B. Nasal tip sutures, part I: the evolution. *Plast Reconstr Surg*. 2003;112(4):1125-1129, discussion 1146-1149.
- [54] Tebbetts JB. Shaping and positioning the nasal tip without structural disruption: a new, systematic approach. *Plast Reconstr Surg*. 1994;94(1):61 -77.
- [55] Mocella S, Bianchi N. Double interdomal suture in nasal tip sculpturing. *Facial Plast Surg*. 1997;13(3):179-196.
- [56] Baker SR. Suture contouring of the nasal tip. *Arch Facial Plast Surg*. 2000;2(1): 34-42.
- [57] Leach JL, Athre RS. Four suture tip rhinoplasty: a powerful tool for controlling tip dynamics. *Otolaryngol Head Neck Surg*. 2006;135(2):227-231.
- [58] Tardy ME, Cheng E. Transdomal suture refinement of the nasal tip. *Facial Plast Surg*. 1987;4(4):317-326.
- [59] Papel ID. Interlocked transdomal suture technique for the wide interdomal space in rhinoplasty. *Arch Facial Plast Surg*. 2005;7(6):414-417.
- [60] Daniel RK. Rhinoplasty: a simplified, three-stitch, open tip suture technique, part I: primary rhinoplasty. *Plast Reconstr Surg*. 1999;103(5):1491-1502.
- [61] McCollough EG, English JL. A new twist in nasal tip surgery: an alternative to the Goldman tip for the wide or bulbous lobule. *Arch Otolaryngol*. 1985;111 (8):524-529.
- [62] Daniel RK. Rhinoplasty: creating an aesthetic tip: a preliminary report. *Plast Reconstr Surg*. 1987;80(6):775-783.
- [63] Kridel RW, Konior FJ, Shumrick KA, Wright WK. Advances in nasal tip surgery: the lateral crural steal. *Arch Otolaryngol Head Neck Surg*. 1989;115(10):1206-1212.
- [64] Pastorek NJ, Becker DG. Treating the caudal septal deflection. *Arch Facial Plast Surg*. 2000;2(3):217-220.

- [65] Gruber RP, Friedman GD. Suture algorithm for the broad or bulbous nasal tip. *Plast Reconstr Surg.* 2002;110(7):1752-1764, discussion 1765-1768.

IntechOpen

IntechOpen