

We are IntechOpen, the world's leading publisher of Open Access books Built by scientists, for scientists

6,900

Open access books available

185,000

International authors and editors

200M

Downloads

Our authors are among the

154

Countries delivered to

TOP 1%

most cited scientists

12.2%

Contributors from top 500 universities



WEB OF SCIENCE™

Selection of our books indexed in the Book Citation Index
in Web of Science™ Core Collection (BKCI)

Interested in publishing with us?
Contact book.department@intechopen.com

Numbers displayed above are based on latest data collected.
For more information visit www.intechopen.com



T3 - Soft Face Lift by Suspension Surgery

Pier Antonio Bacci

Additional information is available at the end of the chapter

<http://dx.doi.org/10.5772/56710>

1. Introduction

Surgical strategy using barbed or not barbed threads is now an asserted truth with numerous and official follow-up and experiences. These strategies are named as “mini invasive aesthetic methodologies” because provide for good results with little incisions and few complications

Today there are many different mini-invasive surgical techniques available, using different kinds of surgical suspension threads. All of these are due to four main authors: Guilleman, Sulamanidze, Serdev and Ruff.

2. The Guilleman technique

This is the basic technique known and published under the name of “*Curl Lift*” and is certainly the mother of all the other methods used.

It is the simplest and most intelligent method to lift the relaxed tissues with simple and everyday used surgical threads, absorbable or not. (Fig. 1)

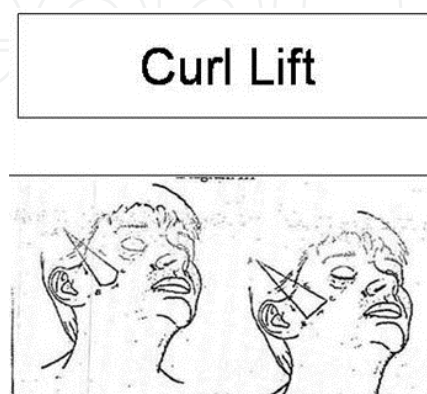


Figure 1. The initial idea of the Curl Lift

3. The Sulamanidze technique

This method uses a particular surgical thread with barbs, like opposing ears of wheat, thanks to which the threads support themselves in the tissue.

The criticism that can be made about this technique is the fact that the calibre of the needle-cannula used to introduce the thread into the tissue is greater than the thread itself, which can cause some difficulties in hooking the barbs and easy bruising. Finally, this method may be sometime as no long-lasting as the others. It can be very useful in some mini-invasive corrections of the face, such as of the eyebrows or neck. (Fig. 2)

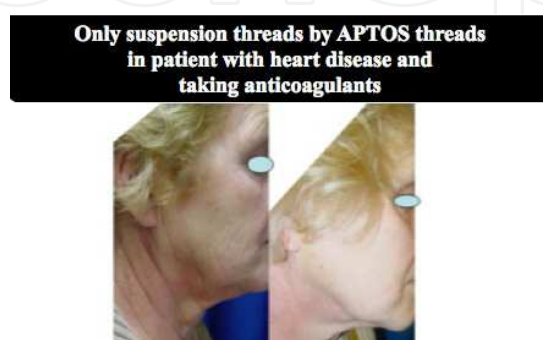

Figure 2. Mini invasive treatment of the neck with original Russian APTOS threads in a subject with heart disease taking Acenocumarol (*Bacci archive*)

4. The Serdev technique

Starting from French surgeons Galland and Clavier, the Bulgarian cosmetic surgeon Nikolay Serdev uses special semi-elastic threads with long-term absorption, along with special needles of his direct invention and preparation that are used to fix the tissues to solid or fixed structures.

In our experience this method has had almost always good results in various aesthetic pathologies, especially for outlining ill-defined cheekbones and the chin line, thanks to the possibility of creating tobacco-pouch sutures that allow us to define the outlines. (Fig. 3-4)

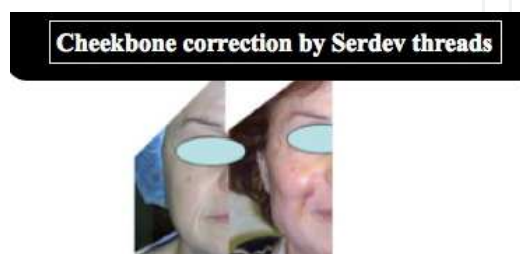

Figure 3. Definition of the cheekbones with Serdev threads (*Bacci archive*)

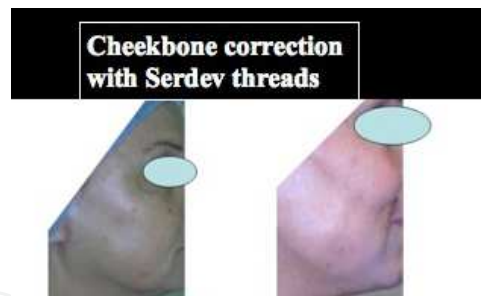

Figure 4. Definition of the cheekbones with Serdev threads (*Bacci archive*)

This is the ideal methodology for increasing volume and projecting the tissues without prostheses, for cheekbones, chin, breasts or buttocks, of course, in selected cases.

5. The Ruff method

This strategy has certainly represented a new era in cosmetic surgery as it is the first methodology officially approved by the FDA for rejuvenation of the face and neck using unidirectional barbed threads.

It is an effective mini-invasive strategy offer us good results. It uses barbed not-adsorbable one-directional threads introduced by special needles and a method that offers the concrete possibility of creating a true anchor point for the thread, thus becoming similar to a track upon which the skin slides and is anchored, thanks to the unidirectional barbs that are arranged in a spiral shape, guaranteeing its strong hold on the tissues. (**Fig. 5**)

Typical arrangement of the barbs




Figure 5. Typical spiral arrangement of the unidirectional barbs. (*Bacci Archive*)

Typical characteristic of these barbed surgical threads is the possibility to lift-up all part of the tissue, particularly midface, neck and eyebrow, or the cutaneous layer that the adipose-muscular deep wraps.

To conclude, we have today four basical mini invasive strategy by threads, according to Guilleman, Sulamanidze, Serdev and Ruff, we can use different strategies, in integrate methodology too, on respect to different indications.

6. T3 - Soft Lift

In 2001 we began our first experiences with the integration of two methods, suspension threads and surgical soft lift.

We started with unidirectional, barbed absorbable surgical threads we made by hand in the operating room using a simple method with a monofilament. Our experience then developed particularly while observing their capacity to form a temporary tissue fibrosis along the thread's path in 8-12 weeks' time.

This is how we started the mini-invasive method we call "*T3-Soft Face Lifting*", meaning "*Traction Threads Treatment*", or a treatment that uses the traction on surgical threads to lift the tissues, avoiding more extensive dissection, in one or more sessions.

Basically, this strategy consists of two mini-invasive surgical sessions done with local anaesthesia.

- *1st session* - The purpose of this procedure is to introduce the barbed unidirectional "polypropylene" suspension threads using particular carriers that adapt to the various positioning needs of the different suspension threads. (Fig. 6)

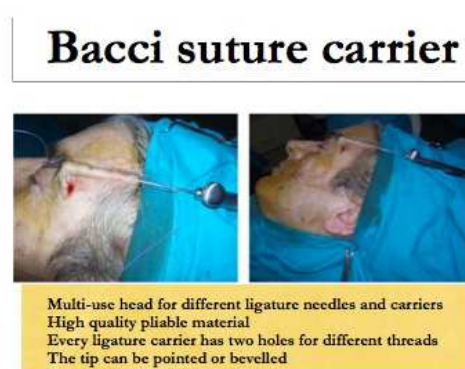


Figure 6. Bacci's instrument for introducing threads – (Bacci Archive)

Depending on need or the skin to be eliminated, an incision can also be made (as small as possible) along the classical lines in front of or behind the ear, in the frontotemporal area, then the smallest dissection necessary is done to traction the SMAS, doubling it or creating a small flap.

Then a typical vertical mini-lift is done, but using the traction of the threads, therefore avoiding tissue dissection and complications. (Fig. 7)

Suspension threads + mini-lift

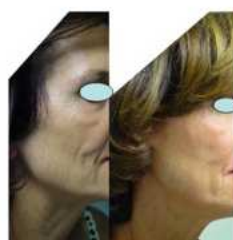

Figure 7. Suspension threads and mini-face lift (Bacci Archive)

In patients requesting or needing greater traction or greater excision of skin tissue we can also associate a more ample lift, lifting both the temporal region and the midface and neck, thus reconstructing a better triangle of youth, and still limiting dissection thanks to the use of unidirectional barbed threads or of Serdev's circular method. (Fig. 8)

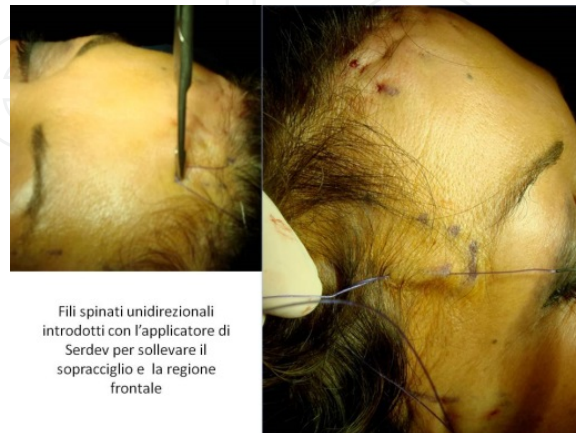

Figure 8. Suspension threads and superior blepharoplasty using Serdev Methodology (*Archive Bacci*)

Normally, in this first session lipofilling is associated with the suspension threads, allowing the tissue metabolism to activate thanks to the hormonal impulse given by the autologous fat tissue inserted into the tissue.

The suspension thread and fatty tissue association (*T3-Fat Lift*, or *stabilised lipofilling*) has a particular importance since it favours metabolic recovery of the tissues and vascularization of the cells of the fatty tissue injected, thus prolonging its life and active stay in the tissue.

Sometimes we also perform a superior blepharoplasty in this first session in order to increase eye brightness.

-2nd session - When it is necessary, the second session is as a rule done after 2-3 years, it allows stabilization of the results and offers new traction without dissection. A small incision with local anaesthesia is sufficient to pick up, by Muller's hook for microvarices, the old thread which will be pulled and sutured to the fascia with a 5/0 nylon thread, in a new position.

Method

Usually, four or six non-absorbable unidirectional barbed threads are applied for side. They allow traction of the tissues, thus limiting dissection. Then a semi-circular or "S" incision is done, separating the layer as little as possible and locating the threads in place we traction on them and work the SMAS which is duplicated with suture, when it's necessary. (Figs. 9-10)

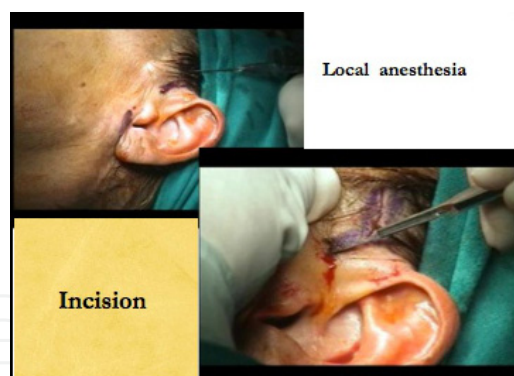

Figure 9. After a little local anaesthesia we traction the tissue and SMAS pulling the threads that hook onto the tissue, and then we suture. (*Bacci Archive*)

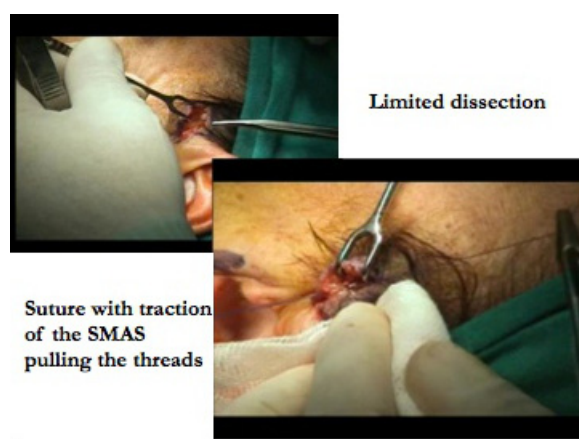


Figure 10. After a little local anaesthesia we traction the tissue and SMAS pulling the threads that hook onto the tissue, and then we suture. (*Bacci Archive*)

After this phase the excess skin is cut and then sutured, following the same traction path of the threads if possible and doubling the tissue for better harmony of the neck, within the same amount of operating time. (**Fig. 11**)

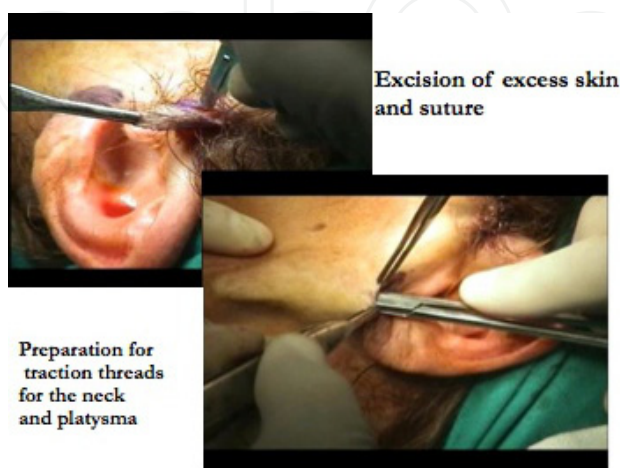

Figure 11. Skin excision and traction on the tissues of the neck. (*Bacci Archive*)

We then move on to reshaping the outlines and volumes of the face in the naso-labial, zygomatic areas, of the cheeks and chin with “rice grain” lipofilling, after taking fatty tissue from the abdomen and periumbilical area, where it guarantees greater resistance to possible initial deficits in vascularization. Usually this fatty tissue is reinserted directly without altering it or traumatizing it. **(Fig. 12)**

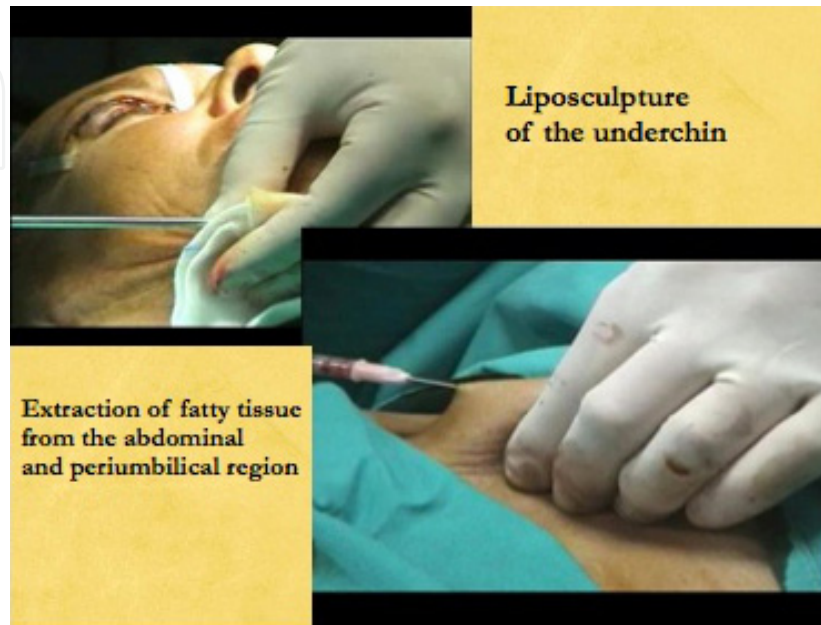

Figure 12. Our micro-cannulae for mini-liposculpture and for extracting fatty tissue, which can also be done with a simple needle, even if more traumatic. *(Bacci Archive)*

Fill - traction

Today, we have more than twenty years of experience with Sulamanidze and Serdev's methods, and we have ten years of experience with unidirectional absorbable or not-absorbable barbed threads, which are used to have a new position of the tissues and to activate processes of bio-stimulation, in particular with surgical threads absorbables by hydrolytic way, such as polydioxanone (PDO). **(Fig.13)**

Currently, thanks to the changing demands of patients seeking rejuvenation of the face even before the age of 40, methodologies are greatly reduced and they are absolutely minimally invasive.

We have reduced the incisions with small lines between the tragus or hidden in the hair or behind the ear. Were reduced detachments of the skin, as results have been virtually eliminated hematoma and major complications. **(Fig.14 - 15)**

The words "Fill-Traction" means a mini-invasive strategy that uses in the same session a Prolene 2/0 not-absorbable unidirectional barbed threads for side, both in the temporal region that in the midface.

In the same session we can apply unidirectional absorbable barbed threads to maintain the position of the skin and improve the contours in the same time.

T3 – Soft Face Lifting

so the use of thread's traction to have a new position of the tissues (reducing tissue's separation)

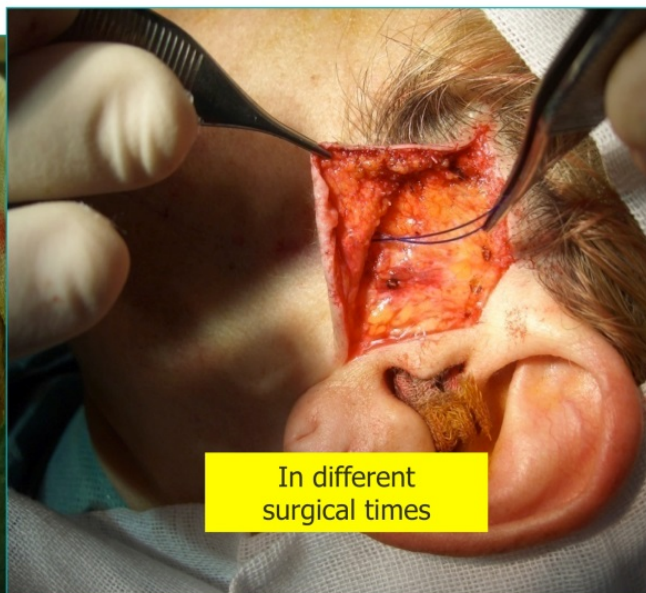
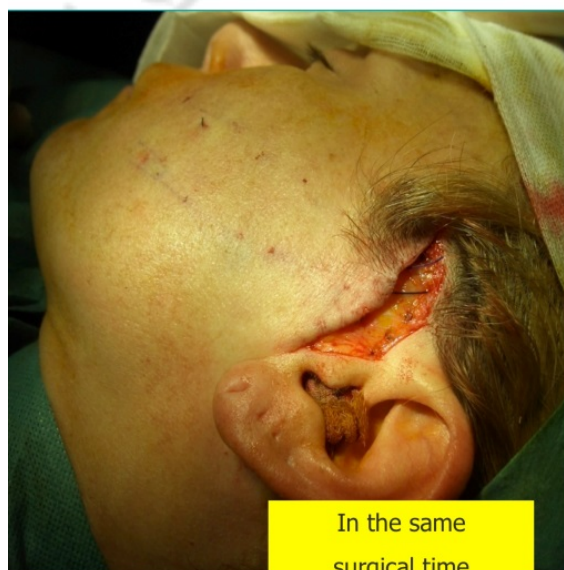
Figure 13. T3 –soft face lift (*Bacci Archive*)

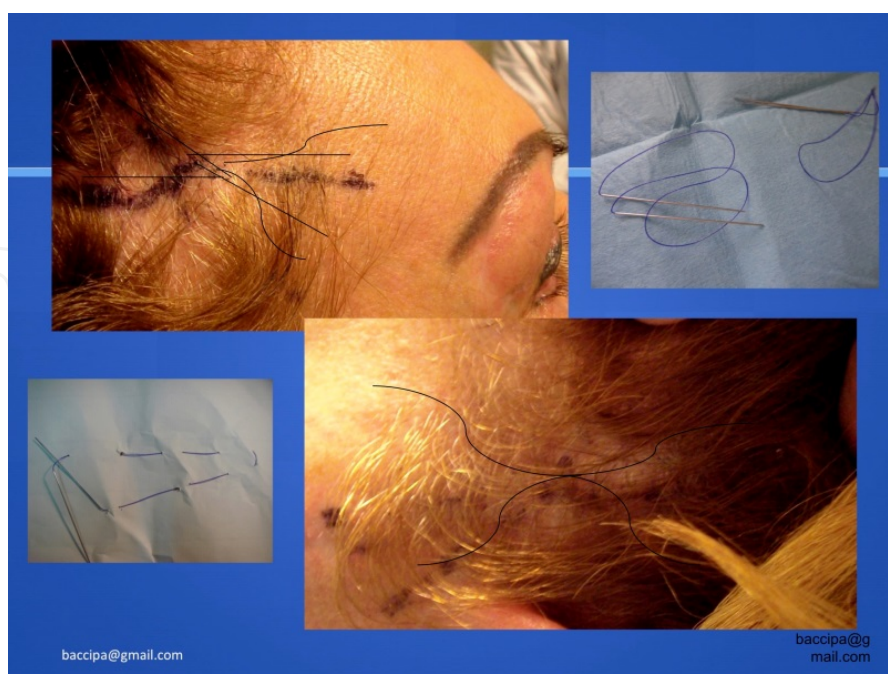
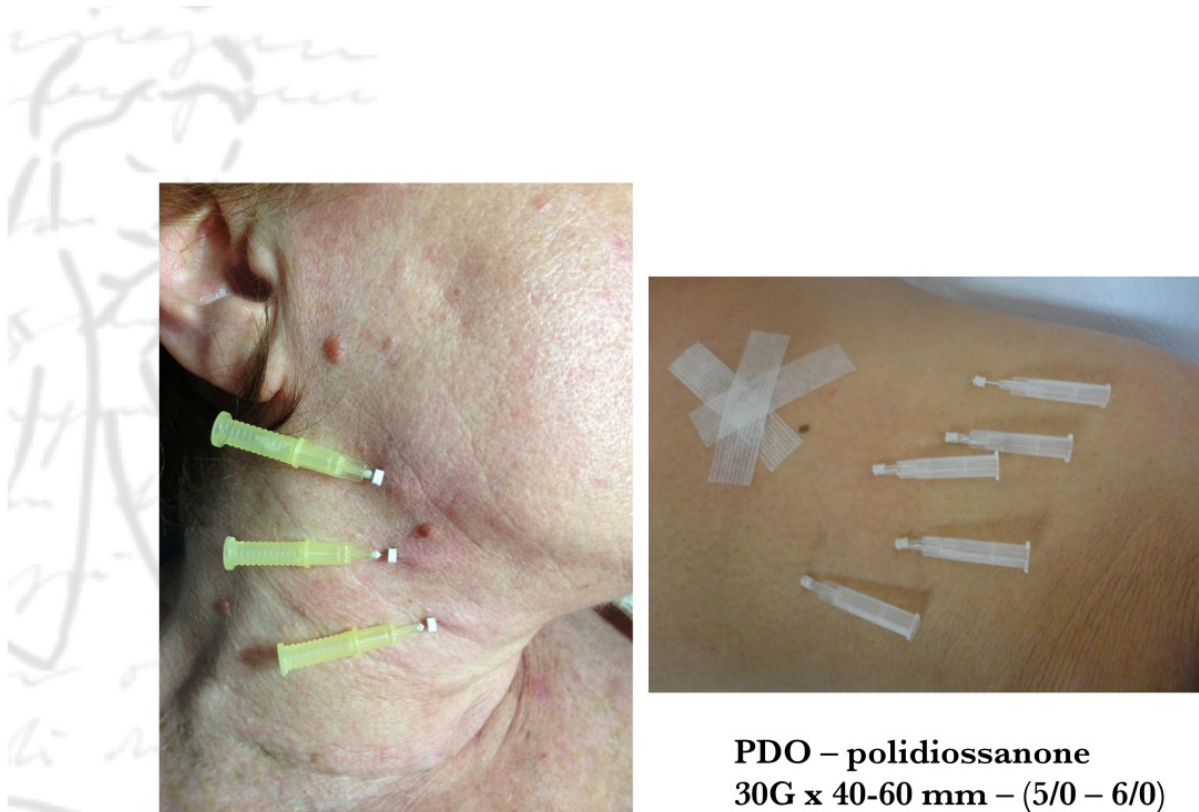

Figure 14. Mini invasive strategy using suspension barbed threads and skin stimulation using absorbable PDO minithreads. (*Bacci Archive*)



ACCADEMIA ITALIANA
DELLA BELLEZZA

info@baccipa.it

3

Figure 15. Mini invasive strategy using suspension barbed threads and skin stimulation using absorbable PDO minithreads. (Bacci Archive)

Also in the same session, we can use botulinum toxin or lipofiling when it is necessary.

Currently, to stimulate the tissues, we use less frequently fillers with hyaluronic acid, in fact today we can also use small threads in PDO - polydioxanone - according to the korean technique that allows us an interesting skin stimulation, in particular in the neck and in midface.

This small absorbable suture may be repeated after 6-8 months, demonstrating that we have good results with fast recovery and few complications using an integration of minimally invasive methodologies. (Fig. 16-17)

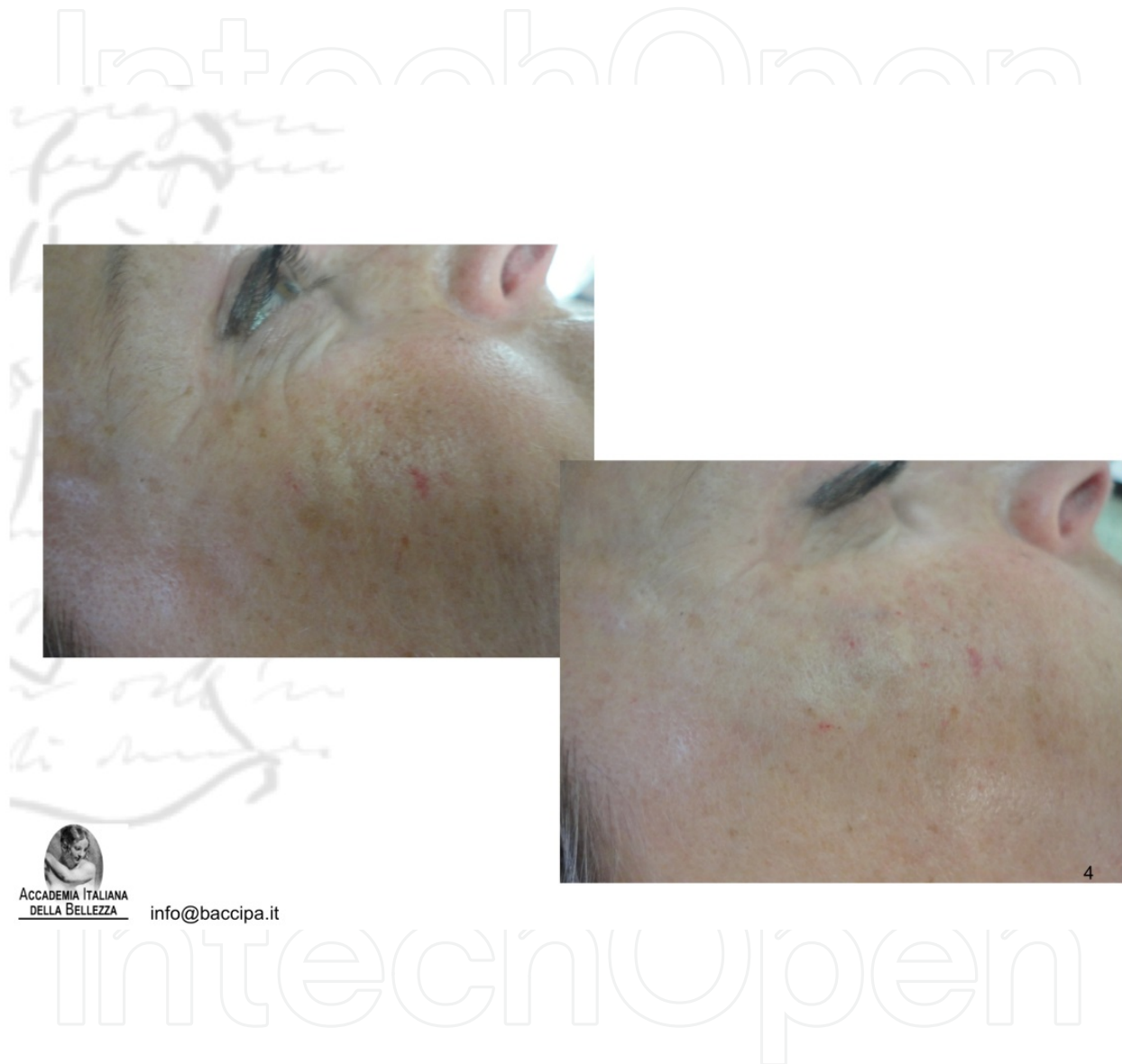

Figure 16. Interesting results using Fill-Traction. (*Bacci Archive*)

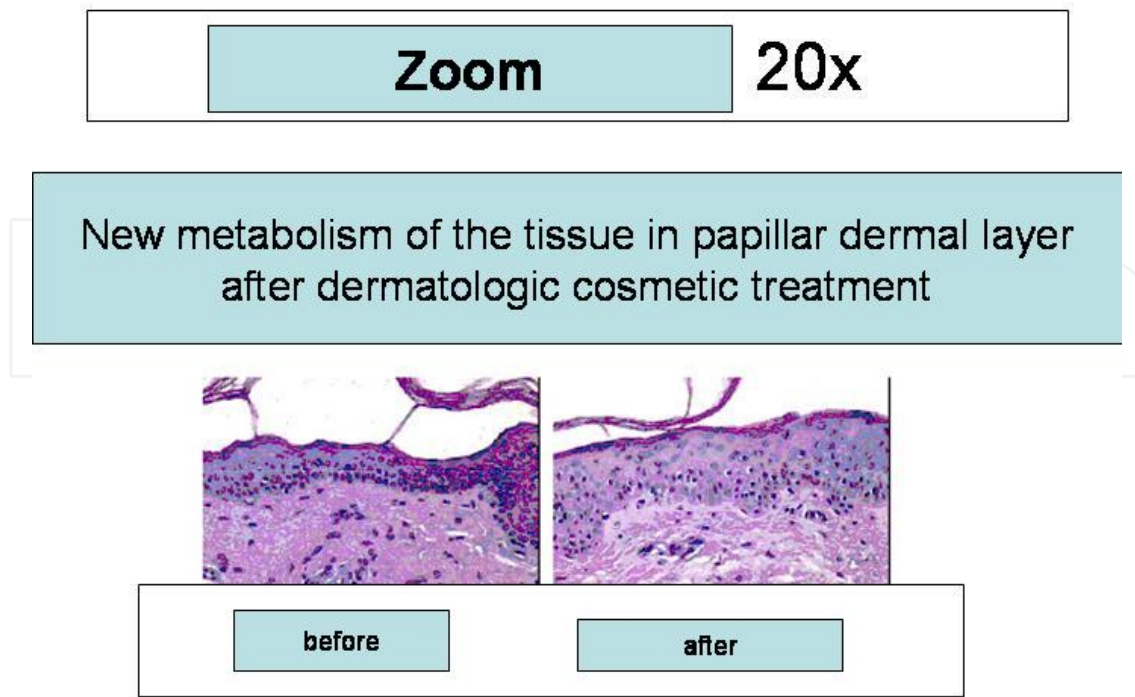


Figure 17. Interesting results using Fill-Traction. (*Bacci Archive*)

7. Conclusion

Certainly, today suspension surgery, as mini invasive aesthetic surgery by threads, is an official surgical strategy, but the best results are always lie to the precise diagnosis and in the rapport between doctor and patient, without never to have miracles or eternal results.

Author details

Pier Antonio Bacci
Mini invasive Aesthetic Surgery Italian Centre, Arezzo, Italy

8. References

- [1] Abraham R.F., De Fatta R.J., Williams III E.F.: "Thread-lift for facial rejuvenation. Assessment of long-term results". Arch. Facial Plast. Surg. 11(3):178-183; 2009.
- [2] Bacci P.A.: "T3 soft face lifting and bioresurfacing". Paper presented at the Cosmetic Surgery congress, Varna, June 2003
- [3] Bacci P.A.: "T3-soft face lifting". Paper presented at the Aesthetic Medicine Congress AGORA, Milan, October 2004
- [4] Bacci P.A.: "T3-soft face lifting". Paper presented at the 29th World Congress of Cosmetic and dermatology surgery, Manila, February 2004

- [5] Bacci P.A.: "Soft face lifting and reposition threads". Presentazione al 49th World Meeting of the International Academy of Cosmetic Surgery, Lisbona, September 17-18th; 2004.
- [6] Bacci P.A.: "T3-Biolifting using absorbable fillers with a few quantity of proteins". Presentazione al World Meeting AACS, Tokyo, 2005, February 24th; 2005.
- [7] Bacci P.A.: "T3 Soft Face Lifting using new Threads and fillers". Presentazione al 49th World Meeting of World Meeting EMEA, Parigi, September 30th – October 2nd; 2005.
- [8] Bacci P.A., Mancini S.: "Chirurgia estetica mini-invasiva: fili di sostegno (Not invasive aesthetic surgery using threads)". Minelli, Arezzo; 45–180; 2006.
- [9] Botti G.: "Chirurgia estetica dell'invecchiamento facciale". Piccin Editore, Padova, 521-540; 1995.
- [10] Capurro S.: "The Double-Tipped Needle". *Plast. Reconst. Surg.* 79 n°6: 1006-7, 1987
- [11] Capurro S. Jr.: "The double tipped needle". *Plast. Reconst. Surg.*, June 1987.
- [12] De Lorenzi C.L.: "Barbed sutures: rationale and technique". *Aesth. Surg J.* 26:223-229; 2006.
- [13] Eremia S., Willoughby M.A.: "Novel face-lift suspension suture and inserting instrument: use of large anchors knotted into the suture with attached needle and inserting device allowing for single entry point placement of suspension suture. Preliminary report of 20 cases with 6- to 12-month follow-up". *Dermatol. Surg.* 32:335–45; 2006.
- [14] Fournier P., Flores M.: "Le lifting invisible". *Rev. Chir. Esthet. Langue Fr.* 27(113):9–20; 2003.
- [15] Fournier P.: "Historie de l'aiguille a deux pointes". *Rev. Chir. Esthet. Langue Fr.* 28(115):19–27; 2004.
- [16] Goldman M., Bacci P.A., Hexsel D., & Coll.: "Cellulite: diagnosis and therapy". Taylor & Francis Ed., New York, : 28-74; 2006
- [17] Hernandez Perez E., Abbar K.: "A percutaneous approach to eyebrow lift: the Salvadorian option". *Dermatol. Surg.* 29(8):852–855; 2003.
- [18] Hochman M.: " Mid-face barbed suture lift". *Facial Plast. Surg. Clin. North Am.* 15(2):201-207, 2007.
- [19] Horne D.F., Kaminer M.S.: "Reduction of face and neck laxity with anchored, barbed polypropylene sutures (Contour Threads). *Skin Therapy Lett.* 11(1):5-7; 2006.
- [20] Hudson D.A., Fernandes D.B.: "Caveats for the use of suspension sutures". *Aesth. Plastic Surg.* 28:170-173; 2004.
- [21] Ingle N.P., King M.W., Leung J.C., Batchelor S.: "Barbed suture anchoring applicability to dissimilar polymeric materials, society for biomaterials". 29th annual meeting transactions, 26:100; 2003.
- [22] Kazinnikova O.G., Adamian A.A.: "Age specific changes in facial and cervical tissue: a review". *Ann. Plast. Reconstr. Surg.* 1:52–61; 2000.

- [23] Khawaja H.A., Hernandez-Perez E.: "The Delta Lift : a modification of S-Lift for facial rejuvenation". Inter. J. of Cosmetic Surgery and Aesthetic Dermatology, Glendale USA, Mary Ann Liebert Ed., Vol.4, N.4:309-315; 2002.
- [24] Lee S., Isse N.: "Barbed polypropylene sutures for mid-face elevation: early results". Arch. Facial Plast. Surg. 7: 55, 2005.
- [25] Leung J.C., Ruff G.L., Megaro M.A.: "Barbed bi-directional medical sutures: biomechanical properties and wound closure efficacy study". Society For Biomaterials 28th annual Meeting Transactions 25:724, 2002.
- [26] Lycka B., Bazan C., Poletti E., Treen B.: "The emerging technique of the antiptosis subdermal suspension thread". Dermatol. Surg. 30: 41, 2004.
- [27] Mc Kenzie A. R.: " An experimental multiple barbed suture for the long flexor tendons of the palm and fingers". J. Bone Joint Surg.49:440-47; 1967.
- [28] Rashid R.M., Sartori M., White L.E et Alii: "Breaking strength of barbed polypropylene sutures: rater-blinded, controlled comparison with non-barbed sutures of various calibers". Arch. Dermatol. 143:869-72; 2007.
- [29] Serdev N.: "Own method scarless breast lift by suture and needles perforations only". Int. J. Cosmet. Surg. 1(1):1-41; 2001.
- [30] Serdev N.: "Scarless Serdev suture methods in brow and face lifts". Int. J. Cosmet. Med. Surg. 3(1):9-15; 2001.
- [31] Serdev N.: "Serdev suture for scarless buttock and ultrasonic liposculpture of the buttocks". Int. J. Cosmet. Med. Surg. 5(1):27-34; 2003.
- [32] Serdev N.: "Scarless buttock lift using Serdev suture". International Journal of Cosmetic Surgery, Vol.3 N.3: 294-329; 2003.
- [33] Serdev N.: "Scarless APTOS versus SERDEV suture lifting methods". Int. Journal of Cosmetic Surgery, vol. 4 – N. 2: 1-10; 2004.
- [34] Sulamanidze M. A., Salti G., Mascetti M., Sulamanidze G. M.: "Wire scalpel for surgical correction of soft tissue contour defects by subcutaneous dissection". Dermatol. Surg. 26:146, 2000.
- [35] Sulamanidze M. A., Fournier P. F., Paikidze T. G., Sulamanidze G.: "Removal of facial soft tissue ptosis with special threads". Dermatol. Surg. 28: 367, 2000.
- [36] Sulamanidze M. A., Shiffman M. A., Paikidze T. G., Sulamanidze G. M., Gavasheli L. G.: "Facial lifting with Aptos threads". Int. J. Cosmet. Surg. Aesth. Dermatol. 4: 275, 2001.
- [37] Sulamanidze M.A., Fournier P.F., Paikidze T.G., Sulamanidze G.M.: "Removal of facial soft tissue ptosis with special threads". Dermatol. Surg. 28:367-371; 2002.
- [38] Stark G.B., Bannasch H.: "The 'Golden Thread Lift': radiologic findings". Aesth. Plast Surg. 31(2):206-208; 2007.
- [39] Helling E.R., Okpaku A., Wang P.T. H., Levine R. A.: "Complications of facial suspension sutures". Aesth. Surg J.27:155-161; 2007.
- [40] Lee C. J., Park J.H., You S.H., Hwang J.H. et Alii: " Dysesthesia and fasciculation: unusual complications following face-lift with Cog Thread". Dermatol. Surg. 33:253-255; 2007.

- [41] Silva-Siwady J.G., Diaz-Garza C., Ocampo-Candiani J.: “A case of Aptos thread migration and partial expulsion”. *Dermatol. Surg.* 31:356-358; 2005.
- [42] Winkler E., Goldan O., Regev E. Mendes D., Orenstein A., Haik J.: “Stensen duct rupture (sialoceles) and other complications of the Aptos Thread Technique”. *Plast. Reconstr. Surg.* 118: 1468, 2006.

IntechOpen

IntechOpen