

We are IntechOpen, the world's leading publisher of Open Access books Built by scientists, for scientists

6,900

Open access books available

185,000

International authors and editors

200M

Downloads

Our authors are among the

154

Countries delivered to

TOP 1%

most cited scientists

12.2%

Contributors from top 500 universities



WEB OF SCIENCE™

Selection of our books indexed in the Book Citation Index
in Web of Science™ Core Collection (BKCI)

Interested in publishing with us?
Contact book.department@intechopen.com

Numbers displayed above are based on latest data collected.
For more information visit www.intechopen.com



Rare Tumors of the Colon and Rectum

Goran Stanojević and Zoran Krivokapić

Additional information is available at the end of the chapter

<http://dx.doi.org/10.5772/56937>

1. Introduction

Malignant tumors of the colon and rectum represent a separate entity, due to their early clinical manifestation, specific methods of examination and, particularly, due to treatment, which is predominantly based on the need for conservation of the sphincter mechanism, without disturbing the oncological principles of surgical treatment and the necessary radicalism. In spite of introduction of the new surgical procedures, and the significant improvements in radio, i.e. chemotherapy, the prognosis of these tumors remains serious.

With regard to the histological structure, tumors can be:

1. Adenocarcinomas,
2. Carcinoids,
3. Lymphomas,
4. Gastrointestinal stromal tumors (GISTs),
5. Squamous cell carcinoma
6. Melanomas
7. Other (extremely rare forms of malignant tumors)

Adenocarcinomas account for 95-97% of all malignant tumors, while the remaining 3-5% belongs to, so called, rare tumors of colon and rectum. The annual percent change in incidence for each rare tumor increased significantly during the 10 years (range: 3.1–9.4%, $p < 0.05$), except squamous cell carcinoma (5.9%, $p > 0.05$) [1]. With regard to the incidence, all rare tumors of the large bowel can be divided into 2 groups:

1. tumors with the incidence 0,1-2% and
2. rare tumors with the incidence <0,1%.

In the first group the most common ones are: carcinoids 1,8%, primary lymphomas 0,1-1%, GISTs 0,9%, melanomas 0,5-1%, and squamous cell carcinoma 0,1% (without the anal canal). The second group or extremely rare forms of malignant tumors consist of: teratoma, plasmocytoma, schwannomas, metastatic tumor. Literature data are limited and mostly concern series of operated patients of some institutions or several published national studies, but there are no randomized studies or meta-analyses which have higher degree of scientific verification because these tumours are very rare [2].

The aims of studying the rare tumors of the colon and rectum are:

- determination of the incidence among population,
- determination of the clinical characteristics
- comparative analysis of the treatment outcome in different parts of the gastrointestinal tract and
- overall and five-year survival of patients.

2. Carcinoids

Carcinoid tumors represents rare, slow growing tumors and they occur in 1,8% of all malignant tumors of the large bowel. There is no clear predominance related to sex and, in the most of cases, the patients are in their sixties or seventies. They originate from the enterochromaffin (argentafile, Kulchitsky) cells, as a part of the diffuse endocrine system and they belong to the group of neuroendocrine tumors, so called well-differentiated "NET's". They are also called APUDomas, which is an abbreviation for "amine precursor uptake and decarboxylation", due to their ability to take over and decarboxylase amines, originally described by Pearse in 1969 [3]. They can occur in all parts of gastrointestinal tract as well as outside of the tract. Therefore with regard to the place of occurrence and according to the division of the primitive intestine during the embryological development, carcinoids are divided into:

1. foregut carcinoid tumors start in the lungs, bronchi, or stomach;
2. midgut carcinoid tumors start in the small intestine, appendix, or proximal large bowel;
3. hindgut carcinoid tumors start in the distal colon or rectum.

Data from literature indicate that the incidence of carcinoids in certain locations is different, although it is considered to be most often localized on the appendix vermiformis, in about 40% of cases, on ileum about 25%, on rectum 15-20% and on respiratory system around 10%. On the other hand, the Japanese National Study has identified, in 90 057 operated patients during the period of 15 years, 345 cases of carcinoids on the small and large bowel, out of which 0,9% was localized on the ileum, 2,3% on the appendix, 8,2% on the colon and 88,6% on the rectum

[1]. Their secretion is active and secrete around 30 vasoactive substances, the most important of which are serotonin, histamine and substance P. In 1867, Langhans [1] first described a gut carcinoid tumor, but the first detailed description of the tumor, similar to carcinoid, was given by Lubrasch 1888, after performing the autopsy on two persons, previously treated due to having multiple tumors of ileum. A German pathologist Oberndorfer first mentioned the term “carcinoid” in 1907, while Siburg published the first data about the rectum carcinoid in 1929 [4-5]. The term “carcinoid” indicates that the tumor, according to some histological characteristics, is similar to carcinoma, but it behaves in a more benign way and less aggressive. They have often been discovered accidentally, during the colonoscopy, or by examination of the clinical symptoms, such as rectoragia or diarrhea. During the primary diagnosing, 60-90% of carcinoids are less than 1 cm of size. These tumors have a variable malignant potential, which depends on: size, localization, depth of invasion and way of growth of the tumor itself.

According to the data from literature, the colon and rectum carcinoids less than 1 cm of size have metastases in about 5,5% of cases. The bigger sized tumors, 1-1.9 cm, have metastasis within the range of 4 to 30%, while those above 2 cm, within the range of 70-80%. With regard to localization, the rectum carcinoids have metastasis in 18% on average, unlike the colon ones in 60%, jejunoileal localization in 34%, stomach in 23% and lungs in 21% [2]. The depth of invasion, particularly the tumors, which are less than 2 cm in size, represents a very important predictive factor in the method and outcome of treatment. Invasion of muscularis propria and lymphovascular, i.e. perineural invasion, anaplastic reaction, positive Ki-67 mutations and frequent mitosis increase the risk of metastasis of tumors, which are less than 2 cm in size. Macroscopically, these are small tumors in the nodular form, covered with the normal mucosa, with intensive fibrosis of the intestine wall. Ulcerous forms with a tendency of bleeding, have metastasis in larger percent and represent a significant risk factor. Histologically, the tumor cells look similar, rounded or polygonal with expressed nucleus and acidophilic cytoplasmic granules. Immunohistochemically, they show focal or diffuse existence of chromogranin A and/or neuron-specific enolase, synaptophysina, CD 56 and pancreatic polypeptide. There is no clear histological difference between benign and malignant large bowel carcinoids, except the size of the tumor itself and invasion of muscularis proprie.

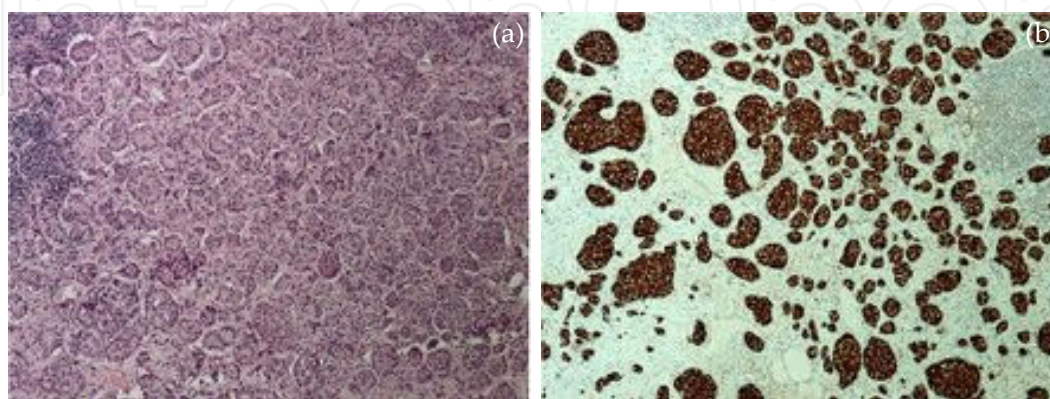


Figure 1. a) colon carcinoid (H&E 10x); b) colon carcinoid (chromogranin A 10x)

2.1. Clinical presentation and diagnosis

The clinical presentation is characterized by the existence of symptoms resulting from the secretion of different biochemical substances and growth of the tumor itself. Occasional abdominal pains, followed by facial flushing, diarrhea, bronchospasm, arrhythmia, hyperthermia, - blood pressure variations and vasomotor collapse, which, based on the intensity can lead to a life dangerous condition, or so called "carcinoid crisis". Various daily activities and psychological conditions, such as alcohol drinking, emotional stress, increased body temperature and difficult defecation potentiate the intensity of symptoms.

The diagnosis of the large bowell carcinoids was usually made by detailed anamnesis and clinical examination of the abdomen and digital rectal examination. Very often, it is an unclear finding, due to the intact mucosa, so it is necessary to take biopsy from the part of the tumor surface, as well as, from the deeper structures. It is also necessary to include a colonoscopy in clinical examination, due to the possible existence of the synchronous lesion, and magnetic resonance imaging or endoluminal ultrasound of the small pelvis, because of the pre-operative staging. The examination of the liver metastasis, should be completed with an ultra-sound and CT scan. The modern diagnostics of carcinoids understands also the, so called, functional or biochemical examinations based on taking over of the certain substances by the tumor cells, which makes them different from the normal tissue. The biochemical properties of carcinoid tumors reflect the presence of neurosecretory granules. They are classified as biochemically typical or atypical based on the presence of high levels of serotonin in so-called typical tumors. The best known metabolite of serotonin in carcinoid tumors is 5-HIAA(hydroxyl indole acetic acid). In a 24-hour sample, the urinary level of 5-HIAA is the test most commonly used in the endocrine work-up of carcinoid tumors. Despite its popularity, it lacks the sensitivity and specificity for the diagnosis of carcinoid tumors because 5-HIAA may not be elevated in atypical carcinoids and can be elevated in other conditions such as tropical sprue, celiac disease, Whipple's disease, and small bowel obstruction, and can be caused by ingestion of food high in serotonin, or certain medications.

Although a number of other tumor markers have been investigated for carcinoid tumor overproduction, serum analysis of chromogranin A, a glycoprotein that is secreted with other hormones by neuroendocrine tumors, appears to be the most promising, with specificity approaching 95% and sensitivity for carcinoid tumors approaching 80 percent. A 40 percent false-positive rate has been seen in patients with multiple myeloma[6].

For this purpose, the scintigraphy of the somatostatin receptors on the surface of tumor cells is applied, or SRS and PET scan, which uses a metabolic taking over of FDG Fluorin- 18 fluoro-deoxyglucose, by the tumor cells. The results of the research indicate that, Octreoscan is the most optimal for identification of the primary tumor and existence of the positive lymph nodes, while in the case of distant metastasis, it is CT or NMR. Within the frame of the biochemical analyses, in case of doubt that there is a carcinoid present, it is necessary to determine the level of 5 hydroxy-indole acetic acid in urine.

2.2. Treatment

The treatment of the colon carcinoid can be divided into two groups:

- a. minimally invasive procedure
- b. laparotomy
- c. Minimally invasive procedure includes several types of interventions:
 - endoscopic mucosectomy or submucosectomy
 - transanal tumor extirpation
 - TEM (transanal endoscopic microsurgery)
 - laparoscopic resections of colon and rectum

Endoscopic mucosectomy or submucosectomy represent one of the possible methods in the conditions of the initial stadium of disease, without penetration into muscularis mucosae, and up to 1 cm of size. The literature data show that endoscopic mucosetomy or submucosetomy are performed in 54% of patients suffering from rectum carcinoid, transanal extirpation of tumor /TEM in 27% of the operated patients, on one hand, as well as in 6% of patients treated by the invasive procedure, on the other [7-9].

The results of the treatment indicate that, in patients treated by the endoscopic methods, in 83% of cases, it was about the positive limits (R1 status), in 16% it was the residual tumor (R2 status) with 2% of acute complications in terms of the occurrence of post-operative bleeding. In 12 patients (14%), a sub-mucosectomy was done, with 42% of the positive margins present.

The advantage of the endoscopic approach is a minimally invasive procedure, faster recovery of a patient and smaller operative trauma, but there are also disadvantages in terms of the high percent of R1 or R2 procedure, (positive margins or residual tumor).

Transanal extirpation/TEM is indicated in the conditions of rectal carcinoid invasion to the submucosa and muscularis propriae. They are mainly performed after the unsuccessful, previously done mucosectomy i.e. sub-mucosectomy. The results of treatment indicate that in 43% of the operated patients, RO resection was done, while in 52% of cases R1, i.e. R2 resection was done. The post-operative complications occurred in about 9% of patients. The disadvantage of the procedure is still a high percentage of R1 and R2 operations.

Laparoscopic resections of colon and rectum represent a trend in the modern colorectal surgery, with all characteristics of the minimally invasive procedure. It is indicated in tumors, which spread to the structures deeper than lamina muscularis mucosa (T2 stadium), most often to the upper third of rectum, but the other parts of rectum as well, where performing the endoscopic procedure would lead to a high percent of R1 and R2 operations.

2.2.1. Laparotomy

- resection of colon (according to the type of segmental or right/left hemicolectomies)

- (resections of rectum with different forms of reconstructions T-T anastomosis, L-T anastomosis, colonic J pouch, etc.)
- incontinence operations (abdominoperineal amputation of rectum, etc.)
- in case of inoperability of tumor, the performance of colostomy.

Laparotomy is indicated in carcinoids of greater median size, so-called bulky tumors, with infiltration to the surrounding organs, as well as, with the potential risk of the colon obstruction. In relation to the outcome of treatment, the resection procedures are loaded with a higher percent of the local recurrence rate, which is explained by the existence of the more invasive and bigger tumors, treated in this way [10-13].

Systemic therapy in carcinoid treatment has two aims

- to reduce intensity of the systemic effects of disease and
- treatment of metastasis.

Reducing intensity of the systemic effects means the use of various medicaments, such as: H2 blockers, Phenothiazin, corticosteroids, serotonin blockers serotonin, bronchodilators etc. The analogues of Somatostatin have a significant effect that, by blocking the receptors reduce the production and systemic effects, primarily the intensity of flushing and diarrhea, in 80% of patients.

Staging system	Colon carcinoids		Rectal carcinoids	
	% patien. 5-year surv. %		% patient. 5-year surv. %	
I	13	97	83	97
II	32	69	6,5	84
III	12	21	2,8	27
IV	43	17	7,4	20
N 0	52		96	
1	48		4	
M 0	76		97,6	
1	24		2,4	

Table 1. Staging system and 5- year survival rate [14-16]

In treatment of metastasis, the effect of chemotherapy application (5-fluorouracil, streptozotocin, doxorubicin,, etoposide, cisplatin, carboplatin, etc.) is insignificant, with a clinical response (Response Rate- RR) from 0 to 30%. In some cases, Interferon is used, in duration of up to 2,5 years, but due the numerous unfavorable effects, its use is limited [6].

The prognosis of the disease, depending on TNM stadium. A search of 15,983 patients with carcinoid tumors from the National Cancer Institute's SEER (Surveillance Epidemiology and

End Results) database identified 2459 with colon tumors and 4701 patients with rectal carcinoid tumors from 1973 to 2004. Patients were analyzed according to various clinicopathologic factors and a tumor (T1, T2, T3), lymph node (N0, N1), and metastasis (M0, M1) staging system was created according to these parameters. Results is shown in Table 1.

3. Primary non-Hodgkin lymphomas

Lymphomas of colon and rectum are the rare tumors that make 1,4% of human lymphomas, 10-20% of gastrointestinal lymphomas, 0,2-0,6% of all malignant tumors of colon, that is, 0,1-1% of all tumors of the large bowel. According to the incidence in the gastrointestinal system in adults, they take a third place, following the stomach and small intestine, unlike with the age of up to seventeen, where the intestinal localization is predominant. In relation to the incidence of all malignant colon and rectum diseases, they take a third place, following adenocarcinoma and carcinoids [17,18]. The predilection places of occurrence are cecum and rectum, due to large amount of lymph tissue in these regions of the large bowel.

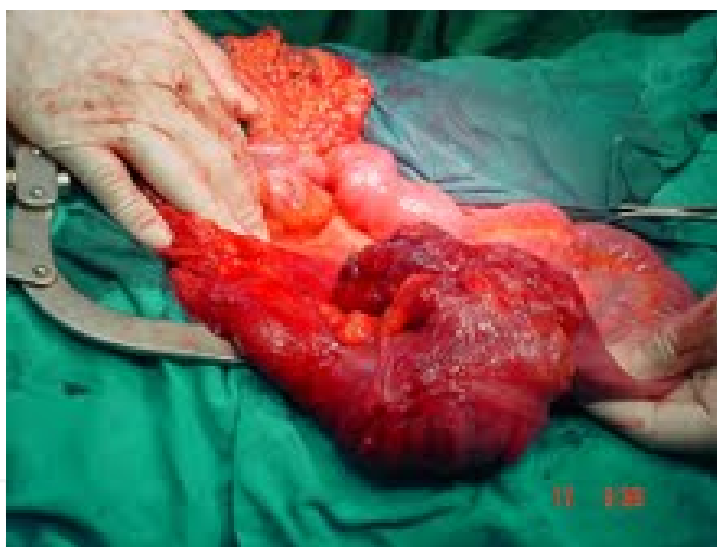

Figure 2. Primary non-Hodgkin lymphoma of the cecum

It occurs more often in male patients, older than 50. With regard to the degree of spreading, diseases can be: primary (localized) and secondary (diffuse form). The primary lymphomas of the large bowel are characterized by the existence of the so-called Dawson's criteria [19]:

1. no palpable, superficial lymph nodes at presentation;
2. no enlarged mediastinal lymph nodes on chest x-ray;
3. normal range for white blood cell count including total and differential
4. at surgery, only the regional lymph nodes are involved;

5. the liver and spleen are without disease

Primary lymphoma of the colon is a predominantly extranodal form of non-Hodgkin lymphoma, while Hodgkin type is much rarer, present in less than 5% of all patients autopsied due to this disease [20-22]. Devin and his coworkers from the Mayo Clinic, published the largest study of patients with rectum lymphomas, which shows that, out of 61 patients treated in the period of 27 years, 49 of them had a diffuse form and only 12 had a localized disease [23]. The tumors usually have a form of polypoid and ulceriform mass, and sometimes, they form excrescent on mucosa, similar to multiple adenomatous polyposis.

Etiological factors in formation of the large bowel lymphoma are unknown, as well as for the other types of malignant diseases. However, the higher incidence was noticed in the conditions of immunosuppression, such as the inflammatory disease – ulcerative colitis, HIV virus infections and conditions after organ transplantations, although there are no clear scientific proofs about the connections among these diseases.

More than two-thirds of intestinal lymphomas are supposed to be of B cell lineage, while T cell intestinal lymphomas are rather infrequent and often multifocal and most frequently localized in the small bowel. In relation to the histological type of B cell, non-Hodgkin lymphomas can be: diffuse B cell type, MALT lymphoma, mantle type, Burkitt type and follicular lymphoma. The incidence of some histopathological forms differs from study to study, so Anderson and his associates presented the data of the, so-called, International Study Group about Lymphomas, which included 1378 patients from 8 different cities from 4 continents. Out of the total number of the histopathological findings, in 80% of cases B-cell lymphoma was diagnosed, where the most common form was the one with the large cells, while the other forms, such as mantle, Burkitt and MALT types were significantly rare. In relation to the histological grades, in 75% of tumors, a moderate and intermediately type of diffuse lymphoma of the large cells was established [24-27].

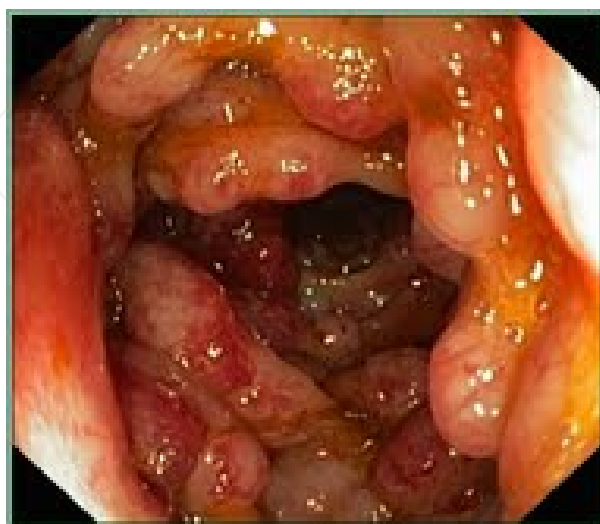

Figure 3. Mantle type of primary non-Hodgkin lymphoma

The degree of disease spreading to the surrounding structures was the best presented by the, so-called, Ann-Arbor staging, modification according to Musshoffu [28,29]. The aim of the successful treatment is the early detection of the disease in IE or IIE stage where still there is a possibility of curative resection. The data from literature are significantly different in relation to the stage of a disease in treated patients, which is a consequence of the various criteria according to which the patients were included into the study, different methodologies of performance and the level of health culture among the tested population.

Stage	Characteristics
IE	Limited to the colonic/rectal wall
IIE 1	Involvement of paracolic lymph nodes
IIE 2	Involvement of intermedial lymph nodes.
III	Involvement of the large bowel and lymph nodes on both sides of diaphragm
IV	Involvement of distant organs (large bowel and one or more extralymphatic organs or tissue)

Table 2. Ann-Arbor staging- Musshoff modifications of primary colorectal lymphoma[29].

3.1. Clinical presentation and diagnosis

The clinical presentation is characterized by the existence of rectoragia and the changed bowel habits. By analyzing the symptoms of the disease, Cho and his associates, presented the study data, which showed that, out of 23 patients, 56% had a non-specific symptoms, abdominal pain and weight loss or anorexia, that is, 35% the of tested patients were operated in the advanced stage of the disease [30]. The data from the research made by Fan and associates, showed that, out of 37 tested patients, 59% had only abdominal pain and 75,7% were operated in the stage of the disease where positive lymphoma nodes were present in the mesenterium of colon and mesorectum. The specific symptoms, such as bleeding per rectum, were present in only 12,5% of patients [17]. Non-specificity of symptoms often postpones timely visit to a doctor and timely diagnosing, which leads to a much higher incidence of the advanced stages of the disease. A special problem is primary colorectal lymphomas - present as surgical emergency, caused by tumors of the IIIIE and IVE stages[31]. Surgical emergencies, caused by the obstruction of the large bowel, or perforation, initiate a need for urgent surgical intervention, which leads to significantly higher rate of mortality of 58% and more frequent disease recurrence [32-36]. The diagnosis can be made - by taking the anamnestic data and clinical examination including digito rectal examination and colonoscopy with biopsy. There are data from literature, which show that it is not always possible to establish the diagnosis by endoscopic procedures, due to inadequately made biopsy of the tumor, as well as the need for timely performance of an adequate immunohistochemical staining during histopathological examination, which is done by a pathologist. It very often leads to inability to give correct interpretation of the pathologic finding [37].

3.2. Treatment

Modern treatment of the primary lymphoma of colon and rectum implies a multi-modal approach, that is, a surgical intervention, chemotherapy and radiotherapy in selected cases. Beside the doubtless improvements achieved in surgical technique, as well as in anesthesiology and chemotherapy, during the last three decades, there is still a low level of the five-year survival among the operated patients, which is 42% [29, 37]. The treatment of the large bowel Non-Hodgkin lymphoma is characterized by the existence of different attitudes about it, from applying only chemo and radiotherapy on one side, to the performance of surgical procedures, on the other. Bilsel and his associates published a review of the case from 2005, which gave a complete clinical response of the primary rectal lymphoma, after the treatment with chemo and radiotherapy [24]. The other authors also presented similar data [38,39]. Pricolo and his associates, in their analysis of the case presentation from 2002, describe the treatment of rectum lymphoma using the resection procedures and then chemo and radio therapy, while Shimono from Japan recommends a pre-operative radiotherapy first, and then a surgical intervention [40,41]. Regarding the type of operation, there are recommendations that, with small dimension primary rectal lymphoma and low malignant potential – MALT or mantle type lymphoma, it is enough to perform a limited resection or transanal extirpation of tumor [42,43]. The differences in attitude are the consequence of the results achieved based on the presentations of cases or studies about a small number of patients and a heterogeneous groups of the treated tumors, in various stages of the disease, with different histopathological diagnosis etc. Nevertheless, based on the modest experience of the authors, the resection of the large bowel is recommended whenever possible, together with neo or adjuvant therapy [44, 45].

4. GISTs

Gastrointestinal stromal tumors or, shortly GISTs, are the most common mesenchymal tumors, which are characterized by positive c-KIT, that is, CD117, CD 34 antigens, and they make 0,1-1% of all gastrointestinal tract tumors. They occur most commonly in the stomach 60-70% and small intestine 20-25%, while they are the least present in the large bowel, around 5%, and 0,9% of all tumors in the rectum. In relation to the incidence of occurrence only in the large bowel, they occur in 80% of all patients in the rectum, while in 20% of cases it is in the colon. They occur in middle-aged persons between 40-60 and between both sexes equally, with the incidence of 6,8 / 1 000 000 [46].

At the beginning of XXth century, Theodor Bilroth provided the first descriptions of the stromal tumors. However, the term “stromal tumor” was introduced by Mazur and Clark only in 1983, following the development of immunohistochemistry. One year later, in 1984, Henry Appelman introduced the term "GIST-gastrointestinal stromal tumors" for the first time, while Kindblom and his associates proved that GISTs originate from the interstitial Cajal cells, which represent the so called, pace maker cells of the gastrointestinal tract. Due to the similar structural and immunohistochemical characteristics of GISTs and Cajal cells, many authors are of the opinion that they originate from the same mesenchymal cell [45]. Invasiveness, or

the metastasis risk assessment of the GISTs on various locations, determined by the size of tumor and mitotic index, as shown in table 4 [47].

Mitotic count	Size	Gastric GIST	Duodenal GIST	Jejunal & ileal GIST	Rectal GIST
≤5/50	<2 cm	0%	0%	0%	0%
	>2 ≤5	1.9%	8.3%	4.3%	8.5%
	>5 ≤10	3.6%	34%	24%	57%
	>10	12%		52%	
>5/50	≤2	0%	N/A	50%	54%
	>2 ≤5	16%	50%	73%	52%
	>5 ≤10	55%	86%	85%	71%
	>10	86%		90%	

Table 3. Metastasis risk assessment of GISTs in different parts of GI tract [48].

4.1. Clinical presentation and diagnosis

GISTs are symptomatic in about 70%, - in about 10% asymptomatic and in 20% they are discovered during the autopsy, which shows that 1/3 of the large bowel stromal tumors are clinically completely silent. The symptomatology is very similar to the other colon tumors, and is characterized by hematochezia, abdominal or rectal pain, occurrence of complete rectum prolapse etc.[49]. Depending on the tumor size, it is possible to get the clinical presentation of the obstruction or ileus, caused by the growth of GISTs. The diagnosis - can be made by taking the anamnestic data, clinical examination including a digital rectal exam, which should be completed with rectoscopy, colonoscopy, endorectal ultrasound and NMR. It is necessary to do a biopsy of tumor with immunohistochemical analysis, for definite confirmation of the GIST existence in the large bowel. In the case of any doubt that there is metastasis in the liver, it is also necessary to perform the ultrasound and CT scan, within the complete staging of tumor. PET scan is indicated in the operated patients in order to follow up.

4.2. Treatment

Surgical intervention is a method of choice in treatment of large bowel GISTs, and is applied in the following cases:

- 1. Primary disease;
- 2. Metastatic diseases
- 3. Recurrence

The main aims of surgical treatment of the primary disease are the complete resection, so-called R0 resection and preservation of the tumor pseudocapsule, without wide resection margins and lymphadenectomy. This is very important in treatment of the rectum GISTs, due to the

aims of sphincter saving procedure and improve the patient's quality of life. With regard to the size and localization of the large bowel stromal tumors, it is possible to use various surgical procedures: segmental resection, local excision, anterior and abdominoperineal resection. The performance of the anterior resection (high or low), means the observance of the partial or total mesorectal excision principles, in order to prevent sacral nerves injury, bleeding or local recurrence.

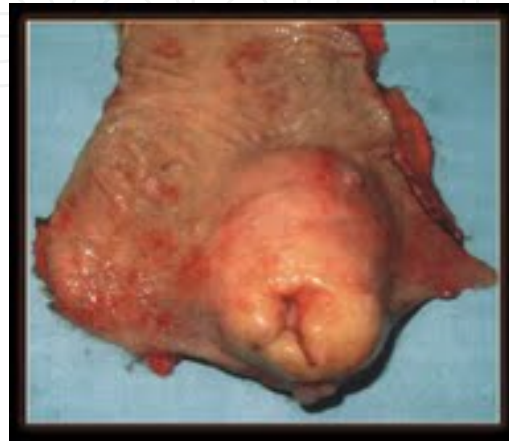

Figure 4. Rectal GIST

When GIST adheres to contiguous organs, consideration should be given to an en bloc resection. The modern aspects of the GISTs treatment also mean the use of Imatinib, a medicament, which revolutionary contributed to the significantly better results in treatment in GISTs. Joensuu, Heinrich van Oosterom and Tuveson made the first reports about the use of Imatinib in 2001. An immediate cause for the invention of this medicament was the discovery of Hirota about the existence of the abnormal activation of KIT oncoprotein or transmembrane receptor tyrosine kinase and the following mutation of C-kit gene, with exceptional cellular proliferation. Imatinib selectively inhibits the receptors of the transmembrane tyrosin kinase, thus blocking the abnormal growth of tumor. Van Oosterom and his associates published the results from 70% of clinical responses in KIT-positive metastatic GISTs [50,51]. Primary unresectable GISTs of the large bowel are initially treated with Imatinib, with an aim to reduce the size of a tumor – “downsizing”. In the case of the existence of a metastatic disease, a non-adjuvant use of Imatinib is indicated, in order to secure good clinical response, meaning a disease without progression, with the possibility of performing R0 resection [52]. When there is a small volume metastasis in liver, some authors recommend the simultaneous resection of the large bowel and liver, and then the application of Imatinib[53]. Distant metastasis occur on the liver in over 50%, and they are treated with the initial application of Imatinib, followed by the various resection procedures.

The treatment of GISTs using chemotherapy has a minimum effect, RR<10%, and has no significance for the overall survival, as well as the application of radiotherapy, since the tumor is radio resistant.

4.3. Treatment outcomes

The outcome of the large bowel GISTs treatment is troubled with a high percentage of local and distant recurrences, so after the R0 resection, it occurs in 45-50% of cases, 20-25 months after the surgical intervention. The average five-year survival rate is 50%, 73% after the R0 and in 26% after R1 and R2 resections. In the case of the advanced disease with local recurrence and metastatic disease, a five-year survival rate is 28-35% [54].

5. Squamous cell carcinoma

Squamous cell Carcinoma of the large bowel is a very rare disease, unlike its localizations on the esophagus and the anal canal. The data from literature are based on the reviews of the clinical cases and series with a small number of patients. Schmidtmann first described the squamous cell carcinoma of the large bowel, actually cecum in 1919, and Reiford described the same disease on the rectum in 1933. Currently, there are about 100 cases of the squamous cell carcinoma of the large bowel described in literature, and the incidence of the disease is 0,1-0,25 on 1000 patients suffering from the colorectal carcinoma [55].

Due to a very rare occurrence of the tumor, there is a lack of prospective studies, or meta analyses, which would offer data about the demographic characteristics of the patients, risk factors, the nature of the disease behavior, as well as the optimal treatment. It mainly occurs in patients of the average age of 60, more often among women 66% than among men 34% [56]. Etiology of the occurrence of colorectal squamous cell carcinoma is still unknown, as well as of the other kinds of malignant diseases, although there are several theories trying to explain the formation of this neoplasm:

- The influence of differentiation of stem cells,
- Squamous metaplasia at the place of existence of colorectal adenoma,
- Proliferation of uncommitted mucosal basal cells into squamous cells which subsequently undergo a malignant transformation
- Oncogenic influence of the chronicle kidney insufficiency, as well as, the application of the immunosuppressive therapy in terms of development of some cancerous viruses or oncogenic differentiation of the stem cells,
- Special influences of irradiation, colocutaneous fistula, ulcerous colitis, Entamoeba histolytica colitis, homosexuality, immunosuppression, schistosomiasis, and still unclear influence of HIV (human papilloma viruses types 16, 18, 31, 33) [57- 59].

5.1. Clinical presentation and diagnosis

The symptoms of the disease are very similar to the symptoms of colon carcinoma, such as bleeding, abdominal pain, change in bowel habits with the episodes of diarrhea and obstipation and weight loss. The diagnosis is established by taking the anamnestic data, clinical

examination including digital rectal exam, which should be completed with rectoscopy, colonoscopy, MSCT, endorectal ultrasound and NMR. Williams and his associates published the following criteria for diagnosing the squamous cell carcinoma of the large bowel, in 1979:

1. non-existence of the squamous cell carcinoma and its metastasis on the other locations (particularly the skin),
2. careful anoscopy and rectoscopy in order to exclude the existence proximal extension of anal squamous cell carcinoma,
3. non-existence of a fistulous tract lined by squamous cells [55, 58].

These criteria should be completed with the excision biopsy of tumor, as well as, the PH, or immunohistochemical confirmation (presence of cytokeratin CAM 5.2, AE1/AE3 i 34B12. CAM 5.2). Sub-mucous localizations of the squamous cell carcinoma represent a separate problem, due to difficult identification during standard examinations, so, in these cases, it is recommended to use endoluminal ultrasound guided needle biopsy of tumor. Determination of values of the tumor markers represents one of the possible auxiliary diagnostic procedures for determination of the disease, under the condition that the marker is specific for a particular tumor. In the case of the squamous cell carcinoma of the colon and rectum, there are no specific tumor markers, so those, usually used for the anal squamous cell carcinoma or for the so called layer plate cells of carcinoma antigen (Squamous cell carcinoma antigen "-SCC Ag"), are used. According to the opinions of some authors, SCC Ag is not specific for the initial diagnosis, but for the follow up of the occurrence of local and distant recurrence after treatment [60].

5.2. Treatment

Surgical intervention is a method of choice in treatment of the squamous cell carcinoma of the large bowel. The type of surgical intervention depends on the size of tumor, its localization, depth of invasion into the colon wall, presence of local and distant metastasis, BMI (Body Mass Index), general condition of the patient and presence of comorbidity. The types of surgical intervention are similar to those used with the colon carcinoma: endoscopic mucosa/sub-mucosa resection, segmental or hemi colectomy, local excision, resection procedures on the rectum, as well as abdominoperineal amputation of the rectum. Endoscopic mucosa/sub-mucosa resection is applied based on the experience acquired in treatment of adenocarcinoma, and is indicated in patients with superficial tumors – T1 stage and with an expressed comorbidity. Endoscopic mucosa/sub-mucosa resection, local excision (trans-anal or trans-anal endoscopic microsurgery-TEM) is a method of choice with T1 stage of the disease, which means a tumor spreading to mucosa/sub-mucosa. There are some dilemmas about the type of treatment in T2 stage (spreading to muscularis propria), because after application of the local excision, a recurrence rate is present in 20% of the operated patients. In these cases, it is necessary to make a good pre-operative staging of tumor in relation to the existence of the positive lymph nodes and the range of spreading to the large bowel wall. In the cases of the transmural spreading to the wall, up to the pericolic/rectal fat tissue – T3 stage, as well as the infiltration into the surrounding organs T4-stage, there are dilemmas whether it is better to do a surgical intervention first, and then the chemotherapy, or vice versa. The researches, which

were made based on the application of the identical treatment protocol in anal squamous cell carcinoma - (combination of the chemo and radio therapy 5-FU +mitomycin-C and radio 45 Gy), did not give the expected results in localization of the proximal parts of the rectum and colon. There are data in literature, which recommend only application of the chemo and radio therapy, as well as, the simultaneous chemo-radiation. However, the majority of authors agree that, for the time being and based on the experiences acquired in treatment of a small number of patients, the optimal therapy means surgical intervention and the adjuvant chemo radiation [52]. Surgical treatment of the advanced disease means the application of the resection procedures (colectomy, high and low resection of rectum) and abdominoperineal amputations of rectum. The resections of rectum, as a sphincter preserving operation, enable better quality of life of the patient on one hand, and compliance with the oncological principles on the other. Regardless of the advantages of the resection procedures in relation to the amputation surgery of rectum, the data from literature show that Miles’s operation has been performed twice as much in treatment of the squamous cell carcinoma of rectum, which has been explained by a large number of advanced tumors at the time of diagnosing [61].

The disease prognosis is based on determination of the TNM stage, the most important prognostic factor, identical to the one in anal squamous cell carcinoma. The TNM stage is shown in Table 4.

Stadium	T	N	M
0	Tis	N0	M0
I	T1	N0	M0
	T2	N0	M0
IIA	T3	N0	M0
IIB	T4	N0	M0
IIIA	T1-T2	N1	M0
IIIB	T3-T4	N1	M0
IIIC	Any T	N2	M0
IV	Any T	Any N	M1

Table 4. TNM staging system of squamous cell carcinoma of the large bowel [56].

By comparing the disease prognosis from adenocarcinoma of the colon and rectum of the same stage, it has been established that stages of the disease I and II have a similar prognosis, unlike the advanced ones (stages III and IV), where squamous cell carcinoma has worse prognosis. The average five-year survival is 32%, with variations, which are related to the certain stages: Dukes B 50%, Dukes C 33% & Dukes D 0%. Application of the adjuvant therapy improves the overall survival of a patient, on one hand, while the pre-operative radiotherapy increases the percent of the sphincter preserving operation, on the other [58,59].

6. Melanoma

Melanoma of the gastrointestinal tract is a rare mucosal melanoma with a particularly aggressive biology compared with cutaneous one of equal stage. They most often occur as a metastatic tumor, while the primary localization is rare and possible in esophagus, stomach, small intestine and anorectum, that is, at the places where melanocyte normally exist. The colon melanoma is an extremely rare tumor with regard to the fact that, embryologically, melanocytes do not exist in this part of colon and that, up to now, only 12 cases have been describes in the English literature. There are several theories, which describe the formation of the colon melanoma: relation to neural crest cells, model of tumor regression and ectodermal differentiation, but none of them has been completely proved so far. Localization in the anorectum takes the third place regarding the incidence of localization, behind the rest of skin and eyes surfaces and it makes 1-1,5% of all melanomas in the human body, and 3-15% of all tumors of the colon and rectum [62,63]. Moore described it for the first time in 1857 and, until now, the total of 500 cases was described in the literature. The most often it occurs on the skin, under the dental line, and rarely at the level of cuboidal epithelium of the transition zone and mucosae of the distal rectum. It is more common in women (twice as much than in men), between 60 and 70 years of age [64]. The melanoma represents a disease of the neuroectodermal origin, which the most often originates from melanocytes and nevus cells of the basal layer of epidermis, and significantly less from mucosa. It has an extremely worse long-term prognosis, because of the disease discovery in the advanced stage, mainly with metastasis in the inguinal nodes. Beside the lymphogenous dissemination, spreading is possible by the local ingrowth and in hematogenous way. The local spread is according to the radial (horizontal) and vertical growth. Radial growth means circular spreading around the primary tumor, through the epithelium of mucosa and the superficial layers of sub-mucosa, without tendency of metastasizing. Vertical growth means penetration into the deeper layers of the colon wall, with simultaneous metastasizing. Determination of level of the vertical tumor growth, i.e. involvement of the colon and rectum wall layers, is essential for the choice of surgical intervention. The most important roles here have the MSCT (multi-slice scanner), NMR (magnetic resonance) and endoluminal ultrasound. Hematogenous dissemination occurs by penetration of the melanoma cells into the blood vessels, with further spreading to the whole body. About 30% of patients, at the moment of diagnosing, are considered to have a disseminated process, while only 17% of the operated ones have a five-year survival. [65,66]. It differs from skin melanoma in the way that 25% of tumors do not contain a pigment of the so called "coloured" tumor, and because ultraviolet radiation is a factor of protection, not a risk. In case of existence of the pigment tumor of the rectum, the macroscopic appearance is very similar to thrombosed external and prolapsing internal hemorrhoids (see figure 5), which can mislead a doctor in setting a diagnosis[67,68].

The symptoms of the disease are different, but the most common ones are the abdominal pain, weight loss and bleeding. The diagnosis of the disease implies to detailed anamnesis, physical examination with special reference to inspection of all parts of skin and eyes, as the most common primary localizations, as well as, taking biochemical laboratory analyses, digito rectal examination, colonoscopy, barium enema, multi-slice scanner (MSCT), magnetic resonance

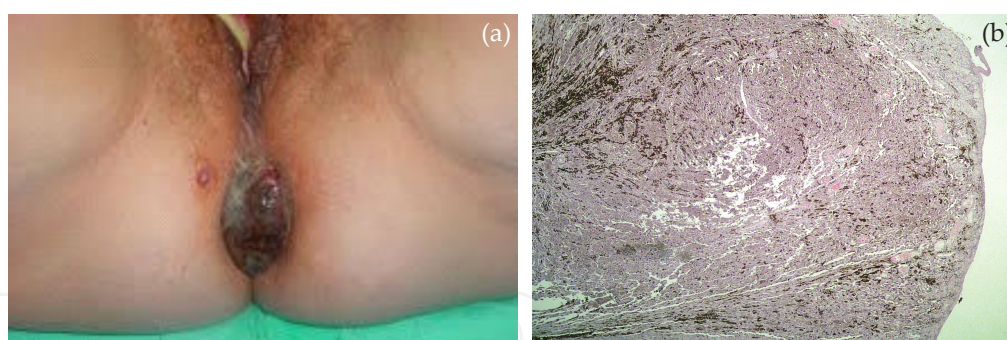


Figure 5. a). Prolapsed melanoma recti; b). Histopathological finding of melanoma recti (H&E 40x)

(NMR), endoluminal ultrasound and tumor biopsy with pathohistological and immunohistochemical processing. Special attention should be paid to the examination of certain groups of lymph nodes, depending on the primary tumor localization. Taking into account the results made by Kalid and his associates, the most often localization of the primary colon melanoma is cecum ascendens and transversum, while with the metastatic melanoma these are the ascendant and descendant parts of colon [62]. Curative treatment of the large bowel melanoma is exclusively surgical. The main aim of the treatment is to achieve a compromise between the necessity to apply a radical oncological treatment and a need to preserve the patient's quality of living. The contemporary approach to treatment of the primary colon and rectum melanoma implies to the performance of surgical interventions, such as:

- a. colectomy with wide excisional margins (partial, hemi-colectomy, subtotal and total)
- b. trans-anal wide local excision with preservation of the anal sphincter (in the case of the initial stage of the rectum tumor)
- c. extensive surgeries according to the type of the rectum resection or abdominoperineal amputation.

There are numerous dilemmas about which type of surgical intervention to be applied in certain stages of the disease. The supporters of radical treatment recommend the resection or rectum abdominoperineal amputation, depending on the localization, with dissection of both inguinal regions, stating the following advantages:

- possibility of the detailed exploration of the abdomen and the eventual discovery of distant metastasis;
- lower percent of the local recurrence rate [69].

On the other hand, some authors recommend a wide local excision of tumor with preservation of the sphincter mechanism, for the following reasons:

- absence of definitive stoma,
- similar five-year survival [70,71].

The authors from MD Anderson Cancer Center present 20-year experience with treatment of 54 patients with localized anorectal melanoma, demonstrating that combined surgical wide local excision and adjuvant radiotherapy provides good local disease control with acceptable side effects [72]. The existence of such different attitudes in literature is a consequence of, primarily, uneven criteria of the researches made, comparison of different localizations of the anorectal melanoma and stage of the disease. The most significant parameter, based on which a decision about the type of surgical intervention is made, is the thickness of tumor. According to Weynadt and his associates, indication for a wide local excision are melanomas up to 4 mm thick, with the limits of excision up to 2 cm from the primary tumor, without involvement of sphincter, while the extensive surgeries on the rectum are recommended for the melanomas over 4 mm thick [73]. In relation to the adjuvant therapy, melanomas are considered hemi resistant tumors, so certain cytostatic medicaments have an effect in 10-25% of the treated ones. The most often used are: dacarbazin, temozolamid, cisplatin, carboplatin, nitrosoureas. The latest research showed that determination of biological markers RAS/RAF/MEK/ERK, represent a significant indicator of the cell growth intensity degree, as well as, the invasion and survival [62]. The adjuvant therapy of anorectum melanoma is not very much successful because all these tumors are radio resistant and scarcely responsive to chemotherapy [74,75].

6. Extremely rare tumors

Other tumors include an extremely rare malignant diseases of the large bowel: primary teratomas, extramedullary plasmacytomas, schwannomas and metastasis of distant tumors.

Primary teratomas of the large bowel are very rare diseases and, there are only about 50 cases published in literature until now, mainly the ones in the rectum and in the form of clinical presentation. It occurs more often in women at the average age of 42,5. They are considered to originate as consequence of the ectopic development of the so-called "captured" ectodermal tissue although, in their composition, some structures of mesodermal endodermal origin are possible. Histologically, it is composed of the stratified squamous epithelia, fat cells, hair follicle, cartilage and, partially glandular tissue. They are usually benign tumors, however some malignant transformations are also possible, which create a need for the total elimination of tumor, due to compliance with the oncological principles. Data from literature indicate that teratomas usually occur in the ovary, testicles, mediastinum and the middle lines such as sacrococcygeal region, while they occur less frequently in the gastrointestinal tract (rectum, sigmoid part of colon, appendix and terminal ileum) [76]. The rectal teratomas usually have a polypoid cystic form, with protrusion into the lumen area. The solitary cysts are mainly present, filled in with sebaceous whitish liquid into which the sebaceous glands, hair follicles and teeth are immersed. Beside the cystic form, the existence of the solid tumors is possible, which indicates a mature form of the teratoma.

The clinical presentation is characterized by the presence of pain during defecation, bleeding and change in bowel habits. The diagnosis is established by the anamnesis and digital rectal examination, which confirms the existence of the polypoid tumor mass of mainly smooth edges

and a pedicle. The cases of rupture of the ovarian teratoma into the rectal lumen are described, with the similar difficulties. The additional diagnostic procedures, such as the endoluminal ultrasound, multi-slice scanner and NMR give the additional information about the extensity of the tumor itself, as well as, the estimation of operability. Some malignant transformations of teratomas with a tendency of creating squamous cell carcinoma are possible, and due to this, it is not advisable to perform the transanal punctuation because of the danger of malignant cells spreading, on one hand, and the potential infection, on the other. The method of choice in the treatment is the complete elimination of the cystic tumor.

The most frequent form of plasma cell neoplasm is a multiple myeloma. Out of the total number of all multiple myeloma, only 2% are the so-called extramedullary plasmacytoma. More the 75% of extramedullary plasmacytoma occur in the upper part of the respiratory system, while the most common places of occurrence in the gastrointestinal tract are the stomach and small intestine. Until now, 22 cases of the occurrence of extramedullary plasmacytoma in the colon, have been reported, where the average age of patients was around 52,3. The most frequent localization on the large bowel are the cecum with 36,4% and rectum with 22,7%. It is essential to make a differential diagnosis differentiation between the primary and secondary plasmacytoma, that is, the metastasis of the multiple myeloma. It is achieved by determination of the Bence-Jones proteins in urine, by serum electrophoresis, as well as, the immunohistochemical finding of the collections of monoclonal plasma cells.

The treatment involves the application of:

- surgical intervention in 81,8% of cases,
- radio-therapy in 9% of cases,
- combined application of surgical intervention and radio-therapy in 4,5% of cases [77,78].

Schwannomas originate from Schwann cells, which form neural sheath and belong to the group of stromal tumors. In the gastrointestinal tract, they most frequently appear in the stomach, while the primary Schwannomas of the large bowel are extremely rare and, until to now, only 39 clinical cases have been reported. They mainly occur in older patients around 65 years of age, of both sexes equally. They grow slowly and there is a large number of patients who do not have any symptoms at the moment of diagnosing. The symptoms occur depending on the size and localization of tumor, but vague pain in the abdomen, bleeding and change of bowel habitus mainly manifest them. The pre-operative diagnosing, using the standard procedures such as anamnesis, physical examination, colonoscopy MSCT, NMR and endoluminal ultrasound, is possible in determination of the tumor mass, but not the type and kind of tumor because it resembles to the GIST tumors of the colon. The most accurate diagnosis implies the elimination of tumor as a whole, with pathohistologic and immunohistochemical analysis. It is also difficult to differentiate it from GISTs in respect of immunohistochemical analysis and some authors classify it the sub-group of GISTs, such as GANT tumors, i.e. gastrointestinal autonomous nerve tumors [79].

7. Metastases in the colon and rectum from the distant tumors

The metastasis of distant primary tumors rarely spread to the large bowel, and it is usually related to the carcinoma of the surrounding organs (stomach, pancreas, ovarian etc.) which, due to their growth and size, spread to the surrounding parts of colon, or “fall” on the intraperitoneal rectum with secondary infiltration. The degree of the tumor spreading depends on the length of the primary tumor existence and the histologic type, although the literature data indicate that serosa is infiltrated in 28%, muscles’ layer in 31% and mucosa in 14% of patients. The expansion of the prostate cancer is possible, with perforation to Denonvilliers fascia and the secondary spreading to the rectum, according to the type of circumferential, i.e. annular stenosis, without spreading to mucosa in men, as well as the carcinoma portie vaginalis uteri, in women [80,81]. The pouch of Douglas, as the lowest point in the abdomen and in the close vicinity of the rectum, is a place of intraperitoneal spreading of carcinoma of any intra-abdominal or retroperitoneal organ, with predomination of the stomach and ovarium. Carcinoma metastasis of retroperitoneal and extra-abdominal organs, pancreas, kidneys and breast, are described in literature [82,83]. The clinical presentation is similar to those of the other colon tumors (bleeding, change in the bowel habitus, pain in the region of anus), supplemented with symptomatology of the primary localization of the malignant process. The diagnosis implicates anamnesis, digital rectal examination, colonoscopy, endoanal ultrasound, multi-slice scanner, NMR, as well as, the biopsy with pathohisiological confirmation.

The strategy of treatment depends on:

- localization of the primary malignant process,
- advancement of the disease,
- histological type of the primary tumor

If the primary tumor localization is in the immediate vicinity of the colon and rectum (pancreas, sigma, prostate, cervix and vagina), it is recommended to use the so called en block resections, with an aim to achieve the oncological principle of radicalism or R0 procedure [84]. Sometimes, it is necessary to perform a non-adjuvant therapy in order to reduce the volume of tumor, so called “downsizing”, and the biological aggressiveness of tumor, “down-staging”, on one hand, or to supplement the surgical intervention with the adjuvant therapy, on the other. In the case of extra abdominal localization of the primary tumor, it is necessary to assess the effect of successfulness of the surgical intervention in achieving a R0 resection, or the application of the neoadjuvant therapy.

8. Conclusion

Rare tumors of the colon and rectum represent an important group of neoplasms, due to their specific prognosis secondary to late diagnosis, and resistance to conventional cancer therapy. Over the last 20 years, their overall incidence has increased, due to advent of novel imaging

techniques, especially the development of more sophisticated diagnostic tools including high resolution CT and MRI, capsule endoscopy and somatostatin scintigraphy for NETs. Although the development of specific targeted therapies such as tyrosine kinase inhibitors for GISTs and somatostatin analogs for NETs have improved prognosis, early detection remains the critical variable in determining outcome. Similarly, promising therapeutic data in some subgroups are encouraging although the majority is still diagnosed late and targeted effective therapy is lacking. Difference in survival is the consequence of the difference in biological aggressiveness of tumor, way of the disease spreading and tendency towards metastasis on one hand, and the frequency of appearance and symptomatology on the other. Carcinoid was an indolent tumor with the best prognosis, both non-Hodgkin lymphoma and squamous cell carcinoma of the large bowel showed significantly worse overall survival rate, as compared to adenocarcinoma, while melanoma has the shortest time of survival. The aim of this chapter is to draw our attention to the rare tumors in everyday clinical practice.

Acknowledgements

We would like to express our gratitude to Mrs. Gorjana Djordjevic, for meticulous proofreading and assistance with the English text.

Author details

Goran Stanojević^{1,2} and Zoran Krivokapić^{3,4}

*Address all correspondence to: stgoran1964@gmail.com

1 Department of Surgery of the Medical Faculty – University of Niš, Niš, Serbia

2 Clinic for General Surgery, Clinical Center Niš, Niš, Serbia

3 Medical Faculty –University of Belgrade, Department of Surgery, Belgrade, Serbia

4 First Surgery Clinic, Clinical Center Serbia, Belgrade, Serbia

References

- [1] Kang H, O'Connell JB, Leonardi MJ, Maggard MA, McGory ML, Ko CY. Rare tumors of the colon and rectum: a national review. *Int J Colorectal Dis* 2007; 22(2):183-189.

- [2] Gordon Ph. Malignant neoplasms of the Colon. In: Gordon Ph, Nivatvongs S, (eds) Principles and Practice of the Surgery for the Colon Rectum and Anus. New York, London: Informa Healthcare; 2007. p 489-645
- [3] Vilallonga R, Espín Basany E, López Cano M, Landolfi S, Armengol Carrasco. Neuroendocrine carcinomas of the colon and rectum. A unit's experience over six years Rev Esp Enferm Dig 2008;100(1):11-16.
- [4] Gustafsson BI, Siddique L, Chan A, Dong M, Drozdov I, Kidd M, Modlin IM. Uncommon cancers of the small intestine, appendix and colon: an analysis of SEER 1973-2004, and current diagnosis and therapy. Int J Oncol. 2008;33:1121-1131.
- [5] Yoon SN, Sik CY, Shin US. Clinicopathological characteristics of rectal carcinoids. Int J Colorectal Dis 2010; 25:1087-1092
- [6] Robertson R G, Geiger W, Davis N. Carcinoid Tumors. Am Fam Physician. 2006;74(3):429-434.
- [7] Devine R, Brand M. Miscellaneous Neoplasms. In: Wolff B, Fleshman J, Beck D, Pemberton J, Wexner S, (eds) The ASCRS Textbook of Colon and Rectal Surgery. Springer; 2007.p 515-524.
- [8] Gibbs NM. The histogenesis of carcinoid tumours of the rectum.J Clin Pathol 1963; 22: 206-214.
- [9] Kwann MR, Goldberg JE, Bleday R. Rectal carcinoid tumors: review of results after endoscopic and surgical therapy. Arch Surg. 2008;143(5):471-475.
- [10] Soga J. Carcinoids of the rectum: an evaluation of 1271 reported cases. Surg Today 1997;27(2):112-119
- [11] Jetmore AB, Ray JE, Gathright JB Jr, McMullen KM, Hicks TC, Timmcke AE. Rectal carcinoids: the most frequent carcinoid tumor. Dis Colon Rectum 1992;35(8):717-725
- [12] Koura AN, Giacco GG, Curley SA, Skibber JM, Feig BW, Ellis LM. Carcinoid tumors of the rectum: effect of size, histopathology, and surgical treatment on metastasis free survival. Cancer 1997;79(7):1294-1298
- [13] Neary P, Redmond PH, Houghton T, Watson GRK, Bouchier-Hayes D. Carcinoid disease: Review of the literature. Dis Colon Rectum 1997; 40 (3):349-362
- [14] Landry CS, Brock G, Scoggins CR, McMasters KM, Martin RC. Proposed staging system for colon carcinoid tumors based on an analysis of 2,459 patients. J Am Coll Surg. 2008;207(6):874-881
- [15] Landry CS, Brock G, Scoggins CR, McMasters KM, Martin RC. Proposed staging system for rectal carcinoid tumors based on an analysis of 4701 patients. Surgery. 2008;144(3):460-466.

- [16] Schindl M, Niederle B, Häfner M; et al. Stage-dependent therapy of rectal carcinoid tumors. *World J Surg* 1998;22(6):628-634.
- [17] Fan CW, Changchien Cr, Wang JY, Chen JS, Hsu KC, Tang R, et al. Primary colorectal lymphoma. *Dis Colon Rectum* 2005; 43: 1277-1282
- [18] N. Doolabh, T. Anthony, C. Simmang, S. Bieligk, E. Lee, P. Huber, R. Hughes, et al. Primary colonic lymphoma. *J Surg Oncol* 2000; 74: 257-262.
- [19] Dawson IM, Cornes JS, Morson BC. Primary malignant lymphoid tumours of the gastrointestinal tract. *Br J Surg* 1961; 49:80-9.
- [20] Keighley MRB, Williams NS. Rare tumours of the colon and the rectum. In: Keighley MRB, Williams NS, (eds) *Surgery of The Anus Rectum & Colon*. WB Saunders, London-Toronto; 2001.p 1329-1347.
- [21] Pandey M, Kothari KC, Wadhawa MK, Patel HP, Patel SM, Patel DD. Primary malignant large bowel lymphoma. *Am Surg* 2002; 68:121-126
- [22] Koch P, del Valle F, Berdel WE, Willich NA, Reers B, HiddemannW, et al. Primary gastrointestinal Non-Hodgkin's lymphoma: I. Anatomic and histologic distribution, clinical features, and survival data of 371 patients registered in the German multicenter study GIT NHL 01/92. *J Clin Oncol* 2001; 19:3861-3873
- [23] Devine RM, Beat RW Jr, Wolf BG. Malignant lymphoma of the rectum. *Dis Colon Rectum* 1986; 29: 812-814
- [24] Jezersek Novakovic,B, Novakovic S, Frkovic-Grazio S. A single-center report on clinical features and treatment response in patients with intestinal T cell non-Hodgkin's lymphomas. *ONCOLOGY REPORTS* 2006; 16: 191-195.
- [25] Harris ML, Jaffe ES, Diebold J, Flandrin G, Konrad MH, Vardiman J, et al. The World Health Organization classification of hematological malignancies. Report of the Clinical Advisory Committee meeting, Airline House, Virginia, November 1997. *Mod Pathol* 2000;13: 193-199.
- [26] Bairey O, Ruchlemer R, Shpilberg O. Non-Hodgkin's lymphomas of the colon. *Isr Med Assoc J* 2006; 8:832-835
- [27] Anderson JR, Armitage JO, Weisenburger DD. Epidemiology of the non-Hodgkin's lymphomas: distributions of the major subtypes differ by geographic locations. Non-Hodgkin's Lymphoma Classification Project. *Ann Oncol* 1998; 9: 717-720.
- [28] Musshoff K. Klinische stadieneinteilung der nicht-Hodgkin lymphoma. *strahlentherapie*; 1977;153:218-221.
- [29] National Cancer Institute. Summary and description of a working formulation for clinical usage. The Non-Hodgkin's Lymphoma Pathologic Classification Project 1982; 49:2112-2135.

- [30] Cho MJ, Ha CS, Allen PK, Fuller LM, Cabanillas F, Cox J. Primary Non-Hodgkin Lymphoma of the Large Bowel. *Therapeutic Radiology* 1997; 205:535-539
- [31] Gonzalez QH, Heslin MJ, Dávila-Cervantes A, Alvarez-Tostado J, de los Monteros AE, Shore G, Vickers SM. Primary colonic lymphoma. *Am Surg* 2008; 74: 214-216
- [32] Cai S, Cannizzo F Jr, Bullard Dunn KM, Gibbs JF, Czuczman M, Rajput A. The role of surgical intervention in non-Hodgkin's lymphoma of the colon and rectum. *Am J Surg* 2007; 93:409-412
- [33] Wang MH, Wong JM, Lien HC, Lin CW, Wang CY. Colonoscopic manifestations of primary colorectal lymphoma. *Endoscopy* 2001; 33:605-609.
- [34] Jinnai D, Iwasa Z, Watanuki T. Malignant lymphoma of the large intestine-operative results in Japan. *Surg Today* 1983;13: 331-336.
- [35] Contrery K, Nance FC, Becker WF. Primary lymphoma of the gastrointestinal tract. *Ann Surg* 1980;191:593-598.
- [36] Busch E, Rodriguez-Bigas M, Mamounas E, Barcos M, Petrelli NJ. Primary colorectal non-Hodgkin's lymphoma. *Ann Surg Oncol* 1994;1: 222-228
- [37] MTC Wong and KW Eu. Primary colorectal lymphomas. *Colorectal Dis* 2006;8:586-591.
- [38] Devine R., Brand M. Miscellaneous Neoplasms. In: Wolff B, Fleshman J, Beck D, Pemberton J, Wexner S, (eds) *The ASCRS Textbook of Colon and Rectal Surgery*. Springer; 2007.p 515-524.
- [39] Teare JP, Greenfield SM, Slater S. Rectal lymphoma after colectomy for ulcerative colitis. *Gut* 1992;33:138-139
- [40] Ahmed M, El-Ghani M, Shafiey M, Fawzy M, Ismail H, Monir M. Clinico-Pathological Features and Outcome of Management of Pediatric Gastrointestinal Lymphoma J Egypt Nat Canc Inst 2005;17: 251-259.
- [41] Pricolo R, Parziale A, Filosa M, Voltolini F, Zangrandi A. Primary lymphoma of the rectum: a case report and review of the literature. *Chir Ital* 2002; 54 (4): 549-554.
- [42] Shimono R, Mori M, Kido A, Adachi Y, Sugimachi K. Malignant lymphoma of the rectum treated preoperatively with hyperthermia and radiation. *Eur J Surg Oncol* 1995; 21(1): 83-84
- [43] Terauchi S, Yamamoto K, Fujii H, Koyama F, Sugimori S, Enomoto H, Yamanouchi M, Nakano H. Mantle cell lymphoma of the rectum at an early stage: a case report. *Hepato gastroenterology* 2001; 48: 675-677.
- [44] G Stanojević, M Stojanović, M Jovanović, M Stojanović, M Jeremić, B Branković, N Ignjatović, V Katić. Primarni kolorektalni limfomi. *Vojnosan preg* 2009; 66:295-302

- [45] Goran Stanojevic, Milica Nestorovic, Branko Brankovic, Miroslav Stojanovic, Milan Jovanovic, Milan Radojkovic. Primary colorectal lymphoma: An overview. *World J Gastrointest Oncol* 2011; 3(1): 14-18
- [46] Grassi N, Cipolla C, Torcivia A, Mandala S, Graceffa G, Bottino A, Latteri F. Gastrointestinal stromal tumour of the rectum: report of a case and review of literature. *World J Gastroenterol*. 2008 28;14(8):1302-1304.
- [47] Miettinen M, Sobin LH, Sarlomo-Rikala M. Immunohisto-chemical spectrum of GISTs at different sites and their differential diagnosis with a reference to CD117 (KIT) *Mod Pathol*. 2000;13:1134–1142.
- [48] Miettinen M, Lasota J. Gastrointestinal stromal tumors: pathology and prognosis at different sites. *Semin Diagn Pathol*. 2006;23(2):70-83
- [49] DeMatteo RP, Lewis JJ, Leung D, Mudan SS, Woodruff JM, Brennan MF. Two hundred gastrointestinal stromal tumors: recurrence patterns and prognostic factors for survival. *Ann Surg*. 2000;231:51–58.
- [50] Manouras A, Pappas A, Katergiannakis V, Filis K, Chrysikos J, Pattas M, Genetzakis M, Tsekouras D, Lagoudianakis E. Gastrointestinal stromal tumors of the rectum: report of five cases. *Acta Gastroenterol Belg* 2009;72(2):257-261.
- [51] van Oosterom AT, Judson I, Verweij J, Stroobants S, Donato di Paola E, Dimitrijevic S, Martens M, Webb A, Sciot R, Van Glabbeke M, Silberman S, Nielsen OS. European Organisation for Research and Treatment of Cancer Soft Tissue and Bone Sarcoma Group. Safety and efficacy of imatinib (STI571) in metastatic gastrointestinal stromal tumours: a phase I study. *Lancet* 2001;358:1421-1423.
- [52] van der Zwan SM, DeMatteo RP Gastrointestinal stromal tumor: 5 years later *Cancer*. 2005 ;104(9):1781-1788.
- [53] Verweij J, Casali PG, Zalcberg J, LeCesne A, Reichardt P, Blay JY, Issels R, van Oosterom A, Hogendoorn PC, Van Glabbeke M, Bertulli R, Judson I. Progression-free survival in gastrointestinal stromal tumours with high-dose imatinib: randomised trial. *Lancet* 2004;364:1127-1134.
- [54] Marc Everett M, Gutman H. Surgical management of gastrointestinal stromal tumors: Analysis of outcome with respect to surgical margins and technique. *J Surg Oncol* 2008; 98:588-593
- [55] M. Najeeb Al Hallak MN, Hage-Nassar G, Mouchli A. Primary Submucosal Squamous Cell Carcinoma of the Rectum Diagnosed by Endoscopic Ultrasound: Case Report and Literature Review. *Case Rep Gastroenterol*. 2010; 4(2): 243–249
- [56] Dyson T & Draganov P. Squamous cell cancer of the rectum. *World J Gastroenterol*. 2009; 15(35): 4380–4386

- [57] Yurdakul G, de Reijke TM, Blank LE, Rauws EA. Rectal squamous cell carcinoma 11 years after brachytherapy for carcinoma of the prostate. *J Urol*. 2003;169:280.
- [58] Williams GT, Blackshaw AJ, Morson BC. Squamous carcinoma of the colorectum and its genesis. *J Pathol*. 1979;129:139–147
- [59] Leung KK, Heitzman J, Madan A. Squamous cell carcinoma of the rectum 21 years after radiotherapy for cervical carcinoma. *Saudi J Gastroenterol*. 2009;15:196–198
- [60] Audeau A, Han HW, Johnston MJ, Whitehead MW, Frizelle FA. Does human papilloma virus have a role in squamous cell carcinoma of the colon and upper rectum? *Eur J Surg Oncol*. 2002;28:657–660.
- [61] Nahas CS, Shia J, Joseph R, Schrag D, Minsky BD, Weiser MR, Guillem JG, Paty PB, Klimstra DS, Tang LH, et al. Squamous-cell carcinoma of the rectum: a rare but curable tumor. *Dis Colon Rectum*. 2007;50:1393–1400
- [62] Khalid U, Saleem T, Imam AM, Khan MR. Pathogenesis, diagnosis and management of primary melanoma of the colon. *World J Surg Oncol* 2011; 9: 1-9.
- [63] Lens M, Bataille V, Krivokapic Z. Melanoma of the small intestine. *Lancet Oncol*. 2009;10:516-521.
- [64] Keighley MRB, Williams NS Malignant Tumours of The Anal Canal and Anus. In: Keighley MRB, Williams NS, eds. *Surgery of The Anus Rectum & Colon*. London-Toronto:WB Saunders, 2001. p 1303-1328.
- [65] Malik A, Hull TL, Milsom J. Long-term survivor of anorectal melanoma: report of a case. *Dis Colon Rectum* 2002 ; 45:1412-1415.
- [66] Thibault C, Sagar P, Nivatvongs S. Anorectal melanoma: an incurable disease? *Dis Colon Rectum* 1997; 40: 661-667.
- [67] Brady MS, Kavolius JP, Quan SH. Anorectal melanoma. A 64 –year experience at Memorial Sloan-Kettering Cancer Center. *Dis Colon Rectum* 1995; 38: 146-151
- [68] Fripp VT, Esquivel J, Cerruto CA. Perianal melanoma disguised as hemorrhoids: case report and discussion. *J Natl Med Assoc* 2005; 97 :726-31.
- [69] G Stanojević., Z Krivokapić., M Kontić., G Barišić., M Stojanović., M Jeremić Hirurgija rektuma i anusa. In: Jeremić M (ed) *Abdominalna hirurgija II*, Medicinski fakultet Niš; 2009. p771-847.
- [70] Roumen RMH. Anorectal melanoma in The Netherlands:a report of 63 patients. *Eur J Surg Oncol* 1996; 22: 598-601.
- [71] Malik A, Hull TL, Floruta C. What is the best surgical treatment for anorectal melanoma ? *Int J Colorectal Dis* 2004 ; 19:121-123.

- [72] Kelly P, Zagars GK, Cormier JN, Ross MI, Guadagnolo AB. Sphincter-Sparing Local Excision and Hypofractionated Radiation Therapy for Anorectal Melanoma. *Cancer* 2011;117:4747–4755
- [73] Weyandt GH, Egget AO, Houf M, Raulf F, Brocker EB, Becker JC. Anorectal melanoma: surgical management guidelines according to tumour thickness. *Br J Cancer* 2003; 89 :2019-2022.
- [74] G Stanojevic, Z Rancic, M, Jovanovic, M Stojanovic, D Mihailovic, B Brankovic. Melanoma of the anal canal. *Acta Chir Yugoslavica* 2006; (3): 83-85.
- [75] Longo WE, Vernava AM, Wade TP, Coplin MA, Virgo KS, Johnson FE. Rare anal canal cancers in the U.S. veteran: patterns of disease and results of treatment. *Am Surg* 1995; 61:495-500.
- [76] Gordon Ph. Malignant neoplasms of the Rectum. In: Gordon Ph, Nivatvongs S, (eds) *Principles and Practice of the Surgery for the Colon Rectum and Anus*. Informa Healthcare, New York, London; 2007. p 645-742.
- [77] Singh O, Gupta SS, Mathur RK. A rare case of primary solid intrarectal dermoid. *Saudi J Gastroenterol*. 2011; 17(1):74-76.
- [78] G Stanojević, Z Krivokapić, B Branković, M Nestorović. Retki tumori rektuma. In: Krivokapić Z (ed) *Karcinom rektuma*. Zavod za udžbenike, Beograd; 2012. p 513-528.
- [79] Braumann C, Guenther N, Charalambos M, Junghans T. Schwannoma of the colon mimicking carcinoma: a case report and literature review. *Int J Colorectal Dis* 2007; 22:1547–1548.
- [80] Laser A. Adenocarcinoma of the prostate involving the rectum. *Dis Colon Rectum* 1978; 21:23-25
- [81] Christodouloupoulos JB, Papaionnou AN, Drakopoulou EP, et al. Carcinoma of the cervix presenting with the rectal symptomatology: Report of three cases. *Dis Colon Rectum* 1972; 15: 373-376
- [82] Cervi G, Vettoretto N, Vinco A, et al. Rectal localization of the metastatic lobular breast cancer: report of a case. *Dis Colon Rectum* 2001; 44:453-455.
- [83] Rosito MA, Damin DC, Lazzaron AR, et al. Metastatic renal cell carcinoma involving the rectum. *Int J Colorectal Dis* 2002; 17:359-361.
- [84] Stojanovic MP, Radojkovic M, Jeremic LM, Zlatic AV, Stanojevic GZ, Jovanovic MA, Kostov MS, Katic VP. Malignant schwannoma of the pancreas involving transversal colon treated with en-bloc resection. *World J Gastroenterol* 2010;16:119-122.

