

We are IntechOpen, the world's leading publisher of Open Access books Built by scientists, for scientists

6,900

Open access books available

185,000

International authors and editors

200M

Downloads

Our authors are among the

154

Countries delivered to

TOP 1%

most cited scientists

12.2%

Contributors from top 500 universities



WEB OF SCIENCE™

Selection of our books indexed in the Book Citation Index
in Web of Science™ Core Collection (BKCI)

Interested in publishing with us?
Contact book.department@intechopen.com

Numbers displayed above are based on latest data collected.
For more information visit www.intechopen.com



Single-Incision Laparoscopic Colectomy: A New Era in the Treatment of Colorectal Cancer?

Fabio Cianchi, Fabio Staderini and Benedetta Badii

Additional information is available at the end of the chapter

<http://dx.doi.org/10.5772/56871>

1. Introduction

The laparoscopic technique has been enthusiastically applied to the resection of colorectal cancer for more than 15 years [1]. There is evidence that laparoscopy for colorectal cancer offers the opportunity for a meticulous dissection of the mesocolon and mesorectum under direct vision while facilitating a true no-touch technique [2]. Additional benefits, such as less postoperative pain, reduced need for postoperative analgesia, less ileus, shorter hospital stay, less blood loss, and better cosmesis are also well documented [3,4].

During recent years, great effort has been made to minimize parietal trauma for cosmetic reasons and to further reduce surgery-related pain and morbidity. New techniques, such as natural orifice transluminal endoscopic surgery (NOTES) [5] have been developed in order to reach the goal of “scarless” surgery. Although NOTES actually allows for no scarring of the body surface, it has several disadvantages and limitations with the currently available instruments, including limited access, less familiar working angles and operative approaches. Furthermore, it is associated with possible complications caused by opening of the stomach, colon or vagina, and may not be fully suitable or safe for advanced procedures, such as colectomies [6].

Single incision laparoscopic surgery (SILS) is currently regarded as the next major advance in minimally invasive surgical approaches to colorectal disease that is more feasible for generalized use [7-10]. SILS reduces the invasiveness of laparoscopic conventional surgery (LCS) by decreasing the number of incisions and ports through the abdominal wall. This theoretically could provide important clinical advantages, including less postoperative pain, reduction of port-site associated morbidity (such as wound infection, bleeding, visceral injury and port site herniation), quicker recovery and shorter hospital stay. The small incision through the abdominal wall allows for “scarless” surgery as the wound is usually hidden within the

umbilicus, thus providing potentially better cosmesis. Moreover, SILS permits surgeons to use familiar standard laparoscopic instruments but also perform complex procedures, such as colorectal operations, which require extraction of large surgical specimens or intestinal anastomosis.

2. Technical aspects of SILS

SILS was first reported in 1992 by gynecologists who performed single-incision hysterectomy [11]. The performance of the first transumbilical cholecystectomy was published in 1999 [12] and the first single-incision appendectomy was reported in 1998 [13]. The use of SILS in colorectal surgery was first reported in 2008 by Remzi and co-workers [8] and Bucher and colleagues [14].

Since these first reports, it has been evident that SILS raises a number of specific new challenges compared with LCS. The skills required for SILS are different from those needed in conventional multiport laparoscopy, even for experienced laparoscopic surgeons [15]. The handling of straight instruments in parallel with the laparoscope through a small single incision decreases the freedom of movement for the surgeon, and complicates the holding of the laparoscope for the assistant and instruments for the surgeon. The most outstanding technical challenges involved in SILS are the following:

1. Loss of triangulation with straight instruments: the loss of this dogmatic principle of laparoscopic surgery often imposes the need to operate with crossed hands and does not allow an ergonomically favorable position for the surgeon and assistants. The inherent technical challenge is that the visual axis becomes more axial or in-line, so a movement of the camera often results in a inadvertent movement of an adjacent instrument, thus increasing the difficulty of performing even relatively simple tasks.
2. Restricted number of working instruments and thus difficulty of achieving correct exposure and the necessary traction to tissues.
3. Restricted external working space: the multiple instruments and laparoscopes required for a procedure are competing for the same space at the fulcrum of the entry port, causing external hand collisions and difficulty with instrument tip manipulation internally.
4. Difficulty in maintaining pneumoperitoneum.
5. Requirement of training and adjustment.

New operative hardware is being developed to facilitate the technique [16]. Many of the big healthcare manufacturers have developed multilumen access devices to allow for the insertion of several instruments through a single large fascial incision (Figure 1).

Initially, these devices offered three openings with limited gas inflow and outflow, but we are now seeing revision of the devices, incorporating more access ports so standard laparoscopic dissection techniques can be utilized. Newly designed equipment, such as




Figure 1. Single port systems: (a) Uni-x (Pnavel Systems, Morganville, New Jersey, USA); (b) X-Cone (Karl Storz, Tuttlingen, Germany); (c) Endo-Cone (Karl Storz, Tuttlingen, Germany); (d) SILS Port (Covidien, Norwalk, Connecticut, USA); (e) Olympus TriPort + (Advanced Surgical Concepts, Bray, Ireland).

articulating or curved instruments and flexible scopes, have been introduced to recreate triangulation (Figure 2).

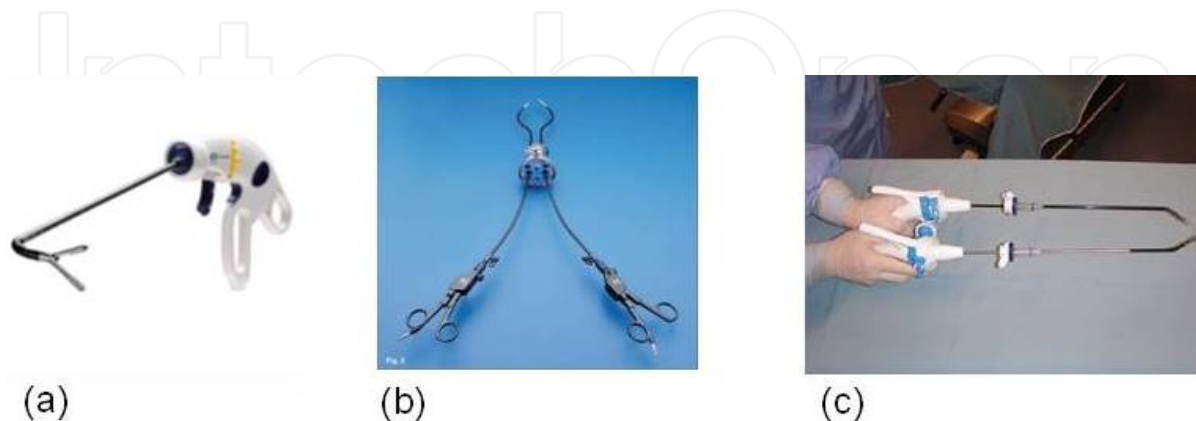


Figure 2. Articulating and curved instruments for SILS: (a) SILS Hand Instrument (Covidien, Norwalk, Connecticut, USA); (b) The Cuschieri Coaxial Deviating Instruments (Karl Storz, Tuttlingen, Germany); (c) Cambridge Endo Instruments (Cambridge Endoscopic Devices, Framingham, Massachusetts, USA).

Moreover, the introduction of an extra-long, 5 mm laparoscope allows placement of the camera on a different plane from the other instruments and help in moving the operator's hand further apart to avoid handle collision (Figure 3) [17]. All these devices have made single site surgery easier and more efficient.



Figure 3. Extra-long, 5 mm, 30° laparoscope (Karl Storz, Tuttlingen, Germany).

3. Feasibility and safety of single-incision colectomy

All the challenges encountered with single-port surgery are magnified with colorectal procedures. Unlike laparoscopic cholecystectomy or appendicectomy, which involve surgery in only one abdominal quadrant, single-incision laparoscopic colectomy often requires operating in different abdominal quadrants. In addition, the need for adequate oncological margins and the creation of a tension-free anastomosis are essential. Although the use of this new approach for complex colorectal procedures might understandably be viewed as difficult to implement, over the past few years there has been significant interest in SILS for colonic resections in both benign and malignant conditions. In fact, between 2008 and 2012, a nearly 7-fold increase occurred in the number of articles related to single-port colorectal surgery [18-20]. Unfortunately, the currently available literature relating to the technique includes mostly case reports or small case series describing the feasibility, safety and technical difficulties of different operations [21-42]. There are very few studies comparing SILS to LCS and there is a need for randomized controlled trials to definitively establish that SILS is no different from standard laparoscopic surgery in terms of completion rates, complications and oncological adequacy but with the advantage of being more cosmetic with subsequently reduced morbidities including pain [43]. The studies published to date have a number of other flaws limiting their impact. These include low sample size, selection bias and difficulty in blinding the patients enrolled. The vast majority of studies involve a very carefully selected SILS cohort of uncomplicated cases, which significantly limits their generalization.

The most significant datum emerging from the literature is that colonic SILS has been offered to date to a highly selected group of patients [18,19]. This selection is based on two main parameters: body mass index (BMI) that is an indirect measure of visceral fat, and tumor site, that is directly linked to the type of surgical procedure.

It is well known that visceral fat is one the most critical factors in the identification of the correct surgical plane in laparoscopic surgery [44]. This concept is obviously amplified in SILS and visceral obesity is reported as the primary cause of conversion to multiport laparoscopy in most studies [45]. Therefore it is understandable that most patients who are candidates for this

type of surgery had a low BMI. Makino et al. [18] have reviewed 23 studies with a total of 378 patients undergoing single-port colectomy. The mean value of BMI was 25.5 kg/m² in these patients. Similar results have been found by Fung et al. [19] in their recent review. These authors have analyzed 38 colonic SILS articles containing 565 patients and the median BMI was 25.8 kg/m². On the basis of these findings, some studies have suggested the use of preoperative abdominal computed tomography to predict accurately the pattern of visceral fat, allowing better selection of patients for SILS colectomy and reducing the number of conversions [44].

The other factor that has markedly influenced the currently available data on SILS for colorectal cancer is the type of surgical procedure. Makino et al. [18] have reported that 279 (73.8%) of the 378 procedures analyzed in their review were right hemicolectomy, followed by sigmoidectomy (n = 27), performed essentially for diverticular disease, and anterior resection of the rectum (n = 20). Moreover, a high number of published studies have specifically limited the analysis of safety, feasibility and short-term results to only single-port right hemicolectomy [14,25,32-38,42,45-48], thus demonstrating that this type of procedure is the least complex to perform with the single-port technique at the beginning of the experience. Actually, right hemicolectomy involves surgery only in one/two quadrants while left procedures require operating in a multitude of different and opposite abdominal quadrants, from the hypochondrium for splenic flexure mobilization to the pelvis for a total mesorectal excision (TME). Moreover, in right hemicolectomy the surgeon has the possibility of creating an extracorporeal intestinal anastomosis through umbilical access while in left colectomies and anterior resection of the rectum the anastomosis is intracorporeal, thus augmenting the complexity of the procedure.

These considerations clearly show that there is an inevitable case-selection bias in assessing the outcomes of colo-rectal SILS from published studies. Although randomized controlled trials comparing single-port and multi-port right hemicolectomy have not been reported yet, the most significant data available to date relate to this type of procedure. In 2012, the two largest experiences with single-port right hemicolectomies in a single institution have been reported. Waters et al. [49] analyzed the short-term outcomes with single-incision right hemicolectomy in 100 patients. Operative indications were oncological in 92 patients, 57 for adenocarcinoma and 35 for polyps not suitable for endoscopic removal. Morbidity (13%) and mortality (1%) rates were acceptable as well as operative time (median value, 105 minutes) and conversion rate to multiport or open procedures (2% and 4%, respectively). Most importantly, there was no compromise of oncological adequacy with no positive tumor margins and a mean number of 18 lymph nodes retrieved and examined in the surgical specimens. Interestingly, patients with a wide range of BMI measurements were offered single-incision right hemicolectomy, with the largest approaching superobesity at a BMI of 46 kg/m² and a mean patient BMI of 28. Unfortunately, no results regarding postoperative pain, cosmetic results or direct comparison with the multi-port laparoscopic approach were reported.

Chew et al. [50] have reported the short outcomes of single-incision laparoscopic hemicolectomy in 40 consecutive patients. These results were compared with those of 104 conventional laparoscopic hemicolectomies. Indications for surgery were oncological in the majority of

patients in the two groups. The authors found that single-incision right hemicolectomy is a feasible and safe procedure with equivalent outcomes in terms of operative time, oncological adequacy, postoperative morbidity, and conversions when compared with conventional laparoscopic right hemicolectomy. In particular, there were no differences in lymph node retrieval (median value of 18 and 19 lymph nodes for multi-port and single-port surgery, respectively) and resection margin clearance.

The data regarding left sided procedures, in particular anterior resection of the rectum for cancer, are much more limited. This is mainly due to the complexity of these procedures, in particular some surgical steps such as mobilizing the splenic flexure and dissection of the mesorectum. The fairly great distance of the spleen and the deep pelvis from the umbilicus amplify the difficulty of creating instrument triangulation, especially when standard, straight laparoscopic instruments are used. Even adequate traction of the rectum and stapling procedures have been associated with technical difficulties and adjunctive methods of traction and suspension such as transparietal suture, are frequently needed to achieve adequate surgical exposure [51-56]. Bulut et al. [57] have recently reported their early experience in single-incision surgery for rectal cancer treatment. This study was conducted on 10, highly selected patients: the mean tumor diameter was very small (3.2 cm), BMI was ≤ 25 in all patients and 8 of them were females, thus providing the advantages of a wide pelvis and relative lack of visceral fat. Although the authors stated that single-incision surgery for rectal cancer can be performed safely in this kind of patient, the overall mean operation time was quite long (240 min) and 6 patients received stomas (4 had diverting ileostomy after anterior resection of the rectum and 2 had colostomy after Hartmann procedure and abdominoperineal resection). Moreover, mesorectum excision was classified as nearly complete in 4 patients and the median number of examined lymph nodes was quite low, namely 14.

One of the most challenging maneuvers in single-incision rectal surgery is maintaining an adequate operative field during TME. Uematsu et al. [54] have proposed a new rectum-suspending system composed of a suspending bar and a bowel clamp with an extracorporeal magnetic tool. This apparatus, along with single access through the right iliac fossa instead of the umbilicus, allowed the authors to perform TME and transect the rectum by ensuring a proper tension. Nevertheless, the proposed new technique is actually complex and, as the authors stated, is not recommended for males with narrow pelvis or obese individuals or when mobilization of the splenic flexure is required because of the distance between the spleen and the single access through the right iliac fossa. Altogether, these data clearly show that some unresolved issues still remain in performing SILS for the treatment of rectal cancer.

There are more data, which are somewhat more reliable regarding other less complex left-sided procedures, such as left hemicolectomy or sigmoidectomy [52,58-60]. In fact, sigmoidectomy is the most frequent procedure performed for benign left-side pathology, predominantly diverticular disease or large colonic polyps not suitable for endoscopic removal. Recently, Vestweber et al. [61] have reported the largest series of patients undergoing single-incision colorectal surgery in a single institution. One hundred and fifty out of 244 procedures were sigmoidectomy ($n = 145$) with left hemicolectomies ($n = 4$) and high anterior resection of the rectum ($n = 1$). Most of these patients were operated on for diverticular disease

(n = 142) followed by colonic polyps (n = 4) and colonic cancer (n = 4). The mean operative time for left-sided procedures was 146 ± 48 min and in all cases standard straight, non-articulating laparoscopic instruments along with ultrasonic or radiofrequency dissector/sealer were used. It seems that the authors did not experience any particular technical problems in performing these types of procedures that do not actually need wide splenic flexure mobilization or mesorectal dissection. The fairly higher incidence of early postoperative complications (12.6%) than rates stated in the literature, was imputed to the high rate of severe, complicated diverticular disease rather than to the complexity of single-incision procedure.

The literature concerning subtotal colectomy or proctocolectomy (with or without ileoanal anastomosis), at this time consists only of case reports and a few small case series [62-68]. The predominant indication for this type of operation has been ulcerative colitis followed by polyposis coli [64,65,67]. Overall, 36 single-incision total colectomies have been reported in the literature: these studies have demonstrated the feasibility and safety of single-incision technique even in these more complex colonic procedures but cannot provide any comparative results with traditional laparoscopy. It is likely that cosmetic results will be magnified by single-incision total colectomy since patients suffering from ulcerative colitis or polyposis coli are usually young and may prefer a small incision hidden in the umbilicus. If an ileostomy is scheduled, the single incision is usually performed in the right lower quadrant of the abdomen and the terminal ileum is brought out through this port-site, thus minimizing the traumatic and cosmetic impact of the procedure.

4. Comparison between single-incision and conventional laparoscopic colectomy

As all these data indicate, there are still several limitations to an analysis of the adequacy of single-incision technique in the treatment of colorectal cancer. The most important limiting factor in the interpretation of reported outcomes is the careful selection of patients, with an almost 3-fold predominance of right-sided pathology, a low to average BMI and non-bulky colonic disease. If this case-selection bias is taken into account and the oncological adequacy of a single-incision procedure is hypothetically accepted, this innovation would be justified only in the presence of clear short-term benefits over conventional laparoscopic colonic surgery. These benefits should comprise a lower complication rate, reduced postoperative pain, faster recovery and better cosmesis.

To date, only two randomized trials have compared short-term outcomes after single-incision and conventional laparoscopic colectomies for colon cancer. In 2011, Huscher et al. [69] reported the results of a study conducted on 32 patients, with 16 in the single-incision and 16 in the conventional laparoscopic group. Although the authors confirmed the safety and technical feasibility of single-incision colectomy, they did not show any superiority of the procedure over conventional laparoscopy in terms of postoperative morbidity, resumption of oral liquid/solid food intake and length of hospital stay.

More recently, Poon et al. [70] reported findings from a randomized controlled trial, which enrolled 50 patients, 25 in each study group. As expected, the patients were carefully selected in regard to BMI (median value, 23.2 kg/m²) and tumor size (< 4 cm). On the contrary, there was a predominance of left-sided procedures, with 14 anterior resections, 1 sigmoidectomy, 2 left hemicolectomies and only 8 right hemicolectomies in the single-incision group. The authors did not find any statistically significant difference in operative outcome and oncological adequacy between the single-incision and the conventional laparoscopic group. Interestingly, they found a lower postoperative pain score and shorter median hospital stay in the single-incision group. Although these findings emerge from a randomized controlled trial, they cannot be considered definitive due the low number of patients involved in the study.

Two recent meta-analyses have addressed the issue of comparison between SILS and LCS for both benign and malignant colorectal diseases [71,72]. Both studies have been published in 2012 and thus have included all the comparative studies published to date with the exception of the above mentioned randomized trial by Poon et al. Notwithstanding the heterogeneity of the analyzed studies (14 by Zhou et al. and 15 by Yang et al) in terms of type of procedures performed, indication for surgery, different patient inclusion and exclusion criteria, neither meta-analysis found any significant difference in the incidence of postoperative complications or operative time between single-incision and conventional laparoscopic colectomy. Importantly, they show that patients undergoing single-incision colectomy had a significantly shorter length of hospital stay, significantly shorter incision length, significantly less estimated blood loss, and significantly more lymph nodes harvested during oncological resections. Unfortunately, the two pooled analyses were not able to compare the pain score due to lack of data, the differences in scoring methods and in postoperative care and pain management in the available reported data. However, at least three studies [48,73,74] show a significant decrease in pain scores for patients undergoing single-incision colectomy compared to conventional laparoscopy. The decreased pain score is likely due to less surgical trauma as a consequence of eliminating the additional ports at separate sites on the abdominal wall. There is no meta-analysis regarding cosmetic results due to absence of adequate information on this interesting outcome in the individual studies. Only one study reported cosmetic score results with an advantage for SILS over LCS [23]. However, it is logical to assume that a shorter final incision length in single-incision surgery results in improved cosmetic satisfaction for the majority of the patients.

Another important issue emerging from the literature data is that experienced laparoscopic surgeons have performed almost all single-incision colectomies. This implies that SILS is offered not only to a select group of patients but is also performed by a select group of surgeons. It might appear premature to propose a complex and technically challenging evolution of conventional laparoscopy colectomy when this has yet to be fully accepted as a gold standard in the treatment of colorectal cancer [75]. It must be considered that in 2010, only about 20% of colorectal resections in England and in other countries were performed laparoscopically [76]. Therefore, although the principles of SILS are highly attractive, they might not, at this moment, be transferable and proposed to the general community of surgeons.

The last but not least important concern about single-incision colectomy regards the costs. It is logical to expect an initial increase in costs associated with SILC over conventional laparoscopic surgery since the additional equipment such as single-incision access ports or flexible/articulating instruments are still relatively new. In their analysis of single-incision right-hemicolectomy, Waters et al. [46] found a marginal increase in direct operative cost of US \$310 to \$410 per case. If patients have a shorter length of hospital stay, and consequently, a quicker return to work and normal activity after single-incision surgery, it is likely there will be an improvement in the cost-effectiveness of SILS in the future.

5. Conclusion

Most of the current studies on single-incision colectomy for cancer are observational and lack statistical power due to the relatively low number of patients studied. Although meta-analyses can increase the statistical power by pooling results of all available trials, only randomized, controlled studies can provide high levels of evidence. To date, only two randomized controlled studies have compared short-term results between single-incision and conventional laparoscopic surgery and, unfortunately, even these studies have enrolled a very low number of patients. Bearing in mind these limitations, we can still glean several important factors from these published series:

1. Colonic SILS is technically demanding but the introduction of new specialized equipment including multilumen ports, angled scopes, articulated instruments and instruments of variable length, will eventually reduce this difficulty.
2. Principles of colonic SILS are attractive and applicable in carefully selected groups of patients, namely with right-sided pathology, low BMI and non-bulky tumors.
3. In the hands of experienced laparoscopic surgeons, colonic SILS in the above mentioned patients has been demonstrated to be safe and feasible with rates of surgery-related complications and mortality, operative time and oncological adequacy comparable with those of conventional laparoscopy.
4. Two meta-analyses and one randomized controlled study provide evidence in support of some advantages of SILS over conventional laparoscopy, namely, shorter length of hospital stay, significantly shorter incision length and significantly less estimated blood loss; other hypothesized benefits, such as reduction in postoperative pain and improvement of cosmesis remain unproven.

Further high-powered randomized studies comparing SILS and LCS by using standardized outcome assessment tools are needed to confirm or not the above-mentioned results. But one thing is certain: we will not see the same dramatic clinical advantages with the passage from LCS to SILS as we saw with the advent of laparoscopic technique over open surgery.

Furthermore, the more complex the procedure performed by single-incision surgery, the more likely are there to be advantages in comparison with conventional laparoscopic procedures.

In this prospective, a possible field of investigation might be the assessment of systemic stress response of single-incision versus conventional laparoscopy in colorectal surgery. The reduced parietal trauma and manipulation of the peritoneum could decrease the postoperative inflammatory response to surgical stress and as a consequence, more efficient immunocompetency against tumor cells might be maintained since the earliest postoperative days [77,78]. All these factors might influence the long-term oncological results of SILS with a potential improvement in survival rates of patients operated on for colorectal cancer.

Author details

Fabio Cianchi^{1,2*}, Fabio Staderini^{1,2} and Benedetta Badii^{1,2}

*Address all correspondence to: fabio.cianchi@unifi.it

1 Department of Surgery and Translational Medicine, Center of Oncological Minimally Invasive Surgery, University of Florence, Italy

2 Unit of Endocrine and Minimally Invasive Surgery, AOU Careggi, Florence, Italy

References

- [1] Jacob BP, Salky B. Laparoscopic colectomy for colon adenocarcinoma: an 11-year retrospective review with 5-year survival. *Surg Endosc* 2005;19 (5) 643-649.
- [2] Lujan HJ, Plasencia G, Jacobs M, Viamonte M 3rd, Hartmann RF. Long-term survival after laparoscopic colon resection for cancer: complete five-year follow-up. *Dis Colon Rectum* 2002;45 (4) 491-501.
- [3] Guillou PJ, Quirke P, Thorpe H, Walker J, Jayne DG, Smith AM, Heath RM, Brown JM; MRC CLASICC trial group. Short-term end points of conventional versus laparoscopic-assisted surgery in patients with colorectal cancer (MRC CLASSICC trial): multicentre, randomized controlled trial. *Lancet* 2005;365 (9472) 1718-1726.
- [4] Clinical outcomes of surgical therapy (COST) study group. A comparison of laparoscopically assisted and open colectomy for colon cancer. *N Engl J Med* 2004;350 (20) 2050-2059.
- [5] Gumbs AA, Fowler D, Milone L, Evanko JC, Ude AO, Stevens P, Bessler M. Transvaginal natural orifice transluminal endoscopic surgery cholecystectomy: early evolution of the technique. *Ann Surg* 2009;249 (6) 908-912

- [6] Brunner W, Schirnhöfer J, Waldstein-Wartenberg N, Frass R, Weiss H. Single incision laparoscopic sigmoid colon resections without visible scar: a novel technique. *Colorectal Dis.* 2010;12(1) 66-70.
- [7] Romanelli JR, Earle DB. Single-port laparoscopic surgery: an overview. *Surg Endosc* 2009;23 (7) 1419-1427.
- [8] Remzi FH, Kirat HT, Kaouk JH, Geisler DP. Single port laparoscopy in colorectal surgery. *Colorectal Dis* 2008;10 (8) 823-826.
- [9] Bucher P, Pugin F, Morel P. Transumbilical single incision laparoscopic sigmoidectomy for benign disease. *Colorectal Dis* 2009;12 (1) 61-65
- [10] Curcillo PG 2nd, Podolsky ER, King SA. The road to reduced port surgery: from single big incisions to single small incisions, and beyond. *World J Surg* 2011;35 (7) 1526-1531
- [11] Pelosi MA, Pelosi MA 3rd. Laparoscopic supracervical hysterectomy using a single-umbilical puncture (mini-laparoscopy). *J Reprod Med.* 1992;37(9) 777-784.
- [12] Bresadola F, Pasqualucci A, Donini A, Chiarandini P, Anania G, Terrosu G, Sistu MA, Pasetto A. Elective transumbilical compared with standard laparoscopic cholecystectomy. *Eur J Surg.* 1999;165(1) 29-34.
- [13] Esposito C. One-trocar appendectomy in pediatric surgery. *Surg Endosc.* 1998;12(2)177-178.
- [14] Bucher P, Pugin F, Morel P. Single port access laparoscopic right hemicolectomy. *Int J Colorectal Dis.* 2008;23(10) 1013-1016
- [15] Islam A, Castellvi AO, Tesfay ST, Castellvi AD, Wright AS, Scott DJ. Early surgeon impressions and technical difficulty associated with laparoendoscopic single-site surgery: a Society of American Gastrointestinal and Endoscopic Surgeons learning center study. *Surg Endosc* 2011;25 (8) 2597-2603.
- [16] Chew MH, Wong MT, Lim BY, Ng KH, Eu KW. Evaluation of current devices in single-incision laparoscopic colorectal surgery: a preliminary experience in 32 consecutive cases. *World J Surg.* 2011;35(4) 873-880.
- [17] Dhumane P, Diana M, Leroy J, Marescaux J. Minimally invasive single-site surgery for the digestive system: a technological review. *J Minim Access Surg* 2011;7 (1) 40-51.
- [18] Makino T, Milsom JW, Lee SW. Feasibility and safety of single-incision laparoscopic colectomy: a systematic review. *Ann Surg.* 2012;255(4) 667-676.
- [19] Fung AK, Aly EH. Systematic review of single-incision laparoscopic colonic surgery. *Br J Surg.* 2012;99(10) 1353-1364.

- [20] Diana M, Dhumane P, Cahill RA, Mortensen N, Leroy J, Marescaux J. Minimal invasive single-site surgery in colorectal procedures: Current state of the art. *J Minim Access Surg*. 2011;7(1) 52-60.
- [21] Bucher P, Pugin F, Morel P. Single-port access laparoscopic radical left colectomy in humans. *Dis Colon Rectum* 2009;52 (10) 1797-1801.
- [22] Brunner W, Schirnhöfer J, Waldstein-Wartenberg N, Frass R, Weiss H. Single incision laparoscopic sigmoid colon resections without visible scar: a novel technique. *Colorectal Dis* 2010;12 (1) 66-70.
- [23] Lee SW, Milsom JW, Nash GM. Single-incision versus multiport laparoscopic right and hand-assisted left colectomy: a case-matched comparison. *Dis Colon Rectum* 2011;54(11) 1355-1361.
- [24] Gash KJ, Goede AC, Chambers W, Greenslade GL, Dixon AR. Laparoendoscopic single-site surgery is feasible in complex colorectal resections and could enable day case colectomy. *Surg Endosc* 2011;25(3) 835-840.
- [25] Keshava A, Mackenzie S, Al-Kubati W. Single-port laparoscopic right colonic resection. *ANZ J Surg* 2010; 80(1-2) 30-32.
- [26] Ross H, Steele S, Whiteford M, Lee S, Albert M, Mutch M et al. Early multi-institution experience with single-incision laparoscopic colectomy. *Dis Colon Rectum* 2011;54 (2) 187-192.
- [27] Lu CC, Lin SE, Chung KC, Rau KM. Comparison of clinical outcome of single incision laparoscopic surgery using a simplified access system with conventional laparoscopic surgery for malignant colorectal disease. *Colorectal Dis* 2012;14 (4) 171-176
- [28] Gaujoux S, Bretagnol F, Ferron M, Panis Y. Single-incision laparoscopic colonic surgery. *Colorectal Dis* 2011;13 (9) 1066-1071
- [29] Geisler D, Garrett T. Single incision laparoscopic colorectal surgery: a single surgeon experience of 102 consecutive cases. *Tech Coloproctol* 2011; 15 (4) 397-401.
- [30] Ramos-Valadez DI, Patel CB, Ragupathi M, Bokhari MB, Pickron TB, Haas EM. Single-incision laparoscopic colectomy: outcomes of an emerging minimally invasive technique. *Int J Colorectal Dis* 2011;26 (6) 761-767.
- [31] van den Boezem PB, Sietses C. Single-incision laparoscopic colorectal surgery, experience with 50 consecutive cases. *J Gastrointest Surg* 2011;15 (11) 1989-1994.
- [32] Adair J, Gromski MA, Lim RB, Nagle D. Single-incision laparoscopic right colectomy: experience with 17 consecutive cases and comparison with multiport laparoscopic right colectomy. *Dis Colon Rectum* 2010;53 (11) 1549-1554.
- [33] Boni L, Dionigi G, Cassinotti E, Di Giuseppe M, Diurni M, Rausei S et al. Single incision laparoscopic right colectomy. *Surg Endosc* 2010;24 (12) 3233-3236.

- [34] Keshava A, Young CJ, Mackenzie S. Single-incision laparoscopic right hemicolectomy. *Br J Surg* 2010;97 (12) 1881–1883.
- [35] Lim YK, Ng KH, Eu KW. Single site laparoscopic right hemicolectomy: an oncological feasible option. *World J Surg Oncol* 2010;8 (8) 79.
- [36] Pietrasanta D, Romano N, Prosperi V, Lorenzetti L, Basili G, Goletti O. Single-incision laparoscopic right colectomy for cancer: a single-centre preliminary experience. *Updates Surg* 2010; 62(2) 111–115.
- [37] O'Connor DJ, Feinberg E, Jang J, Vemulapalli P, Camacho D. Single-incision laparoscopic-assisted right colon resection for cancer. *JSLs* 2010;14 (4) 558–560.
- [38] Ramos-Valadez DI, Patel CB, Ragupathi M, Bartley Pickron T, Haas EM. Single-incision laparoscopic right hemicolectomy: safety and feasibility in a series of consecutive cases. *Surg Endosc* 2010;24 (10) 2613–2616.
- [39] Cianchi F, Qirici E, Trallori G, Mallardi B, Badii B, Perigli G. Single-incision laparoscopic colectomy: technical aspects and short-term results. *Updates Surg* 2011;64(1) 19–23.
- [40] Katsuno G, Fukunaga M, Nagakari K, Yoshikawa S, Ouchi M, Hirasaki Y. Single-incision laparoscopic colectomy for colon cancer: early experience with 31 cases. *Dis Colon Rectum* 2011;54 (6) 705–710.
- [41] Papaconstantinou HT, Thomas JS. Single-incision laparoscopic colectomy for cancer: assessment of oncologic resection and short-term outcomes in a case-matched comparison with standard laparoscopy. *Surgery* 2011;150 (4) 820–807.
- [42] Saber AA, El-Ghazaly TH. Single-incision transumbilical laparoscopic right hemicolectomy using SILS port. *Am Surg* 2011;77 (2) 252–253.
- [43] Arezzo A, Morino M. Endoscopic surgery through single-port incision: time for a trial?. *Surg Endosc*. 2011; 25(6) 1709–1711.
- [44] Tsujinaka S, Konishi F, Kawamura YJ, Saito M, Tajima N, Tanaka O et al. Visceral obesity predicts surgical outcomes after laparoscopic colectomy for sigmoid colon cancer. *Dis Colon Rectum* 2008;51 (12) 1757–1765.
- [45] Chen WT, Chang SC, Chiang HC, Lo WY, Jeng LB, Wu C et al. Single-incision laparoscopic versus conventional laparoscopic right hemicolectomy: a comparison of short-term surgical results. *Surg Endosc* 2011;25 (6) 1887–1892.
- [46] Waters JA, Guzman MJ, Fajardo AD, Selzer DJ, Wiebke EA, Robb BW et al. Single-port laparoscopic right hemicolectomy: a safe alternative to conventional laparoscopy. *Dis Colon Rectum* 2010;53 (11) 1467–1472.
- [47] Wong MT, Ng KH, Ho KS, Eu KW. Single-incision laparoscopic surgery for right hemicolectomy: our initial experience with 10 cases. *Tech Coloproctol* 2010;14 (3) 225–258.

- [48] Papaconstantinou HT, Sharp N, Thomas JS. Single-incision laparoscopic right colectomy: a case-matched comparison with standard laparoscopic and hand-assisted laparoscopic techniques. *J Am Coll Surg* 2011;213 (1) 72–80.
- [49] Waters JA, Rapp BM, Guzman MJ, Jester AL, Selzer DJ, Robb BW, Johansen BJ, Tsai BM, Maun DC, George VV. Single-port laparoscopic right hemicolectomy: the first 100 resections. *Dis Colon Rectum*. 2012;55(2) 134-139
- [50] Chew MH, Chang MH, Tan WS, Wong MT, Tang CL. 1. Conventional laparoscopic versus single-incision laparoscopic right hemicolectomy: a case cohort comparison of short-term outcomes in 144 consecutive cases. *Surg Endosc*. 2012 18. [Epub ahead of print].
- [51] Uematsu D, Akiyama G, Magishi A, Nakamura J, Hotta K. Single-access laparoscopic left and right hemicolectomy combined with extracorporeal magnetic retraction. *Dis Colon Rectum* 2010;53 (6) 944–948.
- [52] Takemasa I, Sekimoto M, Ikeda M, Mizushima T, Yamamoto H, Doki Y, Mori M. Video. Transumbilical single-incision laparoscopic surgery for sigmoid colon cancer. *Surg Endosc* 2010; 24 (1) 2321.
- [53] Law WL, Fan JK, Poon JT. Single incision laparoscopic left colectomy for carcinoma of distal transverse colon. *Colorectal Dis* 2010;12 (7) 698–701.
- [54] Uematsu D, Akiyama G, Narita M, Magishi A. Single-access laparoscopic low anterior resection with vertical suspension of the rectum. *Dis Colon Rectum* 2011;54 (5) 632–637.
- [55] Co CS, Cheung HY, Yau KK, Chung CC, Li M. Combined single-port and endoluminal technique for laparoscopic anterior resection. *Surg Laparosc Endosc Percutan Tech* 2010;20 (4) 253–256.
- [56] Kawahara H, Watanabe K, Ushigome T, Noaki R, Kobayashi S, Yanaga K. Umbilical incision laparoscopic surgery with one assist port for anterior resection. *Dig Surg* 2010;27 (5) 364–366.
- [57] Bulut O, Nielsen CB, Jespersen N. Single-port access laparoscopic surgery for rectal cancer: initial experience with 10 cases. *Dis Colon Rectum*. 2011; 54(7) 803-809
- [58] Remzi FH, Kirat HT, Geisler DP. Laparoscopic single-port colectomy for sigmoid cancer. *Tech Coloproctol* 2010;14 (3) 253–255.
- [59] Uematsu D, Akiyama G, Matsuura M, Hotta K. Single-access laparoscopic colectomy with a novel multiport device in sigmoid colectomy for colon cancer. *Dis Colon Rectum* 2010;53 (4) 496–501.
- [60] Ramos-Valadez DI, Ragupathi M, Nieto J, Patel CB, Miller S, Pickron TB et al. Single-incision versus conventional laparoscopic sigmoid colectomy: a case-matched series. *Surg Endosc* 2012;26 (1) 96–102.

- [61] Vestweber B, Galetin T, Lammerting K, Paul C, Giehl J, Straub E, Kaldowski B, Alfes A, Vestweber KH. Single-incision laparoscopic surgery: outcomes from 224 colonic resections performed at a single center using SILS™. *Surg Endosc*. 2013; 27 (2) 434-442.
- [62] Geisler DP, Condon ET, Remzi FH. Single incision laparoscopic total proctocolectomy with ileopouch anal anastomosis. *Colorectal Dis* 2010;12 (9) 941-943.
- [63] Nagpal A, Soni H, Haribhakti S. Single-incision laparoscopic restorative proctocolectomy with ileal pouch anal anastomosis for ulcerative colitis: first Indian experience and literature review. *Int J Colorectal Dis* 2011;26 (4) 525-526.
- [64] Fichera A, Zoccali M, Gullo R. Single incision ('scarless') laparoscopic total abdominal colectomy with end ileostomy for ulcerative colitis. *J Gastrointest Surg* 2011;15 (7) 1247-1251.
- [65] Cahill RA, Lindsey I, Jones O, Guy R, Mortensen N, Cunningham C. Single-port laparoscopic total colectomy for medically uncontrolled colitis. *Dis Colon Rectum* 2010;53 (8) 1143-1147.
- [66] Geisler DP, Kirat HT, Remzi FH. Single-port laparoscopic total proctocolectomy with ileal pouch-anal anastomosis: initial operative experience. *Surg Endosc* 2011;25 (7) 2175-2178.
- [67] Leblanc F, Makhija R, Champagne BJ, Delaney CP. Single incision laparoscopic total colectomy and proctocolectomy for benign disease: initial experience. *Colorectal Dis* 2011;13 (11) 1290-1293.
- [68] Paranjape C, Ojo OJ, Carne D, Guyton D. Single-incision laparoscopic total colectomy. *JSLs*. 2012;16(1) 27-32.
- [69] Huscher CG, Mingoli A, Sgarzini G, Mereu A, Binda B, Brachini G, Trombetta S. Standard laparoscopic versus single-incision laparoscopic colectomy for cancer: early results of a randomized prospective study. *Am J Surg*. 2012;204(1) 115-120.
- [70] Poon JT, Cheung CW, Fan JK, Lo OS, Law WL. Single-incision versus conventional laparoscopic colectomy for colonic neoplasm: a randomized, controlled trial. *Surg Endosc*. 2012;26(10) 2729-2734.
- [71] Zhou YM, Wu LP, Zhao YF, Xu DH, Li B. Single-incision versus conventional laparoscopy for colorectal disease: a meta-analysis. *Dig Dis Sci*. 2012;57(8) 2103-2112.
- [72] Yang TX, Chua TC. Single-incision laparoscopic colectomy versus conventional multiport laparoscopic colectomy: a meta-analysis of comparative studies. *Int J Colorectal Dis* 2013;28 (1) 89-101.
- [73] Kim SJ, Ryu GO, Choi BJ, Kim JG, Lee KJ, Lee SC, Oh ST. The short-term outcomes of conventional and single-port laparoscopic surgery for colorectal cancer. *Ann Surg*. 2011;254(6) 933-940

- [74] Vasilakis V, Clark CE, Liasis L, Papaconstantinou HT. Noncosmetic benefits of single-incision laparoscopic sigmoid colectomy for diverticular disease: A case-matched comparison with multiport laparoscopic technique. *J Surg Res* 2013; 180 (2) 201-207.
- [75] Hassan I, Advani V. Single incision laparoscopic colon surgery. Is the ride worth the curve? *Colorectal Dis* 2010;12 (9) 847–848.
- [76] National Institute for Health and Clinical Excellence (NICE). NICE Implementation Uptake Report: Laparoscopic Surgery for Colorectal Cancer, 2010; <http://www.nice.org.uk/media/B4D/4A/UptakeReportColorectalCancer.pdf>
- [77] Sammour T, Kahokehr A, Chan S, Booth RJ, Hill AG. The humoral response after laparoscopic versus open colorectal surgery: a meta-analysis *J Surg Res*. 2010;164(1) 28-37.
- [78] Huang C, Huang R, Jiang T, Huang K, Cao J, Qiu Z. Laparoscopic and open resection for colorectal cancer: an evaluation of cellular immunity. *BMC Gastroenterol*. 2010;28(10) 127.