

# We are IntechOpen, the world's leading publisher of Open Access books Built by scientists, for scientists

6,900

Open access books available

186,000

International authors and editors

200M

Downloads

Our authors are among the

154

Countries delivered to

TOP 1%

most cited scientists

12.2%

Contributors from top 500 universities



WEB OF SCIENCE™

Selection of our books indexed in the Book Citation Index  
in Web of Science™ Core Collection (BKCI)

Interested in publishing with us?  
Contact [book.department@intechopen.com](mailto:book.department@intechopen.com)

Numbers displayed above are based on latest data collected.  
For more information visit [www.intechopen.com](http://www.intechopen.com)



---

# Overview of Different Location of Muscle Strain

---

Francisco Arroyo

Additional information is available at the end of the chapter

<http://dx.doi.org/10.5772/56622>

---

## 1. Introduction

Up to 30% or more of all the sports injuries that we deal with in our daily medical practice, including contusions and bruises [1] are injuries to muscle.

Muscular injuries can occur anywhere on our whole body. The treatment methods available to us today are of such a wide variety that the athlete can return to physical activity as soon as possible (in most of the cases) without any permanent damage or secondary reactions.

Many of these injuries are not properly treated due to several factors, for example, physician inexperience or that athletes minimize the injury in their quest to stay in the competition; athletes hide (especially during the clinical evaluation) their pain, which is very important information for the medical doctors to set the guidelines on how to treat the pathology.

Unfortunately, now we have these injuries in children and adolescent athletes because of the availability of high level of competition in all sports even at those ages.

So having the knowledge to make the correct diagnosis in these pathologies is essential for physicians who treat athletes every day.

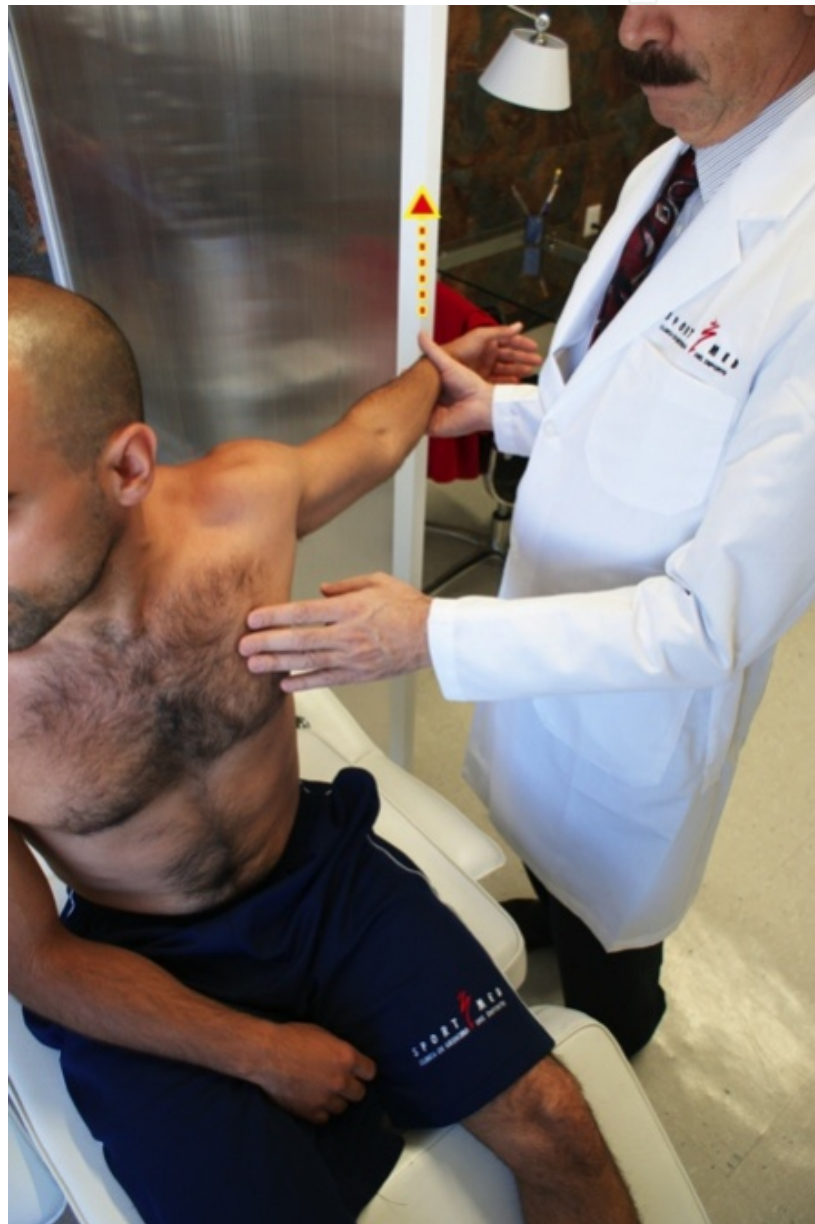## 2. Injury

### 2.1. Pectoral strains

A strained pectoral muscle is actually a slight tear in the chest muscles named pectoral muscles and these two muscles are located at the front of the chest. One is the largest (pectoralis major) and originates from the sternum, ribs and collar bone and goes to the upper part of the humerus and the smallest is the pectoralis minor that finish in the front of the shoulder blade.

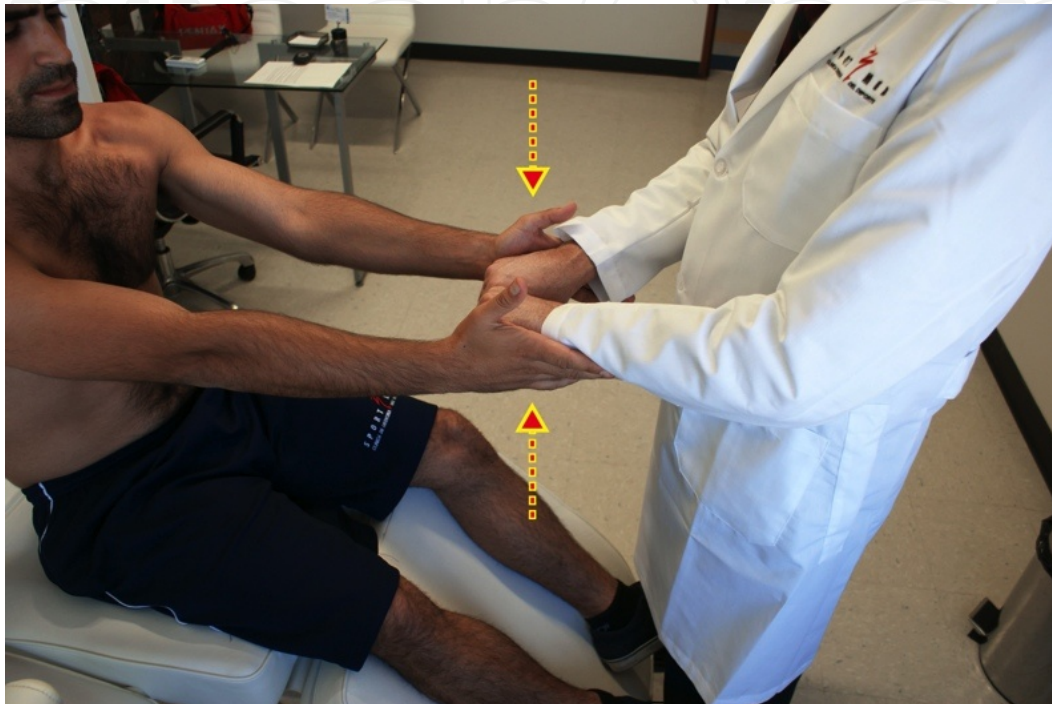
An injury happens when the muscle is stretched too far and the pain can be felt at the same moment or in some cases latter during the cooling down phase after the exercise and sometimes the pain radiates to the upper arm or neck [2].

Diagnosis.- During the physical examination some patients show an obvious swelling and bruising area that is tender under digital palpation and others just have pain when you ask them to move the arms backwards, (Fig. 1) in some others you can ask them to try to do a push up and the patients refers pain over the affected area.



**Figure 1.** With the arm in lateral extension ask the patient to move forward against resistance

Another way to make the diagnosis is to ask the athlete that with the arms extended try to get together the hands and you put your fist between the hands for not allow him to do it (fig. 2)



**Figure 2.** With both arms straighten at front ask the patient to put their hand together against resistance

To assess the severity of the injury an Ultrasound, CT scan or MRI scan may be required.

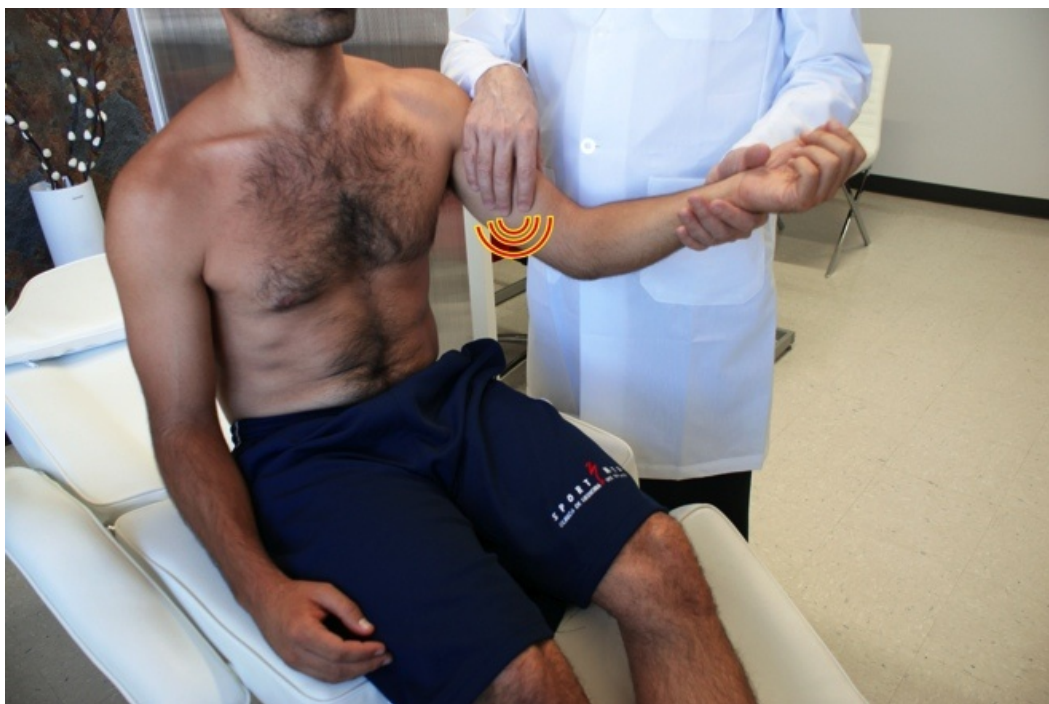## 2.2. Biceps strains

The biceps is located in the front of the upper arm and it is attached to the elbow and the shoulder. When we flex the elbow most of this movement is done by the biceps.

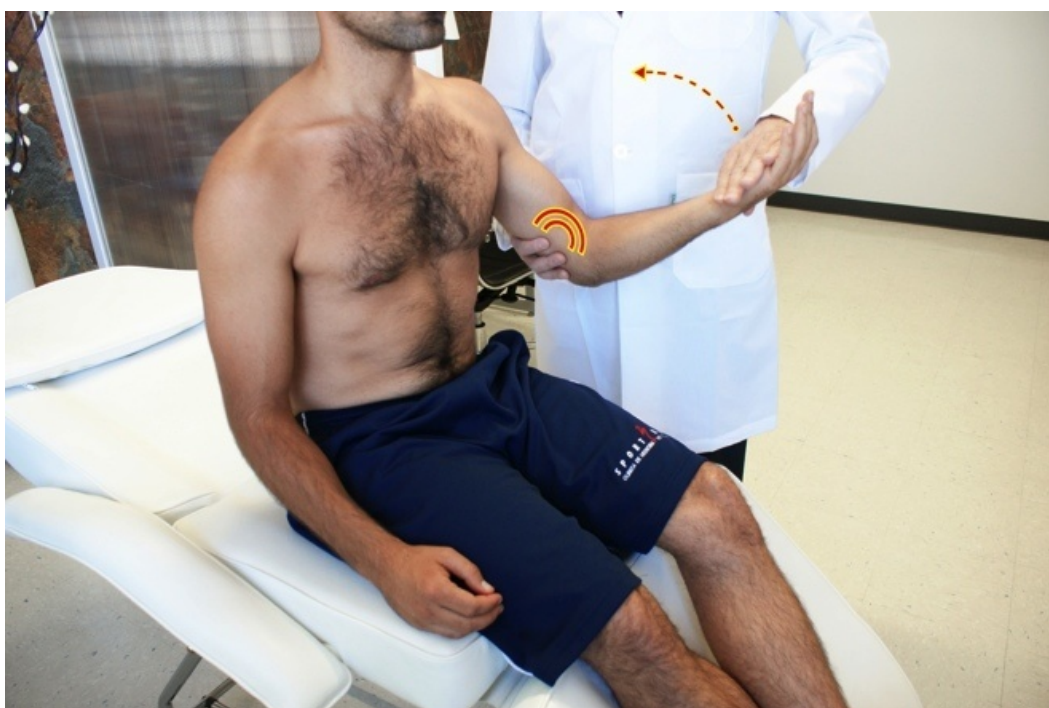Symptoms of a biceps strain include sudden and severe pain at the front of the shoulder and also the athlete can experience swelling, deformity of the muscle and loss of strength, presence of a bruise over the affected area, depending on the severity.

In the physical evaluation with the elbow straighten palpate all along the biceps (fig. 3) ask the patient to flex the elbow with the palm up and tell him not to let you push it toward the floor (fig. 4) an ultrasound study is very useful to assess the severity of the injury because some tears at the level of the elbow more often require surgical repair [3].





**Figure 3.** With the elbow flex at 90° palpate the biceps all along



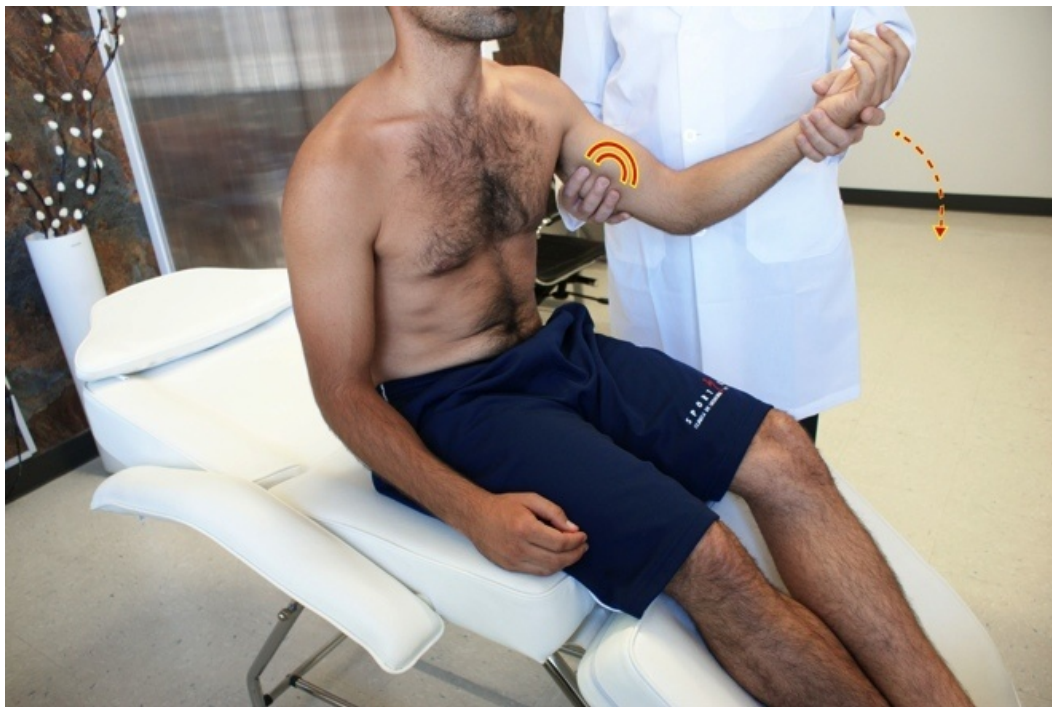**Figure 4. A** With the elbow flex at 90° ask the patient to flex it against resistance

### 3. Triceps strains

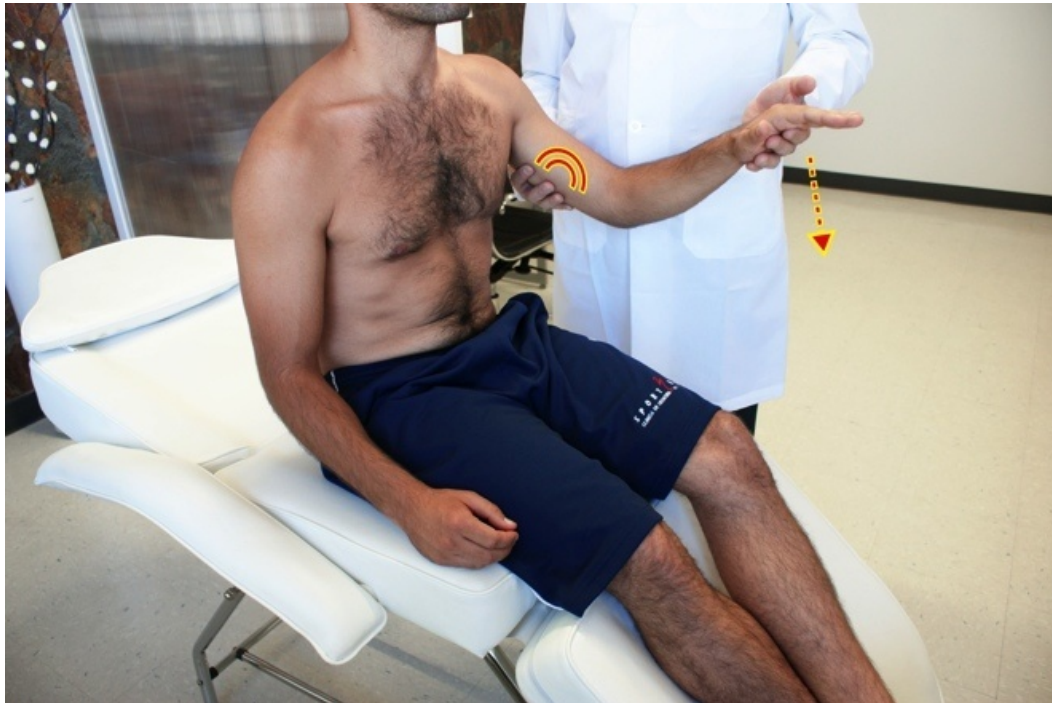The triceps muscle is located in the back side of the upper arm and its main action is straightening the elbow. A triceps strain can be a simple overstretch to a partial or complete tear. This pathology may result from overusing or in a single boost of force.

When this occurred the symptoms are pain, stiffness, tenderness, edema, in some cases bruising and loss of strength.

During the physical examination the patient refers pain over the area and the palpation can be done with the elbow in flexion to relax the muscle (fig. 5), also if we ask the athlete to straighten the elbow with the palm down against resistance (fig. 6). Some patients require surgical treatment depends on the site and the severity of the injury. [4]



**Figure 5.** With the elbow flex at 90° palpate the triceps all along



**Figure 6.** With the elbow at 90° and the palm facing down ask the patient straighten the elbow against resistance

#### 4. Medial flexor pronator muscles strain) medial flexor pronator strain

This is an injury that occurs on the inside of the elbow after either direct trauma as in wrestling or baseball or from valgus strain in golf or football soccer.

The injury occurs to the forearm muscles that attach to the inside (medial) aspect of the elbow; the first indication of injury is pain, swelling, or even in an acute hematoma may be present.

Physical examination should determine the exact location of the injury according to pain (using digital palpation). The maneuvers to be performed include:

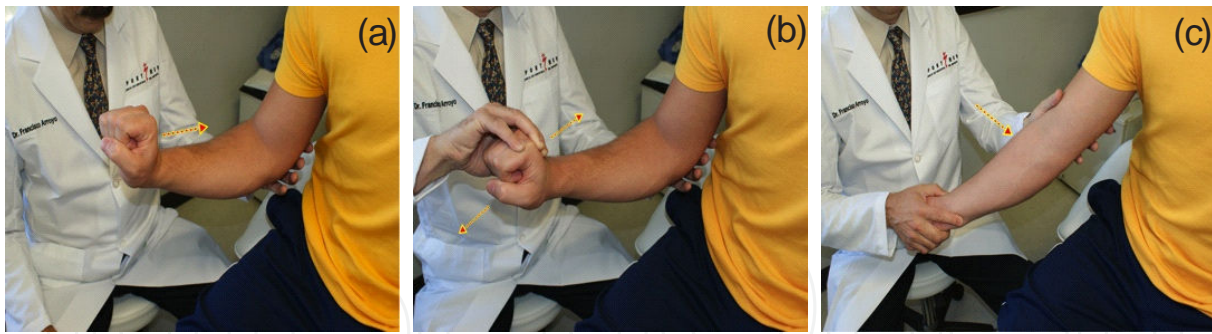Ask patient to perform wrist flexion and pronation. Pain is often referred into the affected area (figure 7a).

With the elbow at 45° of flexion, movements of flexion, extension, pronation, and valgus stress are carried to determine the location and magnitude of the injury.(figure 7c)

These maneuvers should be done on the contralateral elbow as well to see how great is the difference in pain intensity and location as well as motion between the two joints.

Another maneuver that can be used to assess pain is forced flexion of the wrist against resistance (figure 7b).





**Figure 7.** a) Ask the patient to flex the wrist; b) Ask the patient flex the wrist against resistance; c) Apply force to the lateral side of the elbow to take it to a valgus position

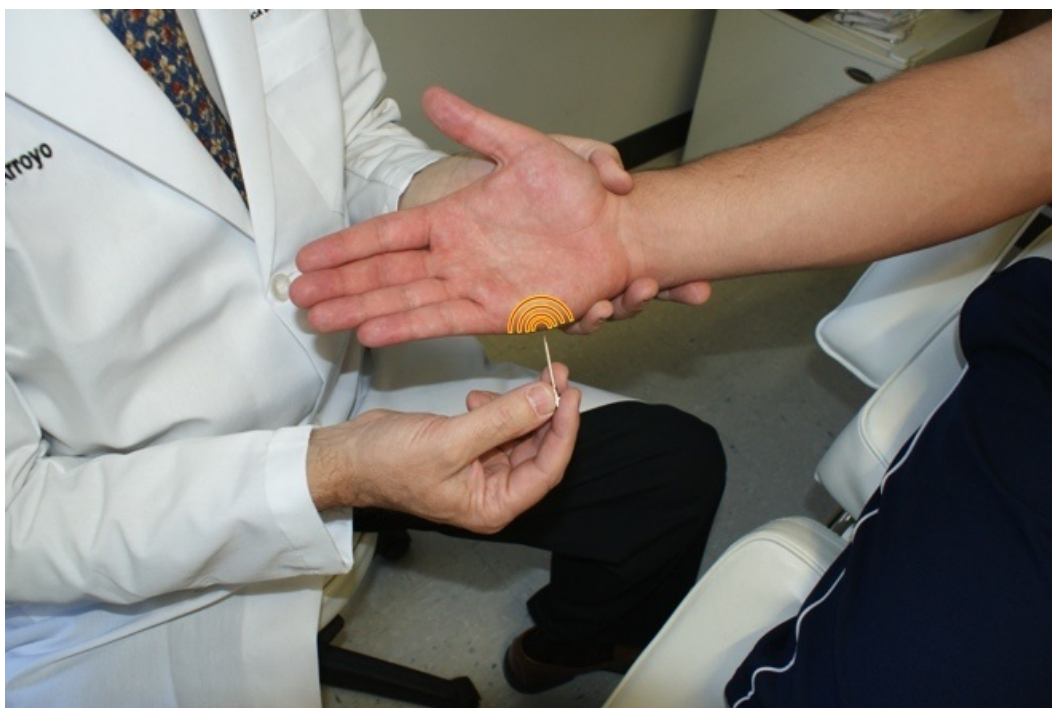You can define three grades of injury:

First.-There is damage to a small fraction of muscle fibers.

Second.-This can include an avulsion of the muscles insertion

Third.-There is a broader breakdown of muscle fibers. There may also be the presence of an avulsion fracture cause by detachment of the tendon in the affected area.

One complication may be an injury to the ulnar nerve. If this happens the sensitivity of the little finger and the ring finger are affected [5] to be sure to perform a small sensitivity neurological examination (figure 8).



**Figure 8.** Test the sensitivity neurological area of the little finger using a small needle



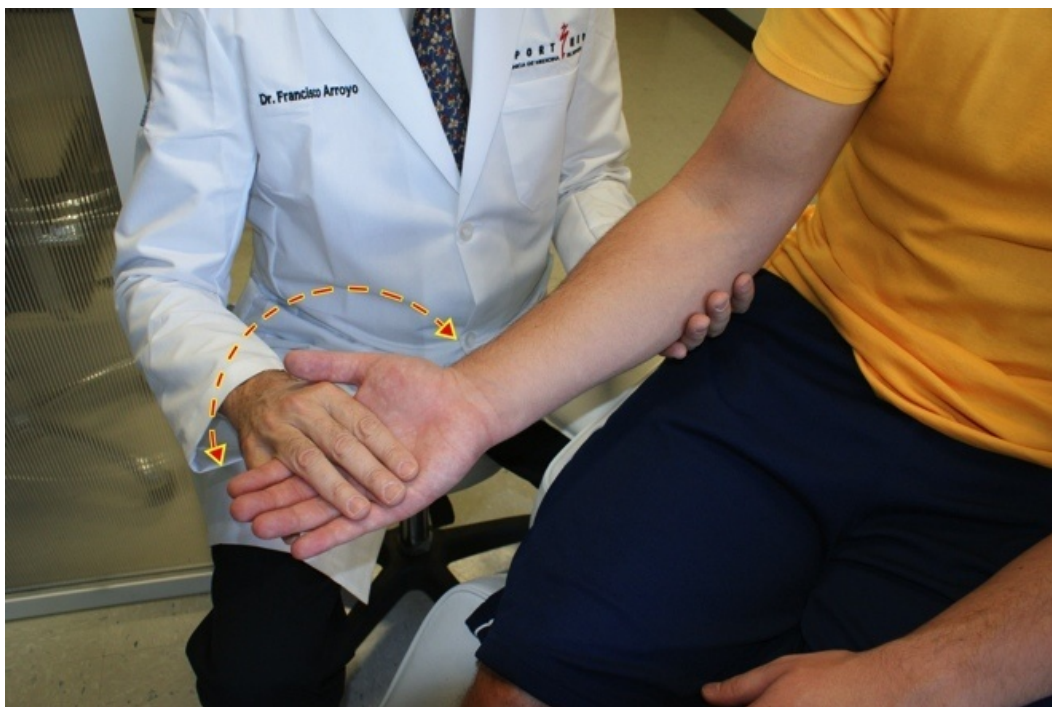## 5. Flexor muscle strain

Another common injury is the forearm flexor injury.

For example in sports requiring abduction and external rotation after a sudden adduction internal rotation of the can cause forearm flexor muscles to be injured (e.g., baseball, swimming, etc.)

Once injured, there will be tenderness around over the forearm flexor muscles.

The pain from this injury can be provoked by asking the athlete to flex the wrist against resistance; pain should arise in the medial side (figure 9).



**Figure 9.** With the wrist straighten ask the patient to flex it against resistance

In some athletes (those with a pronator injury) a hematoma can be present. Pain can be provoked with pressure on the lateral side of the elbow joint forcing the elbow into valgus.

## 6. Abdominal muscle strain

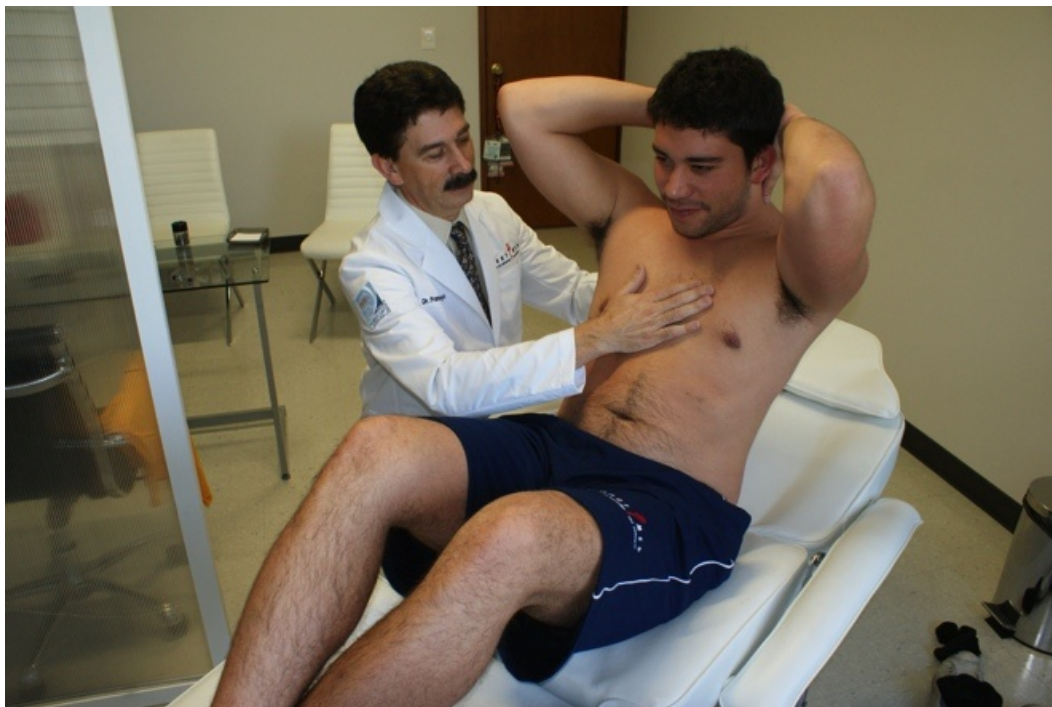Several muscles converge in the abdomen: rectus, internal and external obliques and also the transverse and the pyramid

On physical examination is difficult to establish the diagnosis because beneath these muscles is the abdominal cavity that contains different organs that also can cause pain.

Not all the abdominal pain has an muscle origin and it is our challenge to know what signs or symptoms differentiates the different pathologies.

Whenever an athlete refers abdominal pain, we should start the physical examination away from the zone of pain and gradually get closer to the area that the athlete describes as being the most annoying in appearance, swelling, deformity, tumors, etc.

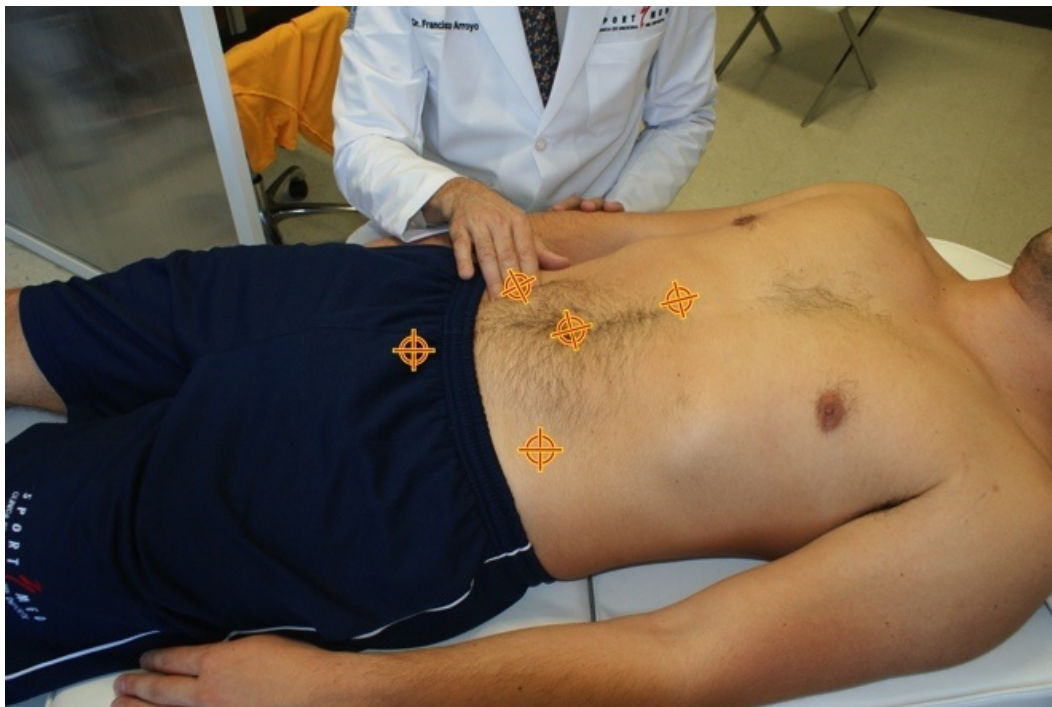
If we suspect a muscular abdominal tear [6], part of the physical examination would be to ask the athlete to do a sit up and putting an effort on the abdominal area. There will be patients in which you have to ask the athlete to contract the abs against resistance in order to get a painful response (figure 10).



**Figure 10.** In a sit up position ask the patient to hold it against resistance

Other conditions to rule out are:

Appendicitis.- IPain localized to the bottom and right side of the patient, this is called McBurney's point. (Right lower quadrant). Pain may also be around the navel and usually is accompanied by nausea and vomiting and will likely have evidence of malaise and in some cases fever (figure 11).



**Figure 11.** The doctor's hand is palpating the Mc Burney's point which is painful at the pressure in appendicitis, all the other target points usually are just related to pelvic inflammation.

**PELVIC INFLAMMATORY DISEASE.**-This disease occurs mostly in women who may have a pelvic infection. Pain may be related to both iliac fossae.

**GASTRITIS, COLITIS, ULCER.**- Pain may have been present for many hours of duration coincident with swelling, presence of abdominal gas, bloating, and burning over the stomach area. Pain can also be referred from the colon.

In abdominal pathologies unrelated to the muscle and if we have any doubt, it is best to refer the athlete to a specialist and not cause more damage by waiting and see if the symptoms disappear. This is a very valuable time if the cause is pain comes from an organ of the abdominal cavity.

## 7. Groin muscle strain

For example in soccer players the incidence of groin injury is approximately 5% to 6.2%, [7].

If we talk about the local anatomy, there are four muscles that converge at the same point and any of them could be torn or stretched so even though the symptoms may be closely related the source, pain could be localized to any of these muscles: rectus femoris, adductors, psoas major or sartorius.

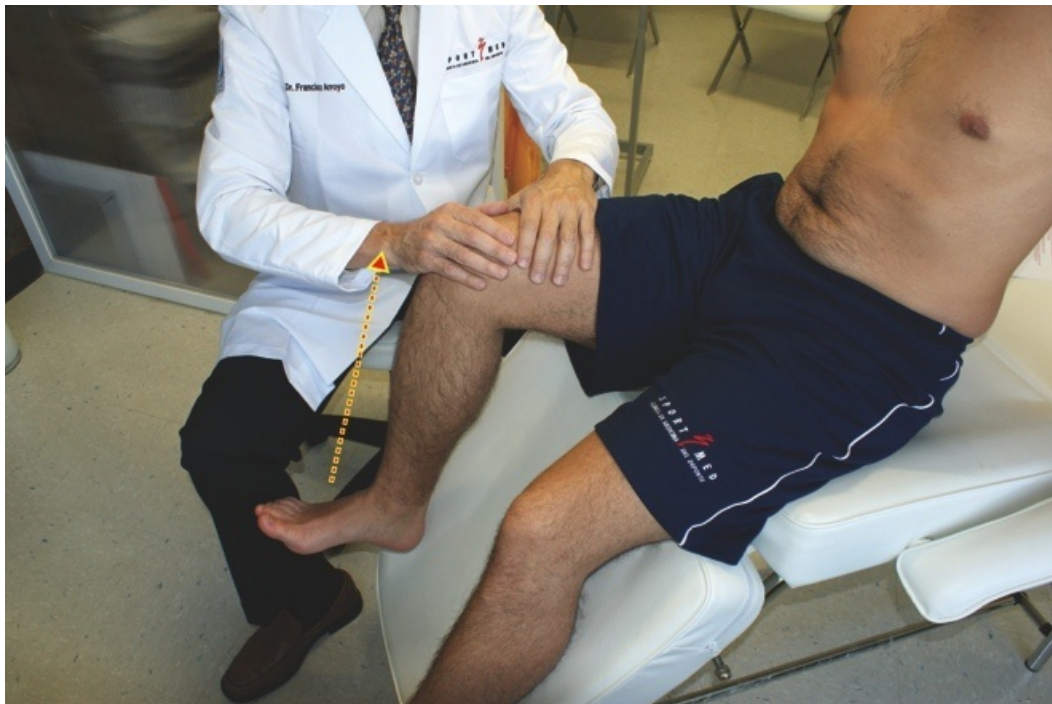Remember that these muscles are involved in hip flexion so in the physical examination, we must look for pain when the athlete is flexing the hip.



The athlete may have exacerbation and decrease in symptoms while in some cases the pain is only present when there are changes in the speed or change of direction. It is not unusual for the athlete to have no pain when running forward without changing direction.

The symptoms can be vague and often undefined because of the convergence of various anatomical structures. Pain could be due to a sport's hernia, osteitis pubis, nerve pain (neurally referred pain), bursitis, tumors, etc.

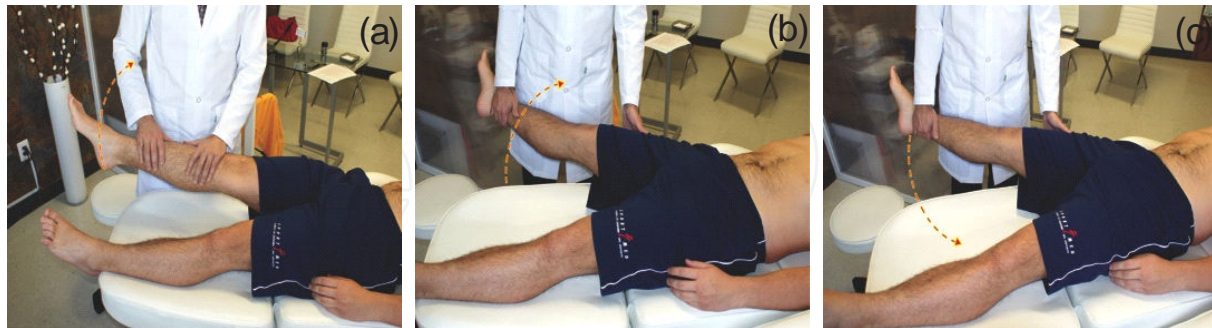A physical examination can begin examining the painful area to rule out that pain that could be from a node or an inguinal hernia (in all the cases there is tenderness). If the lesion is muscular in origin, pain should increase when the athlete is asked the patient to perform hip flexion against resistance (figure 12).



**Figure 12.** With the knee flex at 90° ask the patient to raise it against resistance

Other provocative maneuvers are to have the athlete lift the leg (with the knee extended) (figure 13a), against resistance or the examiner takes the leg in extension and do some abduction movement (figure 13b, 13c). Si hacemos este movimiento de forma contralateral con la pierna no involucrada podremos ver que el rango de movimiento está limitado en la pierna afectada. Similar tests of the contralateral (uninvolved) leg will show just how much range of motion is limited in the affected leg.





**Figure 13.** a) Ask the patient to rise the leg straighten against resistance; b) Take the leg straighten to an abduction position till the pain is triggered; c) Ask the patient to move the leg inward (adduction) against resistance

An initial recommendation is for rest to allow time for the symptoms to be minimized. Treatment is based on a good diagnosis and since here we encounter the convergence of various etiologies of pain, any misdiagnosis could lead to chronic pain that can result in limitation of the athlete's sports performance

## 8. Lumbar strains

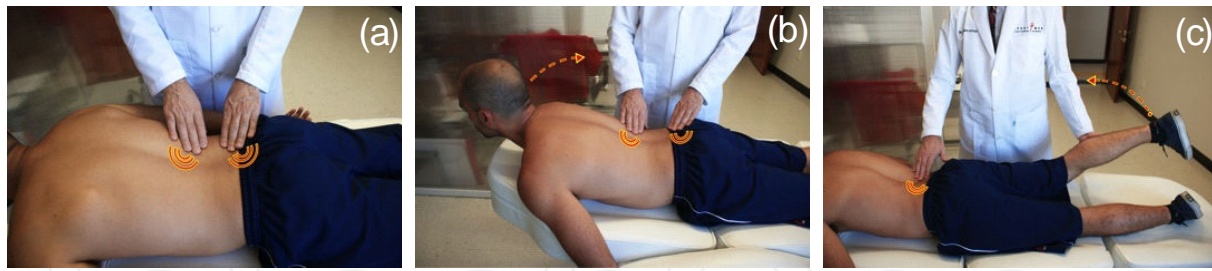Lumbar sprains are the most common causes of low back pain. A low back muscle strain occurs when the muscle fibers are abnormally stretched or torn. The injury can occur because of overuse, improper use, or trauma. It is classified as "acute" if it has been present for days to weeks. If the strain lasts longer than 3 months, it is referred to as "chronic".

Almost all of these low back injuries are due to injuries of the muscle. Certain risk factors, such as excessive lower back curvature, forward-tilted pelvis, weak back and/or abdominal muscles, and tight hamstrings, can increase the risk for this injury.

The symptoms are: Pain around the low back and upper buttocks, Low back muscle spasm, Pain associated with activities, and generally relieved with rest spasms in the lower back that result in more severe pain and lower back feels sore to the touch

Trauma of great force can injure the tendons and muscles in the lower back. Pushing and pulling sports, such as weight lifting or football, can lead to a lumbar strain.

The diagnosis of lumbar strain is based on the history of injury, but in the physical examination we palpate all the back of the patient facing down, to locate the pain (fig.14 a). We also ask him to try to rise the head while we are holding the ankles(fig. 14 b) and another maneuver is ask him to rise the leg with the knee straighten,on at the time, (fig. 14 c).



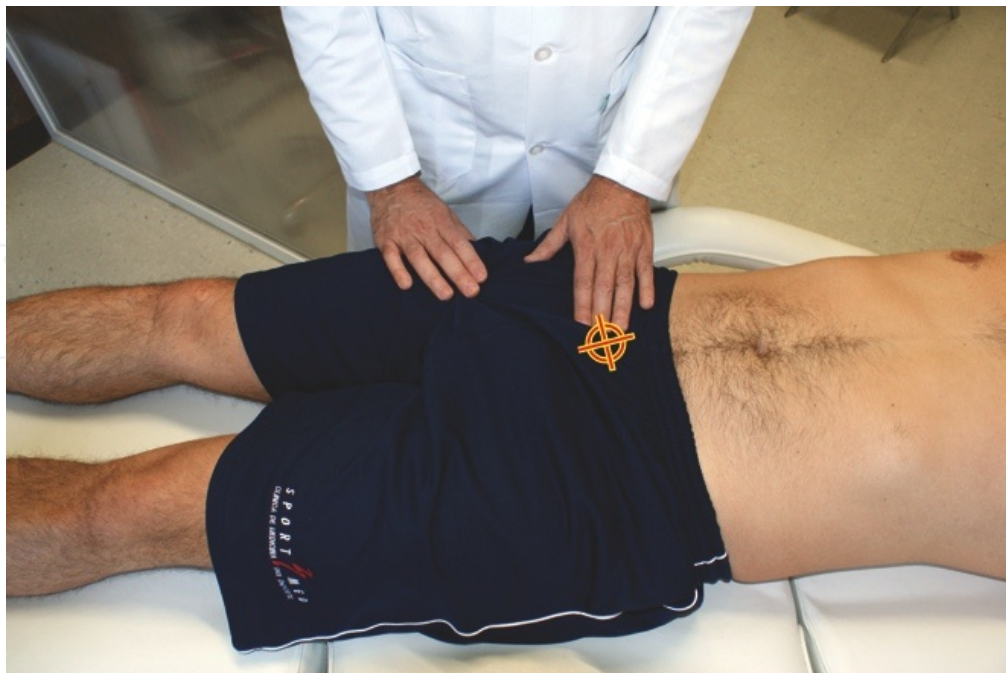**Figure 14.** a) With the patient facing down palpate the paravertebral muscles all along; b) Ask the patient to rise the neck to provoke and discomfort; c) Ask the patient to rise the leg straighten

## 9. Pubic adductor strain

The pubic adductor strain is a very common pathology in runners. Attached to the pubis are three muscle that converge: the adductor magnus, minimus and longus.

This injury usually occurs suddenly after having made a sharp sprint or change of direction and speed. When this injury happens, the athlete suddenly suspends the exercise and seeks medical help.

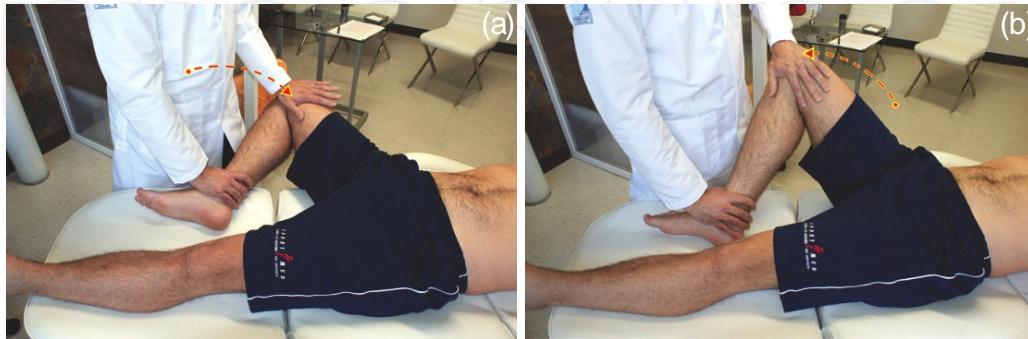
In the physical examination, pain is referred to a specific area of the adductor region to the inner and upper part of the leg. Palpation of the area may reveal edema, increased temperature, and in some cases a visible bruise (figure 15).



**Figure 15.** Palpate all over inguinal area searching for pain over the pubic bone

In carrying out exploratory maneuvers, a patient is unable to laterally raise the leg without pain and may require help to perform this movement.

With the athlete lying supine, ask him to flex the knee and hip to  $45^\circ$  and then ask him to let the leg drop outward to the point of pain. If the injury is minor, the examiner may need to apply some resistance to provoke pain (figure 16a,16b).



**Figure 16.** a) With the knee flex at  $45^\circ$  and lying over the lateral side ask the patient to rise it against resistance; b) With the knee flex at  $45^\circ$  ask the patient don't let you push it out

## 10. Quadriceps

One of the largest muscles in our body is the one on the front of the thigh. It is called the Quadriceps because it has four distinct beginnings (heads) that form separate muscles (vastus medialis, vastus intermedius, vastus lateralis and rectus femoris) that come together and insert as a single unit to the superior pole of the patella wrapping it and then inserting into the anterior tibial tuberosity.

Functionally, the quadriceps contributes significantly to the knee's stability. The quadriceps is a prime mover of knee extension and assists in hip flexion. The athlete can be injured in two ways. One is by a direct blow to the muscle and a second method is when the extension movement is performed suddenly.

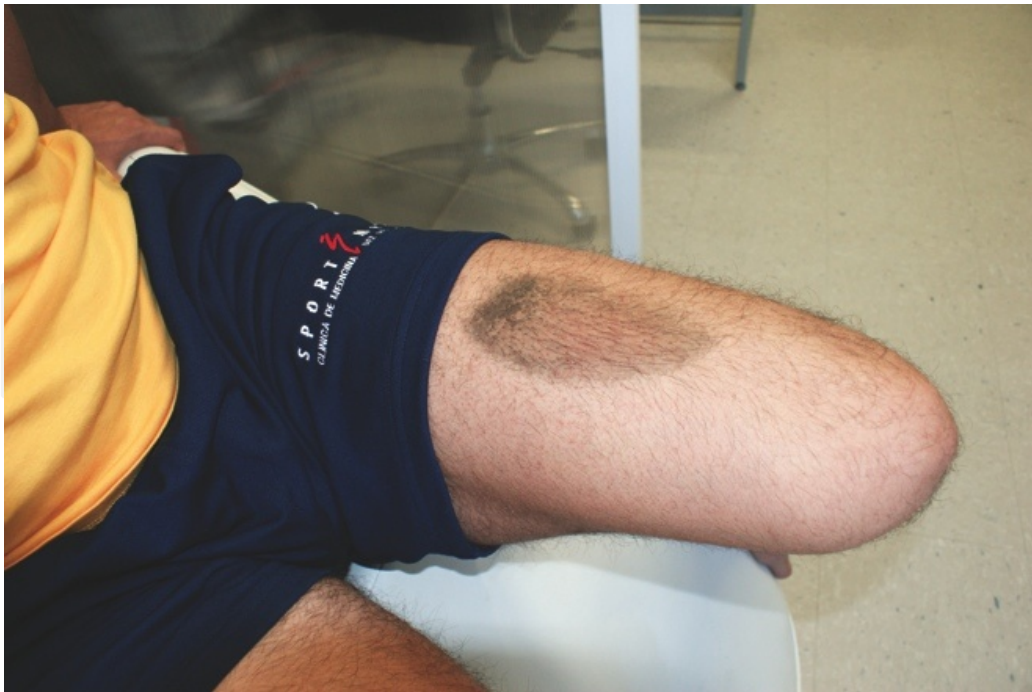A direct blow can cause blood vessels to break leading to intermuscular or intramuscular hematomas.

Physical examination includes a direct palpation to the injured area that should provoke pain and limping by the patient. This diagnosis is not difficult to determine because the athlete's history leaves no doubt (figure 17).

When there is a torn muscle caused by an overexertion, the examiner can also palpate underlying edema. The athlete will usually be quite uncomfortable in the area of the injury and unable to perform an isometric contraction of the thigh similar to the unaffected leg.

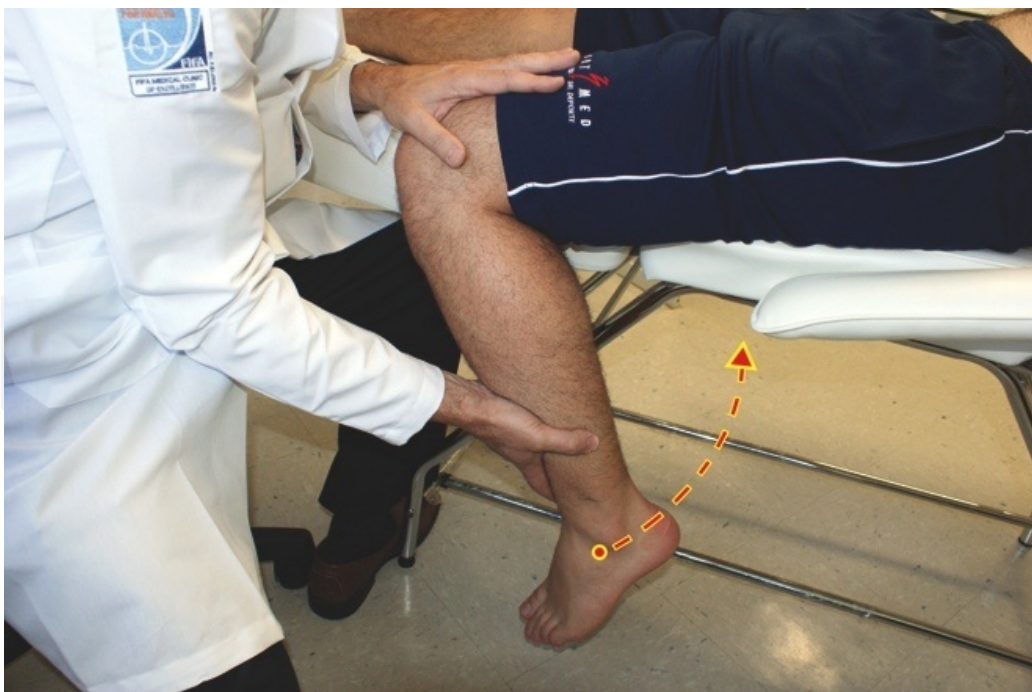
We can check the range of motion of the leg with the athlete lying supine on the edge of the examination table and bending the knee to the limit of pain (figure 18). At this point, stop the





**Figure 17.** A visible bruise is often seen

movement and measure the hip and knee angles. Repeat the test with the uninvolved leg and determine the difference in the measurements. Treatment should be instituted immediately to prohibit the injury from complicating and increasing the pain as time passes.



**Figure 18.** With the injured leg hanging from the lateral of the examination table flex the knee and measure the angle at which the pain is triggered and you can compared it to the contralateral side



Some times in the clinical history we have reports of previous ruptures that left an obvious muscle deformity (such a depression in the rectus femoris), but from the functional point of view the athlete's performance is unaffected even although the defect could be very large and might even need surgery, [8].

## 11. Hamstring

The hamstring muscles are located on the back of the thigh and function to flex the knee and extend the hip. These muscles form the back and inside out of the thigh (semitendinosus, semimembranosus and biceps femoris (long and short head) the latter being the outermost of these muscles).

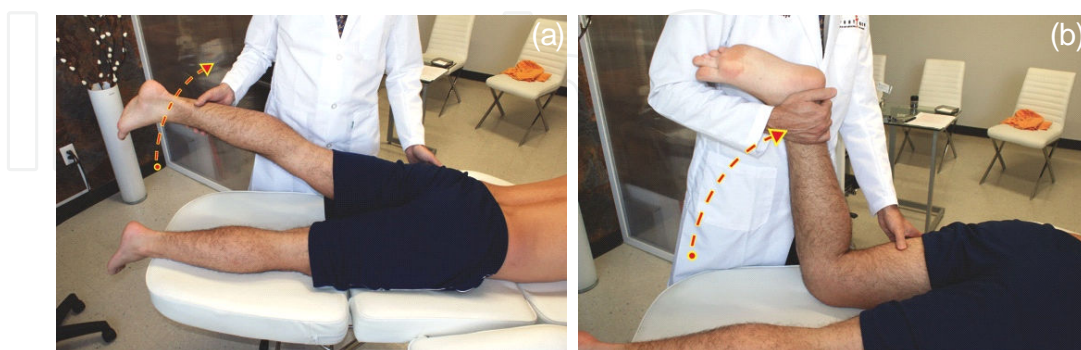
When this group of muscles are injured, the athlete reports having felt a "pull" especially when they are doing explosive exercises, and so the athlete stops and suspends all activity immediately.

There are hamstrings injuries that can occur in a slow and chronic manner, so the symptoms are vague and can be confused with pain in the lower back; not all injuries to this muscle group are acute, [9].

The causes of this injury can be very marked imbalance quadriceps strength (muscle imbalance), also often are due to lack of elasticity or warm-up previous to ballistic sports activity [10].

When this injury occurs, pain is widespread, edema occurs quickly and the patient is unable to stand or walk on the injured leg. Moreover, in the course of a few hours a hematoma is present, which can be displaced by gravity towards the back of the knee.

On physical examination (with the patient lying prone) pain in the area of the tear is provoked by palpation and the patient cannot perform an isometric knee flexion or hip extension nor can the athlete perform hip extension (figure 19a).



**Figure 19.** a) With the patient facing down ask to rise the affected leg as high as he can; b) With the knee flex at 90° palpate all the hamstring muscle to locate the exact spot of the muscle injury

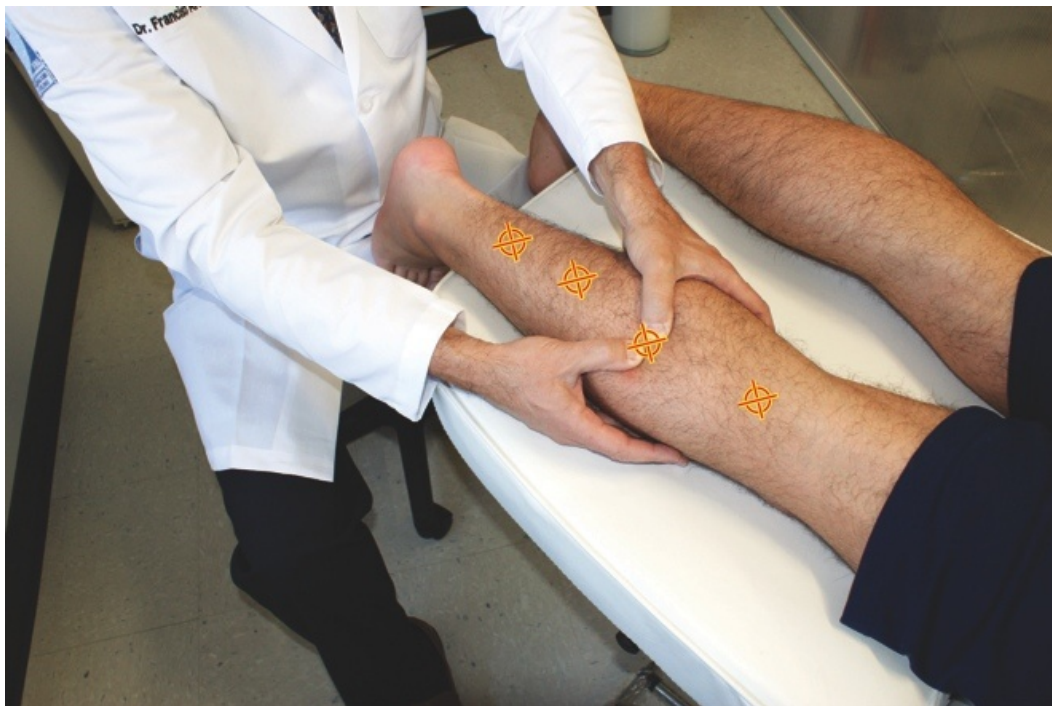When the examiner bends the knee of the affected leg (to relax the hamstrings) palpation of the entire length of the hamstrings can locate the site and of the muscle injury (figure 19b).

## 12. Gastrocnemius tear

These muscles are the gastrocnemius (medial and lateral head), and soleus and all combine to form the Achilles tendon. Their function is to help flex the knee and the foot (plantar flexion) and also the supination of the foot. Injuries in the calf are often due to lack of adequate warm up, stretching, or by overexertion when the muscle is already fatigued.

Generally speaking, the injury usually occurs acutely and patients say it feels as if someone had stuck in the back of the leg, yet when they turn around nobody is behind them, [11].

Pain is present immediately and the athlete can no longer stand and may have to be removed from the field on a stretcher. On physical examination, the prone patient is examined and the site of injury can be determined by palpation; edema is not always present (figure 20).

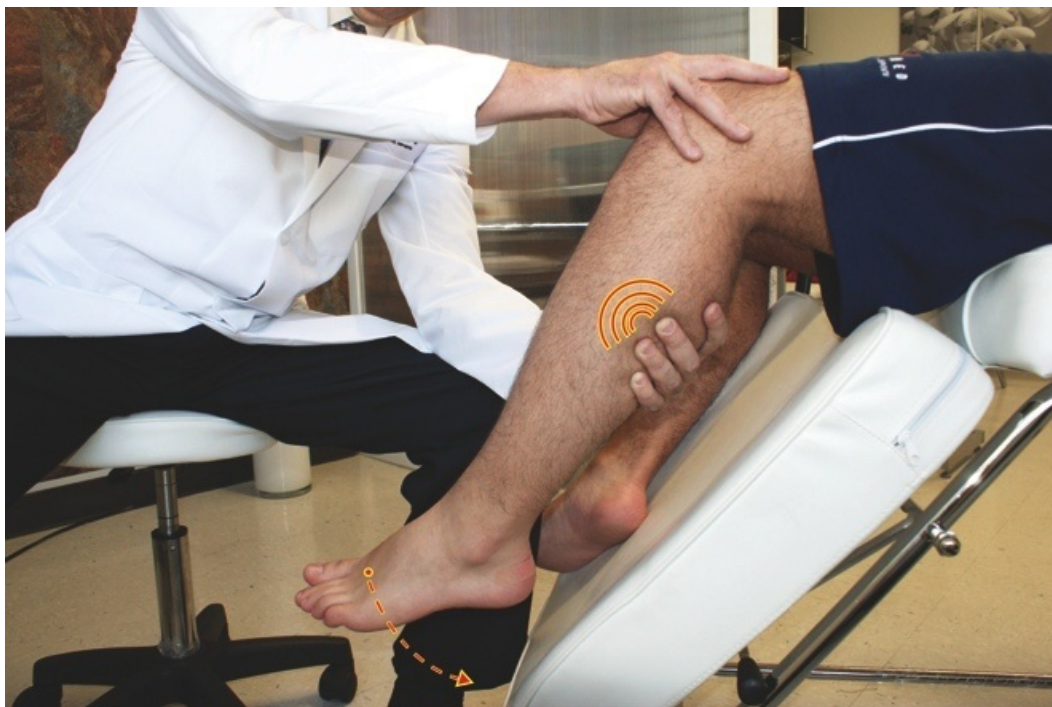

**Figure 20.** The gastrocnemius with patient prone is palpate all along

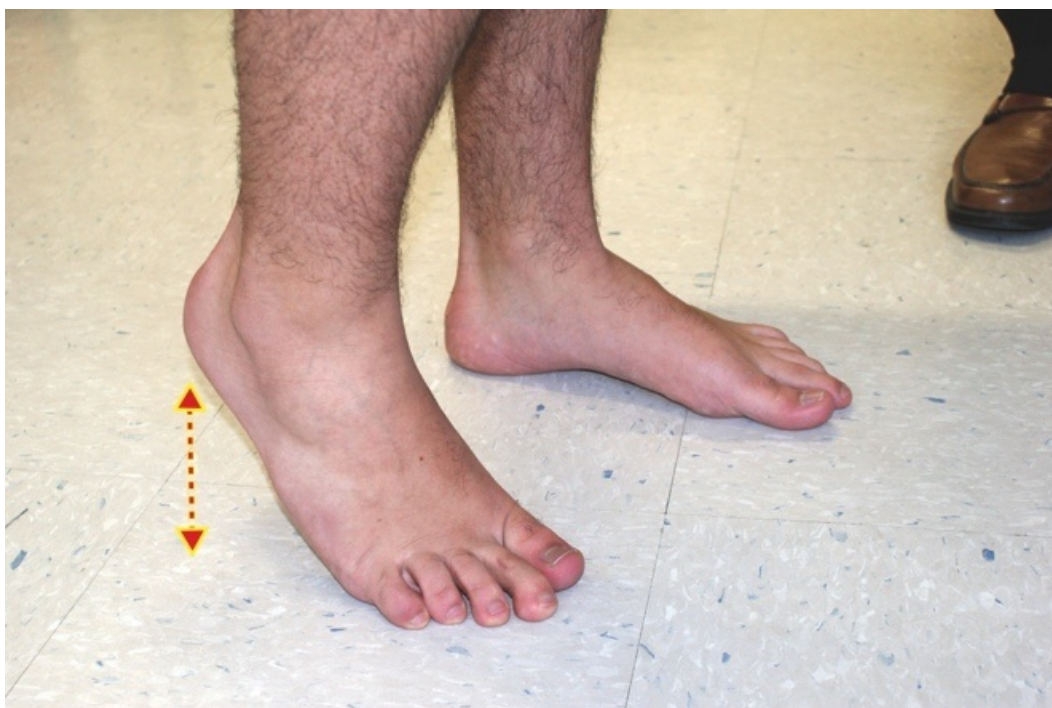With the athlete still lying prone, the knee is flexed to 90°. Pain is triggered when the athlete is asked to perform plantar flexion.

A complication of this condition is when the Achilles tendon ruptures; it is very important to rule out this complication. With the patient in a sitting position, compress the muscles (figure 21) to make the toes goes directly downward (Thompson sign). If this movement does not occur, the tendon could be completely torn and surgical treatment may be necessary.

Standing on the toes causes too much pain and the patient is unable to apply equal force by both legs to remain standing (figure 22).



**Figure 21.** Thompson's sign. With the knee flex at 90° squeeze the gastrocnemius muscle to provoke a tip toe of the foot



**Figure 22.** Standing on a tip toe position is painful



## Author details

Francisco Arroyo\*

Medical Director, Sport Med. FIFA Medical Clinic of Excellence Guadalajara, Mexico

## References

- [1] Jacobs CL, Hincapié CA, Cassidy JD. Musculoskeletal injuries and pain in dancers: a systematic review update. *J Dance Med Sci.* 2012;16(2):74-84.
- [2] Beloosesky et al. Pectoralis major rupture in elderly patients: a clinical study of 13 patients. *Clin Orthop Relat Res.* 2003 Aug;(413):164-9.
- [3] Sarda et al. Distal biceps tendon rupture: Current concepts *Injury.* 2013 Apr;44(4):417-20. doi: 10.1016/j.injury.2012.10.029. Epub 2012 Nov 27.
- [4] Kokkalis et al. Distal biceps and triceps ruptures. *Injury.* 2013 Jan 23. pii: S0020-1383(13)00015-6. doi: 10.1016/j.injury.2013.01.003. [Epub ahead of print].
- [5] Giannicola G, Polimanti D, Sacchetti FM, Scacchi M, Gumina S, Greco A, Cinotti G. Soft tissue constraint injuries in complex elbow instability: prevalence, pathoanatomy, and classification. *Orthopedics.* 2012 Dec;35(12):e1738-45. doi: 10.3928/01477447-20121120-18.
- [6] Kulhanek J, Mestak O. Treatment of umbilical hernia and recti muscles diastasis without a periumbilical incision. *Hernia.* 2013 Jan 20. [Epub ahead of print]
- [7] Jankovic S., D. Delimar, and D. Hudetz. 2001. The groin pain syndrome (In croatian. *Harviv Za Higijenu Rada i Toksikologiju.* 52:421 -428.
- [8] Hart ND, Wallace MK, Scovell JF, Krupp RJ, Cook C, Wyland DJ. Quadriceps tendon rupture: a biomechanical comparison of transosseous equivalent double-row suture anchor versus transosseous tunnel repair. *J Knee Surg.* 2012 Sep;25(4):335-9.
- [9] Petersen J, Thorborg K, Nielsen MB, Budtz-Jørgensen E, Hölmich P. Preventive effect of eccentric training on acute hamstring injuries in men's soccer: a cluster-randomized controlled trial. *Am J Sports Med.* 2011 Nov;39(11):2296-303.
- [10] Opar DA, Williams MD, Shield AJ. Hamstring strain injuries: factors that lead to injury and re-injury. *Sports Med.* 2012 Mar 1;42(3):209-26.
- [11] Cheng Y, Yang HL, Sun ZY, Ni L, Zhang HT. Surgical treatment of gastrocnemius muscle ruptures. *Orthop Surg.* 2012 Nov;4(4):253-7. doi: 10.1111/os.12008.



