Chapter 8

Locally Advanced Esophageal Cancer

Hend Ahmed El-Hadaad and Hanan Ahmed Wahba

Additional information is available at the end of the chapter

http://dx.doi.org/10.5772/56484

1. Introduction

Cancer of the esophagus is a highly lethal malignancy. There are approximately 16,980 people diagnosed with esophageal cancer each year in the United States and 14,710 deaths from the disease (Siegel et al., 2011). It currently ranks ninth among the most frequent cancers in the world (Lerut et al., 2001), and it is the sixth leading cause of death from cancer (Falk et al., 2007). Although the best treatment for locally advanced esophegeal cancer is still being debated, the use of neoadjuvant chemoradiotherapy has gained acceptance (Tepper et al., 2008). The rationale for chemoradiotherapy (CRT) followed by surgery has potential to downsize the tumor, thereby increasing the rate of tumor-free (RO) resections, reducing early relapses, and improving survival (Swisher et al., 2005; Brucher et al.,2006). Chemoradiotherapy (CRT) has proved effective against resectable/unresectable esophageal squamous cell carcinoma. The Radiation Therapy Oncology Group (RTOG) trial 85-01 demonstrated the superiority of CRT with cisplatin (CDDP), 5-fluorouracil (5-FU), and concurrent irradiation (50.4 Gy) over radiotherapy alone (64 Gy) in patients with T1–3N0–1M0 esophageal cancer (Herskovic et al., 1992). Definitive chemoradiotherapy is appropriate for locally advanced cancer in patients who do not want surgery or in whom surgery is not possible as a result of technical or medical reasons. The higher doses of radiation administered with concurrent chemotherapy was explored in the protocol RTOG9504 which established 50.4 Gy as the standard dose of radiation to be administered concurrently with chemotherapy (Minsky et al., 2002). Three-dimensional conformal radiotherapy (3D-CRT) is an approach to the planning and delivery of radiation therapy and numerous investigators have demonstrated the benefits of this modality in a variety of cancers. These benefits include its normal tissue-sparing capabilities and its ability to deliver higher radiation doses compared with conventional radiotherapy (Oh et al., 1999).

To enhance the efficacy and tolerability of multimodal treatment, new chemotherapeutic agents such as oxaliplatin and capecitabine have been incorporated into esophegeal cancer therapy. Oxaliplatin is a third generation platinum compound, it forms inter and intrastrand

cross links with DNA that inhibit DNA replication and transcription. In phase I and II, trials suggest that it has been found to be at least as effective as cisplatin in esophageal cancer and better tolerated (Khushalani et al., 2002). Neoadjuvant concurrent chemoradiotherapy with capecitabine and oxaliplatin concurrently with conformal radiotherapy in patients with locally advanced esophageal cancer better tolerated and effective with OAR 54.8% (Wahba et al., 2012).

Objectives:

The chapter examines:

- Diagnostic procedures
- Recommendations for treatment of locally advanced esophageal cancer
- The use of neoadjuvant chemotherapy and radiotherapy for treatment of locally advanced esophageal cancer
- Concurrent chemotherapy and radiotherapy for definitive treatment
- Follow-up care

2. Diagnosis and staging

In Western countries, the diagnosis of esophageal cancer is generally made by endoscopic biopsy of the esophagus. In the Far East, cytologic evaluation is frequently used.

The most accurate staging modalities are CT scanning and endoluminal ultrasound (EUS). CT scanning most accurately detects distant visceral metastases although both EUS and laparoscopic ultrasound are capable of detecting small metastases, particularly in the left lobe of the liver that may be missed on CT (Nguyen et al., 1999 & Wakelin et al., 2000). In locoregional staging, EUS is considerably more accurate than CT.

PET: Positron emission tomography (PET) scanning is a more recently described staging modality that detects uptake of fluorodeoxyglucose by tumor cells. Early studies suggest it may be more reliable than EUS alone in detecting nodal metastases (Choi et al., 2000 & Lerut et al., 2000), several recent studies have applied PET scanning for the assessment of response to neoadjuvant chemoradiation, demonstrating a correlation between fluorodeoxyglucose uptake, pathologic response at surgery, and subsequent survival (Kato et al., 2002).

As PET becomes more widely available; its use will probably become an important part of the preoperative evaluation of these patients.

Accurate staging provides useful information relating to prognosis and has considerable therapeutic implications.

3. Treatment of locally advanced esophageal cancer

3.1. Treatment principles

The treatment of locally advanced esophageal cancer is a multidisciplinary approach; single modality approaches have disappointing control rates.

Radiochemotherapy is the standard of care; neoadjuvant chemoradiotherapy is associated with a higher response rate in comparison to chemotherapy alone.

Definitive chemoradiation remains a reasonable therapeutic option for patients.

External beam radiation therapy alone can be considered for definitive treatment when chemotherapy is contraindicated.

For palliation of symptomatic locally advanced esophageal cancer, radiotherapy is highly effective, also endoscopic procedures such as dilating, stenting, and laser ablative techniques are effective in rapid symptoms alleviation.

3.2. Neoadjuvant chemotherapy

A trial performed by the Medical Research Council Oesophageal Cancer Working Group randomized 802 patients to surgery alone versus two cycles of preoperative cisplatin/5-FU. At a relatively short median follow-up of only 2 years, the chemotherapy-treated group demonstrated improved median OS (16.8 vs 13.3 months) and 2-year survival (43% vs 34%). The curative resection rate was improved marginally from 55% to 60%, and the pCR rate was 4% in the preoperative therapy group (Medical Research Council Oesophageal Cancer Working Group 2002). A French trial of 224 patients with gastric or lower esophageal adenocarcinoma (Boige et al., 2007), in which patients were randomized to two or three cycles of preoperative cisplatin/5-FU followed by surgery versus surgery alone. Those patients who appeared to benefit clinically or radiographically from preoperative therapy or who had persistent T3 or node-positive disease at surgery also received an additional three or four cycles of chemotherapy. Preoperative chemotherapy was associated with a significant improvement in R0 resection rate (74% vs 87%), 5-year disease-free survival (34% vs 21%), and 5-year OS (38% vs 24%). the survival benefit seen with preoperative cisplatin/5-FU on this trial appears to be very similar to that seen with perioperative ECF in the MAGIC trial (Cunningham et al., 2006). Polee et al have evaluated a biweekly combination of cisplatin and paclitaxel in a phase II study, with promising results. Objective responses occurred in 59% of 49 patients. No patients had progressive disease. Although 71% of patients had severe neutropenia, it was often asymptomatic. Forty-seven patients underwent resection subsequently. Complete pathologic responses occurred in 14% of patients. The median survival of patients in this study was 20 months, but it was 32 months in patients who had disease responsive to chemotherapy. The 3-year survival rate was 32% (Polee et al., 2003).

3.3. Neoadjuvant RadiationTherapy

Trials that evaluated the use of preoperative radiation as a single modality have consistently reported no benefit. Whenever a survival benefit was suggested, it tends to be modest, similar to neoadjuvant chemotherapy alone (Arnott et al., 1992; 2005 & Nygaard et al., 1992). One randomized trial revealed no benefit for either preoperative radiation or chemotherapy, concluding that both treatment modalities might be necessary to treat both local and

systemic disease. Also, a meta-analysis could not demonstrate a significant survival benefit for preoperative radiation as a single modality (Arnott et al., 1992).

3.4. Neoadjuvant chemoradiotherapy

Chemoradiotherapy typically involves regimens of cisplatin or mitomycin and continuous-infusion 5-FU, with radiotherapy dosages from 30 to 40 Gy and up to 60 Gy in some trials. It results in pCR rates of 20–40%, with long-term survival of no more than 25–35% (Coia et al., 1991 & Valerdi et al., 1993). Superior survival is consistently achieved, though, in patients achieving a pCR to chemoradiotherapy (up to 50–60% at 5 years) (Berger et al., 2005; Makary et al., 2003; Stahl et al., 2005 &Heath et al., 2000). A meta-analysis of randomized trial comparing neoadjuvant chemoradiation therapy followed by surgery with surgery alone found that neoadjuvant concurrent chemoradiation therapy improved 3-year survival (odds ratio, 0.66) compared with surgery alone, with a non significant trend toward increased mortality with neoadjuvant treatment (Kaklamanos et al., 2003).

Newer chemotherapy agents are active and may improve outcome over conventional cisplatin/5-FU-based regimen such as paclitaxel, irinotican, oxaliplatin, xeloda and docetaxel.

A phase II trial of 129 patients employed paclitaxel/carboplatin [Paraplatin]/5-FU with 45 Gy of radiation therapy followed by esophagectomy. A pathologic complete response was seen in 38% of patients, with a median survival of 22 months and a 3-year survival of 41% (Meluch et al., 2003).

Ajani et al reported a series of 43 patients who received 12 weeks of cisplatin and irinotecan (Camptosar) followed by weekly paclitaxel with infusional 5-FU and concurrent radiation therapy (4,500 cGy) and then esophagectomy. Therapy was well tolerated, with no deaths from chemotherapy or chemoradiation therapy, and an operative mortality rate of 5%. Cisplatin and irinotecan induced responses in 37% of patients, and 91% of patients underwent complete resection. Pathologic complete responses occurred in 26% of patients, and some tumor shrinkage was noted in 63% of patients. With a median follow-up of more than 30 months, the median disease progression free survival was 10. 2 months, the median survival was 22.1 months, and the 2-year survival was 42%. The patients who had a pathologic response to therapy had significantly better outcomes than the rest of the study population. However, systemic recurrences remained a prominent cause of failure, with five patients experiencing recurrence first in the brain and an additional five patients, in the liver (Ajani et al., 2004).

Neoadjuvant concurrent capecitabine and oxaliplatin with conformal radiotherapy (45Gy) in 42 patients reported OAR 54.8% and pathological response 38%.Median survival time was 20 months and 2-year survival rate 42 % (Wahba et al., 2012).

A phase II trial assessed the feasibility and safety of induction chemotherapy with cisplatin (25 mg/m^2 d1-5, d29-34)/docetaxel (75 mg/m^2 d1, d29)/5-fluorouracil ((5-FU, 750 mg/m^2 d1-5, d 29-34) followed by external beam radiotherapy concurrent with docetaxel (15 mg/m^2

d1,8,15,22) and 5-FU (300 mg/m^2 continuous infusion on the days of radiotherapy).Twenty-four patients with locally advanced carcinoma of the esophagus were included. Following chemotherapy and chemoradiation eligible patients underwent esophagectomy. Sixteen patients underwent resection. Pathologic complete remission was achieved in 5 of those 16 patients, 13 patients had downstaging of disease. R0 resection was feasible in all 16 patients (Eisterer et al., 2011).

The incidence of residual disease in patients who have a complete clinical response to chemoradiation therapy is 40%-50%. Patients with complete response following chemoradiation therapy have the best survival rates with surgery. RTOG 9207 Phase I/II treated 49 patients with concurrent 5-FU,cisplatin+radiotherapy (50Gy/25 fractions and high dose rate brachytherapy 5Gyx3 or low dose rate 20x1); reported 24% grade 4 toxicity,12% fistula,10% treatment related deaths with median survival 11 months. Brachytherapy not recommended due to high toxicity (Caspar et al., 2000).

3.5. Positron emission tomography-directed therapy

18F-2-fluoro-deoxy-D-glucose positron emission tomo-graphy (PET) scanning is emerging as an important tool to investigate response to therapy. Several studies have demonstrated that the degree of response detected by PET following preoperative chemoradiotherapy (Downey et al., 2003 & Flamen et al 2002) or chemotherapy (Ott et al., 2006 & Weber et al., 2001) is highly correlated with pathologic response at surgery and with patient survival.

The German MUNICON trial evaluated the strategy of taking patients with locally advanced GE junction tumors with a suboptimal response to 2 weeks of induction chemotherapy with cisplatin/5-FU, as determined by serial PET scans, directly to immediate surgery, instead of continuing with presumably ineffective chemotherapy (Lordic et al., 2007). Patients with a metabolic response by PET (defined as ≥35% reduction in standard uptake value between baseline and repeat PET scan) continued with an additional 12 weeks of chemotherapy prior to surgery. This trial revealed a significantly improved R0 resection rate (96% vs. 74%), major pathologic response rate (58% vs. 0%), median event-free survival (29.7 vs. 14.1 months), and median OS (median not reached vs. 25.8 months) for PET responders versus PET non responders. The outcome for PET non responders referred for immediate surgery was similar to the outcome of such patients in an earlier trial who completed 3 months of preoperative chemotherapy (Ott et al., 2006), indicating that non responding patients were not compromised by referral to immediate surgery.

3.6. Primary chemoradiation therapy

Patients with locally advanced esophageal cancer (T1-4 N0-1 M0) may be cured with definitive chemoradiation therapy. Randomized trials have demonstrated a survival advantage for chemoradiation therapy over radiotherapy alone in the treatment of esophageal cancer. In an RTOG randomized trial involving 129 patients with esophageal cancer, irradiation (50 Gy) with concurrent cisplatin and 5-FU provided a significant

survival advantage (27% vs 0% at 5 years) and improved local control over radiation therapy alone (64 Gy). Median survival also was significantly better in the combined-therapy arm than in the irradiation arm (14.1 vs 9.3 months) (Cooper et al., 1999).

A Cochrane review confirmed the superiority of chemoradiotherapy versus radiotherapy in fit patients (Rebecca, 2003).

3.7. Radiotherapy

Radiotherapy is one of the main, effective and relatively safe treatment modalities for cancer esophagus. It could be used for early stage and advanced diseases and as locally palliative treatment for metastatic disease.

The Radiation Therapy Oncology Group (RTOG) 85-01 trial was a randomized controlled comparison of definitive radiotherapy alone (64 Gy), and definitive concurrent chemoradiation (50 Gy delivered concurrently with 5-fluorouracil [5-FU] and cisplatin). A statistically significant benefit was noted for overall survival among patients receiving concurrent chemoradiation (Cooper et al., 1999).The Intergroup trial 0123 subsequently randomized 231 patients to receive definitive chemoradiation with 50 Gy delivered concurrently with 5-FU and cisplatin vs. 64 Gy delivered concurrently with the same chemotherapeutic regimen. No significant differences were noted in median or overall survival or locoregional control (al-Sarraf et al., 1997).Given these findings, the current standard of care for inoperable esophageal cancer is concurrent chemoradiation with 50 Gy radiotherapy.

3.7.1. 3D Conformal Radiotherapy

Three-dimensional conformal radiation therapy (3-DCRT) has been demonstrated to improve dose distribution, thereby allowing significant increase of target dose and decrease of lung and heart doses.

Target volume delineation:

It is based on the International Commission on Radiation Units and Measurements (ICRU)-50 definitions of gross tumour volume (GTV), clinical target volume (CTV), and planning target volume (PTV). To cover both submucosal tumour spread and lymphatics along the oesophagus, enlarged longitudinal safety margins have been validated by clinical and pathological reviews (Hosch et al., 2001 & Gao et al., 2007).

GTV (gross tumor volume) is tumor extension visible in imaging, including primary tumor and enlarged lymph nodes. The commonly used imaging methods include endoscope, esophagogram, CT, MRI; PET-CT. Complementary effect exists between each imaging examination method, and could significantly improve the accuracy and sensitivity when judging the gross tumor volume. Many studies recommend PET-CT for planning simulation (Konshi et al., 2005 & Moureau-Zabotto et al., 2005). Leong et al., (2006) enrolled 21 esophageal carcinoma patients in a prospective trial to determine effects of PET-CT on

delineation of tumor volume for radiation therapy planning. PET-CT detected disease in eight patients that was not detected by CT scan: four of these patients were found to have metastatic disease and four had regional nodal disease. In 16 of 21 patients who proceeded to the radiotherapy planning phase of the trial, 69%had PET-CT–positive disease that would have been excluded if CT alone had been used for radiation planning. In cases where an endoscope is unable to pass through a stenosed oesophagus to visualize the lower boundary of the tumour, PET may be the only way to estimate the lower border of the tumour. PET has a significant impact on GTV and PTV in oesophageal cancer, often helping to avoid geographic miss by identifying unsuspected lymph node involvement.

CTV (clinical target volume) refers to the range of subclinical lesions. The microscopic infiltration ranges were < 3 cm superior and inferior along the vertical axis of esophagus in 94% of the patients with esophageal carcinoma as reported by Gao et al. (2007) who concluded that a 50 mm CTV would be necessary to cover distal microscopic spread in 94% of adenocarcinomas of the gastroesophageal junction. A 30 mm CTV would be adequate to cover microscopic disease spread in 94% of squamous cell carcinomas and for coverage of proximal microscopic spread for adenocarcinomas of the gastroesophageal junction.

Clinical target volume node refers to the lymphatic drainage districts of esophageal carcinoma. There is no high grade evidence identifying the range of lymphatic drainage districts in prophylactic radiation for esophageal carcinoma. The final CTV may be larger since for cervical primaries; the supraclavicular nodes need to be included; and for distal primaries, the celiac nodes need to be included.

Planning Target Volume (PTV) will provide margin around the CTV to compensate for variations in treatment set-up, and organ motion will be included in the treatment fields.

A volumetric treatment planning CT study is required to define GTV and PTV. The local regional nodes will be included in the clinical target volume (CTV). Each patient will be positioned in an individualized immobilization device in the treatment position on a flat table. Contiguous CT slices, 3-5 mm thickness of the regions harboring gross tumor and grossly enlarged nodes and 8-10 mm thickness of the remaining regions, are to be obtained starting from the level of the cricoid cartilage and extending inferiorly through the liver. The GTV and PTV and normal organs are outlined on all appropriate CT slices and displayed using beam's eye view. Normal tissues to be contoured include lungs, kidneys, skin, heart, spinal cord, esophagus, and liver. A measurement scale for the CT image shall be included. Barium swallow during the planning CT is optional provided a diagnostic chest CT was done with contrast to delineate the outline of the esophagus (RTOG 0436).

Variability in treatment setup, breathing, or motion during treatment:

Lorchel et al. (2006) and Yaremko et al. (2008) reported that the movement range of esophagus in all directions was 0.5 cm in upper part, 0.6 - 0.7cm in middle part, and 0.8 - 0.9 cm in lower part. A margin around the CTV will define the PTV. The PTV volume must include a minimum of 1 cm and a maximum of 2 cm around the CTV. Once again, the final PTV may be larger, since the supraclavicular nodes need to be included in the treatment

fields for cervical primaries and the celiac nodes need to be included in the treatment fields for distal primaries.

The ICRU reference point is to be located in the central part of PTV. Typically, this point should be located on the beam axis or at the intersection of the beam axis (isocenter).

Radiotherapy doses:

External beam radiation therapy to a total dose of 50.4 Gy at 1.8 Gy/fraction, in combination with concurrent cisplatin + 5-FU chemotherapy is currently the standard regimen for definative treatment. The Intergroup 0123 trial randomly assigned 236 patients with locally advanced esophageal cancer (T1-4, N0/1) to radiation to a total dose of 50.4 Gy or 64.8 Gy at 1.8 Gy/ fraction. Concurrent chemotherapy (cisplatin +5-FU) was used in both groups. The results revealed no differences in locoregional failure rates (56% versus 52%) and 2-year overall survival rates (31% versus 40%), as well as in median survival (13 months versus 18 months) (Minsky et al., 2002). analysis of RTOG 94-05 did show that a dose of 64.8 Gy was not superior to 50.4 Gy (Wither and Peters, 1980). Whba et.al (2012) reported overall response rate 54.8% and median overall survival 20 months on using chemoradiotherapy with capecitabine, oxaliplatin and radiotherapy dose 45Gy. RTOG 0436 trial recommend a total dose of 50.4 Gy (1.8 Gy/Fx/day), the prescription dose will be specified at the ICRU-50 reference point; this point will usually be the isocenter (intersection of the beams). The isodose curve representing 93% of the prescription dose must encompass the entire planning target volume (PTV). The daily prescription dose will be 1.94 Gy at the International Commission on Radiation Units and Measurement (ICRU) reference point. 1.8 Gy (which corresponds to the 93% isodose curve) is to be delivered to the periphery of the PTV.

In the trial by Bosset and coworkers (1997) the fractionation consisted of two 1-week courses of 3.7 Gy /5 fractions, the field included the tumor with 5-cm superior and inferior margins and 2 cm radial margins. The celiac axis was not included. Walsh and coinvestigators (2006) used a dose of 40 Gy in 2.67-Gy fractions. The Cancer and Leukemia Group B 9781 trial (Krasna et al., 2006) treated to 50.4 Gy. Radial margins were 2 cm beyond the esophagus; superior and inferior field borders were 5 cm above and below the gross tumor, including the supraclavicular nodes for proximal tumors and the celiac axis for distal tumors.

The fractination schemes, with 50.4 Gy commonly used in the United States and lower doses with larger fraction sizes more common in Europe (Hong et al., 2007).

RTOG9504 established 50.4 Gy as the standard dose of radiation to be administered concurrently with chemotherapy (Minsky et al., 2002).

Field arrangement:

The preferable method is a 3-field technique (2 anterior obliques and a posterior field). In most cases, this is not possible; therefore, it is acceptable to initially treat AP/PA to approximately 39.6 Gy, then switch to obliques to exclude the spinal cord. The supraclavicular field, which is excluded from the obliques, can be supplemented with

electrons to bring the total dose up to 50.4 Gy (RTOG 0436). A common approach is anterior: posterior (APPA) fields for the first course, and a 3-field approach consisting of an AP and 2 posterior obliques, or opposed obliques, for the cone-down volume. The advantages of this approach include limiting the lung dose during the AP-PA portion of treatment and then limiting the spinal cord dose by replacing the PA field with off-cord obliques. A disadvantage is the significant cardiac volume often included in treatment filed (Hong et al., 2007).

Dose constraint:

The dose limitation for critical structures includes, the spinal cord dose limited to 45 Gy, 60% of the liver should not exceed 30 Gy, at least two thirds of one kidney should not exceed more than 20 Gy, and one third of the heart should receive less than 50 Gy (Wither and Peters, 1980). The mean lung dose should not exceed 20 Gy, and specific limits have been recommended for volumes that receive 10, 20, and 30 Gy, respectively (V10, V20, V30) (Hong et al., 2007).



a

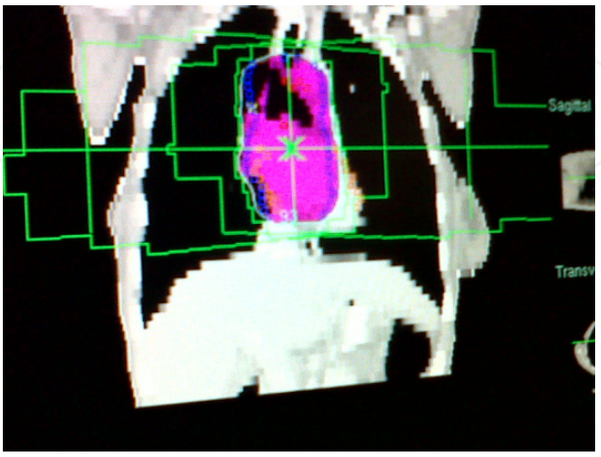

b

Figure 1. a, b Dose distribution by using an AP field and two oblique fields.

3.7.2. Intensity Modulated Radiation Therapy (IMRT)

Most data regarding IMRT for esophageal malignancies has been limited to dosimetric analyses.

Wang et al (2006) reported outcomes of seven patients with locally advanced upper or cervical esophageal cancer treated definitively with concurrent chemoradiation with a total radiation dose of 59.4–66 Gy five- to nine-beam IMRT were used to deliver a total dose of 59.4-66 Gy (median: 64.8 Gy) to the primary tumor. After median fellow up period 15 months all 6 evaluable patients achieved complete response. Of them, 2 developed local recurrences and 2 had distant metastases, 3 survived with no evidence of disease. After treatment, 2 patients developed esophageal stricture requiring frequent dilation and 1 patient developed tracheal-esophageal fistula.

Another study conducted by Fu et al (2004) comparing IMRT and 3D Conformal radiotherapy, The IMRT plans were superior in that they reduced the percent of total lung volume exceeding 20 Gy (V20) or 30 Gy (V30) while generating more conformal and homogeneous target coverage. Heterogeneity and conformality indices were improved with IMRT. No significant reductions were noted in heart, spinal cord, liver and total body integral dose (Chandra et al., 2005).

3.7.3. Follow up after radiotherapy

One month after radiotherapy then every four months in the first year, once every six months in the second year, once every year thereafter to at least five years. If the patients have symptoms they should be followed up according to clinical requirement. Evaluations during these follow-up visits included blood routine, biochemistry test, upper gastroenterography and/or esophagoscopy, chest- X ray films/chest computed tomography (CT).

3.8. Targeted therapy

Bonner et al. (2006) conducted a phase III trial in locally advanced head and neck cancer patients documented the benefit of combination of cetuximab and radiation and reported an improvement in both local control and overall survival. The Brown University Oncology Group and the University of Maryl and Greenebaum Cancer Center (Suntharalingam et al., 2006) have piloted the addition of cetuximab with a concurrent chemoradiation (weekly carboplatin, paclitaxel, and 50.4 Gy), this phase II trial reported complete response rate of 65% in patients presenting with locally advanced disease with no grade 4 toxicities and 20% grade 3 esophagitis.

4. Palliative treatment of locally advanced esophageal cancer

The majority of patients presented with locally advanced or metastatic disease which is difficult to control. Considering this fact, it is important to offer treatment providing

adequate and rapid palliation of symptoms especially the obstructive symptoms which reflect on the quality of life.

Several management options have been developed to palliate malignant dysphagia. These include endoluminal stenting or surgery and external beam radiation, brachytherapy, chemotherapy, chemoradiotherapy, laser treatment, photodynamic therapy or ablation using injection of alcohol or chemotherapeutic agents (Weigel et al., 2002; Allum et al., (2002) & Bown (1991).

4.1. Surgical bypass

Surgical bypass advocated as a palliative modality, particularly when unresectability is only discovered at an attempt at curative resection, on the basis that this offers better restoration of swallowing than many palliative modalities (Segslin et al., 1989). However, operative mortality is 40% or more, whichever bypass procedure is used (Segalin et al., 1989 & Whouley et al., 2002).

4.2 Stenting

Since 1990, several case series, retrospective reviews, and prospective studies including more than 2,000 patients have shown that Self-expandable metal stents (SEMS) are effective in relieving dysphagia and improving dysphagia scores, with immediate success rates between 96% and 100% (Dua, 2007).

Madhusudan et al. (2009) reported significant improvements in all QOL parameters after stent placement in patients with advanced inoperable esophageal cancer. This improvement was maintained until 8 weeks.

Another prospective study by Maroju et al. (2006) reported similar improvement in QOL following stenting.

Contraindications to stent use include particularly exophytic tumors, proximal tumors due to pharyngeal irritation caused by prostheses sited too proximally. Complications include tumor ingrowth (predominantly with uncovered stents), tumor overgrowth at the stent margins, and stent migration (particularly with covered stents and lesions close the esophagogastric junction) (Hills et al., 1998 & Tytgat et al., 1986).

4.3 External beam radiotherapy

External beam radiotherapy (EBRT) is known to provide durable and effective relief of dysphagia. However, there is a time lag before symptomatic relief occurs, and up to 6 weeks are required for maximum benefit (Bown, 1991).

Most studies have used radiotherapy in a dose range of 40–60 Gy. However, a higher dose of radiotherapy does not add to the therapeutic value, and may increase the loco-regional toxicity (Minsky et al., 2002).

4.4. Stenting and external beam radiotherapy:

Although SEMS are easy to place and the beneficial effects are immediate, recurrent dysphagia has been observed in many patients during a follow-up period of 4–10 weeks (Homann et al., 2008). Radiotherapy, on the other hand, provides long-term relief of dysphagia (Bown, 1991). Zhong et al. (2003) and Han et al. (2004) have investigated the effect of combined stenting and radiotherapy on survival of patients with advanced esophageal cancer and reported superior results with regard to both relief of dysphagia and survival for stenting followed by radiotherapy in those patients.

Eldeeb and El-Hadaad (2012) conducted a prospective study on 91 locally advanced esophageal cancer patients, they reported median overall survival (OAS) 169 days in radiotherapy group (the radiation doses ranged from 20Gy/5fractions to 30Gy/10 fractions), 119 days in stenting group and 237 days in combined radiotherapy- stenting group, the difference between radiotherapy group and combined radiotherapy- stenting group was significant.

4.5. Thermal ablative therapy

Laser photocoagulation has been the most studied modality; two studies have demonstrated better palliation using laser photocoagulation, its disadvantages include the necessity to repeat treatment at approximately 6-week intervals (Carter et al., 1992) & Loizou et al., 1991). Laser treatment is best reserved for tumors least amenable to stent placement

4.6. Brachytherapy

The use of intracavitary irradiation (brachytherapy) in doses of 1,800 cGy in the palliation of esophageal cancer has encouraging results (Sur M et al., 1996 & Sur RK et al., 2002). Endoluminal approach, high dose-rate brachytherapy (HDRBT) alone may offer sustained symptomatic relief. An established regimen is two fractions of 8 Gy, each prescribed at 1.0 cm, which has been tested in IAEA-randomized trial; it resulted in a median survival of 237 days and the incidences of strictures (11%) and fistulae (10%) (Sur RK et al., 2002).

The combination of high dose-rate brachytherapy (HDRBT) and External Beam Radiation Therapy (EBRT) is superior to HDRBT alone for the palliation of oesophageal cancer. Addition of EBRT to HDRBT improved dysphagia-relief experience (DRE). The average benefit was an absolute +18% improvement in DRE which was sustained between 50 to 350 days of follow-up. The overall improvement in mean dysphagia score was -0.44. While HDRBT alone produced, on average, a relatively stable dysphagia score, the addition of EBRT led to a further reduction in the score compared with that from HDRBT alone (Rosenblatt et al., 2010).

5. Conclusion and future recommendations

The treatment of locally advanced esophageal cancer is a multidisciplinary approach; Radiochemotherapy is the standard of care; combined chemotherapy and radiation therapy

is the definitive treatment of choice for unresectable or medically inoperable locally advanced esophageal

Cancer, neoadjuvant chemoradiation therapy improves OAS survival.

In future, it will be crucial to improve chemotherapy regimens, radiation delivery, and surgical techniques to reduce morbidity and mortality and to increase cure rates. All esophageal cancer patients should be managed at a center where a multidisciplinary setting is well established (Kaifi et al., 2011).

To improve treatments outcomes, utilization of modern radiation therapy technology including respiratory gating, image guidance and IMRT allow high precise localization, greater dose of radiation to target and decreasing normal tissues toxicity. Incorporation of newer chemotherapeutic agents into chemoradiation regimens, also using targeted therapies in combination with chemoradiotherpy may be having promising results.

Author details

Hend Ahmed El-Hadaad and Hanan Ahmed Wahba
Clinical Oncology and Nuclear Medicine, Faculty of Medicine, Mansoura University, Mansoura, Egypt

6. References

Ajani JA, Walsh G, Komaki R et al (2004) Preoperative induction of CPT-111 and cisplatin chemotherapy followed by chemoradiotherapy in patients with locoregional carcinoma of the esophagus or gastroesophageal junction. Cancer 100:2347–354.

Allum WH, Griffin SM, Watson A et al (2002) Guidelines for the management of oesophageal and gastric cancer. Gut; 50 Suppl 5: v1-v23.

al-Sarraf M, Martz K, Herskovic A et al (1997) Progress report of combined chemoradiotherapy versus radiotherapy alone in patients with esophageal cancer: an intergroup study. J Clin Oncol. 15:277–284.

Arnott SJ, Duncan W, Gignoux M et al (2005) Preoperative radiotherapy for esophageal carcinoma. Cochrane Database Syst Rev. CD001799.

Arnott SJ, Duncan W, Kerr GR et al (1992) Low dose preoperative radiotherapy for carcinoma of the oesophagus: results of a randomized clinical trial. Radiother Oncol. 24:108-113.

Berger AC, Farma J, Scott WJ et al (2005) Complete response to neoadjuvant chemoradiotherapy in esophageal carcinoma is associated with significantly improved survival. J Clin Oncol. 23:4330-4337.

Boige V, Pignon J, Saint-Aubert B et al (2007) Final results of a randomized trial comparing preoperative 5-fluorouracil (F)/cisplatin (P) to surgery alone in adenocarcinoma of stomach and lower esophagus (ASLE): FNLCC ACCORD07-FFCD 9703 trial. J Clin Oncol. 25(18S):Abstract 4510.

Bonner JA, Harari PM, Giralt J et al (2006) Radiotherapy plus cetuximab for squamous-cell carcinoma of the head and neck. N Engl J Med 354:567- 578.

Bosset JF, Gignoux M, Triboulet JP et al (1997) Chemoradiotherapy followed by surgery compared with surgery alone in squamous-cell cancer of the esophagus. N Engl J Med 337:161-167.

Bown SG. (1991): Palliation of malignant dysphagia: surgery, radiotherapy, laser, intubation alone or in combination? Gut; 32: 841-844.

Brücher BL, Becker K, Lordick F et al (2006) The clinical impact of histopathologic response assessment by residual tumor cell quantification in oesophegeal squamous cell carcinoma. Cancer. 106:2119–27.

Carter R, Smith JS, Anderson JR (1992) Laser recanulization versus endoscopic intubation in the palliation of malignant dysphagia: a randomised prospective study. Br J Surg 79:1167–1170.

Caspar LE, Winter K, Kocha WI et al (2000) A phase I/II study of external beam radiation, brachytherapy, and concurrent chemotherapy for patients with localized carcinoma of the esophagus (Radiation Therapy Oncology Group Study 9207): final report. Cancer 88:988-95.

Chandra A, Guerrero TM, Liu HH et al (2005) Feasibility of using intensity-modulated radiotherapy to improve lung sparing in treatment planning for distal esophageal cancer. Radiother Oncol.77:247–253.

Choi JY, Lee KH, Shim YM et al (2000) Improved detection of individual nodal involvement in squamous cell carcinoma of the esophagus by FDG-PET. J Nucl Med 41:808–815.

Coia LR, Engstrom PF, Paul AR et al (1991) Long-term results of infusional 5-FU, mitomycin-C and radiation as primary management of esophageal carcinoma. Int J Radiat Oncol Biol Phys. 20:29-36.

Cooper JS, Guo, Herskovic A et al (1999) Chemoradiotherapy of locally advanced esophageal cancer long term follow –up of a prospective randomized trial (RTOG 85-01). JAMA 281:1623-1627.

Cunningham D, Allum WH, Stenning SP et al (2006) Perioperative chemotherapy versus surgery alone for resectable gastroesophageal cancer. N Engl J Med. 355:11-20.

Downey RJ, Akhurst T, Ilson D et al (2003) Whole body 18FDG-PET and the response of esophageal cancer to induction therapy: results of a prospective trial. J Clin Oncol. 21:428-432.

Dua KS (2007) Stents for palliating malignant dysphagia and fistula: is the paradigm shifting? Gastrointest Endosc. 65(1):77–81.

Eisterer W, Kendler D, De Vries A et al (2011) Triple induction chemotherapy and chemoradiotherapy for locally advanced esophageal cancer. A phase II study Anticancer Research 12:4407-4412.

Eldeeb H, El-Hadaad HA (2012) Radiotherapy Versus Stenting In treating malignant dysphagia. J Gastrointest Oncol. 3(4):322-5. DOI: 10.3978/j.issn.2078-6891.2012. 011.

Falk J, Carstens H, Lundell L et al (2007) Incidence of carcinoma of the oesophegus and gastric Cardia-Changes over time and geographical differences. Acta Oncol. 46:1070–4.

Flamen P, Van Cutsem E, Lerut A et al (2002) Positron emission tomography for assessment of the response to induction radiochemotherapy in locally advanced oesophageal cancer. Ann Oncol. 13:361-368.

Fu WH, Wang LH, Zhou ZM et al (2004) Comparison of conformal and intensity-modulated techniques for simultaneous integrated boost radiotherapy of upper esophageal carcinoma. World J Gastroenterol. 10:1098–1102.

Gao XS, Qiao X, Wu F et al (2007) Pathological analysis of clinical target volume margin for radiotherapy in patients with esophageal and gastroesophageal junction carcinoma. Int J Radiat Oncol Biol Phys 67:389–96.

Han YT, Peng L, Fang Q et al (2004) Value of radiotherapy and chemotherapy after SEMS implantation operation in patients with malignant esophageal stricture. Ai Zheng 23(6): 682–4.

Heath EI, Burtness BA, Heitmiller RF et al (2000) Phase II evaluation of preoperative chemoradiation and postoperative adjuvant chemotherapy for squamous cell and adenocarcinoma of the esophagus. J Clin Oncol.18:868-876.

Herskovic A, Martz K, al-Sarraf M et al (1992) Combined chemotherapy and radiotherapy compared with radiotherapy alone in patients with cancer of the esophagus. N Engl J Med 326:1593–1598.

Hills KS, Chopra KB, Pal A et al (1998) Self-expanding metal oesophageal endoprostheses covered and uncovered: a review of 30 cases. Eur J Gastroenterol Hepatol 5:367–370.

Homann N, Noftz MR, Klingenberg-Noftz RD et al (2008) Delayed complications after placement of self-expanding stents in malignant esophageal obstruction: treatment strategies and survival rate. Dig Dis Sci. 53(2):334–40.

Hong TS, Crowley EM, Killoran J et al (2007) Considerations in treatment planning for esophageal cancer. Semin Radiat Oncol 17:53–61.

Hosch SB, Stoecklein NH, Pichlmeier U et al (2001) Esophageal cancer: the mode of lymphatic tumor cell spread and its prognostic significance. J Clin Oncol 19:1970–5.

Kaifi JT, Gusani NJ, Jiang Y et al [2011] Multidisciplinary Management of Early and Locally Advanced Esophageal Cancer.J Clin Gastroenterol 45:391–399.

Kaklamanos IG, Walker GR, Ferry K et al (2003) Neoadjuvant treatment for resectable cancer of the esophagus and the gastroesophageal junction: A meta-analysis of randomized clinical trials. Ann Surg Oncol 10:754–761.

Kato H: Kuwano H, Nakajima M et al (2002) Usefulness of positron emission tomography for assessing the response of neoadjuvant chemo-radiotherapy in patients with esophageal cancer. Am J Surg 184:279–283.

Khushalani NI, Leichman CG, Proulx G et al (2002) Oxaliplatin in combination with protracted infusion fluorouracil and radiation: report of a clinical trial for patients with oesophegeal cancer.J Clin Oncol. 20:2844–50.

Konski A, Doss M, Milestone B et al (2005) The integration of 18-fluoro-deoxy-glucose positron emission tomography and endoscopic ultrasound in the treatment-planning process for esophageal carcinoma. Int J Radiat Oncol Biol Phys. 61:1123–1128.

Krasna M, Tepper JE, Niedzwiecki D et al (2006) Trimodality therapy is superior to surgery alone in esophageal cancer: Results of CALGB 9781. Paper presented at: ASCO 2006 Gastrointestinal Cancers Symposium, San Francisco, California, January 26-28.

Leong T, Everitt C, Yuen K et al (2006) A prospective study to evaluate the impact of FDG-PET on CT based radiotherapy treatment planning for oesophageal cancer. Radiother Oncol. 78:254– 261.

Lerut T, Coosemans W, Decker G et al (2001) Cancer of the esophagus and gastroesophegeal junction: potentially curative therapies. Surg Oncol. 10:113–22.

Lerut T, Flamen P, Ectors N et al (2000) Histopathological validation of lymph node staging with FDG-PET in cancer of the esophagus and gastro-esophageal junction. Ann Surg 232:743–752.

Loizou LA, Grigg D, Atkinson M et al (1991) A prospective comparison of laser therapy and intubation in endoscopic palliation of malignant dysphagia. Gastroenterology 100:1303–1310.

Lorchel F, Dumas JL, Noel A et al (2006) Esophageal cancer: determination of internal target volume for conformal radiotherapy. J Radiother Oncol, 80(3):327-332.

Lordick F, Ott K, Krause BJ et al (2007) PET to assess early metabolic response and to guide treatment of adenocarcinoma of the oesophagogastric junction: the MUNICON phase II trial. Lancet Oncol. 8:797-805.

Madhusudan C, Saluja SS, Pal S et al (2009) Palliative stenting for relief of dysphagia in patients with inoperable esophageal cancer: impact on quality of life. Dis Esophagus. 22(4):331–6.

Makary MA, Kiernan PD, Sheridan MJ et al (2003) Multimodality treatment for esophageal cancer: the role of surgery and neoadjuvant therapy. Am Surg. 69:693-700; discussion 700-692.

Maroju NK, Anbalagan P, Kate V et al (2006) Improvement in dysphagia and quality of life with self-expanding metallic stents in malignant esophageal strictures. Indian J Gastroenterol. 25(2):62–5.

Medical Research Council Oesophageal Cancer Working Group (2002) Surgical resection with or without preoperative chemotherapy in oesophageal cancer: a randomised controlled trial.Lancet. 359:1727-1733.

Meluch AA, Greco FA, Gray JR et al (2003) Preoperative therapy with concurrent paclitaxel/carboplatin /infusional 5- FU and radiation therapy in locoregional esophageal cancer: final results of a Minnie Pearl Cancer Research Network phase II trial. Cancer J.9:251-260.

Minsky BD, Pajak TF, Ginsberg RJ et al (2002) INT0123 (Radiation Therapy Oncology Group 94-05) phase III trial of combined-modality therapy for esophageal cancer: High-dose versus standard-dose radiation therapy. J Clin Oncol. 20:1167-1174.

Moureau-Zabotto L, Touboul E, Lerouge D et al (2005) Impact of CT and 18F-deoxyglucose positron emission tomography image fusion for conformal radiotherapy in esophageal carcinoma. Int J Radiat Oncol Biol Phys. 63:340–345.

National Comprehensive Cancer Network guidelines (2009) Clinical practice guidelines in oncology, Esophageal cancer. Available at: http://www.nccn.org/ Accessed 07 January 2009.

Nguyen P, Feng JC, Chang KJ (1999) Endoscopic ultrasound (EUS) and EUSguided fine-needle aspiration (FNA) of liver lesions. Gastrointest Endosc 50:357–361.

Nygaard K, Hagen S, Hansen HS et al (1992) Pre-operative radiotherapy prolongs survival in operable esophageal carcinoma: a randomized, multicenter study of pre-operative radiotherapy and chemotherapy.The second Scandinavian trial in esophageal cancer. World J Surg.16:1104-1109; discussion 1110.

Oh CE, Antes K, Darby M et al (1999) Comparison of 2D conventional, 3D conformal, and intensity-modulated treatment planning techniques for patients with prostate cancer with regard target-dose homogeneity and dose critical, uninvolved structures. Med Dosim 24:255–263.

Ott K, Weber WA, Lordick F et al (2006) Metabolic imaging predicts response, survival, and recurrence in adenocarcinomas of the esophagogastric junction. J Clin Oncol. 24:4692-4698.

Polee M, Tilanus HW, Eskens FA et al (2003) Phase II study of neo-adjuvant chemotherapy with paclitaxel and cisplatin given every 2 weeks for patients with a resectable squamous cell carcinoma of the esophagus. Ann Oncol 14:1253–1257.

Rebecca WO, Richard MA (2003) Combined chemotherapy and radiotherapy (without surgery) compared with radiotherapy alone in localized carcinoma of the esophagus. Cochrane Database Sys Rev (1):CD002092.

Rosenblatt E, Jones G, Sur RK et al (2010) Adding external beam to intra-luminal brachytherapy improves palliation in obstructive squamous cell oesophageal cancer: A prospective multi-centre randomized trial of the International Atomic Energy Agency. Radiotherapy and Oncology 97: 488–494.

Segalin A, Little AG, Ruol A et al (1989) Surgical and endoscopic palliation of esophageal carcinoma. Ann Thorac Surg 48:267–271.

Siegel R, Ward E, Brawley O, Jemal A (2011) Cancer statistics, 2011: The impact of eliminating socioeconomic and racial disparities on premature cancer deaths. CA Cancer J Clin 61:212.

Stahl M, Stuschke M, Lehmann N et al (2005) Chemoradiation with and without surgery in patients with locally advanced squamous cell carcinoma of the esophagus. J Clin Oncol. 23:2310-2317.

Suntharalingam M, Dipetrillo T, Ackerman P et al (2006) Cetuximab, paclitaxel, carboplatin, and radiation for esophageal and gastric cancer. Proc Am Soc Clin Oncol 24:185s, (abstr 4029).

Sur M, Sur RK, Cooper K et al (1996) Morphologic alterations in esophageal squamous cell carcinoma after preoperative high dose rate intraluminal brachytherapy. Cancer 77:2200–2205.

Sur RK, Levin CV, Rad FF et al (2002) Prospective randomised trial of HDR brachytherapy as a sole modality in palliation of advanced esophageal carcinoma: an International Atomic Energy Agency study. Int J Radiat Oncol Biol Phys 53:127–133.

Swisher SG, Hofstetter W, Wu TT et al (2005) Proposed revision of the oesophegeal cancer staging system to accommodate pathologic response (PP) following pre-operative chemoradiation. Ann Surg. 241:810–20.

Tepper J, Krasna MJ, Niedzwiecki D, et al (2008) Phase III trial of trimodality therapy with cisplatin, fluorouracil, radiotherapy and surgery compared with surgery alone for oesophegeal cancer. CALGB 9781. J Clin Oncol. 26(7):1086–92.

Tytgat GNJ, den Hartog Jager FC et al (1986) Endoscopic prosthesis for advanced esophageal cancer. Endoscopy 18:32–39.

Valerdi JJ, Tejedor M, Illarramendi JJ et al (1993) Neoadjuvant chemotherapy and radiotherapy in locally advanced esophagus carcinoma: long-term results. Int J Radiat Oncol Biol Phys. 27:843-847.

Wahba HA, El-Hadaad HA, Abd-Ellatif EA (2012) Neoadjuvant concurrent chemoradiotherapy with capecitabine and oxaliplatin in patients with locally advanced esophageal cancer. Med Oncol. 29:1693-1698.

Wakelin SJ, Deans C, Crofts TJ et al (2000) A comparison of computerised tomography, laparoscopic ultrasound and endoscopic ultrasound in the preoperative staging of oesophago-gastric carcinoma. Eur J Radiol 41:161–167.

Walsh TN, Noonan N, Hollywood D et al (1996) A comparison of multimodal therapy and surgery for esophageal adenocarcinoma. N Engl J Med 335:462-467.

Wang SL, Liao Z, Liu H et al (2006) Intensity-modulated radiation therapy with concurrent chemotherapy for locally advanced cervical and upper thoracic esophageal cancer. World J Gastroenterol. 12:5501–5508.

Weber WA, Ott K, Becker K et al (2001) Prediction of response to preoperative chemotherapy in adenocarcinomas of the esophagogastric junction by metabolic imaging. J Clin Oncol. 19:3058-3065.

Weigel TL, Frumiento C, Gaumintz E (2002) Endoluminal palliation for dysphagia secondary to esophageal carcinoma. Surg Clin North Am; 82: 747-761.

Whouley BP, Law S: Murthy SC et al (2002) The Kirschner operation in unresectable esophageal cancer. Arch Surg 137:1z28–1232.

Withers HR, Peters LJ (1980) Basic principles of radiotherapy: basic clinical parameters. In: Fletcher GA, editor. Textbook of radiotherapy. Philadelphia: Lea & Febiger p. 180.

Yaremko BP, Guerrero TM, McAleer MF et al (2008) Determination of respiratory motion for distal esophagus cancer using four-dimensional computed tomography [J]. Int J Radiat Oncol Biol Phys, 70(1):145-153.

Zhong J, Wu Y, Xu Z et al (2003) Treatment of medium and late stage esophageal carcinoma with combined endoscopic metal stenting and radiotherapy. Chin Med J. 116(1): 24–8.