

We are IntechOpen, the world's leading publisher of Open Access books Built by scientists, for scientists

6,900

Open access books available

185,000

International authors and editors

200M

Downloads

Our authors are among the

154

Countries delivered to

TOP 1%

most cited scientists

12.2%

Contributors from top 500 universities



WEB OF SCIENCE™

Selection of our books indexed in the Book Citation Index
in Web of Science™ Core Collection (BKCI)

Interested in publishing with us?
Contact book.department@intechopen.com

Numbers displayed above are based on latest data collected.
For more information visit www.intechopen.com



The Diabetic Charcot Foot – New Insights on Treatment

Fernando Grover Páez, Sylvia Elena Totsuka Sutto,
Sara Pascoe González,
Ernesto G. Cardona Muñoz and
Carlos Enrique Medina García

Additional information is available at the end of the chapter

<http://dx.doi.org/10.5772/56399>

1. Introduction

The association between Charcot neuroarthropathy (CN) and diabetes mellitus was first described by Jordan in 1936 (Jordan WR, 1936). Since that time numerous treatment protocols have been proposed for this potentially devastating condition. Early diagnosis and swift care are the keys to reducing amputation risk in this patient population. Conservative management remains efficacious for certain clinical scenarios. Treatment of the patient should take into account the stage of CN, site(s) of involvement, presence or absence of ulceration, presence or absence of infection, overall medical status, and level of compliance. The most commonly used classification is the three-staged system described by Eichenholtz: Stage I is the developmental or acute phase, Stage II is the coalescent or quiescent phase, and Stage III is the consolidation or reconstruction and reconstitution phase (Eichenholtz SN, 1966). Involvement of the midfoot is most common in the diabetic population and this site tends to be more amenable to conservative options versus hindfoot or ankle CN. Generally, conservative care for the CN foot and ankle has been recommended for the following scenarios: joints in the acute phase, deformities that are clinically stable and that do not compromise the soft tissue envelope, stable deformities without soft tissue or bone infection, patients who do not have adequate arterial perfusion to support surgical reconstruction, and those patients who are extremely high risk for anesthesia and surgical intervention due to the presence of multiple severe comorbid conditions. In this

chapter we present an overview of evidence-based non-operative treatment for CN with an emphasis on the most recent developments in therapy.

2. Clinical presentation

Acute diabetic neuroarthropathy may evolve slowly over many months or develop rapidly within weeks (Rajbhandari SM et al., 2002; Pogonowska MJ et al., 1967). The process begins with a hyperemia usually following trauma to the foot or ankle (Yu GV & Hudson JR, 2002). The trauma is often mild and may not even be recalled by the patient (Sanders LJ & Frykberg RG, 1993; Rajbhandari SM et al., 2002; Armstrong DG & Peters EJG, 2002; Armstrong DG et al., 1997). Not infrequently there may be a delay of several months between the trauma and the incipient neuroarthropathy (Sanders LJ & Frykberg RG, 1993).

Classical clinical findings are an edematous, warm foot with bounding pulses and a severe peripheral neuropathy. The normal architecture of the foot may be disturbed and plantar ulceration at the site of deformity may be present. Most patients complain of pain, but the complaints are usually less than would be expected from the clinical findings (Sanders LJ & Frykberg RG, 1993; Rajbhandari SM et al., 2002; Armstrong DG & Peters EJG, 2002). Men and women are equally affected. Most patients are in the mid-fifties, but neuroarthropathy can occur at any age (Sanders LJ & Frykberg RG, 1993). Unilateral development is most common, but a significant number of patients can develop bilateral involvement (Sanders LJ & Frykberg RG, 1993; Fabrin J et al., 2000). Patients with long-standing (>10 years) and poorly controlled diabetes, neuropathy, history of ulceration, recent history of trauma, prior neuroarthropathy, or renal transplantation are high risk and should be watched closely since early clinical findings may be mild (Sanders LJ & Frykberg RG, 1993).

However, the acute phase of CN often goes unnoticed, resulting in a delayed positive diagnosis and progression to the chronic phase, with irreversible deformation. The main problem is that, at this stage of the disease, not only is the clinical diagnosis not easy to make, but standard radiography often cannot distinguish acute CN from other conditions. Indeed, X-ray radiography may fail to document any evidence of fracture and/or dislocation. Radioisotope technetium (Tc-99m) bone scintigraphy has good sensitivity, but poor specificity, for osseous pathology and only shows increased focal uptake during the bony phase.

Only magnetic resonance imaging (MRI) is capable of revealing, in greater detail, the nature of the bony damage and evidence of inflammation in the bone (subchondral bone-marrow oedema with or without microfracture) as well as in the adjacent soft tissues (Edmonds ME et al., 2005; Chantelau E & Poll LW, 2006). MRI is particularly useful in the earliest stages of the disease, as there is a significant correlation between the intensity of bone-marrow oedema and clinical parameters such as soft-tissue oedema or pain (Schlossbauer T et al., 2008).

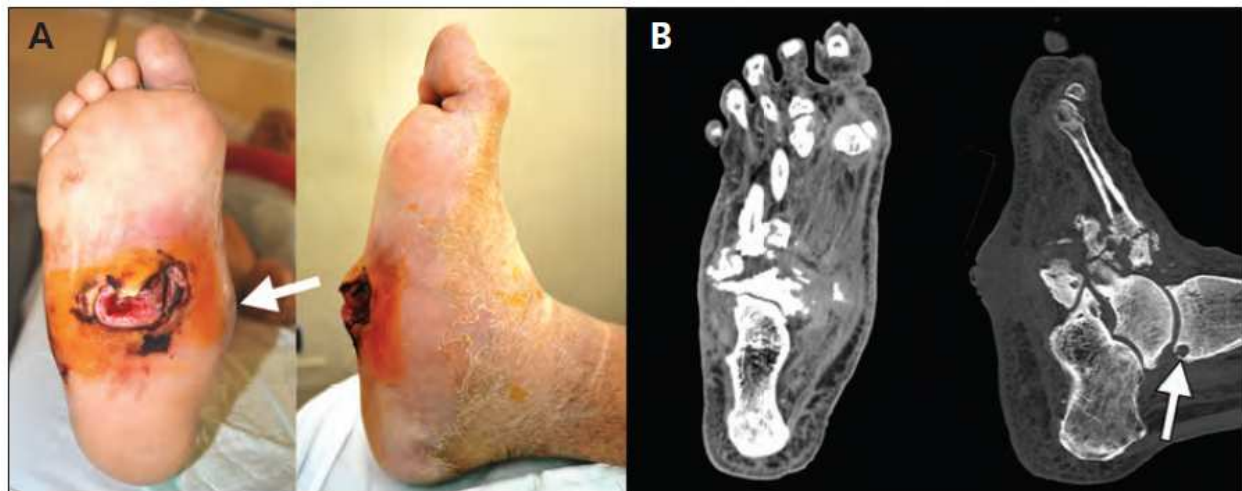

Figure 1. The right foot (plantar and lateral views) of a 59-year-old man with diabetic neuropathy showing collapse of the internal arch (arrow) and a large neuropathic ulcer on the midplantar surface. (B) Computed tomographic images (dorsoplantar and lateral views) of the patient's right foot showing a subchondral cyst (arrow), fragmentation, disorganization, and loss of normal architecture of the talus, calcaneus, tarsal bones and bases of the metatarsals. (Nicola Mumoli MD & Alberto Camaiti MD, 2012).

3. Classification

Different systems have been proposed to classify CN, and the one most commonly used is an anatomically based system, the Sanders–Frykberg anatomical classification that divides the foot into five zones, according to the joints involved (Sanders LJ & Frykberg RG, 1991):

Type I: involves the metatarsophalangeal and interphalangeal joints

Type II: involves the tarsometatarsal joints

Type III: involves the tarsal joints

Type IV: involves the subtalar joints

Type V: involves the calcaneum.

This classification has proved especially helpful in predicting prevalence and prognosis. Types I and II are the most common types, while types II and III are particularly associated with the risk of abnormal friction and ulceration, and types IV and V carry poor prognoses due to the effects of weight distribution during walking as shown in table 1, (Edmonds ME et al., 1985).

The most common classification of Charcot osteo-arthropathy follows the natural history of Charcot and was originally described by (Sidney Eichenholtz S.N, 1966). This classification incorporates both a clinical and a radiographic evaluation of the patient Table 2:

Pattern	Location	% of cases	Common findings
I	Forefoot	35	Atrophic destruction: resorption of metatarsal and phalangeal shafts, osteolysis, subluxation of metatarsophalangeal joints, plantar ulceration
II	Tarsometatarsal joint	30	Subluxation of metatarsal bases, Rocker-bottom deformity, plantar ulceration, chronic instability
III	Talonavicular, calcaneocuboid and naviculocuneiform joint	25	Osteolysis of naviculocuneiform joint, Rocker-bottom deformity, often found in conjunction with Pattern II
IV	Ankle joint	9	Extensive joint destruction, severe deformity and instability, risk of high level amputation
V	Calcaneus	1	No joint involvement, calcaneal insufficiency avulsion fracture

Table 1. Sanders-Frykberg anatomical classification of neuroarthropathy.

Pattern	Location	% of cases	Common findings
I	Forefoot	35	Atrophic destruction: resorption of metatarsal and phalangeal shafts, osteolysis, subluxation of metatarsophalangeal joints, plantar ulceration
II	Tarsometatarsal joint	30	Subluxation of metatarsal bases, Rocker-bottom deformity, plantar ulceration, chronic instability
III	Talonavicular, calcaneocuboid and naviculocuneiform joint	25	Osteolysis of naviculocuneiform joint, Rocker-bottom deformity, often found in conjunction with Pattern II
IV	Ankle joint	9	Extensive joint destruction, severe deformity and instability, risk of high level amputation
V	Calcaneus	1	No joint involvement, calcaneal insufficiency avulsion fracture

Table 2. Add caption

Stage 0 has been added to the classification by Schon and Marks in 1995 in an attempt to indicate the high risk of developing an acute Charcot osteo-arthropathy following a traumatic event. (Schon LC et al., 1998; Brodsky JW, 1999).

4. Pathogenesis

The Charcot foot has been documented to occur as a consequence of various peripheral neuropathies; however, diabetic neuropathy has become the most common etiology. The interaction of several component factors (diabetes, sensory-motor neuropathy, autonomic

neuropathy, trauma, and metabolic abnormalities of bone) results in an acute localized inflammatory condition that may lead to varying degrees and patterns of bone destruction, subluxation, dislocation, and deformity.

This inflammation leads to osteolysis and is indirectly responsible for the progressive fracture and dislocation (Uccioli L et al., 2010; La Fontaine J et al., 2008). When a bone is fractured, the release of proinflammatory cytokines including tumor necrosis factor- α and interleukin-1 β leads to increased expression of the polypeptide receptor activator of nuclear factor- κ B ligand (RANKL) from any of a number of local cell types. RANKL triggers the synthesis of the nuclear transcription factor nuclear factor- κ B (NF- κ B), and this in turn stimulates the maturation of osteoclasts from osteoclast precursor cells. At the same time, NF- κ B stimulates the production of the glycopeptide osteoprotegerin (OPG) from osteoblasts. This “decoy receptor” acts as an effective antagonist of RANKL (Mabilleau G et al., 2008). It has been suggested that this results in continual production of proinflammatory cytokines, RANKL, NF- κ B, and osteoclasts, which in turn leads to continuing local osteolysis (La Fontaine J et al., 2008). Osteoclasts generated in vitro in the presence of macrophage colony-stimulating factor and RANKL from patients with active CN have been shown to be more aggressive and exhibit an increase in their resorptive activity that peptides normally secreted from nerve terminals are also important in the underlying pathophysiology. Of these, calcitonin gene-related peptide (CGRP) is a likely candidate because it is known to antagonize the synthesis of RANKL.

The receptor activator of the nuclear factor-ligand (RANKL)-activated peripheral blood monocytes have been found to induce a significant increase in bone resorption in Charcot patients (Mabilleau G et al., 2008; Jeffcoate W et al., 2004).

A possible link between proinflammatory cytokines and neuroarthropathy in the context of an exaggerated inflammatory response to trauma has been mentioned (Jeffcoate WJ et al, 2005), and the inability of the Charcot patient to control the intensity and the length of the local inflammatory response would lead to increased expression of tumor necrosis factor- α (TNF- α) and interleukin-1(IL-1) which, in turn, would trigger increased expression of RANKL leading to maturation of osteoclast and subsequent bone changes (Lam J et al., 2002; Boyle WJ et al., 2003).

The immune phenotype of monocytes was assessed by testing spontaneous and induced production of proinflammatory and anti-inflammatory cytokines by measuring the expression of surface molecules (CD40, CD80, and CD86), which enable monocytes to become competent co-stimulatory cells and to activate T lymphocytes responses (Jenkins MK et al 2001; Kuchroo VK et al., 1995; Yang Yet al., 1996), and by studying the ability of monocytes to undergo apoptosis, an important homeostatic mechanism that contributes to regulate the intensity and length of the inflammatory response (Gonzalez-Mejia ME & Doseff AI, 2009). Patients with acute Charcot, in both the active and recovered phase, peripheral monocytes acquire a proinflammatory immune phenotype characterized by increased production of proinflammatory cytokines, reduced secretion of anti-inflammatory cytokines, increased expression of co-stimulatory surface molecules, and increased resistance to apoptosis. Monocytes play a pivotal role in the development and maintenance of the inflammatory response. These cells are the major source of proinflammatory (TNF- α , IL-1, and IL-6) as well as anti-inflammatory

cytokines (IL-4 and IL-10) (Kiener PA et al., 1995; Gautam SC et al., 1992; De Waal Malefyt R et al., 1991).

Alterations in the correct timing, intensity, and balance of expression of proinflammatory versus anti-inflammatory cytokines by monocytes result in pathologic modulation of the inflammatory response. Thus, the activation of inflammatory and suppression of anti-inflammatory cytokines that we have found in patients with acute Charcot is consistent with the abnormally intense and prolonged inflammatory response that characterizes the acute phase of this disease. A growing body of evidence is now supporting the possibility that this inflammatory response plays a pivotal pathogenetic role in the changes in bone and joints that develop in this disorder (Jeffcoate WJ et al., 2005). Indeed, TNF- α and IL-1, released during the inflammatory process, trigger increased expression of RANKL (Lam J et al., 2002; Xu J et al., 2009).

This leads to activation of NF κ -B and maturation of osteoclasts (Hofbauer LC et al 2000; Boyle WJ et al 2003). The effect of IL-6 on bone formation/resorption is more controversial. Indeed, several reports support the possibility that IL-6 could in fact induce an osteocytic phenotype (Chipoy C et al., 2004). As opposed, there is evidence that IL-6 can stimulate osteoclasts differentiation and bone resorption by an indirect mechanism, increasing interactions between osteoblasts and osteoclasts (Palmqvist Pet al 2002; Sinistro A et al., 2008).

The proinflammatory alterations we have found in the phenotype of monocytes from acute Charcot patients appear to be specific to this condition. Indeed, both the phenotype of monocytes from diabetic patients with uncomplicated neuropathy and that of monocytes from diabetic patients with neuropathy and osteomyelitis-associated foot inflammation was not different from that of cells from healthy control subjects. This indicates that neither diabetes nor neuropathy or inflammation, per se, is associated with any modulation of the inflammatory response of monocytes. Interestingly, we found that all the modification of the immune phenotype of monocytes disappeared after recovery in patients with acute Charcot. This suggests that the initiating cause that triggers the inflammatory response in patients with acute Charcot acts in an environment where mechanisms that physiologically control the intensity and duration of inflammation are lacking. calcitonin gene-related peptide (CGRP), a 37-amino acid peptide widely distributed in the central and peripheral nervous systems and mainly in sensory nerves (Poyner DR et al., 1992), has been shown to inhibit proinflammatory cytokine production and augment the release of IL-10 by monocytes (Feng Y et al., 1997).

On the other hand, pathogenetic knowledge has focused on purely mechanical theories for some time. Two theories, initially thought to be competing concepts, are now considered to be overlapping to varying degrees. On the one hand, the neurotraumatic theory proposes that, in the presence of sensorimotor neuropathy, abnormal plantar pressure occurs. This is supported by the amyotrophy of intrinsic muscles, and the imbalance between the extensor and flexor muscles. In addition, the bones and joints lose their protective sensory capacity, allowing repetitive trauma that, in turn, leads to excessive extension of the ligaments, and microfractures and more joint dislocation. On the other hand, the neurovascular theory suggests that the autonomic neuropathy leads to a hyperaemic state, with an increase in blood flow to the lower limbs due to the development of arteriovenous shunts. The hyperaemia

appears to cause osteopenia, bone resorption and bone weakening. Ultimately, it is on this weakened foot that, either spontaneously or due to minor trauma, microfractures and dislocations occur.

Although both these theories are attractive, they are not able to explain some of the typical features of acute Charcot neuro-osteoarthropathy (CN) and, in particular, why the condition is unilateral while neuropathy is most often bilateral, why CN is so infrequent while neuropathy is a common complication of diabetes, and what is the link with the inflammatory reaction that is initially observed.

There is no singular cause for the development of the Charcot foot, but there are factors that predispose to its development, as well as a number of likely precipitating events. The current belief is that once the disease is triggered in a susceptible individual, it is mediated through a process of uncontrolled inflammation in the foot. This inflammation leads to osteolysis and is indirectly responsible for the progressive fracture and dislocation that characterizes its presentation (Jeffcoate WJ et al, 2005).

However, as mentioned before, the common link is the local inflammation (Baumhauer et al, 2006) that is associated with the release of proinflammatory cytokines such as interleukin (IL)-1 β and tumour necrosis factor (TNF)- α , which are known mediators of bone resorption *via* excess osteoclastic activity (Petrova et al, 2007).

Interestingly, a dissociation between the local inflammatory response related to the increased proinflammatory cytokine secretion and lack of systemic inflammatory response has been found in patients with CN (Jeffcoate WJ, 2004).

At the same time, NF- κ B induces the increased expression of the glycoprotein osteoprotegerin (OPG), which acts as a decoy receptor for RANK-L to effectively neutralize its effect and so avoid excess osteolysis (Fig. 1) (Boyle WJ, 2003).

The role of this pathway in acute CN pathogenesis is supported by the fact that the same RANK/RANK-L/OPG system is also involved in the process of medial arterial calcification, a feature that is strongly associated with both the distal symmetrical neuropathy of diabetes (Jeffcoate WJ, 2009) and CN (Sinha S et al., 1972; Clouse ME et al., 1974).

Nevertheless, a traumatic triggering factor causes the release of inflammatory cytokines that increase the expression of RANK-L, thereby resulting in clinical signs of inflammation, osteoclast maturation and activation, and osteolysis. Physiologically, this process is limited by immobilization in response to the pain caused by local inflammation. However, when pain perception is reduced due to sensory neuropathy, there is no protective suppression, thereby allowing the inflammatory process to continue which, in turn, ultimately leads to osteolysis and bone breakdown. The result is the establishment of a vicious circle of inflammation and worsening structural damage to the foot (Frykberg RG et al, 2000).

4.1. Diferential diagnosis

While cellulitis may seem to be the likely diagnosis, if a patient with long-standing diabetes, a history of poor glycemic control, and peripheral neuropathy presents with a red, hot, swollen

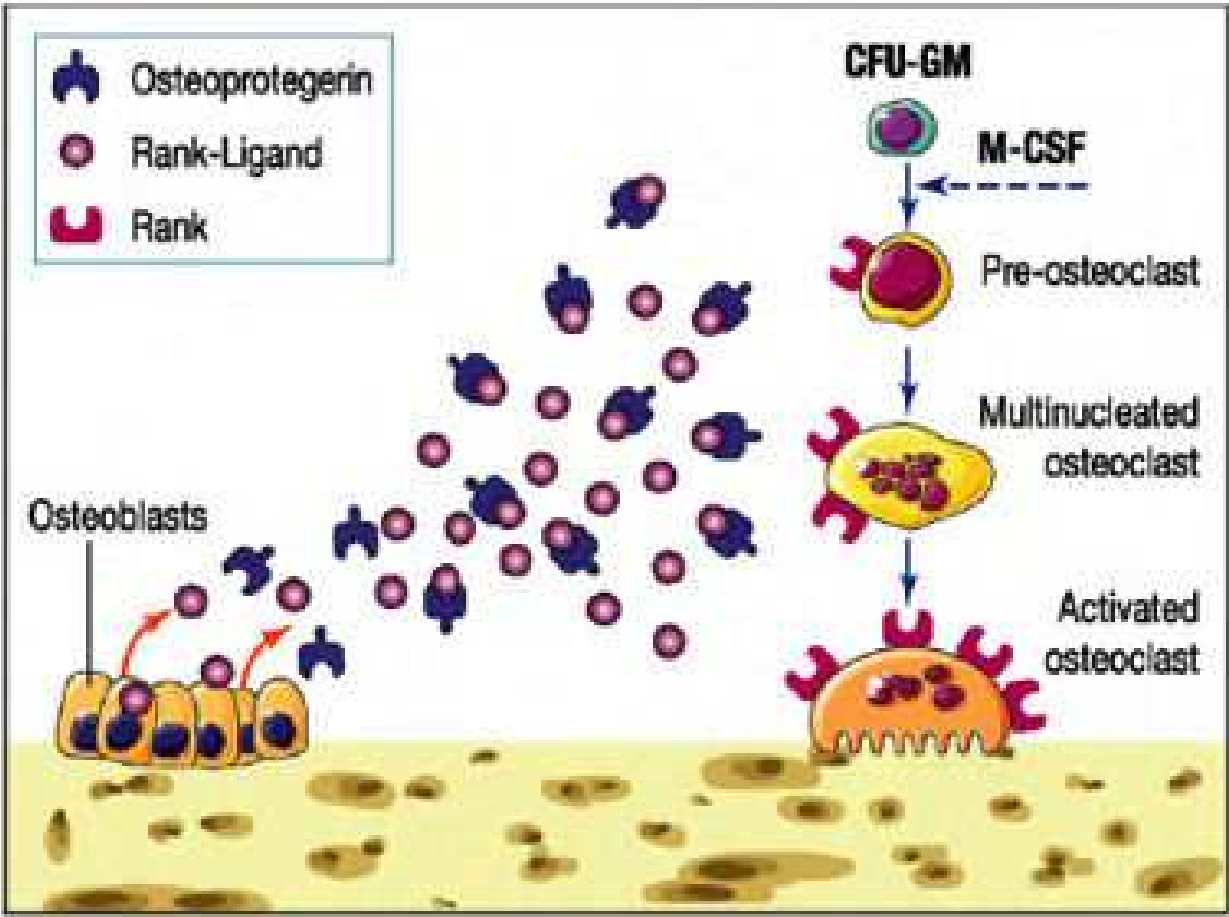


Figure 2. Diagrammatic representation of the RANK/RANK-L/OPG signalling pathway in the process of bone resorption. On the one hand, RANK-L (receptor activator of nuclear factor- κ B ligand), a surface-bound molecule found on osteoblasts and bone-marrow stromal cells, binds to its specific membrane-bound receptor RANK (receptor activator of nuclear factor- κ B) at the surface of preosteoclasts and other cells of this lineage. The binding subsequently triggers a kinase cascade that promotes osteoclast differentiation, activation and survival. On the other hand, OPG (osteoprotegerin), which is also expressed by osteoblasts, acts as a decoy receptor to bind and effectively neutralize RANK-L which, in turn, limits excess osteoclastogenesis and osteolysis. CFU-GM: colony-forming unit granulocyte-macrophage; M-CSF: monocyte colony-stimulating factor. (L. Molines et al, 2010)

foot with no history of open ulceration, then Charcot neuroarthropathy should be at the top of the list in the differential diagnosis. Other possibilities include osteomyelitis, acute gout, cellulitis, abscess, neuropathic fracture, and deep venous thrombosis. However, if the patient has no open ulceration or history of an open wound, infection is probably not the culprit. Most diabetic foot infections begin with a direct inoculation through an opening in the skin, such as a diabetic neuropathic foot ulcer.

4.2. Laboratory tests

There are no laboratory criteria for the diagnosis of Charcot neuroarthropathy and no hematologic markers, but laboratory testing can help narrow the differential diagnosis. Leukocytosis, an elevated C-reactive protein and erythrocyte sedimentation rate, and recent

unexplained hyperglycemia suggest infection. However, unremarkable results on clinical tests in this population may not comprehensively exclude infection.

4.3. Imaging studies

Radiographs are the primary initial imaging method for evaluation of the foot in diabetic patients. Easily available and inexpensive, they provide information on bone structure, alignment, and mineralization. X-rays may be normal or show subtle fractures and dislocations or later show more overt fractures and subluxations.

In later stages, the calcaneal inclination angle is reduced and the talo-first metatarsal angle is broken.

However, radiographic changes of Charcot neuropathic osteoarthropathy (CN) are typically delayed and have low sensitivity (Morrison WB et al., 2002).

Magnetic resonance imaging (MRI) allows detection of subtle changes in the early stages of active Charcot neuropathic osteoarthropathy when X-rays could still be normal. MRI primarily images protons in fat and water and can depict anatomy and pathology in both soft tissue and bone in great detail. Because of its unique capability of differentiating tissues with high detail, MRI has a high sensitivity and specificity for osteomyelitis and has become the test of choice for evaluation of the complicated foot in diabetic patients (Morrison WB et al., 2001).

Although not required for diagnosis when X-rays are diagnostic for Charcot bone and joint changes, MRI is very useful in making the diagnosis at its earliest onset before such changes become evident on plain films. Nuclear medicine includes a number of exams based on the use of radioisotopic tracers. Three-phase bone scans, based on technetium-99m (^{99m}Tc), are highly sensitive for active bone pathology. However, diminished circulation can result in false-negative exams and, perhaps more importantly, uptake is not specific for osteoarthropathy. Labeled white blood cell scanning (using ^{111}In or ^{99m}Tc) provides improved specificity for infection in the setting of neuropathic bone changes but it can be difficult to differentiate soft tissue from bone (Keidar Z et al., 2005; Palestro CJ et al., 1998).

More recently, positron emission tomography scanning has been recognized as having potential for diagnosis of infection and differentiating the Charcot foot from osteomyelitis (Hopfner S et al., 2005). However, this remains investigational at this time. Evaluation of bone mineral density (BMD) may be useful in those with diabetes to assess onset of CN as well as fracture risk. BMD can be assessed using dual-energy X-ray absorptiometry or calcaneal ultrasound. (Frykberg RG et al., 2010).

Experts agree that radiographs are important as the first exam in virtually all settings (Hopfner S et al., 2005;). However, a negative result obviously should not offer any confidence regarding lack of disease.

The MRI is very effective at excluding osseous disease. If the patient has an ulceration with a high likelihood of deep infection, MRI is the best diagnostic modality. The decision of nuclear imaging versus MRI is largely based on personal preference, availability, and local experience.

In general, if metal is present in the foot, nuclear medicine exams are preferred, whereas diffuse or regional ischemia makes MRI the preferred exam.

The diagnosis of active Charcot foot is primarily based on history and clinical findings but should be confirmed by imaging. Inflammation plays a key role in the pathophysiology of the Charcot foot and is the earliest clinical finding. The X-rays should be the initial imaging performed, and one should look for subtle fractures or subluxations if no obvious pathology is visible. MRI or nuclear imaging can confirm clinical suspicions in the presence of normal-appearing radiographs. (Lee C et al., 2011).

In the other hand, Positron emission tomography (PET) with fluorine-18 fluorodeoxyglucose is also gaining support, especially when combined with computed tomography (CT). This PET-CT hybrid has better anatomic localization than PET alone.

PET-CT is very reliable for differentiating Charcot neuroarthropathy from osteomyelitis, a distinction that can be difficult to make when Charcot neuroarthropathy is complicated by adjacent loss of skin integrity. The sensitivity of PET-CT in this situation has been reported as 100%, and its specificity 93.8%.²²

5. Treatment

The goals of treatment for acute or quiescent Charcot neuroarthropathy should be to maintain or achieve structural stability of the foot and ankle, to prevent skin ulceration, and to preserve the plantigrade shape of the foot so that prescription footwear can be used.

Immobilization: A total-contact cast is worn until the redness, swelling, and heat subside, generally 8 to 12 weeks, after which the patient should use removable braces or a Charcot restraint orthotic walker for a total of 4 to 6 months of treatment. Many physicians also recommend elastic stockings (eg, Stockinette) or an elastic tubular bandage (eg, Tubigrip) to reduce edema under the cast.

6. Drug therapy

Due to bone mineral density alterations in CN patients manifested by localized osteopenic changes, bisphosphonates have been tested for their benefit with off-loading in Stage I. Bisphosphonates are pyrophosphate analogs that inhibit osteoclastic bone resorption and are commonly used in treatment of conditions characterized by abnormal bone turnover. Pamidronate is the most commonly used and acts by attaching onto hydroxyapatite crystals in newly synthesized bone matrix, blocking access of osteoclast precursors to this matrix. (Jude EB et al., 2001) performed a randomized double-blind placebo-controlled trial in 39 patients with active Charcot in which a single 90 mg pamidronate infusion was administered and standard off-loading provided while foot temperatures, symptoms, and bone turnover markers were measured over 1-year. There was a statistically significant reduction in bone turnover,

symptoms, and disease activity. Similarly, (Pitocco et al., 2005) showed significant reduction in bone resorption markers with the use of another bisphosphonate alendronate and noted clinical improvements in the CN foot at 6 months. Some clinicians also prescribe bisphosphonates in the early stages of treatment, as the bone mineral density of the affected foot is low. Unfortunately, while these drugs can significantly reduce the levels of bone turnover markers, temperature, and pain, evidence of clinical benefit such as an earlier return to ambulation or radiographic improvement is weak at best.

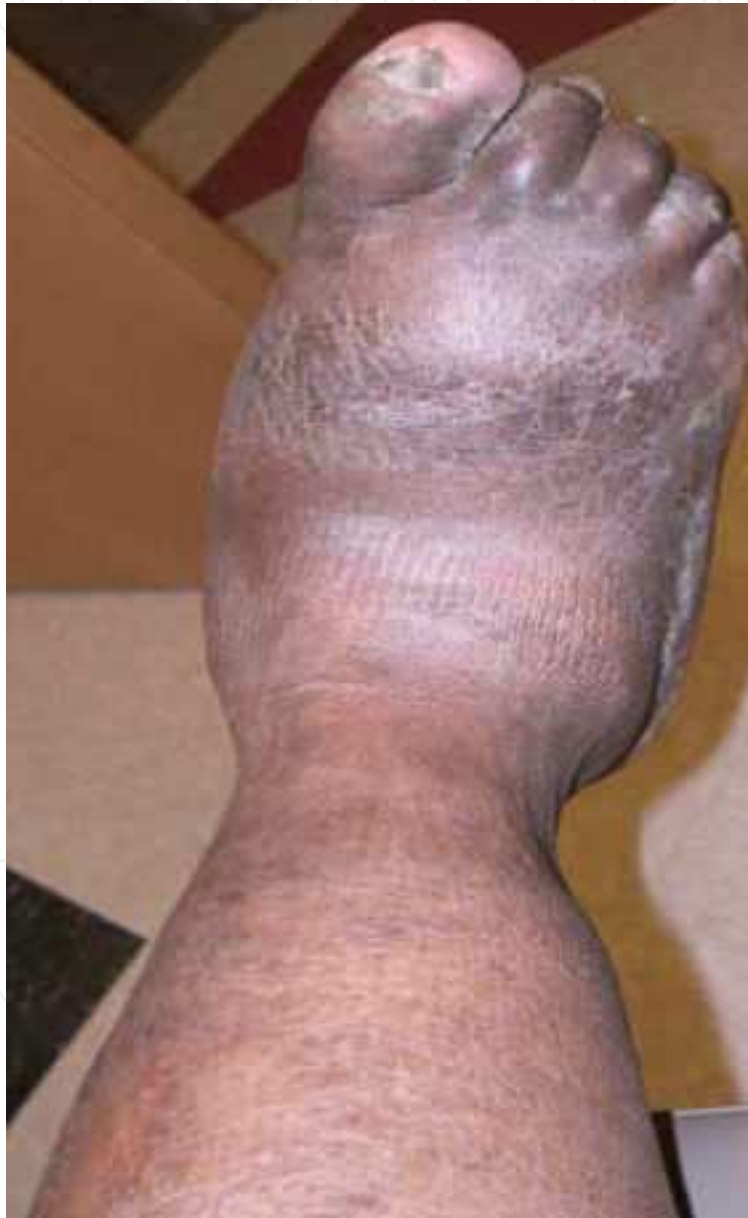

Figure 3. Neuro-osteoarthropathy of Charcot foot

Surgery is reserved for severe ankle and midfoot deformities that are susceptible to skin ulcerations and that make braces and orthotic devices difficult to use.

7. New insights on treatment

Similarly, use of calcitonin and non-steroidal anti-inflammatory drugs has been reported as adjunct treatment to conventional therapy. Recently, new anti-inflammatory therapeutic agents such as corticosteroids, TNF- α antagonists (infliximab, etanercept) and RANK-L antagonists (denosumab) have been proposed, but further research is needed.

Another potential therapeutic agents that also have a direct effect on the RANK-L/OPG system in addition to calcitonin are inhibitors of tumor necrosis factor- α (TNF- α), glucocorticoids and non-steroidal anti-inflammatories, (Jeffcoate WJ et al., 2005) has also mentioned other future options including synthetic OPG and RANK-L antagonists and other inhibitors of NF- κ B and TNF- α like diacerein.

Diacerein is another medication used frequently in the treatment of some articular diseases as a result of its effect on the inflammatory process. Diacerein decreases cytokine concentrations, in particular, TNF- α and IL-1 β and it could be one of the most promising strategies in the current treatment of the acute phase of the diabetic Charcot foot.

Diacerein (9,10-dihydro-4,5-bis(acetyloxy)9,10-dioxo-2-anthracene carboxylic acid) is one of symptomatic slow-acting drugs in osteoarthritis (SYSADOA) for the treatment of OA (Bruyère O et al., 2008). After oral administration, it is rapidly broken down and deacetylated into its active metabolite, rhein, (Spencer CM., 1997). The potential disease modifying properties of diacerein and its metabolite have been shown in vitro and in vivo models to be primarily due to potent inhibition of the production and activity of inflammatory cytokines and other catabolic cytokines expressed in OA and in CN, which are involved in cartilage catabolism and also may induce the apoptosis of chondrocytes (De Isla NG et al, 2008; Tamura T et al., 2001)

In addition to this, Briefly, activation of osteoclasts involved in osteolysis is accomplished by the nuclear transcription factor NF- κ B. The expression of NF- κ B is induced by the cytokine RANK-L, which is accompanied by increased production of osteoprotegerin (OPG). The RANK-L/OPG system's theoretical role in osteopenia associated with diabetic neuropathy led to the development and use of intranasal salmon calcitonin for treatment of acute CN. A randomized controlled trial by (Bem et al., 2006) was performed on 32 acute CN patients administered 200 IU daily, showing reduction in markers of bone turnover as well as a decreased time to healing. This therapy has shown fewer complications compared to bisphosphonate use.

8. Conclusion

Conservative options continue to evolve in their indications for the treatment of the CN foot and ankle. The modalities discussed within this chapter provide a wide variety of options; yet, a further higher level of evidence studies is warranted. There is no doubt that there are specific indications for conservative management versus surgical. Regardless of the chosen

treatment pathway, all protocols should be specific to the patient based on their lower extremity pathology, overall medical status, and ability to comply with the given therapy.

Author details

Fernando Grover Páez, Sylvia Elena Totsuka Sutto, Sara Pascoe González,
Ernesto G. Cardona Muñoz and Carlos Enrique Medina García

Department of Physiology, Cardiovascular Research Unit, University Center of Health Science, Universidad de Guadalajara, México

References

- [1] Armstrong, D. G. Peters EJG. Charcot's arthropathy of the foot. *J Am Podiatr Med Assoc* (2002). , 92, 390-4.
- [2] Armstrong, D. G, Todd, W. F, Lavery, L. A, Harkless, L. B, & Bushman, T. R. The natural history of acute Charcot's arthropathy in a diabetic foot specialty clinic. *Diabetic Med* (1997). , 14, 357-63.
- [3] Baumhauer, J. F, Keefe, O, Schon, R. J, Pinzur, L. C, & Cytokine-induced, M. S. osteoclastic bone resorption in Charcot arthropathy: an immunohistochemical study. *Foot Ankle Int* (2006). , 27, 797-800.
- [4] Bem, R, Jirkovska, A, Fejfarova, V, Skibova, J, & Jude, E. B. Intranasal calcitonin in the treatment of acute Charcot neuroosteoarthropathy: a randomized controlled trial. *Diabetes Care* (2006).
- [5] Boyle, W. J, Simonet, W. S, & Lacey, D. L. Osteoclast differentiation and activation. *Nature* (2003). , 423, 337-42.
- [6] Brodsky, J. W. The diabetic foot. In: Coughlin MJ, Mann RA, editors. *Surgery of the foot and ankle*. Mosby; (1999). , 895e969.
- [7] Bruyère, O, Burlet, N, Delmas, P. D, Rizzoli, R, Cooper, C, & Reginster, J. Y. Evaluation of symptomatic slow-acting drugs in osteoarthritis using the GRADE system," *BMC Musculoskeletal Disorders*, article 165, (2008). , 9
- [8] Chantelau, E, & Poll, L. W. Evaluation of the diabetic foot by MR imaging or plain radiography-an observational study. *Exp Clin Endocrinol Diabetes* (2006). , 114, 428-31.
- [9] Chipoy, C, Berreur, M, Couillaud, S, Pradal, G, Vallette, F, & Colombeix, C. Re'dini F, Heymann D, Blanchard F. Downregulation of osteoblast markers and induction of

the glial fibrillary acidic protein by oncostatin M in osteosarcoma cells require PKCdelta and STAT3. *J Bone Miner Res* (2004). , 19, 1850-1861.

- [10] Clouse, M. E, Gramm, H. F, Legg, M, & Flood, T. Diabetic osteoarthropathy: clinical and roentgenographic observations in 90 cases. *Am J Roentgenol Radium Ther Nucl Med* (1974). , 121, 22-33.
- [11] De Isla, N. G, Mainard, D, Muller, S, & Stoltz, J. F. In vitro effects of diacerein on NO production by chondrocytes in response to proinflammatory mediators," *Bio-Medical Materials and Engineering, supplement*, (2008). , 18(1), S99-S104.
- [12] De Waal Malefyt RAbrams J, Bennett B, Figdor CG, de Vries JE. Interleukin 10 (IL-10) inhibits cytokine synthesis by human monocytes: an autoregulatory role of IL-10 produced by monocytes. *J Exp Med* (1991). , 174, 1209-1220.
- [13] Edmonds, M. E, Clarks, M. B, Newton, S, Barrett, J, & Watkins, P. J. Increased uptake of bone radiopharmaceutical in diabetic neuropathy. *Q J Med* (1985). , 57, 843-55.
- [14] Edmonds, M. E, Petrove, N. L, & Elias, D. A. The earliest magnetic resonance imaging sign of mid-foot charcot osteoarthropathy is oedema of subchondral (subarticular) bone marrow which needs prompt therapeutic offloading. *Diabet Med* (2005). Suppl. 2):93. , 272.
- [15] Eichenholtz, S. N. Charcot joints. Springfield, IL: Charles C. Thomas; (1966).
- [16] Fabrin, J, Larsen, K, & Holstein, P. E. Long-term follow-up in diabetic Charcot feet with spontaneous onset. *Diabetes Care* (2000). , 23, 796-800.
- [17] Feng, Y, Tang, Y, Guo, J, & Wang, X. Inhibition of LPS-induced TNF- α production by calcitonin gene-related peptide (CGRP) in cultured mouse peritoneal macrophages. *Life Sci* (1997). , 61, 281-287.
- [18] Frykberg, R. G, & Eneroth, M. Principles of conservative management. In *The Diabetic Charcot Foot: Principles and Management*. Frykberg RG, Ed. Brooklandville, MD, Data Trace Publishing Company, (2010). , 93-116.
- [19] Frykberg, R. G, & Mendeszoon, E. Management of the diabetic Charcot foot. *Diabetes Metab Res Rev* (2000). Suppl. 1):S, 59-65.
- [20] Gautam, S. C, Chikkala, N. F, & Hamilton, T. A. Anti-inflammatory action of IL-4: negative regulation of contact sensitivity to trinitrochlorobenzene. *J Immunol* (1992). , 148, 1411-1415.
- [21] Gonzalez-mejia, M. E, & Doseff, A. I. Regulation of monocytes and macrophages cell fate. *Front Biosci* (2009). , 14, 2413-2431.
- [22] *Growth Factor Rev* 2009; 20:7-17.

- [23] Hofbauer, L. C, & Heufelder, A. E. The role of receptor activator of nuclear factor-ligand and osteoprotegerin in the pathogenesis and treatment of metabolic bone diseases. *J Clin Endocrinol Metab* (2000). , 85, 2355-2363.
- [24] Hopfner, S, Krolak, C, Kessler, S, & Tiling, R. Preoperative imaging of Charcot neuroarthropathy. Does the additional application of 18F-FDG-PET make sense?. *Nuklearmedizin* (2005). , 45, 15-20.
- [25] Jeffcoate, W. J, Game, F. L, & Cavanagh, P. R. The role of proinflammatory cytokines in the cause of neuropathic osteoarthropathy (acute Charcot foot) in diabetes. *Lancet* (2005). , 366, 2058-61.
- [26] Jeffcoate, W. J, Rasmussen, L. M, Hofbauer, L. C, & Game, F. L. Medial arterial calcification in diabetes and its relationship to neuropathy. *Diabetologia* (2009). , 52, 2478-88.
- [27] Jeffcoate, W. J. Charcot neuro-osteoarthropathy. *Diabetes Metab Res Rev* (2008). Suppl. 1):S, 62-5.
- [28] Jeffcoate, W. J. Vascular calcification and osteolysis in diabetic neuropathy Is RANK-L the missing link? *Diabetologia* (2004). , 47, 1488-92.
- [29] Jenkins, M. K, Khoruts, A, Ingulli, E, Mueller, D. L, Mcsorley, S. J, Reinhardt, R. L, Itano, A, & Pape, K. A. In vivo activation of antigenspecific CD4 T cells. *Annu Rev Immunol* (2001). , 19, 23-45.
- [30] Jordan, W. R. Neuritic manifestations in diabetes mellitus. *Arch Intern Med* (1936). , 57, 307-66.
- [31] Jude, E. B, Selby, P. L, Burgess, J, Lilleystone, P, Mawer, E. B, Page, S. R, et al. Bisphosphonates in the treatment of Charcot neuroarthropathy: a double-blind randomised controlled trial. *Diabetologia* (2001). , 44, 2032-7.
- [32] Keidar, Z, Militianu, D, Melamed, E, Bar- Shalom, R, & Israel, O. The diabetic foot: initial experience with 18F-FDG PET/CT. *J Nucl Med* (2005). , 46, 444-449.
- [33] Kiener, P. A, Moran-davis, P, Rankin, B. M, Wahl, A. F, Aruffo, A, & Hollenbaugh, D. Stimulation of CD40 with purified soluble gp39 induces proinflammatory responses in human monocytes. *J Immunol* (1995). , 155, 4917-4925.
- [34] Kuchroo, V. K, Das, M. P, Brown, J. A, Ranger, A. M, Zamvil, S. S, Sobel, R. A, Weiner, H. L, Nabavi, N, & Glimcher, L. H. B. and B7-2 costimulatory molecules activate differentially the Th1/Th2 developmental pathways: application to autoimmune disease therapy. *Cell* (1995). , 80, 707-718.
- [35] La Fontaine JHarkless LB, Sylvia VL, Carnes D, Heim-Hall J, Jude E. Levels of endothelial nitric oxide synthase and calcitonin gene-related peptide in the Charcot foot: a pilot study. *J Foot Ankle Surg* (2008). , 47, 424-429.

- [36] Lam, J, Abu-amer, Y, Nelson, C. A, Fremont, D. H, Ross, F. P, & Teitelbaum, S. L. Tumor necrosis factor superfamily cytokines and the pathogenesis of inflammatory osteolysis. *Ann Rheum Dis* (2002). Suppl. 2):iii83, 82.
- [37] Lee, C. Rogers, Robert G. Frykberg, David G. Armstrong, Andrew J.M. Boulton, The Charcot Foot in Diabetes. *Diabetes Care* (2011). , 34, 2123-2129.
- [38] Mabileau, G, Petrova, N. L, Edmonds, M. E, & Sabokbar, A. Increased osteoclastic activity in acute Charcot's osteoarthropathy: the role of receptor activator of nuclear factor-ligand. *Diabetologia* (2008). , 51, 1035-1040.
- [39] Molines, L, et al. Charcot's foot: Newest findings on its pathophysiology, diagnosis and treatment, *Diabetes & Metabolism* (2012). , 36, 251-255.
- [40] Morrison, W. B, Ledermann, H. P, & Schweitzer, M. E. MR imaging of the diabetic foot. *Magn Reson Imaging Clin N Am* (2001). , 9, 603-613.
- [41] Morrison, W. B, & Ledermann, H. P. Work-up of the diabetic foot. *Radiol Clin North Am* (2002). , 40, 1171-1192.
- [42] Nicola Mumoli MD & Alberto Camaiti MD Charcot foot, *CMAJ*, (2012).
- [43] Palestro, C. J, Mehta, H. H, Patel, M, et al. Marrow versus infection in the Charcot joint: indium-111 leukocyte and technetium-99m sulfur colloid scintigraphy. *J Nucl Med*(1998). , 39, 346-350.
- [44] Palmqvist, P, Persson, E, Conaway, H. H, & Lerner, U. H. IL-6, leukemia inhibitory factor, and oncostatin M stimulate bone resorption and regulate the expression of receptor activator of NF-ligand, osteoprotegerin, and receptor activator of NF- in mouse calvariae. *J Immunol* (2002). , 169, 3353-3362.
- [45] Pitocco, D, Ruotolo, V, Caputo, S, Mancini, L, Collina, C. M, Manto, A, et al. Six-month treatment with alendronate in acute Charcot neuroarthropathy: a randomized controlled trial. *Diabetes Care* (2005). , 28, 1214-5.
- [46] Pogonowska, M. J, Collins, L. C, & Dobson, H. L. Diabetic osteopathy. *Radiology* (1967). , 89, 265-71.
- [47] Poyner, D. R. Calcitonin gene-related peptide: multiple actions, multiple receptors. *Pharmacol Ther* (1992). , 56, 23-51.
- [48] Rajbhandari, S. M, Jenkins, R. C, Davies, C, & Tesfaye, S. Charcot neuroarthropathy in diabetes mellitus. *Diabetologia* (2002). , 45, 1085-96.
- [49] Sanders, L. J, & Frykberg, R. G. Charcot foot. In: Levin ME, O'Neal LW, Bowker JH, eds. *The Diabetic Foot*. St. Louis: Mosby, (1993). , 1993, 149-80.
- [50] Sanders, L. J, & Frykberg, R. G. Diabetic neuropathic osteoarthropathy: the Charcot foot. In: Frykberg RG, editor. *The high risk foot in diabetes mellitus*. New York: Churchill Livingstone; (1991). , 297-333.

- [51] Schlossbauer, T, Mioc, T, Sommerey, S, Kessler, S. B, Reiser, M. F, & Pfeifer, K. J. Magnetic resonance imaging in early stage charcot arthropathy: correlation of imaging findings and clinical symptoms. *Eur J Med Res* (2008). , 22, 409-14.
- [52] Schon, L. C, Weinfeld, S. B, Horton, G. A, & Resch, S. Radiographic and clinical classification of acquired midtarsus deformities. *Foot Ankle Int* (1998). , 19(6), 394-404.
- [53] Sinha, S, Munichoodappa, C, & Kozak, G. P. Neuro-arthropathy (Charcot joints) in diabetes mellitus: a clinical study of 101 cases. *Medicine (Baltimore)* (1972). , 51, 191-210.
- [54] Sinistro, A, Almerighi, C, Ciaprin, C, Natoli, S, & Sussarello, E. Di Fino S, Calo-Car-ducci F, Rocchi G, Bergamini A. Downregulation of CD40 ligand response in monocytes from sepsis patients. *Clin Vaccine Immunol* (2008). , 15, 1851-1858.
- [55] Spencer, C. M, & Wilde, M. I. Diacerein," *Drugs*, (1997). , 53(1), 98-108.
- [56] Stanley & Collier Charcot osteo-arthropathy, *Current Orthopaedics*, (2008). , 22, 428-433.
- [57] Tamura, T, Kosaka, N, Ishiwa, J, Sato, T, Nagase, H, & Ito, A. Rhein, an active metabolite of diacerein, down-regulates the production of pro-matrix metalloproteinases-1,-3,-9 and-13 and up-regulates the production of tissue inhibitor of metalloproteinase-1 in cultured rabbit articular chondrocytes," *Osteoarthritis and Cartilage* (2001).
- [58] Uccioli Luigi Anna Sinistro, Cristiana Almerighi. Proinflammatory Modulation of the Surface and Cytokine Phenotype of Monocytes in Patients With Acute Charcot Foot. *Diabetes Care* (2010). , 33, 350-355.
- [59] Vega, D, Maalouf, N. M, & Sakhaee, K. The role of receptor activator of nuclear factor- κ B (RANK)/RANK Ligand/Osteoprotegerin: clinical implications. *J Clin Endocrinol Metab* (2007). , 92, 4514-21.
- [60] Xu, J, & Wu, . . NF- modulators in osteolytic bone diseases. *Cytokine*
- [61] Yang, Y, Wilson, J. M, & Ligand-dependent, C. D. T cell activation: requirement of B7- CD28 signaling through CD40. *Science* (1996). , 273, 1862-1864.
- [62] Yu, G. V, & Hudson, J. R. Evaluation and treatment of stage 0 Charcot's neuroarthropathy of the foot and ankle. *J Am Podiatr Med Assoc* (2002). , 92, 210-20.

