

# We are IntechOpen, the world's leading publisher of Open Access books Built by scientists, for scientists

6,900

Open access books available

186,000

International authors and editors

200M

Downloads

Our authors are among the

154

Countries delivered to

TOP 1%

most cited scientists

12.2%

Contributors from top 500 universities



WEB OF SCIENCE™

Selection of our books indexed in the Book Citation Index  
in Web of Science™ Core Collection (BKCI)

Interested in publishing with us?  
Contact [book.department@intechopen.com](mailto:book.department@intechopen.com)

Numbers displayed above are based on latest data collected.  
For more information visit [www.intechopen.com](http://www.intechopen.com)



---

# Arterialized Venous Flaps in Reconstructive and Plastic Surgery

---

Hede Yan, Cunyi Fan, Feng Zhang and Weiyang Gao

Additional information is available at the end of the chapter

<http://dx.doi.org/10.5772/56364>

---

## 1. Introduction

Venous flaps are defined as a composite flap of skin and subcutaneous veins that relies on the venous system alone for flap perfusion, that is, the primary blood supply enters and exits the flap through the venous system. [1] Unlike conventional arterial flaps, venous flaps do not sacrifice an artery of the donor site nor do they require deep dissection. This results in an easier procedure as well as a decrease in morbidity of the donor site. In addition, they are thinner and more pliable because they consist only of skin, venous plexus, and subcutaneous fat. They can also be transferred simultaneously as a composite flap to reconstruct the defects of affected tendons and vessels. [2]- [9] These advantages make venous flaps an ideal indication for the repair of soft tissue defects in hands and fingers, especially when the local flaps and other conventional flaps are not available. [10]

The arterialized venous flaps (AVFs) were first introduced in an experimental study by Nakayama et al in 1981 [1] and in clinical practice in 1987. [11], [12] Since then, during the last decades the AVFs have been mainly utilized in reconstructive surgeries as a result of more unreliable outcomes of early clinical studies using purely venous flaps with venous inflow and outflow. [13] In the early clinical study, Yoshimura et al transplanted 13 flaps with arterial inflow and venous outflow. Twelve flaps survived completely; one had superficial necrosis leading the authors to confirm that arterialized venous flaps were more reliable.

However, many problems have also been encountered using this flap in clinical settings, especially in several relatively large series. [9], [14]- [16] Lorenzi et al [15] noted that postoperative congestion was present in all flaps; partial necrosis rate was as high as 42.5 % with a total flap necrosis rate of 7.5 %; a superficial epidermolysis occurred in 17.5% of flaps causing the development of a full-thickness skin necrosis that required grafting. Inoue et al [14] demonstrated that failure rates as high as 50% occurred in 15 patients when a large arterialized

venous flap from the leg was used. A subsequent series involving 16 arterialized venous flaps showed some improvement of flap survival, but the outcomes were still not satisfactory with only seven complete successes, six partial successes, and three complete failures.

Due to the unpredictable survivals of the arterialized venous flaps, many modifications have been practiced in an attempt to improve its survival status, including flap design, venous orientation, venous anatomy, and using noncontiguous central veins. [17] Undoubtedly, certain improvements on the application of all kinds of AVFs have been achieved; however, many questions are still left unanswered.

## 2. Animal models for experimental investigations of AVFs

Since high occurrence rate of partial flap necrosis and prolonged healing or secondary procedures, further investigation is needed for this non-conventional flap. Several animal models have been developed for experimental studies with the involvement of rats, rabbits, dogs and pigs as well.

The first animal model developed for the study of venous flaps was the rat reported by Nakayama et al in 1981. [1] The flap was designed using the superficial inferior epigastric vein distally and a branch of the lateral thoracic vein proximally served as the venous system. The arterialized venous flap model was established with the anastomosis between the epigastric vein in the flap and the femoral artery in the distal side. Lenoble and associates [18] described another venous flap, which was sited transversely between the left and right epigastric venous systems.

Rabbits are the most common animal model utilized for the study of venous flaps. [18]- [24] The rabbit ear has served as a model for venous flaps. Its reliable anatomic characteristics have provided additional rationale for the selection of this model making this flap a genuine flow-through venous flap. Another model for the venous flap in rabbits was illustrated by Xiu et al. [25] The venous flap was tailored along the axis of the thoracoepigastric veins as a flow-through venous flap. Recently, Tan et al [24] introduced another rabbit model for the evaluation of retrograde flow venous flaps. Although clinical and experimental studies have concentrated mainly on the antegrade arterialization of venous flaps to increase survival, retrograde AVFs may have the greatest potential. This animal model utilized the rabbit's valved, thoracoepigastric vein (consisting of the lateral thoracic and epigastric veins) as the source vessel for the study of retrograde arterialized venous flaps (RAVFs). This designed rabbit thoracoepigastric RAVF is simple to apply and easily reproducible. It is the first animal flap adapted specifically for the study of RAVFs, and may be used for the further investigation of these flaps, which have shown unpredictable survival to date.

There are also several other animal models undertaken as venous flap models, which were not widely utilized in experimental studies, including the dog saphenous or cephalic venous flaps [26] and the swine pedicled buttock venous flap [27].

### 3. Mechanisms of flap survival

Arterialized venous flaps differ from conventional flaps in that the classic Harvesian model of arterial inflow-capillaries-venous outflow is replaced by the arterial inflow- without capillary network-venous outflow. There are considerable controversies on the real nature of their survivals accompanied with their advent. Investigations on the blood supply of venous flaps mostly focus on the purely venous flaps. [26], [28], [29]

Noreldin et al [28] performed an experimental study to investigate how the perivenous areolar tissue affects survival of the rat inferior epigastric venous flap model in 1992. Histological examination of the pedicle showed that many minute vascular channels (single-cell-layered capillaries) were present apart from the inferior epigastric vein. This result confirms the importance of the perivenous areolar tissue in perfusion of the skin island, at least, in the inferior epigastric venous flap in the rat. In another study from Shalaby et al [29], histological study of the pedicles of long and short saphenous and cephalic venous flaps in fresh human cadavers and two clinical cases showed that one or two arterioles and multiple capillaries were present in the perivenous areolar tissue, indicating the perivenous areolar tissue which contains small arteries is vital to the survival of venous flaps in rats.

On the other hand, the results of Xiu et al's showed that the similar perivenous areolar tissue was purely venous and had no fine arteries with the vein in the rabbit, and the role of perivenous areolar tissue is strictly to protect and nourish the vein itself. They otherwise proved that the profuse venous network in flow-through venous flaps and early invasion of new blood vessels are the mainstays of venous flap survival. [25] Another hypothesis of "to-and-fro" flow [26] was also introduced as the single venous channels providing both perfusion and drainage to the flap tissue, and the "to-and-fro" flow in the single vein was also observed. Many authors demonstrated that the early invasion of new blood vessels is essential to venous flap survival and the low perfusion of venous flaps enhances the invasion of new vessels. [25]

Whatever hypotheses of its survival mechanisms were put forward, three main theories have been postulated as to the physiology of the venous flap. These include "A-V shunting" or retrograde flow from the venous system to the arterial system via paralyzed arterial-venous shunts, "reverse flow" or flow from the venules into the capillaries, and "capillary bypass" or flow through the venous system without entrance into the arterial side until neovascularization. [30] There is no conclusive evidence and therefore no consensus regarding the exact mechanism for venous flap survival. However, it is probable that a combined work of the aforementioned factors is responsible for the perfusion of venous flaps and further investigation is required for better understanding of its survival mechanisms.

### 4. Classifications

In literature, several classification systems have been developed and still being updated. It is essential to gain insight into its classifications based on the fully understanding of this flap, facilitating promising clinical outcomes.

The classification of venous flaps utilized in clinical setting was first introduced by Chen and colleagues in 1991. [31] In their original report, venous flaps were classified into four types: Type I, a free venous flap with total venous perfusion where both ends of its vein was anastomosed with two veins; Type II, a pedicled venous flap with total venous perfusion where one end of the vein was intact and the other end of the vein was anastomosed to an adjacent vein; Type III, a free venous flap of arterialized venous perfusion with an afferent A-V fistula where the distal anastomosis was an artery to a vein and the proximal anastomosis was a vein to a vein; Type IV, a venous flap with total arterialized venous perfusion in which both ends of the vein were connected to arteries. Type I and II flaps have a failure rate between 30 and 80% and are limited to small flaps. [17] It is postulated that their poor survival is due to the low O<sub>2</sub> concentration of the afferent blood supply and venous congestion. [30] Type III and type IV are the basic patterns of arterialized venous flaps. The author didn't emphasize the concerns of intravenous valve in their classification system; however, it is supposed that both types of arterialized venous flaps are perfused in an antegrade mode based on their illustrations. Although Arterialized venous flaps show higher survival rates than type I or II venous flaps, they are still prone to venous congestion and partial full-thickness necrosis. [10], [32] (Figure 1)

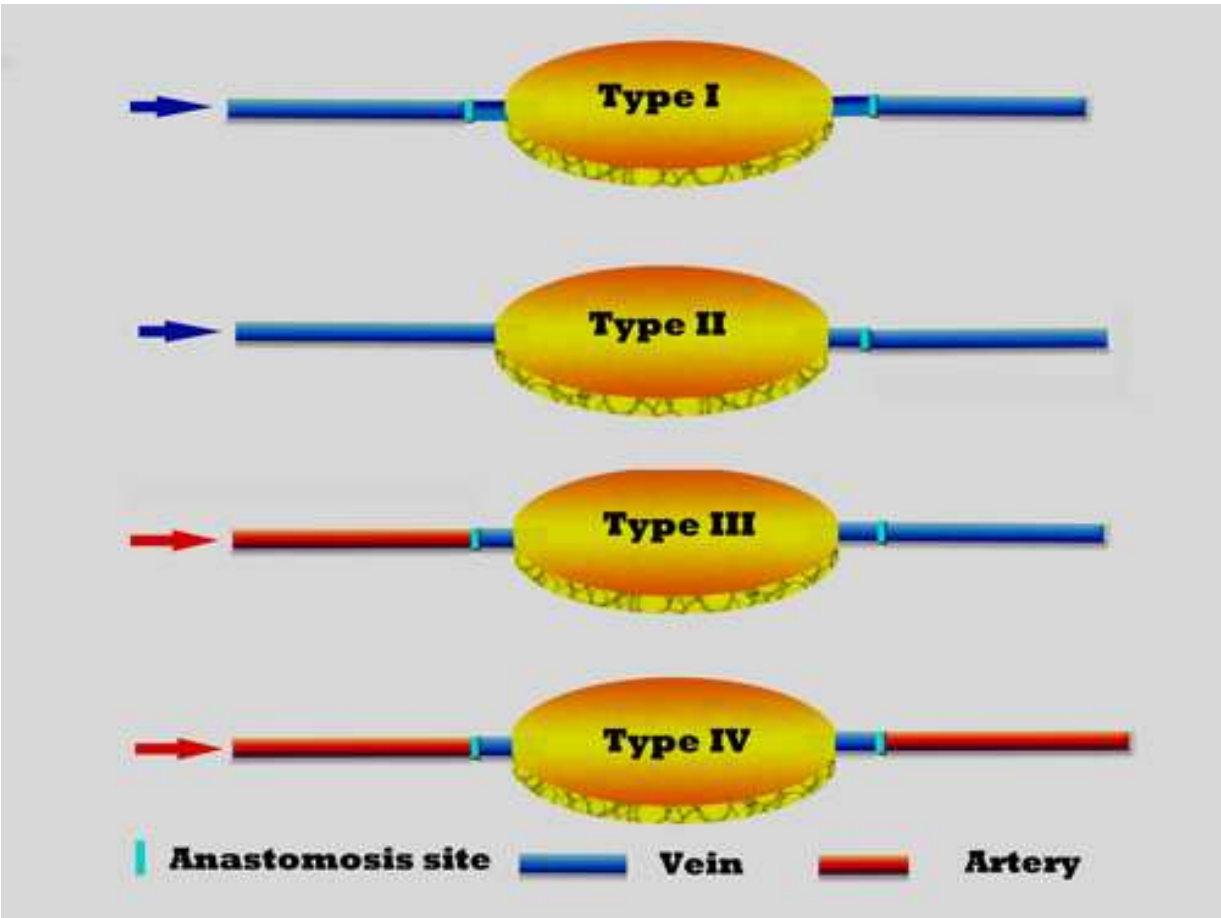


Figure 1.



Thereafter, Thatte et al [33] proposed a three-type classification system of venous flaps. This classification, which was based on the vessels that enter and leave the flap as well as the direction of flow within these vessels, was detailed as follows: type I, unipedicled venous flaps; type II, bipedicled venous flaps; type III, arterio-venous venous flaps. This classification system briefly illustrates the general modes of venous flaps which were cited most commonly both experimentally and clinically. Then In 1994, Fukui et al [34] proposed another four-type classification system of venous flaps, which is very similar to that of Chen et al's. In 2007, Woo et al [35] refined the classification of arterialized venous flaps used in hand and finger reconstruction into three types. Their classification takes into consideration the presence of an intravenous valve, the venous network of the donor site, the location, and the number of veins at the recipient site. Type I is a "through and along-valve" type which mimics similar blood flow as in a standard vein graft with a straight or Y-shaped pattern. Type II is against-valve, which is arterial inflow against the valve through the afferent vein with a reversed Y- or H-shaped venous network. In type III venous flaps, venous flow drains through efferent veins against intravenous valves. (Figure 2)

Recently, Goldschlager et al [17] further modified the flow-through venous flaps, which were also divided into four types: type I and type II are the same to Chen's classification; type III) and IV) are arterialized flaps, similar as described by Chen et al. However, two descriptors were added:  $C_x$ , the number of efferent vessels contiguous with the central vein, where "x" refers to the number of central efferent vessels with zero included; and  $P_x$ , the number of efferent veins discontinuous with the central vein, where "x" refers to the number of peripheral efferent vessels with zero included. The direction of flow is assumed to be along the valve, unless the descriptor "retrograde" is added. In this classification system as shown above, the following concerns were considered: 1) the type of afferent vessel anastomosed to the central vein, 2) the type of efferent vessel anastomosed to the central vein, 3) the number of efferent vessels, 4) the number of efferent veins that are not contiguous with the central vein, that is the number of peripheral veins, 5) whether the central vein is pedicled or not, either at the afferent or at the efferent end, and 6) the direction of the central vein. So far, this classification system provides a simple and descriptive nomenclature for venous flaps. (Figure 3)

## 5. Clinical applications

### 5.1. Resurfacing of skin defects only in hand surgery

Arterialized venous flaps have been mostly used for the closure of small defects, especially on hand and digits. Yoshimura et al. [11] first introduced the arterialized venous flap in 1987. Thirteen arterialized venous flaps measuring in size from 1.3 cm x 3.1 cm to 6.0 cm x 1.0 cm were utilized to resurface the skin defects at fingers in 11 cases. Complete survival was achieved in 12 (92.3%) and 1 sustained partial superficial necrosis. Later, they presented another larger series of these flaps for the coverage of skin defects on the hands in 22 patients, of which an A-V-A type of venous flap was used in 12 patients and an A-V-V type in 10 patients. [36] Seventeen were completely successful, 4 were partially

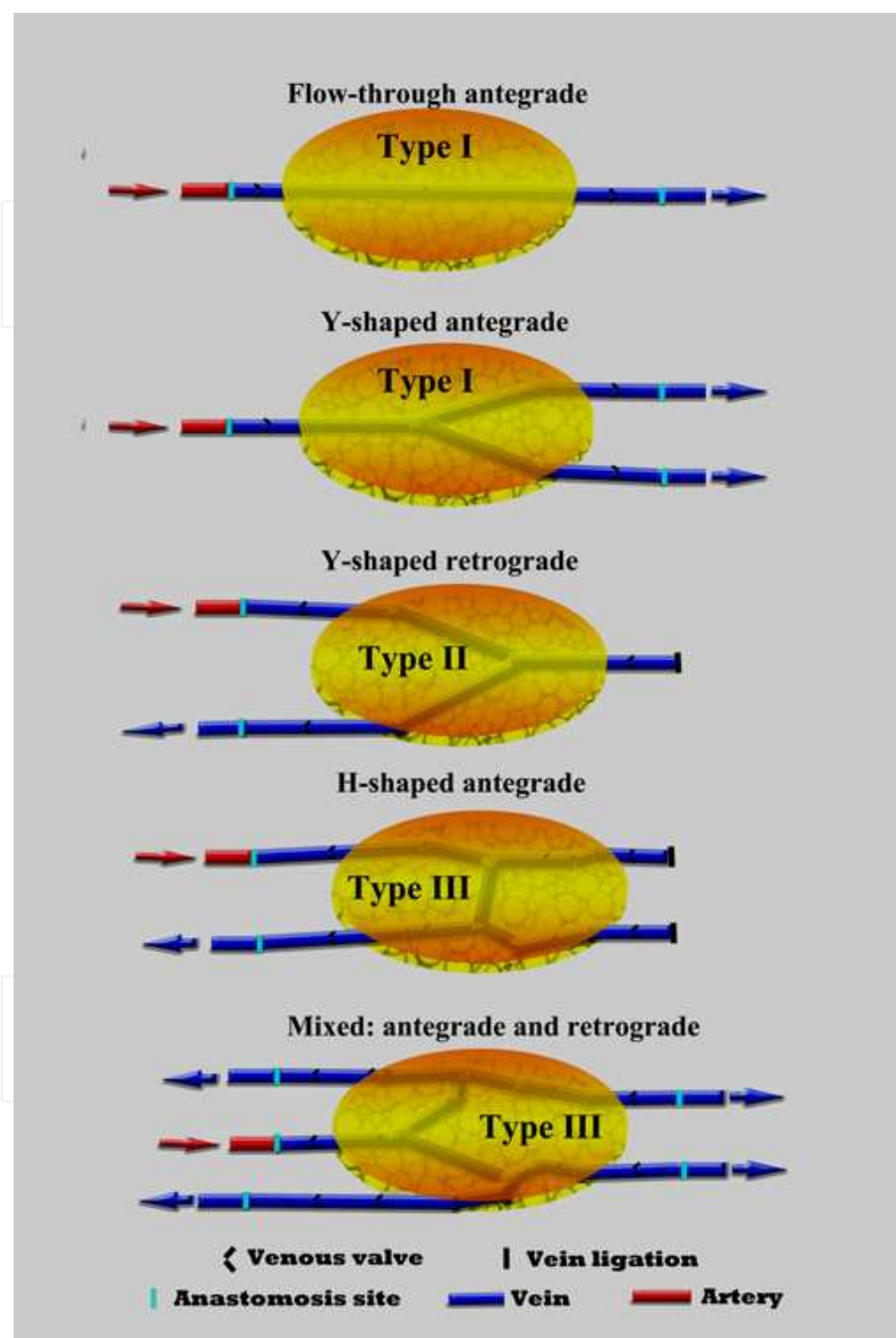


Figure 2.

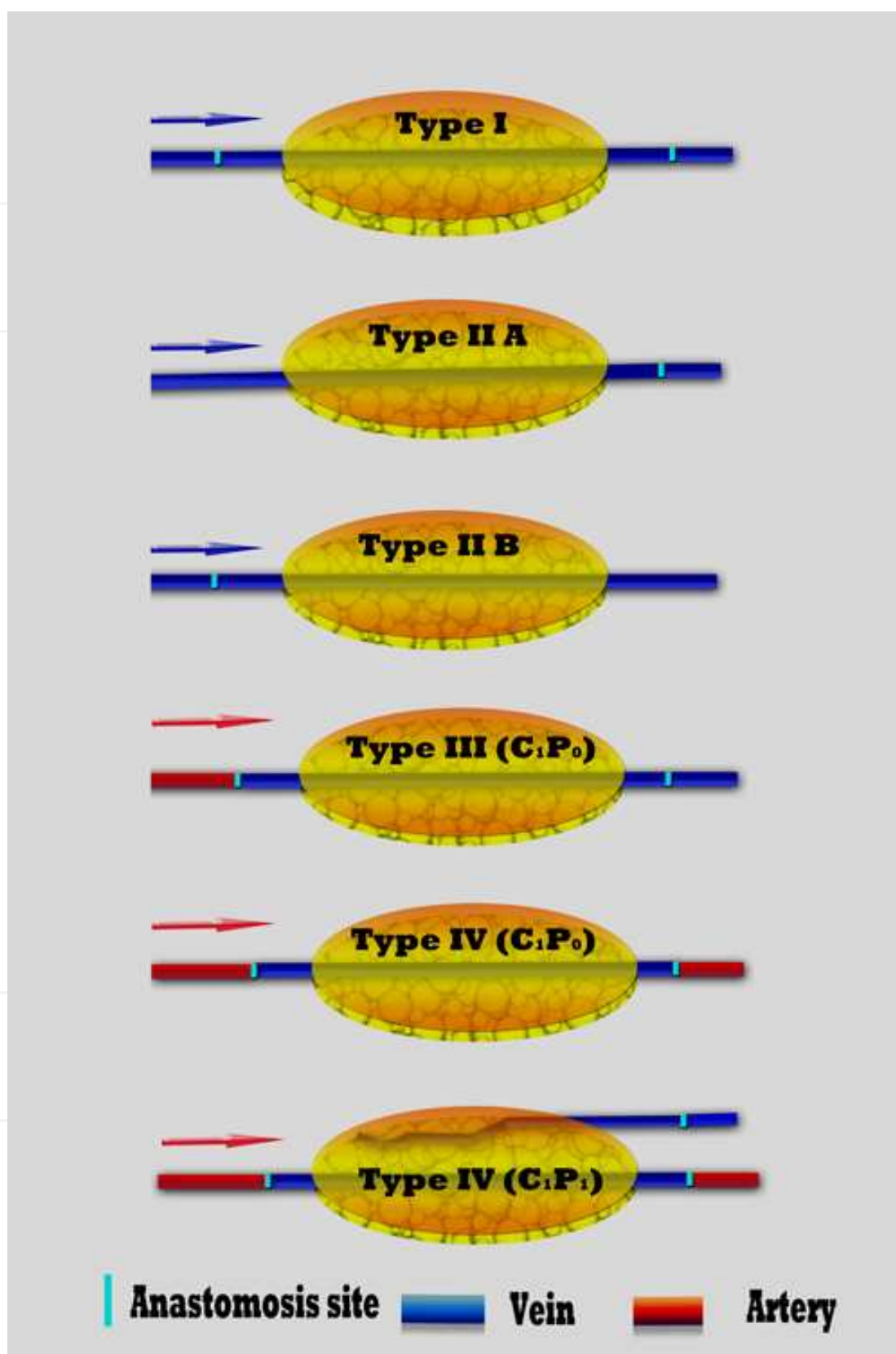


Figure 3.



successful and 1 resulted in complete failure. While Chen et al achieved 100% flap survival using arterialized venous flaps for the coverage of skin defects on hands and digits in 11 cases in 1991. Recently, Brook and colleagues succeeded in resurfacing an upper extremity stump with a 9 x 6-cm venous flap harvested from a nonreplantable part after partial hand amputation. The flap provided durable coverage, and avoided additional procedures for coverage and staged tendon reconstructions. [37]

The Arterialized venous flaps has been considered as potential reconstructive options for large dorsal digital defects with exposed bone, joint and/or extensor tendons, if local flaps are inadequate or unusable. [10] In 1996, Yilmaz et al [38] designed an arterialized venous flap utilizing the venous network of the forearm and applied this flap in 5 patients with various defects in the extremities ranging in size from 6 x 8 cm to 10 x 12 cm. Four flaps totally survived. One flap had 30% partial necrosis. Overall clinical results were successful. Woo et al [39] also presented 12 cases of relatively large skin defects of the hand with AVFs ranging in size from 6 cm x 3 cm to 14 cm x 9 cm. Although the flaps showed remarkable edema and multiple bullae on their surface postoperatively, partial necrosis of the flap only developed in three cases. In 2004, Nakazawa et al [40] presented four cases of successful reconstruction of severe and extensive contractures of the palm using large arterialized venous flaps measuring from 5 cm x 13 cm to 9 cm x 17 cm. All four flaps showed complete survival with uneventful clinical courses and none of them required a defatting procedure after the operation. Recently, Hyza and colleagues [41] also described their experience of 13 venous free flaps in 12 patients with large dorsal digital defects. Their survival rate for these flaps is comparable to the published data. This reconstructive option has become a well-established procedure in their hands and is the alternate reconstructive method of choice for large dorsal digital defects where local flaps are not usable or inadequate due to complex hand injuries or multiple finger defects.

Multiple skin defects of digits due to trauma or burns pose challenging reconstructive problems. Traditional therapeutic options for salvaging these digits were problematic, limiting their clinical applications to the treatment of injury. Inoue G and Suzuki K [42] succeeded in resurfacing multiple skin defects of hand caused by trauma or burns in five patients. Four flaps survived uneventfully (80%), and 1 showed 30 percent partial necrosis. Although this procedure will require additional refinement, it permits a certain range of motion of the involved digits prior to flap division and inset. In 2005, Hyza et al [43] reported a case of a 17-year-old patient who sustained volar and dorsal defects of the middle finger, which were covered simultaneously with bilobed arterialized venous free flap from the forearm. The flap was composed of 2 paddles, which were connected by a subcutaneous bridge containing a subcutaneous venous network. The flap survived completely with only temporary mild venous congestion. Excellent functional and cosmetic result was reached. The bilobed arterialized venous free flap was, therefore, considered as a useful option for coverage of concomitant volar and dorsal digital defects. Trovato et al [44] also treated a patient who sustained multiple finger injuries on the hand with the similar approach. Two dorsal defects of the middle and ring fingers were covered simultaneously with a single arterialized venous free flap from the right forearm. The flap was used to create a dorsally syndactylized digit which survived completely and was subsequently divided longitudinally. The key point for the coverage of

multiple defects in fingers with this flap is to select the proper donor site, in which a sufficient diffuse venous plexus and lax configuration including at least two separate pathways for anastomosing with the recipient vessels should be ensured. [10] Therefore, this application of Arterialized venous flaps is a useful option for the simultaneous coverage of multiple skin defects of digits and excellent functional and cosmetic results can be expected.

## **5.2. Reconstruction of both skin and vascular defects in hand surgery**

Due to the anatomical nature of venous flaps, the best scenario for the clinical use of the arterialized venous flap occurs when both revascularisation and skin coverage are needed. [10] Honda et al [13] first developed the clinical application of the arterialized venous flap as a composite skin and subcutaneous vein graft in the replantation of six amputated digits which were complicated by the loss of skin and veins and with the exposure of bone and tendon in 1984. Satisfactory results were obtained. Then in 1989, Nishi et al [2] reported seven cases of arterialized venous flaps for the treatment of both skin and digital arterial defects. The flaps were applied to cover the skin defect as well as to restore blood circulation. Almost complete survival of the flaps was achieved in all cases. In 1993, Fasika et al [3] also achieved the similar outcomes in their series. In 1999, Koch et al [5] reported the first case of successful coverage of a skin and soft-tissue defect, including revascularization with an arterialized venous flap bridging both arterial and venous defects in a finger avulsion injury. Similarly, several other case reports with this flap for the same purpose all achieved satisfactory results, [4], [45], [46] indicating that this procedure is a well-established technique to not only provide flap coverage for exposed bone and tendon, but also provide an one-stage procedure for digits in need of revascularization and skin coverage.

## **5.3. Reconstruction of both skin and tendon defects in hand surgery**

It is not rare that composite components defects including extensor tendons can occur simultaneously in clinical settings and the treatment will become extremely challenging, especially when multiple fingers are involved. Ideally, surgical management of these defects should fulfill the goal of primary reconstruction in a single surgical procedure with thin and reliable flaps. Conventionally, these injuries are managed with primary soft tissue coverage followed by a later secondary tendon reconstruction. In literature, local or regional flaps are often the preferred choice for soft tissue reconstruction of hand and digits; however, when facing larger dorsal defects, extensive and multiple digits injuries, these flaps are sometimes precluded and free flaps are frequently considered as the optimal options. In 1991, Inoue and Tamura [6] first introduced a novel technique of composite free-flap and tendon transfer using an arterialized venous flap containing the palmaris longus tendon to repair finger injuries involving the skin and both flexor and extensor tendons in four patients. Although the final range of motion was disappointing, with an average of 10 degrees, further trials of this technique conducted in four more patients achieved encouraging results after refining the indications of the procedure. [47] In 1994, Chen et al [7] reported three similar cases of combined skin and tendon loss on the dorsum of the finger that were treated with the same procedure and achieved good results. Their investigations demonstrated that the technique is

feasible and offers a good treatment modality for the small but complex defects on the dorsum of the finger using a one-stage operation. [10]

Then In 1999, Cho et al [8] introduced a similar technique which was applied to reconstruct the defects of skin and multiple extensor tendons on the dorsum of hand using Arterialized venous flaps in a manner of surgical delay in two cases. The patients were reconstructed with a dorsalis pedis tendocutaneous arterialized venous flap. One patient sustained a soft-tissue defect on the dorsum of the right hand, including the absence of the extensor pollicis longus and the extensor digitorum communis of the index finger, and the other sustained a soft-tissue defect on the dorsum of the right hand with the absence of the extensor digitorum communis tendons of the index and middle fingers. Two weeks after the surgical delay on the donor site, an arterialized venous flap, including the extensor digitorum longus tendons of the second and third toes, was transferred to the recipient site. Excellent results were achieved both aesthetically and functionally. Although this technique is a two-stage operation with donor-site scarring and weak extension of the toes, a larger arterialized venous flap can be obtained than when using a pure venous flap or arterialized venous flap; this technique also can increase the survival rate, and multiple tendon grafts can be harvested simultaneously. [10]

Recently, we performed 7 composite palmaris longus venous flaps and 5 arterialized venous flaps with an average size of 6.1cm x 2.9 cm in the reconstruction of post-traumatic extensive dorsal digital injuries in 8 patients. [48] All the flaps survived completely despite of the occurrence of universal venous congestion and swelling. The outcomes at an average follow-up of about 12 months were very satisfactory in terms of functional recovery, aesthetic appearance and sensation restoration. Based on our experience, the Arterialized venous flaps are reliable and good candidates for resurfacing large dorsal digital defects when local flaps are not available or insufficient for coverage. Composite arterialized venous flap with palmaris longus tendon is an optimal choice for one-stage reconstruction of dorsal composite finger injuries.

#### **5.4. Innervated arterialized venous flap**

Sensation is vital to hand function and it is always optimal to resurface a skin defect and reconstruct the sensation simultaneously whenever possible. In 1998, Kayikcioglu et al [49] first reported two cases using innervated Arterialized venous flaps and achieved satisfactory sensory recovery with 4 - 6 mm static two-point discrimination. They concluded that the innervated arterialized venous flap is a useful method that provides functional and cosmetic coverage for digit reconstruction. Then in 2000, Takeuchi et al [50] presented two more innervated arterialized venous flaps for the reconstruction of finger degloving injuries from the dorsum of the foot. Sensation was preserved by anastomosing branches of superficial peroneal nerves with the digital nerves. All the flaps provided successful coverage over the denuded fingers. Good sensation and nearly full range of motion of the fingers were obtained. In our study we also found that all the innervated AVFs for the fingertip reconstruction almost obtained normal sensation at a mean follow-up of 15.4 months, while most cases of the insensate AVFs only achieved protective sensation. Cold intolerance was present in most cases of the insensate group in comparison with the sensate group with only one case suffering from

slight cold intolerance. [51] However, Kushima et al [52] revealed that the sensory recovery was satisfactory even without nerve repair in the application of this flap. Their study hypothesized that the sensory recovery after AVFs transfer on hand and digits was donor-site dependent without nerve repair. In their series, soft tissue loss of fingers were repaired in 22 patients using 25 arterialized venous flaps harvested from the thenar, hypothenar, or forearm regions. Good sensory recovery was obtained for the thenar and hypothenar venous flaps, while moving two-point discrimination was not recorded during the follow-up period in the group using forearm venous flaps. Therefore, the differences among these studies regarding the sensation recovery after reconstruction with AVFs in hand surgery can't be single factor of nerve repairing dependent and most possibly they are as a work of multiple factors, like donor sites, recipient sites, patients' demographic disparities, etc.

### **5.5. Reconstruction of degloving injuries in hand surgery**

Circumferential defects of the digits are uncommon but present a challenging problem to the surgeons. Although many reconstructive options are available for the treatment of this injury, simple skin grafting tends to cause tendon adhesions, limiting the range of motion. The use of local skin flaps, such as a cross-finger flap, is limited by the considerable skin loss that is naturally found in a defect that is circumferential in nature. Other options include the use of a reversed forearm flap or some free tissue transfers resulting in limited donor sites available as well as donor morbidity. [53] Takeuchi et al [50] first described the technique of the reconstruction of digit avulsion injuries with arterialized venous flaps in a wrap-around fashion in 2000. Chia et al reported another case in which the circumferential defect of an index finger, measuring 6 cm around the digit and 3 cm long, is resurfaced by the use of a free arterialized venous flap raised from the volar forearm skin with excellent contour and full range of motion. Recently, Brook et al [54] presented use of the this flap for the reconstruction of severe ring avulsion injury. Eight AVFs were transplanted for 3 Urbaniak class II and 5 Urbaniak class III ring avulsions. Average size of the venous flap was 6 cm<sup>2</sup>. All flaps and digits survived without partial necrosis. The soft tissue envelope was supple in all cases. Total active motion (TAM) ranged from 160 to 210 degrees. Based on all these results, the arterialized venous flap has proven itself to be a reliable solution for the complex circumferential avulsion injury which requires simultaneous soft tissue and digital vessel reconstruction. [10]

### **5.6. Reconstruction of finger pulp**

Fingertip injuries also pose a challenging reconstructive problem. Various skin flaps have been used in the reconstruction of fingertip defects. In repairing pulp tissue loss, local flaps are the first choice from the point of view of sensory recovery and skin texture. In cases where local flaps are not suitable, regional flaps harvested from elsewhere in the hand, such as the cross-finger flap or the thenar flap, are applied. However, these methods require long immobilization, multiple operations, and lengthy hospitalizations. [10] Iwasawa et al [55] introduced a new fingertip reconstruction procedure with arterialized venous flaps from the thenar or hypothenar regions. In their study, 13 of the 15 flaps survived completely. All the flaps that survived exhibited stable coverage and good texture



at follow-up. These flaps are not sensory flaps; however, they exhibited useful sensory recovery within 6 months of the operation. This showed that the thenar and hypothenar skin is durable with appropriate texture for replacement of fingertip defects. However, this donor site is size limited and the conspicuous scarring might be a concern at follow up, especially when primary closure can be achieved. Yokoyama et al [56]- [58] developed the medial plantar area as a donor site for AVFs in the reconstruction of large finger pulp defect. The medial plantar venous flap was designed, the distal subcutaneous vein or communicating vein of the medial plantar area was anastomosed to the proper digital artery, and the proximal vein of the flap was anastomosed to the dorsal subcutaneous vein of the stump of the digit. The flaps survived in all the patients. At 12 months after the surgery, all the treated fingers had attained a good shape and sensory restoration. We also found that the survival of AVFs harvested from the medial plantar area was more “natural” than from the forearm without obvious edema and venous congestion. (Figure 4 a-h vs Figure 5 a-h)

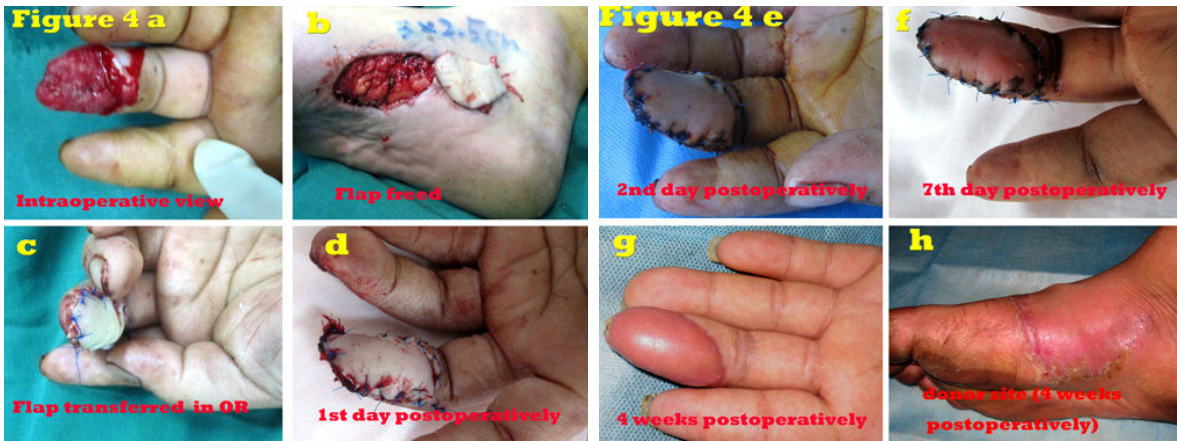

Figure 4.

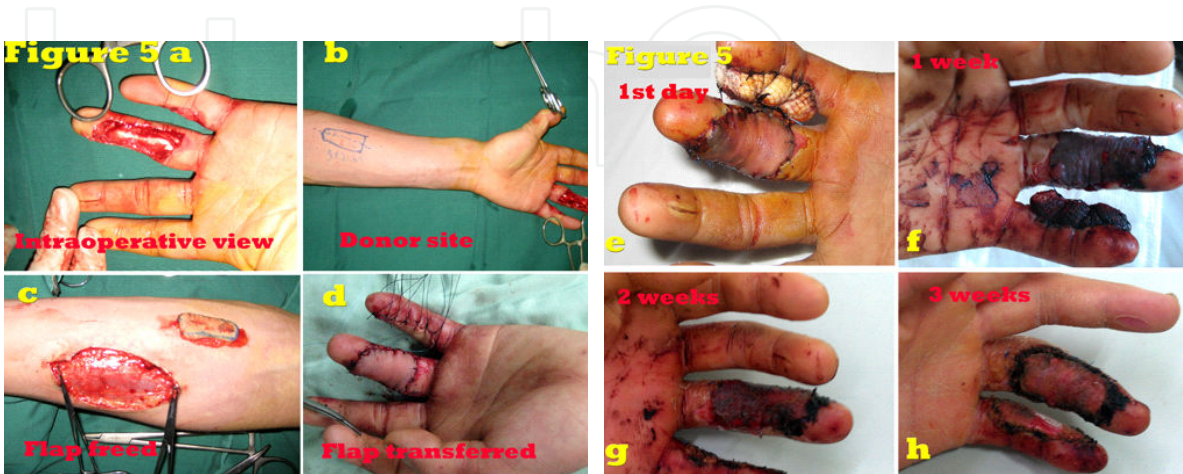

Figure 5.



### **5.7. Reconstruction of fingernails**

The reconstruction of a missing or deficient nail is an important and difficult procedure for plastic surgeons. The vascularized free graft is becoming increasingly reliable, and it is now considered to be the best method. [59] However, preparation of the vascularized nail graft is rather difficult and tedious. To simplify this procedure, Nakayama et al [60] developed a new method to reconstruct the fingernails using the principles from the arterialized venous flaps in 1990. Three patients underwent successful transplantation of the great toenails to their index fingers utilizing the venous system of the nail graft for perfusion by anastomosing the two venous pedicles with the recipient digital artery and dorsal vein. Then in 1999, Patradul et al reported ten arterialized venous toenail flaps for the reconstruction of fingernail loss due to trauma in nine patients. Four flaps were taken from the lateral part of the big toe and six flaps from the second toe. Four toenail flaps with pulp and three flaps with the distal half of distal phalanx were used. Nine flaps survived completely and one had partial necrosis. All showed excellent aesthetic and functional results except for one case with minimal deformity in growth of the nail. They suggested that this procedure is easy, reliable, and a useful alternative for the reconstruction of nail loss.

### **5.8. Resurfacing soft tissue defects other than hand and digits**

Based on the special nature of venous flaps, their applications have not been limited for the reconstruction of soft tissue defects in hand and digits only. In 1998, Kovacs [61] first utilized this kind of flaps for oral reconstruction with varied results. In 2008, Iglesias et al [62] used a forearm arterialized venous free flap (23 cm x 14 cm) in a 25-year-old male with facial burns sequels to reconstruct both cheeks, chin, lips, nose, columella, nasal tip, and nostrils. It was arterialized by the facial artery to an afferent vein anastomosis. The venous flow was drained by four efferent vein to vein anastomoses. Although it developed small inferior marginal necrosis in the lower lip, the rest of the flap survived with good quality of the skin in both texture and color without the need of additional thinning surgical procedures.

After extensive excision of skin cancer on the face, or when skin cancer is located on the 3-dimensional structures of the face, reconstruction with a local flap can be impossible, or clinicians are reluctant to reconstruct defects with a skin graft because of postoperative contraction, hyperpigmentation, or other complication. Instead, an arterialized venous free flap can be used as an alternative method of reconstruction to prevent distortion and recurrence. [63]

Recently, Park and colleagues [63] reported eight patients underwent surgery with an arterialized venous-free flap. All of the soft-tissue defects made by excising the tumor were reconstructed with good outcomes, except for 1 case. Regarding the cosmetic evaluation, the color was fair, the contour and texture were good, absence of distortion of surrounding structures was excellent, and the overall results in most all cases were good. There were no recurrences or metastases during the follow-up period. They considered that the arterialized venous flap is an alternative plan among several reconstruction methods when skin cancer on the face is extensively excised.

## 6. Surgical principles

The arterialized venous flap is an unconventional flap in that the classic Harvesian model of arterial inflow-capillaries-venous outflow is replaced by the venous inflow-capillary network-venous outflow. The physiological basis for its survival is not entirely understood. Due to its atypical pattern as a skin flap, its progress is not easily predictable. Generally, the following concepts are regarded as guidelines for the design of arterialized venous flaps: (1) avoid perfusing the afferent phase by applying the largest possible arterial flow; (2) lax configuration of the efferent phase, using at least two available receptor veins; and (3) flap designing over the diffuse venous plexus while attempting to include not only the pathway of a single vein. Furthermore, the following principles are of great importance for success: firstly, the afferent vein must be left close to the recipient artery in order to avoid pedicle kinking; and secondly, the efferent veins must be longer in order to reach the recipient veins. [64]

Inoue et al [14] observed that the survival status of AVFs appeared to be influenced by the donor site and size of the flap. When a small flap from the forearm was used, the success rate was almost 100 percent. However, there was a 50 percent success rate when a large flap from the leg was used. Recently, Kakinoki et al [65] performed a retrospective analysis of the free arterialized venous flaps that were utilized in 51 patients to identify prognostic factors that correlate with flap necrosis. Multivariate analysis showed that the size of the flap was the factor that correlated statistically with a successful result after a flap operation. They found that the arterialized venous flaps that were less likely to develop necrosis of the skin generally had a surface area less than 767 mm<sup>2</sup>. The influence of donor site on the survival of arterialized venous flaps may be attributed to the configuration of venous network of different donor sites. This postulation has also been revealed in our practice. (Figure 4 a-h vs Figure 5 a-h) Of all the popular donor sites for arterialized venous flaps, it is believed that the configuration of the dorsal skin of digits and hypothenar or thenar is more favorable than that of the volar forearm, while the donor site of lower leg, in which there is a poor venous network, is considered the last choice for venous flaps. On the other hand, the medial plantar area might be the optimal donor site for the reconstruction of the finger pulp defect in terms of functional and cosmetic concerns together with the consideration of donor site morbidities.

## 7. Technical controversies

### 7.1. Type III vs Type IV

Basically two perfusion patterns are related to the AVFs, that is, either Chen's [31] or Goldschlager's [17] type III (A-V-V) and type IV (A-V-A). The investigation of Nishi et al's [16] showed that type IV is likely more favorable than type III. Based on most of the literature that was reviewed, however, no significant difference in flap survival rate was noted despite that the statistical analysis was precluded. [10] The A-V-A type is mostly used for skin coverage and providing a conduit for arterial flow when the vessel is injured. The A-V-V type can be used regardless of the location of the soft tissue defect and therefore has been more widely

used. The A-V-V type has been used in many situations including multiple digits, fingertip, finger shaft injuries, web space, and circumferential soft tissue defects.

## 7.2. Antegrade vs retrograde

A majority of AVFs used in clinical practice were applied in an antegrade perfusion fashion. However, controversies were put forward in an attempt to demonstrate that retrograde perfusion can enhance the perfusion of the flaps. [10] An experimental study with flaps from human cadavers indicated that blood circulation in the periphery of arterialized venous flaps can be increased by retrograde arterialization. [66] Koch et al [67] utilized the retrograde arterialized venous flaps to resurface the skin and soft-tissue defects in 13 flaps. There was venous congestion with superficial epidermolysis in six flaps, but not in the other seven. All flaps survived except for partial skin necrosis in two of the lower-extremity flaps. Their results suggest that retrograde perfusion enhances blood flow in the periphery of arterialized venous flaps and gives good results in terms of flap survival, especially on the upper extremity. They speculated that if blood flows through the flap in the original anatomic direction, and thus the venous valves do not impose any resistance to blood flow. As a result, the greater part of the blood flows through the flap's central vein only and that the flap's periphery will be in danger of insufficient perfusion leading to partial necrosis. While Woo et al [35] recently also published their clinical series utilizing their antegrade approach with a 98% (151/154) success rate and a 5.2% (8/154) partial loss rate. These studies show that either antegrade or retrograde approach can result in success rates comparable to conventional flaps. However, few further investigations were found in literature using the retrograde arterialized venous flaps in clinical setting, so caution should be taken for clinical applications. [10]

## 8. Technical modifications

### 8.1. Delay procedures

Surgical delay procedures have been researched and applied clinically in traditional flap transfers to extend the expected survival length of a flap, to define the survival of a flap of uncertain viability, and to improve the circulation of an established flap of expected viability. [68] Byun et al [22] first reported that a 14-day delay procedure significantly increased the survival of arterialized venous flaps with a 94.0 % of mean viable surface area of the flaps in the delayed group compared to total necrosis in the non-delayed group. Subsequently, Cho et al [20] investigated the efficacy of a surgical delay procedure and a combined surgical and chemical delay procedure on the survival of arterialized venous flaps. The mean percentage survival of arterialized venous flaps was from 36.6 % to 59.7 % in different period delay groups, while in the combined surgical and chemical delay group, the mean percentage survival was on average 90 %. They concluded that the combination of surgical and chemical delay procedures would be more effective than any of the single delay procedures in increasing the survival of arterialized venous flaps, and the delay period could be shortened.

In clinical practice, arterialized venous flaps using delay procedures were first reported by Cho et al [69] in 1997 and achieved satisfactory results. They reported a series of 15 flaps using surgical or surgical-chemical delay procedure with only one flap loss. Their results suggest that except for a disadvantage of two-stage operation, the delayed arterialized venous flap may develop a larger flap than can be obtained with a pure venous flap or arterialized venous flap and increase the survival rate of the arterialized venous flap, which permits the possibility of using a composite flap besides all the advantages of the pure venous flap.

## 8.2. Pre-arterialization techniques

Pre-arterialization is considered as a promising procedure to improve the survival of venous flaps and this concept was first introduced by Nakayama et al [1]. Briefly, pre-arterialization was achieved by performing an arteriovenous fistula of the vein within the flap at the donor site for different periods of time before harvesting the arterialized venous flaps. Since then, pre-arterialization procedure as another promising technique was investigated to improve the survival of larger arterialized venous flaps by many authors. [21], [70], [71] Fukui et al [21] employed this technique by a two-week prearterialization to prevent congestion and necrosis of arterialized venous flaps using the model of rabbit ears with success. However, if a one-week pre-arterialization was performed, only slightly better results than in the standard arterialized venous flaps was achieved. Recently, Wungcharoe et al [72] noted that 7-day pre-arterialized flaps had no statistically significantly larger area of survival than arterialized venous flaps, and only the 14-day pre-arterialized flaps did. The mechanisms why pre-arterialized procedures improve the survival of arterialized venous flaps are still under investigation and its effects are inconsistent. A reasonable pre-arterialization period may play an important role on the improvement of the arterialized venous flaps. [30]

Recently, we performed an experimental study to investigate the improvement of the survival status of AVFs using pre-arterialization combined with delay procedure in rats. [73] We observed that the flaps in the group of pre-arterialization with delay procedure for one week achieved similar results as the conventional perfusion group. Vascular perfusion studies also revealed that the Indian ink filled the entire flaps in comparison with partially-filled flaps in other groups. This method may be a strategy for flap prefabrication based on the venous network.

## 8.3. Technique of noncontiguous and dual venous drainage

The reasons why the survival of AVFs is inconsistent are mainly attributed to the concerns of venous congestion. Rozen et al [74] introduced a modification in the design of saphenous venous flaps, whereby an arterialized flap is provided with a separate source of venous drainage that is not connected to the central vein-especially at the periphery of the flap for true venous drainage. There was a 0% complete flap loss rate (with only one case of superficial partial loss), and ultimately better survival than previous series of saphenous venous flaps described to date. The success of these techniques offers the potential to re-establish flow to large segmental losses to axial arteries, offer safe and definitive flap coverage to traumatic wounds, improve the array of flap options in this

setting, and minimize donor site morbidity. [74] In Goldschlager et al's classification system [17], this technique was specifically emphasized.

Similarly, Lin et al [32] introduced a technique to improve flap survival following the similar concept using shunt-restricting approach. Shunt restriction was achieved in one of the following ways, according to the flap's venous pattern: (1) two parallel veins (II-pattern): use of separate veins for inflow and outflow; (2) two parallel veins with connecting branch (H-pattern): as for II-pattern, with ligation of connecting branch; (3) branching vein (Y/lambda-pattern): ligation of one branch near bifurcation, with use of that branch for outflow and other segment for inflow (or vice versa); and (4) one continuous vein (I-pattern): ligation at midpoint. A consecutive series of 15 flaps were transferred with the antegrade pattern. All flaps survived entirely with good outcomes comparable to conventional arterial flaps. Restriction of arterio-venous shunting enhances peripheral perfusion and decreases congestion of venous flaps, thereby improving reliability and utility in reconstructive surgery.

## 9. Summary

The arterialized venous flaps are easily designed and harvested with good quality. They are thin and pliable, without the need to sacrifice a major artery at the donor site, and no limitation of the donor site. They can be transferred not only as pure skin flaps, but also as composite flaps including tendons and nerves as well as vein grafts. Thus, the arterialized flaps are sometimes good candidates in reconstructive surgery, especially for the reconstruction of relatively small defects of hand and digits and have been useful tools in the plastic surgeons' armamentarium, which provide additional options in certain cases. Nonetheless, there is no consensus regarding their mechanism of survival or even the best approach to their design or transplantation, therefore, they do not completely replace the conventional flaps in plastic surgery and should be utilized in selected cases.

## Author details

Hede Yan<sup>1,2\*</sup>, Cunyi Fan<sup>2</sup>, Feng Zhang<sup>3</sup> and Weiyang Gao<sup>1</sup>

\*Address all correspondence to: [yanhede@hotmail.com](mailto:yanhede@hotmail.com)

1 Department of Orthopedics (Division of Plastic and Hand Surgery), The Second Affiliated Hospital of Wenzhou Medical College, Wenzhou, China

2 Department of Orthopedics, The Sixth Affiliated People's Hospital, Shanghai Jiao Tong University, Shanghai, China

3 Division of Plastic Surgery, University of Mississippi Medical Center, Jackson, Mississippi, USA



## References

- [1] Nakayama, Y, Soeda, S, & Kasai, Y. Flaps nourished by arterial inflow through the venous system: an experimental investigation. *Plast Reconstr Surg.* Mar (1981). , 67(3), 328-334.
- [2] Nishi, G, Shibata, Y, Kumabe, Y, Hattori, S, & Okuda, T. Arterialized venous skin flaps for the injured finger. *J Reconstr Microsurg.* Oct (1989). , 5(4), 357-365.
- [3] Fasika, O. M, & Stilwell, J. H. Arterialized venous flap for covering and revascularizing finger injury. *Injury.* (1993). , 24(1), 67-68.
- [4] Cheng, T. J, Chen, H. C, & Tang, Y. B. Salvage of a devascularized digit with free arterialized venous flap: a case report. *J Trauma.* Feb (1996). , 40(2), 308-310.
- [5] Koch, H, Moshhammer, H, Spendel, S, Pierer, G, & Scharnagl, E. Wrap-around arterialized venous flap for salvage of an avulsed finger. *J Reconstr Microsurg.* Jul (1999). , 15(5), 347-350.
- [6] Inoue, G, & Tamura, Y. One-stage repair of both skin and tendon digital defects using the arterialized venous flap with palmaris longus tendon. *J Reconstr Microsurg.* Oct (1991). , 7(4), 339-343.
- [7] Chen, C. L, Chiu, H. Y, Lee, J. W, & Yang, J. T. Arterialized tendocutaneous venous flap for dorsal finger reconstruction. *Microsurgery.* (1994). , 15(12), 886-890.
- [8] Cho, B. C, Byun, J. S, & Baik, B. S. Dorsalis pedis tendocutaneous delayed arterialized venous flap in hand reconstruction. *Plast Reconstr Surg.* Dec (1999). , 104(7), 2138-2144.
- [9] Kong, B. S, Kim, Y. J, Suh, Y. S, Jawa, A, Nazzal, A, & Lee, S. G. Finger soft tissue reconstruction using arterialized venous free flaps having 2 parallel veins. *J Hand Surg Am.* Dec (2008). , 33(10), 1802-1806.
- [10] Yan, H, Zhang, F, & Akdemir, O. Clinical applications of venous flaps in the reconstruction of hands and fingers. *Arch Orthop Trauma Surg.* Jan (2011). , 131(1), 65-74.
- [11] Yoshimura, M, Shimada, T, Imura, S, Shimamura, K, & Yamauchi, S. The venous skin graft method for repairing skin defects of the fingers. *Plast Reconstr Surg.* Feb (1987). , 79(2), 243-250.
- [12] Tsai, T. M, Matiko, J. D, Breidenbach, W, & Kutz, J. E. Venous flaps in digital revascularization and replantation. *J Reconstr Microsurg.* Jan (1987). , 3(2), 113-119.
- [13] Honda, T, Nomura, S, Yamauchi, S, Shimamura, K, & Yoshimura, M. The possible applications of a composite skin and subcutaneous vein graft in the replantation of amputated digits. *Br J Plast Surg.* Oct (1984). , 37(4), 607-612.

- [14] Inoue, G, & Maeda, N. Arterialized venous flap coverage for skin defects of the hand or foot. *J Reconstr Microsurg*. Jul (1988). , 4(4), 259-266.
- [15] De Lorenzi, F, & Van Der Hulst, R. R. den Dunnen WF, *et al*. Arterialized venous free flaps for soft-tissue reconstruction of digits: a 40-case series. *J Reconstr Microsurg*. Oct (2002). discussion 575-567., 18(7), 569-574.
- [16] Nishi, G. Venous flaps for covering skin defects of the hand. *J Reconstr Microsurg*. Sep (1994). , 10(5), 313-319.
- [17] Goldschlager, R, Rozen, W. M, Ting, J. W, & Leong, J. The nomenclature of venous flow-through flaps: Updated classification and review of the literature. *Microsurgery*. Sep (2012). , 32(6), 497-501.
- [18] Lenoble, E, Foucher, G, Voisin, M. C, Maurel, A, & Goutallier, D. Observations on experimental flow-through venous flaps. *Br J Plast Surg*. Jul (1993). , 46(5), 378-383.
- [19] Yuen, Q. M, & Leung, P. C. Some factors affecting the survival of venous flaps: an experimental study. *Microsurgery*. (1991). , 12(1), 60-64.
- [20] Cho, B. C, Lee, M. S, Lee, J. H, Byun, J. S, & Baik, B. S. The effects of surgical and chemical delay procedures on the survival of arterialized venous flaps in rabbits. *Plast Reconstr Surg*. Sep (1998). , 102(4), 1134-1143.
- [21] Fukui, A, Inada, Y, Murata, K, Ueda, Y, & Tamai, S. A method for prevention of arterialized venous flap necrosis. *J Reconstr Microsurg*. Jan (1998). , 14(1), 67-74.
- [22] Byun, J. S, Constantinescu, M. A, Lee, W. P, & May, J. W. Jr. Effects of delay procedures on vasculature and survival of arterialized venous flaps: an experimental study in rabbits. *Plast Reconstr Surg*. Dec (1995). , 96(7), 1650-1659.
- [23] Takato, T, Zuker, R. M, & Turley, C. B. Viability and versatility of arterialized venous perfusion flaps and prefabricated flaps: an experimental study in rabbits. *J Reconstr Microsurg*. Mar (1992). , 8(2), 111-119.
- [24] Tan, M. P, Lim, A. Y, & Zhu, Q. A novel rabbit model for the evaluation of retrograde flow venous flaps. *Microsurgery*. (2009). , 29(3), 226-231.
- [25] Xiu, Z. F, & Chen, Z. J. The microcirculation and survival of experimental flow-through venous flaps. *Br J Plast Surg*. Jan (1996). , 49(1), 41-45.
- [26] Baek, S. M, Weinberg, H, Song, Y, Park, C. G, & Biller, H. F. Experimental studies in the survival of venous island flaps without arterial inflow. *Plast Reconstr Surg*. Jan (1985). , 75(1), 88-95.
- [27] Germann, G. K, Eriksson, E, Russell, R. C, & Mody, N. Effect of arteriovenous flow reversal on blood flow and metabolism in a skin flap. *Plast Reconstr Surg*. Mar (1987). , 79(3), 375-380.

- [28] Noreldin, A. A, Fukuta, K, & Jackson, I. T. Role of perivenous areolar tissue in the viability of venous flaps: an experimental study on the inferior epigastric venous flap of the rat. *Br J Plast Surg*. Jan (1992). , 45(1), 18-22.
- [29] Shalaby, H. A, & Saad, M. A. The venous island flap: is it purely venous? *Br J Plast Surg*. Jun (1993). , 46(4), 285-287.
- [30] Yan, H, Brooks, D, Ladner, R, Jackson, W. D, Gao, W, & Angel, M. F. Arterialized venous flaps: a review of the literature. *Microsurgery*. (2010). , 30(6), 472-478.
- [31] Chen, H. C, Tang, Y. B, & Noordhoff, M. S. Four types of venous flaps for wound coverage: a clinical appraisal. *J Trauma*. Sep (1991). , 31(9), 1286-1293.
- [32] Lin, Y. T, Henry, S. L, Lin, C. H, Lee, H. Y, Lin, W. N, & Wei, F. C. The shunt-restricted arterialized venous flap for hand/digit reconstruction: enhanced perfusion, decreased congestion, and improved reliability. *J Trauma*. Aug (2010). , 69(2), 399-404.
- [33] Thatte, M. R, & Thatte, R. L. Venous flaps. *Plast Reconstr Surg*. Apr (1993). , 91(4), 747-751.
- [34] Fukui, A, Inada, Y, Maeda, M, Mizumoto, S, Yajima, H, & Tamai, S. Venous flap--its classification and clinical applications. *Microsurgery*. (1994). , 15(8), 571-578.
- [35] Woo, S. H, Kim, K. C, & Lee, G. J. A retrospective analysis of 154 arterialized venous flaps for hand reconstruction: an 11-year experience. *Plast Reconstr Surg*. May (2007). , 119(6), 1823-1838.
- [36] Inoue, G, Maeda, N, & Suzuki, K. Resurfacing of skin defects of the hand using the arterialised venous flap. *Br J Plast Surg*. Mar (1990). , 43(2), 135-139.
- [37] Brooks, D, Buntic, R, & Buncke, H. J. Use of a venous flap from an amputated part for salvage of an upper extremity injury. *Ann Plast Surg*. Feb (2002). , 48(2), 189-192.
- [38] Yilmaz, M, Menderes, A, Karatas, O, Karaca, C, & Barutcu, A. Free arterialised venous forearm flaps for limb reconstruction. *Br J Plast Surg*. Sep (1996). , 49(6), 396-400.
- [39] Woo, S. H, Jeong, J. H, & Seul, J. H. Resurfacing relatively large skin defects of the hand using arterialized venous flaps. *J Hand Surg Br*. Apr (1996). , 21(2), 222-229.
- [40] Nakazawa, H, Nozaki, M, Kikuchi, Y, Honda, T, & Isago, T. Successful correction of severe contracture of the palm using arterialized venous flaps. *J Reconstr Microsurg*. Oct (2004). , 20(7), 527-531.
- [41] Hyza, P, Vesely, J, Novak, P, Stupka, I, Sekac, J, & Choudry, U. Arterialized venous free flaps--a reconstructive alternative for large dorsal digital defects. *Acta Chir Plast*. (2008). , 50(2), 43-50.
- [42] Inoue, G, & Suzuki, K. Arterialized venous flap for treating multiple skin defects of the hand. *Plast Reconstr Surg*. Feb (1993). discussion 303-296., 91(2), 299-302.

- [43] Hyza, P, Vesely, J, Stupka, I, Cigna, E, & Monni, N. The bilobed arterialized venous free flap for simultaneous coverage of 2 separate defects of a digit. *Ann Plast Surg.* Dec (2005). , 55(6), 679-683.
- [44] Trovato, M. J, Brooks, D, Buntic, R. F, & Buncke, G. M. Simultaneous coverage of two separate dorsal digital defects with a syndactylizing venous free flap. *Microsurgery.* (2008). , 28(4), 248-251.
- [45] Nakazawa, H, Kikuchi, Y, Honda, T, Isago, T, Morioka, K, & Itoh, H. Use of an arterialised venous skin flap in the replantation of an amputated thumb. *Scand J Plast Reconstr Surg Hand Surg.* (2004). , 38(3), 187-191.
- [46] Titley, O. G, & Chester, D. L. Park AJ. A-a type, arterialized, venous, flow-through, free flap for simultaneous digital revascularization and soft tissue reconstruction-revisited. *Ann Plast Surg.* Aug (2004). , 53(2), 185-191.
- [47] Inoue, G, Tamura, Y, & Suzuki, K. One-stage repair of skin and tendon digital defects using the arterialized venous flap with palmaris longus tendon: an additional four cases. *J Reconstr Microsurg.* Feb (1996). , 12(2), 93-97.
- [48] Yan, H F. C, Gao, W, Zhang, F, Li, Z, & Wang, C. Reconstruction of large dorsal digital defects with arterialized venous flaps: our experience and comprehensive review of literature. *Annals of Plastic Surgery.* (2012).
- [49] Kayikcioglu, A, Akyurek, M, Safak, T, Ozkan, O, & Kecik, A. Arterialized venous dorsal digital island flap for fingertip reconstruction. *Plast Reconstr Surg.* Dec (1998). discussion 2373., 102(7), 2368-2372.
- [50] Takeuchi, M, Sakurai, H, Sasaki, K, & Nozaki, M. Treatment of finger avulsion injuries with innervated arterialized venous flaps. *Plast Reconstr Surg.* Sep (2000). , 106(4), 881-885.
- [51] Yan, H, Gao, W, Zhang, F, Li, Z, Chen, X, & Fan, C. A comparative study of finger pulp reconstruction using arterialised venous sensate flap and insensate flap from forearm. *J Plast Reconstr Aesthet Surg.* Sep (2012). , 65(9), 1220-1226.
- [52] Kushima, H, Iwasawa, M, & Maruyama, Y. Recovery of sensitivity in the hand after reconstruction with arterialised venous flaps. *Scand J Plast Reconstr Surg Hand Surg.* (2002). , 36(6), 362-367.
- [53] Chia, J, Lim, A, & Peng, Y. P. Use of an arterialized venous flap for resurfacing a circumferential soft tissue defect of a digit. *Microsurgery.* (2001). , 21(8), 374-378.
- [54] Brooks, D, Buntic, R. F, & Taylor, C. Use of the venous flap for salvage of difficult ring avulsion injuries. *Microsurgery.* (2008). , 28(6), 397-402.
- [55] Iwasawa, M, Ohtsuka, Y, Kushima, H, & Kiyono, M. Arterialized venous flaps from the thenar and hypothenar regions for repairing finger pulp tissue losses. *Plast Reconstr Surg.* May (1997). , 99(6), 1765-1770.

- [56] Yokoyama, T, Cardaci, A, Hosaka, Y, Revol, M, Alcontres, d, & Servant, F. S. JM. Location of communicating veins for medial plantar venous flap. *Ann Plast Surg.* Jul (2008). , 61(1), 99-104.
- [57] Yokoyama, T, Hosaka, Y, Servant, J. M, Takagi, S, & Cardaci, A. A simplification for harvesting medial plantar venous flap with communicating veins: usefulness of pre-operative ultrasound imaging. *Ann Plast Surg.* Apr (2008). , 60(4), 379-385.
- [58] Yokoyama, T, Tosa, Y, Hashikawa, M, Kadota, S, & Hosaka, Y. Medial plantar venous flap technique for volar oblique amputation with no defects in the nail matrix and nail bed. *J Plast Reconstr Aesthet Surg.* Nov (2010). , 63(11), 1870-1874.
- [59] (Lille S, Brown RE, Zook EE, Russell RC. Free nonvascularized composite nail grafts: an institutional experience. *Plast Reconstr Surg.* Jun 2000;105(7):2412-2415). 105(7), 2412-2415.
- [60] Nakayama, Y, Iino, T, Uchida, A, Kiyosawa, T, & Soeda, S. Vascularized free nail grafts nourished by arterial inflow from the venous system. *Plast Reconstr Surg.* Feb (1990). discussion 246-237., 85(2), 239-245.
- [61] Kovacs, A. F. Comparison of two types of arterialized venous forearm flaps for oral reconstruction and proposal of a reliable procedure. *J Craniomaxillofac Surg.* Aug (1998). , 26(4), 249-254.
- [62] Iglesias, M, Butron, P, Chavez-munoz, C, Ramos-sanchez, I, & Barajas-olivas, A. Arterialized venous free flap for reconstruction of burned face. *Microsurgery.* (2008). , 28(7), 546-550.
- [63] Park, S. W, Heo, E. P, & Choi, J. H. Reconstruction of defects after excision of facial skin cancer using a venous free flap. *Ann Plast Surg.* Dec (2011). , 67(6), 608-611.
- [64] Inada, Y, Hirai, T, Fukui, A, Omokawa, S, Mii, Y, & Tamai, S. An experimental study of the flow-through venous flap: investigation of the width and area of survival with one flow-through vein preserved. *J Reconstr Microsurg.* Jul (1992). , 8(4), 297-302.
- [65] Kakinoki, R, Ikeguchi, R, Nankaku, M, & Nakamua, T. Factors affecting the success of arterialised venous flaps in the hand. *Injury.* Oct (2008). Suppl , 4, 18-24.
- [66] Moshhammer, H. E, Schwarzl, F. X, & Haas, F. M. Retrograde arterialized venous flap: an experimental study. *Microsurgery.* (2003). , 23(2), 130-134.
- [67] Koch, H, Scharnagl, E, Schwarzl, F. X, Haas, F. M, Hubmer, M, & Moshhammer, H. E. Clinical application of the retrograde arterialized venous flap. *Microsurgery.* (2004). , 24(2), 118-124.
- [68] Morris, S. F, & Taylor, G. I. The time sequence of the delay phenomenon: when is a surgical delay effective? An experimental study. *Plast Reconstr Surg.* Mar (1995). , 95(3), 526-533.



- [69] Cho, B. C, Lee, J. H, Byun, J. S, & Baik, B. S. Clinical applications of the delayed arterialized venous flap. *Ann Plast Surg.* Aug (1997). , 39(2), 145-157.
- [70] Alexander, G. Multistage type III venous flap or 'pre-arterialisation of an arterialised venous flap'. *Br J Plast Surg.* Dec (2001).
- [71] Wungcharoen, B, Santidhananon, Y, & Chongchet, V. Pre-arterialisation of an arterialised venous flap: clinical cases. *Br J Plast Surg.* Mar (2001). , 54(2), 112-116.
- [72] Wungcharoen, B, Pradidarcheep, W, Santidhananon, Y, & Chongchet, V. Pre-arterialisation of the arterialised venous flap: an experimental study in the rat. *Br J Plast Surg.* Oct (2001). , 54(7), 621-630.
- [73] Yan, H, Brooks, D, Jackson, W. D, Angel, M. F, Akdemir, O, & Zhang, F. Improvement of prearterialized venous flap survival with delay procedure in rats. *J Reconstr Microsurg.* Apr (2010). , 26(3), 193-200.
- [74] Rozen, W. M, Ting, J. W, Gilmour, R. F, & Leong, J. The arterialized saphenous venous flow-through flap with dual venous drainage. *Microsurgery.* May (2012). , 32(4), 281-288.

