

We are IntechOpen, the world's leading publisher of Open Access books Built by scientists, for scientists

6,900

Open access books available

186,000

International authors and editors

200M

Downloads

Our authors are among the

154

Countries delivered to

TOP 1%

most cited scientists

12.2%

Contributors from top 500 universities



WEB OF SCIENCE™

Selection of our books indexed in the Book Citation Index
in Web of Science™ Core Collection (BKCI)

Interested in publishing with us?
Contact book.department@intechopen.com

Numbers displayed above are based on latest data collected.
For more information visit www.intechopen.com



Liver Transplantation for Hepatocellular Carcinoma

Emad H. Asham, Howard Mansour and
Mark Ghobrial

Additional information is available at the end of the chapter

<http://dx.doi.org/10.5772/55374>

1. Introduction

The incidence of hepatocellular carcinoma (HCC) has increased exponentially. Liver cancer, primarily HCC, has become the third cause of death from cancer worldwide and the ninth cause of cancer deaths in the U.S.A. According to the center for disease control and prevention statistics, the annual incidence of HCC has increased significantly to an average of 3.0 per 100,000 persons. The annual percentage change in incidence (APC) is 3.5% and the highest APC was found in age group 50-59 years [1]. These statistics should be tampered with caution as only biopsy proven HCC, histology code 8170 and 8175, were counted. This definitely underestimates the scope of the disease.

2. Risk factors

While HCC may arise in healthy livers, the majority of cases develop in a back ground of chronic liver disease i.e. cirrhosis which makes management even more challenging. Viral hepatitis, both B (HBV) and C (HCV), cause 78% of primary liver cancer worldwide [1]. Other risk factors include alcoholic liver disease [2], fatty liver disease (FLD) and non-alcoholic steatohepatitis (NASH) [3, 4], hemochromatosis [5], primary biliary cirrhosis [6] and primary sclerosing cholangitis [7]. Moreover, liver adenoma carries a 10% risk for malignant transformation [8]. Tobacco smoking increases the incidence of HCC [9]. Fungi *Aspergillus flavus* present in poorly stored grains produce Aflatoxin, an environmental hazard for HCC [10]. Hepatic venous occlusive disease has been implicated in HCC development in anecdotal case reports [11].

3. Who is eligible?

Orthotropic Liver transplantation (OLT) offers the *prima facie* cure for both HCC and liver cirrhosis. Historically, while orthotropic liver transplantation (OLT) was at its infancy, courageous attempts by Dr. Thomas Starzl and colleagues to offer OLT as a cure for HCC were complicated by early recurrence [12]. As experience with OLT grew, researchers explored HCC benchmarks that would guarantee comparable survival in tumor and non-tumor patients. These efforts lead Mazzafero et al to Milan criteria. In HCC confined to the liver without macrovascular invasion single tumor $\leq 5\text{cm}$ or up to three tumors each $\leq 3\text{ cm}$ had a five year survival of 75% and a disease free survival of 83% [13]. Milan criteria results for OLT were reproducible and ushered a new dawn for HCC patients. This success led to pushing the size limits even further and University of California San Francisco (UCSF) criteria were introduced. Such criteria include single tumor $\leq 6.5\text{ cm}$ or up to three tumors the maximum diameter of which $\leq 4.5\text{ cm}$ or the total diameter $\leq 8\text{cm}$. The one- and five -year survivals were 90% and 75% respectively [14].

It is intriguing that both criteria gained wide acceptance by the transplant community when they focused on number and size of HCC lesions and ignored biological signature of the tumor at a molecular level. To fuel the argument even more, according to data from Euro Transplant, current imaging modalities when compared with explanted liver pathology were found to underestimate by 10.4% or overestimate by 36.2% tumor size [15].

University of Toronto liver group took matters even further. They developed a protocol biopsy for tumors up to 10cm in diameter and excluded poorly differentiated ones. Ablative therapies were employed intensively to downstage/control the tumor while waiting for liver transplantation. Patient survival was similar for those with HCC within Milan criteria compared to patients beyond such criteria [16].

Mazzafero et al recently reevaluated Milan criteria to find if they are restrictive to patients with more tumor burden who may achieve similar outcomes. A multicenter data base was established. A retrospective analysis came up with the up-to-seven (Up-to-7) criteria; with 7 being the sum of the size and number of tumors for any given hepatocellular carcinoma [17]. OLT listing criteria are summarized in table 1.

Criteria	UNOS	TNM	Definition
UNOS/ TNM	I	T1	1 nodule $\leq 1.9\text{ cm}$
	II	T2	1 nodule, 2 to 5 cm, or 2 to 3 nodules, all $\leq 3\text{ cm}$
	III	T3	1 nodule $> 5\text{ cm}$ or 2 to 3 nodules, 1 $> 3\text{ cm}$
	IV	T4a	≥ 4 nodules, any size; no gross vascular invasion
		T4b	Any T with gross vascular invasion
		N1,M1	Metastases
Milan			1 nodule $\leq 5\text{cm}$ or up to three nodules each $\leq 3\text{cm}$
UCSF			1 nodule $\leq 6.5\text{ cm}$ or up to 3 nodules,
			all $\leq 4.5\text{ cm}$; total diameter $\leq 8\text{ cm}$
Up-to-7			Diameter of the largest nodule (cm) + number of nodules ≤ 7

Table 1. Current criteria employed in liver allocation for HCC patients.

4. Patient evaluation for OLT

Thorough history and physical examination by transplant surgeons and hepatologists are the corner stone in assessment for OLT candidacy. Thereafter, patients undergo stringent testing literally from head to toe.

4.1. Blood tests

An extensive laboratory tests are essential for patients' evaluation. 1. Blood type and antibody screen, panel of reactive antibody (PRA). 2. Full hepatitis profile, to include serum HCV-RNA titers, HCV genotype, HBV-DNA, HBV-E antigen and antibody. 3. Full autoimmune markers to include iron and copper studies, immune protein electrophoresis. 4. Cancer markers, i.e. alpha fetoprotein (AFP), CEA, PSA (prostate specific antigen) for males and CA 19-9. Another diagnostic HCC marker has been recently introduced is descarboxyprothrombin (DCP) also known as Prothrombin Induced by Vitamin K absence II (PIVKA II) [18]. 5. Complete blood count (CBC), complete metabolic panel (CMP) to include magnesium and phosphate. 6. Coagulation studies, i.e., PT/INR, fibrinogen levels and 7. Cytomegalovirus (CMV) status, varicella titers, cryptococcal antibodies

4.2. Endoscopy

Esophago-gastro-duodenoscopy (EGD); to screen for esophageal/gastric varices, to identify the extent of portal hypertensive gastropathy (PHG). This is important for bleeding risk stratification while the patient is on the waiting list. Usually the esophageal varices are ligated with rubber bands endoscopically.

Colonoscopy: All patients with cirrhosis older than age 35, or younger patients with higher risk with history of colitis or family history of early colon cancer, undergo screening colonoscopy with prostatic digital exam being performed in men at the same time. Polyps are identified and endoscopically removed. Patients with precancerous polyps and with history of colitis will require further screening colonoscopies every few years following OLT.

Endoscopic retrograde cholangio-pancreatography (ERCP): may be required in certain cases at the discretion of the transplant surgeons e.g. tumors at the porta hepatis or involving the confluence of the bile ducts.

4.3. Imaging

Ultrasound of liver for HCC surveillance and to determine vessels patency by Doppler studies

Liver protocol 4- phase dynamic contrast computerized tomography (CT) of abdomen and pelvis with oral and intravenous contrast is pivotal for HCC patients. Liver and spleen volumes are computed, and the spinal bone density is detected during the procedure. Number, largest diameter and location as well as macrovascular invasion are well documented to stratify the tumor within transplant candidacy criteria. HCC has a characteristic pattern on 4-phase CT scan. During the arterial phase it appears enhanced by taking up the i.v. contrast and in the

following portal phase and delayed venous phase it appears hypointense the so called “wash out” [19].

In addition, CT of lungs and brain as well as nuclear bone scan are obtained to look for potential metastatic disease. Any extra hepatic disease precludes the patient from candidacy for OLT.

Magnetic resonance scan (MRI): may be required if the CT scan is not conclusive to further delineate the diagnostic patterns of HCC. During gadolinium contrast dynamic MRI, on T1 weighted images the tumor appears hypointense, isointense or hyperintense. On T2 weighted images HCC appears hyperintense on the arterial hepatic phase [20].

4.4. Cardiac assessment

In Cirrhotic patients, cardiomyopathy can compound the situation [21, 22]. All patients get base line echocardiogram. Further testing such as cardiolyte cardiac stress testing and coronary angiogram is at the discretion of the transplant cardiologist.

4.5. Pulmonary assessment

Chest roentgenogram (X R) is the base line test. Pulmonary function tests and ABG are ordered as indicated e.g. ex-smokers, pulmonary hypertension (HTN) and hepatopulmonary syndrome. Pulmonary HTN requires right sided heart catheterization and pressure measurement. Hepatopulmonary syndrome is evaluated by bubble echocardiogram.

Sinus XR, panorex XR of teeth may be required according to history and physical examination. Any sinus infection or dental caries has to be treated prior to transplantation.

4.6. Vaccinations

Prior to OLT, candidates should receive the following vaccines guided by their history of previous vaccination 1. Hep A and B vaccination, if there is no evidence of prior immunity indicated by antibody titers. 2. Pneumovax (pneumonia vaccine needs to be repeated every five years). 3. Flu vaccination once a year. 4. PPD skin test for TB screening is also applied.

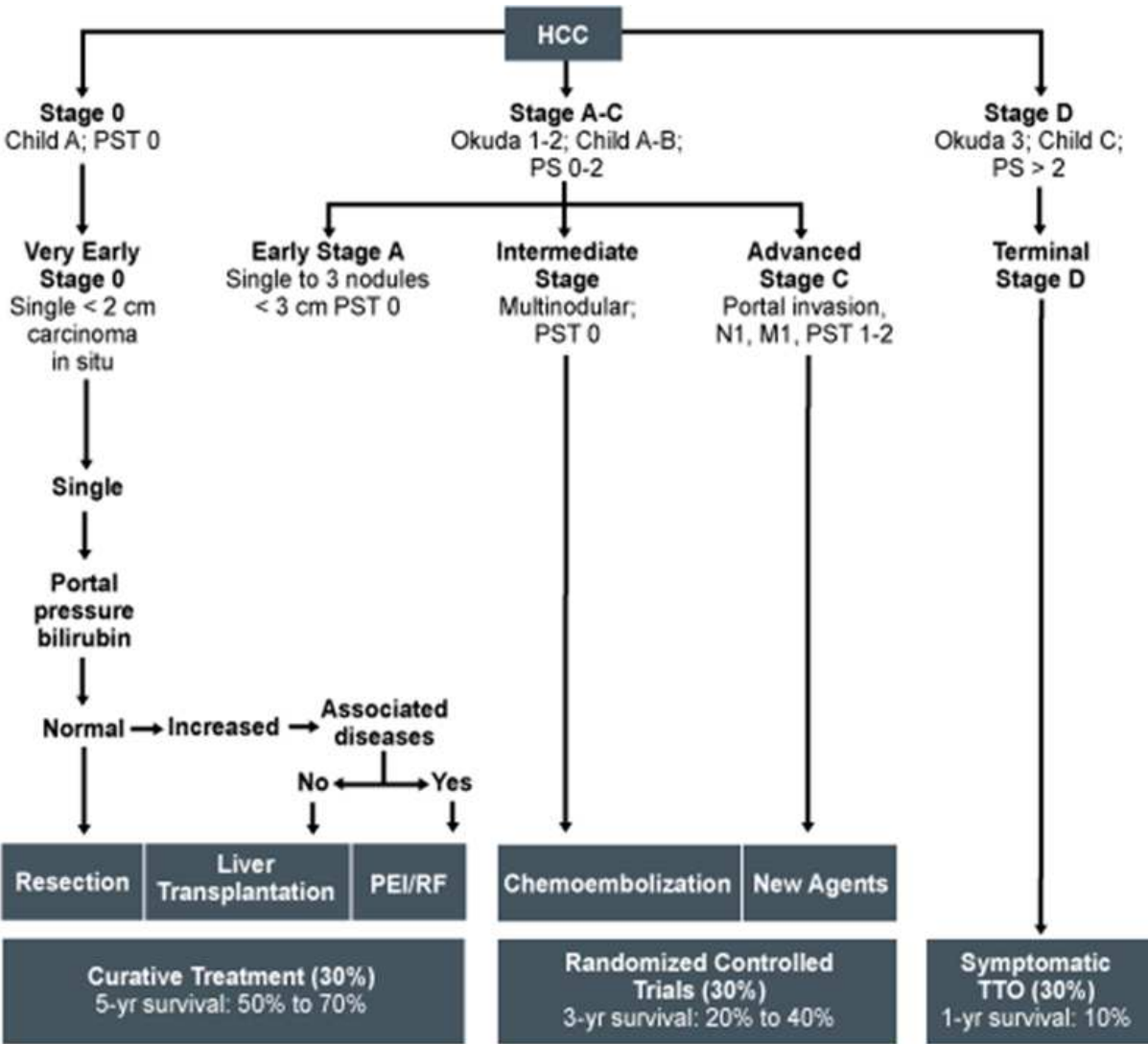
Also, Mammogram / Pap smear for women as appropriate for age are part of the pre transplant evaluation tests.

4.7. Biopsy

The role of liver biopsy is contentious. The most dreaded complications are hemorrhage and tumor seeding rate of 2%-3%. HCC recurrence rates were found to be higher in patients who underwent liver transplant and had tumors >3cm, alpha feto protein >200ng/l and underwent biopsy [23]. Liver biopsy is not routinely required for patients' evaluation as long as the imaging characteristics are diagnostic [24]. Correlation with serum alpha feto protein levels can shed more light. In rare cases; lesion image guided biopsy is required for definitive diagnosis. Liver biopsy can be done via trans jugular approach in coagulopathic patients. Hepatic venous pressure gradient (HVPG) can be measured at the same time HVPG objectively

assess the degree of portal hypertension [25]. As future research unfolds molecular signatures and proteomics profiling of HCC; the role of pre transplant biopsy in liver transplant candidacy for HCC patients will gain grounds. On a molecular level, proliferating indices, tumor promoter genes, tissue invasion and metastases markers, angiogenic markers, growth factors and genetic biomarkers and micro RNA have been implicated in diagnosis and prognostication of HCC patients [26].

Barcelona clinic scheme for management of HCC offers a practical staging and treatment strategy for HCC patients (Figure 1)



PEI, percutaneous ethanol injection; PS performance status; PST, performance status test; RF, radiofrequency; TTO, time trade off.

Figure 1. Bracelona Clinic Scheme from Llovet et al [27]

5. Diagnostic dilemmas

Often times, diagnosis of HCC is not that straight forward. Currently used markers such as serum alpha feto protein and PIVKA II as well as imaging study can be equivocal. The lesion may be too small to characterize with current imaging modalities. Also, hyperplastic or macroregenerative nodules in cirrhotic livers can be difficult to distinguish from HCC. The guide lines of the American Association for the Study of the liver disease (AASLD) recommends repeat ultrasound for lesions < 1cm at three month [28].

Positron emission tomography (PET) scan using F-18 fluoro-2-deoxy-D-glucose (FDG) has a limited role in HCC diagnosis because of low sensitivity of 50%-55% [29].

Mixed tumors HCC/intrahepatic cholangiocarcinoma may have unconventional enhancement patterns on CT and MRI scans. Usually, they are diagnosed on the explanted liver histopathology and carry worse survival than HCC [30, 31].

Even more, some small HCC are hypovascular and only diagnosed by biopsy or at the explant pathological examination [32]

6. Care of HCC patients while on the waiting list:

6.1. Surveillance

Patients on the transplant waiting list with risk factors for HCC should be screened for HCC. Once screening is positive they should join a surveillance protocol. For those who have HCC enhanced follow up is required to monitor tumor development and treat as appropriate. Liver ultrasound (US) and serum alpha feto protein at six months interval is the gold standard according to AASLD are the main stay for surveillance. US reported sensitivity is between 65%- 80% and specificity is greater than 90% [33]. Nodular cirrhotic livers, small tumors and obese patients impose a challenge for US. In such cases contrast enhanced dynamic CT or MRI is invaluable for lesion characterization.

6.2. The concept of down staging and bridging therapy

Only 5% of HCC patients evaluated for OLT are amenable for transplant [34]. This led to adoption of techniques to control tumor size. The rapidly evolving loco-regional therapies have served well HCC patients by; (i) down staging the tumor to acceptable, within criteria, size and number, (ii) disease control, while the patient is awaiting deceased donor OLT, so called "bridging therapy" i.e. bridge to transplantation and (iii) and improving post OLT survival with particular reference to tumor recurrence [35, 36]. Treatment has to be "tailored" for each patient according to their Child-Pugh score, tumor burden and location and available expertise and resources. T2 patients who are predicted to wait more than six months on the list benefit from tumor therapy [35]. Loco regional therapies include percutaneous alcohol injection (PEI), thermal ablation such as radio frequency ablation (RFA) and microwave,

chemotherapy delivered directly to the tumor tissue i.e. transarterial chemoembolization (TACE), radiotherapy delivered in various ways such as transarterial Yttrium- 90, three dimensional conformal radiotherapy and proton beam radiotherapy. In a prospective study including forty eight patients, Graziadei et al reported tumor control and survival using TACE for HCC patients while on the waiting list for OLT. The intention to treat 5- year survival was 93% and patients 5 year survival was 93%. Tumor recurred in one patient only, 2.4% rate [37]. Different modalities of radiotherapy are usually reserved for advanced HCC beyond transplant candidacy.

RFA as a bridge to transplantation was studied in a series of 52 patients with 87 HCC nodules. Mean tumor diameter was 2.5 cm (range 0.4-5.07). Radiographic local tumor control was achieved in 74 out of 87 tumors. In the 41 patients who received OLT; complete tumor necrosis was found on explant pathology in 46 out of 70 lesions (65.7%) [38].

Combining two modalities can have a synergistic effect, ameliorate complications of each and reduce the number of sessions to achieve tumor necrosis in patients with well compensated liver functions.

Combination of RFA and PEI has increased the efficacy of RFA to produce coagulative necrosis of HCC [39]. Another study employed TACE and laparoscopic RFA each as a single modality or in combination for down staging a series of sixty one patients who had tumors exceeding T2 stage i.e. a single lesion 2–5 cm or up to three lesions <3 cm. Tumor down staging was achieved in 70.5% of patients and thirty five patients (57.4%) became candidates for OLT. The explanted liver histology showed complete tumor necrosis in thirteen patients and down staging to T2 in seventeen patients [40].

Irreversible Electroporation (IRE or Nano knife): This is an emerging technology that is still undergoing clinical trials yet promising. Short pulses of high voltage current through electrodes inserted into the target tissue produces Nano size pores in the cell membrane that leads to cell death. It has been validated in animal models [41] and limited number of patients with variable inoperable tumors [42]. No intense heat is produced which makes it applicable for tumors near major vessels, bile ducts and porta hepatis.

Molecular targeted therapies have emerged as an effective treatment for a variety of tumors. Sorafineb is an oral multikinase inhibitor that blocks tumor cell proliferation by targeting raf/ MEK/ERK signaling. It also has antiangiogenic properties by targeting the vascular endothelial growth factor receptor-2/-3 and platelet derived growth factor beta tyrosine kinases [43]. Using the Markov model for decision making analysis [44], assuming that therapy starts on the day of listing Sorafineb was found to be cost effective as compared to no therapy [45]. This theoretical model does not take into account side effects of sorafineb particularly its antian- giogenic effect in proximity to major surgery as liver transplant. Clinical trials are awaited to examine if sorafineb improves outcomes and reduce post-transplant recurrence.

6.3. Liver resection as bridge to transplantation

In view of organ shortage and unpredictable waiting list time for deceased organs donors, liver resection may be a rational option for patients with favorable lesions and well compensated

livers. However, only a small percentage, 10%-15%, of HCC is resectable at time of presentation due to advanced cirrhosis, extensive burden of the neoplasm or patients cardiopulmonary status [46]. This rate of resectability is higher in Asian centers. One explanation is the higher prevalence of HBV than HCV in Asia. In the natural history and hepatocarcinogenesis of HBV, HCC can develop in earlier stages of the disease than HCV. In a review of 271 patients who are candidate for OLT, 98 of whom treated by liver resection multivariate analysis showed that liver resection as a first line of treatment was a negative independent factor for disease free survival as compared to primary OLT. Only 20% of the 98 patients who were suitable for transplant but treated by resection received OLT later 17% for tumor recurrence and 3% for liver decompensation [47].

In another series of 107 patients who underwent OLT for HCC; 88 patients were within Milan criteria. Of those 88 patients, 70 underwent primary OLT and 18 patients had liver resection first before “salvage” transplantation. The mean time between liver resection and listing was 20 months (range 1-84). Indication for salvage transplant was tumor recurrence in 11 patients, liver decompensation in 4 patients and high risk for recurrence in 3 patients. Three- year survival (82 versus 82%) and five year survival (59% versus 61 %) were comparable in the two groups [48].

It seems that the role of liver resection is limited to a highly selected group of HCC patients with single small well differentiated lesion, no vascular invasion and well compensated cirrhosis without portal hypertension. Therapeutic options has to be individualized taking into consideration tumor biology, organ availability, patient preference, center practice and regional rules for organ allocation.

7. Organ allocation

Shortage of deceased organ donors led to the development of organ allocation schemes to ensure that such scarce resource is allocated to those patients who need it the most regarding justice in distribution of organs amongst different patients groups. Model for end stage liver disease (MELD) score is adopted by United Network for Organ sharing to prioritize patients on the waiting list. MELD was originally developed to predict mortality for patients with portal hypertension undergoing transjugular intrahepatic porto-systemic shunts (TIPS). MELD mathematical equation is $0.957 \times \log(\text{serum creatinine, mg/dl}) + 0.378 \times \log(\text{serum bilirubin, mg/dl}) + 1.120 \log(\text{INR}) + 0.643$ [49]. Patients who have T2 (2-5 cm) HCC tumors within Milan criteria gain 22 exceptional MELD points. If the patient with stable disease is still waiting for OLT for three month the exceptional points are increased to 25 [50]. These exceptional points led to an exponential increase in the number of registered HCC patients for OLT [51].

8. Living liver donors

One of the major challenges facing the liver transplant community is donor organ shortage especially in Asia where deceased organ donation is limited. High mortality while on the

transplant waiting list compounds the challenge. Living donor liver transplant (LDLT) programs have emerged as one of the solutions to bridge the gap between the overwhelming demand and the limited supply. Live donation offers many advantages to the recipients; it eliminates waiting time on the list, offers the convenience of scheduling the operation at an opportune time and optimal short cold ischemia time. Nevertheless, it subjects healthy donors to a major operation with possible 1% mortality and significant morbidity [52]. Healthy volunteers for donation undergo scrutinizing tests to validate their candidacy for liver donation including psychological evaluations. In a large number of living donor volunteers who step forward for evaluation; liver anatomical morphology and/or anomalies prohibit donation [53]. Pediatric patients usually receive left lateral segment (segments II and III) while adult recipients may receive right or left lobe depending on the liver volume, size and recipients' weight and height.

Advances in imaging technology allow calculating the liver volume of each lobe and also each segment as desired [54]. Actual knowledge of liver parenchymal, vascular and biliary anatomy is crucial to minimize operative and post-operative complications [55]. Computer assisted and image guided surgery have contributed to the safety and precision of the donor operation. Two dimensional CT scans are converted to three dimensional (3D) images that delineate the vascular and biliary anatomy. Pre-operative planning and virtual resection have contributed significantly to liver resection safety. Also 3D pre-operative images guide venous reconstruction and help surgeons avoid venous congestion [56].

In a series of 236 patients who received LDLT for HCC and 172 patients outside Milan criteria; the recurrence rate was 12.7%. One and three year recurrence free survival was 72.7% and 64.7% respectively. Independent risk factors for tumor recurrence were serum alpha feto protein level, tumor size, bilobar distribution, tumor differentiation and vascular invasion. [57]. Vakili et al found that in HCC tumor recurrence is higher in LDLT recipients than in deceased donor recipients; 28.6 % versus 12.1% respectively. Paradoxically one- and five -year patient and graft survival in LDLT were 94% and 81% [58]. This higher HCC recurrence rate in LDLT may be explained by the time lag bias. Longer waiting time for deceased donors liver recipients discloses tumors with aggressive biology and patients drop out from the list. Another explanation may be the milieu of tumor regeneration with outpouring of growth factors that enhances tumor recurrence. Whether LDLT enhances recurrence remains controversial. In a well matched cohort of LDLT and DDLT recipients for HCC; the survival and recurrence rate were similar in the two groups. Microvascular invasion was the only predictor of tumor recurrence using regression analysis [59]. In a series of 221 LDLT for HCC; one of the significant factors for tumor recurrence is tumor size and number. Three-year HCC recurrence rates were 13.6% within Milan criteria, 20% within UCSF criteria and 51.6% beyond UCSF criteria [60].

9. Split livers

Another solution that was improvised to expand the donor pool in face organ shortage is split livers. The deceased donor liver is split to transplant two patients. Usually, the split incurs left

lateral segment (segment II and III) for a pediatric recipient and the extended right (segments IV-VIII) for an adult recipient. Survival of split liver transplant is comparable to those of whole graft [61, 62]. *In vivo*, also *in situ*, splitting offers better outcomes than *ex vivo* splitting in terms of post-operative complications and graft dysfunction [63]. In a series of six patients with HCC who received split liver grafts with a median follow up of 20 months no recurrence was observed [64].

In both approaches of reduced grafts, LDLT and split liver transplant, size matching is an important consideration in LDLT. A ratio of graft volume to standard liver volume of > 30% is crucial for adequate post-transplant hepatic function [65].

Small for size syndrome has been described in LDLT recipients when the graft liver volume is too small for the recipient [66]. Graft failure was attributed to high portal blood flow. It was described mainly in left lobe recipients. One of the protective strategies is of portal blood modulation. This is achieved by partial diversion of the portal blood flow to the inferior vena cava (IVC) by anastomosing the right portal branch to the right hepatic vein [67].

Also, large for size syndrome is a result of size mismatch when the abdominal cavity of the recipient cannot accommodate comfortably the graft [68]. Graft compression exaggerates the ischemia reperfusion injury. Using synthetic grafts such as gortex mesh or alloderm to close the abdominal wall without tension increase the chances of postoperative infections.

10. Immunosuppression

Immunosuppression remains the drawback of transplantation. Immunosuppression entails substantial cost, compliance, vulnerability to a wide scope of infections and side effects and *de novo* malignancies.

Steroids, calcinurin inhibitors (CNIs) including cyclosporine and tacrolimus, mycophenolate mofetil and mammalian target of rapamycin (mTOR) inhibitor (rapamycin) remain the main agents for maintenance therapy. Each of those agents has a myriad of side effects. Usually two to three agents are used in combination in a trial to reduce the dose of each and subsequently minimize side effects. Major side effects of CNIs are renal toxicity, hypertension, diabetes mellitus and neurotoxicity. Serum levels have to be monitored frequently and dose adjusted accordingly. Major side effects of sirolimus are impaired wound healing, hypercholesterolemia, anemia, thrombocytopenia and mouth ulcers.

Steroids have a wide range of side effects including increased susceptibility to infections, diabetes mellitus, hypertension, impaired wound healing and cataracts to name a few. Early withdrawal of steroids is thought to be beneficial especially in HCV patients to control recurrence of viral hepatitis. One study found that early steroid withdrawal had no influence on HCV recurrence but reduced the incidence of post OLT diabetes mellitus [69].

In quest for the holy grail of transplantation, immune tolerance, induction immunosuppressive therapies have evolved to include various biological agents that are either monoclonal

(muromonab-CD3, daclizumab, basiliximab, alemtuzumab) or polyclonal antithymocyte globulin [equine] or antithymocyte globulin [rabbit] antibodies. These agents can be further classified to depleting agents and non-depleting agents according to their ability to deplete lymphocyte. Depleting agents include antithymocyte globulin and anti CD52, alemtuzumab (Campath). Antilymphocyte globulin causes T lymphocyte lysis through a complement – dependent manner while alemtuzumab causes lymphocyte lysis by binding to CD 52, a receptor present on virtually all B and T lymphocytes. Non depleting agents include basiliximab (simulect) and Daclizumab (zenapax). Both agents are receptor antagonists that have high affinity to alpha subunits of IL-2 receptor, also known as CD- 25. IL-2 antagonism prevents T lymphocyte activation and proliferation.

The rational of induction immunotherapy is immunomodulation to curb allograft rejection, reduce the steroid and CNIs doses and subsequently minimize the side effects. The initial results are encouraging. In a randomized controlled study using rabbit antithymocyte globulin (RATG) for induction therapy; steroids were avoided, rejection episodes were less and HCV recurrence was decreased [70]. Using interleukin-2 receptor antibody (basiliximab) for induction allowed early withdrawal of the steroids and reduction of the tacrolimus dose. This was associated with fewer incidences of post OLT diabetes and acute cellular rejection [71].

New immunosuppression agents or immunomodulation agents for a better term, are being developed and tested in clinical trials involving mainly kidney transplant. Voclosporin (ISA247) is a novel CNI that proved to have similar effectiveness to Tacrolimus with potential reduction in new onset diabetes mellitus [72]. Belatacept is a chimeric fusion protein that blocks costimulation of T-lymphocytes was comparable to cyclosporine plus an improved renal function and fewer metabolic complications but increased risk of post-transplant lymphoproliferative disease [73]. Everolimus is an mTOR inhibitor, a rapamycin analogue. In a randomized controlled study involving liver transplant recipients, everolimus was found to impart same efficacy and better renal function when used with low dose tacrolimus compared to standard dose tacrolimus [74].

11. Tumor recurrence

Tumor recurrence remains a potential threat to HCC patients who receive liver transplants. HCC recurrence can be as high as 40% following OLT [75]. Researchers at University of Western Ontario, Canada looked at variables that significantly influence HCC recurrence post OLT. In a total of 75 cases 20 cases had recurrence within a follow up mean of 8 years. Tumor criteria were assessed based on the explant pathology. Those patients within UCSF criteria had a recurrence rate of 67% versus 12% of those within Milan criteria ($p < 0.001$). Also, 5-year survival was lower in UCSF group compared to Milan group 15% versus 83% respectively ($p < 0.001$) [76].

Immunosuppression regimen may have an influence on tumor recurrence. Decaens and colleagues found out that induction therapy with lymphocyte antibody (ATG) or anti CD3 antibody is a risk factor for HCC recurrence after OLT [77].

The antiproliferative property of rapamycin (sirolimus) makes it an attractive option for HCC patients in an attempt to reduce tumor recurrence and reduce the long term side effects of CNIs. In an animal model using human HCC tumor (LCI-D20) cell line; rapamycin alone or in combination with sorafineb was found to inhibit primary tumor growth and lung metastasis [78]. In one matched -cohort of HCC patients who underwent OLT; one group received sirolimus and the other group received tacrolimus based immunosuppression. Three-year recurrence free survival in the sirolimus group was 86% compared to 56% in the tacrolimus based group ($p < 0.04$) [79]. This issue remains controversial specially that HCC patients fall under different criteria; Milan, UCSF and beyond UCSF and immunosuppression protocols can vary great deal. Most publications in favor of the hypothesis that using sirolimus for post OLT immunosuppression reduces tumor recurrence are retrospective and level 3-4 evidence according to center for evidence based medicine, Oxford, U.K. [80]. This highlights the need for prospective, well designed, multicenter studies to solve this debate.

In a multivariate analysis involving 109 patients who underwent OLT, Lai et al found that exceeding UCSF criteria ($p = 0.003$) and microvascular invasion ($p = 0.007$) were independent risk factors for recurrence [81].

Up- to -7 criteria was tested in a recent study involving 479 HCC patients who received OLT at two different centers. In 335 patients who met up -to -7 criteria; the calculated recurrence probability at 1-, 3- and 5- year was 4%, 8% and 14%. Multivariate analysis showed that only macrovascular invasion and tumor grade were significant predictors of survival [82].

Many liver transplant centers confirm that tumor biology plays an important role post OLT survival and recurrence. Crude markers such as degree of differentiation (G1-G4) and microvascular invasion are increasingly found to be predictors of recurrence [83]. Also, tumor numbers, diameter of the largest lesion and donor age were significant predictors of recurrence [84]. Another study included 48 patients found that pre transplant AFP slope greater than 50 $\mu\text{g/L}$ per month is associated with higher rate of one year recurrence [85].

The fact that tumor recurs in a subgroup of transplant patients after removal of the only source i.e. HCC bearing liver coupled with the growing evidence of the role of vascular invasion, both micro and macro, as a risk factor for recurrence supports the hypothesis of circulating tumor cells (CTC) role in recurrence [86].

12. Conclusion and future look

In conclusion, the major strides in liver transplantations made it a valuable therapeutic option for a subset of carefully selected HCC patients. Studies continue to identify tumor criteria that yield post-transplant outcomes comparable to those of non-tumor transplant patients. Tumor signature at a molecular level is a promising field to further characterize HCC in the context of liver transplantation. Pre transplant loco-regional therapies, especially for T2 HCC patients who are anticipated to wait more than six months, provide tumor control and possibly improve outcomes. Ongoing research in surgical technology adds new items to the surgical armamen-

tarium such as image guided surgery, Nano knife that makes liver surgery safer and more effective. Advances in immunomodulation are coming up with promising new agents that are more efficient and with fewer side effects.

Author details

Emad H. Asham¹, Howard Mansour² and Mark Ghobrial^{1*}

*Address all correspondence to: rmghobrial@tmhs.org

1 Transplant & HPB Surgery, Center for Liver Disease and Transplantation, The Methodist Hospital, Texas Medical Center, Houston, Texas, USA

2 Hepatology, Center for Liver Disease and Transplantation, The Methodist Hospital, Texas Medical Center, Houston, Texas, USA

References

- [1] Center for Disease Control and Prevention. Morbidity and Mortality Weekly Report 2010; 59 (17):517.
- [2] Morgan TR, Mandayam S, Jamal MM. Alcohol and hepatocellular carcinoma. Gastroenterology. 2004 ;127(5 Suppl 1):S87-96.
- [3] McCollough. The clinical features, diagnosis and natural history of non-alcoholic fatty liver disease. Clin Liver Dis 2004; 8:521-533.
- [4] Shimada M, Hashimoto E, Taniai M, Hasegawa K, Hiroaki Okuda H, Hayashi N, Takasaki K, Ludwig J. Hepatocellular carcinoma in patients with non-alcoholic steatohepatitis. J Hepatol 2002; 37:154-160.
- [5] Finch SC, Finch CA, 1995. Idiopathic hemochromatosis and iron storage disease: A. Iron metabolism in hemochromatosis. Medicine 34: 381-430.
- [6] Farinati F, Floreani A, De Maria N, Fagiuoli S, Naccarato R, Chiaramonte M.. Hepatocellular carcinoma in primary biliary cirrhosis. J Hepatol. 1994; 21(3):315-6.
- [7] Bassendine M, Rushbrook S, Chapman R. In: Sherlock S (ed.) Diseases of the liver and Biliary, Diseases of the Liver and Biliary System. Edinburgh. 12th Edition. Blackwell Science 2011 page 338-342.
- [8] Belghiti J, Vilgrain V, Paradis V In: L.H. Blumgart (ed.) Surgery of The Liver and Biliary Tract and the pancreas. 4th Edition. Edniburgh .Saunders 2007: 1142-1143.
- [9] Kuper H, Tzonou A, Kaklamani E, Hsieh C, Lagiou P, Adami H, Trichopoulos D, Stuver S. Tobacco smoking, alcohol consumption and their interaction in the causa-

- tion of hepatocellular carcinoma. *International Journal of Cancer* 2000, 85(4): 498–502.
- [10] Liu Y, Chang CC, Marsh GM, Wu F. Population attributable risk of aflatoxin-related liver cancer: Systematic review and meta-analysis. *Eur J Cancer*. 2012 Mar 8. Epub ahead of print.
 - [11] Takayasu K, Muramatsu Y, Moriyama N, Wakao F, Makuuchi M, Takayama T, Kosuge T, Okazaki N, Yamada R. Radiological study of idiopathic Budd-Chiari syndrome complicated by hepatocellular carcinoma. A report of four cases. *Am J Gastroenterol*. 1994 Feb; 89(2):249-53.
 - [12] Iwatzuki S, Gordon R, M.D., Sahw Jr B, Starzl T. Role of Liver Transplantation in Cancer Therapy. *Ann Surg* 1985; 202(40: 401-407.
 - [13] Mazzaferro V, Regalia E, Doci R, Andreola S, Pulvirenti A, Bozzetti F, et al. Liver transplantation for the treatment of small hepatocellular carcinomas in patients with cirrhosis. *N Engl J Med* 1996;334:693-699.
 - [14] Yao FY, Ferrell L, Bass. NM, et al. Liver transplantation for hepatocellular carcinoma: expansion of the tumor size limits does not adversely impact survival. *Hepatology* 2001; 33: 1394– 403.
 - [15] Adler M, De Pauw F, Vereerstraeten P, et al. Outcome of patients with hepatocellular carcinoma listed for liver transplantation within the Euro transplant allocation system. *Liver Transpl* 2008; 14: 526–33.
 - [16] DuBay D, Sandroussi C, Sandhu L, et al. Liver transplantation for advanced hepatocellular carcinoma using poor tumor differentiation on biopsy as an exclusion criterion. *Ann Surg*. 2011; 253:166-72.
 - [17] Mazzaferro V, Llovet JM, Miceli R, Bhoori S, Schiavo M, Mariani L, et al. Predicting survival after liver transplantation in patients with hepatocellular carcinoma beyond the Milan criteria: a retrospective, exploratory analysis. *Lancet Oncol* 2009;10:35-43.
 - [18] Paradis V, Degos F, Dargere D, Pham N, Belghiti J, Degott C, et al. Identification of a new marker of hepatocellular carcinoma by serum protein profiling of patients with chronic liver diseases. *HEPATOLOGY* 2005; 41:40-47.
 - [19] Kim T, Murakami T, Takahashi S, Tsuda K, Tomoda K, Narumi Y, Oi H, Sakon M, Nakamura H. Optimal phases of dynamic CT for detecting hepatocellular carcinoma: evaluation of unenhanced and triple-phase images. *Abdom Imaging* 1999; 24: 473–480.
 - [20] Ito K. Hepatocellular carcinoma: Conventional MRI findings including gadolinium-enhanced dynamic imaging. *European Journal of Radiology* 2006; 58 (2): 186–199.
 - [21] Alqahtani SA, Fouad TR, Lee SS. Cirrhotic cardiomyopathy. *Semin Liver Dis*. 2008 Feb;28(1):59-69.

- [22] Møller S, Henriksen J H. Cirrhotic cardiomyopathy: a pathophysiological review of circulatory dysfunction in liver disease. *Heart* 2002;87:9–15.
- [23] Saborido BP, Diaz JC, de Los Galanes SJ, Seguro CL, de Usera MA, Garrido MD, et al. Does preoperative fine needle aspiration-biopsy produce tumor recurrence in patients following liver transplantation for hepatocellular carcinoma? *Transplant Proc* 2005;37:3874-3877.
- [24] Mullhaupt B , Francois Durand, Tanja Roskams,4 Philipp Dutkowski,2 and Markus Heim. Is Tumor Biopsy Necessary? *Liver transplantation*2011; 17:S14-S25.
- [25] Bellis L, Castellacci R, Fabrizio M, Festuccia F, Corvisieri P and Puito C.Hepatic venous pressure gradient determination in patients with hepatitis C virus-related and alcoholic cirrhosis. *Euro J of Gastroent & Hepat* 2003; 15(10): 1085-1089.
- [26] Singhal A, Jayaraman M, Dhanasekaran D, Kohli V. Molecular and serum markers in hepatocellular carcinoma: Predictive tools for prognosis and recurrence. *Crit Rev Oncol Hematol*. 2012 May; 82(2):116-40.
- [27] Llovet JM, Bru C, Bruix J. Prognosis of hepatocellular carcinoma: the BCLC staging classification. *Semin Liver Dis* 1999; 19: 329–338.
- [28] Burix J and Sherman M. Management of Hepatocellular Carcinoma: An Update *Hepatology* 2011; 53(3):1020-2.
- [29] Kashiwagi T. PDG-PET and hepatocellular carcinoma. *J Gastroenterol* 2004; 39:1017-1018.
- [30] Panjalaa C, D. L. Senecalb, M. D. Bridgesc,G. P. Kimd, R. E. Nakhlehe, J. H. H. Nguyenf and D. M. Harnois. The Diagnostic Conundrum and LiverTransplantation Outcome for Combined Hepatocellular-Cholangiocarcinoma. *Am J Transpl* 2010; 10: 1263–1267.
- [31] Tickoo S, Zee S, Obiekwe S, Xiao, Koea, Robiou C ,Blumgart L, Jarnagin, W, Ladanyi M , Klimstra, D. Combined Hepatocellular-Cholangiocarcinoma: A Histopathologic, Immunohistochemical, and In Situ Hybridization Study. *Am J Surg Path.* 2002; 26 (8): 989-997.
- [32] Bolondi L, Gaiani S, Celli N, Golfieri R, Grigioni W, Leoni S, Venturi A, Piscaglia F . Characterization of Small Nodules in Cirrhosis by Assessment of Vascularity: The Problem of Hypovascular Hepatocellular Carcinoma. *Hepatology* 2005;42(1): 27-34.
- [33] Bolondi L, Sofia S, Siringo S, Gaiani S, Casali A, Zironi G, et al. Surveillance programme of cirrhotic patients for early diagnosis and treatment of hepatocellular carcinoma: a cost-effectiveness analysis. *Gut* 2001;48:251-259.
- [34] Rougier P, Mitrya E, Barbareb JC , Taiebc J. Hepatocellular Carcinoma (HCC): An Update. *Sem Oncol* 2007 ; 34, Supplement 1: S12–S20.

- [35] Majno P, Riccardo Lencioni,² Francoise Mornex,³ Nicolas Girard,³ Ronnie T. Poon,⁴ and Daniel Cherqui. Is the Treatment of Hepatocellular Carcinoma on the Waiting List Necessary? *Liver Transp* 2011; 17:S98–S108.
- [36] Cilloa U, A. Vitaleb,*¹, F. Grigolettoc, E. Gringeria, F. D'Amicoa, M. Valmasonia, A. Brolesea,² G. Zanusa, N. Srsena, A. Carraroa, P. Burrad, F. Farinatid, P. Angelie and D. F. D'Amicoa. Intention-to-Treat Analysis of Liver Transplantation in Selected, Aggressively Treated HCC Patients Exceeding the Milan Criteria. *American Journal of Transplantation* 2007; 7: 972–981.
- [37] Graziadei W, Sandmueller H, Waldenberger P, Koenigsrainer A, Nachbaur K, Jaschke W, Margreiter R, Vogel W. Chemoembolization Followed by Liver Transplantation for Hepatocellular Carcinoma Impedes Tumor Progression While on the Waiting List and Leads to Excellent Outcome. *Liver Transplantation* 2003; 9(6): 557-563
- [38] Lu D, Yu N, Raman S, Lassman C, Tong M, Britten C, Durazo F, Saab S, Han S, Finn R, Hiatt J, Bussuttil R. Percutaneous radiofrequency ablation of hepatocellular carcinoma as a bridge to liver transplantation. *Hepatology* 2005; 41(5) 1130- 1137.
- [39] Kurokohchi K, S Watanabe, T Masaki, N Hosomi, T Funaki, K Arima, S Yoshida, Y Miyauchi, S Kuriyama. Combined use of percutaneous ethanol injection and radiofrequency ablation for the effective treatment of hepatocellular carcinoma. *Inter J Onc* 2002; 21(4):841-6.
- [40] Yao F., kerlan R, Hirose R, Davern T, Bass N, Feng S, Peters M, terrault N, Freise C, Ascher N and Roberts J. Excellent Outcome Following Down-Staging of Hepatocellular Carcinoma Prior to Liver Transplantation: An Intention-to-Treat Analysis. *Hepatology* 2008; 48(3):
- [41] Guo Y, Zhang Y, Klein R, Nijm GM, Sahakian AV, Omary RA, et al. Irreversible electroporation therapy in the liver: longitudinal efficacy studies in a rat model of hepatocellular carcinoma. *Cancer Res* 2010; 70:1555-1563.
- [42] Thomas K, Chung W, Ellis S, Frederman D, Kavnoudias H, Loader-Oliver D, Robert S, Evans P, Ball C, Haydon A. Investigation of the Safety of Irreversible Electroporation in Humans. *J Vas Interven Rad* 2011; 22,(5): 611-621.
- [43] Wilhelm SM, Carter C, Tang L, et al. BAY 43-9006 exhibits broad spectrum oral anti-tumor activity and targets the RAF/MEK/ERK pathway and receptor tyrosine kinases involved in tumor progression and angiogenesis. *Cancer Res.* 2004; 64: 7099-7109.
- [44] Sonnenberg F, Beck R, Markov Models in Medical Decision Making. A Practical Guide. *Med Decision Making* December 1993; 13(4): 322-338.
- [45] Vitale A,¹ Michael L. Volk,² Davide Pastorelli,³ Sara Lonardi,³ Fabio Farinati,⁴ Patrizia Burra,⁴ Paolo Angeli, Cillo U. Use of Sorafenib in Patients With Hepatocellular

Carcinoma Before Liver Transplantation: A Cost-Benefit Analysis While Awaiting Data on Sorafenib Safety. *Hepatology* 2009; 51 (1): 165-173.

- [46] Llovet JX, Bruix J, Gores GJ. Surgical resection versus transplantation for early hepatocellular carcinoma. Clues for the best therapy. *Hepatology* 2000; 31:1019-1021.
- [47] Adam, R, Azoulay D, Castaing D, Eshkenazy R, Pascal G, Hashizume K, Samuel D and Bismuth H. Liver resection as a bridge to transplantation for Hepatocellular carcinoma on cirrhosis. A reasonable strategy? *Ann Surg* 2003; 238(4):508-519.
- [48] Belghiti J, Cortes A, Abdalla E, Regimbeau J, Parkash K, Durand F, Sommacale D, Dondero F, Lesurtel M, Sauvanet A, Farges O, Kianmanesh R. Resection prior to transplantation for hepatocellular carcinoma. *Ann Sur* 2003; 238(6):885-893.
- [49] Malinchoc M, Kamath P, Gordon F, Peine CJ, Rank J, ter Borg PC. A Model to predict poor survival in patients undergoing transjugular portosystemic shunts. *Hepatology* 2000;31:864-71.
- [50] United Network for Organ Sharing/Organ Procurement and Transplantation Network. UNOS/OPTN policy 3.6.4.4. <http://optn.transplant.hrsa.gov/>.
- [51] Scientific Registry of Transplant Recipients annual report 2010. www.srtr/annual_reports/2010/flash.
- [52] Pomfret EA, Pomposelli JJ, Lewis WD, et al. Live donor adult liver transplantation using right lobe grafts: donor evaluation and surgical outcome. *Arch Surg* 2001; 136:425–433.
- [53] Lee S, Hwang S, Moon D, Ahn C, Kim K, Sung K, Ko G, Park K, Ha T, Song G. Expanded Indication Criteria of Living Donor Liver Transplantation for Hepatocellular Carcinoma at One Large-Volume Center. *Liver Transpl* 2008 14:935-945.
- [54] Koichi Urata¹, Seiji Kawasaki MD^{1,*}, Hidetoshi Matsunami¹, Yasuhiko Hashikura¹, Toshihiko Ikegami¹, Shinpachi Ishizone³, Yoshitaka Momose³, Atsushi Komiyama², Masatoshi Makuuchi. Calculation of child and adult standard liver volume for liver transplantation. *Hepatology* 1995; 21(5): 1317–1321.
- [55] Chen YS, Chen CL, Liu PP, Chiang YC. Preoperative evaluation of donors for living related liver transplantation. *Transplant Proc* 1996; 28:2415–2416.
- [56] Lang H, Radtke A, Hindennach M, Schroeder T, Frühauf N, Malagó M, Bourquain H, Peitgen H, Oldhafer K, Broelsch C. *Arch Surg*. 2005;140:629-638. Impact of Virtual Tumor Resection and Computer-Assisted Risk Analysis on Operation Planning and Intraoperative Strategy in Major Hepatic Resection *Br J Surg*. 2012; 99(6):855-63.
- [57] Todo S and Hiroyuki Furukawa H, on behalf of the Japanese Study Group on Organ Transplantation. Living Donor Liver Transplantation for Adult Patients With Hepatocellular Carcinoma: Experience in Japan. *Ann Surg*. 2004; 240(3): 251-26.

- [58] Vakili K, Pomposelli JJ, Cheah YL, et al. Living donor liver transplantation for hepatocellular carcinoma: increased recurrence but improved survival. *Liver Transpl* 2009; 15: 1861–6.
- [59] Sandhu L, Sandroussi C, Guba M, Selzner M, Ghanekar A, Cattral M, McGilvary I, Levy G, Greig P, Renner E and Grant D. Living Donor Liver Transplantation Versus Deceased Donor Liver Transplantation for Hepatocellular Carcinoma: Comparable Survival and Recurrence. *Liver Transpl*. 2012 Mar;18(3):315-22.
- [60] Lee SG, Hwang S, Moon DB, Ahn CS, Kim KH, Sung KB, Ko GY, park KM, Ha TY, Song GW. Expanded Indication Criteria of Living Donor Liver Transplantation for Hepatocellular Carcinoma at One Large-Volume Center. *Liver transpl*. 2008; 14: 935-945.
- [61] Muller S, Mehrabi A, Schmied B, Welsch T, Engleman F, Schemmer P, Weits J and Schmidt J. Partial liver transplantation-living donor liver transplantation and split liver transplantation. *Nephrol Dial Transplant* (2007) 22 [Suppl 8]: viii13–viii22.
- [62] Rela M, Vougas V, Muiesan P, Valica-Melendez H, Smyrniotis V, Gibbs P, Kaani J, Williams R, Heaton N. Split Liver transplantation: King's College Hospital Experience. *Ann Surg* 1998; 227(2): 282-288
- [63] Busuttill R, Goss J. Split liver transplant. *Ann Surg* 199; 229(3): 313-321.
- [64] Sotiropoulos GC, Lang H, Frühauf NR, Molmenti EP, Omar OS, Radtke A, Paul A, Nadalin S, Frilling A, Broelsch CE, Malagò M.. Split liver transplantation for hepatocellular carcinoma. *Hepatogastroenterology*. 2006 Sep-Oct;53(71):764-7.
- [65] Lo MC, Fan ST, Chan JKF, et al. Minimum graft volume for successful adult to adult living donor liver transplantation for fulminant hepatic failure. *Transplantation* 1996; 62:696-698.
- [66] Dahm F, Georgeiv, Clavien P. Small-for-Size Syndrome After Partial Liver Transplantation: Definition, Mechanisms of Disease and Clinical Implications. *Am J Transpl* 2005; 5: 2605–2610.
- [67] Botha J, Langnas A, Campos D, Grant W, Freise C, Ascher N, Mercer D, Roberts J. Left Lobe Adult-to-Adult Living Donor Liver Transplantation: Small Grafts and Hemiportocaval Shunts in the Prevention of Small-for-Size Syndrome. *Liver Transpl*. 2010 May;16(5):649-57.
- [68] Emond JC, Leib M. The living-related liver transplant evaluation: linking risk factors and outcome. *Liver Transpl Surg* 1996;2 [5 Suppl 1]: S57–S63.
- [69] Klintmalm GB, Davis GL, Teperman L, Netto GJ, Washburn K, Rudich SM, Pomfret EA, Vargas HE, Brown R, Eckhoff D, Pruett TL, Roberts J, Mulligan DC, Charlton MR, Heffron TG, Ham JM, Douglas DD, Sher L, Baliga PK, Kinkhabwala M, Koneru B, Abecassis M, Millis M, Jennings LW, Fasola CG. A randomized, multicenter study comparing steroid-free immunosuppression and standard immunosuppression for

liver transplant recipients with chronic hepatitis C. *Liver Transpl.* 2011; 17(12): 1394-403.

- [70] Eason J, Loss G, Blazek J, Nair S, Mason A. Steroid-Free Liver Transplantation Using Rabbit Antithymocyte Globulin Induction: Results of a Prospective Randomized Trial. *Liver Transplantation* 2001; 7(8): 693-697
- [71] Liu C, Fan S, Lo C, Chan S, Ng I, Lai C, Wong J. Interleukin-2 Receptor Antibody (Basiliximab) for Immunosuppressive Induction Therapy After Liver Transplantation: A Protocol With Early Elimination of Steroids and Reduction of Tacrolimus Dosage. *Liver Transplantation* 2004; 10, (6): 728-733.
- [72] Busque S, Cantarovich M, Mulgaonkar S, Gaston R, Gaber AO, Mayo PR, Ling S, Huizinga RB, Meier-Kriesche HU; PROMISE Investigators. The PROMISE study: a phase 2b multicenter study of voclosporin (ISA247) versus tacrolimus in de novo kidney transplantation. *Am J Transplant.* 2011 Dec;11(12):2675-84.
- [73] Vincenti F, Charpentier B, Vanrenterghem Y, Rostaing L, Bresnahan B, Darji P, et al. A phase III study of belatacept-based immunosuppression regimens versus cyclosporine in renal transplant recipients (BENEFIT study). *Am J Transplant* 2010;10:535-546.
- [74] Saliba F, De Simone P, Nevens F, De Carlis LMetselaar HJ, Beckebaum S, et al. Efficacy and safety of everolimus with early reduction or elimination of tacrolimus in 719 de novo liver transplant recipients: 12 month results of a randomized, controlled study. *Hepatology* 2011;54 (Suppl);
- [75] Marsh JW, Dvorchik I, Subotin M, et al. The prediction of risk of recurrence and time to recurrence of hepatocellular carcinoma after orthotopic liver transplantation: a pilot study. *Hepatology.* 1997;26(2):444-450.
- [76] Parfitt J, Marotta P, AlGhamdi M, Wall W, Khakhar A, Suskin N, Quan D, McAllister V, Ghent C, Levstik M, McLean C, Chakrabarti S, Garcia B and Driman D. Recurrent Hepatocellular Carcinoma after Transplantation: Use of a Pathological Score on Explanted Livers to Predict Recurrence. *Liver Trans* 2007; 13:543-551.
- [77] Decaens T, Roudot-Thoraval F, Bresson-Handi S, Meyer C, Gugenheim J, Durand F, Bernard P, Boillot O, Compagnon P, Calmus Y, Hardwigsen J, Ducef C, Pageaux P, Dharancy S, Chazouilleres O, Cherqui D, Duvoux C. Role of immunosuppression and tumor differentiation in predicting recurrence after liver transplantation for hepatocellular carcinoma: A multicenter study of 412 patients. *W J Gastroent* 2006; 12(45): 7319-7325.
- [78] Wang Z, Zhou J, Fan J, Qiu SJ, Yu Y, Huang XW and Tang ZY. Effect of Rapamycin Alone and in Combination with Sorafenib in an Orthotopic Model of Human Hepatocellular Carcinoma. *Clin Cancer Res* August 15, 2008 14; 5124.
- [79] Vivarelli M, Dazzi A, Zanella M, Cucchetti A, Cescon M, Ravaioli M, Del Gaudio M, Lauro A, Grazi G, Pinna A. Effect of Different Immunosuppressive Schedules on Re-

currence-Free Survival After Liver Transplantation for Hepatocellular Carcinoma. Transplantation 2010; 89 (2): 227-231.

- [80] Schnitzbauer A, Schlitt H, and Geissle E. Influence of Immunosuppressive Drugs on the Recurrence of Hepatocellular Carcinoma After Liver Transplantation: A Gap Between Basic Science and Clinical Evidence. Transplantation 2011; 91(11): 1173- 1176.
- [81] Lai Q , Merlib M, Ginanni Corradinib S, Menninia G, Gentilib F, Molinarob A, Morabitoa V, Ferrettic G, Pugliesed F, Novellia G, Berlocoa P, Rossia M. Predictive Factors of Recurrence of Hepatocellular Carcinoma After Liver Transplantation: A Multivariate Analysis. Transplantation Proceedings 2009;41(4): 1306–1309.
- [82] D’Alco F, Schwartz M, Vltale A, Tabrizian P, Roayale S, Thing A, Guido M, Martin J, Schlano T and Cllio U. Predicting Recurrence After Liver Transplantation in Patients with Hepatocellular Carcinoma Exceeding the Up-To-Seven CriteriaLiver Transpl 15:1278-1287, 2009.
- [83] Dudek K, Kornasiewicz O , Remiszewska P, Kobryńb K, Ziarkiewicz-Wróblewska B, Górnicka B, Zieniewicz K, Krawczyka M. Impact of Tumor Characteristic on the Outcome of Liver Transplantation in Patients With Hepatocellular Carcinoma. Transplantation Proceedings 2009; 41, (8): 3135–3137.
- [84] Sharma P, Welch K, Hussain H, Pelletier S, Fontana R, Marrero J, Merion R. Incidence and risk factors of Hepatocellular carcinoma recurrence after liver transplantation in the MELD era. Dig Dis Sci 2012; 57:806-812.
- [85] Han K, Tziman G, Barkun J, Metrakos P, Tchervenkv J, Hilzenrat N, Wong P, Deschenes M. Pre-operative alpha feto protein slope is predictive of hepatocellular carcinoma recurrence after liver transplantation. Can J Gastroenterol 2007; 21(1): 39-45.
- [86] Xu W, Cao L, Chen L, Isolation of circulating tumor cells using a novel cell separation strategy. Clin Cancer Res. 2011; 17: 3783-93.

IntechOpen