

# We are IntechOpen, the world's leading publisher of Open Access books Built by scientists, for scientists

6,900

Open access books available

186,000

International authors and editors

200M

Downloads

Our authors are among the

154

Countries delivered to

TOP 1%

most cited scientists

12.2%

Contributors from top 500 universities



WEB OF SCIENCE™

Selection of our books indexed in the Book Citation Index  
in Web of Science™ Core Collection (BKCI)

Interested in publishing with us?  
Contact [book.department@intechopen.com](mailto:book.department@intechopen.com)

Numbers displayed above are based on latest data collected.  
For more information visit [www.intechopen.com](http://www.intechopen.com)



---

# **The Use of Proximal and Distal Ends of Internal Mammary Arteries and Veins as the Recipient Vessels for Combined Breast and Chest Wall Reconstruction with Free Bipedicled TRAM or DIEP Flap**

---

Lan Mu and Senkai Li

Additional information is available at the end of the chapter

<http://dx.doi.org/10.5772/56612>

---

## **1. Introduction**

Breast reconstruction, after the traditional radical mastectomy, is particularly challenging for a plastic surgeon. For these patients, not only the breast but subclavian and anterior axillary fold deformities need to be reconstructed. The TRAM flap including zone IV is usually required to be used for this complex reconstruction. The design of a TRAM FLAP with bipedicled deep inferior epigastric vessels would insure the perfusion of whole flap. However, it is difficult to find two sets healthy recipient vessels since the thorocodorsal vessels are usually damaged during axillary dissection or radiation therapy.

Fujino first reported the use of the internal mammary artery (IMA) as the recipient artery in breast reconstruction with superior gluteal microvascular free flap in 1975 [1]. The technique of use of the IMA as a recipient artery was modified and popularized by Shaw (1983) [3]. In 1994 [5], Blondeel and colleagues reported a refinement of breast reconstruction by the use of a bilateral deep inferior epigastric perforator flap in one woman with a vertical infraumbilical scar, in which the two arterial pedicles were anastomosed to the proximal IMA by end-end and end-side patterns. However, the procedure is complicated and technically demanding.

Conventionally, the proximal ends of internal mammary artery and vein (IMA, IMV) are usually used as the recipient vessels in breast reconstruction with free flaps. Since 1980s, we have used both the proximal and distal ends of internal mammary vessels as recipient vessels for end-end anastomoses to the vessels of the bipedicled flap and proved that the distal IMA

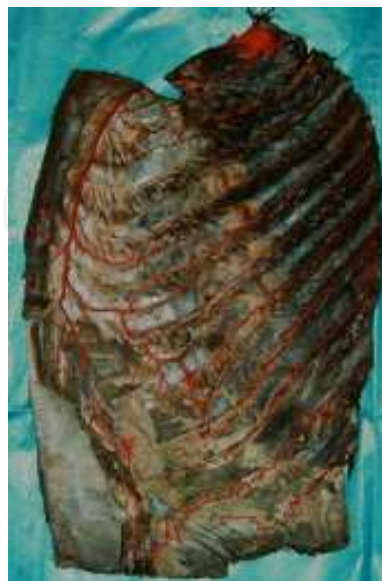with retrograde flow could be used as one of the supplying arteries for a second anastomoses in the breast reconstruction. [6 - 11]

This chapter will describe the anatomy, arterial pressures of antegrade and retrograde flows of IMA, and clinical applications of the use of proximal and distal IMAs as recipient arteries for breast reconstruction with bipediced TRAM or DIEP flap from our experimental and clinical studies.

## 2. Anatomic study

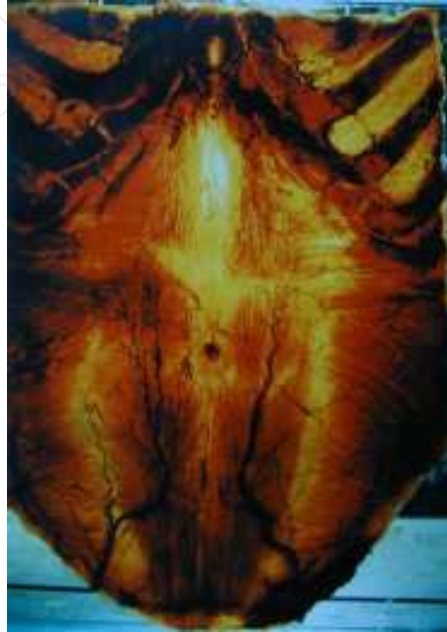*Materials and Methods:* The cadavers (3 males and 7 females) fixed with formalin were used in the study. Sixteen sides of abdomino-thoracic wall were dissected and four sides were made into morphological transparent specimen [8]. How the vessels were running, the relationship of vessels and the vessels' diameter were recorded by photo and measured by vernier caliper.

*Results:* 1) The IMA was found originating from the subclavian artery, then running along the sternum, and segmentally connecting to the intercostal arteries from the aorta. It was divided into two ends at the sixth intercostal space as the deep superior epigastric and musculophrenic arteries. The musculophrenic artery was found linked to the abdominal aorta by anastomosed with superior and inferior phrenic arteries. This is the anatomic basis of distal end of IMA as one recipient supply artery, which means that, if the IMA was cut off near the third intercostal space during the clinical procedure, the retrograde IMA flowed distally from the extensive anastomoses among the intercostal, musculophrenic and deep superior epigastric arteries.[Fig.1].

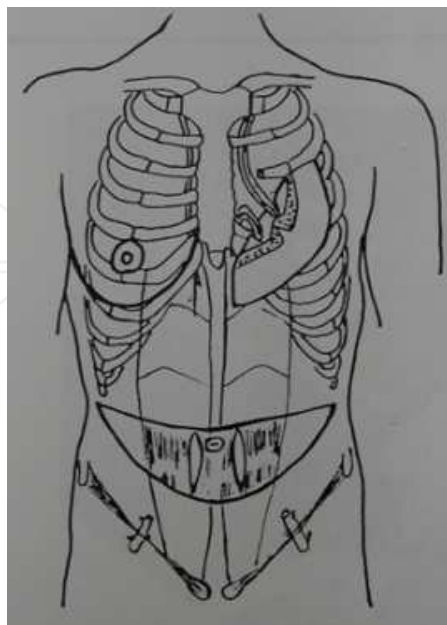


**Figure 1.** The anastomoses among DSEA,m.p.a. and i.c.a;

2) There were two accompanying veins found with communicating branches. No valve had been found inside the internal mammary vein, intercostal vein and communicating branches. The IMV retrogradely drained distally from two direct ways, via the communicating branches to the other IMV and then to the subclavian vein and via the intercostal vein to the posterior intercostal vein and then to the vena azygos [Fig.2].



**Figure 2.** Transparent Morphology specimen of the Thoracoabdominal Wall



**Figure 3.** Operative Technique Demonstration

- 3) The mean diameter and standard deviation of the IMA at the third intercostal space was  $2.79 \pm 0.15$  mm. The diameter of the IMV ranges from 1.50 to 3.94 mm.
- 4) The Deep Inferior Epigastric Artery (DIEA) was found originating from the external iliac artery under the middle of the inguinal ligament, and then running up medially between peritoneal and transverse abdominal fascia. Under the posterior sheath of rectus abdominal muscle above the semicircular line, it ran up inside the muscle, and connected with the deep superior epigastric artery (DSEA) with "spiral chock anastomosis" at the nearest tendinous intersection above the umbilicus.
- 5) There were two accompanying veins to the DIEA. The mean diameter of the larger vein was  $2.14 \pm 0.05$  mm, while the DIEA was  $2.42 \pm 0.06$  mm at their original points of inguen [9].

### 3. Pressures in a canine model

**Materials and Methods:** Ten dogs (weight 6-8kg) were given general anesthesia and monitored. After the anterior thoracic wall was opened along the middle line, in the third intercostal space, the pressures at the two ends (proximal and distal) of IMA were measured in twenty sides (both right and left sides using Eight Channel Physiologic Instrument 6400 Japan).

**Results:** The mean pressure at distal end was  $86/77 \pm 0.02$  mmHg (left sides) and  $87/78$  mmHg  $\pm 0.03$  (right sides). It was 63-71% of the proximal end ( $p < 0.05$ ). There is no statistical significance ( $p > 0.05$ ) between the pressure of left side and that of right side<sup>[10]</sup>.

### 4. Arterial pressures measurement in patients

**Patients and Methods:** Between 1988 and 2010, 50 cases of unilateral breast reconstructions were performed using the free TRAM, muscle sparing TRAM or DIEP flaps including bilateral deep inferior epigastric vessels as the pedicles. Both pedicles were anastomosed to the two ends of internal mammary vessels (proximal and distal) all by end-end. Here, the procedures of the arterial pressures from both proximal and distal and skin Perfusion Units on different points of flap were measured in two cases. Case 1: A thirty-six-year-old woman was hospitalized for right breast reconstruction, five years after radical mastectomy. Case 2: A fifty-year-old woman wanted her left breast reconstructed, eleven years after radical mastectomy.

#### 4.1. Surgical technique

**Pre-operative planning:** The diameter and flowmeter of IMA, IMV, DIEA, DIEV were checked by colour Duplex scanning (Acuson 128\*P). The flaps were measured 13 cm in height and 42 cm in width. From the middle line, four points were marked cranially and laterally from each side for the measurement of the Perfusion Units. The pressures of both sides DIEA were measured with the same method described above before they were transected.

**Preparing of IMA, IMV and the measurement of pressures:** 2 cm length of 3<sup>rd</sup> or 4<sup>th</sup> rib cartilage was removed. About 4 cm of IMA, IMV was exposed well. Before transection, a needle that had been connected with Multifunction Monitor (HP 6112 U.S.A.) was punched inside the middle point of IMA. The IMA was clamped at the proximal end for pressure measurement of the distal end and vice versa.

**Skin Perfusion Units with bilateral DIEA, DIEV pedicles:** The Perfusion Units on different points of TRAM flap were measured with Laser Doppler Flowmeter (PEREFLUX PF3 Sweden) with different conditions: before flap incision; on both pedicles and with right or left pedicle only.

**Preoperative MDCT:** Since 2006, MDCT has been used to help pre-operation planning, harvesting the perforators. Both donor site (deep inferior epigastric artery and vein) and recipient site (internal mammary artery and vein) can be evaluated. [12]

**Vascular Anastomosis:** After transection of the pedicle, the flap was weighed, photographed and transferred to the chest wall. The flap was bent 90° so that the donor vessels close to the recipient vessels are without tension. The flap was then fixed to the chest wall skin. Next, four conventional end-to-end anastomoses were performed among the arteries and vein. The immediate rate of blood flow of the arteries anastomosis site was measured with Electromagnetic Flowmeter (3200 Japan). Then, the PU was monitored under different conditions.

**Shaping of the breast:** With bilateral pedicles (two arteries and two veins) the whole flap could be used safely. The flap was positioned in a U-shape, lateral part of the flap ending up laterally de-epithelialised and placed under the local flap to recreate a natural looking anterior axillary fold.

**Post-operation monitoring and follow-up:** The Perfusion Units on different points of TRAM flap were measured from the first to seventh day, and on the fourteenth day after the operation.

## 4.2. Results

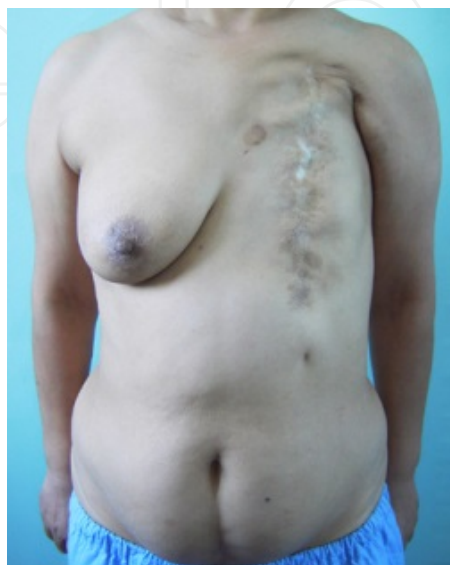The flap survived 100% with satisfied contour. The two anastomosis sites were followed up by colour Doplex scanning (Acuson 128\*P) five years after the operation on one patient. Both, the flowmeter of the proximal and distal anastomosis stomas were similar. One flap failed due to the artery thrombosis during and after operation, despite several re-anastomosis. 48 hours after the operation, the flap was removed and skin graft was performed. Every part of remaining 49 flaps survived completely with satisfied breast contour.

## 4.3. Typical cases

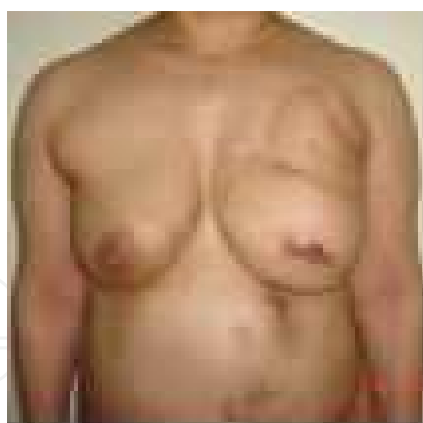**Case 3:** A fifty-six-year-old female, 12 years after the radical mastectomy and radiation therapy. Verticle and long incision scar was noticed. Not only that the left breast was lost, but serious deformity of chest wall including an unstable scar in part below clavian, axillary fold and axillary area was noticed. Her right breast was big and a matched felt reconstructive breast was desired. Middle vertical infraumbilical caesarean scar was noticed on her abdominal wall. Free bilateral deep inferior epigastric vessels TRAM flaps (12\*42cm\*), anastomosed to the two



ends of internal mammary vessels (proximal and distal) all by end-end was performed for left breast reconstruction. Upper and lateral part of the flap were de-epithelialised and placed under the local flap to recreate a natural looking chest wall and anterior axillary fold. Six months after the operation, nipple reconstruction with modified “arrow” flap was made. [Fig 4,5]



**Figure 4.** Pre-operation

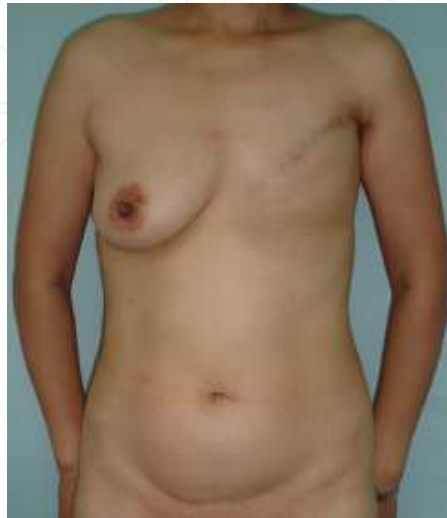

**Figure 5.** Post-operation

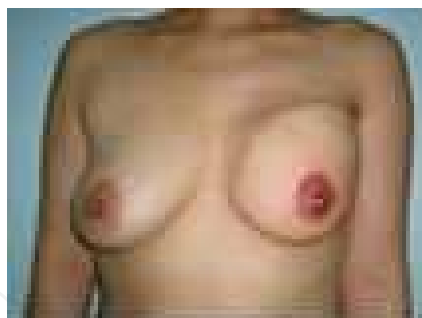
**Typical case 4:** A forty-two-year-old female, five years after the left modified radical mastectomy and radiation therapy. Her right breast was big, with abdominal wall not thick enough having a transverse Caesarean scar.

Free bilateral deep inferior epigastric vessels DIEP flaps (10\*30cm\*), anastomosed to the two ends of internal mammary vessels (proximal and distal), all by end-end were performed.

Upper and lateral part of the flap were de-epithelialised and placed under the local flap to recreate a natural looking chest wall and anterior axillary fold. New nipple was reconstructed with modified “arrow” flap, and the areolar was made by a tattoo. [Fig 6,7]



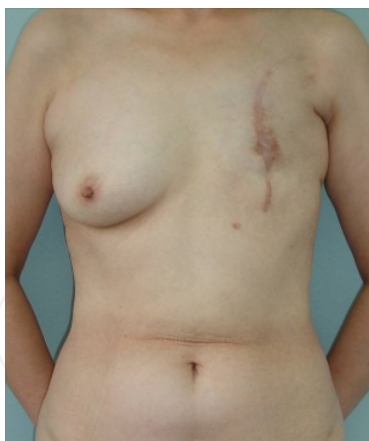**Figure 6.** Pre-operation



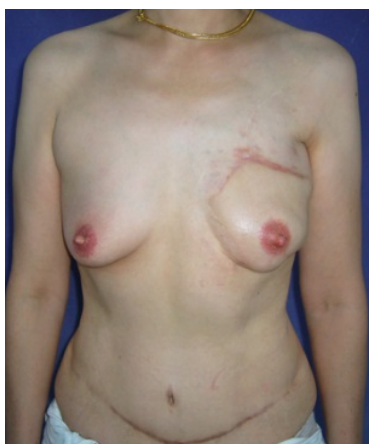**Figure 7.** Post-operation

**Typical case 5:** A fifty-one-year-old old female, ten years after a radical mastectomy and radiation therapy with verticle scar. Even though her right breast was big, her abdominal wall was thin. Free bilateral deep inferior epigastric vessels DIEP flaps (9\*28cm\*), anastomosed to the two ends of internal mammary vessels (proximal and distal),all by end-end were performed. Upper and lateral part of the flap were de-epithelialised and placed under the local flap to recreate a natural looking chest wall and anterior axillary fold. New nipple was reconstructed with modified “arrow” flap, the areolar was made by tattoo, bilateral for symmetry [Fig 8,9,10]

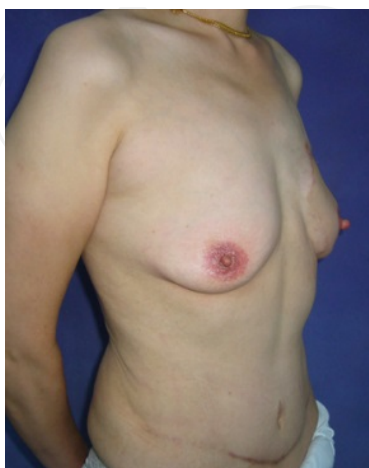



**Figure 8.** Pre-operation



**Figure 9.** Post-operation



**Figure 10.** Post-operation

## 5. Discussion

Owing to its anatomic position, the internal mammary artery (IMA) has been popular in coronary artery myocardial revascularization since 1968 [13]. Studies on its histology, histochemistry, immunohistochemistry, morphology and hemodynamics have shown that the IMA has many advantages such as: thin intima with endothelium-derived relaxing factor (EDRF), fine compliance, relative freedom from arteriosclerosis, and decreased thrombosis or arteriostenosis after coronary bypass operation. Both, the early and late patency in patients are higher than that with vein bypass. In order to reduce the anastomotic tension, some authors proposed that the coronary artery myocardial revascularization could be made by means of retrograde IMA flow. So far, this theory has been only proved to be feasible in animal experiments by Folts (1981) [14] and Wang Zheng(1987) [15]. Paletta (1994) [16] described the extensive anastomoses among the IMA, DSEA, intercostal arteries, musculophrenic arteries in dogs. It is similar to that of human being.

This chapter confirmed the feasibility of using the distal ends of the IMA as recipient vessels for free flaps simultaneous by using the proximal ends. In patients, the pressure at distal end was 66 and 58 mmHg. It was 75-77% of the pressure of the proximal ends. When the flap was supplied only by distal ends of IMA, IMV, the Perfusion Unit of ipsilateral flap was 4.0-6.0, and the Perfusion Unit of contralateral side of flap was 1.4-1.8. When the flap was supplied only by proximal ends of IMA, IMV, the perfusion unit of ipsilateral flap was 3.0-15.0, and the perfusion unit of contralateral side of flap was 1.8-2.1. When the flap was supplied by distal and proximal ends of IMA, IMV simultaneously, the Perfusion Unit of flap with distal side was 4.0-6.5, and the perfusion unit of flap with proximal side was 4.0-16.0. The blood flow at the two anastomoses sites were similar to each other in a later stage (measured five years after the operation). This indicated that, at the beginning, the pressure of the distal end of IMA are lower than the pressure of the proximal end. However, over the time, they have reached a balance. The vascularity in all territories of revascularized bipediced (proximal and distal) TRAM flap is very good. 49 cases survived completely with satisfied breast contour.

This technique has been popularized in China [17,18], Canada [19], U.S.A. [20], UK and Italy [21].

## 6. Conclusion

Free bipediced deep inferior epigastric TRAM /DIEP flap is needed for radical mastectomy deformity or big breasts and can be performed on thin patients or patients with vertical midline scar.

Internal mammary vessels can provide double recipient vessels (proximal and distal ends) for anastomosis to both DIEA, DIEV anastomosis.

Our clinical and experimental studies showed that the distal IMA has reduced perfusion pressure but it provides excellent flow and flap perfusion. This allows reliable use of two pedicles for the survival of the entire flap.

## Acknowledgements

We wish to thank Dr. William W Shaw, Dr. Robert J Allen and Dr. Feng Zhang for their refinements in this chapter and their kind suggestions.

## Author details

Lan Mu\* and Senkai Li

\*Address all correspondence to: Lanhu\_mu@yahoo.com

Aesthetic and Reconstructive Surgery Center of Breast, Plastic Surgery Hospital, Peking Union Medical College, Chinese Academy of Medical Sciences, China

## References

- [1] Fujino T, Harashina T, Aoyagi F. Reconstruction for aplasia of the breast and pectoral region by microvascular transfer of a free flap from the buttock. *Plast reconstr Surg*. 1975;56:178-81.
- [2] Fujino T, Harashina T, Enomoto K. Primary breast reconstruction after a standard radical mastectomy by a free flap transfer. *Plast Reconstr Surg*. 1976; 58: 371-5.
- [3] Shaw W W. Breast reconstruction by superior gluteal microvascular free flaps without silicon implants. *Plast Reconstr Surg*. 1983; 72: 490-501.
- [4] Senkai, Li, Yangqun Li, Jun Xu, et al: Breast reconstruction with free superior gluteal microvascular flap (one case report.) *Chin J Plast Surg Burns*. 1990;6(3):228- 229.
- [5] Blondeel PN, Boeckx WD. Refinements in free flap breast reconstruction: the free bilateral deep inferior epigastric perforator flap anastomosed to the internal mammary artery. *Br J Plast Surg*. 1994 Oct. 47(7):495-501.
- [6] Lanhua Mu, Jun Xu, Yuanbo Liu, et al. Breast Reconstruction with the Free Bipedicled Inferior TRAM or DIEP Flaps by Anastomosis to the Proximal and Distal Ends of the Internal Mammary Vessels. *Seminars in Plastic Surgery*. 2002, 16(1):61-67.

- [7] Senkai Li, Lanhua Mu, Yangqun Li, et al. Breast Reconstruction with the Free Bipedicled Inferior TRAM Flap by Anastomosis to the Proximal and Distal Ends of the Internal Mammary Vessels. *J Reconstr Microsurg* 2002,18(3):161-167.
- [8] Lanhua Mu, Yiping Yan, Senkai Li et al. Transparent Morphology of the Thoracoabdominal Wall. *J Reconstr Microsurg* 2001, 17(8):611-614.
- [9] Lanhua Mu, Yan Yiping, Li Senkai, et al. The anatomy study of superior and inferior TRAM. *Chinese Journal of Plastic Surgery and Burns*.1998;14(2):122-123.
- [10] Lanhua Mu, Li Senkai, Li Yangqun, et al. Pressure measurement of the Two Ends (proximal and distal ) of Internal Mammary Artery. *Chinese Journal of Plastic Surgery and Burns*.1999;15(6):427.
- [11] Lanhua Mu, Li Senkai, Li Yangqun, et al. Breast reconstruction with TRAM by anastomosed to the internal mammary artery. *Chinese Journal of Plastic Surgery and Burns*.1997;(13)2:100-101.
- [12] Minqiang Xin, Lanhua Mu, Jie Luan et al. The Value of Multidetector Row CT Angiography for Pre-operative Planning of Breast Reconstruction with Deep Inferior Epigastric Arterial Perforator Flaps. *The British Journal of Radiology*, 2010 ,83:40-43.
- [13] Green GE, Sterzer SH, Reppert EH. Coronary artery bypass grafts. *Ann Thorac Surg* 1968;5:443-46. *Cardioangiol*.1995 Jan-Feb;43(1-2):21-7.
- [14] Folts JD, Gallagher KO, Kroncke GM, et al. Myocardial revascularization of the canine circumflex coronary artery using retrograde internal mammary artery flow without cardiopulmonary bypass. *Ann Thorac Surg*.1981;31:21-7.
- [15] Zhen Wang, Yuanzhong Shen, LiangHua Zhang, et al. Experimental study of bypass surgery with retrograde flow of internal mammary artery anastomosed to right coronary artery .1987;4(2):75-7.
- [16] Paletta CE, Vogler G, Freeman B. Viability of the rectus abdominis muscle following internal mammary artery ligation. *Plast Reconstr Surg* 1993;92:234.
- [17] Dong Jiasheng, Wang Tao, FENG Reizheng, et al, Breast Reconstruction by Using Transverse Rectus Abdominals Flap with with Deep Inferior Epigastric Perforator (DIEP) .*Chinese Journal of Tissue Engineering and Reconstructive Surgery*.2005,1(3): 154-156.
- [18] Lanhua Mu. Needing a large DIEAP flap for unilateral breast reconstruction: Double-pedicle flap and Unipedicle flap with additional venous discharge. *Chinese Microsurgery* 2010, 30 (2): 111-117.
- [19] Zenn MR, Heitmann C. Extended TRAM flap: feasibility study on fresh human cadavers. *Ann Plast Surg*. 2003 Mar;50(3):256-62.
- [20] Bergeron L, Tang M, Morris SF. A review of vascular injection techniques for the study of perforator flaps. *Plast Reconstr Surg*. 2006 May;117(6):2050-7.

- [21] Marzia Salgarello, Liliana Barone-Adesi, Marcella Sturla, et al, Correspondence to Lanhua Mu. Needing a large DIEAP flap for unilateral breast reconstruction: Double-pedicle flap and Unipedicle flap with additional venous discharge. *Microsurgery* 2010, 30 (2): 111-117.

IntechOpen

IntechOpen