

We are IntechOpen, the world's leading publisher of Open Access books Built by scientists, for scientists

6,900

Open access books available

186,000

International authors and editors

200M

Downloads

Our authors are among the

154

Countries delivered to

TOP 1%

most cited scientists

12.2%

Contributors from top 500 universities



WEB OF SCIENCE™

Selection of our books indexed in the Book Citation Index
in Web of Science™ Core Collection (BKCI)

Interested in publishing with us?
Contact book.department@intechopen.com

Numbers displayed above are based on latest data collected.
For more information visit www.intechopen.com



Bicuspid Aortic Valve

George Tokmaji, Berto J. Bouma,
Dave R. Koolbergen and Bas A.J.M. de Mol

Additional information is available at the end of the chapter

<http://dx.doi.org/10.5772/55325>

1. Introduction

Bicuspid aortic valve (BAV) disease is one of the most frequent observed congenital heart abnormalities affecting 0.5-1.4% of the general population and has a 3:1 male predominance [1-4]. Although some genes have been described that found to be responsible for the abnormal valvulogenesis, little is known about BAV disease with respect to the genetic and embryological insight of calcification and why patients with BAV disease develop aortic valve calcification including severe aortic valve stenosis (AS) at an earlier age compared with degenerative tricuspid valve. BAV disease is also associated with several cardiovascular abnormalities including coarctation of the aorta (COA) and Turner Syndrome. While patients with BAV disease are often asymptomatic during the childhood, BAV disease is generally diagnosed in the adulthood using echocardiography when aortic stenosis with or without valve calcification, infective endocarditis, aortic regurgitation (AR), and proximal thoracic aortic dilatation are detected, often necessitating surgical intervention [5]. Patients with BAV disease require close observation before complications as heart failure and aortic dissection may occur. In this chapter, the contemporary knowledge regarding BAV disease will be discussed.

2. Anatomy and pathology

The anatomic features of BAV are characterized by smooth cusps margins and the fusion of two cusps of unequal size. These cusps often include a central raphé or false commissure which are usually in the centre of the larger cusp [Figure 2]. The main difference between a commissure and a raphé is that the commissure does not completely span into the cusp [6]. The raphé is to be considered as a hypoplastic commissure between two partially fused cusps. The most commonly seen variant of BAV is the fusion of the left and right coronary cusps (L-R BAV)

also known as the latero-lateral cusps position which is seen in 70-86% of the BAV cases, whereas the fusion of the right and noncoronary cusps (R-N BAV; antero-posterior cusps position) are observed in 12-28% and the left and noncoronary cusps (L-N BAV) in 0.5-3% of the cases [7-11] [Figure 1]. R-N BAVs and asymmetrical sized cusps are relative risk factors that seem to accelerate the stenosis with 27 mm Hg per decade and are therefore more often associated with AS [12]. BAV with equal cusps and absence of raphe have also been reported [6, 7]. In some cases, the raphe can have a quite deep indentation, which could give a false echocardiographic image of a normal tricuspid aortic valve [13]. Calcium depositions are often confined to the raphe and the base of the cusps [7]. AS tend to develop in BAVs which contain no redundant cusp tissue whereas AR tend to develop in BAVs due to the different dimensions of the two cusps, valve prolapse or redundancy of one cusp [14-16]. Histological examination demonstrates that the raphe does not contain fibrous valve tissue but rather include elastin fibers [17]. BAV should also be distinguished from unicommissural valves that tend to calcify and degenerate even earlier in life. Unicommissural valves includes one commissure with normal height and two raphe's that are much lower height, while there is one large cusp, more or less moving like a bicuspid valve. Up to 90% of the individuals with normal tricuspid valve have right coronary artery dominance whereas 29% to 57% of the patients with BAV disease present with left coronary artery dominance. The average length of the left main stem for individuals with BAV and tricuspid valve is less than 5 mm (90% of the cases) and 10 mm in length, respectively. Recognition of these associations with BAV is mandatory due to the increased risk of perioperative myocardial infarction and a potential risk of insufficient myocardial preservation at the time of aortic valve replacement (AVR) [18, 19, 20]. L-R BAVs are often associated with right coronary artery taking its origin from the right sinus of Valsalva, while in the R-N BAVs, both coronary arteries derive from the anterior sinus [21]. The vast majority of the patients with COA present with a L-R BAV (66-90%) [9, 135, 136].

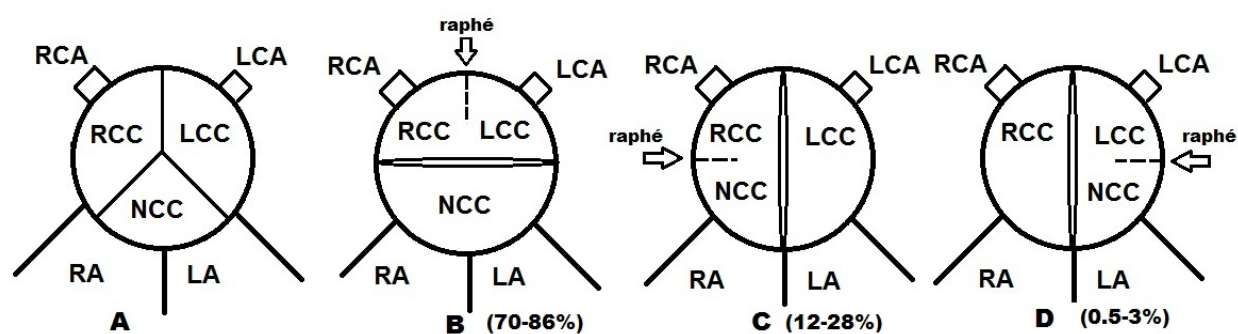


Figure 1. Schematic illustration of the anatomic variations of BAV. (A) normal tricuspid aortic valve. (B) Bicuspid aortic valve, fusion of the left and right coronary cusps. (C) Bicuspid aortic valve, fusion of the right and noncoronary cusps. (D) Bicuspid aortic valve, fusion of the left and noncoronary cusps.

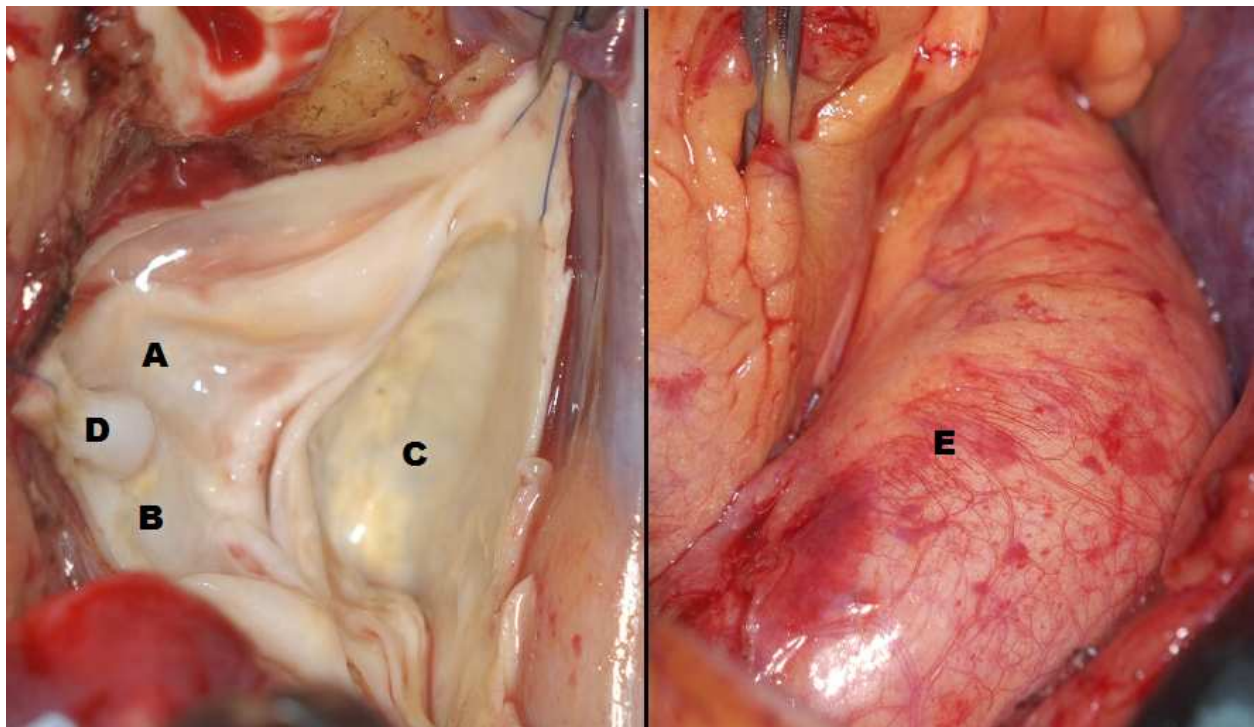


Figure 2. Macroscopic illustration of a bicuspid aortic valve with the fusion of the right and noncoronary cusps (left image) and a dilated ascending aorta (right image). A: Non coronary cusp, B: Right coronary cusp, C: Left coronary cusp, D: Raphé, E: Ascending aorta (dilated).

3. Morphogenesis

The embryogenesis of BAV is still not fully understood. It seems that both genetic predisposition and environmental factors, which could influence the valve morphogenesis, play an important role in the pathogenesis of BAV disease. Initially, the major factor in the formation of BAV is the fusion of the two cusps at the early foundation of the valvulogenesis [22]. The valve morphogenesis occurs in the early stage of foetal development. The heart is one of the first organs to develop through the specification and migration of the anterior lateral plate mesoderm cells which later forms the cardiac crescent [23]. At 3 weeks of gestation in humans, the cardiac progenitors migrate along the ventral midline where they fuse and form a linear heart tube. This beating heart tube is composed of an inner endocardial cell layer which is separated by the extracellular matrix (ECM). Cardiac looping occurs at 4 to 5 weeks of gestation which brings the atrial region of the linear tube into the posterior position of the common ventricles. This is followed by the increase of ECM production which causes the tissue to swell at several areas of the primitive heart, which leads to the formation of the endocardial cushions at the outflow tract (OFT) and atrioventricular (AV) canal. The inner endocardial cells transform into mesenchymal cells, also known as the epithelial-to-mesenchymal transformation (EMT). EMT initiates the formation of the aortic valve in the OFT. Afterwards, the cushions undergo massive cell proliferation, as a result growing towards each other with cushion fusion

being the outcome. Subsequently, the endocardial cushions develop into thin protruding leaflets that are composed of endocardial cells and ECM which remodels the valves. This complex development is reliant on apoptosis, ECM remodeling and cell differentiation. The main contributors for the aortic valve in the OFT are the mesenchymal cells that reach the OFT cushions in association with the endocardial derived mesenchymal cells [24, 25]. Therefore, any disorder in the endocardial cushion development could lead to potential valve disorder including BAV. A disturbance in the neural crest migration which could lead to the fusion of the aortic valve cushions is thought to be a possible embryological explanation for the pathogenesis of BAV disease [22, 26-28]. Several aneurysms which originate from the neural crest including intracranial aneurysms, aortic aneurysms, and cervicocephalic aneurysm have also been observed in patients with BAV disease [29, 30]. Endothelial nitric oxide synthase is a vital protein for valve formation during embryogenesis. Knockout mice lacking this protein showed a high predisposition for BAV due to the fact that malformation in this protein could lead to disturbance of the intricate cell signals which are essential for valvulogenesis [31]. Moreover, it seems that L-R BAV and R-N BAV have different etiological attributes and genotypes. The pathogenesis of R-N BAV is most likely the result of morphogenetic defect which occurs before the OFT septation and is dependent on an aggravated nitric oxide-dependent epithelial-to-mesenchymal transformation. In contrast, L-R BAV is most probably the outcome from the anomalous septation of the proximal portion of the OFT which is caused by distorted activities of neural crest cells [32].

4. Genetics

Genetic burden also seem to contribute to the pathogenesis of BAV disease. It appears that BAV disease has a male-to-female ratio of roughly 3:1 [1-4]. Although some anatomical risk factors have been described, little is known about BAV disease with respect to the genetic insight of calcification process and why patients with BAV disease develop aortic valve calcification including stenosis at an earlier age compared with degenerative tricuspid valve. Chromosomal linkage with BAV disease has been discovered in chromosomal regions 5q, 13q and 18q [36]. Genetic mutations in the *NOTCH 1* gene, which is situated at chromosome 9q seems to be one of the major genetic contributors in the pathogenesis of BAV disease. *NOTCH 1* gene contributes to the pathogenesis of BAV disease through the pathological acceleration of aortic valvular calcium deposition by the increase of the osteogenesis due to the abnormalities in the signalling pathways [37]. Also, genetic mutations in the *ACTA2* gene which is located at chromosome 10q, is associated not only with BAV disease, but also with familial thoracic aortic aneurysms [38]. *ACTA2* gene encodes for the smooth muscle protein α -actin which is an important element of the contractile apparatus. Several familial clusters associated with BAV disease with an estimated prevalence of 24% of aortic valve disorder were found in relatives with more than one member with aortic valve disorder [33]. Additionally, an estimated BAV disease prevalence of up to 9% in first-degree family members of patients with BAV disease has been reported [34, 35]. Based on this known data, it is advisable for first-

degree family members of BAV patients to receive an echocardiographic screening to exclude any potential congenital heart disease including thoracic aortic aneurysms [39, 67, 68].

5. Congenital associated cardiovascular malformations

Although the vast majority of BAV disease are isolated cases, patients with BAV could also present with additional congenital cardiovascular malformations [40-43]. BAV associated anomalies are illustrated in Table 1. Whereas most associated anomalies need treatment early in life, BAV often contributes to morbidity at an older age. COA and Turner Syndrome will be further discussed in this chapter.

5.1. Coarctation of the aorta

COA is a commonly seen congenital abnormality with an incidence of 50 of 100.000 births, whereby the aorta is narrowed in the region where the ductus arteriosus enters [figure 3]. COA can present itself as a simple or complex COA with simple COA referring to COA being an isolated defect and complex COA referring to a combination of COA with other cardiac defects. Congenital BAV is present in around 57% of the COA cases [44]. In the vast majority of the cases, COA in combination with BAV is observed with the fusion of left and right coronary cusps [9]. Patients with both BAV and COA have an increased risk for developing several aortic complications including aortic dissection, AS, AR, and aortic aneurysms [16, 44, 46, 49]. The overwhelming majority of BAV patients present with a L-R BAV (66-90%) [9, 135, 136].

Patients with both BAV and COA receive surgical intervention at a relative young age. Surgical options, mostly depending of the type of lesion include bypass of the coarctation, patch aortoplasty, aneurysm replacement, arch and descending aorta replacement, subclavian artery patch aortoplasty, tube graft replacement, ascending aorta-to- descending aorta bypass or 2-stage combined BAV surgery [69]. Endovascular balloon dilatation and stent placement are currently becoming successful novel interventional options to conventional open surgical treatment [70]. Around 11% to 14% of the patients require a reoperation somewhere in the adulthood [50]. A large cohort study showed that up to 41% of the patients who had a COA required a valve related re-operation [9]. Thus, long-term follow-up in (all) patients with COA including the evaluation of the function of the aortic valve, but also to trace re-coarctation and dilatation of the ascending aorta with routine MRI or echocardiographic evaluation is obligatory.

5.2. Turner Syndrome

Turner Syndrome is a gonadal dysgenesis with complete or partial absence of one of the X chromosome. Cardiovascular defects are frequently observed in Turner Syndrome patients. Turner Syndrome is characterized as neck webbing, short stature, low hairline, and a shield-like chest. BAV disease is the most frequently seen cardiovascular abnormality in Turner Syndrome patients [51, 52]. In Turner Syndrome patients, cardiovascular abnormalities are often the primary cause of mortality including the increase risk of aortic

dissection due to aortic root dilatation and therefore responsible for a much lower life expectancy in this subgroup of BAV disease [53, 54]. Due to the relative small body size, Turner Syndrome patients require an elective ascending aortic aneurysm replacement at a much smaller absolute size [54]. Moreover, it should be noted that the aortic size has to be properly indexed to the body surface area. Therefore, proper follow-up and evaluation of the cardiovascular lesions including imaging of the heart and the aorta for evidence of BAV disease or dilatation of the ascending aorta is mandatory. When imaging appears to be without any lesions and there are no additional risk factors for aortic dissection present, a repeated imaging should be conducted every 5 to 10 years or otherwise clinically indicated. In contrast, when abnormal imaging is present, regular imaging at smaller intervals should be made with echocardiography or CMRI [67].

<ul style="list-style-type: none">• Coarctation of the Aorta• Turner Syndrome• Patent Ductus Arteriosus• William’s Syndrome• Ventricular Septal Defect• Shone’s Syndrome	<ul style="list-style-type: none">• Ascending Aortic Aneurysm• Coronary Artery Anomalies• Sinus of Valsalva Aneurysm• Supravalvular Aortic Stenosis• Aortic Dissection
---	--

Table 1. Known cardiovascular abnormalities related to BAV disease.

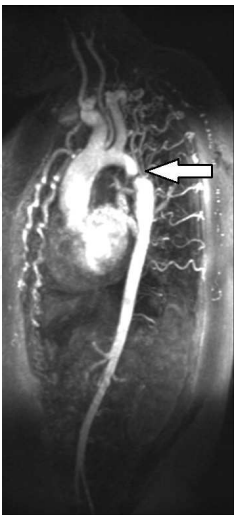


Figure 3. Sagittal plane cardiac magnetic resonance imaging illustrating coarctation of the aorta. Typical post ductal stenosis (arrow).

6. Diagnosis

6.1. Clinical examination

AS or AR can present themselves with significant symptoms in patients with BAV disease during activity, stress or rest including angina, shortness of breath, syncope or dizziness. In many cases, clinical examination reveals an ejection sound during auscultation at the apex. When AS is present, an ejection click can be often heard at the S1. The S2 is often simultaneously with P2 when AS is present. A diastolic murmur can often be heard when an AR is present. Heart failure of unknown cause could also be present during clinical examination. The ejection sound in BAV patients is most likely associated with anterior movement of the dome shaped BAV, and in rare cases heart failure could also be present during clinical examination in case of rapid deterioration [55]. AS, mitral valve prolapsed, AR, and COA are several associated pathological findings which have to be considered with BAV when a murmur is present.

6.2. Echocardiography

The current golden standards for diagnosing, surveilling and monitoring BAV disease are echocardiography and cardiac magnetic resonance imaging (CMRI) [39].

Both transthoracic echocardiography (TTE) and transesophageal echocardiography (TEE) can be used in the diagnosis of BAV disease. TTE has a sensitivity of 78% to 87% and a specificity of 91% to 96% for the diagnosis of BAV disease whereas TEE has a sensitivity and specificity of 87% and 96%, respectively [56, 57, 58]. However, up to 25% of TTE have non-diagnostic findings for aortic valve morphology due to severe valvular calcification [57].

The features of BAV on a TTE include systolic doming, an eccentric closure line in the parasternal long axis views, presence of a single commissural line in the diastolic phase with the occurrence of two cusps and the occurrence of two commisures in the parasternal short axis views [figure 4] [59, 60].

Moreover, both preoperative echocardiography and intraoperative TEE are essential for surgical preparation. When BAV disease is present, the degree of AS and AR should be determined with the help of Doppler analysis. After determining the severity of the AR, to ascertain the indication for surgery, especially TEE is needed to clarify the mechanisms that are responsible for AR. This is required to estimate the chance of successful repair and indispensable in surgical preparation. Moreover, any associated cardiovascular abnormalities or complications should be considered. Aortic diameters should therefore also be measured at several levels including valvular insertion, sinuses of Valsalva, sino-tubular junction and the ascending aorta. It should also be noted that in order to measure the severity of the AS by echocardiography- Doppler analysis, the aortic valve area and mean gradient should be applied rather than measuring only on peak systolic gradient, sequentially to prevent overestimation of the severity of the AS [39]. Also, aortic valve area should always be indexed to body surface area in order to correct for different habitus and body sizes, especially in Turner Syndrome patients [39, 54].

6.3. Cardiac magnetic resolution imaging

CMRI as a noninvasive diagnostic tool appears to have a high diagnostic sensitivity and specificity. CMRI showed a sensitivity of 100% and a specificity of 95% with steady state free-precession (SSFP) cine [61]. It seems that CMRI is more reliable than the standard TTE in diagnosing BAV [Figure 5]. When TTE is found to be non-diagnostic for aortic valve morphology, particularly in patients with severe AS, CMRI can be conducted as a complementary test [62].

When the diagnostic results of AR with the use of echocardiography is indefinite or at borderline, CMRI can be used to quantify the AR more accurately [39]. In addition, the valve can be visualized with any correlated lesion of the ascending aorta. This could be used for proper evaluation of the entire aortic and to prepare complex surgical interventions for both the aorta valve and the surrounding cardiovascular structures including the ascending aorta and the aortic root. Of importance, all patients with evidence of BAV should have the aortic root and ascending aorta inspected for indication of aortic dilatation with echocardiography or MRI [67].

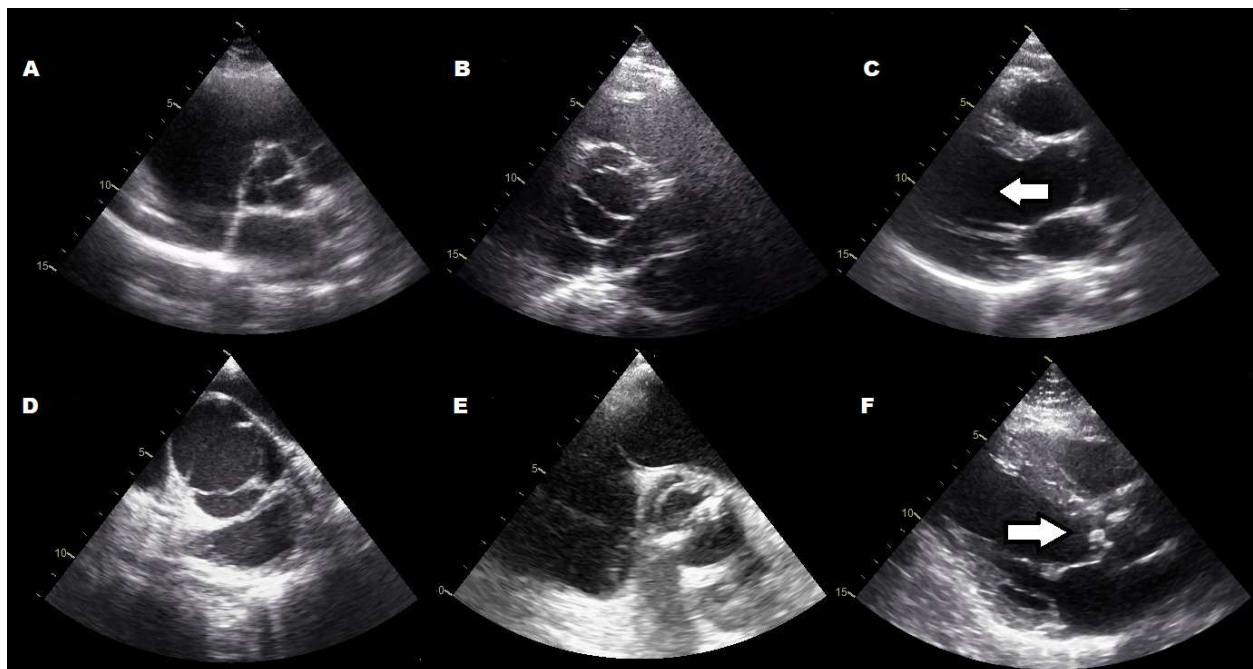


Figure 4. (A) Transthoracic echocardiography short axis view illustrating a normal tricuspid aortic valve. (B) Transthoracic echocardiography short axis view illustrating a bicuspid aortic valve with fusion of the left and right coronary cusps. (C) Transthoracic echocardiography long axis view illustrating a dilated ascending aorta (Arrow). (D) Transthoracic echocardiography short axis view illustrating a bicuspid aortic valve with fusion of the right and non coronary coronary cusps. (E) Transthoracic echocardiography short axis view illustrating a severe calcified bicuspid aortic valve with fusion of the right and non coronary coronary cusps. (F) Transthoracic echocardiography long axis view illustrating a severe calcified bicuspid aortic valve.

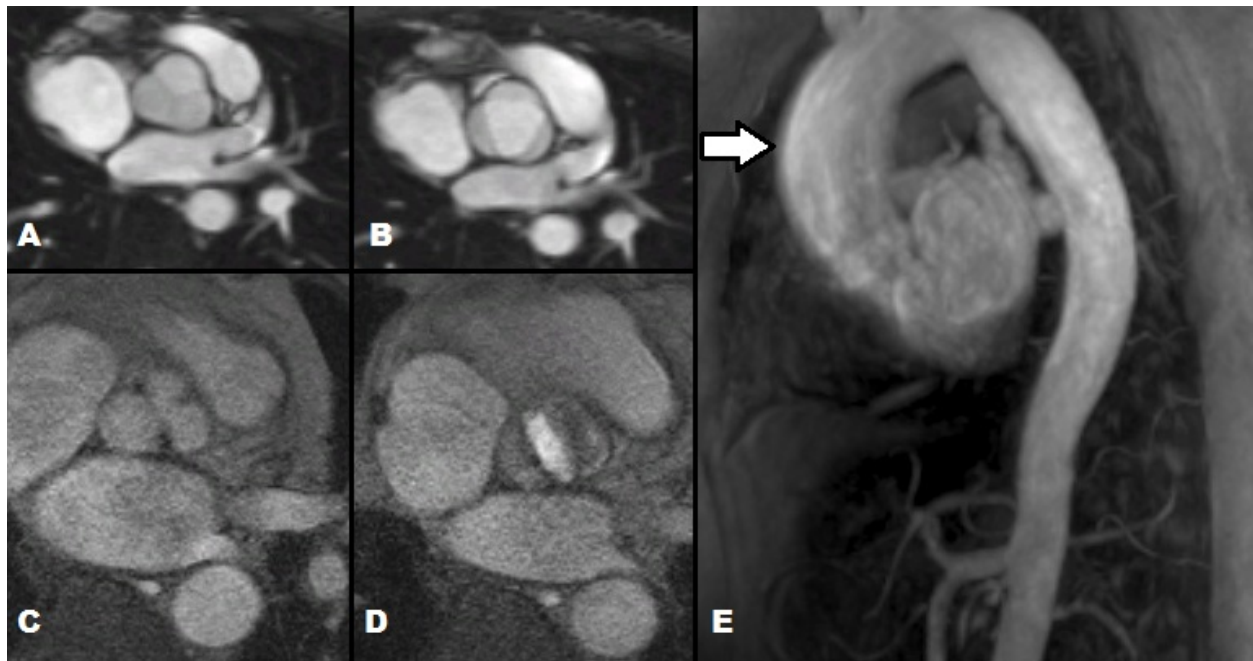


Figure 5. Panel (A, B) Cardiac magnetic resonance imaging in the axial plane illustrating a normal tricuspid valve in the diastolic (A) and systolic phase (B). (Panel C, D) Bicuspid aortic valve with fusion of the right coronary cusp and the non coronary cusp in the diastolic (C) and systolic (D) phase. (Panel E) Sagittal plane illustrating a dilatation of the ascending aorta (Arrow).

7. Complications associated with BAV

7.1. Aortic stenosis

Up to 50% of the adults who present with AS show evidence of BAV disease [71]. BAV degeneration is due to both fibrosis and calcification and is age related [16, 72, 73]. Additionally, the incidence of BAV related AS that is observed in patients with the age of under 60 years, 60 to 75 years, and more than 75 years are 59%, 40% and 32%, respectively [74].

Patients with BAV generally require AVR 5 years earlier compared with the patients who have an AS of the tricuspid valve [75]. Three-quarters of the patient with BAV who underwent AVR showed to have an isolated AS [7]. Both fibrosis and cusp calcifications occur in an accelerated pattern in BAV compared with tricuspid aortic valve [Figure 4, E &F] [76]. Moreover, several valve related factors seem to accelerate the calcification in BAV including larger sized cusp, presence of raphé and the overall BAV anatomy. It seems that sclerosis of the aortic valve starts in the second decade whereas calcification tends to develop around the fourth decade onwards with a 18 mmHg per decade increase of the average aortic valve gradient [75, 12]. Both R-N BAVs and asymmetrical sized cusps seem to contribute to the acceleration of the stenosis due to the progressive calcification and fibrosis with 27 mm Hg per decade [9, 45, 12]. It has to be noted that smoking and a poor lipid panel are both modifiable independent risk factors that could have a great impact on BAV degeneration [77]. In children, BAV with stenosis can

sometimes be treated with balloon valvuloplasty whereas in other cases surgical commissurotomy is indicated [75, 78-80]. Severe fibrosis of the cusp tissue and calcified degeneration, which is found in the older population, make surgical repair difficult or impossible in most cases. AVR is therefore the primary surgical treatment of BAV with severe stenosis in adults.

7.2. Aortic regurgitation

AR most often involves patients with a young age and is less frequently seen than AS with prevalence ranging from 7% to 20% [15, 78, 81, 82]. AR can occur in the isolated form due to the prolapse of one of the cusps, but it could also occur due to and in combination with endocarditis, COA, and proximal aortic root dilatation [16, 25]. The presence of AR could have severe consequences for the patient's morbidity including the increased risk of heart failure, endocarditis and arrhythmia [80]. Aortic root dilatation is found in nearly half of the young adults with BAV disease, thus increasing the risk for AR [83]. In selected cases, patients with BAV disease and isolated AR can be a candidate for aortic valve repair [84].

7.3. Aortic dilatation and dissection

BAV disease is linked with dilatation of the proximal aortic root and ascending aorta and develops independently from stenotic or regurgitant aortic valvular lesions [91]. This process eventually leads to dissection or rupture of the aortic wall with potentially fatal consequences. Several molecular pathways have been discovered, possibly of genetic basis, which suggest that histopathologic modifications in the extracellular matrix of the dilated proximal aortic wall are a key pathogenesis of aortic dilatation in BAV patients. This includes the loss of smooth muscle cells, cystic medial necrosis and elastic fibre fragmentation [92, 93]. Furthermore, morphometric analysis of the aortic media showed deformities of the elastic lamellae and less elastic tissue in BAV patients in comparison with patients with tricuspid aortic valves [93, 94]. It appears that apoptosis is a key mechanism for the loss of the smooth muscle cells in the ascending aorta of BAV patients which can eventually lead to cardiovascular complications [95, 96, 97]. In addition, regarding the remodeling of the extracellular matrix, fibrillin-1 microfibrils were significantly reduced while the matrix metalloproteinase-2 and -9 activities were significantly increased in the aortic media of BAV patients. When fibrillin-1 deficiency is present, the release of enzymes, also known as matrix metalloproteinases, will increase and weaken the aortic wall by degrading elastic matrix components, thus resulting in aortic dilatation and degeneration [98, 99, 100].

Approximately 40% of the BAV cases develop proximal aortic root dilatation while an estimation of 6% lifetime risk is observed for aortic dissection [101].

Risk factors for developing an adverse aortic complications such as rupture or dissection in BAV patients include positive family history of aortic aneurism, dilatation of the sinotubular junction, the presence of AR, young age (<40 years), and aortic dilatation greater than 50 mm [101, 102]. Aortic dissection occurs most commonly in young adults with an asymptomatic medical history of BAV. A severe risk for aortic dissection is present when the aortic diameter surpasses 50 mm. [102]. When BAV is present in combination with aortic dilatation, the risk

of aortic dissection is increased 9 fold compared with tricuspid valve cases [16]. Additionally, the area of the aortic dilation also varies among BAV patients. Some patients have a dilatation of the proximal ascending aorta dilation, while others have a dilation of the sinuses of Valsalva and yet other patients present with a dilatation of the transverse arch or a combination of these locations [103].

Aortic dilatation of the sinuses of Valsalva is often seen in patients with L-R BAV, whereas patients with R-N BAV present with the dilatation of the ascending aorta [10]. Of note, aortic dilatation and thoracic aortic aneurysm formation could also occur in BAV patients or related family members with the absence of significant valve pathology in the form of AS or AR [51, 68].

7.4. Infective endocarditis

Infective endocarditis is a condition high risk on mortality and morbidity which effects 10% to 30% of the BAV patients with actual risk assessment of 0.3% to 2% per patient-years in adults. Although these estimations are based on selected cases, the true incidence of BAV related infective endocarditis is most likely lower. [16, 85, 86]. Moreover, one-fourth of the infective endocarditis cases are a complication due to BAV. Infective endocarditis is frequently seen in young adults and adolescents rather than in elderly patients, particularly the male gender [16]. Almost three-quarters of the endocarditis related BAV cases are caused by *Viridans streptococci* and *Staphylococci* [87]. Poor dental hygiene, presence of a dialysis shunt and venous catheters are major independent risk factors for developing infective endocarditis due to the high risk of contamination [88]. Several complications due to infective endocarditis in BAV patient can occur including heart failure, the formation of myocardial or valvular abscess, and mortality within 6 month after hospital admission [89]. Antibiotic prophylaxis is nowadays no longer recommended for patients with BAV and with calcified aortic stenosis, except in BAV patients with a prior history of infective endocarditis, prosthetic heart valves, or prosthetic material used for heart valve repair [90].

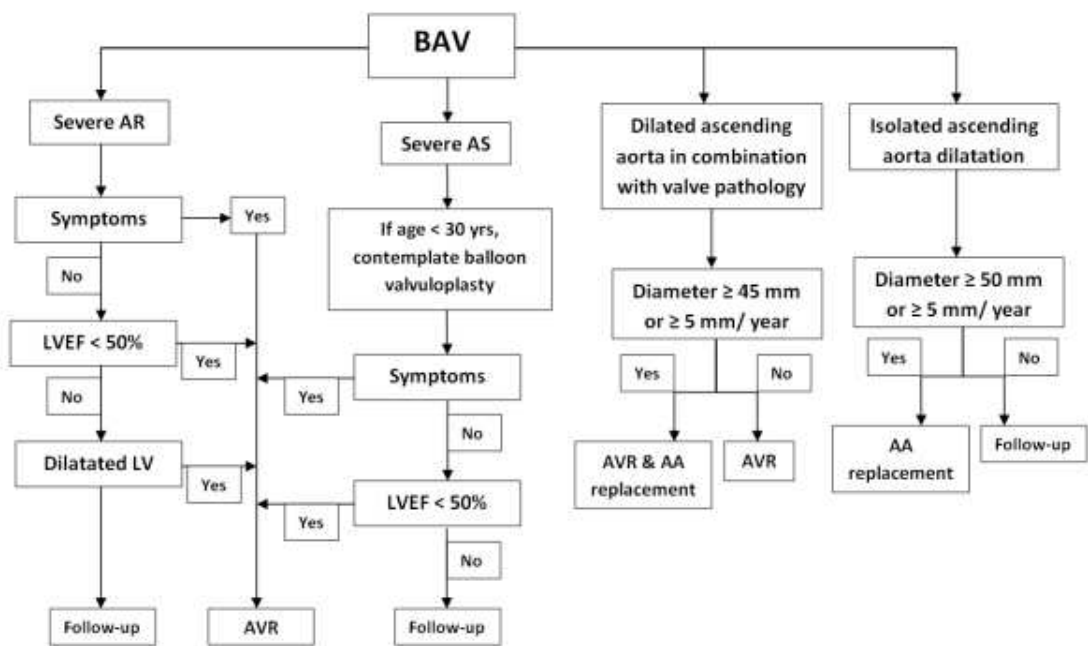
8. Interventions

Surgical intervention is the key treatment option for patients with symptomatic BAV disease and the related aortic dilatation. Several factors are dependent on the surgical treatment management including the location and the severity of the aortic dilatation and the performance status of BAV.

8.1. Surgical indications for aortic valve repair/replacement

Surgical intervention for patients with BAV disease occurs at a relative earlier age than for degenerative tricuspid aortic valve disease [71]. In a study of 212 asymptomatic community residents, an average age for surgical intervention was reported for BAV disease versus degenerative tricuspid valve disease of 40 ± 20 years and 67 ± 16 years, respectively [85]. In Scheme 1, indications for surgical intervention in patients with BAV disease including AR, AS and/or proximal ascending aorta dilation are described. In adults with BAV disease, surgical

intervention in the form of AVR is recommended when severe AS, chronic AR and left ventricle dysfunction (LV) with a LV ejection fraction (EF) of < 50% is present. Furthermore, adolescents and young adults with severe AR who have developing symptoms, persistent LV dysfunction with LV EF < 50%, or progressive LV dilatation, are also suitable candidates for AVR [39]. Several factors has to be kept in mind when choosing a patient tailored intervention namely, the risk for reoperation with bioprosthetic valves due to valve degeneration, and the necessity of lifelong anticoagulation with mechanical valve replacement. In athletic patients, bleeding risks due to chronic use of anticoagulation should be discussed, as well as the potential risk of teratogenic dangers of warfarine for women who desire pregnancy in the future. The discussion of the risk and benefits for both procedures is therefore mandatory.



Scheme 1. Indication for cardiac surgical intervention in patients with bicuspid aortic valve disease including aortic regurgitation (AR), aortic stenosis (AS), and/or aortic dilatation. LVEF = left ventricle ejection fraction; LV dilatation = Left ventricle dilatation (End-systolic diameter > 55mm or end-diastolic diameter > 75 mm); Clinical symptoms include dyspnoea, angina, or syncope; Severe AS = jet velocity > 4 m/s, mean gradient. 40 mm Hg, valve area < 1 cm²; severe AR = jet width < 65% of LOVT, vena contracta width > 0.6 cm, regurgitant volume > 60 mL, regurgitant fraction > 60%, regurgitant orifice area >0.3 cm². AVR = aortic valve replacement (Data derived from Bonow *et al.* [39]).

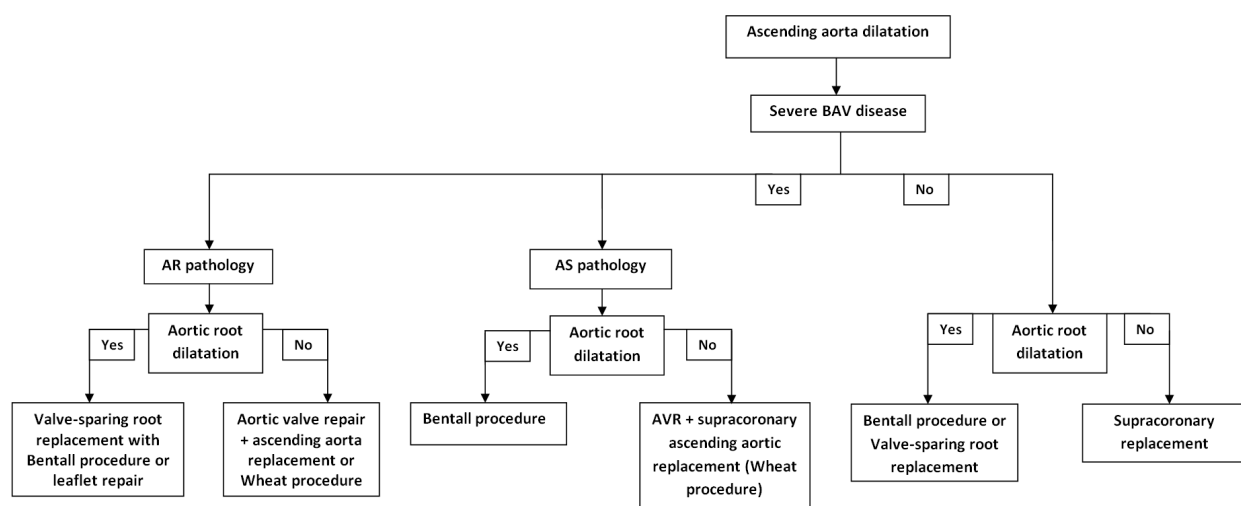
8.2. Surgical indications for ascending aorta dilation

As mentioned earlier, BAV disease is associated with aortic dilatation. BAV patients with the presence of AR or AS should receive surgical intervention of the ascending aorta when an aortic diameter of ≥ 45 mm is present. Conversely, BAV patients with absence of additional risk factors and co morbidities should receive surgical intervention at an aortic root or ascending aorta dilatation of ≥ 50 mm or a aortic dilatation expansion rate of ≥ 5 mm per year [39]. However, it seems that aortic size relative to body size could be a more superior novel technique to define high risk patients requiring surgical intervention [104]. Proper routine

evaluation of the aortic root and ascending aorta is therefore mandatory in patients with BAV with echocardiography or MRI to determine the potential presence of an aortic dilatation [67].

8.3. Pharmacological treatment options

Systematic high blood pressure is an independent risk factor for developing complications including aorta dissection in patients with stenotic BAV with aortic root dilatation. B-blocker therapy is therefore advisable for patients with BAV disease [39]. Moreover, osteogenic and proteolytic activities, which is a precursor to atherosclerotic and calcified degenerative AS, have been revealed in early aortic valve disease with the use of multimodality molecular imaging [115]. However, lipid lowering therapy didn't reduce calcific valve progression with respect to moderate to severe AS [116, 134]. Although, little evidence have acknowledged the beneficial use of statins in BAV disease, patients with BAV disease who have risk factors for atherosclerosis should receive statins with the purpose of reducing the degenerative risk in the aorta and potentially preventing atherosclerosis. Long-term vasodilator therapy is only recommended in BAV patients with AR if systematic hypertension is present [39]. Despite this, there is currently no concrete evidence suggesting that pharmacological treatments could alter the natural history or halt the development BAV calcification.



Scheme 2. Cardiac surgical options for aortic dilatation in patients with bicuspid aortic valve disease. AR = aortic regurgitation, AS = Aortic stenosis.

8.4. Surgical options

The surgical options are illustrated in Scheme 2 for BAV disease with aortic dilatation. When patients require an intervention of the aortic valve with an aortic diameter < 45 mm, the main surgical option is a bioprosthetic AVR, mechanical AVR, the Ross procedure which is contra-indicated in older patients with BAV and onset of aortic dilatation, or aortic valve repair in selected cases of AR. In patients with > 45 mm ascending aorta root dilatation with significant

aortic valve pathology, aortic root replacement therapy, (Bentall procedure) is the main surgical option.

8.5. Valve repair

Surgical repair can be considered when BAV disease is presented without any significant signs of calcification or valve thickening [105]. Several surgical repair options are available including raphé resection with or without leaflet placcation, shortening or reinforcement of the free margin, augmentation of the pericardial patch cusp, aortic root repair, and subcommissural annuloplasty [105, 106]. Patients with BAV disease show evidence of sclerosis after the second decade and calcification associated with increasing stenosis at the fourth decade [12, 75]. This raises the question with respect to valve sparing replacement of a dilated aorta, especially in young patients. Although, it appears that the need for reoperation is greater in the surgical repair group for AR, this surgical option still remains attractive in both young adults with AR and women with BAV disease who want to become pregnant.

8.6. Ross procedure

The Ross procedure, also known as the pulmonary autograft, is a cardiac surgical procedure in which the pathological aortic valve is replaced with a patient's own pulmonary valve after which a pulmonary allograft is performed with a valve from a donor which is then used to substitute the patient's own pulmonary valve. Several benefits have been reported with the Ross procedure including the absence of anticoagulation, reduced endocarditis risk, and encouraging valve hemodynamic gradients [107]. However, major concerns have been raised including the most important concern regarding the durability of the autograft and allograft. In addition, another key concern is that histopathologic alterations of the pulmonary trunk may occur, after which the pulmonary trunk can show resemblances of the proximal aorta, thus increasing the risk for aortic aneurysms with a reoperation being the most likely end result [108]. The Ross procedure has no beneficial benefits over conventional AVR in adult patients with respect to hemodynamics or postoperative outcomes. Nevertheless, the Ross procedure offers adolescents, young adults and women with BAV disease who want to become pregnant, an adequate solution in the first decade after the operation. However, limitation with respect to the durability is evident by the end of the first postoperative decade, especially in younger patients [109]. Ross procedure in the setting of BAV disease still remains controversial and should only be performed in selected cases in specialized centres.

8.7. Bentall procedure

Due to the risk of aortic dilatation in patients with BAV disease, the majority of the surgeons evaluate the option of reinforcing or replace the ascending aorta with at the time of the valve surgery. The Bentall procedure is a widely used surgical procedure for patients with BAV and aortic root dilatation. This procedure includes the replacement of the aortic valve, aortic root and ascending aorta with the reimplantation of the coronary arteries [110]. Excellent long-term results have been observed with the Bentall procedure with respect to survival in patients with aortic valve disease and aorta dilatation [111]. This procedure is a suitable intervention in older

patients with severe BAV pathology with normal-sized sinuses and dilatation of the supra-coronary ascending aorta.

8.8. Yacoub and David procedure

Valve sparing aortic root replacement procedure may be an alternative to Bentall procedures in selected BAV patients such as young adults who present with aortic root lesion with normally functioning aortic valve including the absence of calcified aortic valves, multileaflet prolapsed and annular dilatation [112]. Two variations for this procedure have been described namely the remodeling (Yacoub) procedure and the re-implantation (David) procedure [113, 114]. The coronary artery ostia are removed as buttons in both procedures followed by reimplantation of a Dacron aortic graft with additional leaflet repair, if required. However, in the David procedure, the aortic root is mobilized to below the plane of the ventriculo-aortic junction followed by a Dacron graft replacement which is telescoped down outside the aortic root to provide a functional aortic annuloplasty. It seems that there is no significant difference between these two procedures in BAV patients. Valve sparing procedures are more surgically challenging than the traditional Bentall procedure and are only conducted in specialized aortic centres. When tubular ascending aorta dilatation is present with no root or valve pathology, supracoronary ascending aortic replacement is required in BAV patients. When valve pathology is present with this anatomical lesion, a Wheat procedure should be preformed. This procedure includes separate AVR or repair leaving the sinus segment intact. However, due to the fact that in most cases sclerosis of the aortic valve starts in the second decade and calcification begins to develop around the fourth decade, serious consideration have to be made with respect to valve-sparing replacement of a dilated aorta in young adults with normally functioning BAV [12, 75].

8.9. Balloon valvuloplasty

Due to the growth of adolescents during childhood, prosthetic valve insertion is unsatisfactory. Balloon valvuloplasty is therefore a successful treatment option because of the fact the aortic valve is not calcified at this age of the child and the fact that valvuloplasty disrupts the commissural fusion and reduces the obstruction when implemented. Balloon valvuloplasty is indicated in young adults and adolescents without significantly calcified BAV and no AR who experience symptoms with a peak-to-peak gradients of > 50 mm Hg. Also, asymptomatic adolescents who develop ST- or T wave changes with exercise or rest or demonstrate a peak-to-peak gradient of > 60 mm Hg should be considered candidates for balloon valvuloplasty. Additional indications for balloon valvuloplasty are asymptomatic adolescent or young adult who are interested in sport activities or becoming pregnant with a peak-to-peak gradient > 50 mm Hg. When severe AR is evident after balloon valvuloplasty, AVR should be considered. Conversely, valvuloplasty is seldom performed in old adults due to often severe calcification of the aortic valve [39, 86]. However, balloon valvuloplasty should be considered as a bridge to surgery in adults with AS who have a high risk for AVR, who are hemodynamically unstable, or when AVR is not possible to perform due to secondary co morbidities. Excellent mid-term results have been observed after balloon valvuloplasty at experienced centres [117-119].

8.10. Transcatheter aortic valve implantation

Transcatheter aortic valve implantation (TAVI) is a novel minimally invasive technique indicated for patients who are contraindicated for cardiac surgery due to associated comorbidities or who have a high risk of perioperative mortality. TAVI is an alternative treatment for patients with valve disease in which a valve replacement is introduced through the femoral artery via a small incision or in some cases, an incision into the chest after which the catheter is inserted into the left ventricular apex, also known as the transapical approach. Other methods include subclavian in which the catheter is inserted beneath the collar bone and direct aortic incision in which the catheter is inserted directly into the aorta via a minimally invasive incision in the chest [120]. Due to the asymmetric anatomy which is observed with BAV disease, the TAVI device could potentially be affected to a noncircular expansion, thus creating an elevated risk of paravalvular leak [121]. Due to this major concern, BAV is considered a contraindication with respect to TAVI. BAV have been overall excluded in all the major TAVI trials in which little clinical experience is now known with regard to TAVI in BAV cases. However, several centres showed acceptable results in selected BAV patients with AS [121-123]. A high risk of suboptimal device seating has been observed in BAV patients with asymmetric valvular anatomy, AR, and bulky leaflets. Whether novel valve designs could improve TAVI performance in the BAV group, still remains uncertain.

9. Surveillance

All patients with BAV disease whether AS, AR, operated or not, should receive lifelong serial follow-up depending on symptoms and degree of the functional disorder. Moreover, serial follow-up with imaging assessment with respect to the cardiac and aortic anatomy including valve function, LV function, diameter of both ascending aorta, sinotubular junction, sinuses of Valsalva and the annulus should be performed in BAV patients regardless the severity of the pathology. TTE is a reliable diagnostic tool to monitor the aortic valve and ascending aorta. However, it should be noted that it is difficult to obtain adequate imaging with the TTE regarding the mid and distal ascending aorta and arch, especially in BAV patients with large body index, in which MRI or CT scan should be used.

The occurrence of imaging should depend on the size of the aortic root at the initial assessment. If the aortic root is < 40 mm with no clinical symptom alternations, the ascending aorta should be reimaged every 2 years. Whereas, if the aortic root is ≥ 40 mm, it should be reimaged annually or even more often if progression of the aortic root dilatation is present or whenever a change in clinical symptoms and/or findings occur with echocardiography or MRI [39]. Also of importance, first degree family members of patients with BAV disease should receive echocardiographic screening due to the increased risk of cardiovascular abnormalities [39].

10. Sport participation

The vast majority of young adults with BAV disease are asymptomatic. Little is known regarding the risks of aortic dissection and sudden cardiac death in young adults with BAV who participate in athletic activity. Also, the severity of the valve pathology and aortic root dilatation in this subgroup of BAV patients influence the clinical decision making with respect to strategy and recommendations for sport activity.

No restrictions are necessary with respect to BAV patients with an athletic lifestyle who present with a mild AS. However, asymptomatic BAV patients with moderate AS can only conduct low-intensity athletic competitive activities. Exercise stress testing is mandatory for BAV patients with moderate AS to detect any additional risk factors including unusual blood pressure during exercise, onset of symptoms during exercise or pathological arrhythmias, which could eventually alter the clinical strategy and recommendations. In addition, BAV patients with symptomatic moderate or severe AS should receive immediate surgical intervention and should therefore not participate in any form of competitive sport activities upon surgery [124].

BAV patients with mild enlargement of the left ventricular end-diastolic dimension and mild to moderate AR have no restriction in participating in all forms of athletic activity. Also in this case, an exercise stress testing should be performed to estimate the risk. Patients with BAV disease who have a definite LV enlargement of ≥ 60 mm, pulmonary hypertension, or any degree of LV systolic dysfunction at rest should avoid any form of competitive sport activities [124]. BAV patients who underwent an AVR should avoid any form of contact sport.

Also, BAV patients with severe AR and left ventricular end-diastolic diameter > 65 mm should avoid any form of competitive sport activities. This also includes BAV patients with mild-to-moderate AR associated with positive symptoms for valve disease [124]. Young adults with uncalcified AS with a peak-to-peak gradient > 50 mm Hg should who play competitive sports are candidates for aortic balloon valvuloplasty [39]. The recommendation for sport activity for BAV patients with respect to dilatation of the proximal aortic root depends on the level of severity the aortic dilatation. BAV patients with an aortic root diameter of 40 to 45 mm should only perform low to moderate intensity sport activity and preferably avoid any form of contact sport. Moreover, BAV patients with an aortic root diameter of > 45 mm are allowed to conduct low-intensity sport activity due to due to the potential risk of aortic root dissection [125].

11. Pregnancy

Although, the vast majority of pregnancies with congenital AS go through labour uncomplicated, some pregnancies with severe AS have a higher risk rate of morbidity, although the mortality rates still remains rare [126, 127].

Severe AS is not well tolerated in pregnant women and is associated with high peripartum complications [75]. Around one-third of the pregnant women with maternal congenital AS showed clinical complications with a significant rate of abortion [128]. Of note, it is recommended that women with AS who are considering becoming pregnant receive pre-pregnancy counselling [39].

Nevertheless, mild-to-moderate AS is well tolerated by pregnant women and show no complications with respect to labour compared to pregnant women with severe AS who had a deterioration rate of 10% [126].

Asymptomatic severe AR is well endured by pregnant women unlike severe AS [129]. A possible explanation for this phenomenon is because of pregnancy related physiologic changes which presents with an afterload decrease and heart rate increase with a shortening of the diastole, thus reducing the level of AR.

Of note, several recommendations has to be considered in pregnant women with severe BAV pathology with symptoms including pre-pregnancy counselling, foetal echocardiography during the second trimester to investigate whether cardiac defects is present in the foetus, and close cardiac follow-up in the form of echocardiography to monitor changes in symptoms and further valve deterioration [39]. Several side effects have been reported when cardiac surgery requiring cardiopulmonary bypass is used including the potential risk of fetal distress, fetal wastage and growth retardation [130, 131]. Therefore, it should be noted that women with a high risk for complications during pregnancy should abstain from pregnancy until the valve pathology is properly surgically treated [124]. Moreover, parents should receive proper clinical counselling with respect to the genetic predisposition and the risk of congenital cardiac defect in their children [132].

Encouraging results have been observed with the balloon valvuloplasty during pregnancy including successful completion of the pregnancy [133]. However, concerns have been raised regarding symptomatic AR after balloon valvuloplasty which is also a burden for pregnant patients. Therefore, balloon valvuloplasty should be considered as a bridge to surgery in pregnant women with severe AS. When an unplanned pregnancy occurs in women with severe aortic pathology with symptoms, physical restriction with close cardiac follow-up are obligated. Furthermore, vasodilatation and volume depletion medicine should be avoided at all time. Due to the compression of the inferior vena cava by the gravid uterus, it is recommended that the delivery should be performed in the left lateral decubitus position.

12. Conclusion

BAV disease is a frequently seen congenital cardiac defect, complicated with proximal thoracic aortic aneurysm and associated with other cardiovascular malformations including Turner Syndrome and COA. Although little is known about the pathogenesis of BAV dis-

ease, it seems that BAV disease is linked with both genetic predisposition and defects in the early valvulogenesis. Further investigation is required with respect to the basic genetic and embryological defects associated with BAV disease and the proximal aortic dilatation including the cellular mechanisms and signalling pathways. This will give us more understanding regarding the background of the degeneration and calcification of the bicuspid valve, and the development of aortic aneurysm. This could offer new pharmacological targets to prevent calcification, degeneration and aortic dilatation.

The dilatation of the proximal thoracic aorta may lead to complications including ascending aortic aneurysm and dissection. Early detection, vigilant patient assessment and frequent follow-up by imaging including echocardiography, CT and CMRI can potentially persevere both long-term survival and quality of life in patients affected by BAV disease.

Several interventional options are available for patients with BAV disease and aortic dilatation. Balloon valvuloplasty is indicated in young adults and adolescents without significantly BAV calcification. Surgical repair (Yacoub and David procedure) should be considered when BAV disease is presented without any significant signs of calcification or valve thickening. In contrast, when calcified BAV disease is present, AVR, Bentall procedure or Ross procedure is necessary. Although in some cases these procedures are performed in valves without calcification. TAVI is relatively contraindicated due to the asymmetric anatomy which is observed patients with BAV disease. The TAVI device could potentially be affected to a noncircular expansion with the risk of paravalvular leak. BAV patients were excluded in the major TAVI studies. Future research should focus on novel valve designs.

Despite the fact that limited data exist with respect to prophylactic interventions, BAV disease associated aortic dilatation with absence of additional risk factors and co morbidities is indicated when the diameter is ≥ 50 mm or an aortic dilatation expansion rate of ≥ 5 mm per year. In patients with BAV disease with additional risk factors, such as COA, Turner Syndrome and a family history of aortic dissection, replacement should be considered when a diameter of ≥ 45 mm is present. Patients with symptoms of BAV disease due to AR or AS, or asymptomatic LV dysfunction all require surgery. If the ascending aorta exceeds 45 mm, the root should be replaced as well. Valve sparing aortic root replacement procedure is recommended in young patients who present with aortic root lesion with normally functioning aortic valve including the absence of calcified aortic valves, multileaflet prolapsed and annular dilatation. Future studies are mandatory, not only to predict the optimal timing for AVR when symptoms occur, but also to investigate whether prophylactic intervention of the ascending aorta at the time of AVR is necessary. Also, additional studies are required to determine the risks factors for aortic dissection and the optimal diameter at which replacement of the ascending aorta should be performed in patients with BAV disease. Future studies should also focus on sudden cardiac death in young adults with BAV disease who participate in athletic activity.

Author details

George Tokmaji¹, Berto J. Bouma², Dave R. Koolbergen^{1,3} and Bas A.J.M. de Mol¹

1 Department of Cardiothoracic Surgery, Academic Medical Center, Amsterdam, The Netherlands

2 Department of Cardiology, Academic Medical Center, Amsterdam, The Netherlands

3 Department of Cardiothoracic Surgery, Leiden University Medical Center, Leiden, The Netherlands

References

- [1] Tadros TM, Klein MD, Shapira OM. Ascending aortic dilatation associated with bicuspid aortic valve. Pathophysiology, molecular biology, and clinical implications. *Circulation* 2009;119:880-890.
- [2] Nistri S, Basso C, Marzari C, et al. Frequency of bicuspid aortic valve in young male conscripts by echocardiogram. *Am J Cardiol.* 2005;96:718-21.
- [3] Tutar E, Ekici F, Atalay S, et al. The prevalence of bicuspid aortic valve in newborns by echocardiographic screening. *Am Heart J.* 2005;150:513-5.
- [4] Basso C, Boschello M, Perrone C, et al. An echocardiographic survey of primary school children for bicuspid aortic valve. *Am J Cardiol.* 2004;93:661-3.
- [5] Yener N, Oktar GL, Erer D, Yardimci MM, Yener A. Bicuspid aortic valve. *Ann Thorac Cardiovasc Surg* 2002;8:264-7.
- [6] Roberts WC. The congenitally bicuspid aortic valve. A study of 85 autopsy cases. *Am J Cardiol.* 1970;26 (1):72-83.
- [7] Sabet HY, Edwards WD, Tazelaar HD, Daly RC. Congenitally bicuspid aortic valves: a surgical pathology study of 542 cases (1991 through 1996) and a literature review of 2,715 additional cases. *Mayo Clin Proc.* 1999;74(1):14-26.
- [8] Sievers HH, Schmidtke C. A classification system for the bicuspid aortic valve from 304 surgical specimens. *J Thorac Cardiovasc Surg.* 2007;133(5):1226-33.
- [9] Fernandes SM, Sanders SP, Khairy P, Jenkins KJ, Gauvreau K, Lang P, et al. Morphology of bicuspid aortic valve in children and adolescents. *J Am Coll Cardiol.* 2004;44(8):1648-51.

- [10] Schaefer BM, Lewin MB, Stout KK, Gill E, Prueitt A, Byers PH, et al. The bicuspid aortic valve: an integrated phenotypic classification of leaflet morphology and aortic root shape. *Heart*. 2008;94(12):1634–8.
- [11] Russo CF, Cannata A, Lanfranconi M, Vitali E, Garatti A, Bonacina E. Is aortic wall degeneration related to bicuspid aortic valve anatomy in patients with valvular disease? *J Thorac Cardiovasc Surg*. 2008;136(4):937–42.
- [12] Beppu S, Suzuki S, Matsuda H, et al. Rapidity of progression of aortic stenosis in patients with congenital bicuspid aortic valve. *Am J Cardiol* 1993;71:322–7.
- [13] Mancuso D, Basso C, Cardaioli P, Thiene G. Clefted bicuspid aortic valve. *Cardiovasc Pathol* 2002; 11:217–220.
- [14] Peacock TB. *Valvular disease of the heart*. London: Churchill, 1865:2–33.
- [15] Olson LJ, Subramanian R, Edwards WD. Surgical pathology of pure aortic insufficiency: a study of 225 cases. *Mayo Clin Proc* 1984;59:835–41.
- [16] Ward C. Clinical significance of the bicuspid aortic valve. *Heart* 2000; 83:81–85.
- [17] Johnson AD, Detwiler JH, Higgins CB. Left coronary artery anatomy in patients with bicuspid aortic valves. *Br Heart J*. 1978;40(5):489–93.
- [18] Hutchins GM, Nazarian IH, Bulkley BH. Association of left dominant coronary arterial system with congenital bicuspid aortic valve. *Am J Cardiol*. 1978;42:57–9.
- [19] Higgins CB, Wexler L. Reversal of dominance of the coronary arterial system in isolated aortic stenosis and bicuspid aortic valve. *Circulation* 1975;52:292–6.
- [20] Murphy ES, Rosch J, Rahimtoola S. The frequency and significance of coronary arterial dominance in isolated aortic stenosis. *Am J Cardiol* 1977;39:505–9.
- [21] Roberts WC. The structure of the aortic valve in clinically isolated aortic stenosis. An autopsy of 162 patients over 15 years of age. *Circulation* 1970; 42:91–97.
- [22] Sans-Coma V, Fernandez B, Duran AC, Thiene G, Arque JM, Munoz-Chapuli R, Cardo M. Fusion of valve cushions as a key factor in the formation of congenital bicuspid aortic valves in Syrian hamsters. *Anat Rec* 1996; 244:490–498.
- [23] R. Abu-Issa and M. L. Kirby, “Heart field: from mesoderm to heart tube,” *Annual Review of Cell and Developmental Biology*, vol. 23, pp. 45–68, 2007.
- [24] R. R. Markwald, T. P. Fitzharris, and F. J. Manasek, “Structural development of endocardial cushions,” *American Journal of Anatomy*, vol. 148, no. 1, pp. 85–119, 1977.
- [25] A. D. Person, S. E. Klewer, and R. B. Runyan, “Cell biology of cardiac cushion development,” *International Review of Cytology*, vol. 243, pp. 287–335, 2005.
- [26] Duran AC, Frescura V, Sans-Coma V, et al. Bicuspid aortic valves in hearts with other congenital heart disease. *J Heart Valve Dis* 1995;4:581–90.

- [27] Fernández B, Fernandez MC, Durán AC, et al. Anatomy and formation of congenital bicuspid and quadricuspid pulmonary valves in Syrian hamsters. *Anat Rec* 1998;250:70-9.
- [28] Kappetein AP, Gittenberger-de Groot AC, Zwinderman AH, et al. The neural crest as a possible pathogenetic factor in coarctation of the aorta and bicuspid aortic valve. *J Thorac Cardiovasc Surg* 1991;102:830-6.
- [29] Schievink WI, Mokri B. Familial aorto-cervicocephalic arterial dissections and congenitally bicuspid aortic valve. *Stroke* 1995;26: 1935–40.
- [30] Schievink WI, Mokri B, Piepgras DG, Gittenberger-de Groot AC. Intracranial aneurysms and cervicocephalic arterial dissections associated with congenital heart disease. *Neurosurgery* 1996;39:685–9, discussion 689–90.
- [31] Lee TC, Zhao YD, Courtman DW, Stewart DJ. Abnormal aortic valve development in mice lacking endothelial nitric oxide synthase. *Circulation* 2000;101:2345–8.
- [32] Fernández B, Durán AC, Fernández-Gallego T, Fernández MC, Such M, Arqué JM, Sans-Coma V. Bicuspid aortic valves with different spatial orientations of the leaflets are distinct etiological entities. *J Am Coll Cardiol*. 2009 Dec 8;54(24):2312-8.
- [33] Glick BN, Roberts WC. Congenitally bicuspid aortic valve in multiple family members. *Am J Cardiol*. 1994 Feb 15;73(5):400-4.
- [34] Cripe L, Andelfinger G, Martin J, et al. Bicuspid aortic valve is heritable. *J Am Coll Cardiol*. 2004;44:138–43.
- [35] Huntington K, Hunter AG, Chan KL. A prospective study to assess the frequency of familial clustering of congenital bicuspid aortic valve. *J Am Coll Cardiol*. 1997;30:1809–12.
- [36] Martin LJ, Ramachandran V, Cripe LH, et al. Evidence in favor of linkage to human chromosomal regions 18q, 5q and 13q for bicuspid aortic valve and associated cardiovascular malformations. *Hum Genet*. 2007;121:275–84.
- [37] Garg V, Muth AN, Ransom JF, et al. Mutations in NOTCH 1 cause aortic valve disease. *Nature*. 2005;437:270–4.
- [38] Guo DC, Pannu H, Tran-Fadulu V, et al. Mutations in smooth muscle alpha-actin (ACTA2) lead to thoracic aortic aneurysms and dissections. *Nat Genet*. 2007;39:1488–93.
- [39] Warnes CA, Williams RG, Bashore TM, et al. ACC/AHA 2008 guidelines for the management of adults with congenital heart disease: a report of the American College of Cardiology/American Heart Association Task Force on Practice Guidelines (Writing Committee to Develop Guidelines on the Management of Adults With Congenital Heart Disease). *J Am Coll Cardiol* 2008;52:e1–121.

- [40] Bolling SF, Iannettoni MD, Dick M. Shone's anomaly: operative results and late outcome. *Ann Thorac Surg* 1990;49:887-93.
- [41] Oppenheimer-Dekker A, Gittenberger-de Groot AC, Bartelings MM. Abnormal architecture of the ventricles in hearts with an overriding aortic valve and a perimembranous ventricular septal defect. *Int J Cardiol* 1985;9:341-55.
- [42] Neumayer U, Stone S, Somerville J. Small ventricular septal defects in the adult. *Eur Heart J* 1998;9:1573-82.
- [43] Sugayama SM, Moises RL, Wagenfur J, Ikari NM, Abe KT, Leone C, et al. Williams-Beuren syndrome: cardiovascular abnormalities in 20 patients diagnosed with fluorescence in situ hybridization. *Arq Bras Cardiol*. 2003;81(5):462-73.
- [44] Oliver JM, Gallego P, Gonzalez A, et al. Risk factors for aortic complications in adults with coarctation of the aorta. *J Am Coll Cardiol* 2004;44:1641-7.
- [45] Kuboki K. Clinicopathologic study of congenital bicuspid aortic valve in the aged. *Cardio* 2000; 35:287-296.
- [46] Abbott ME. Coarctation of the aorta of adult type; statistical study and historical retrospect of 200 recorded cases with autopsy; of stenosis or obliteration of descending arch in subjects above age of two years. *Am Heart J* 1928;3:574.
- [47] Luijendijk P, Franken RJ, Vriend JW, Zwinderman AH, Vliegen HW, Winter MM, Groenink M, Bouma BJ, Mulder BJ. Increased risk for ascending aortic dilatation in patients with complex compared to simple aortic coarctation. *Int J Cardiol*. 2012 Feb 25
- [48] Attenhofer Jost CH, Schaff HV, Connolly HM, et al. Spectrum of reoperations after
- [49] air of aortic coarctation: importance of an individualized approach because of
- [50] xistent cardiovascular disease. *Mayo Clin Proc* 2002;77:646-53.
- [51] Roos-Hesselink JW, Scholzel BE, Heijdra RJ, et al. Aortic valve and aortic arch pathology after coarctation repair. *Heart* 2003;89:1074-7.
- [52] Miller MJ, Geffner ME, Lippe BM, et al. Echocardiography reveals a high incidence of bicuspid aortic valve in Turner syndrome. *J Pediatr* 1983;102:47-50.
- [53] Price WH, Clayton JF, Collyer S, et al. Mortality ratios, life expectancy, and causes of death in patients Turner's syndrome. *J Epidem Comm Health* 1986;40:97-102.
- [54] Matura LA, Ho VB, Rosing D, et al. Aortic dilation and dissection in Turner syndrome. *Circulation* 2007;116:1e7.
- [55] Perloff, JK. *The Clinical Recognition of Congenital Heart Disease*, 4th ed. Philadelphia, PA: W.B. Saunders, 1994.

- [56] Espinal M, Fuisz AR, Nanda NC, Aaluri SR, Mukhtar O, Sekar PC. Sensitivity and specificity of transeophageal echocardiography for determination of aortic valve morphology. *A Heart J*. 2000;139 (6):1071-6.
- [57] Brandenburg Jr RO, Tajik AJ, Edwards WD, Reeder GS, Shub C, Seward JB. Accuracy of 2-dimensional echocardiographic diagnosis of congenitally bicuspid aortic valve: echocardiographic-anatomic correlation in 115 patients. *Am J Cardiol*. 1983;51(9):1469-73.
- [58] Espinal M, Fuisz AR, Nanda NC, Aaluri SR, Mukhtar O, Sekar PC. Sensitivity and specificity of transesophageal echocardiography for determination of aortic valve morphology. *Am Heart J*. 2000;139 (6):1071-6.
- [59] Fowles RE, Martin RP, Abrams JM, et al. Two dimensional echocardiographic features of bicuspid aortic valve. *Chest* 1979;75:434-40.
- [60] Nanda NC, Gramiak R. Echocardiographic recognition of the congenital bicuspid aortic valve. *Circulation* 1974;49:870-5.
- [61] Gleeson TG, Mwangi I, Horgan SJ, Craddock A, Fitzpatrick P, Murray JG. Steady-state free-precession (SSFP) cine MRI in distinguishing normal and bicuspid aortic valves. *J Magn Reson Imaging*. 2008;28(4):873-8.
- [62] Malaisrie SC, Carr J, Mikati I, Rigolin V, Yip BK, Lapin B, McCarthy PM. Cardiac magnetic resonance imaging is more diagnostic than 2-dimensional echocardiography in determining the presence of bicuspid aortic valve. *J Thorac Cardiovasc Surg*. 2012 Aug;144(2):370-6.
- [63] McElhinney DB, Lock JE, Keane JF, et al. Left heart growth, function, and reintervention after balloon aortic valvuloplasty for neonatal aortic stenosis. *Circulation* 2005;111:451.
- [64] Maskatia SA, Ing FF, Justino H, et al. Twenty-five year experience with balloon aortic valvuloplasty for congenital aortic stenosis. *Am J Cardiol* 2011; 108:1024.
- [65] Rehnström P, Malm T, Jögi P, Fernlund E, Winberg P, Johansson J, Johansson S. Outcome of surgical commissurotomy for aortic valve stenosis in early infancy. *Ann Thorac Surg*. 2007 Aug;84(2):594-8.
- [66] Alexiou C, Langley SM, Dalrymple-Hay MJ, Salmon AP, Keeton BR, Haw MP, Monro JL. Open commissurotomy for critical isolated aortic stenosis in neonates. *Ann Thorac Surg*. 2001 Feb;71(2):489-93.
- [67] Hiratzka LF, Bakris GL, Beckman JA, et al. 2010 ACCF/AHA/AATS/ACR/ASA/SCA/SCAI/SIR/STS/SVM Guidelines for the diagnosis and management of patients with thoracic aortic disease. A Report of the American College of Cardiology Foundation/American Heart Association Task Force on Practice Guidelines, American Association for Thoracic Surgery, American College of Radiology, American Stroke Association, Society of Cardiovascular Anesthesiologists, Society for Cardiovascular

Angiography and Interventions, Society of Interventional Radiology, Society of Thoracic Surgeons, and Society for Vascular Medicine. *J Am Coll Cardiol*. 2010 Apr 6;55(14):e27-e129.

- [68] Loscalzo ML, Goh DL, Loeys B, et al. Familial thoracic aortic dilation and bicommissural aortic valve: a prospective analysis of natural history and inheritance. *Am J Med Genet A*. 2007;143A:1960–7.
- [69] Svensson LG, Crawford ES. *Cardiovascular and Vascular Disease of the Aorta*. Philadelphia, PA: WB Saunders Co; 1997.
- [70] Kutty S, Greenberg RK, Fletcher S, et al. Endovascular stent grafts for large thoracic aneurysms after coarctation repair. *Ann Thorac Surg*. 2008;85:1332–8.
- [71] Roberts WC, Ko JM. Frequency by decades of unicuspid, bicuspid, and tricuspid aortic valves in adults having isolated aortic valve replacement for aortic stenosis, with or without associated aortic regurgitation. *Circulation* 2005; 111:920–925.
- [72] Wallby L, Janerot-Sjoberg B, Steffensen T, et al. T lymphocyte infiltration in non-rheumatic aortic stenosis: a comparative descriptive study between tricuspid and bicuspid aortic valves. *Heart* 2002;88:348–51.
- [73] Subramanian R, Olson LJ, Edwards WD. Surgical pathology of pure aortic stenosis: a study of 374 Cases. *Mayo Clin Proc* 1984;59:683–90.
- [74] Pomerance A. Pathogenesis of aortic stenosis and its relation to age. *Br Heart J* 1972;34:569–74.
- [75] Mautner GC, Mautner SL, Cannon RD, et al. Clinical factors useful in predicting aortic valve structure in patients >40 years of age with isolated valvular aortic stenosis. *Am J Cardiol* 1993;73:194–8.
- [76] Wallaby L, Janerot-Sjoberg B, Steffensen T, Broqvist M. T-lymphocyte infiltration in non-rheumatic aortic stenosis: a comparative descriptive study between tricuspid and bicuspid aortic valves. *Heart* 2002; 88:348–351.
- [77] Chan KL, Ghani M, Woodend K, Burwash IG. Case-controlled study to assess risk factors for aortic stenosis in congenitally bicuspid aortic valve. *Am J Cardiol* 2001; 88:690–693.
- [78] Pachulski RT, Chan KL. Progression of aortic valve dysfunction in 51 adult patients with congenital bicuspid aortic valve: assessment and follow-up by Doppler echocardiography. *Br Heart J* 1993; 69:237–240.
- [79] Yotsumoto G, Moriyama Y, Toyohira H, Shimokawa S, Iguro Y, Watanabe S, et al. Congenital bicuspid aortic valve: analysis of 63 surgical cases. *J Heart Valve Dis* 1998; 7:500–503.
- [80] Fedak PWM, Verma S, Tirone ED, Leask RL, Weisel RD, Butany J. Clinical and pathophysiological implications of a bicuspid aortic valve. *Circulation* 2002; 106:900–904.

- [81] Roberts WC, Morrow AG, McIntosh CL, Jones M, Epstein SE. Congenitally bicuspid aortic valve causing severe, pure aortic regurgitation without superimposed infective endocarditis. Analysis of 13 patients requiring aortic valve replacement. *Am J Cardiol*. 1981;47(2):206–9.
- [82] Lewin MB, Otto CM. The bicuspid aortic valve: adverse outcomes from infancy to old age. *Circulation*. 2005;111(7):832–4.
- [83] Nistri S, Sorbo MD, Marin M, et al. Aortic root dilatation in young men with normally functioning bicuspid aortic valves. *Heart* 1999;82:19–22.
- [84] Cosgrove DM, Valvuloplasty for aortic insufficiency. *J Thorac Cardiovasc Surg* 1991, 102, 571–576.
- [85] Michelena HI, Desjardins VA, Avierinos JF, et al. Natural history of asymptomatic patients with normally functioning or minimally dysfunctional bicuspid aortic valve in the community. *Circulation* 2008; 117:2776–84.
- [86] Tzemos N, Therrien J, Yip J, et al. Outcomes in adults with bicuspid aortic valves. *JAMA* 2008;300:1317–25.
- [87] Thiene G, Basso C Pathology and pathogenesis of infective endocarditis in native heart valves. *Cardiovasc Pathol* 2006, 15, 256–263.
- [88] Habib G, Hoen B, Tornos P, et al. Guidelines on the prevention, diagnosis, and treatment of infective endocarditis (new version 2009): the Task Force on the Prevention, Diagnosis, and Treatment of Infective Endocarditis of the European Society of Cardiology (ESC). Endorsed by the European Society of Clinical Microbiology and Infectious Diseases (ESCMID) and the International Society of Chemotherapy (ISC) for Infection and Cancer. *Eur Heart J*. 2009 Oct;30(19):2369–413.
- [89] Lamas GC, Eykyn SJ. Bicuspid aortic valve—a silent danger: analysis of 50 cases of infective endocarditis. *Clin Infect Dis* 2000;30:336–41.
- [90] Nishimura RA, Carabello BA, Faxon DP et al. ACC/AHA 2008 guideline update on valvular heart disease: focused update on infective endocarditis: a report of the American College of Cardiology/American Heart Association Task Force on Practice Guidelines: endorsed by the Society of Cardiovascular Anesthesiologists, Society for Cardiovascular Angiography and Interventions, and Society of Thoracic Surgeons. *Circulation*. 2008 Aug 19;118(8):887–96.
- [91] Keane MG, Wiegers SE, Plappert T et al. (2000) Bicuspid aortic valves are associated with aortic dilatation out of proportion to coexistent valvular lesions. *Circulation*, 102, III35–III39.
- [92] Niwa K, Perloff JK, Bhuta SM, Laks H, Drinkwater DC, Child JS, Miner PD. Structural abnormalities of great arterial walls in congenital heart disease. Light and electron microscopic analyses. *Circulation* 2001; 103:393– 400.

- [93] Parai JL, Masters RG, Walley VM, Stinson WA, Veinot JP. Aortic medial changes associated with bicuspid aortic valve: myth or reality? *Can J Cardiol* 1999; 15:1233–1238.
- [94] Bauer M, Pasic M, Meyer R. Morphometric analysis of aortic media in patients with bicuspid and tricuspid aortic valve. *Ann Thorac Surg* 2002; 74:58–62.
- [95] Bonderman D, Gharehbaghi-Schnell E, Wollenek G, Maurer G, Baumgartner H, Lang IM. Mechanisms underlying aortic dilatation in congenital aortic valve malformation. *Circulation* 1999; 99:2138–2143.
- [96] Schmid FX, Bielenberg K, Schneider A, Haussler A, Keyser A, Birnbaum D. Ascending aortic aneurysm associated with bicuspid and tricuspid aortic valve: involvement and clinical relevance of smooth muscle cell apoptosis and expression of cell death-initiating proteins. *Eur J Cardiothorac Surg* 2003; 23:537–543.
- [97] Nataatmadja M, West M, West J, Summers K, Walker P, Nagata M, Watanabe T. Abnormal extracellular matrix protein transport associated with increased apoptosis of vascular smooth muscle cells in Marfan syndrome and bicuspid aortic valve thoracic aortic aneurysm. *Circulation* 2003; 108 (suppl II):329–334.
- [98] Fedak PW, de Sa MP, Verma S, Nili N, Kazemian P, Butany J, et al. Vascular matrix remodeling in patients with bicuspid aortic valve malformations: implications for aortic dilatation. *J Thorac Cardiovasc Surg* 2003; 126:797–806.
- [99] Boyum J, Fellingner EK, Schmoker JD, Trombley L, McPartland K, Ittleman FP, Howard AB. Matrix metalloproteinase activity in thoracic aortic aneurysms associated with bicuspid and tricuspid aortic valves. *J Thorac Cardiovasc Surg* 2004; 127:686–691.
- [100] Koullias GJ, Korkolis DP, Ravichandran P, Psyrri A, Hatzaras I, Elefteriades JA. Tissue microarray detection of matrix metalloproteinases, in diseased tricuspid and bicuspid aortic valves with or without pathology of the ascending aorta. *Eur J Cardiothorac Surg* 2004; 26:1098–1103.
- [101] El-Hamamsy I, Yacoub MH. A measured approach to managing the aortic root in patients with bicuspid aortic valve disease. *Curr Cardiol Rep.* 2009;11 (2):94–100.
- [102] Roberts CS, Roberts WC (1991) Dissection of the aorta associated with congenital malformation of the aortic valve. *J Am Coll Cardiol*, 17, 712–716.
- [103] Fazel SS, Mallidi HR, Lee RS, Sheehan MP, Liang D, Fleischman D, Herfkens R, Mitchell RS, Miller DC: The aortopathy of bicuspid aortic valve disease has distinctive patterns and usually involves the transverse aortic arch. *J Thorac Cardiovasc Surg* 2008, 135 (4):901–907, 907 e901-902.
- [104] Davies RR, Gallo A, Coady MA, Tellides G, Botta DM, Burke B, Coe MP, Kopf GS, Elefteriades JA. Novel measurement of relative aortic size predicts rupture of thoracic aortic aneurysms. *Ann Thorac Surg.* 2006 Jan;81(1):169-77.

- [105] Borger MA, David TE. Management of the valve and ascending aorta in adults with bicuspid aortic valve disease. *Semin Thorac Cardiovasc Surg*. 2005;17(2):143–7.
- [106] El Khoury G, Vanoverschelde JL, Glineur D, Pierard F, Verhelst RR, Rubay J, et al. Repair of bicuspid aortic valves in patients with aortic regurgitation. *Circulation*. 2006;114(1 Suppl):I610–1616.
- [107] Cameron DE, Vricella LA. What is the proper place of the Ross procedure in our modern armamentarium? *Curr Cardiol Rep*. 2007;9(2):93–8.
- [108] de Sa M, Moshkovitz Y, Butany J, David TE. Histologic abnormalities of the ascending aorta and pulmonary trunk in patients with bicuspid aortic valve disease: clinical relevance to the ross procedure. *J Thorac Cardiovasc Surg*. 1999;118(4):588–94.
- [109] Takkenberg JJ, Klieverik LM, Schoof PH, van Suylen RJ, van Herwerden LA, Zonder-van PE, Roos-Hesselink JW, Eijkemans MJ, Yacoub MH, Bogers AJ. The Ross procedure: a systematic review and meta-analysis. *Circulation*. 2009 Jan 20;119(2):222–8.
- [110] Bentall H, De Bono A. A technique for complete replacement of the ascending aorta. *Thorax*. 1968;23 (4):338–9.
- [111] Etz CD, Bischoff MS, Bodian C, et al. The Bentall procedure: is it the gold standard? A series of 597 consecutive cases. *Ann Thorac Cardiovasc Surg*. 2010;140:S64–71.
- [112] Schmitto JD, Mokashi SA, Chen FY, Chen EP. Aortic valve-sparing operations: state of the art. *Curr Opin Cardiol*. 2010 Mar;25(2):102–6.
- [113] David TE, Feindel CM. An aortic valve-sparing operation for patients with aortic incompetence and aneurysm of the ascending aorta. *J Thorac Cardiovasc Surg* 1992; 103:617–621.
- [114] Sarsam MA, Yacoub M. Remodeling of the aortic valve annulus. *J Thorac Cardiovasc Surg* 1993; 105:435–438.
- [115] Aikawa E, Nahrendorf M, Sosnovik D, et al. Multimodality molecular imaging identifies proteolytic and osteogenic activities in early aortic valve disease. *Circulation*. 2007;115:377– 86.
- [116] Cowell SJ, Newby DE, Prescott RJ, et al. A randomized trial of intensive lipid-lowering therapy in calcific aortic stenosis. *N Engl J Med*. 2005 Jun 9;352(23):2389–97
- [117] Moore P, Egito E, Mowrey H, Perry SB, Lock JE, Keane JF. Midterm results of balloon dilation of congenital aortic stenosis: predictors of success. *J Am Coll Cardiol* 1996;27:1257– 63.
- [118] McCrindle BW, for the Valvuloplasty and Angioplasty of Congenital Anomalies (VACA) Registry Investigators. Independent predictors of immediate results of percutaneous balloon aortic valvotomy in children. *Am J Cardiol* 1996;77:286 –93.

- [119] Rosenfeld HM, Landzberg MJ, Perry SB, Colan SD, Keane JF, Lock JE. Balloon aortic valvuloplasty in the young adult with congenital aortic stenosis. *Am J Cardiol* 1994;73:1112–7.
- [120] Holmes DR Jr, Mack MJ, Kaul S, et al. 2012 ACCF/AATS/SCAI/STS expert consensus document on transcatheter aortic valve replacement. *J Am Coll Cardiol*. 2012 Mar 27;59(13):1200–54.
- [121] Wijesinghe N, Ye J, Rodes-Cabau J, et al. Transcatheter aortic valve implantation in patients with bicuspid aortic valve stenosis. *J Am Coll Cardiol Interv*. 2010;3:1122–5.
- [122] Delgado V, Tops LF, Schuijf JD, et al. Successful deployment of a transcatheter aortic valve in bicuspid aortic stenosis: role of imaging with multislice computed tomography. *Circ Cardiovasc Imaging*. 2009;2: e12–3.
- [123] Chiam PT, Chao VT, Tan SY, et al. Percutaneous transcatheter heart valve implantation in a bicuspid aortic valve. *J Am Coll Cardiol Interv*. 2010;3:559–61.
- [124] Bonow RO, Carabello BA, Kanu C, et al. ACC/AHA 2006 guidelines for the management of patients with valvular heart disease: a report of the American College of Cardiology/American Heart Association Task Force on Practice Guidelines (Writing Committee to Revise the 1998 Guidelines for the Management of Patients With Valvular Heart Disease). *J Am Coll Cardiol* 2006;48:e1–148.
- [125] Bonow RO, Cheitlin MD, Crawford MH, Douglas PS. Task Force 3: valvular heart disease. *J Am Coll Cardiol*. 2005;45(8):1334–40.
- [126] Silversides C, Colman JM, Sermer M, et al. Early and intermediate-term outcomes of pregnancy with congenital aortic stenosis. *Am J Cardiol* 2003;91:1386–9.
- [127] Hameed A, Karaalp IS, Tummala PP, et al. The effect of valvular heart disease on maternal and fetal outcome of pregnancy. *J Am Coll Cardiol*. 2001;37:893–9.
- [128] Lao TT, Sermer M, Magee L, et al. Congenital aortic stenosis. *Am J Obstet Gynecol* 1993;169:540–5.
- [129] Elkayam U, Bitar F. Valvular heart disease and pregnancy part I: native valves. *J Am Coll Cardiol*. 2005 Jul 19;46(2):223–30.
- [130] Sullivan HJ. Valvular heart surgery during pregnancy. *Surg Clin North Am* 1995;75:59–75.
- [131] Goldstein I, Jakobi P, Gutterman E, et al. Umbilical artery flow velocity during maternal cardiopulmonary bypass. *Ann Thorac Surg* 1995;60:1116–8.
- [132] Brickner ME. Valvar aortic stenosis. In: Gatzoulis MA, Webb GD, Daubeney PE, editors. *Diagnosis and Management of Adult Congenital Heart Disease*. Philadelphia, PA: Churchill Livingstone, 2003.

- [133] Banning AP, Pearson JF, Hall RJ. Role of balloon dilatation of the aortic valve in pregnant patients with severe aortic stenosis. *Br Heart J* 1993;70:544-5.
- [134] Teo KK, Corsi DJ, Tam JW, Dumesnil JG, Chan KL Lipid lowering on progression of mild to moderate aortic stenosis: meta-analysis of the randomized placebo-controlled clinical trials on 2344 patients. *Can J Cardiol.* 2011 Nov-Dec;27(6):800-8.
- [135] Ciotti GR, Vlahos AP, Silverman NH. Morphology and function of the bicuspid aortic valve with and without coarctation of the aorta in the young. *Am J Cardiol.* 2006 Oct 15;98(8):1096-102.
- [136] Wendell DC, Samyn MM, Cava JR et al. Including aortic valve morphology in computational fluid dynamics simulations: Initial findings and application to aortic coarctation. *Med Eng Phys.* 2012 Aug 20.