

We are IntechOpen, the world's leading publisher of Open Access books Built by scientists, for scientists

6,900

Open access books available

185,000

International authors and editors

200M

Downloads

Our authors are among the

154

Countries delivered to

TOP 1%

most cited scientists

12.2%

Contributors from top 500 universities



WEB OF SCIENCE™

Selection of our books indexed in the Book Citation Index
in Web of Science™ Core Collection (BKCI)

Interested in publishing with us?
Contact book.department@intechopen.com

Numbers displayed above are based on latest data collected.
For more information visit www.intechopen.com



Chronic Thromboembolic Pulmonary Hypertension

Mehdi Badidi and M'Barek Nazi

Additional information is available at the end of the chapter

<http://dx.doi.org/10.5772/54749>

1. Introduction

Chronic thromboembolic pulmonary hypertension (CTEPH) is a form of pulmonary hypertension caused by obstruction and vascular remodeling of the pulmonary arteries after a pulmonary embolism [1]. Once considered rare, CTEPH is likely under-diagnosed and its true prevalence is still uncertain [2,3]. CTEPH is a consequence of the persistence and fibrous organization of clots in the pulmonary arteries after one or more acute pulmonary emboli. Recent research has provided evidence, suggesting that the old view of CTEPH as a disease caused solely by obliteration of pulmonary arteries by organized thrombus constitutes a very superficial understanding of the consequences of pulmonary thromboemboli [3]. In fact, pulmonary embolism, either as a single episode or as recurrent episodes, is probably the trigger followed by progressive pulmonary vascular remodeling leading to elevated pulmonary vascular resistance, progressing to right ventricular (RV) failure [4]. Thanks to enhanced vascular and cardiac imaging, less-invasive diagnostic work-up of CTEPH have become widely available. Doppler ultrasound echocardiography and pulmonary ventilation/perfusion (V/Q) scintigraphy are two excellent and complementary examinations for CTEPH [5]. Computed tomography (CT) and pulmonary angiography are the two best tools to decide on the operability of the endovascular lesions. [6]. Equally important, CTEPH is a type of pulmonary hypertension (PH) that is unique because it is potentially curable by PEA [7, 8]. Indeed, the prognosis of CTEPH was transformed by this technique [8]. The first surgery for CTEPH was performed in 1958 [9]. The mortality in the early surgical series was 22% but with advances in surgery and improved and peri-operative care, it has decreased to about 4% [10, 11].

2. Epidemiology of CTEPH

Pulmonary embolism (PE) is a common condition with an annual incidence estimated at 50 per 100,000 persons [12]. This is an acute disease and usually reversible after anticoagulation and / or after thrombolysis. Patients are frequently deemed to be "cured" after treatment. However, studies based on V/Q lung or computed tomography pulmonary angiogram (CTPA) reported the presence of residual perfusion disorders after acute pulmonary embolism [13]. Other echocardiographic studies have also shown that 30% of patients with PAH have residual or impaired right ventricular wall motion abnormalities and functional impairment after acute pulmonary embolism [14]. These data suggest that a significant proportion of patients with acute symptomatic PE develop persistent pulmonary vascular sequelae with serious long-term consequences [14,15]. Initial estimates of the frequency of CTEPH are of the order of 0.1% to 0.5% of patients surviving an episode of acute pulmonary embolism [16, 17]. More recent data suggest that 1% to 4% of patients may develop CTEPH after a first episode of pulmonary embolism [18, 19]. This frequency is even higher after recurrent thromboembolic events [20].

In a series of 866 patients with acute pulmonary embolism, all patients who had not previously been diagnosed with pulmonary hypertension (PH) and had survived until inclusion in the study were asked to undergo echocardiography. Patients suspected of having PH by echocardiogram underwent complete assessment to test chronic thromboembolic pulmonary hypertension. This procedure includes V/Q scintigraphy and right heart catheterization. The results showed the incidence of CTEPH to be about 0.5% [21, 22].

In a prospective study, after a first episode of symptomatic pulmonary embolism for patients with unexplained persistent dyspnea, echocardiographic abnormality, a V/Q scan, pulmonary angiography, and right heart catheterization, the cumulative incidence of symptomatic CTEPH was 1.0% at six months, 3.1% at one year and 3.8% at two years [23]. In another study of 320 patients who presented with a symptomatic pulmonary embolism, V/Q scintigraphy results showed persistent perfusion defects 6 and 12 months after pulmonary embolism. The cumulative incidence of CTEPH was 0.9% to 1.3% [24]. The true incidence of CTEPH may have been underestimated due to exclusion of patients with a history of venous thromboembolism, thrombophilia or other potential causes of pulmonary hypertension. In addition, a significant proportion of patients with CTEPH have not shown any previous episode of symptomatic pulmonary embolism [25, 26]. The discrepancy between theoretical estimates and the number of patients diagnosed with CTEPH emphasizes that CTEPH is likely to be underdiagnosed. The time between an acute pulmonary embolism episode and the development of CTEPH is also a matter of debate. Most cases of CTEPH are diagnosed during the first two years after the acute symptomatic pulmonary embolism [23]. However, some patients may experience symptoms of CTEPH many years later [27, 28]. This variability was attributed to progressive vasculopathy which affected the distal small pulmonary arteries [29].

3. Risk factors for CTEPH

To better identify patients with pulmonary embolism who are more likely to develop CTEPH, many studies have assessed the potential risk factors for CTEPH including demographic factors, the specific details of pulmonary embolism, the presence of co-morbidities and underlying thrombophilia (table 1) [23, 30]. An increased risk of CTEPH is associated with splenectomy, cancer, chronic inflammatory diseases (Crohn's disease and ulcerative colitis), hypothyroidism, an atrioventricular shunt and infected cardiac pacemaker [30, 31]. Complications associated with pulmonary embolism such as acute perfusion defects, idiopathic, recurrent thromboemboli, massive pulmonary emboli, and delayed diagnosis may also predispose patients to CTEPH. Patients older than 70 years whose systolic pulmonary artery pressure is above 50 mmHg have a higher risk of persistent pulmonary hypertension one year after an acute pulmonary embolism [30, 32].

Independent clinical risk factors for CTEPH
<ul style="list-style-type: none">• Splenectomy• Ventriculo-atrial (VA) shunts• Pacemaker leads• Indwelling central venous catheters (e.g. Port, Hickman catheter)• Chronic inflammatory diseases (osteomyelitis, inflammatory bowel diseases)• Malignant diseases• Thyroid hormone replacement therapy
Risk factors associated with CTEPH after symptomatic PE
<ul style="list-style-type: none">• Previous pulmonary embolism• Young age• Large perfusion defect• Idiopathic PE at presentation
Plasmatic risk factors associated with CTEPH
<ul style="list-style-type: none">• Elevated factor VIII levels $\geq 250\%$• APA/LAC• Combined coagulation defects• Fibrinogen mutations
APA, antiphospholipid antibodies; LAC, lupus anticoagulans.

Table 1. Risk factors for CTEPH [23].

Thrombolytics are frequently used to treat acute pulmonary emboli. The rapid and complete recanalization of the pulmonary arteries may decrease the subsequent development of CTEPH [33]. 23 of 40 patients who had angiographically proven pulmonary embolism and who had initially been randomized to an IV infusion of heparin (n = 11) or a thrombolytic agent (urokinase or streptokinase, n = 12) were restudied after a mean follow-up of 7.4 years to

Recommendation	Class of recommendation	Level of evidence
The diagnosis of CTEPH is based on the presence of pre-capillary PH (mean PAP ≥25 mmHg, PCWP ≤15 mmHg, PVR " />2 Wood units) in patients with multiple chronic/organized occlusive thrombi/emboli in the elastic pulmonary arteries (main, lobar, segmental, subsegmental), persisting after effective anticoagulation over a minimum period of three months.	I	C
In patients with CTEPH, lifelong anticoagulation is indicated	I	C
Surgical pulmonary endarterectomy (PEA) is the recommended treatment for patients with CTEPH.	I	C
Once perfusion scanning and/or CT angiography shows signs compatible with CTEPH, the patient should be referred to a center with expertise in surgical pulmonary endarterectomy.	IIa	C
The selection of patients for surgery should be based on the extent and location of the organized thrombi, on the degree of PH, and on the presence of co-morbidities.	IIa	C
PAH-specific drug therapy may be indicated in selected CTEPH patients such as patients who are not candidates for surgery or patients with residual PH after pulmonary endarterectomy.	IIb	C

Table 2. Recommendations of the ESC/ERS guidelines for CTEPH [93].

measure the right-sided pressures at rest and after supine bicycle ergometry exercise. At rest, the pulmonary artery (PA) mean pressure and the pulmonary vascular resistance (PVR) were significantly higher in the heparin group compared with the thrombolytic group (22 vs. 17 mmHg, $p<0.05$, and 351 vs. 171 dynes s (-1) cm (-5), $p<0.02$, respectively). During exercise both parameters rose to a significantly higher level in the heparin group (from rest to exercise, PA: 22-32 mmHg, $p<0.01$; PVR: 351-437 dynes s (-1) cm 5, $p<0.01$, respectively), but not in the thrombolytic group (rest to exercise, PA: 17-19 mm Hg, $p = \text{NS}$; PVR: 171-179 dynes s (-1) cm (-5), $p = \text{NS}$). Thus, thrombolytic therapy preserves the normal hemodynamic response to exercise in the long-term and may prevent the development of pulmonary hypertension [34].

CTEPH may be related to a disorder of hemostasis such as elevated levels of factor VIII. The expression of plasminogen activator inhibitor (PAI-1) of type 1 was found to be higher in patients monitored for CTEPH [30, 35, 36]. Abnormalities in the structure of fibrinogen and function were also observed in other series. Traditional risk factors for venous thromboembolism (VTE) include antithrombin deficiency, protein C deficiency, protein S deficiency, factor V Leiden, plasminogen deficiency, and anticardiolipin antibodies [26]. However, in 147 consecutive patients with CTEPH, the prevalence of hereditary thrombotic risk factors was not increased when compared to 99 consecutive patients with IPAH or to 100 control patients.

Thrombophilia studies have shown that lupus anticoagulant may be found in 10% of CTEPH patients, and 20% carry antiphospholipid antibodies, lupus anticoagulant, or both. A recent study has demonstrated that the plasma level of factor VIII, a protein associated with both primary and recurrent VTE, is elevated in 39% of patients with CTEPH [12]. No abnormalities of fibrinolysis have been identified. Blood groups type A, B, and AB were found to be significantly more common in patients with CTEPH compared to patients with PAH (88% vs. 56%). Plasma lipoprotein levels (a) (Lp(a)), a subgroup of the low density lipoprotein with high atherogenic potency, were significantly higher in patients with CTEPH than in patients with PAH and control subjects, indicating an overlap of venous and arterial thrombotic risk factors. Antiphospholipid antibodies (APLA) have been documented in a significant proportion of patients followed for CTEPH [30, 37, 38]. There is also evidence that underlying genetic predisposition may be involved in the pathogenesis of CTEPH.

4. Natural history and pathogenesis of CTEPH

The pathophysiological basis of CTEPH is not yet well known. Despite progress in determining the pathophysiology and treatment of PH, CTEPH pathogenesis is complex and poorly understood [39]. The mechanisms by which acute pulmonary embolism evolves into chronic thromboembolic residues incorporated into the pulmonary vessel wall have been difficult to define [39,40]. The incomplete resolution of pulmonary emboli rather than in situ thrombosis of pulmonary arteries appears to be the main contributing factor [41]. Pulmonary hypertension in patients without preexisting cardiopulmonary disease occurs when at least 30% of the pulmonary vascular bed is obstructed [42]. Development of pulmonary hypertension is not simply related to a simple mechanical obstruction by chronic thromboembolic material, but rather the appearance of a secondary vasculopathy developed in regions injured by shear stresses caused by persistent thromboembolic lesions [43]. Vascular injury and shear stress eventually lead to the proliferation of endothelial cells and smooth muscle cells of the pulmonary arterial bed [42, 43, and 44]. These results were reported from pathological observations in patients examined for CTEPH who displayed an organization of the clot into fibrous tissue, but also vascular remodeling with disappearance of the intima and infiltration of the media arterial wall [45, 46, 47, 48, and 49]. This hypothesis was initially suggested by Moser and Braunwald in 1971 [4]. Indeed, they observed that the pulmonary arteries of small caliber located in the unobstructed territories had remodeling lesions similar to those described in idiopathic pulmonary arterial hypertension.

5. Clinical presentation

Generally, the clinical history is not helpful in the diagnosis of CTEPH.. Indeed, up to half of patients with CTEPH have no documented history of pulmonary embolism [50]. In one series, 63% of patients had no specific history of acute venous thromboembolism [51]. Therefore, the clinical index of suspicion has been clarified below. The Hispanic clinic has an important place

in the diagnosis. It identifies clinical events that could be compatible with an unidentified acute venous thromboembolism [52, 53]. Symptoms of CTEPH are very similar to many other etiologies of pulmonary arterial hypertension. The majority of patients who displayed CTEPH were past the age of 60. The symptoms often occurred insidiously and were often attributed to other cardiac comorbidities, obesity or an underlying lung disease [54]. Dyspnea and fatigue were the symptoms most frequently encountered. Patients may present with exertional angina, presyncope, syncope and lower extremity edema. Chest pain may be caused by right ventricular ischemia. Syncope is an alarming symptom that raises concerns of advanced heart failure and should prompt urgent examination.

6. Physical examination

Physical signs vary depending on the severity of the pulmonary hypertension and associated right heart failure. Cardiac auscultation may be notable for accentuated pulmonic valve closure, tricuspid regurgitant murmur, or possibly bruit over the lung fields caused by turbulent blood flow through partially occluded pulmonary arteries [55, 56]. At a late stage, clinical signs of right ventricular failure may be present (jugular venous distension, hepatojugular reflux, lower limb edema, enlarged liver, and ascites). [56, 57].

7. Diagnostic approach

Patients with CTEPH have a higher mortality rate that may reach up to 10% to 20% among untreated patients [58, 59]. Thus, the most important step is the early detection of a population at risk, patients with a CTEPH and the accurate diagnosis of this pathology in order to adopt the best therapeutic strategy. Patients who experience acute symptomatic pulmonary embolism, persistent symptoms of dyspnea and chest pain may guide further diagnostic studies. Moreover, the persistence of pulmonary vascular perfusion defects are also common, 30% within 12 months after acute pulmonary embolism, and are associated with a higher prevalence of persistent symptoms, worse exercise capacity and pulmonary hypertension [60]. Thus, clinical and radiologic monitoring may detect patients with pulmonary embolism who have an increased risk of developing CTEPH.

It is important to acknowledge a history of deep vein thrombosis as an element that can guide the diagnosis, but it lacks sensitivity. Indeed, many patients with CTEPH have not had a documented DVT or PE [61, 62]. Patients monitored for pulmonary hypertension of another cause may exhibit symptoms similar to those of CTEPH [63]. V/Q scanning is an important tool for evaluation of all patients with pulmonary hypertension. It is essential because of the fact that CTEPH requires different therapies and may be amenable to surgical intervention. Thus, the objectives of the diagnostic processes are first to identify CTEPH, and then to define the stage of the disease and distribution of pulmonary arterial occlusion, with an assessment of the severity of pulmonary hypertension and other

concomitant diseases, and finally determine eligibility for pulmonary endarterectomy (PEA) or medical treatment.

After a thorough history and physical exam, patients with suspicious symptoms or signs of pulmonary hypertension and a history of pulmonary embolism or pulmonary hypertension of unknown cause should be investigated to confirm or exclude the diagnosis of CTEPH [64]. Imaging is central to making the diagnosis and management of CTEPH, but which test do you use, and when? The imaging algorithm used at Papworth Hospital for CTEPH diagnosis is shown in Figure 1. Echocardiography is used in the initial assessment of suspected pulmonary hypertension. V/Q lung scanning may be used to differentiate chronic thromboembolic pulmonary hypertension from other causes of pulmonary hypertension.

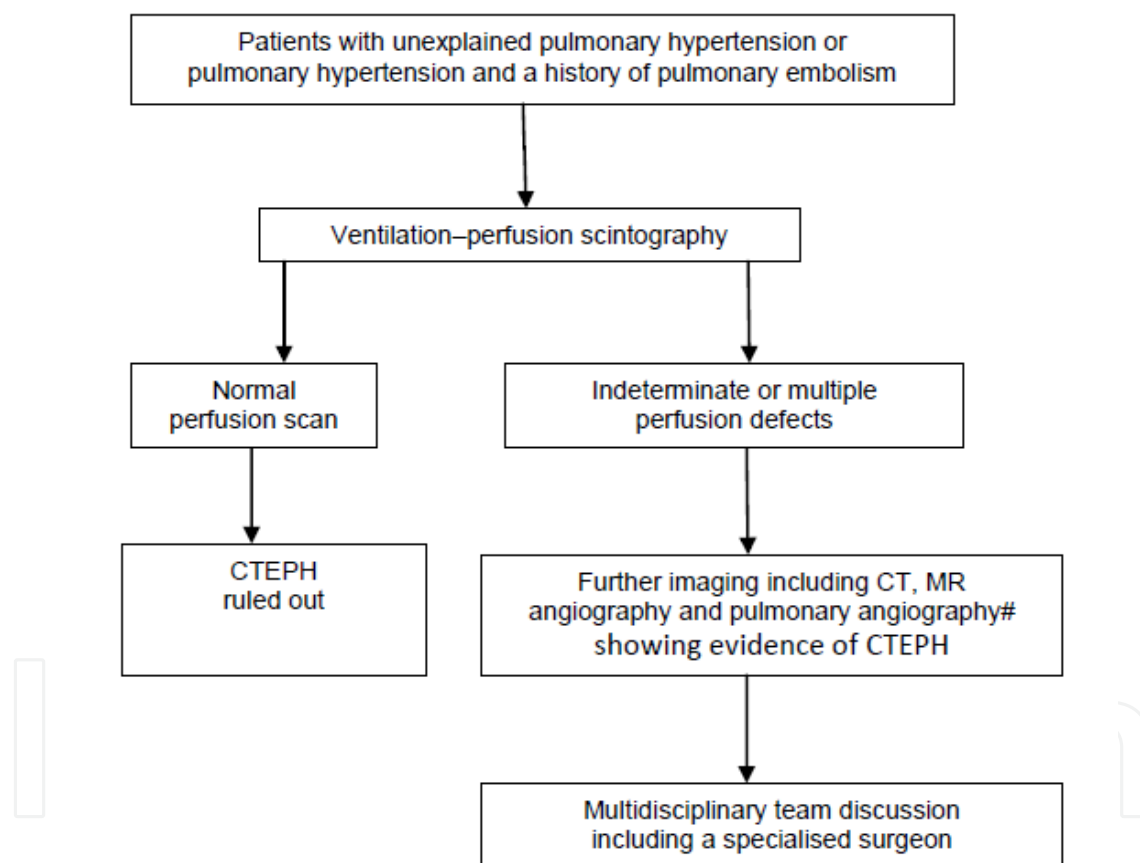


Figure 1. Diagnostic imaging algorithm for chronic thromboembolic pulmonary hypertension (CTEPH). CT: computed tomography; MR: magnetic resonance.: pulmonary angiography is usually performed in conjunction with right heart catheterisation and should be performed at centres experienced with CTEPH and pulmonary endarterectomy [20].

7.1. Echocardiography

Transthoracic echocardiography with Doppler imaging is a sensitive exam for the detection of pulmonary hypertension and right ventricular dysfunction, but it is not specific for the

diagnosis of chronic thromboembolic pulmonary hypertension. [65] Common echocardiographic findings include right ventricular dilatation, hypertrophy, and hypokinesis; right atrial enlargement; right ventricular pressure overload as suggested by interventricular septal deviation toward the left ventricle during systole; and tricuspid regurgitation. The tricuspid regurgitant jet gradient provides an estimate of the pulmonary artery systolic pressure. In rare cases, transthoracic echocardiography shows proximal pulmonary artery thrombus. However, echocardiography cannot be used to reliably differentiate among acute, subacute, and chronic pulmonary embolism. Thus, all patients with pulmonary hypertension should be evaluated with a V/Q scan [66, 67] in addition to angiography.

7.2. Lung scan ventilation-perfusion

The V/Q lung scan should be performed in patients with PH to look for potentially treatable CTEPH. The V/Q scan remains the screening method of choice for CTEPH because of its higher sensitivity relative to CT scans. A normal- or low-probability V/Q scan effectively excludes CTEPH with a sensitivity of 90–100% and a specificity of 94–100% [68, 69, 76]. A recent study has shown that lung scintigraphy V/Q had a negative predictive value of 98.5% to exclude CTEPH, while CT pulmonary angiography had a negative predictive value of 79.7% compared with pulmonary angiography gold standard. Therefore, a negative pulmonary CT angiography does not formally exclude CTEPH [76].

In PAH the V/Q lung scan may be normal; it may also show small peripheral unmatched and nonsegmental perfusion defects. Contrast-enhanced CT may be used as a complementary investigation but does not replace the ventilation/perfusion (henceforth V/Q) scan or traditional pulmonary angiogram. One caveat is that unmatched perfusion defects are also seen in pulmonary veno-occlusive disease (PVOD). The V/Q scan in CTEPH typically shows multiple segmental or larger perfusion defects in areas of normal ventilation. Since there is often only partial vascular obstruction in CTEPH, there may be grey zones, and the lung perfusion scan can underestimate the degree of vascular obstruction. On the other hand, a normal or low probability V/Q scan virtually excludes the possibility of surgical intervention of CTEPH [70, 71].

7.3. Computed tomography

The spiral CT has the advantage of being non-invasive, with a spatial resolution close to pulmonary angiography. In patients with CTEPH, the spiral CT lung may reveal the presence of an organized thrombus lining the proximal pulmonary vessels and may better visualize thickening of the pulmonary arterial wall to identify a cleavage plane for endarterectomy. Conversely, it allows for the identification of atherosclerotic calcification of the arterial wall lung, which will increase the complexity of PEA. It also evokes rare differential diagnoses such as fibrous mediastinitis, arteritis, pulmonary emboli tumors or/and sarcomas [72]. The spiral CT lung is now considered the benchmark in acute pulmonary embolism and can accurately define the nature and extent of disease in CTEPH, and provide multi-planar reconstruction to produce a three-dimensional vascular tree [73]. The recent development of this method allows imaging to differentiate perfusion defects distal to those of proximal infusion [74]. The V/Q

analysis does not distinguish between acute and chronic embolism. However, several studies have shown that acute pulmonary embolism disappears within 4 to 6 weeks in 90% of patients and within 6 months in all patients [75]. Therefore, symptomatic patients in whom perfusion defects persist despite adequate anticoagulation after 3 to 6 months should be referred to a specialist center for further evaluation, especially if there is direct or indirect evidence of pulmonary hypertension in the echocardiography. Sometimes, patients show symptoms at a later stage after the appearance of the signs of severe right ventricular dysfunction which might require urgent surgery or semi-urgent surgery, even if they have not yet completed 3 to 6 months of anticoagulation. Right heart catheterization and pulmonary angiography are generally required for definitive diagnosis of CTEPH. The spiral lung CT is also increasingly used to assess the extent of chronic thromboembolic disease. However, the spiral CT lung can sometimes fail to identify the presence of chronic thromboembolic disease.

7.4. Magnetic resonance imaging

This test is also useful for defining the anatomy and extent of obstruction in CTEPH. Currently, it is not routinely used in patients who can undergo conventional angiography, but in comparison with spiral CT, it seems to be equivalent for the identification of signs of CTEPH [77]. Both techniques provide a wealth of additional anatomical information, allowing the detection of other diagnoses that may be associated with pulmonary hypertension such as pulmonary vein stenosis and fibrosing mediastinitis.

7.5. Right heart catheterization and pulmonary angiography and angioscopy

7.5.1. Right heart catheterization

Preoperative evaluation of patients with CTEPH requires a battery of complementary examinations, starting with right heart catheterization and pulmonary angiography [78]. Right heart catheterization is necessary to confirm the diagnosis and severity of pulmonary hypertension and provide prognostic information. It allows precise measurement of pulmonary artery pressure and right atrial pressure, pulmonary artery occlusion pressure, and cardiac output. In patients with chronic thromboembolic obstruction, PH usually occurs with increased cardiac output; pulmonary artery pressure will rise in a nearly linear fashion and normal pulmonary vascular resistance will not occur [79]. In patients with CTEPH and risk factors for coronary artery disease, left heart catheterization with coronary angiography is performed before PEA.

7.5.2. Pulmonary angiography

Pulmonary angiography may confirm the diagnosis of chronic pulmonary thromboembolic disease. The angiographic appearance of CTEPH is distinct from that seen in acute pulmonary embolism, although the two processes can be seen simultaneously [80]. By defining the character of the proximal or distal lesions, pulmonary angiography is a determining factor in the use of PEA. The angiographic abnormalities related to CTEPH include intraluminal filling defects. A recently developed classification system for the anatomical location of thrombi is

helpful in the selection of patients for PEA. Type I disease is characterised by a clear central thrombus; type II consists of the thickening of the intima and fibrous reticulum in a main or segmental bronchus, without thrombus in a main vessel; type III is limited to segmental or sub-segmental regions and type IV involves only peripheral vessels and is not an operable disease.[80, 81]. In addition, pulmonary angiography is not free of significant risk in the context of severe pulmonary hypertension. Therefore, some security measures should be taken [82, 83]. The biplane acquisition technique should be used whenever possible. The systematic use of the side view is extremely useful in determining the location and extent of anatomical proximal embolic obstruction and, therefore, surgical accessibility.

7.5.3. *Pulmonary angioscopy*

Pulmonary angioscopy is used as an adjunct to pulmonary angiography. In the early years of endarterectomy, pulmonary angioscopy was used more frequently. More recently, it has been replaced by other, less invasive imaging techniques [84]. The technique involves the introduction of the angioscope through an introducer, preferably in the right internal jugular vein, then through the right atrium and right ventricle and the right and left pulmonary arteries, where it can be guided in each lobe of the arteries. The distal balloon is inflated with carbon dioxide, which obstructs blood flow transiently and allows visualization of the vascular bed [84].

8. Treatment of CTEPH

Several therapies have been used for CTEPH patients since the initial discovery of this clinical entity [85, 86]. In recent years scientific societies have unanimously endorsed surgical intervention with PEA as the preferred treatment for CTEPH because of the significant improvement in survival for the majority of patients and long-term improved outcomes.

PAH specific medications have been investigated in CTEPH, though the number of patients studied is much smaller than those enrolled in PAH clinical trials. These studies have shown safety of several therapies, and varying degrees of benefit. Medical therapies are often considered for use in inoperable patients, or for patients who have residual pulmonary hypertension after surgery.

The decision to use a specific medication in patients with CTEPH who cannot undergo surgery or who present with residual PH after surgical intervention should be made after an evaluation by a referral center. In addition, these patients should remain under close clinical monitoring.

8.1. Surgical approach

8.1.1. *Preparation of patients before pulmonary endarterectomy*

After diagnostic evaluation, PEA is the treatment of choice for symptomatic patients with proximal CTEPH. The preoperative assessment of patients scheduled for PEA involves

evaluating the presence of associated left heart disease with echocardiography to assess LV size and function as well as coronary angiography to exclude coronary artery disease in the appropriate patient [87]. Patients are also evaluated for significant concurrent disorders such as malignancy, using age-appropriate targeted screening, based on careful consideration of the symptoms presented. Patients are usually maintained on systemic anticoagulation immediately before surgery, although the actual protocol depends on local experience and preference of the expert center. Supplemental oxygen and diuretics are often administered to optimize the patient's oxygen and volume status. Thromboendarterectomy is the treatment of choice for symptomatic patients with CTEPH when surgically feasible. In some of these patients, particularly those with severe pulmonary hypertension and right ventricular failure, medical treatment pre-PEA with parenteral prostanoids (eg epoprostenol) may be initiated as a bridge to endarterectomy [87, 88, 89].

8.1.2. Pulmonary Endarterectomy (PEA)

Pulmonary endarterectomy is the preferred treatment for patients with CTEPH because of the potential for cure and complete resolution of PH and its complications. PEA has the potential to restore near normal cardiopulmonary function. Patient selection for surgery depends on the extent and location of the organized thrombus in relation to the degree of pulmonary hypertension. When the thrombus is situated in a proximal location, it represents the ideal condition for surgery, but if the thrombus is more distal, the intervention becomes more difficult.

8.1.2.1. Surgical strategy

PEA is performed during total circulatory arrest under conditions of profound hypothermia. This is required to enable visibility in the distal pulmonary arterial branches, which would otherwise be subject to back-bleeding during the endarterectomy due to the development of a systemic-to-pulmonary artery circulation at the precapillary level. A relatively recent technical advance is the introduction of video-assisted pulmonary endarterectomy, which uses a video camera connected to a rigid angioscope [90, 91]. Video technology is beneficial because it provides a source of light, allows visualization of the distal pulmonary vascular tree, and facilitates a close view of the surgery by the assistant surgeons.

8.1.2.2. Surgical procedure

After a median sternotomy, followed by a vertical pericardiotomy, the patient is placed on cardiopulmonary bypass with hypothermia at 18 to 20 °C. Before the cardiopulmonary bypass the patient's head is wrapped in a blanket with circulating cold water at 4° C. [90, 91]. This blanket has a thermometer and a device for regulating the water circulation. After the cardiopulmonary bypass has been started vents are placed in the pulmonary artery and the right superior pulmonary vein. The right pulmonary artery is dissected between the aorta and the superior vena cava and is mobilised within the pericardial reflection. During a first period of circulatory arrest, the plane is circumferentially followed down to the segmental and sometimes subsegmental branches of each lobe using special suction dissectors, until a complete endarterectomy is achieved. Once the field has been prepared, the endarterectomy

precedes with the aid of a microscopic aspirator with a rounded tip. The surgical specimen often resembles the arborization of pulmonary arteries, sometimes containing a mixture of fresh and old clots. The pulmonary artery pressures are commonly reduced immediately after surgery. The patient is reperfused for approximately 15 min with cardiopulmonary bypass, while the arteriotomy is closed with a back-and-forth running suture. An arteriotomy is performed on the left pulmonary artery and the endarterectomy is repeated in the left lung within another period of circulatory arrest. The final stage comprises reperfusion during closure of the left pulmonary artery, de-airing of the cardiac chambers, unclamping of the aorta, and slow rewarming of the patient to 37°C. [92, 93].

8.1.3. PEA in patients with distal CTEPH

The potential benefits of PEA are uncertain in patients with distal arterial obstruction and associated CTEPH. Studies have focused specifically on this issue by comparing clinical and hemodynamic results of surgery in patients with CTEPH and proximal thrombosis or distal thrombosis [94]. In a study of patients evaluated for CTEPH, 83 patients were considered for thrombo-endarterectomy [95], 40 patients underwent the procedure of whom 14 had distal lesions affecting small vessels. In these 14 subjects, PEA was associated with improvement of the baseline dyspnea index. However, the distal thrombo-endarterectomy was associated with increased perioperative mortality and severe residual PH post-thrombo-endarterectomy. Currently, there is no clear consensus on optimal management of distal chronic thromboembolic disease with associated PH. [94].

8.1.4. Management of patients after surgery

This is a crucial element for the success of the pulmonary PEA. Although pulmonary hemodynamics improved immediately after surgery in most patients, the postoperative course may be complicated. Complications are usually not related to any specific aspect of the heart surgery (pericardial effusion, arrhythmia, atelectasis, wound infection), or specific to the pulmonary thromboendarterectomy [96]. The postoperative course is marked mainly by the risk of pulmonary edema-like lesions which may appear up to 72 hours after surgery in the areas where the thromboembolic obstruction was removed [96, 97]. This pulmonary edema is of varying severity, ranging from a simple acute hypoxemia transition to a fatal hemorrhagic complication sometimes requiring prolonged mechanical ventilation. Other complications encountered are right heart failure due to persistent PH, the dehiscence of an arteriotomy suture during an episode of PAH, nosocomial pneumonia, hemoptysis, which will be easily treated by embolization, or phrenic nerve paralysis which might prolong mechanical ventilation.

Re thrombosis in the region of the thromboendarterectomy is a rare but known complication, especially in unilateral obstruction, which justifies the initiation of anticoagulant therapy as early as possible after the operation. Patients often continue to improve functionally and hemodynamically in the months after the operation.

8.1.5. Postoperative outcomes

Despite the potential for life-threatening complications, the perioperative mortality of patients undergoing lung PEA has improved in recent years. The first results of an international CTEPH registry, which included 386 consecutive patients with newly diagnosed CTEPH undergoing surgery showed a significant and sustained decrease in PVR from 736 to 248 dyn s cm⁻⁵, which was accompanied by substantial improvements in WHO functional class and exercise capacity at 1 year [97]. Reported rates of residual PH after PEA (mean PAP > 30 mmHg) were 16.7% and 31%, respectively. More recently, a greatly reduced surgical mortality rate of 2.2% was reported [98]. Perioperative mortality in patients undergoing pulmonary endarterectomy at the University of California at San Diego was 17% for the first 200 patients who underwent operation from 1970 to 1990 [98]. In a series from UCSD from 1998 until 2002, 500 patients underwent pulmonary endarterectomy, with a rate of hospital mortality of 4.4% [98]. The preoperative factors that may adversely affect surgical outcomes include age over 70 years, the presence of multiple comorbidities, preoperative pulmonary vascular resistance, severe heart failure with high right atrial pressure, and prolonged duration of pulmonary hypertension before surgery [99]. In order to detect persistent or recurrent pulmonary hypertension, systematic monitoring surveys are needed. Right heart catheterization is recommended for a period of 6 to 12 months after PEA.

The danger inherent in the initiation of specific medical treatment of pulmonary hypertension without consultation with a surgeon is that potentially operable patients are not referred to a center of expertise, and they do not respond to medical treatment or are sent to surgery at an advanced stage, which is associated with a significantly increased risk. Before starting treatment, it must be established that the patients are appropriate candidates for the surgical procedure [100].

8.1.6. Long-term outcomes

Changes in short and long term patient outcomes are generally favorable after PEA. Indeed, functional and hemodynamic results are very encouraging. Most patients who were New York Heart Association (NYHA) class III or IV preoperatively became class I or II after surgery and were able to resume normal activities. A significant reduction and standardization of both pulmonary artery pressure and resistance may also be affected. In the largest series to date, the mean pulmonary artery pressure decreased from 46 mm Hg to 28 mm Hg and the mean pulmonary vascular resistance decreased from 893 to 285 dyne/s-1, [98]. Similar improvements were observed in right ventricular function by echocardiography, exercise capacity, and quality of life [101].

8.2. Medical therapy

Pulmonary endarterectomy is the treatment of choice for patients with CTEPH; unfortunately, it cannot be performed in all CTEPH patients because of the inaccessibility of distal lesions or the presence of concomitant life-threatening diseases. [102]. In addition, patients with CTEPH

who have undergone endarterectomy may experience a gradual hemodynamic and symptomatic decline related to a secondary hypertensive arteriopathy in the small precapillary pulmonary vessels. It has also been questioned what can be done to reduce risks from PEA surgery to improve outcomes in “high risk” patients with CTEPH with substantial impairment of pulmonary hemodynamics before surgery. Such patients may benefit from preoperative reduction of pulmonary vascular resistance by means of medical therapy. Conventional medical treatments, such as anticoagulation, diuretics, digitalis, and chronic oxygen therapy, show low efficacy in the treatment of CTEPH as they do not affect underlying disease processes. Over the last decade, several novel therapies have been developed for pulmonary arterial hypertension (PAH), including prostacyclin analogs (epoprostenol, beraprost, iloprost, treprostinil), endothelin receptor antagonists (bosentan, sitaxsentan, ambrisentan), and phosphodiesterase-5 inhibitors (sildenafil, tadalafil). Evidence of efficacy in PAH, coupled with studies showing histopathologic similarities between CTEPH and PAH, provides a rationale to extend the use of some of these medications to the treatment of CTEPH. However, direct evidence from clinical trials in CTEPH is limited to date [103, 104].

The BENEFiT (Bosentan Effects in iNoperable Forms of chronIc Thromboembolic pulmonary hypertension) study was a double-blind, randomized, placebo-controlled study in CTEPH including patients with either inoperable CTEPH or persistent/recurrent pulmonary hypertension after PEA (>6 months after PEA). Independent coprimary end points were change in PVR as a percentage of baseline and change from baseline in 6-min walk distance after 16 weeks of treatment [105]. This study demonstrated a positive treatment effect of bosentan on hemodynamics in this patient population. No improvement was observed in exercise capacity. Further trials are needed to define the role of medical therapy in patients with CTEPH. In a retrospective study, the authors analyzed the effects of long-term intravenous epoprostenol in 27 consecutive functional class III (n = 20) or IV (n = 7) patients with inoperable distal CTEPH. After three months of epoprostenol, NYHA functional class improved by one class in 11 of 23 surviving patients, 6-minute walk distance increased by 66 m (p 0.0001) and hemodynamics also improved. At the last evaluation (20 ± 8 months), functional class was improved in 9 of 18 surviving patients with sustained improvement in 6-minute walk distance (+46 m, p = 0.03) and hemodynamic parameters. Survival at one, two and three years was 73%, 59% and 41%, respectively [88]. Epoprostenol has also been shown to improve hemodynamics in CTEPH patients prior to pulmonary thromboendarterectomy. In an open-label uncontrolled study, the prostacyclin analog treprostinil has been used in patients with severe inoperable CTEPH. Treprostinil improves exercise capacity, hemodynamics and survival in patients with severe inoperable CTEPH. We speculate that the effects may be explained by a combined vasodilatory, platelet-antagonistic and potential antiproliferative action of the drug [106].

A double-blind, placebo-controlled, 12-week pilot study investigated the use of sildenafil, 40 mg three times daily, in 19 patients with inoperable CTEPH. Unfortunately, this study was inadequately powered to test the primary end-point (change in 6-min walk distance). Moreover, there was no significant difference between the sildenafil and placebo groups (17.5 m improvement). Nevertheless, there were significant improvements in WHO functional class (p=0.025) and pulmonary vascular resistance (p=0.044) for the sildenafil-treated [107].

8.3. Management of patients who are not candidates for endarterectomy

PEA remains the preferred approach for patients with CTEPH. Unfortunately, up to 50% of patients are not surgical candidates with the most common reasons for exclusion being distal chronic thromboembolic disease with surgical inaccessibility and significant comorbidities. Specific medical therapies for PAH in the future can be a real alternative for PEA CTEPH patients. Although the distinction between PAH and CTEPH is often clear, there are many similarities between the conditions, including the clinical presentation with progressive PH and RV failure, and overlapping pathophysiology. PAH and CTEPH may represent extremes of a continuum of disease based on several data sources such as the observation that micro-vascular arteriopathy with plexiform lesions may exist in the vascular bed of both obstructed and unobstructed patients with CTEPH [109]. The role of several medical therapies in these specific groups of patients with CTEPH has been explored in many small-uncontrolled studies.

Early indications are that medical therapies may have promise in all these subgroups of patients with CTEPH, but the precise role of medical treatment in each situation remains unclear. Studies to date have not demonstrated the same level of efficacy in CTEPH as for patients with PAH [110]. Other CTEPH patients who might receive PAH medications include those awaiting lung transplantation. The currently available data do not justify the continuation of medical treatment in these patients if the waiting time to lung transplantation is long.

8.4. Balloon angioplasty in patients with CTEPH

Some patients with CTEPH, despite proximal (main, lobar or segmental) pulmonary artery occlusion are not candidates for thromboendarterectomy or decline surgery. In these patients, balloon angioplasty is a therapeutic option to relieve the obstructed pulmonary artery and improve the degree of pulmonary hypertension. Uncontrolled case series [111] have demonstrated a short-term improvement in pulmonary hemodynamics, WHO functional class, and exercise capacity.

Although angioplasty may be beneficial, the long term results have not been thoroughly studied in CTEPH.

8.5. Review of transplantation in patients with CTEPH

Concerned patients with CTEPH in functional class III/IV who are inoperable or have residual pulmonary hypertension post-PEA are referred for lung transplantation to improve their clinical outcomes. Although no studies specifically addressing this medical issue have been identified, patients with CTEPH were included in studies of lung transplantation for pulmonary hypertension, and in reports from international transplant registries [112]. The average survival for patients with idiopathic pulmonary hypertension undergoing lung transplantation was 5.6 years. The absence of any direct evidence for lung transplantation compared to medical treatment, especially in patients with CTEPH, was noted. However, the health benefits of lung transplantation, and a high impact on morbidity and mortality in selected CTEPH patients was emphasized. The CTEPH patients who are inoperable or experience residual PH post-PEA and who remain in WHO functional class III or IV, despite optimal medical therapy,

should be referred for lung transplantation evaluation. Because there can be significant delays until transplantation, early referral is important.

9. Conclusion

We believe that over the past decade, a paradigm shift has occurred in CTEPH. The disease is much more common than anticipated and it is imperative that patients with this condition be adequately diagnosed to have access to surgery and well designed clinical trials. Although CTEPH is one of the leading causes of severe PH, it remains underdiagnosed. These delays in diagnosis contribute to the poor prognosis associated with the disease. Diagnosis of CTEPH requires input from various imaging techniques. Echocardiography, V/Q scintigraphy and possibly CT angiography are all essential in the initial diagnosis of CTEPH. Pulmonary angiography remains the gold standard diagnostic technique for assessing operability but recent advances in CT and MRI angiography show great promise. Furthermore, haemodynamic evaluation by right heart catheterisation provides vital prognostic information and an estimate of the relative risk of PEA surgery. CTEPH should be considered in all patients with PH as early diagnosis helps to identify those patients suitable for PEA, a potentially curative treatment. All patients with suspected CTEPH should be referred to an expert centre for a proper diagnostic evaluation to exclude or confirm the diagnosis and assess operability.

Author details

Mehdi Badidi* and M'Barek Nazi

*Address all correspondence to: mehdibadidi@hotmail.com or m_nazzi@yahoo.com

Cardiology Department, Military hospital Moulay Ismail in Meknes, University Hospital Center Hassan II of Fes, Morocco

References

- [1] Frachona I., Jaïs X., Leroyera C., Jobica Y. Diagnosis and care of postembolic pulmonary hypertension: The role of the pneumologist. *Revue de Pneumologie Clinique* 2008; 64: 316-324.
- [2] Carroll D. Chronic obstruction of major pulmonary arteries. *American J Med* 1950; 9:175-85.
- [3] Fedullo PF, Auger WR, Channick RN, et al. Chronic thromboembolic pulmonary hypertension. *Clin Chest Med* 1995; 16:353-74.

- [4] Moser KM, Braunwald NS. Successful surgical intervention in severe chronic thromboembolic pulmonary hypertension. *Chest* 1973; 64:29-35.
- [5] Fedullo PF, Auger WR, Kerr KM, Rubin LJ. Chronic thromboembolic pulmonary hypertension. *N Engl J Med* 2001; 345: 1465-72.
- [6] Darteville P, Fadel E, Mussot S, Chapelier A, Hervé P, de Perrot M, et al. Chronic thromboembolic pulmonary hypertension. *Eur Respir J* 2004; 23:637-48.
- [7] Petrucci L, Carlisi E, Ricotti S, et al. Pulmonary endarterectomy in chronic thromboembolic pulmonary hypertension: Short-term functional assessment in a longitudinal study. *Europa Medicophysica*. 2007; 43:147-53.
- [8] Hagl C, Khaladj N, Peters T, et al. Technical advances in pulmonary thromboendarterectomy for chronic thromboembolic pulmonary hypertension. *Eur J Cardiothorac Surg* 2003; 23:776-81.
- [9] Jamieson SW, Auger WR, Fedullo PF, et al. Experience and results with 150 pulmonary thromboendarterectomy operations over a 29-month period. *J Thorac Cardiovasc Surg* 1993; 106:116-27.
- [10] Daily PO, Auger WR. Historical perspective: Surgery for chronic thromboembolic disease. *Sem Thorac Cardiovasc Surg* 1999; 11:143-51.
- [11] Jamieson SW, Kapelanski DP. Pulmonary endarterectomy. *Curr Probl Surg* 2000; 37:165-252.
- [12] Anderson FA, Jr, Wheeler HB, Goldberg RJ, et al. A population-based perspective of the hospital incidence and case-fatality rates of deep vein thrombosis and pulmonary embolism. The Worcester DVT Study. *Arch Intern Med*. 1991; 151:933-8.
- [13] Hvid-Jacobsen K, Fogh J, Nielsen SL, et al Scintigraphic control of pulmonary embolism. *Eur J Nucl Med* 1988; 14, 71-72.
- [14] Stevinson BG, Hernandez-Nino J, Rose G, Kline JA. Echocardiographic and functional cardiopulmonary problems 6 months after first-time pulmonary embolism in previously healthy patients. *Eur Heart J*. 2007; 28:2517-24.
- [15] Pengo V, Lensing AW, Prins MH, Marchiori A, Davidson BL, Tiozzo F, Albanese P, Biasiolo A, Pegoraro C, Iliceto S, Prandoni P: Incidence of chronic thromboembolic pulmonary hypertension after pulmonary embolism. *N Engl J Med* 2004; 350: 2257-64.
- [16] Dalen JE, Alpert JS. Natural history of pulmonary embolism. *Prog Cardiovasc Dis*. 1975; 17:259-70.
- [17] Fedullo PF, Auger WR, Kerr KM, Rubin LJ. Chronic thromboembolic pulmonary hypertension. *N Engl J Med*. 2001; 345:1465-72.

- [18] Becattini C, Agnelli G, Pesavento R, et al. Incidence of chronic thromboembolic pulmonary hypertension after a first episode of pulmonary embolism. *Chest* 2006; 130:172-5.
- [19] Dentali F, Donadini M, Gianni M, et al. Incidence of chronic pulmonary hypertension in patients with previous pulmonary embolism. *Thromb Res* 2009; 124: 256-8.
- [20] Hoeper MM, Albert Barbera J, Channick RN, et al. Diagnosis, assessment, and treatment of non-pulmonary arterial hypertension pulmonary hypertension. *J Am Coll Cardiol* 2009; 54: Suppl. 1, S85-S96
- [21] Klok FA, Zondag W, van Kralingen KW, et al. Patient outcomes after acute pulmonary embolism. A pooled survival analysis of different adverse events. *Am J Respir Crit Care Med*. 2010; 181: 501-6.
- [22] Klok FA, van Kralingen KW, van Dijk AP, Heyning FH, Vliegen HW, Huisman MV. Prospective cardiopulmonary screening program to detect chronic thromboembolic pulmonary hypertension in patients after acute pulmonary embolism. *Haematologica*. 2010; 95: 970-5.
- [23] Pengo V, Lensing AW, Prins MH, et al. Incidence of chronic thromboembolic pulmonary hypertension after pulmonary embolism. *N Engl J Med*. 2004; 350:2257-64
- [24] Becattini C, Agnelli G, Pesavento R, et al. Incidence of chronic thromboembolic pulmonary hypertension after a first episode of pulmonary embolism. *Chest*. 2006; 130:172-5.
- [25] Jais X., Darteville P., Parent F., Sitbon O., Humberte M. al. Postembolic pulmonary hypertension. *Rev Mal Respir* 2007; 24: 497-508
- [26] Wilkens H., Lang I., Behr J. Berghaus T. Chronic thromboembolic pulmonary hypertension (CTEPH): Updated Recommendations of the Cologne Consensus Conference 2011. *International Journal of Cardiology* 2011; 154S: S54-S60.
- [27] Miniati M, Monti S, Bottai M, et al. Survival and restoration of pulmonary perfusion in a long-term follow-up of patients after pulmonary embolism. *Medicine* 2006; 85:253-262.
- [28] Moser KM, Daily PO, Peterson K, et al. Thromboendarterectomy for chronic, major-vessel thromboembolic pulmonary hypertension. Immediate and long-term results in 42 patients. *Ann Intern Med*. 1987; 107:560-5.
- [29] Moser KM, Auger WR, Fedullo PF. Chronic major-vessel thromboembolic pulmonary hypertension. *Circulation* 1990; 81: 1735-43.
- [30] Kim N.H, Lang I.M. Risk factors for chronic thromboembolic pulmonary hypertension. *Eur Respir Rev* 2012; 21: 123, 27-31

- [31] Ribeiro A, Lindmarker P, Johnsson H, et al. Pulmonary embolism: A follow-up study of the relation between the degree of right ventricular overload and the extent of perfusion defects. *J Intern Med* 1999; 245:601–10.
- [32] Ribeiro A, Lindmarker P, Johnsson H, Juhlin-Dannfelt A, Jorfeldt L. Pulmonary embolism: One-year follow-up with echocardiography doppler and five-year survival analysis. *Circulation*.1999; 99:1325–30.
- [33] Lund O, Nielsen TT, Ronne K, Schifter S. Pulmonary embolism: Long-term follow-up after treatment with full-dose heparin, streptokinase or embolectomy. *Acta Med Scand*. 1987; 221:61–71.
- [34] Sharma GV, Folland ED, McIntyre KM, Sasahara AA. Long-term benefit of thrombolytic therapy in patients with pulmonary embolism. *Vasc Med*. 2000; 5:91–5.
- [35] Lund O, Nielsen TT, Schifter S, Roenne K. Treatment of pulmonary embolism with full-dose heparin, streptokinase or embolectomy – results and indications. *Thorac Cardiovasc Surg*. 1986; 34:240–6.
- [36] Remy-Jardin M, Louvegny S, Remy J, et al. Acute central thromboembolic disease: Posttherapeutic follow-up with spiral CT angiography. *Radiology*. 1997; 203:173–80.
- [37] Colorio CC, Martinuzzo ME, Forastiero RR, Pombo G, Adamczuk Y, Carreras LO. Thrombophilic factors in chronic thromboembolic pulmonary hypertension. *Blood Coagul Fibrinolysis*. 2001; 12: 427–32.
- [38] Bonderman D, Turecek PL, Jakowitsch J, et al. High prevalence of elevated clotting factor VIII in chronic thromboembolic pulmonary hypertension. *Thromb Haemost*. 2003; 90:372–6.
- [39] Jais X, Darteville P, Parent F, Sitbon O, Humbert M, Fadel E, et al. Postembolic pulmonary hypertension. *Rev Mal Respir* 2007; 24(4 Pt 1): 497—508.
- [40] Dalen JE, Alpert JS. Natural history of pulmonary embolism. *Prog Cardiovasc Dis* 1975; 17:259–70.
- [41] Nijkeuter M, Hovens MM, Davidson BL, Huisman MV. Resolution of thromboemboli in patients with acute pulmonary embolism: A systematic review. *Chest*. 2006; 129:192–7.
- [42] Stevinson BG, Hernandez-Nino J, Rose G, Kline JA. Echocardiographic and functional cardiopulmonary problems 6 months after first-time pulmonary embolism in previously healthy patients. *Eur Heart J*. 2007; 28:2517–24.
- [43] Lang IM. Chronic thromboembolic pulmonary hypertension – not so rare after all. *N Engl J Med* 2004; 350:2236–8.
- [44] Wolfe MW, Lee RT, Feldstein ML, et al. Prognostic significance of right ventricular hypokinesis and perfusion lung scan defects in pulmonary embolism. *Am Heart J* 1994; 127:1371–5.

- [45] Moser KM, Bloor CM: Pulmonary vascular lesions occurring in patients with chronic major vessel thromboembolic pulmonary hypertension. *Chest* 1993; 103: 685-92.
- [46] Azarian R, Wartski M, Collignon MA, Parent F, Herve P, Sors H, Simonneau G: Lung perfusion scans and hemodynamics in acute and chronic pulmonary embolism. *J Nucl Med* 1997; 38: 980-3.
- [47] Blauwet LA, Edwards WD, Tazelaar HD, McGregor CG: Surgical pathology of pulmonary thromboendarterectomy: a study of 54 cases from 1990 to 2001. *Hum Pathol* 2003; 34: 1290-8.
- [48] Puthenkalam S, Jakowitsch J, Panzenboeck A, et al. Angiogenesis in chronic thromboembolic pulmonary hypertension (CTEPH). *Am J Respir Crit Care Med* 2011; 183: A2424.
- [49] de Perrot M, Fadel E, McRae K, Tan K, Slinger P, Paul N, Mak S, Granton JT. Evaluation of persistent pulmonary hypertension after acute pulmonary embolism. *Chest* 2007 Sep; 132(3): 780-5.
- [50] Rubin LJ, Badesch DB. Evaluation and management of the patient with pulmonary arterial hypertension. *Ann Intern Med* 2005; 143: 282-292.
- [51] Pepke-Zaba J, Delcroix M, Lang I, et al. Chronic thromboembolic pulmonary hypertension (CTEPH): results from an international prospective registry. *Circulation* 2011; 124: 1973-1981.
- [52] Azarian R, Brenot F, Sitbon O, Musset D, Grimon G, Boyer-Neumann C et al. Hypertension artérielle pulmonaire d'origine thrombo-embolique chronique. *Presse Med* 1994; 23: 1017-22.
- [53] Dartevelle P, Fadel E, Mussot S, Cerrina J, Leroy Ladurie F, Lehouerou D, Parquin F, Paul JF, Musset D.; Traitement chirurgical de la maladie thromboembolique pulmonaire chronique. *Presse Med* 2005; 34: 1475-86.
- [54] Ribeiro A, Lindmarker P, Johnsson H, et al. Pulmonary embolism: A follow-up study of the relation between the degree of right ventricular overload and the extent of perfusion defects. *J Intern Med* 1999; 245:601-10.
- [55] Maignan M, Rosso J, Gauthier H, et al. Systematic lung scans reveal a high frequency of silent pulmonary embolism in patients with proximal deep venous thrombosis. *Arch Intern Med* 2000; 160:159-64.
- [56] ZuWallack RL, Liss JP, Lahiri B: Acquired continuous murmur associated with acute pulmonary thromboembolism. *Chest* 1976; 70: 557-9.
- [57] Hoeper MM, Mayer E, Simonneau G, et al. Chronic thromboembolic pulmonary hypertension. *Circulation* 2006; 113: 2011-2020.
- [58] Lewczuk J, Piszko P, Jagas J, et al. Prognostic factors in medically treated patients with chronic pulmonary embolism. *Chest*. 2001; 119:818-23.

- [59] Riedel M, Stanek V, Widimsky J, Prerovsky I. Longterm follow-up of patients with pulmonary thromboembolism. Late prognosis and evolution of hemodynamic and respiratory data. *Chest*.1982; 81:151–8.
- [60] Sanchez O, Helley D, Couchon S, et al. Perfusion defects after pulmonary embolism: Risk factors and clinical significance. *J Thromb Haemost*. 2010; 8:1248–55.
- [61] Bonderman D, Jakowitsch J, Adlbrecht C, et al. Medical conditions increasing the risk of chronic thromboembolic pulmonary hypertension. *Thromb Haemost*. 2005; 93:512–6.
- [62] Darteville P, Fadel E, Mussot S, et al. Chronic thromboembolic pulmonary hypertension. *Eur Respir J*. 2004; 23:637–48.
- [63] McLaughlin VV, Presberg KW, Doyle RL, et al. Prognosis of pulmonary arterial hypertension: ACCP evidence-based clinical practice guidelines. *Chest*. 2004; 126:78S-92S.
- [64] D'Alonzo GE, Bower JS, Dantzker DR: Differentiation of patients with primary and thromboembolic pulmonary hypertension. *Chest* 1984; 85: 457-61.
- [65] Badidi M., Belhachmi H., Lakhal Z., Nazzi M. post embolic pulmonary hypertension revealed with floating thrombosis in the vena cava inferior. *Sang Thrombose Vaisseaux* 2010; 22 (8): 1-2.
- [66] Kapitan KS, Buchbinder M, Wagner PD, et al. Mechanisms of hypoxemia in chronic thromboembolic pulmonary hypertension. *Am Rev Respir Dis* 1989; 139:1149–54.
- [67] Galie` N, Hoeper MM, Humbert M, et al. Guidelines for the diagnosis and treatment of pulmonary hypertension. *Eur Respir J* 2009; 34: 1219–1263.
- [68] Lisbona R, Kreisman H, Novales-Diaz J, et al. Perfusion lung scanning: differentiation of primary from thromboembolic pulmonary hypertension. *Am J Roentgenol* 1985; 144:27–30.
- [69] Powe JE, Palevsky HI, McCarthy KE, et al. Pulmonary arterial hypertension: value of perfusion scintigraphy. *Radiology* 1987; 164:727–730.
- [70] Tunariu N, Gibbs SJR, Win Z, et al. Ventilation-perfusion scintigraphy is more sensitive than multidetector CTPA in detecting chronic thromboembolic pulmonary disease as a treatable cause of pulmonary hypertension. *J Nucl Med* 2007; 48:680–684.
- [71] Silversides CK, Granton JT, Konen E, et al. Pulmonary thrombosis in adults with Eisenmenger syndrome. *J Am Coll Cardiol* 2003; 42:1982–1987.
- [72] Lisbona R, Kreisman H, Novales-Diaz J, et al. Perfusion lung scanning: Differentiation of primary from thromboembolic pulmonary hypertension. *Am J Roentgenol* 1985; 144:27–30.

- [73] Coulden R. State-of-the-art imaging techniques in chronic thromboembolic pulmonary hypertension. *Proc Am Thorac Soc*. 2006; 3:577–83.
- [74] Reichelt A, Hoeper MM, Galanski M, et al. Chronic thromboembolic pulmonary hypertension: evaluation with 64-detector row CT versus digital subtraction angiography. *Eur J Radiol* 2009; 71:49–54.
- [75] Hoeper MM, Mayer E, Simonneau G, Rubin LJ. Chronic thromboembolic pulmonary hypertension. *Circulation* 2006 Apr 25; 113(16): 2011–20.
- [76] Tunariu N, Gibbs SJ, Win Z, Gin-Sing W, Graham A, Gishen P, Al-Nahhas A. Ventilation-perfusion scintigraphy is more sensitive than multidetector CTPA in detecting chronic thromboembolic pulmonary disease as a treatable cause of pulmonary hypertension. *J Nucl Med* 2007 May; 48(5): 680–4.
- [77] Kruger S, Haage P, Hoffmann R, et al. Diagnosis of pulmonary arterial hypertension and pulmonary embolism with magnetic resonance angiography. *Chest*. 2001; 120:1556–61.
- [78] Hoeper MM, Lee SH, Voswinckel R, et al. Complications of right heart catheterization procedures in patients with pulmonary hypertension in experienced centers. *J Am Coll Cardiol* 2006; 48:2546–52.
- [79] Auger WR, Fedullo PF, Moser KM, et al. Chronic major-vessel chronic thromboembolic pulmonary artery obstruction: Appearance of angiography. *Radiology* 1992; 182:393–8.
- [80] Fishman AJ, Moser KM, Fedullo PF. Perfusion lung scans vs pulmonary angiography in evaluation of suspected primary pulmonary hypertension. *Chest* 1983; 84:679–83.
- [81] Coulden R. State-of-the-art imaging techniques in chronic thromboembolic pulmonary hypertension. *Proc Am Thorac Soc*. 2006; 3:577–83.
- [82] Ryan KL, Fedullo PF, Davis GB, et al. Perfusion scan findings understate the severity of angiographic and hemodynamic compromise in chronic thromboembolic pulmonary hypertension. *Chest* 1988; 93:1180–5.
- [83] Sompradeekul S, Fedullo PF, Kerr KM, et al. The role of pulmonary angioscopy in the preoperative assessment of patients with thromboembolic pulmonary hypertension (CTEPH). *Am J Respir Crit Care Med* 1999; 159:A-456.
- [84] de Perrot M, McRae K, Shargall Y, Thenganatt J, Moric J, Mak S, Granton JT. Early postoperative pulmonary vascular compliance predicts outcome after pulmonary endarterectomy for chronic thromboembolic pulmonary hypertension. *Chest* 2011 Jul; 140(1): 34–41.
- [85] Mayer E, Kramm T, Dahm M, et al. Early results of pulmonary thromboendarterectomy in chronic thromboembolic pulmonary hypertension. *Z Kardiol* 1997; 86:920–7.

- [86] Hagl C, Khaladj N, Peters T, et al. Technical advances in pulmonary thromboendarterectomy for chronic thromboembolic pulmonary hypertension. *Eur J Cardiothorac Surg* 2003; 23:776–81.
- [87] Thistlethwaite PA, Kaneko K, Madani MM, Jamieson SW. Technique and outcomes of pulmonary endarterectomy surgery. *Ann Thorac Cardiovasc Surg* 2008; 14:274–82.
- [88] Cabrol S, Souza R, Jais X, Fadel E, Ali RH, et al. Intravenous epoprostenol in inoperable chronic thromboembolic pulmonary hypertension. *J Heart Lung Transplant*. 2007 Apr; 26(4): 357-62.
- [89] Kim M. Kerr, MD, FCCP; Lewis J. Rubin. Epoprostenol Therapy as a Bridge to Pulmonary Thromboendarterectomy for Chronic Thromboembolic Pulmonary Hypertension. *CHEST*.2003; 123(2): 319-320.
- [90] D'Armini AM, Cattadori B, Monterroso C, et al. Pulmonary thromboendarterectomy in patients with chronic thromboembolic pulmonary hypertension: Hemodynamic characteristics and changes. *Eur J Cardiothoracic Surg*. 2000; 18:696–702
- [91] Jamieson SW. Historical perspective: Surgery for chronic thromboembolic disease. *Semin Thorac Cardiovasc Surg*. 2006; 18:218–22.
- [92] Mehta S, Helmersen D, Provencher S, Hirani N, Rubens FD, et al. for the Canadian Thoracic Society Pulmonary Vascular Disease - CTEPH CPG Development Committee; and the Canadian Thoracic Society Canadian Respiratory Guidelines Committee. Diagnostic evaluation and management of chronic thromboembolic pulmonary hypertension: A clinical practice guideline. *Can Respir J* 2010 November/December; 17(6): 301-334.
- [93] Galie N, Hoeper MM, Humbert M, et al. Guidelines for the diagnosis and treatment of pulmonary hypertension: The Task Force for the Diagnosis and Treatment of Pulmonary Hypertension of the European Society of Cardiology (ESC) and the European Respiratory Society (ERS), endorsed by the International Society of Heart and Lung Transplantation (ISHLT). *Eur Heart J* 2009; 30:2493–2537.
- [94] Jamieson SW. Pulmonary endarterectomy. In: *Current problems in surgery*. New-York: Mosby, 2000, 165-252.
- [95] Yoshimi S, Tanabe N, Masuda M, et al. Survival and quality of life for patients with peripheral type chronic thromboembolic pulmonary hypertension. *Circ J*. 2008; 72:958–65.
- [96] Nakajima N, Masuda M, Mogi K. The surgical treatment for chronic pulmonary thromboembolism. Our experience and current review of the literature. *Ann Thorac Cardiovasc Surg* 1997; 3:15–21.
- [97] Mayer E, Jenkins D, Lindner J, D'Armini A, Kloek J, Meyns B, Ilkjaer LB, Klepetko W, Delcroix M, Lang I, Pepke-Zaba J, Simonneau G, Dartevelle P. Surgical management and outcome of patients with chronic thromboembolic pulmonary hypertension: re-

- sults from an international prospective registry. *J Thorac Cardiovasc Surg* 2011 Mar; 141(3):702-10.
- [98] Freed DH, Thomson BM, Berman M, et al. Survival after pulmonary thromboendarterectomy: Effect of residual pulmonary hypertension. *J Thorac Cardiovasc Surg* 2011; 141:383-7.
- [99] Mares P, Gilbert TB, Tschernko EM, et al. Pulmonary artery thromboendarterectomy: A comparison of two different postoperative treatment strategies. *Anesth Analg* 2000; 90:267-73.
- [100] Thistlethwaite PA, Auger WR, Madani MM, et al. Pulmonary thromboendarterectomy combined with other cardiac operations: Indications, surgical approach, and outcome. *Ann Thorac Surg* 2001; 72:13-9.
- [101] Tscholl D, Langer F, Wendler O, et al. Pulmonary thromboendarterectomy— Risk factors for early survival and hemodynamic improvement. *Eur J Cardiothorac Surg* 2001; 19:771-6.
- [102] Jamieson SW, Kapelanski DP, Sakakibara N, Manecke GR, Thistlethwaite PA, Kerr KM, Channick RN, Fedullo PF, Auger WR. Pulmonary endarterectomy: experience and lessons learned in 1,500 cases. *Ann Thorac Surg* 2003; 76:1457-1462.
- [103] Bresser. P, Pepke-Zaba J., Jais X., Humbert M., Therapies for Chronic Thromboembolic Pulmonary Hypertension, An Evolving Treatment Paradigm, *Proc Am Thorac Soc Vol 3*. pp 594-600, 2006.
- [104] Jensen KW, Kerr KM, Fedullo PF, Kim NH, Test VJ, Ben-Yehuda O, Auger WR. Pulmonary hypertensive medical therapy in chronic thromboembolic pulmonary hypertension before pulmonary thromboendarterectomy. *Circulation* 2009; 120:1248-54.
- [105] Ulrich S, Speich R, Domenighetti G, et al. Bosentan therapy for chronic thromboembolic pulmonary hypertension. A national open label study assessing the effect of Bosentan on haemodynamics, exercise capacity, quality of life, safety and tolerability in patients with chronic thromboembolic pulmonary hypertension (BOCTEPH-Study) *Swiss Med Wkly*. 2007;137:573-80.
- [106] Skoro-Sajer N, Bonderman D, Wiesbauer F, Harja E, Jakowitsch J, Klepetko W, Kneussl MP, Lang IM. Treprostinil for severe inoperable chronic thromboembolic pulmonary hypertension. *J Thromb Haemost* 2007; 5: 483-9.
- [107] Suntharalingam J, Treacy CM, Doughty NJ, Goldsmith K, Soon E, Toshner MR, Sheares KK, Hughes R, Morrell NW, Pepke-Zaba J. Long-term use of sildenafil in inoperable chronic thromboembolic pulmonary hypertension. *Chest*. 2008 Aug; 134(2): 229-36.
- [108] Vizza CD, Badagliacca R, Sciomer S, Poscia R, Battagliese A, Schina M, Agati L, Fedele F. Mid-term efficacy of beraprost, an oral prostacyclin analog, in the treatment

of distal CTEPH: a case control study. *Cardiology*. 2006; 106(3): 168-73. Epub 2006 Apr 26.

- [109] Peacock A, Simonneau G, Rubin L. Controversies, uncertainties and future research on the treatment of chronic thromboembolic pulmonary hypertension. *Proc Am Thorac Soc*. 2006; 3:608–14.
- [110] Galie N, Manes A, Negro L, Palazzini M, Bacchi-Reggiani ML, Branzi A. A meta-analysis of randomized controlled trials in pulmonary arterial hypertension. *Eur Heart J*. 2009; 30:394–403.
- [111] Feinstein JA, Goldhaber SZ, Lock JE, Ferndandes SM, Landzberg MJ. Balloon pulmonary angioplasty for treatment of chronic thromboembolic pulmonary hypertension. *Circulation*. 2001; 103:10–13.
- [112] Christie JD, Edwards LB, Aurora P, et al. The Registry of the International Society for Heart and Lung Transplantation: Twenty-sixth Official Adult Lung and Heart-Lung Transplantation Report – 2009. *J Heart Lung Transplant*. 2009; 28:1031–49.

