

We are IntechOpen, the world's leading publisher of Open Access books Built by scientists, for scientists

6,900

Open access books available

186,000

International authors and editors

200M

Downloads

Our authors are among the

154

Countries delivered to

TOP 1%

most cited scientists

12.2%

Contributors from top 500 universities



WEB OF SCIENCE™

Selection of our books indexed in the Book Citation Index
in Web of Science™ Core Collection (BKCI)

Interested in publishing with us?
Contact book.department@intechopen.com

Numbers displayed above are based on latest data collected.
For more information visit www.intechopen.com



Marsupialization of Keratocystic Odontogenic Tumors of the Mandible: Longitudinal Image Analysis of Tumor Size via 3D Visualized CT Scans

Hajime Shudou, Masanori Sasaki,
Takahiro Yamashiro, Shizuo Tsunomachi,
Yasuharu Takenoshita, Yasutaka Kubota,
Tomohiro Ninomiya, Toshiyuki Kawazu and
Yoshihide Mori

Additional information is available at the end of the chapter

<http://dx.doi.org/10.5772/52432>

1. Introduction

The odontogenic keratocyst (OKC) was designated by the World Health Organization (WHO) as a keratocystic odontogenic tumor (KCOT) in 2005. KCOT has been defined as a benign uni- or multicystic, intraosseous tumor of odontogenic origin, with a characteristic lining of parakeratinized stratified squamous epithelium and potential for aggressive, infiltrative behavior. Additionally, these tumors have been characterized by a high recurrence rate [1, 2]. Because the recurrence rate of KCOTs ranges from 13.1% [2] to 62.5% [3, 4, 5, 6], many attempts have been made to reduce the high recurrence rate with improved surgical techniques. Recommended techniques have included tanning the cystic cavity with Carnoy's solution before enucleation [7, 8], or using a combination of enucleation and liquid nitrogen cryotherapy [9], whereas others recommend techniques such as marsupialization or decompression of the cysts followed by secondary enucleation [10, 11, 12]. Specifically, Bramley [13] recommended the use of radical surgery with resection and bone transplantation, whereas Ephros and Lee [14] advocated the removal of the lateral cortical plate and enucleation of the cyst. Bataineh and al Qudah [15] advocated resection without continuity defects as a standard treatment for preoperatively diagnosed KCOTs. To reduce the high recurrence rate of KCOTs, it is essential to completely eradicate the epithelial components of the cyst [16]. However, radical treatment

has been associated with numerous complications, including facial deformity, missing teeth, infection of transplanted bone, and / or permanent numbness of the region innervated by the mental nerve when the KCOTs involved the inferior alveolar nerve. Therefore, considering the benign characteristics of KCOTs, the first priority of the treatment method should be discussed from the perspective of morbidity and the quality of life of the patients; the recurrence rate should not always be the primary factor.

1.1. Marsupialization

Marsupialization or decompression has been used in the past as a conservative treatment modality for large KCOTs, minimizing the tumor size and limiting the extent of surgery [10, 11, 12, 17-19, 20]. Nakamura et al. [19] reported that marsupialization did not affect the recurrence rate of KCOTs. Marker et al. [11] reported long-term results after decompression for 23 KCOTs, and they concluded that these cysts could be treated successfully by marsupialization and secondary enucleation. However, there were some disadvantages in marsupialization, and one of the disadvantages was that, when considering other treatment methods, the time necessary for this treatment was comparatively long [21].

This chapter determines how KCOTs in the mandible are reduced in size by marsupialization and predicts the best time for secondary enucleation by means of analyzing computerized tomography (CT) images. Fifteen patients with KCOTs were treated with marsupialization surgery, and 42 series of CT data taken during the marsupialization process were analyzed. CT data were reconstructed in 3-dimensional (3D) images. The 3D images were used to measure the diameter and volume, and to analyze the changes that occurred after marsupialization. Marsupialized KCOTs tended to be equally reduced towards the window in the tumor. The amount of volume reduction per day (V_r) was reduced in proportion to the volume (V) with the formula:

$V_r = -0.0029 \times V$. The formula manipulation for V was $V = V_1 \times e^{-0.0029 t}$ (t = duration after marsupialization in days). The volume of marsupialized KCOTs was reduced by half over a 239 day period. These results demonstrate that the future shape of marsupialized mandibular KCOTs, under good control, can be predicted with significant accuracy using CT data. This prediction can decrease the prolonged marsupialization period in patients with KCOTs. Herein we clarify how KCOTs are reduced in size during the marsupialization and to predict the best time for secondary enucleation by means of analyzing computerized tomography (CT) images.

1.2. Treatment

Our series of 15 patients with histologically proven KCOTs of the mandible were treated by marsupialization surgery from 2000 to 2010. Of the 15 patients, 9 were male (60.0%) and 6 were female (40.0%). The mean age was 35.9 years (range: 16 to 57). The tumors were located in the posterior molar to mandibular ramus in 5, in the angle to mandibular ramus in 7, and in the anterior molar region in 3 patients. Using X-ray images, the tumors were classified; 10 were unilocular lesions and 5 were multilocular lesions (Table1).

Postoperative follow-up consisted of clinical and radiographic examinations. Cases of recurrent tumors or cases associated with basal cell nevus syndrome were excluded from this study. Clinical information and CT images were obtained from the records of the Section of Oral and Maxillofacial Surgery, Kyushu University Hospital.

	Total	Male	Female
	15	9	6
Age(yr)			
Range	16 - 57	17 - 57	16 - 52
Mean	35.9	39.4	30.5
The duration from day of marsupialisation to day of having taken CT before surgery			
Range	136 - 1150	196 - 1150	136 - 535
Mean	413	467.2	331.7
Location of the tumours			
Molar region - Mandibular ramus	5	3	2
Angular region - Mandibular ramus	7	4	3
Anterior region - Molar region	3	2	1
Radiographic features			
Unilocular	10	6	4
Multilocular	5	3	2
Impacted teeth			
(+)	7	4	3
(-)	8	5	3

Table 1. Distribution of patients treated by marsupialisation for KCOT.

1.3. Marsupialization and secondary enucleation technique

Marsupialization has been used to relieve the pressure within the cystic cavity and allow new bone to fill the defect [22] (Fig. 1). This surgical technique usually involves making a bone window or opening in the wall of the tumor, partially debriding with an excision on the top portion of the tumor, and suturing the edges of the remaining cyst to the surrounding soft tissue. At the beginning of each treatment, marsupialization was performed simultaneously with a biopsy. In multilocular lesions, the intracystic partitions were removed to make a single cavity. After marsupialization, an obturator, made of acrylic resin, was used to keep the window open. The purpose of the obturator was to maintain continuity between the marsupialized tumor and the oral environment during the treatment process. The marsupialized window was kept open until the patients could withstand less aggressive treatment, such as enucleation and curettage. The inner volume of the tumor was estimated by filling the intracavity with saline [23] and measuring the distance between the inferior alveolar nerve and the tumor as well as the thickness of the peritumoral bone. Thus, the duration of marsupialization was different for each case.

The secondary surgery after marsupialization, was enucleation and curettage in which the KCOTs were enucleated, and the overlying mucosa was excised and subsequently curetted to adjacent healthy bone. Using a large round bur, curettage usually extended 1 to 2 mm in depth. This procedure was performed to ensure the removal of the epithelial remnants.

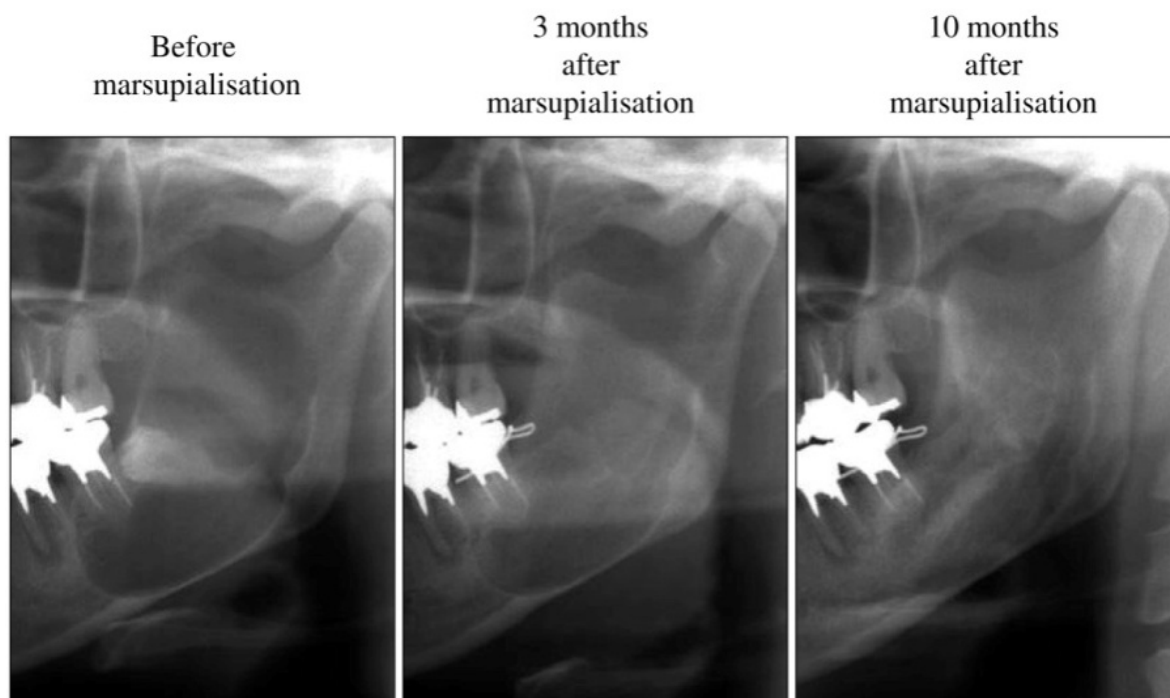


Figure 1. Panoramic radiographs of a typical case of marsupialisation and extraction of mandibular third molar associated with KCOT; Marsupialised window was opened with extraction cavity. KCOT had been reduced successfully.

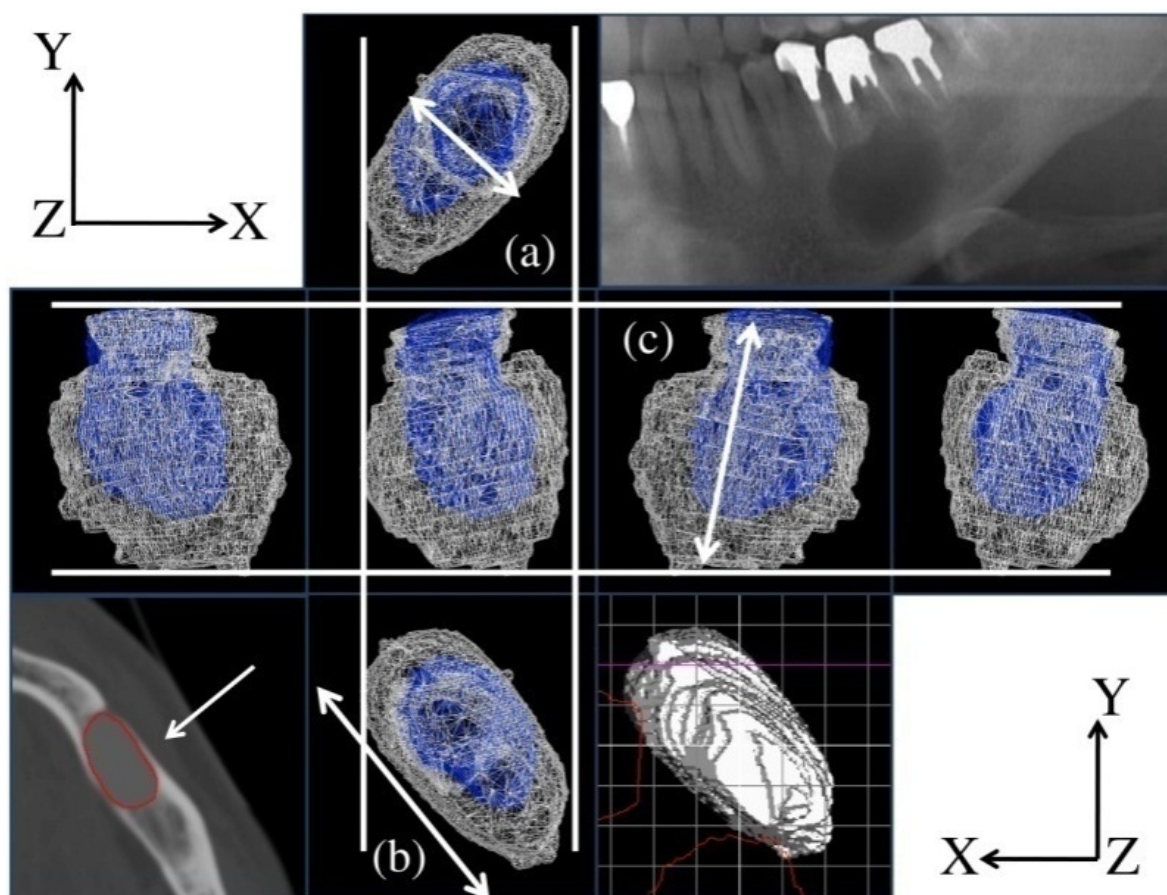
1.4. The effect of marsupialization by visual analysis

Fifteen KCOTs with 42 series of CT data taken during the marsupialization process were analyzed. Images were made with 1 or 2 mm thick contiguous axial scans (Aquilion®, Toshiba, Japan: 120 kV, 250 mA). All of the CT data taken before the secondary enucleation were segmented between the bone and tumor, and reconstructed in 3 dimensional (3D) images. The position adjustment was performed on each patient. The extraction and the position adjustments of the KCOTs were performed with 3D rendering software (VG-STUDIO-MAX 1.2®, Volume Graphics, Heidelberg, Germany) to examine the reduced focus of KCOTs visually.

1.5. The effect of marsupialization on diameter

The width (mm), depth (mm), and height (mm) were measured for each position adjustment with 3D shape analysis software (Rugle5®, Medic Engineering, Kyoto, Japan)(Fig. 2). For each patient, the change in diameter before and after marsupialization was measured.

To investigate correlations between the change in diameter and the duration after marsupialization, all measurements before marsupialization were converted to 100. The measurements after marsupialization were adjusted to the primary rate. The width, depth, height and diameters that were converted were statistically analyzed.



* 3-D visualised CT showed that all of the marsupialised KCOTs were visually reduced towards the window.

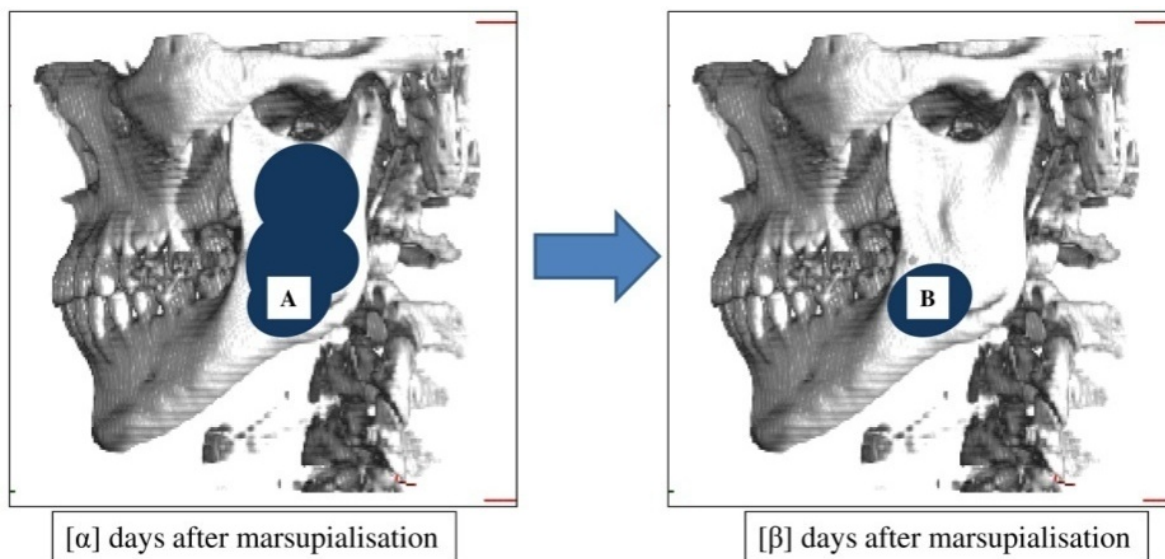
** (A) The width (B) The depth (C) The height

Figure 2. Overlaid 3-D images in the marsupialised period

1.6. The effect of marsupialization on the volume

The 3D data were used to measure the volume (mm^3) with Rugle5® and to determine the change in volume before and after marsupialization, similar to the observation on diameter.

The amount of volume reduction (mm^3) per day (V_r) was calculated using the formula (Fig. 3). V_r was defined as the quotient of the difference of the volume divided by the duration after marsupialization. To investigate correlations between the volume and V_r , these data were statistically analyzed. The regression formula obtained from former analysis of the volume was calculated using differential equations.



* The amount of the volume reduction per day (Vr) = $[B] - [A] / [\beta] - [\alpha]$

Figure 3. Measurement of Vr of KCOTs after marsupialisation. Volume value was calculated on the CT images with Rugle5®. Vr = volume value $[B]$ - volume value $[A]$ / duration $[\beta]$ - duration $[\alpha]$. The regression formula between Vr and volume value $[A]$. The duration before marsupialisation was defined as 0.

1.7. Statistical analysis

Calculation of the polynomial regression analysis is based on the determination coefficient adjusted for the degrees of freedom with statistical software (Microsoft Office Excel 2007®, Microsoft Corporation, USA) and (Statcel 2®, Hisae YANAI, Saitama, Japan). The figure of the formula showing the volume (mm^3) and the duration after marsupialization (Fig. 8) was drawn with graph drawing software (GRAPES®, Katsuhisa TOMODA, Osaka, Japan).

1.8. Approximating the reduction and the change in diameter of KCOTs in the marsupialization period

All of the marsupialized tumors were reduced towards the window (Fig. 2). The width, depth, and height of the tumors were negatively correlated with the duration after marsupialization (Fig. 4). In the converted data, the regression analysis was performed using each diameter as an outcome variable D_x (D_w = width, D_d = depth, and D_h = height), and the duration after marsupialization was calculated as the predictor variable t . Statistically significant correlations (D_w , $R = 0.88$; D_d , $R = 0.94$; D_h , $R = 0.89$) were found between D_x and t ($P < 0.001$). Thus, the results are as follows:

- $D_w = -7.3 \times 10^{-8} \times t^3 + 0.000162 \times t^2 - 0.12941 \times t + 100.1359$ ($P < 0.001$, $R = 0.88$, adjusted $R^2 = 0.76$) ... (Fig. 5)
- $D_d = 5.39 \times 10^{-5} \times t^2 - 0.0938 \times t + 99.53288$ ($P < 0.001$, $R = 0.94$, adjusted $R^2 = 0.87$) ... (Fig. 5)
- $D_h = -5.0 \times 10^{-8} \times t^3 + 0.000135 \times t^2 - 0.13246 \times t + 100.1141$ ($P < 0.001$, $R = 0.89$, adjusted $R^2 = 0.78$) ... (Fig. 5)

As shown in these results, each diameter had similar curves (Figs. 4 and 5). The regression analysis was performed in the same way, using all diameters as outcome variable D_a and duration after marsupialization as the predictor variable t .

- $D_a = -4.9 \times 10^{-8} \times t^3 + 0.00013 \times t^2 - 0.12273 \times t + 100.0652$ ($P < 0.001$, $R = 0.90$, adjusted $R^2 = 0.80$) ... (Fig. 5)

Strong correlations were found between D_a and t .

Therefore, based on these results, marsupialized KCOTs tended to be reduced towards the window equally.

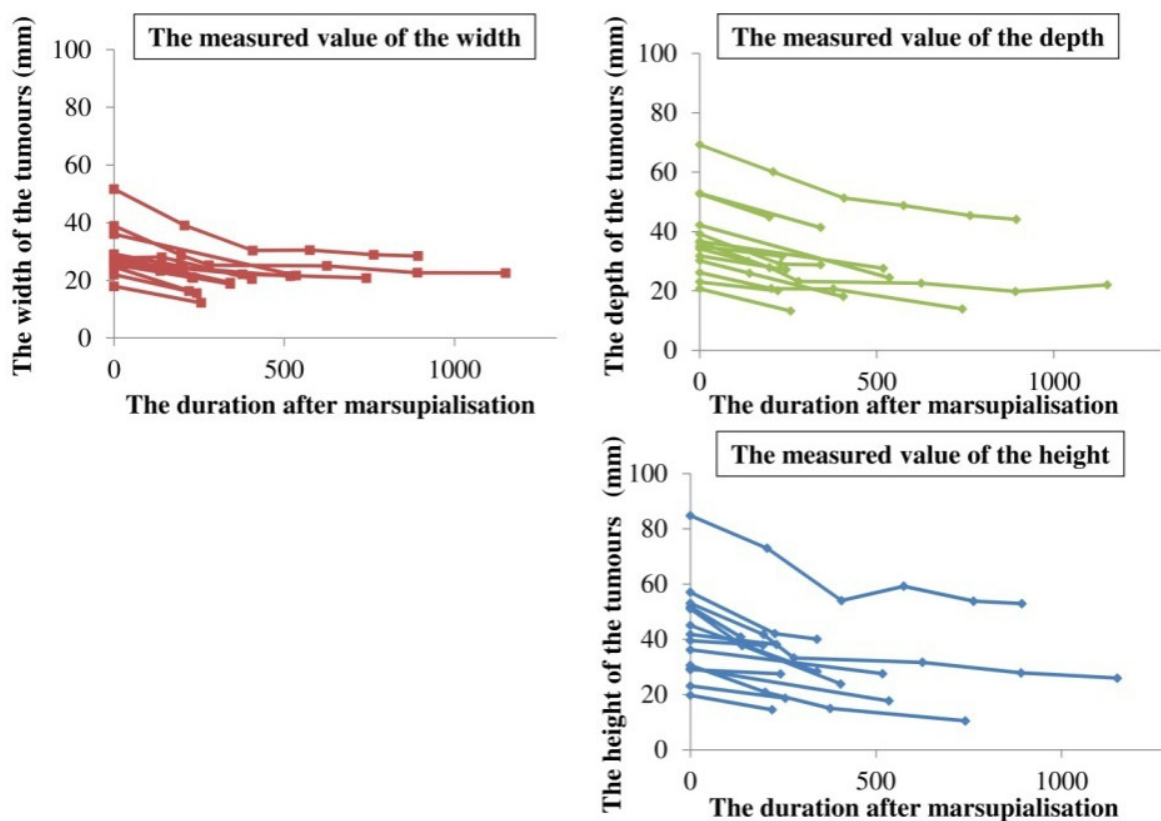


Figure 4. The width (mm), the depth (mm), and the height (mm) of KCOTs were negatively-correlated to the duration after marsupialisation.

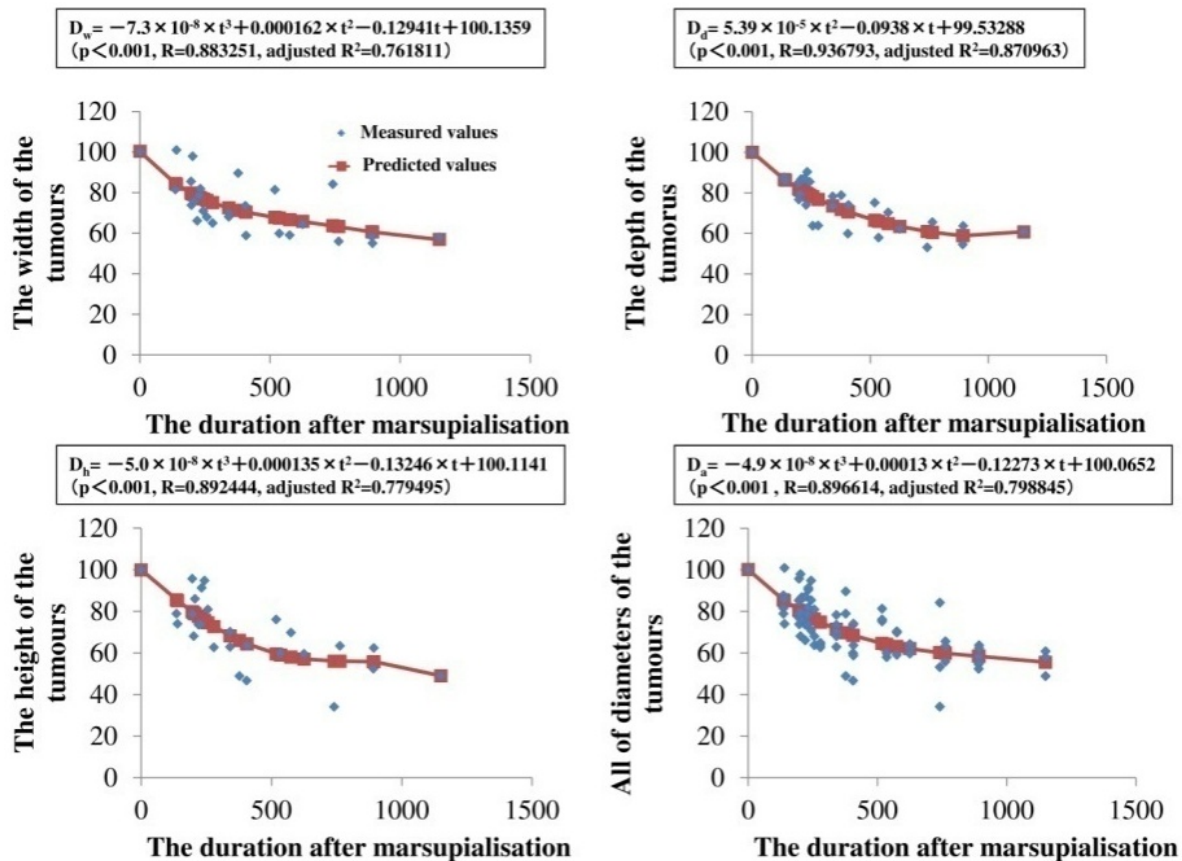


Figure 5. The regression formula of the width, depth, height and diameters of KCOTs (mm) and the duration after marsupialisation (day)

1.9. Change of the volume of KCOTs in the marsupialization period

The volume of KCOTs was negatively correlated with the duration after marsupialization. The tumor seemed to reduce more quickly the larger they were (Fig. 6). Therefore, the V_r was calculated, and the regression analysis was performed using V_r as outcome variable V_r and the volume as predictor variable V . Statistically significant correlations were found between V_r and V .

- $V_r = -0.002915 \times V + 1.23595$ ($P < 0.001$, $R = 0.92$, adjusted $R^2 = 0.85$)

Then y-intercept of the regression formula was converted to 0. There was almost no variation in the coefficient of correlation, and strong correlations were maintained between V_r and V .

- $V_r = -0.0029 \times V \dots$ (Fig. 7) ($P < 0.001$, $R = 0.92$)

Formula manipulation was performed (Fig. 8).

- $V = V_1 \times e^{-0.0029t} \dots$ (Fig. 8) (V_1 means the volume before marsupialization)

Using the above formula (Fig. 8), the half-life and one-quarter-life of the volume of KCOTs were calculated. The half-life of the KCOT volume after marsupialization was 239.0 days, and the one-quarter-life was 478.0 days.

Based on the characteristics of Napier's constant (e), the volume half-life was approximately 240 days.

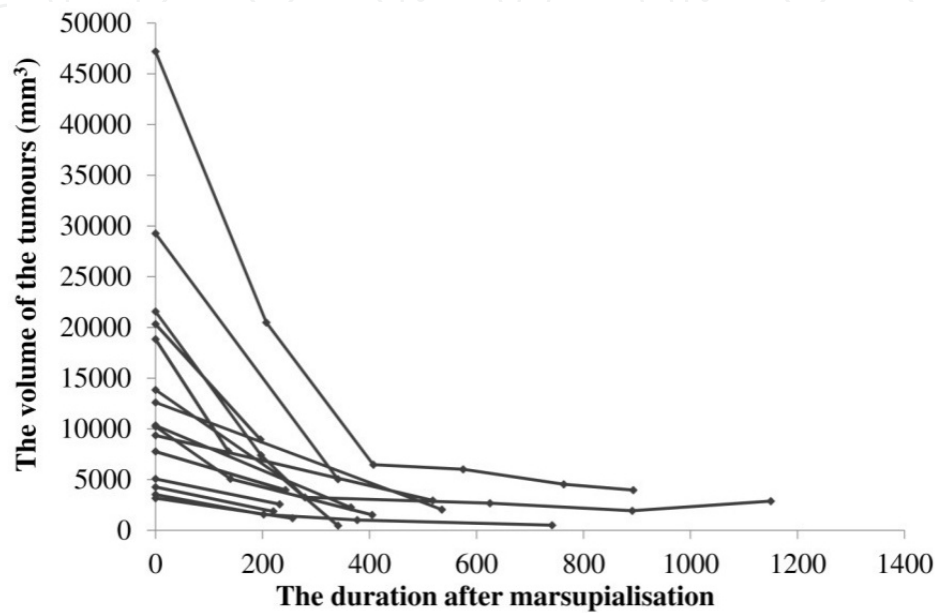


Figure 6. The measured value of the volume. The volumes of KCOTs (mm³) were negatively-correlated with the duration after marsupialisation.

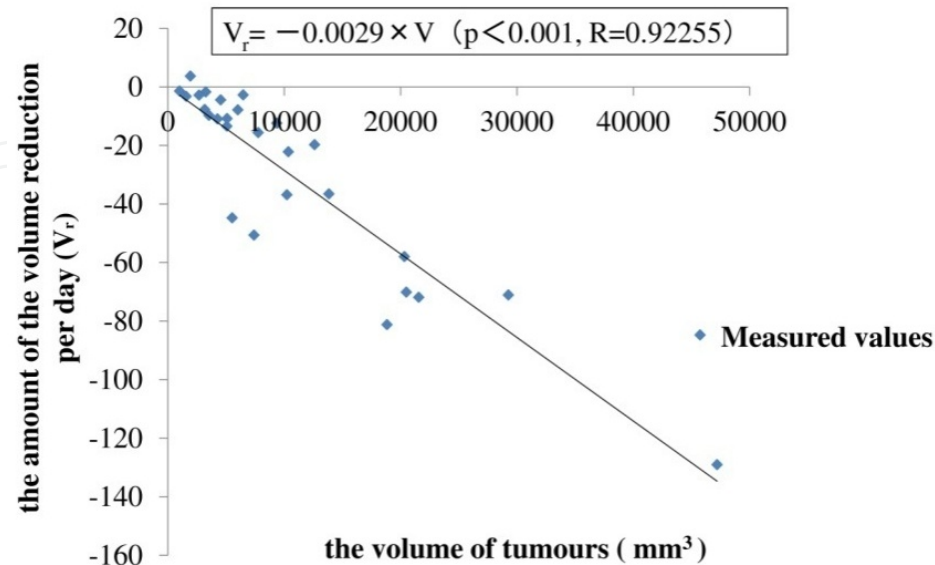


Figure 7. The regression formula of V_r and the volume (mm³)

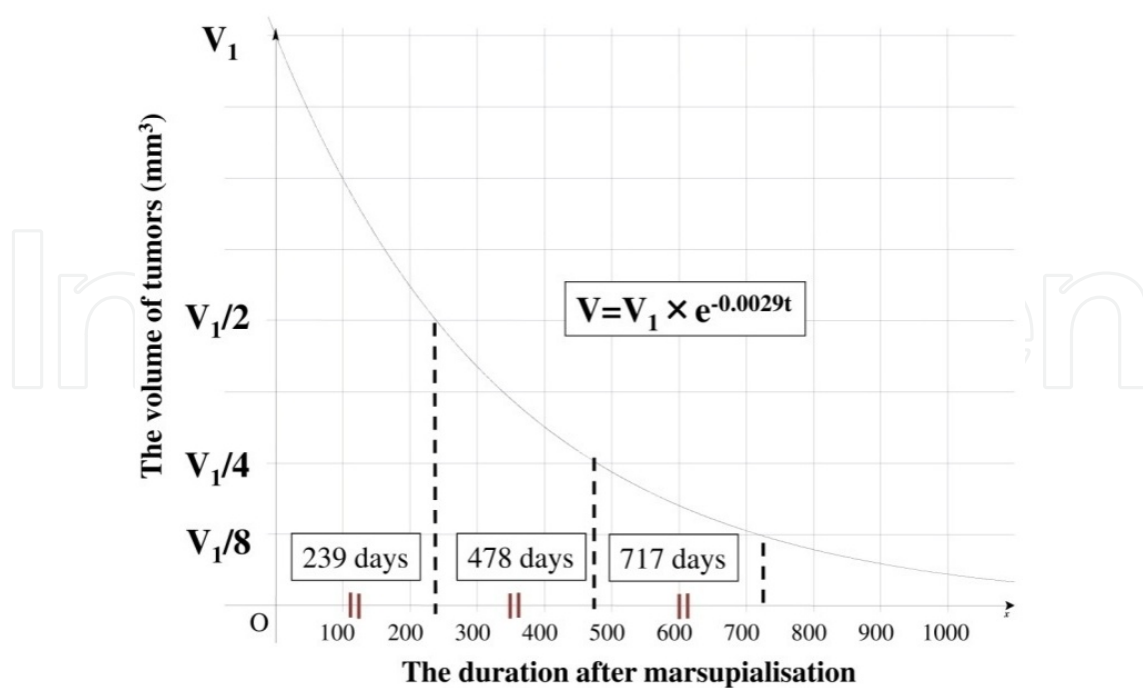


Figure 8. The formula of the volume in the KCOT (mm³) and the duration after masupialisation (day).

2. Discussion

A number of studies have described that marsupialization surgery enables patients with KCOTs to experience less damage to important structures with secondary enucleation. Marsupialization also allows substantial improvements in the symptoms and quality of life of the patients [10-12, 17, 19-21]. However, the exact mechanism that promotes the reduction of KCOTs after marsupialization is unclear. We examined the morphologic characteristics of KCOTs to predict the prognosis after marsupialization. Important aspects on the effect of marsupialization on KCOTs were uncovered.

We have shown that marsupialized KCOTs were reduced equally towards the window, as has previously been reported. This reduction form of tumors resembled those of a balloon, and this concept may be significant considering the morbidity and quality of life of the patients. It seemed that it was better to open the window against the thin peritumoral bone or inferior alveolar nerve because marsupialization tended to be the most effective in the farthest region from the window.

Furthermore, we found that there was a linear relationship between the amount of the volume reduction per day (V_r) and the volume ($V_r = -0.0029 \times V$). When we treated the effect of marsupialization as V_r , the result demonstrated that the effect of marsupialization was not the same in all cases and was affected by the duration after marsupialization. Larger tumors showed a stronger effect on marsupialization. Accordingly, it could be possible to enucleate the tumor only one month after marsupialization. V_r was proportional to the volume; therefore,

the differential equation and the formula between the volume and the duration after marsupialization ($V = V_1 \times e^{-0.0029 t}$) was applied. The volume showed the exponential decay in the duration after marsupialization, and the V-t formula indicated that the characteristics or the speed of the reduction in postmarsupialized KCOTs was dependent on the premarsupialized volume (V_1). We felt that the marsupialized tumor was not significantly reduced when it was of small size. The marsupialized tumor was reduced in the half life of 240 days, according to Napier's constant e and the exponential function. When we focused on the cyclic nature and the regression coefficient of V_r -V formula (- 0.0029), we recognized that the reduction percentage in the volume tended to be unchanged for the same duration. This result was expected based on the hypothesis that the number of cells per unit volume was not based on the surrounding tumor, and that there was no significant change in pressure in the cavity and at the molecular level after marsupialization. However, the regulatory mechanisms of how tumors are reduced or the repair mechanisms of the normal bone are unclear. Many factors must be considered, including the elasticity of the wall, and a comparison between the maxilla and mandible, with or without impacted teeth, must be made. Further studies will be required to clarify these factors.

In addition, when the KCOTs were spherical, a 50% reduction in volume resulted in a 21% reduction in the radius of the sphere. Marsupialized KCOTs tended to be equally reduced towards the window in the tumor. Therefore, a 50% reduction in volume of KCOTs resulted in a 21% reduction in diameter as well as the sphere (Fig. 9).

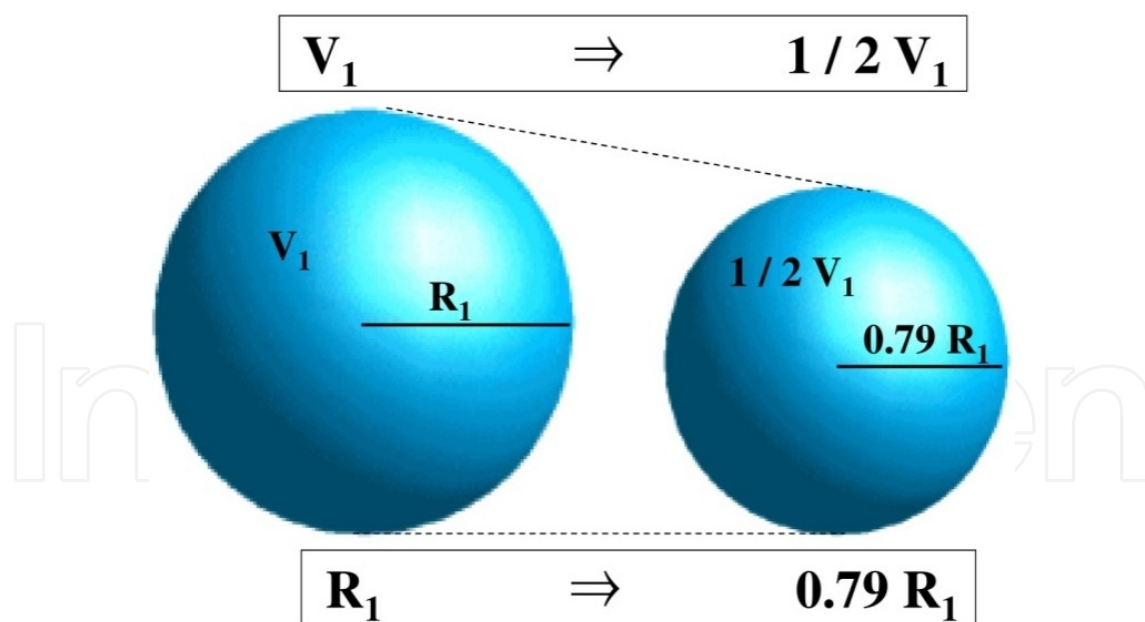


Figure 9. Differences between solid and plane in the reduction ratio. 50% of reduction in three-dimensional volume means 21% of reduction in the profile diameter or radius.

Although the data are not shown, there was no difference in the effect of treatment based on the size of opening window. The pressure within the cavity seemed to be sufficiently released when the window was opened to the degree that the biopsy results could be obtained.

We only referred to the evaluation of CT images, but we also needed follow-up with 2D images, such as a panoramic radiograph. Panoramic radiographs were easy to measure the tumor, and superior for grasping a whole image. Panoramic radiographs and intracystic cavities with sterile physiological saline were important to use as simple diagnostic methods for estimating the size of the cyst because there was a good correlation between the volume and the radio-lucent area [23].

The well-controlled cases of marsupialized mandibular KCOTs could predict the future shape of the tumor with significant accuracy. Considering these features, the primary location of the mental nerve, and the thickness of the peritumoral bone, secondary operative planning before marsupialization could be carried out using CT, which would therefore decrease the mental burden on patients. Finally, there have been various types of treatments for KCOTs. Therefore, the choice of therapy was very important because marsupialization required a long period for treatment, and the patients may not have had a medical examination before treatment was completed.

Author details

Hajime Shudou^{1*}, Masanori Sasaki², Takahiro Yamashiro¹, Shizuo Tsunomachi¹, Yasuharu Takenoshita³, Yasutaka Kubota⁴, Tomohiro Ninomiya², Toshiyuki Kawazu⁵ and Yoshihide Mori⁶

*Address all correspondence to: shudouh@yahoo.co.jp

1 Clinical Fellow, Section of Oral and Maxillofacial Surgery, Division of Maxillofacial Diagnostic and Surgical Sciences, Graduate school of Dental Science, Kyushu University, Fukuoka, Japan

2 Assistant Professor, Section of Oral and Maxillofacial Surgery, Division of Maxillofacial Diagnostic and Surgical Sciences, Graduate school of Dental Science, Kyushu University, Fukuoka, Japan

3 Associate Professor, Section of Oral and Maxillofacial Surgery, Division of Maxillofacial Diagnostic and Surgical Sciences, Graduate school of Dental Science, Kyushu University, Fukuoka, Japan

4 Lecturer, Section of Oral and Maxillofacial Surgery, Division of Maxillofacial Diagnostic and Surgical Sciences, Graduate school of Dental Science, Kyushu University, Fukuoka, Japan

5 Assistant Professor, Department of Oral and Maxillofacial Radiology, Graduate School of Dental Science, Kyushu University, Fukuoka, Japan

6 Professor, Section of Oral and Maxillofacial Surgery, Division of Maxillofacial Diagnostic and Surgical Sciences, Graduate school of Dental Science, Kyushu University, Fukuoka, Japan

References

- [1] Brannon RB: The odontogenic keratocyst A clinicopathologic study of 312 cases. part I. clinical features. *Oral Surg Oral Med and Oral Pathol*(1976). , 42, 54-72.
- [2] Gonzalez-alva, P, Tanaka, A, Oku, Y, Yoshizawa, D, Itoh, S, Sakashita, H, Ide, F, & Tajima, Y. Kusama K: Keratocysticodontogenic tumor: A retrospective study of 183 cases. *J Oral Sci*(2008). , 50, 205-212.
- [3] Browne RM: The odontogenickeratocystClinical aspects. *Br Dent J*(1970). , 128, 225-231.
- [4] Payne TF: An analysis of the clinical and histopathologic parameters of the odontogenickeratocyst*Oral Surg Oral Med and Oral Pathol*(1972). , 33, 538-546.
- [5] Pindborg, J. J. Hansen J: Studies on odontogenic cyst epithelium. 2. clinical and roentgenologic aspects of odontogenickeratocysts.*ActaPatholMicrobiolScand* (1963). , 58, 283-294.
- [6] Toller P: Origin and growth of cysts of the jaws*Ann R CollSurgEngl*(1967). , 40, 306-336.
- [7] Voorsmit, R. A, & Stoelinga, P. J. van Haelst UJ: The management of keratocysts. *J MaxillofacSurg* (1981). , 9, 228-236.
- [8] Williams, T. P. Connor FA Jr: Surgical management of the odontogenickeratocyst: Aggressive approach. *J Oral and MaxillofacSurg* (1994). , 52, 964-966.
- [9] Schmidt, B. L. Pogrel MA: The use of enucleation and liquid nitrogen cryotherapy in the management of odontogenickeratocysts. *J Oral and MaxillofacSurg* (2001). , 59, 720-725.
- [10] Brondum, N. Jensen VJ: Recurrence of keratocysts and decompression treatment. A long-term follow-up of forty-four cases. *Oral Surg Oral Med and Oral Pathol* (1991). , 72, 265-269.
- [11] Marker, P, Brondum, N, & Clausen, P. P. Bastian HL: Treatment of large odontogenickeratocysts by decompression and later cystectomy: A long-term follow-up and a histologic study of 23 cases. *Oral Surg Oral Med Oral Pathol Oral RadiolEndod*(1996). , 82, 122-131.
- [12] Tucker, W. M, & Pleasants, J. E. MacComb WS: Decompression and secondary enucleation of a mandibular cyst: Report of case. *J Oral Surg* (1972). , 30, 669-673.
- [13] Bramley P: The odontogenickeratocyst--an approach to treatment*Int J Oral Surg*(1974). , 3, 337-341.
- [14] Ephros, H. Lee HY: Treatment of a large odontogenickeratocyst using the brosch procedure. *J Oral and MaxillofacSurg*(1991). , 49, 871-874.

- [15] Bataineh, A. B. al Qudah M: Treatment of mandibular odontogenickeratocysts. *Oral Surg Oral Med Oral Pathol Oral RadiolEndod* (1998). , 86, 42-47.
- [16] Forssell, K, & Forssell, H. Kahnberg KE: Recurrence of keratocysts. A long-term follow-up study. *Int J Oral and MaxillofacSurg* (1988). , 17, 25-28.
- [17] Cranin, A. N, & Madan, S. Fayans E: Novel method of treating large cysts of jaws in children. *N Y State Dent J* (1994). , 60, 41-44.
- [18] Maurette, P. E, & Jorge, J. de Moraes M: Conservative treatment protocol of odontogenickeratocyst: A preliminary study. *J Oral and MaxillofacSurg* (2006). , 64, 379-383.
- [19] Nakamura, N, Mitsuyasu, T, Mitsuyasu, Y, Taketomi, T, & Higuchi, Y. Ohishi M: Marsupialization for odontogenickeratocysts: Long-term follow-up analysis of the effects and changes in growth characteristics. *Oral Surg Oral Med Oral Pathol Oral RadiolEndod* (2002). , 94, 543-553.
- [20] Pogrel MA: Treatment of keratocysts: The case for decompression and marsupialization *J Oral and MaxillofacSurg* (2005). , 63, 1667-1673.
- [21] Zhao, Y. F, & Wei, J. X. Wang SP: Treatment of odontogenickeratocysts: A follow-up of 255 chinese patients. *Oral Surg Oral Med Oral Pathol Oral RadiolEndod* (2002). , 94, 151-156.
- [22] Giuliani, M, Grossi, G. B, Lajolo, C, & Bisceglia, M. Herb KE: Conservative management of a large odontogenickeratocyst: Report of a case and review of the literature. *J Oral and MaxillofacSurg* (2006). , 64, 308-316.
- [23] Kubota, Y, Yamashiro, T, Oka, S, Ninomiya, T, & Ogata, S. Shirasuna K: Relation between size of odontogenic jaw cysts and the pressure of fluid within. *Br J Oral MaxillofacSurg* (2004). , 42, 391-395.