

We are IntechOpen, the world's leading publisher of Open Access books Built by scientists, for scientists

6,900

Open access books available

185,000

International authors and editors

200M

Downloads

Our authors are among the

154

Countries delivered to

TOP 1%

most cited scientists

12.2%

Contributors from top 500 universities



WEB OF SCIENCE™

Selection of our books indexed in the Book Citation Index
in Web of Science™ Core Collection (BKCI)

Interested in publishing with us?
Contact book.department@intechopen.com

Numbers displayed above are based on latest data collected.
For more information visit www.intechopen.com



Brain Mapping of Developmental Coordination Disorder

Mitsuru Kashiwagi and Hiroshi Tamai

Additional information is available at the end of the chapter

<http://dx.doi.org/10.5772/56496>

1. Introduction

This chapter discusses the brain mapping of developmental coordination disorder (DCD). DCD is a neurological disorder characterised by impaired motor coordination and impaired performance of daily activities that require motor skills. In the Diagnostic and Statistical Manual of Mental Disorders, fourth edition (DSM-IV) [1], DCD is included in the *Learning Disorders* and the *Motor Skills Disorders* sections [1]. DCD is one of the most common disorders in childhood, and it affects 5% to 6% of school-age children.

DCD is a heterogeneous disorder, and its manifestations are varied and often complex. A meta-analysis of DCD literature that was published between 1974 and 1996 showed that the greatest deficiency in these patients was in visual-spatial processing [2]. The latest meta-analysis of 128 studies suggested that children with DCD show underlying problems in the visual-motor translation (namely inverse modelling) of movements that are directed within and outside peripersonal space, adaptive postural control, and the use of predictive control (namely forward modelling), which impacts their ability to adjust movement to changing constraints in real time [3]. The underlying cognitive mechanisms are still a matter of discussion.

Previous clinical and experimental studies have indicated that motor skill difficulties in DCD children may be related to dysfunction in the parietal lobe [4], the cerebellum (CB) [5], the basal ganglia (BG) [6], the hippocampus [7] and the corpus callosum [8]. However, because the motor system is highly complex, this is not a given conclusion.

Neuroimaging, including functional magnetic resonance imaging (fMRI), will create a new standard in the understanding of the complex cognitive functions in a child's brain. Therefore, it is useful to review the data from current DCD neuroimaging studies as the next critical step

in enhancing our understanding of DCD. Clarifying DCD pathogenesis will be beneficial to clinicians as well as to children suffering from DCD.

2. Neuroimaging studies of DCD

We researched the Medline database with the terms ‘neuroimaging’ and ‘DCD’ for original research articles that were written in English. There were few DCD neuroimaging studies, and only 6 neuroimaging studies that involved the direct identification of the neural substrates responsible for DCD were available (Table 1).

| No. | Citation | types of neuroimaging study | numbers (age) | object | task | results | remarks |
|-----|-----------------|-----------------------------|---|--|---------------------------------------|--|--|
| 1 | Querne et al | fMRI | DCD, 9 control, 10 :7 boys 2 girls (9.9±1.8 years) :7 boys 3 girls (10.0±1.1years) | To assess the impact of DCD on effective connectivity applied to a putative model of inhibition. | go-nogo | [path coefficients] DCD<control, right hemisphere :striatum/parietal cortex DCD>control, left hemisphere :MFC/ACC/IPC | not motor task small sample size |
| 2 | Kashiwagi et al | fMRI | DCD, 12 control, 12 :12 boys (129.4±11.6 months) :12 boys (125.3±11.9 months) | To detect the mechanisms underlying clumsiness in DCD children. | visually guided tracking | [brain activity] tracking condition - watching condition DCD<control, left hemisphere :PPC(SPL,IPL)/postcentral gyrus [magnetic signal change for the DCD and control in IPL] negatively correlated with the task performance | The only study to reveal significant correlation of brain activation with task performance |
| 3 | Zwicker et al | fMRI | DCD, 7 control, 7 :6 boys 1 girl (10.8±1.5 years) :3 boys 4 girls (10.9±1.5years) | To determine whether patterns of brain activity differed between children with and without DCD. | trail-tracing | [brain activity] DCD<control, left hemisphere :pericuneus/superior frontal, inferior frontal, postcentral (gyrus) right hemisphere :superior temporal gyrus/insula DCD>control, left hemisphere : IPL right hemisphere :middle frontal, supramarginal, lingual, parahippocampal posterior cingulate precentral, medial frontal, superior temporal (gyrus)/cerebellar lobule VI | small sample size |
| 4 | Zwicker et al | fMRI | DCD, 7 control, 7 :6 boys 1 girl (10.8±1.5 years) :3 boys 4 girls (10.9±1.5years) | To known whether DCD children employ a different set of brain regions than control children during skilled motor practice. | motor skill practice of trail-tracing | [brain activity] retention practice - early practive DCD<control, left hemisphere :fusiform gyrus/cerebellar lobule VI IX /inferior parietal lobule right hemisphere :inferior parietal lobule/ lingual, middle frontal (gyrus)/cerebellar lobule I | motor learning paradigm small sample size |
| 5 | Maien et al | 99m-ECD SPECT | DCD, 1 woman (19 years old) | To investigate the neural correlates of DCD. | - | [decrease of perfusion] left hemisphere :medial prefrontal right hemisphere :cerebellar/occipital region | Case report 19 years old |
| 6 | Zwicker et al | Diffusion Tensor Imaging | DCD, 7 control, 7 :6 boys 1 girl (10.8±1.5 years) :3 boys 4 girls (10.9±1.5years) | To explored the integrity of motor, sensory, and cerebellar pathways in children with and without DCD. | - | Fractional anisotropy of motor and sensory tracts and diffusion parameters in cerebellar peduncles did not differ. Mean diffusivity of the corticospinal tract and posterior thalamic radiation was lower in DCD children. Axial diffusivity was significantly correlated with motor impairment scores for both the corticospinal tract and posterior thalamic radiation. | not motor task small sample size |

Table 1. DCD neuroimaging studies

2.1. Four fMRI studies

[No. 1] In 2008, Querne et al. [9] reported that DCD children exhibited abnormal brain hemispheric specialisation during development when performing a go/no-go task. Connectivity analyses in the middle frontal cortex-anterior cingulate cortex-inferior parietal cortex (IPC) network indicated that children with DCD are less able than healthy children to easily or promptly switch between go and no-go motor responses. This was the first fMRI study to clarify the attentional brain network of DCD children.

[No. 2] In 2009, Kashiwagi et al. [10] (our group) showed poor performance and less activation in the left superior parietal lobe (SPL), the left inferior parietal lobe (IPL), and the left post-

central gyrus in DCD children during visuomotor tasks. This was the first fMRI study to elucidate the neural underpinnings of DCD children by using a visuomotor task. Furthermore, a connection between the brain activity in the left IPL and task performance that represented clumsiness was suggested.

[No. 3] In 2010, Zwicker et al. [11] demonstrated that DCD children activate different brain regions compared to control children when performing the same trail-tracing task. They found that a correlation of the activation of the right middle frontal gyrus with the number of traces indicated cognitive effort in the children with DCD.

[No. 4] In 2011, Zwicker et al. [12] found that DCD children demonstrated decreased activation in cerebellar-parietal and cerebellar-prefrontal networks as well as in brain regions associated with visuospatial learning. This was the first study in DCD children to examine changes in the patterns of brain activation that were associated with skilled motor practice.

2.2. One single-photon emission computed tomography study

[No. 5] In 2010, Marien et al. [13] reported that the CB is crucially implicated in the pathophysiological mechanisms of DCD, and this reflects a disruption of the cerebello-cerebral network that is involved in executing planned actions, visuospatial cognition, and affective regulation. This was the first single-photon emission computed tomography study of children with DCD.

2.3. One diffusion tensor imaging (DTI) study

[No. 6] In 2012, Zwicker et al. [14] showed that the mean diffusivity of motor and sensory pathways is lower in DCD children. In addition, differences in the intrinsic characteristics of axons or in the extra-axonal/extracellular space may underlie some of the deficits that are observed in DCD children. This was the first DTI study in children with DCD.

3. Different patterns of activation of cerebral areas in DCD patients compared to controls in fMRI motor control tasks

In order to elucidate the main mechanisms underlying the impaired motor skills in DCD patients, we have to examine brain activities that are related to motor performances during motor control tasks. There were 3 fMRI studies (No. 2, 3, and 4) on motor control tasks in DCD patients. One study included a motor learning task. The cerebral areas listed below showed significant differences in activation between DCD children and control children during the motor control task and motor learning task and the functions of those areas.

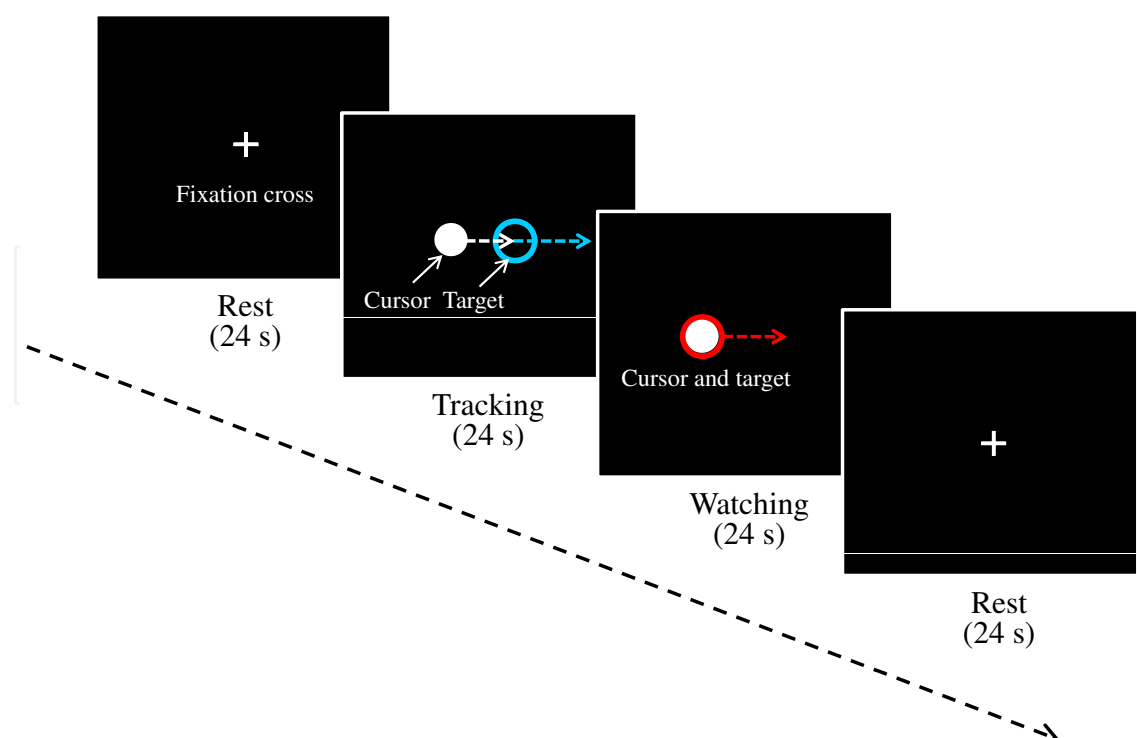


Figure 1. Our study (No. 2) design and conditions. The experiment was designed in a block manner and consisted of 3 conditions. Each condition lasted 24 s and was repeated 6 times in a pseudo-randomised order.

3.1. No. 2: Our study

3.1.1. Study design and conditions

The experiment was designed in a block manner and consisted of the following 3 conditions:

- 1) Tracking condition (TC): tracking the moving blue target by manipulating the joystick,
- 2) Watching condition (WC): watching the moving red target and white cursor without hand manipulation
- and
- 3) Resting condition (RC): looking at a fixation cross.

Each condition lasted for 24 s and was repeated 6 times in a pseudo-randomised order (Figure 1). All of the participants were trained through 40 trials of tracking before scanning. The participants achieved their best performance after several trials. Task performance was represented by the distance (pixels) between the centre of the target and the cursor. We recorded 6 sets of data on the distance and the velocity changes for each participant, and the effects of the group and the participants (within group) on these data were analysed by a two-factor nested design analysis of variance. Furthermore, the effects of the trial numbers and the participants on the task performance during the final 6 training trials and 6 scanning trials were analysed with a factorial two-way analysis of variance.

3.1.2. Behavioural data

Figure 2. (a) shows the behavioural results for a DCD child and a control child. The DCD child showed much error at the return point and particularly at the beginning point compared to the control child.

The distance between the target and the cursor and the change in the velocity of the cursor were significantly greater in the DCD group than in the control group (mean distance, 22.8 vs. 19.5 pixels, $P = 0.001$; mean velocity change, 398.5 vs. 369.9 pixels/s/s, $P = 0.013$). The number of trials did not significantly affect task performance in either group over the final 6 training trials and 6 scanning trials [training trials: DCD group, $F(5,55) = 0.41$, $P = 0.839$ and $F(5,55) = 1.20$, $P = 0.322$; control group, $F(5,55) = 0.49$, $P = 0.784$] [scanning trials: DCD group, $F(5,55) = 0.41$, $P = 0.839$; control group, $F(5,55) = 0.49$, $P = 0.780$] (Figure 2. (b)).

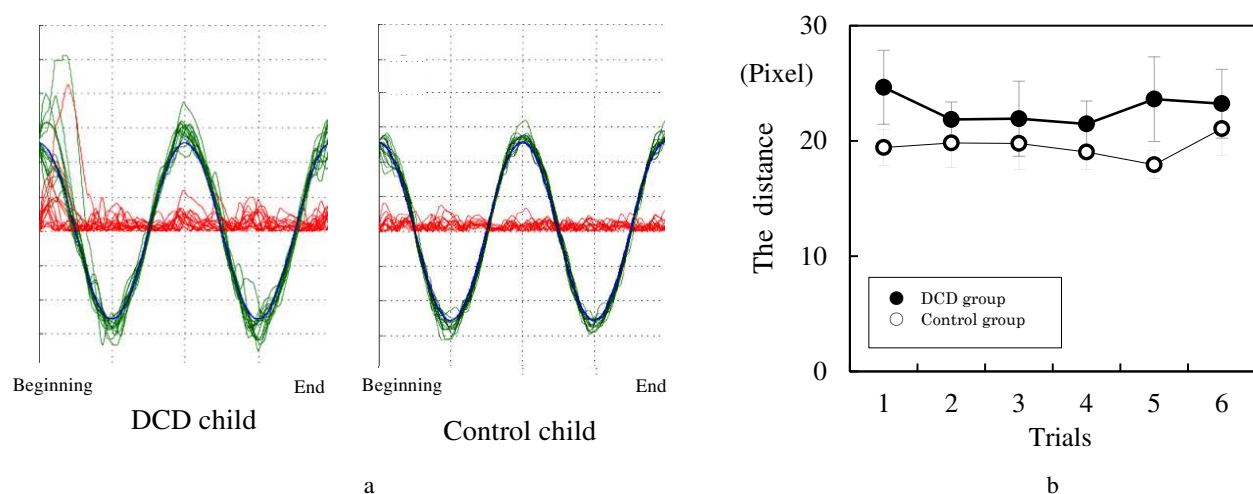


Figure 2. (a) The behavioural results of a child with DCD and a control child. The blue line shows the trajectory of the target, the green line shows the trajectory of the cursor and the red line shows the distance between the target and the cursor. (b) Mean task performances for the DCD and control groups during 6 scanning trials. The vertical bars indicate the standard errors of the means for each data point.

3.1.3. Imaging data

In the comparison of the watching condition versus the resting condition (WC - RC), both the DCD-greater-than-control and control-greater-than-DCD comparisons did not reveal significant differences in the activation maps between the groups. In the comparison of the tracking condition versus the watching condition [(TC - RC) - (WC - RC)], greater activation was not observed in the DCD-greater-than-control comparison. Inversely, the control-greater-than-DCD comparison showed differences in the activation in the left hemisphere.

Different brain activation in the comparison of the tracking condition versus the watching condition [(TC - RC) - (WC - RC)] in the visually guided tracking task between DCD patients and controls

(DCD < control only)

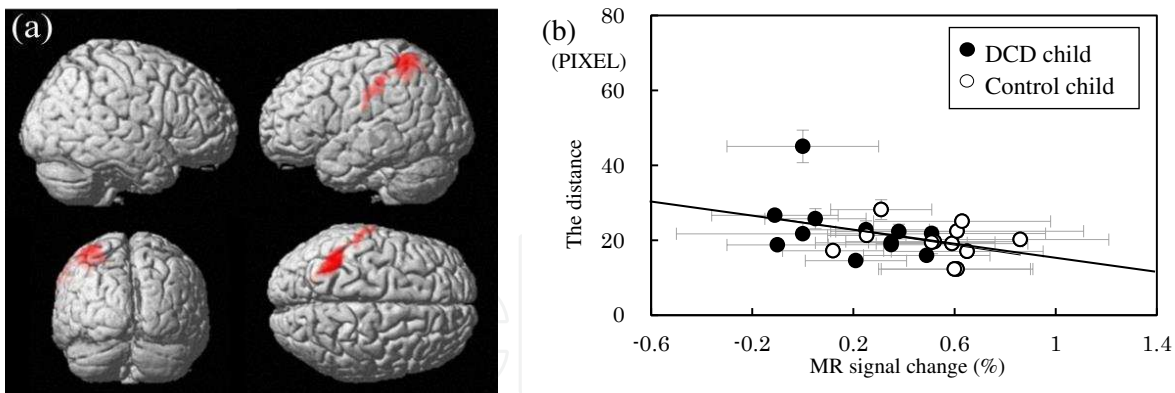


Figure 3. (a) Brain activity differences between the DCD and control groups. In the comparison of the tracking condition versus the watching condition, the control-greater-than-DCD comparison showed differences in left hemisphere activation in the left SPL and IPL and the left postcentral gyrus ($P < 0.001$ at the voxel level and $P < 0.05$ with a correction for multiple comparisons at the cluster level); (b). Mean task performances and magnetic resonance signal changes for the DCD and control groups in the IPC. The vertical bars indicate the standard errors of the means, and the horizontal bars indicate the 90% confidence intervals for each data point.

Left posterior parietal cortex (SPL and IPL): The main brain region involved in skilled motor functions, eye movements, multimodal encoding of locations near the head, reaching and pointing movements with the arm and finger, grasping movements that require preshaping of the hand [15], tool use and motor attention [16], internal representation of the dynamic body schema [17], hand movements [18] and motor imagery [19]. **Left postcentral gyrus:** proprioceptive control of movement [20]. (Table 2, Figure 3.(a).)

The correlations between task performance and the maximal magnetic resonance signal changes within a diameter of 8 mm of each local maximum were analysed. Only the magnetic resonance signal changes in the left IPL negatively correlated with task performance [$r, -0.413$; $P < 0.05$] (Figure 3(b)).

| Region | Cluster | | | MNI coordinates (mm) | | | |
|-------------------------------|---------|------|------------------------|----------------------|-----|-----|----|
| | L/R | Size | P _{corrected} | Z | x | y | z |
| superior parietal lobe (BA7) | L | 1024 | 0.001 | 4.02 | -40 | -48 | 66 |
| postcentral gyrus (BA2) | L | | | 3.89 | -68 | -20 | 34 |
| inferior parietal lobe (BA40) | L | | | 3.83 | -36 | -52 | 50 |

BA, Brodmann area; L, left; R, right

Table 2. Cluster size, Z-values, and coordinates

3.2. No. 3: Zwicker et al. study

Different brain activation in the trail-tracing task between DCD patients and controls

(DCD < control)

Left precuneus: visuospatial processing and initiation of movement programming [21, 22]. **Left superior frontal gyrus:** spatially oriented processing [23]. **Left inferior frontal gyrus:** inhibitory control over motor responses [24]. **Left postcentral gyrus:** motor control and motor learning [25, 26]. **Right insula:** motor control [27], motor learning [28] and error processing [29].

(DCD > control)

Left IPL: interpretation of sensory information [30, 31]. **Right supramarginal gyrus:** visuo-motor/visuospatial processing [32, 33]. **Right posterior cingulate gyrus:** spatial attention [34]. **Right lingual gyrus:** visuospatial processing [35]. **Right precentral and parahippocampal gyri:** spatial memory [36-38]. **Right CB (lobule VI):** spatial processing [39].

3.3. No. 4: Zwicker et al. study

Different brain activation of the retention condition versus the early condition in the trail-tracing task between DCD patients and controls

(DCD < control only)

Right cerebellar crus I: working memory and executive functions [40]. **Left cerebellar lobule VI:** part of the sensorimotor network of the CB [40], spatial processing [41], performance of a variety of tasks, including serial reaction time tasks [42], motor sequence learning [43], reaching tasks [44] and planned, discretely aimed arm movements [45] as well as the magnitude of motor correction during visuomotor learning [46]. **Left cerebellar lobule IX:** unclear [40]. **Right IPL:** spatial working memory [47]. **IPL:** the processing of sensory information and visual feedback [48]. **Right dorsolateral prefrontal cortex:** the initial stages of explicit motor learning [49], motor and visuomotor sequences [50, 51] and attentional control [52]. **Left fusiform gyrus:** higher level visual and visuospatial processing during the consolidation of visuomotor learning [53]. **Right lingual gyrus:** visuospatial processing [54].

4. Discussion

4.1. Previous studies of DCD (terminology, clumsiness, motor learning, and brain area)

4.1.1. What is DCD? Historical perspectives

At the beginning of the 20th century, an awareness of different levels of motor performance was clearly described in studies that identified the motor abilities of children as very clever, clever, medium, awkward or very awkward [55]. As early as 1926, Lippitt was concerned specifically with poor muscular coordination in children [56]. Orton's (1937) discussion of developmental apraxia or abnormal clumsiness was strongly influenced by ideas about adult apraxia and damage to the dominant hemisphere [57]. Since the early 1960s, many terms have been used to describe children whose motor difficulties interfere with daily living, and these include developmental apraxia and agnosia, minimal cerebral dysfunction (Wigglesworth,

1963) [58], minimal brain dysfunction (Clements, 1966) [59], minimal cerebral palsy (Kong, 1963) [60] and developmental dyspraxia [61].

At a 1994 consensus meeting in London, Ontario (Polatajko et al., 1995) [62], a multidisciplinary group of internationally recognised researchers who work with children with motor clumsiness agreed to use the term developmental coordination disorder as described by the American Psychiatric Association (APA) in the DSM-III-R (APA, 1987) and revised in DSM-IV (APA, 1994).

4.1.2. *What is clumsiness? What is dexterity?*

Clumsiness is defined by Morris and Whiting as a maladaptive motor behaviour in relation to expected or required movement performance [63]. The antonym of clumsiness is dexterity.

Dexterity is the ability to find a motor solution for any external situation or to adequately solve any emerging motor problem correctly (adequately and accurately), quickly (with respect to both decision making and achieving a correct result), rationally (expediently and economically) and resourcefully (quick-wittedly and initiatively). In many movements and actions, there are no absolutely unpredictable events, but these movements nevertheless require quick and accurate movement adaptation to external events that cannot be predicted with certainty. This accurate movement adaptation is important for dexterity. The heart of the problem is to quickly and correctly find a solution in conditions of an unexpectedly changed environment. Dexterity apparently is not in the motor action itself but is revealed by its interaction with changing external conditions, including the uncontrolled and unpredicted influences from the environment. The established essential feature of dexterity is that it always refers to the external world. Moreover, dexterity is a complex activity. Real-life movements have an element of adaption to various, although perhaps minor, unexpected events [64].

Quick and correct motion is fundamental to dexterity performance. Quick motion means the rapid initiation of action and fleetness of the performance itself. Accurate motion implies spatially and temporally accurate performance. As we move more rapidly, we become more inaccurate in terms of the goal we are trying to achieve. The adage *haste makes waste* has been a long-standing viewpoint about motor skills.

Identifying optimal measurements of skill learning is not trivial [65]. Previous studies have typically defined skill acquisition in terms of a reduction in the speed of movement execution or reaction times, increases in accuracy or decreases in movement variability. Yet, these measurements are often interdependent, in that, faster movements can be performed at the cost of reduced accuracy and vice versa, which is a phenomenon which has often been referred to as the speed-accuracy trade-off. The principles of speed-accuracy trade-offs, which are known as Fitts' law, are specific to the goal and nature of the movement tasks [66]. One solution to this issue is through the assessment of changes in the speed-accuracy trade-off functions. Therefore, we should assess task performances with both speed and accuracy. The visually guided tracking task that we adopted in our fMRI study has been experimentally used for evaluating motor skills. We assessed task performance as the change in the velocity of the cursor for speed and the distance between the target and the cursor for accuracy.

4.1.3. *What is motor learning?*

Children with DCD have difficulties with motor performance and motor learning [67]. Most clinicians and researchers agree that difficulty with motor learning is a key feature of DCD.

Motor learning depends on maturation, experience, and active learning. Motor learning has been described as a set of processes that are associated with practice or experience and that lead to relatively permanent changes in the capabilities for producing skilled actions [68]. Motor skill learning means, in other words, dexterity learning. Therefore, as mentioned above, accurate movement adaptation is an important fact in motor skill learning.

For motor learning, 3 main theories apply. Fitts and Posner (1967) distinguished the following 3 phases of motor learning: cognitive, associative and autonomous [69].

Hikosaka and colleagues proposed a model of motor skill learning. According to this model, 2 parallel loop circuits operate in the learning of the spatial and motor features of sequences. Whereas the learning of spatial coordinates is supported by the frontoparietal associative BG-CB circuit, the learning of motor coordinates is supported by the primary motor cortex-sensorimotor BG-CB circuit. According to this model, transformations between the 2 coordinate systems rely on the contribution of the supplementary motor area (SMA), the pre-supplementary motor area (preSMA) and the pre-motor cortices. Importantly, it has been suggested that the learning of spatial coordinates is faster, yet requires additional attentional and executive resources that are putatively provided by prefrontal cortical regions [70] (Figure 4. (a)).

Similarly, on the basis of brain imaging studies, Doyon and Ungerleider (Doyon and Ungerleider's model of motor skill learning) [71] proposed that cerebral plasticity is important within the cortico-striatal and cortico-cerebellar systems during the course of learning a new sequence of movements (motor sequence learning) or the adaptation to environmental perturbations (motor adaptation).

This model proposes that, depending upon the nature of the cognitive processes that are required during learning, both motor sequence and motor adaptation tasks recruit the following similar cerebral structures early in the learning phase: the striatum, CB, motor cortical regions, in addition to prefrontal, parietal, and limbic areas. Dynamic interactions between these structures are likely to be crucial in establishing the motor routines that are necessary for the learning of the skilled motor behaviour. A shift of the motor representation from the associative to the sensorimotor striatal territory can be seen during sequence learning, whereas additional representation of the skill can be observed in the cerebellar nuclei after practice in a motor adaptation task. When consolidation has occurred, the subject has achieved asymptotic performance, and their performance has become automatic; however, the neural representation of a new motor skill at that stage is believed to be distributed in a network of structures that involves the cortico-striatal or cortico-cerebellar circuit, depending on the type of motor learning acquired. At this stage, the model suggests that the striatum is no longer necessary for the retention and execution of the acquired skill for motor adaptation; regions representing the skill at this stage include the CB and related cortical regions. In contrast, a reverse pattern of plasticity is thought to occur in motor sequence learning, such that the CB

is no longer essential with extended practice, and the long-lasting retention of the skill is believed at this stage to involve representational changes in the striatum and the associated motor cortical regions (Figure 4. (b)).

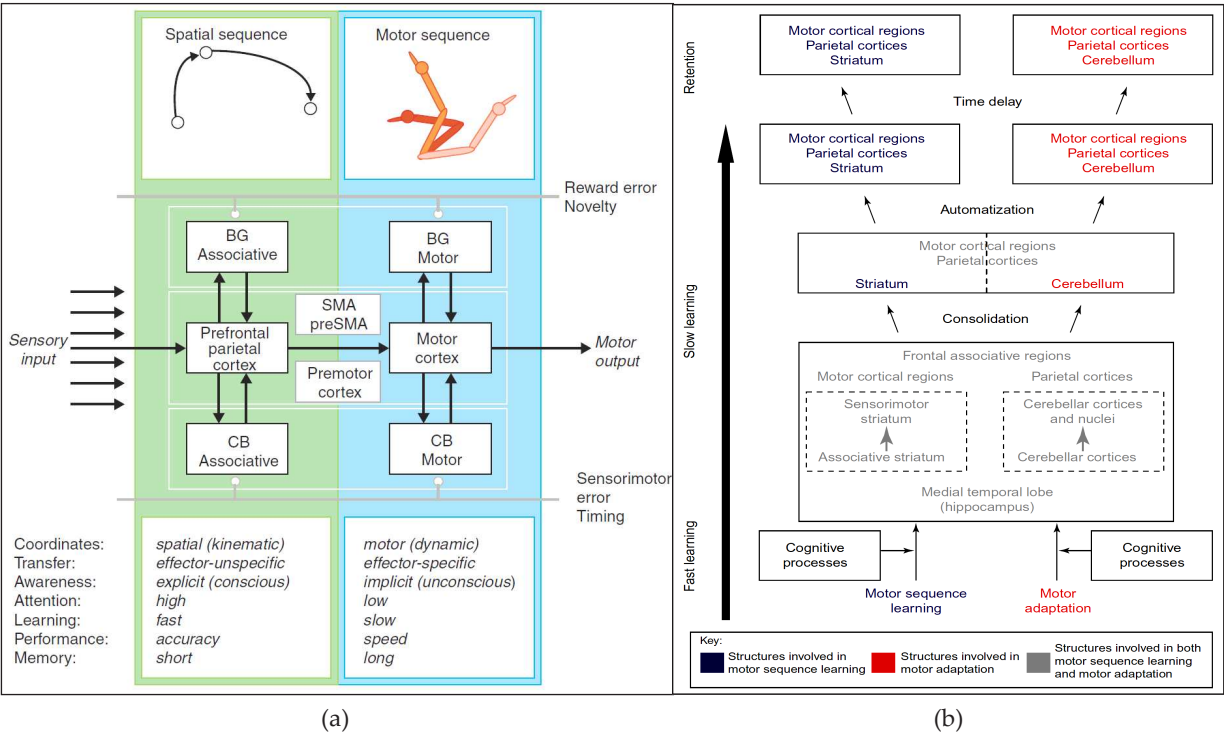


Figure 4. (a). Hikosaka et al.'s scheme of motor skill learning. The figure is from Curr Opin Neurobiol 2002;12(2) 217-222.; (b). Doyon et al.'s model of skill learning. The figure is from Curr Opin Neurobiol 2005;15(2) 161-167.

Both models share the view that motor skill learning involves interactions between distinct cortical and subcortical circuits that are crucial for the unique cognitive and control demands that are associated with this stage of skill acquisition [65].

4.1.4. Where is brain area associated with DCD?

The parietal lobe

The parietal lobe plays a critical role in numerous cognitive functions, particularly in the sensory control of action [72]. As we know, lesions in the left posterior parietal cortex (PPC) are associated with apraxia, which is a higher order motor disorder, whereas lesions in the right PPC are associated with unilateral neglect, which is an attentional disorder [73].

The results of a meta-analysis of the information processing deficits that are associated with DCD children showed that DCD children have significantly poorer visual spatial processing than healthy controls [2, 3]. This evidence suggests that the parietal lobe may be implicated in DCD children because of its primary role in the processing of visual spatial information [74]. In addition, DCD children are less competent in their ability to recognise emotion [75], which has been linked to parietal lobe involvement [76]. Some clinical studies have supported the

notion that the parietal lobe is associated with the mechanisms underlying the impaired motor skills in DCD children. Wilson et al. [77] conducted a study on procedural learning in DCD children and stated that the neurocognitive underpinnings of the disorder may be located in the parietal lobe and not in the BG. Another study involving mental rotation tasks indicated that DCD children might have dysfunction in the parietal lobe, which is involved in the internal representation of the movement [78]. In a recent study, Hyde et al. found that children with DCD show a similar response pattern as patients with lesions of the PPC on a number of paradigms that assess aspects of internal modelling. This has led to the hypothesis that DCD may be attributable to dysfunction at the level of the PPC [79].

Furthermore, a study on imagined motor sequences revealed that the performance of real and imagined tasks are dissociated in DCD children; this finding indicates that a disruption in the motor networks of the parietal lobe is associated with the generation of the internal representations of motor acts [80]. In addition, this group found that the ability of motor imagery in DCD children varied according to their level of motor impairment [81], and motor imagery training ameliorated the clumsiness in DCD children [82]. Recommendations of the definition, diagnosis, and intervention of DCD by the European Academy for Childhood Disability [3] only refer to the fact that Katschmarsky considered parietal dysfunction an underlying organic defect in DCD children from their study [4].

The cerebellum

The CB is related to motor skill learning. Given the CB's role in motor coordination and postural control, it may be involved in the neuropathology of DCD [74]. Geuze reported that the major characteristics of poor control in DCD are the inconsistent timing of muscle activation sequences, co-contraction, a lack of automation and the slowness of response. Converging evidence indicates that cerebellar dysfunction contributes to the motor problems of children with DCD [83]. Motor adaptation, which is also thought to reflect cerebellar function [71], has been demonstrated in children with DCD [84]. Waelvelde reported that the parameterization of movement execution in the Rhythmic Movement Test in children with DCD was significantly less accurate both in time and in space than the performance of same-aged typically developing children. The data of that study support the notion that some children with DCD manifest impairments in the generation of internal representations of motor actions and support the hypothesis that there is some form of cerebellar dysfunction in some children with DCD [85].

The basal ganglia

The BG is involved in motor control and motor skill learning. Clumsiness is a term that is associated in childhood with problems in the learning and execution of skilful movements, the neuronal basis of which is, however, poorly understood. Groenewegen reported that, as far as deficient motor programming is involved, the BG probably plays a role [86]. Wilson et al. did not identify any evidence that the BG is implicated in DCD [77].

The hippocampus

Hippocampal, cortico-cerebellar, and cortico-striatal structures are crucial for building the motor memory trace [71]. Neural structures, such as the hippocampus, parietal cortex, and CB,

have been proposed to contribute to the process of learning new motor sequences. Gheysen et al. found that the sequence learning problems of DCD children might be located at the stage of motor planning rather than at sequence acquisition [87]. The fact that the hippocampus and CB could be involved in the neuropathology of DCD has been frequently proposed given their function in motor coordination and adaptation [71,88].

The corpus callosum

Sigmundsson reported that only DCD children showed significant performance differences in favour of the preferred hand in visual/proprioceptive or proprioceptive conditions. This finding was thought to suggest that the developmental lag that is exhibited by DCD children might have pathological overtones that are possibly related to the development of the corpus callosum [89].

4.2. Present studies of DCD (neuroimaging studies and current conclusion)

4.2.1. Recent neuroimaging studies

The parietal lobe and CB are key brain regions that have been highlighted in recent neuroimaging studies of the visuomotor performance of children with DCD. The brain functions of these 2 regions are known to involve the motor adaptation of motor learning in the past 2 models of motor skill learning. In addition, the parietal lobe and striatum are known to be involved in the motor sequence learning of motor learning. Accordingly, the parietal lobe is a region that is associated with sensory input, motor output, motor adaptation, and motor sequence learning.

In our results, parietal dysfunction reflected the difference in brain activities between DCD and control children during the phase of automation. The task in our study was easy to master, and, therefore, the performances of DCD patients and controls had already reached their plateau before the scanning trials. Thus, this study did not involve motor learning effects. In our fMRI task, the speed of the target was changed sinusoidally during its 12-s round trip. Consequently, we studied both motor sequence learning and motor adaptation in our fMRI task. We reported that DCD children showed poor performance and less activation in the left PPC and postcentral gyrus during the visuomotor task. Thus, a connection was suggested between brain activity of the left PPC and clumsiness.

In the results from other studies, dysfunction of the CB may reflect the different brain activities of consolidation conditions versus cognitive processes between DCD children and controls during the early–slow learning phases. In that study, tracing accuracy in control children improves from early practice to consolidation and shows increased activation in several brain regions. In contrast, the DCD children did not show any improvements in tracing accuracy. The authors noted that further work with a larger sample is needed to confirm the hypothesis that these areas of brain activation may contribute to improved motor performance. In this study design, the results mainly showed motor adaptation.

4.2.2. Current conclusion: Why are DCD children clumsy?

DCD is a disorder of impaired performances in daily activities that require motor skill. The movement parameters of daily activities appear to be encoded by delayed recall and require easy motor skills. Even though DCD children can learn easy motor skills, why they usually require more practice than healthy children and their quality of movement may be compromised is a pressing question.

From the viewpoints of the recent model of motor skill learning, previous studies, and the recent neuroimaging studies, DCD children have some difficulties with the cognitive processes in the fast learning phase, consolidation in the slow learning phase and automation in the retention phase during simple and easy motor skill learning (motor sequence learning and motor adaptation). Accordingly, it is not always easy for DCD children to perfectly acquire even simple motor skills. In fact, real-life movements that are required for daily simple and easy activities require an element of adaption to various, although perhaps minor, unexpected events. Therefore, we assumed that DCD children always seem to be required to adapt to the daily simple and easy activities as unexpected new motor learning every day because it is hard for DCD children to perfectly consolidate motor skills. In addition, DCD children show that the more a task demands the integration and adaptation of different information, the more vulnerable it is. Accordingly, we considered that motor adaptation is more important than motor sequence learning for DCD children.

Given that the main clinical finding in DCD children is motor adaptation, dysfunction in the parietal lobe and CB contributes to the mechanism underlying DCD. In addition, considering that DCD children have problems with sensory input and motor output, we conclude that the parietal lobe is the main neural substrate that is responsible for DCD.

4.3. Future studies of DCD (mirror neuron system, functional connectivity approaches, default mode network, intervention, and motor imagery training)

4.3.1. The mirror neuron system hypothesis

DCD includes impairments in motor skills, motor learning, and imitation. A better understanding of the neural correlates of the motor and imitation impairments in DCD children holds the potential for informing the development of treatment approaches that can address these impairments. In recent years, the discovery of a frontoparietal circuit, which is known as the mirror neuron system (MNS), has enabled researchers to better understand imitation, general motor functions, and aspects of social cognition. Given its involvement in imitation and other motor functions, they propose that dysfunction in the MNS may underlie the characteristic impairments of DCD [90].

4.3.2. Functional connectivity approaches

Most past studies of brain function have built on the concept of the localisation of function, in that different brain regions support different forms of information processing. Yet, no brain region exists in isolation. Information flows between the regions through the action potentials

that are conducted by axons, which are bundled into large fibre tracts. For more than a century, neuroanatomists have mapped the anatomical connections between brain regions in an attempt to understand the structural connectivity of the brain. While much remains to be discovered, the study of the anatomical connections between brain regions has provided a cornerstone for neuroscience research.

Despite the value of this anatomical research, the knowledge of the structural connections between brain regions can only provide a limited picture of information flow in the brain. Descriptions of functional connectivity or of how the activity of one brain region influences activity in another brain region are also needed. Many researchers who are interested in functional connectivity have adopted fMRI techniques because of their utility for measuring changes in activation throughout the entire brain. This approach is useful for the brain mapping of DCD [91]

4.3.3. *Default mode network*

Functional brain imaging studies with fMRI in normal human subjects have consistently revealed expected task-induced increases in regional brain activity during goal-directed behaviours. These changes are detected when comparisons are made between a task state, which is designed to place demands on the brain, and a resting state with a set of demands that are uniquely different from those of the task state. Functional imaging studies should consider the need to obtain information about the baseline.

Researchers have also frequently encountered task-induced decreases in regional brain activity, even when the control state consists of the subject lying quietly with their eyes closed or passively viewing a stimulus. Whereas cortical increases in activity have been shown to be task specific and therefore to vary in location depending on the task demands, many decreases appear to be largely task independent and to vary little in their location across a wide range of tasks. This consistency with which certain areas of the brain participate in these decreases makes us wonder whether there might be an organised mode of brain function that is present as a baseline or default state [92]. Spatial patterns of spontaneous fluctuations in blood oxygenation level-dependent signals reflect the underlying neural architecture. The study of the brain networks that are based on these self-organised patterns is termed resting-state fMRI.

The notion of a default mode of brain function (DMN) has taken on certain relevance in human neuroimaging studies and in relation to a network of lateral parietal and midline cortical regions that show prominent activity fluctuations during the resting state [93]. The DMN is a prominent large-scale brain network that includes the ventral medial prefrontal cortex, the posterior cingulate/retrosplenial cortex, the IPL, the lateral temporal cortex, dorsal medial prefrontal cortex, and hippocampal formation [94]. The parietal lobe is also an important area in the DMN. The DMN is unique in terms of its high resting metabolism, deactivation profile during cognitively demanding tasks and increased activity during the resting state and high-level social cognitive tasks. There is growing scientific interest in understanding the DMN underlying the resting state and higher-level cognition in humans. A recent study found that a goodness-of-fit analysis applied at the individual subject level suggested that the activity in

the default-mode network might ultimately prove to be a sensitive and specific biomarker for incipient Alzheimer's disease [95].

The functional and structural maturation of networks that are comprised of discrete regions is an important aspect of brain development. The putative functions of the DMN, as well as the maturation of cognitive control mechanisms, develop relatively late in children, and they are often compromised in neurodevelopmental disorders, such as autism spectrum disorders and attention-deficit/hyperactivity disorder [96]. The relationship between DMN structure and function in DCD children is not known. Examining the developmental trajectory of the DMN is important not only for the understanding of how the structures of the brain change during development and impact the development of key functional brain circuits, but also for understanding the ontogeny of cognitive processes that are subserved by the DMN [97]. These multimodal imaging analyses will be important for a better understanding of how local and large-scale anatomical changes shape and constrain typical and atypical functional development. Future research should systematically explore the developmental trajectory of the DMN in a normal population and compare this with the maturation of the DMN in DCD children.

4.3.4. Intervention

Can dexterity be individually developed? Is it an exercisable capacity? The answer is positive and multifaceted. It is obvious that natural, inborn, and constitutional prerequisites for dexterity are and will be as different in different persons as their other psychophysical abilities. The attainable individual peaks of development, the degrees of difficulty, and the necessary amount of time for achieving a certain result will inevitably cause great individual variations. It is much more important to state that all natural prerequisites for dexterity can be developed. Both aspects of the structural complex that result in use dexterity can be exercised and developed.

In a systematic review of interventions on DCD children, Hillier generally concluded that an intervention for DCD is better than no intervention [98]. Independently, the guideline group performed a systematic literature search of studies that were published from 1995 to 2010. There is sufficient evidence that physiotherapy and/or occupational therapy intervention are better than no interventions for DCD children [3].

There are many different treatment approaches for DCD. The approaches to interventions are divided into the following 2 categories: process-oriented or bottom-up and task-oriented or top-down [99]. Process-oriented approaches include sensory integration therapy, kinaesthetic training, and perceptual motor therapy. Task-oriented approaches include Cognitive-Orientation to Occupational Performance, neuromotor task training, and motor imagery training [3]. In addition, studies have shown that process-oriented approaches may sometimes be effective but are less so than the task-oriented approaches, which are based on motor learning theories [100].

4.3.5. Motor imagery training

Motor imagery (MI) training is a cognitive approach that was developed by Wilson [101]. It uses the internal modelling of movements that facilitate the child in predicting the consequences for actions in the absence of overt movement. MI is a new intervention method for DCD children. The past literature has already described MI training as a method in stroke rehabilitation [102, 103]. MI training was investigated once in a randomised controlled trial, and it showed a positive effect if it was combined with active training [81].

In an fMRI study that investigated whether the neural substrates mediating MI differed among participants showing high or poor MI ability, intergroup comparisons revealed that good imagers exhibited more activation in the parietal and ventrolateral premotor regions, which are known to play a critical role in the generation of mental images [104]. Our data also indicated that dysfunction in the parietal lobe, such as that in motor imagery, might be a mechanism underlying the motor skill deficits in DCD children. Thus, from our data, MI training may be a helpful strategy for DCD children.

5. Conclusion

From clinical and neuroimaging studies and models of motor skill learning, we conclude that parietal lobe dysfunction is the main mechanism underlying DCD. In addition, the parietal lobe is a key area of the MNS and MI training. However, the parietal lobe is not the only neural correlate brain region in DCD. Dysfunctions in the CB, striatum, and hippocampus are also related to the neurobiology underlying DCD. In order to further elucidate the pathogenesis and interventions of DCD, additional neuroimaging studies that include DMN and DTI are needed that link the neural networks and the functional connectivity of brain regions during motor performance.

Author details

Mitsuru Kashiwagi^{1,2} and Hiroshi Tamai³

1 Department of Pediatrics, Hirakata-City Hospital, Osaka, Japan

2 Department of Developmental Brain Science, Osaka Medical College, Osaka, Japan

3 Department of Pediatrics, Osaka Medical College, Osaka, Japan

References

- [1] American Psychiatric Association. Diagnostic and statistical manual of mental disorders (4th ed). Washington DC: American Psychiatric Association; 1994.
- [2] Wilson PH, McKenzie BE. Information processing deficits associated with developmental coordination disorder: a meta-analysis of research findings. *J Child Psychol Psychiatry* 1998;39(6) 829-840.
- [3] Blank R, Smits-Engelsman B, Polatajko H, Wilson P. European Academy for Childhood Disability (EACD): recommendations on the definition, diagnosis and intervention of developmental coordination disorder (long version). *Dev Med Child Neurol* 2012;54(1) 54-93.
- [4] Katschmarsky S, Cairney S, Maruff P, Wilson PH, Currie J. The ability to execute saccades on the basis of efference copy: impairments in double-step saccade performance in children with developmental co-ordination disorder. *Exp Brain Res* 2001;136(1) 73-78.
- [5] Van Waelvelde H, De Weerdts W, De Cock P, Janssens L, Feys H, Smits Engelsman BC. Parameterization of movement execution in children with developmental coordination disorder. *Brain Cogn* 2006;60(1) 20-31.
- [6] Groenewegen HJ. The basal ganglia and motor control. *Neural Plast* 2003;10(1-2) 107-120.
- [7] Gheysen F, Van Waelvelde H, Fias W. Impaired visuo-motor sequence learning in Developmental Coordination Disorder. *Res Dev Disabil* 2011;32(2) 749-756.
- [8] Sigmundsson H. Perceptual deficits in clumsy children: inter- and intra-modal matching approach-a window into clumsy behavior. *Neural Plast* 2003;10(1-2) 27-38.
- [9] Querne L, Berquin P, Vernier-Hauvette MP, Fall S, Deltour L, Meyer ME, de Marco G. Dysfunction of the attentional brain network in children with developmental coordination disorder: A fMRI study. *Brain Res* 2008;1244 89-102.
- [10] Kashiwagi M, Iwaki S, Narumi Y, Tamai H, Suzuki S. Parietal dysfunction in developmental coordination disorder: a functional MRI study. *Neuroreport* 2009;20(15) 1319-1324.
- [11] Zwicker JG, Missiuna C, Harris SR, Boyd LA. Brain activation of children with developmental coordination disorder is different than peers. *Pediatrics* 2010;126(3) e678-686.
- [12] Zwicker JG, Missiuna C, Harris SR, Boyd LA. Brain activation associated with motor skill practice in children with developmental coordination disorder: an fMRI study. *Int J Dev Neurosci* 2011;29(2) 145-152.

- [13] Mariën P, Wackenier P, De Surgeloose D, De Deyn PP, Verhoeven J. Developmental coordination disorder: disruption of the cerebello-cerebral network evidenced by SPECT. *Cerebellum* 2010;9(3) 405-410.
- [14] Zwicker JG, Missiuna C, Harris SR, Boyd LA. Developmental coordination disorder: a pilot diffusion tensor imaging study. *Pediatr Neurol* 2012;46(3) 162-167.
- [15] Culham JC, Cavina-Pratesi C, Singhal A. The role of parietal cortex in visuomotor control: what have we learned from neuroimaging? *Neuropsychologia* 2006;44(13) 2668-2684.
- [16] Iacoboni M. Visuo-motor integration and control in the human posterior parietal cortex: evidence from TMS and fMRI. *Neuropsychologia* 2006;44(13) 2691-2699.
- [17] Ogawa K, Inui T. Lateralization of the posterior parietal cortex for internal monitoring of self-generated versus externally generated movements. *J Cogn Neurosci* 2007;19(11) 1827-1835.
- [18] Taira M, Kawashima R, Inoue K, Fukuda H. A PET study of axis orientation discrimination. *Neuroreport* 1998;9(2) 283-288.
- [19] Gerardin E, Sirigu A, Lehericy S, Poline JB, Gaymard B, Marsault C, Agid Y, Le Bihan D. Partially overlapping neural networks for real and imagined hand movements. *Cereb Cortex* 2000;10(11) 1093-1104.
- [20] Grefkes C, Ritzl A, Zilles K, Fink GR. Human medial intraparietal cortex subserves visuomotor coordinate transformation. *Neuroimage* 2004;23(4) 1494-1506.
- [21] Cavanna AE, Trimble MR. The precuneus: a review of its functional anatomy and behavioural correlates. *Brain* 2006;129(pt 3) 564-583.
- [22] Treserras S, Boulanouar K, Conchou F, Simonetta-Moreau M, Berry I, Celsis P, Chollet F, Loubinoux I. Transition from rest to movement: brain correlates revealed by functional connectivity. *Neuroimage* 2009;48(1) 207-216.
- [23] du Boisgueheneuc F, Levy R, Volle E, Seassau M, Duffau H, Kinkingnehun S, Samson Y, Zhang S, Dubois B. Functions of the left superior frontal gyrus in humans: a lesion study. *Brain* 2006;129(pt 12) 3315-3328.
- [24] Swick D, Ashley V, Turken AU. Left inferior frontal gyrus is critical for response inhibition. *BMC Neurosci* 2008;9: 102.
- [25] Cunnington R, Windischberger C, Deecke L, Moser E. The preparation and execution of self-initiated and externally-triggered movement: a study of event-related fMRI. *Neuroimage* 2002;15(2) 373-385.
- [26] Frutiger SA, Strother SC, Anderson JR, Sidtis JJ, Arnold JB, Rottenberg DA. Multivariate predictive relationship between kinematic and functional activation patterns in a PET study of visuomotor learning. *Neuroimage* 2000;12(5) 515-527.

- [27] Fink GR, Frackowiak RS, Pietrzyk U, Passingham RE. Multiple nonprimary motor areas in the human cortex. *J Neurophysiol* 1997;77(4) 2164–2174.
- [28] Mutschler I, Schulze-Bonhage A, Glauche V, Demandt E, Speck O, Ball T. A rapid sound-action association effect in human insular cortex. *PLoS One* 2007;2(2) e259.
- [29] Ullsperger M, von Cramon DY. Neuroimaging of performance monitoring: error detection and beyond. *Cortex* 2004;40(4–5) 593–604.
- [30] Clower DM, West RA, Lynch JC, Strick PL. The inferior parietal lobule is the target of output from the superior colliculus, hippocampus, and cerebellum. *J Neurosci* 2001;21(16) 6283–6291.
- [31] Halsband U, Lange RK. Motor learning in man: a review of functional and clinical studies. *J Physiol Paris* 2006;99(4–6) 414–424.
- [32] Bjoertomt O, Cowey A, Walsh V. Near space functioning of the human angular and supramarginal gyri. *J Neuropsychol* 2009;3(pt1) 31–43.
- [33] Medina J, Kannan V, Pawlak MA, Kleinman JT, Newhart M, Davis C, Heidler-Gary JE, Herskovits EH, Hillis AE. Neural substrates of visuospatial processing in distinct reference frames: evidence from unilateral spatial neglect. *J Cogn Neurosci* 2009;21(11) 2073–2084.
- [34] Small DM, Gitelman DR, Gregory MD, Nobre AC, Parrish TB, Mesulam MM. The posteriorcingulate and medial prefrontal cortex mediate the anticipatory allocation of spatial attention. *Neuroimage* 2003;18(3) 633–641.
- [35] Clements-Stephens AM, Rimrodt SL, Cutting LE. Developmental sex differences in basic visuospatial processing: differences in strategy use? *Neurosci Lett* 2009;449(3) 155–160.
- [36] Leung HC, Oh H, Ferri J, Yi Y. Load response functions in the human spatial working memory circuit during location memory updating. *Neuroimage* 2007;35(1) 368–377.
- [37] Eichenbaum H, Lipton PA. Towards a functional organization of the medial temporal lobe memory system: role of the parahippocampal and medial entorhinal cortical areas. *Hippocampus* 2008;18(12) 1314–1324.
- [38] Okudzhava VM, Natishvili TA, Gurashvili TA, Gogeshvili KSh, Chipashvili SA, Bagashvili TI, Andronikashvili GT, Kvernadze GG, Okudzhava NV. Spatial recognition in cats: effects of parahippocampal lesions. *Neurosci Behav Physiol* 2009;39(7) 613–618.
- [39] Stoodley CJ, Schmahmann JD. Functional topography in the human cerebellum: a meta-analysis of neuroimaging studies. *Neuroimage* 2009;44(2) 489–501.

- [40] Habas C, Kamdar N, Nguyen D, Prater K, Beckmann CF, Menon V, Greicius MD. Distinct cerebellar contributions to intrinsic connectivity networks. *Journal of Neuroscience* 2009;29(26) 8586–8594.
- [41] Stoodley CJ, Schmahmann JD. Functional topography in the human cerebellum: a meta-analysis of neuroimaging studies. *Neuroimage* 2009;44(2) 489–501.
- [42] Seidler RD, Purushotham A, Kim SG, Uğurbil K, Willingham D, Ashe J. Cerebellum activation associated with performance change but not motor learning. *Science* 2002;296(5575) 2043–2046.
- [43] Orban P, Peigneux P, Lungu O, Albouy G, Breton E, Laberenne F, Benali H, Maquet P, Doyon J. The multifaceted nature of the relationship between performance and brain activity in motor sequence learning. *Neuroimage* 2010;49(1) 694–702.
- [44] Diedrichsen J, Hashambhoy Y, Rane T, Shadmehr R. Neural correlates of reach errors. *Journal of Neuroscience* 2005;25(43) 9919–9931.
- [45] Boyd LA, Vidoni ED, Siengsukon CF, Wessel BD. Manipulating time-to- plan alters patterns of brain activation during the Fitts' task. *Experimental Brain Research* 2009;194(4) 527–539.
- [46] Grafton ST, Schmitt P, Van Horn J, Diedrichsen J. Neural substrates of visuomotor learning based on improved feedback control and prediction. *Neuroimage* 2008;39(3)1383–1395.
- [47] Anguera JA, Reuter-Lorenz PA, Willingham DT, Seidler RD. Contributions of spatial working memory to visuomotor learning. *J Cogn Neurosci* 2010;22(9) 1917–1930.
- [48] Clower DM, West RA, Lynch JC, Strick PL. The inferior parietal lobule is the target of output from the superior colliculus, hippocampus, and cerebellum. *J Neurosci* 2001;21(16) 6283–6291.
- [49] Halsband U, Lange RK. Motor learning in man: a review of functional and clinical studies. *J Physiol Paris*. 2006 ;99(4-6) 414–424.
- [50] Jenkins IH, Brooks DJ, Nixon PD, Frackowiak RS, Passingham RE. Motor sequence learning: a study with positron emission tomography. *J Neurosci*. 1994 Jun;14(6): 3775–90.
- [51] Sakai K, Hikosaka O, Miyauchi S, Takino R, Sasaki Y, Pütz B. Transition of brain activation from frontal to parietal areas in visuomotor sequence learning. *J Neurosci* 1998 Mar 1;18(5):1827–40.
- [52] Fassbender C, Murphy K, Foxe JJ, Wylie GR, Javitt DC, Robertson IH, Garavan H. A topography of executive functions and their interactions revealed by functional magnetic resonance imaging. *Brain Res Cogn Brain Res* 2004;20(2) 132–143.

- [53] Graydon FX, Friston KJ, Thomas CG, Brooks VB, Menon RS. Learning-related fMRI activation associated with a rotational visuo-motor transformation. *Brain Res Cogn Brain Res* 2005;22(3) 373-383.
- [54] Clements-Stephens AM, Rimrodt SL, Cutting LE. Developmental sex differences in basic visuospatial processing: differences in strategy use? *Neurosci Lett* 2009;449(3) 155-160.
- [55] Bagley, W. C. On the correlation of mental and motor ability in school children. *The American Journal of Psychology* 1901;12(2) 193-205.
- [56] Lippitt, L. C. A manual of corrective gymnastics. New York: Macmillan; 1926
- [57] Orton, S.T. Reading, writing and speech problems in children. New York: Norton; 1937.
- [58] Wigglesworth, R. The importance of recognising minimal cerebral dysfunction in paediatric practice. In: Bax M, MacKeith R. (ed.) *Minimal cerebral dysfunction*. Little Club Clinics in Developmental Medicine No. 10. London: Heinemann Medical; 1963. p.34-38.
- [59] Clements, SD. Minimal brain dysfunction in children; Terminology and identification. Phase I of a Three-Phase Project, NINBD Monograph 3. Washington, DC: U. S. Government; 1966.
- [60] Kong, E. Minimal cerebral palsy: The importance of its recognition. In: Bax M, MacKeith R. (ed.) *Minimal cerebral dysfunction*. Little Club Clinics in Developmental Medicine No. 10. London: Heinemann Medical; 1963. p.29-31.
- [61] Cermak, S. Developmental dyspraxia. In Roy EA. (ed.), *Neuropsychological studies of apraxia and related disorders*. Amsterdam: North-Holland; 1985. p.225-248.
- [62] Polatajko, H. J., Fox, A. M., & Missiuna, C. An international consensus on children with developmental coordination disorder. *Canadian Journal of Occupational Therapy* 1995;62(1) 3-6.
- [63] Morris PR, Whiting HTA. Motor impairment and compensatory education. Philadelphia: G. Bell and Sons; 1971.
- [64] Bernstein NA., Latash ML, Latash MT. *Dexterity and Its Development*. NY: Psychology Press; 1996.
- [65] Dayan E, Cohen LG. Neuroplasticity subserving motor skill learning. *Neuron* 2011;72(3) 443-454.
- [66] Fitts PM. The information capacity of the human motor system in controlling the amplitude of movement. *Journal of Experimental Psychology* 1954;47 381-391.
- [67] Cermak S. A., Larkin, D. *Developmental coordination disorder*. Albany, NY: Delmar/Thompson Learning; 2002

- [68] Shumway-Cook A, Woollacott MH. *Motor Control: Translating Research into Clinical Practice*. Philadelphia: Lippincott Williams & Wilkins; 2011.
- [69] Fitts PM, Posner MI. *Human performance*. Belmont, CA: Brooks/Cole; 1967.
- [70] Hikosaka O, Nakamura K, Sakai K, Nakahara H. Central mechanisms of motor skill learning. *Curr Opin Neurobiol* 2002 ;12(2) 217-222.
- [71] Doyon J, Benali H. Reorganization and plasticity in the adult brain during learning of motor skills. *Curr Opin Neurobiol* 2005;15(2) 161-167.
- [72] Culham JC, Cavina-Pratesi C, Singhal A. The role of parietal cortex in visuomotor control: what have we learned from neuroimaging? *Neuropsychologia* 2006; 44(13) 2668–2684.
- [73] Heilman, K. M., & Valenstein, E. *Clinical neuropsychology* (4th ed.). New York, NY: Oxford University Press; 2003.
- [74] Zwicker JG, Missiuna C, Boyd LA. Neural correlates of developmental coordination disorder: a review of hypotheses. *J Child Neurol* 2009;24(10) 1273-1281.
- [75] Cummins A, Piek JP, Dyck MJ. Motor coordination, empathy, and social behaviour in school-aged children. *Dev Med Child Neurol* 2005;47(7) 437-442.
- [76] Adolphs R, Damasio H, Tranel D, Damasio AR. Cortical systems for the recognition of emotion in facial expressions. *J Neurosci* 1996;16(23) 7678-7687.
- [77] Wilson PH, Maruff P, Lum J. Procedural learning in children with developmental coordination disorder. *Hum Mov Sci* 2003;22(4-5) 515–526.
- [78] Wilson PH, Maruff P, Butson M, Williams J, Lum J, Thomas PR. Internal representation of movement in children with developmental coordination disorder: a mental rotation task. *Dev Med Child Neurol* 2004; 46(11) 754–759.
- [79] Hyde C, Wilson P. Online motor control in children with developmental coordination disorder: chronometric analysis of double-step reaching performance. *Child Care Health Dev* 2011;37(1) 111-122.
- [80] Maruff P, Wilson PH, Trebilcock M, Currie J. Abnormalities of imaged motor sequences in children with developmental coordination disorder. *Neuropsychologia* 1999;37(11) 1317–1324.
- [81] Williams J, Thomas PR, Maruff P, Wilson PH. The link between motor impairment level and motor imagery ability in children with developmental coordination disorder. *Hum Mov Sci* 2008; 27(2) 270–285.
- [82] Wilson PH, Thomas PR, Maruff P. Motor imagery training ameliorates motor clumsiness in children. *J Child Neurol* 2002; 17(7) 491–498.
- [83] Geuze RH. Postural control in children with developmental coordination disorder. *Neural Plast* 2005;12(2-3) 183-196; discussion 263-272.

- [84] Kagerer FA, Contreras-Vidal JL, Bo J, Clark JE. Abrupt, but not gradual visuomotor distortion facilitates adaptation in children with developmental coordination disorder. *Hum Mov Sci* 2006;25(4-5) 622-633.
- [85] Van Waelvelde H, De Weerdt W, De Cock P, Janssens L, Feys H, Smits Engelsman BC. Parameterization of movement execution in children with developmental coordination disorder. *Brain Cogn* 2006;60(1) 20-31.
- [86] Groenewegen HJ. The basal ganglia and motor control. *Neural Plast* 2003;10(1-2) 107-120.
- [87] Gheysen F, Van Waelvelde H, Fias W. Impaired visuo-motor sequence learning in Developmental Coordination Disorder. *Res Dev Disabil* 2011;32(2) 749-756.
- [88] Gheysen F, Van Opstal F, Roggeman C, Van Waelvelde H, Fias W. Hippocampal contribution to early and later stages of implicit motor sequence learning. *Exp Brain Res* 2010;202(4) 795-807.
- [89] Sigmundsson H, Ingvaldsen RP, Whiting HT. Inter- and intrasensory modality matching in children with hand-eye coordination problems: exploring the developmental lag hypothesis. *Dev Med Child Neurol* 1997;39(12) 790-796.
- [90] Werner JM, Cermak SA., Aziz-Zadeh L. Neural Correlates of Developmental Coordination Disorder: The Mirror Neuron System Hypothesis. *Journal of Behavioral and Brain Science* 2012;2,:258-268 doi:10.4236/jbbs.2012.22029 (accessed May 2007)
- [91] Scott A. Huettel, Allen W. Song, Gregory McCarthy. *Functional Magnetic Resonance Imaging*. Massachusetts: Sinauer Associates Inc.; 2009
- [92] Raichle ME, MacLeod AM, Snyder AZ, Powers WJ, Gusnard DA, Shulman GL. A default mode of brain function. *Proc Natl Acad Sci U S A* 2001;98(2) 676-682.
- [93] Harrison BJ, Pujol J, López-Solà M, Hernández-Ribas R, Deus J, Ortiz H, Soriano-Mas C, Yücel M, Pantelis C, Cardoner N. Consistency and functional specialization in the default mode brain network. *Proc Natl Acad Sci U S A* 2008;105(28) 9781-9886.
- [94] Buckner RL, Andrews-Hanna JR, Schacter DL. The brain's default network: anatomy, function, and relevance to disease. *Ann N Y Acad Sci* 2008;1124 1-38.
- [95] Greicius MD, Srivastava G, Reiss AL, Menon V. Default-mode network activity distinguishes Alzheimer's disease from healthy aging: evidence from functional MRI. *Proc Natl Acad Sci U S A*. 2004;101(13) 4637-46742.
- [96] Broyd SJ, Demanuele C, Debener S, Helps SK, James CJ, Sonuga-Barke EJ. Default-mode brain dysfunction in mental disorders: a systematic review. *Neurosci Biobehav Rev* 2009;33(3) 279-296.
- [97] Supekar K, Uddin LQ, Prater K, Amin H, Greicius MD, Menon V. Development of functional and structural connectivity within the default mode network in young children. *Neuroimage* 2010;52(1) 290-301.

- [98] Hillier, S. Intervention for children with developmental coordination disorder: A systematic review. *The Internet Journal of Allied Health Sciences and Practice* 2007;5(3) <http://ijahsp.nova.edu>
- [99] Sugden D. Current approaches to intervention in children with developmental coordination disorder. *Dev Med Child Neurol* 2007;49(6) 467-471.
- [100] Pless M, Carlsson M. Effects of motor skill intervention on developmental coordination disorder: a meta-analysis. *Adapt Phys Activ Q* 2000;17(4) 381-401.
- [101] Wilson PH. Practitioner review: approaches to assessment and treatment of children with DCD: an evaluative review. *J Child Psychol Psychiatry* 2005; 46(8) 806-823.
- [102] Braun SM, Beurskens AJ, Borm PJ, Schack T, Wade DT. The effects of mental practice in stroke rehabilitation: a systematic review. *Arch Phys Med Rehabil* 2006;87(6) 842-852.
- [103] Langhorne P, Coupar F, Pollock A.. Motor recovery after stroke: a systematic review. *Lancet Neurol*. 2009;8(8) 741-754.
- [104] Guillot A, Collet C, Nguyen VA, Malouin F, Richards C, Doyon J. Functional neuroanatomical networks associated with expertise in motor imagery. *Neuroimage* 2008;41(4) 1471-1483.