

# We are IntechOpen, the world's leading publisher of Open Access books Built by scientists, for scientists

6,900

Open access books available

185,000

International authors and editors

200M

Downloads

Our authors are among the

154

Countries delivered to

TOP 1%

most cited scientists

12.2%

Contributors from top 500 universities



WEB OF SCIENCE™

Selection of our books indexed in the Book Citation Index  
in Web of Science™ Core Collection (BKCI)

Interested in publishing with us?  
Contact [book.department@intechopen.com](mailto:book.department@intechopen.com)

Numbers displayed above are based on latest data collected.  
For more information visit [www.intechopen.com](http://www.intechopen.com)



---

# **Maxillofacial Reconstruction of Ballistic Injuries**

---

Mohammad Hosein Kalantar Motamedi,  
Seyed Hossein Mortazavi, Hossein Behnia,  
Masoud Yaghmaei, Abbas Khodayari,  
Fahimeh Akhlaghi, Mohammad Ghasem Shams and  
Rashid Zargar Marandi

Additional information is available at the end of the chapter

<http://dx.doi.org/10.5772/53119>

---

## **1. Introduction**

This chapter presents our experience with treatment of facial fractures and defects subsequent to various ballistic injuries based on experience gained from management of numerous warfare injuries during the Iraq-Iran war and thereafter (1986-2013).

## **2. Presentation**

The clinical presentation and devastation of penetrating injuries of the face resulting from ballistic weaponry varies according to the caliber of the weapon used, the distance from which the victim is shot and velocity of the projectile. Projectiles from ballistic weaponry may be either high-velocity or low-velocity.

### **2.1. High-velocity projectiles**

High-velocity projectiles to the face have devastating functional and esthetic consequences because they shatter and scatter the bones and teeth. The entry wound is usually small while the exit wound is large and management is difficult.

## 2.2. Low-velocity projectiles

Low-velocity projectiles are usually less devastating with regard to fracture pattern and tissue damage ; therefore management of these injuries is usually less complicated.

## 3. Management

Generally, treatment of ballistic injuries mandate prompt assessment and early comprehensive management in the first operation [1-3]. However, some [4,5] feel that delayed reconstruction of ballistic injuries, avoidance of mini-plates, use of small incisions, minimal exposure of bony fragments, external pin fixations, and avoidance of intraosseous wiring is safer (fearing necrosis, infection and other complications).

### 3.1. Controversies in comprehensive management: Early vs. delayed intervention

#### 3.1.1. Proponents of delayed intervention

Ballistic wounds are considered contaminated and this is why some are against early intervention and comprehensive management at the first operation. Advocates of delayed intervention state that delayed repair ensures a clean, segregated wound bed [5].

#### 3.1.2. Proponents of early intervention

Those in favor of early intervention and comprehensive management at the first operation state that delay causes problems such as contracture scars, deformity, displacement of bone segments (due to muscle pull), difficulty in fracture reduction, patient anxiety, longer hospital stay and an additional operation to reopen the same wound (closed hastily at the field hospital, nearest emergency post or local hospital before transfer) in order to graft the hard or soft tissues [6,7].

In the maxillofacial region many ballistic injuries may be treated early; and several authors have opposed the strategy of universally delaying all surgical interventions of facial ballistic injuries suggesting a more comprehensive surgical operation can be done primarily in many [2,6-8]. Good results following acute treatment of projectile facial wounds during a 4-year period in the Afghan war has been reported more recently. Definitive and comprehensive treatment of ballistic facial injuries in the first stage with minimal debridement has been shown to result in better restoration of the facial deformity, lower morbidity, faster return of function, shorter hospital stay, and one less operation for the patient (when bone continuity was obtained)[2,7,9,10]. Additional advantages of early single-stage repair include a fresh wound, ability to expose and locate displaced fracture segments upon debridement, easier anatomic reduction of facial fractures (no fibrosis), facilitated arch bar placement, facilitated fracture manipulation reduction and osteosynthesis (no contractures) and definitive soft-tissue management. Moreover, it also allows for restoration of

occlusion, salvaging loose teeth, a more expedient return of function and closer restoration of pre-injury appearance postoperatively [9,10].

### **3.2. Injury assessment**

Ballistic injuries to the face must be assessed and addressed with regard to the wounds sustained, the injury profile and general status of the patient to decide when and how to treat. The criteria which dictate when to operate are discussed in this chapter as are the results, outcomes, and benefits of treating both hard and soft tissues in the first operation (early comprehensive management).

## **4. Early comprehensive management of ballistic injuries to the face**

From 1991 to 2012 we treated 51 patients aged 8 – 50 years (mean  $24.4 \pm 7.8$  yrs.) for ballistic injuries of the face; 30 were rendered early comprehensive management based on indication.

### **4.1. Indications for early intervention to treat both hard and soft tissue ballistic injuries at the first operation**

Early intervention and comprehensive management was done when there was:

- No gross infection
- No bone comminution to preclude osteosynthesis
- No extensive soft tissue loss to preclude bone coverage
- No general health problems such as medical instability or moribund patient
- No need for major grafting
- No concomitant more serious or life-threatening injuries requiring urgent attention

In these cases, acute management aimed to treat both hard and soft tissue injuries definitively at the first operation to restore arch continuity; because occlusion, form, function and esthetics can be restored later provided that continuity has been restored.

### **4.2. Contraindications for early intervention to treat both hard and soft tissue ballistic injuries in the first operation**

Early intervention and comprehensive management was not done when there was:

- Gross infection
- Concomitant more serious injury or multiple injuries of higher priority
- Poor general health
- Pulverized bone precluding fixation

- Extensive loss of soft-tissue (requiring distant flaps)
- Requirement for large bone grafts

#### 4.3. Treatment procedure (inside-out and bottom-up)

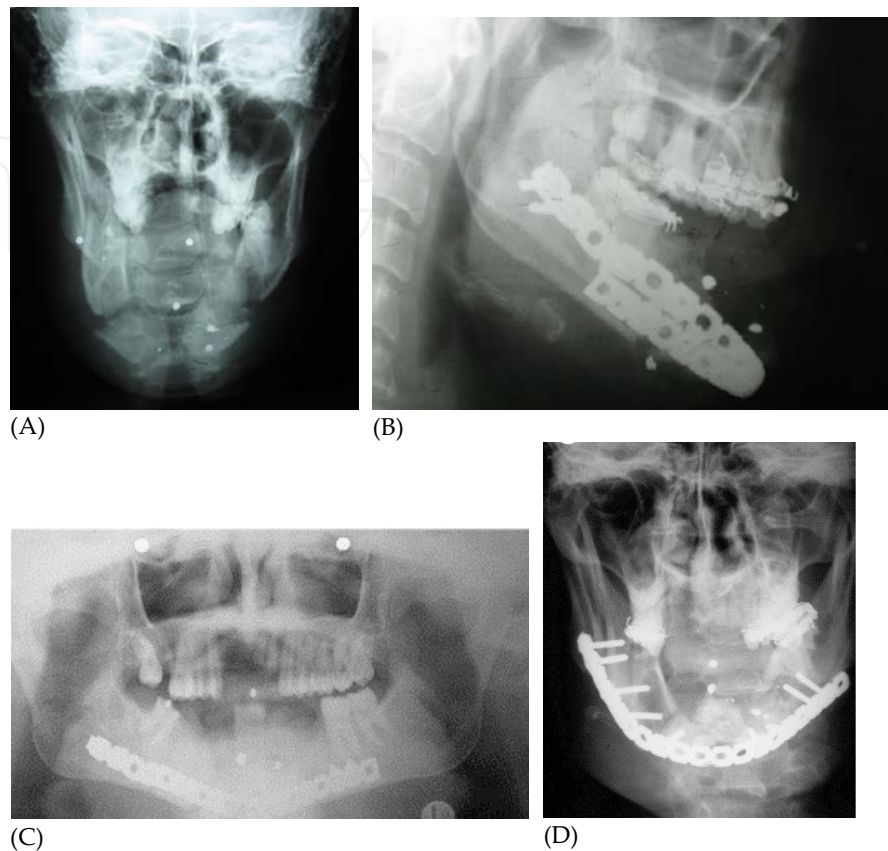
Thirty patients with maxillofacial ballistic injuries underwent early intervention to treat both hard and soft tissues at the first operation; basic treatment included:

- General anesthesia, nasoendotracheal intubation and throat pack placement
- Extensive oral and extraoral irrigation (dilute hydrogen peroxide + povidone iodide followed by normal saline), brushing the teeth and debridement of facial wounds.
- Arch bar placement (in dentate patients), establishing occlusion and temporary maxillo-mandibular fixation (MMF)
- Removal of floating fragments (teeth particles, debris, and shell fragments ) while salvaging bone; tooth roots within the alveolus were not extracted at this stage nor were mobile teeth.
- Locating the scattered bone segments within the wound and using them to restore bone continuity especially in the mandible.
- Removal of temporary MMF and removal of throat pack.
- Placement of MMF.
- Wound closure in layers following irrigation (from the inside-out) using 3-0 polygalactin, 4-0 polygalactin and 5-0 nylon sutures respectively.

**Note:** In addition to arch bars, titanium miniplates or wires were used as necessary following fracture reduction.

- In all dentate cases, arch bars were first placed and intermaxillary fixation (temporary MMF) was done prior to bone reduction to re-establish the occlusion. Then, the fractured and scattered bone segments were realigned and fixated using miniplates, lag screws, reconstruction plates, or titanium trays (Figure 1 A-D). Final MMF was placed after removal of the throat pack.
- Arch bar placement with MMF but without osteosynthesis was possible when the reduced bone segments contained teeth.
- High velocity ballistic wounds cause fracture and dispersion of teeth, bone, foreign bodies and debris into the lips, tongue, cheeks, and elsewhere; these sites were visualized, palpated and searched prior to wound closure.
- Projectiles beyond the depth of the wound and not within reach were not sought.
- After management of the hard tissues, soft tissue injuries were treated by debridement and primary wound closure performed loosely in layers from the inside out, using common local flap techniques to compensate for the tissue loss.

- In cases with bone comminution the soft tissues were closed and bone graft was done 3 – 4 weeks later when wounds had healed.



**Figure 1.** (A) Posterior–anterior skull radiograph of a typical patient shot in the face revealing multiple fragments of the mandible displaced inferiorly into the neck due to suprahyoid muscle pull. First arch bars and MMF and then a reconstruction plate were placed. (B) Lateral view after location, reduction of segments, and screw fixation of bone fragments ; large bone segments were secured to the reconstruction plate restoring continuity and chin projection. Smaller segments were wedged in place. (C) Panoramic view 6 months later showing bone consolidation and restoration of bone continuity. Had this not been done another operation to bone graft the mandible would have been necessary again with MMF. (D). PA view postoperatively. Note bone segments, reduced and fixed by 2.7mm screws in order to obtain mandibular continuity.

## 5. Clinical course

Thirty of 51 patients were treated for both hard and soft tissues injuries at the first operation (comprehensive intervention). Patient ages ranged from 8 to 50 years (mean  $24.4 \pm 7.8$  years). All patients were male. The mandible was injured in 96% and the maxilla in 54%; 22% required tracheotomy; 91% had isolated facial injuries with no other body area injured; 64% were managed in a single definitive early operation and 36% required two major operations. In the acute group, 6/30 patients had minor complications such as scarring and wound discharge. Transient postoperative discharge from the flap suture site was noted in these patients; this

resolved within several weeks following daily irrigation and cleansing of the wound site. The procedures in these patients are shown in Table 1.

Early comprehensive intervention for firearm injuries to the face was effective in all 30 selected cases. This resulted in restoration of occlusion and continuity of the jaw, fixation of luxated or extruded teeth, early return of function, prevention of segment displacement due to tissue contracture, less scarring, and no need for major bone graft reconstruction later on [Table 2]. Flap healing was favorable in all patients. None of the patients had major complications (i.e., necrosis or osteomyelitis).

Procedure and type of fracture fixation	Percentage
Primary debridement + open fracture reduction (without wire, plate, or screw osteosynthesis) + wound closure	62.5 %
Primary debridement + open reduction (with wire, plate, or screw osteosynthesis) + wound closure	37.5 %

**Table 1.** Type of fracture fixation used in 30 patients treated via early comprehensive intervention in the first operation.

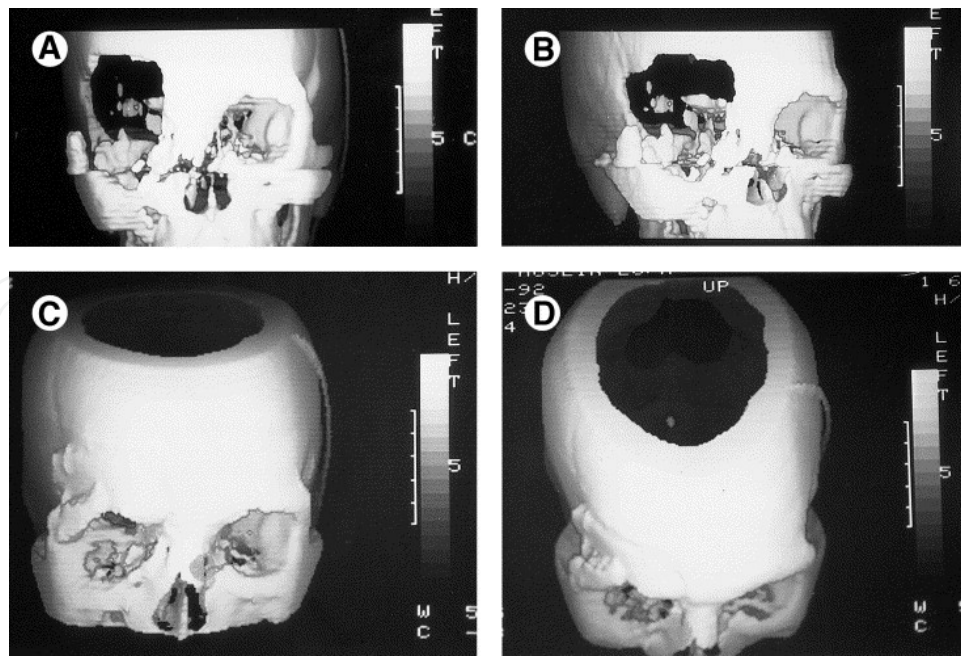
Those not treated primarily were only debrided and had arch bars placed. Definitive treatment of hard and soft tissue management was rendered in another subsequent operation after soft tissues and defects had healed. At that time, bone reduction was difficult because of scarring, and displacement of remaining segments (due to muscle pull especially in the chin, mandibular angle and ramus where medial displacement was common). Reduction of extruded and displaced teeth was also difficult and often not feasible. Wound edges were inverted and required undermining. No significant differences however, were noted in terms of infection or other major complications following early or delayed intervention [Table 2].

Treatment	Displaced / extruded or intruded teeth	Healing	Fracture reduction and fixation	Wound Bed	Contracture	Hospital stay	Arch bar placement and occlusion	Anxiety	Ability to expose / locate
Early	Can be placed back into the socket and into occlusion	Primary	Easy	Fresh	Not seen	Shorter	Easier	Less	Easier
Delayed	Often cannot be placed in the socket or into occlusion	Secondary	Difficult	Often granulated requiring refreshing of tissue borders	Seen often	Longer	More difficult	Greater	More difficult

**Table 2.** Comparison of benefits of early comprehensive intervention versus delayed intervention in management of maxillofacial ballistic injuries.

In some injuries primary treatment may not be indicated nor possible (ie.brain edema) see Figure 2.





**Figure 2.** (A) Three-dimensional computed tomography scan of an extensive high-velocity bullet wound exiting the right orbit and anterior skull. (B) Note the amount of damage that may be inflicted by high-velocity projectiles. (C and D) After neurosurgery, reconstruction of the hard tissues was done via iliac bone grafts.

## 6. Discussion

There is no consensus on the timing of treatment for bone and soft tissue injuries resulting from firearms. The conventional method is primary closure, serial debridements and definitive reconstruction at a later stage. An alternative to this approach is immediate definitive surgical intervention and reconstruction at the first operation [11-17]. The presence of concomitant injuries of the body, fear of postoperative infection, unavailability of surgical hardware and lack of surgical experience in the treatment of penetrating ballistic injuries are among the factors that had created supporters for delayed treatment [2]. The use of external fixators have been recommended by some [4]; but in our unit we find them to be bulky and uncomfortable. They also add additional scars to the already damaged face. Our study shows that ballistic jaw fractures can often be reduced, immobilized, and fixed in occlusion at the time of the first operation along with primary closure and internal fixation with less trauma (provided that soft tissue coverage is feasible and MMF is used). If reconstruction plates are used MMF may be omitted [16,18].

### 6.1. Rationale for primary comprehensive management of hard and soft tissues at the time of the first operation

In our unit, we aim to restore bone continuity primarily (especially in the mandible). Because, if integrity of the jaw is restored, subsequent operations are facilitated for both the patient and



surgeon and because MMF will not be needed again in subsequent operations. Additionally, when intervention is delayed, a myriad of problems set in:

- Fibrosis occurs around bone segments and makes locating and mobilizing them difficult or predisposes them to necrosis.
- Bone edges round-off (we cannot fix the puzzle) and will require refreshing upon reconstruction (for bone graft take).
- Restoration of pre-injury form and function in jaws without continuity is more difficult in delayed patients as the remaining segments often become displaced due to muscle pull (i.e., medial and superior rotational displacement of the mandibular ramus and posterior-inferior displacement of the chin). This makes reduction extremely difficult due to fibrosis and contracture.
- Release of this fibrotic tissue is necessary to reduce fracture segments; this requires stripping the tissues off the bone segments thus devitalizing them.

Often in high velocity facial injuries, the hard tissues are found to be scattered and displaced rather than avulsed. Locating and securing them in place is better than aggressive debridement to remove them in fear of sequestration and infection. Because, doing so, devitalizes and strips the fragments from their vital attachments. Often tracking the path of the projectile to the fracture facilitates finding segments of fractured bone. The bone segments can then be manipulated and wedged into their proper place after locating them at the very time of wound debridement. The bone although fragmented is fresh at that time and more likely to take. Upon primary intervention, projectiles not within reach via the wound bed are disregarded as exploration for these foreign bodies is often unnecessary and may be detrimental for the patient [2,16]. Arch bars, titanium miniplates or wire osteosynthesis were applied when necessary following open reduction along with MMF [Table 1]. All fractures do not require internal fixation however. Arch bar placement and restoration of occlusion following open reduction followed by MMF is sometimes adequate [2]. This is often possible when fractured bone segments contain teeth. Sali Bukhari recently reported on facial gunshot wounds. He found facial gunshot wounds to frequently involve the mandible and reiterated that early management of gunshot wounds not only results in better esthetics, reduced hospital stay and early return to function, but also to a better psychosocial profile preventing depression; when the patient has to tolerate the mutilated face and defective jaw for several days or longer until definitive treatment is rendered he no doubt suffers. The latter is an important issue of concern often overlooked and not addressed in most studies [18].

## 6.2. Overview of consequences inherent to delayed management

Inherent consequences of delayed management include:

- Loss of loose or extruded teeth (which cannot be placed back into the alveolus after delay of several days or more and may not take).
- Problems in restoring occlusion

- Difficulty in fracture reduction due to callus formation
- Displacement of bone segments due to contracture and muscle pull
- Excessive granulation tissue formation and fibrosis of wounds
- Problems in eating due to untreated wound
- Anxiety due to deformity, anticipation of treatment and uncertainty
- Scarring and less esthetic outcome
- Increased cost and length of hospital stay
- An additional major operation

### 6.3. Hard tissue management

Vayvada *et al.* treated 15 patients with high-energy bullet wounds. The conventional approach with delayed reconstruction was done for 10 patients and immediate definitive surgical reconstruction for 5 patients. They stated that immediate reconstruction eliminated the disadvantages of the conventional method such as high infection rate, high scarring rate and deformities resulting from contraction of tissues (similar to our findings)[13]. In our series, 22% of our patients required tracheotomies. This compared well with that found by Hollier *et al.*, where 21% of all facial fractures required a tracheostomy [9]. In all cases, in our series arch bars were placed with MMF prior to bone reduction to ensure proper occlusion. MMF postoperatively prevents chronic osteomyelitis or nonunion *via* preventing movement of segments. The application of arch bars for gunshot injuries of the jaws is the mainstay of treatment to re-establish arch form, occlusion and dentoalveolar stability.

### 6.4. Soft tissue management

Local undermining and the use of regional soft-tissue advancement rotation flaps for primary closure of maxillofacial soft tissue defects during the first operation has proved beneficial from both an esthetic and functional point of view [2,11,13,19]. Leaving defects open results in extensive scarring of the facial tissues and complicates subsequent surgical procedures, and should be avoided even in contaminated penetrating wounds [2,11,13,16,19]. In such situations, debridement and loose closure of the tissues transferred locally followed by administration of antibiotics may be a better alternative [2,11,13,14].

### 6.5. Antibiotics

Antibiotic therapy plays a major role in the prevention of infection of both hard and soft-tissues; early and appropriate surgical debridement, copious irrigation, fixation and immobilization of injured tissues, detailed wound closure, drainage, maintenance of clean dressings, nutrition, tetanus prophylaxis, and restoration of circulating fluid volume are equally important in ballistic injuries [2,11,13,16,19]. Soft tissue healing is usually favorable in patients with penetrating facial injuries; however, postoperative discharge from the suture sites may be seen.

This usually resolves within several weeks after daily irrigation with dilute povidone iodine or hydrogen peroxide solutions. Form and function of the soft tissue reconstructed regions recover usually within a year postoperatively. The esthetic results that can be obtained are generally acceptable to patients [2,11,13,14].

### **6.6. General health**

The general health status of the wounded patient is important. The hemodynamic of the patient must be addressed early on as the oxygen carrying capacity is influential in both wound healing and prevention of infection in injured victims who have suffered extensive blood loss. This issue may warrant delayed intervention especially in the light of more serious concomitant injuries [2,7,11,14].

### **6.7. Mental health**

The emotional conditions of patients with facial ballistic injuries have been evaluated and major depression signs have been reported. Functional evaluation has shown a significant correlation between facial appearance after reconstruction and social activity level [16-18]. Thus, the sooner the surgical treatment is rendered the sooner the psychological recovery.

### **6.8. Revisions**

Revisions and secondary operations are often necessary and were performed in 36% of our patients following the first operation. Revisions are usually needed to remove scars, etc. near the eyes, the alar base of the nose, oral commissures and the vermilion border of the lips. Many of these and other operations including masticatory rehabilitation and restoration of occlusion with osseointegrated implants can be done later under local anesthesia and sedation on an out-patient basis [14,16,20].

## **7. Summary**

The resultant injury from ballistic wounds are diverse because of the variability of the projectile, its motion, velocity, and the characteristics of the tissues involved. When a high-velocity projectile strikes the jaw, often the wound will consist of a severely comminuted mandible surrounded by damaged soft tissues and implanted multiple foreign bodies. This presents a challenge for the treating surgeon. The anatomy and function of the jaw is such that the care of the gunshot wound requires a combination of trauma surgery and reconstructive surgeries. There are varying techniques advocated for the management of ballistic wounds to the face. However, for the comminuted fracture sustained from a ballistic wound, an approach involving intermaxillary fixation, wound debridement and immediate management using a comprehensive approach that can restore function and esthetics. This approach to the comminuted jaw has led to the effective management provided comminution is not extensive. The complication rate is comparable with the current

literature and provides many advantages mainly a 1-stage major operation to restore appropriate function and cosmesis to the patient. [12,14,16].

## 7.1. Surgical Intervention in ballistic injuries

Ballistic wounds are associated with a high incidence of maxillofacial injuries requiring surgical intervention. Many may be treated acutely and definitively with procedures designed to repair both the hard and soft tissue injuries simultaneously to restore bony continuity (especially in the mandible), restoration of esthetics and function using the tissues within or adjacent to the wound. This is advocated because if continuity of the mandible can be obtained subsequent operations will not need maxillomandibular fixation again. Additionally, the course of healing is not disrupted with another subsequent operation (in the same wound) and because it may decrease hospital stay without increasing patient morbidity in patients selected for this intervention. Moreover, residual defects can be treated later as out-patient procedures.

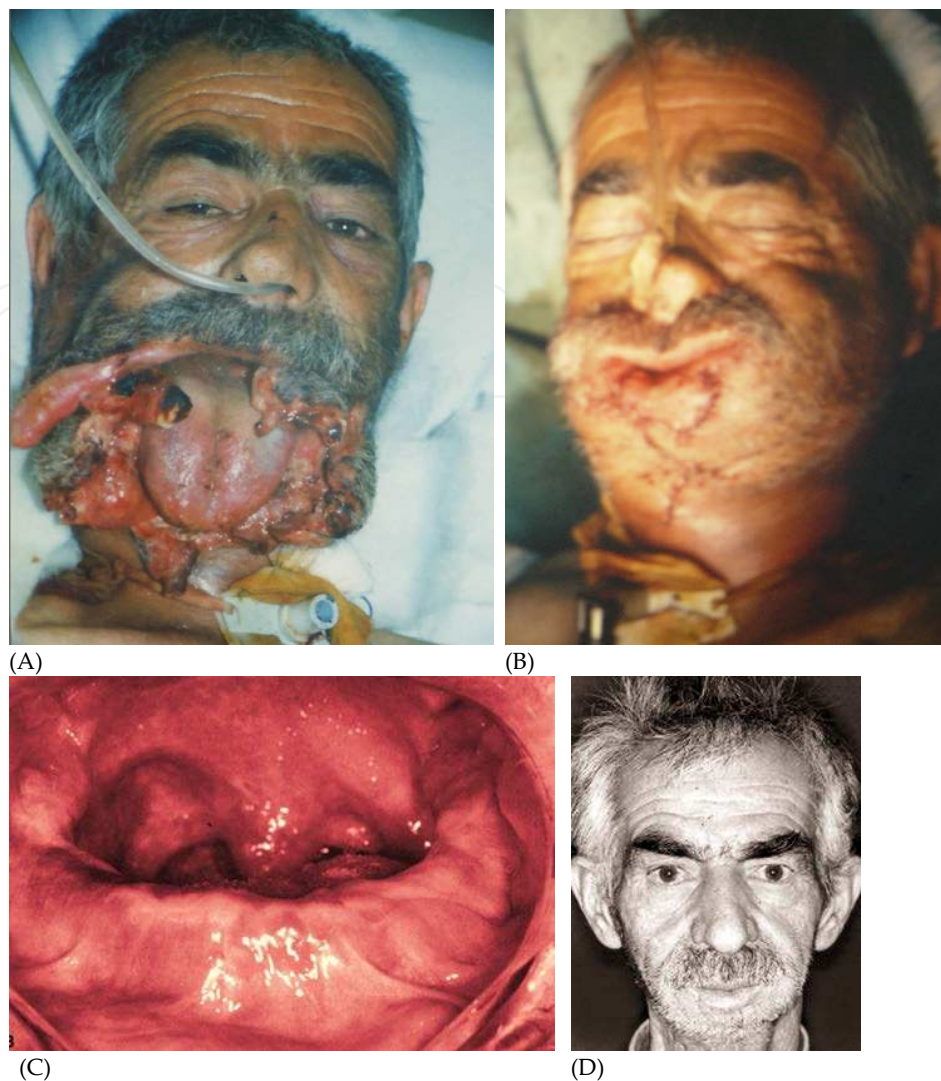### 7.1.1. *Soft-tissue reconstruction*

Soft-tissue reconstruction of facial defects and deformities following ballistic injury is not always an easy or straightforward procedure. The limited availability of adjacent skin, the complex function, contours, texture and intricate innervation of the face, especially in the area of the eyes and the lips, along with the many facial esthetic subunits make the goals of restoring function and esthetics challenging and often difficult to achieve [21]. Local flaps utilize tissue that abuts the defect requiring coverage. These flaps are used to cover skin defects in areas without enough tissue laxity to afford primary closure. The donor site for a local flap ideally should have enough laxity to allow primary repair in addition to providing tissue to the recipient site for coverage of the defect.

In victims of ballistic injuries, the difficulty in application of standard soft-tissue transfer techniques to treat facial defects, is compounded by devastation resulting from high-velocity projectiles in a patient with often multiple, concomitant injuries. Thus, reconstruction is more problematic because of extensive tissue mutilation, edema, compromised blood supply and the involvement of the underlying hard-tissues compounded by the contaminated nature of ballistic wounds [19,22]. Despite these facts, attempting simple closure may often prove adequate to treat the resultant defect or deformity (Figure 3).

However, in complicated cases with extensive tissue loss we face more dilemmas [2,19]. Appreciation of basic flap techniques, as well as applicable modifications and combinations of different flaps can prove invaluable to the maxillofacial surgeon confronted by ballistic injuries, allowing for a more acceptable cosmetic and functional result. In this section we present the application of several useful local flap combinations used to reconstruct various-sized, full-thickness facial defects and deformities in patients with ballistic injuries and discuss applications of local flaps in several facial subunits.





**Figure 3.** (A) View of the patient on admission, depicting extensive hard and soft tissue destruction by the exiting projectile (B) Immediate postoperative photograph. (C) Twelve months after bone grafting the mandible with iliac bone chips in titanium mesh and ridge augmentation. (D) Facial form and function has been restored.

#### 7.1.2. Soft-tissue procedures

The soft-tissue procedures used were basically local-advancement or rotation-advancement flaps, used in conjunction with pedicled fat or subcutaneous supporting flaps, nasolabial, cheek, cervical, Dieffenbach and Abbe-type flaps. Scar revision, tissue repositioning, and lengthening procedures, such as W, V-Y, Z, or multiple Z-plasty techniques were used both primarily and secondarily depending on the individual case.

Thirty-three patients suffering ballistic injuries were treated at our department from 1986 to 2012. There were 32 males and 1 female patient, aged between 8 and 53 years, with an average age of 24.18 years. Bullets were the most common cause (70%), followed by shrapnel (21%), land mines (6%), and one breech block injury (3%). All patients included in this study had full thickness soft-tissue defects and were seen 1-3 days after the initial injury. The soft-tissue

injuries involved the anatomical facial subunits (orbital, infraorbital, buccal, zygomatic, labial, mental and parotidomasseteric). At the operation, after hard tissues were addressed the soft-tissue injuries were treated by debridement and primary closure by combining, modifying, and tailoring standard local flap techniques to fit the location of the injury and compensate for the tissue loss.

The operations were classified regionally: the perioral region was involved in 15 cases (45%), the midface and cheeks were involved in 13 cases (39%), and the periorbital area was involved in 5 cases (15%). Local advancement flaps were applied initially for the majority of the patients (48%) followed by Z-plasty (39%) listed in Table 3.

Soft Tissue Procedure	Number
Cutaneous local advancement flaps	18
Cervicofacial advancement flaps	4
Zygomaticofacial advancement flaps	2
Preauricular advancement flap	1
Columellar reconstruction	1
Tissue rearrangement	8
Mucosal finger flaps	2
Double Abbe flap	1
Commissuroplasty	5
Pedicled fat flap	1
Supporting flaps	5
Dieffenbach flap	1
Nasolabial flaps	4
Perialar flap	1
Skin graft	1
Abbe flap	1
Z-plasty	13
V-Y-plasty	3
W-plasty	1
Palatal flap	1
Direct lip repair	1
Strip graft	1

**Table 3.** List of basic soft-tissue procedures used to treat maxillofacial ballistic soft-tissue injuries. Cutaneous local advancement flaps followed by Z-plasty procedures were most commonly used.

#### 7.1.2.1. Perioral reconstruction

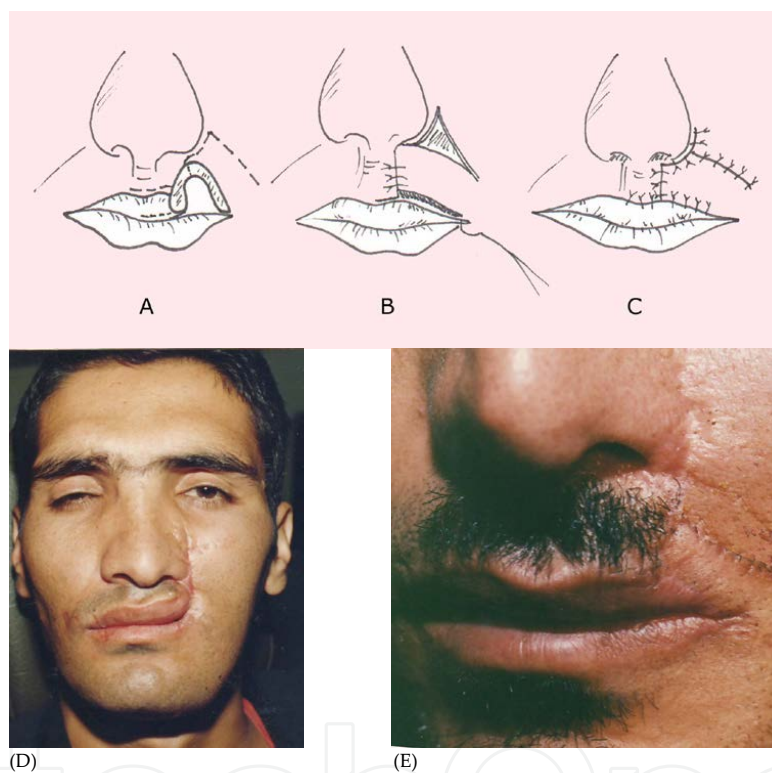
Three basic factors were considered prior to perioral reconstruction: (1) utilization of the remaining portions of the injured lips if possible; (2) using the opposite lip as the next resort when there was inadequate tissue for repair; and (3) use of local flaps from the sides of the defect.



- When as much as one-quarter of the lip was missing, direct linear closure, Z-plasty, or double Z-plasty (to prevent notching of the vermilion) was done. Larger defects of the lips and perioral regions were treated using flaps.
- When reconstruction with flaps was contemplated, several options were considered depending on the lip involved and amount of tissue loss:

### Lateral defects of the lips

For lateral defects of up to one-third of the upper or lower lip, treatment usually utilized nasolabial flaps, a lateral flap combined with vermilion advancement (Figure 4), or the Abbe Estlander flap.

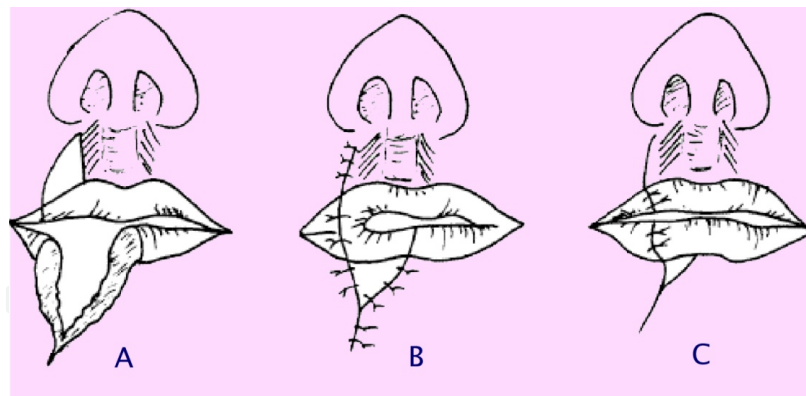


**Figure 4.** (A) Lateral defect of the upper lip with a nasolabial flap outlined for repair, (B) The nasolabial flap is transposed and the vermilion border of the upper lip is advanced laterally to the corner of the mouth. (C) Closure leaving inconspicuous scars in the philtrum, nasolabial, and alar fold. (D) A patient with a lateral upper lip defect resulting from a bullet. (E) View after treatment with a modified nasolabial flap and commisuroplasty. The maxillomandibular fractures were treated earlier.

We used a modified Abbe technique whenever possible, to preclude the need for a subsequent commisuroplasty (Figure 5).

### Midline defects of the lips

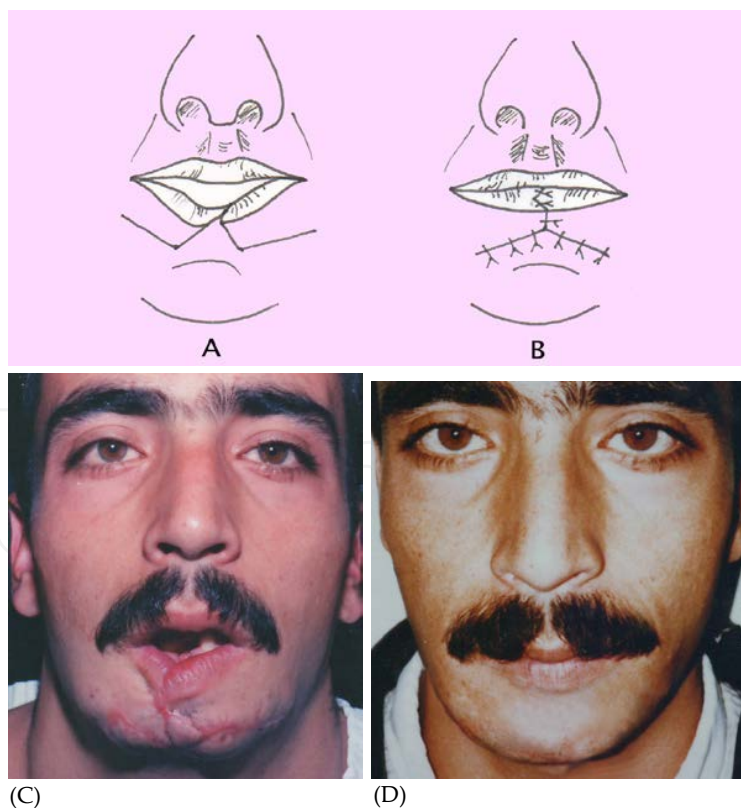
For midline defects of the upper lip, treatment by direct advancement of the remaining portions of the lip with perialar excisions or an Abbe flap, taken from the midline of the lower lip and rotated 180°, was used.



**Figure 5.** (A) Outline of the modified Abbe flap to repair a moderate-sized defect of the lower lip. (B) A triangular section of the upper lip is rotated to repair the lower lip defect. (C) The pedicle is sectioned two weeks later (note the commissures are spared).

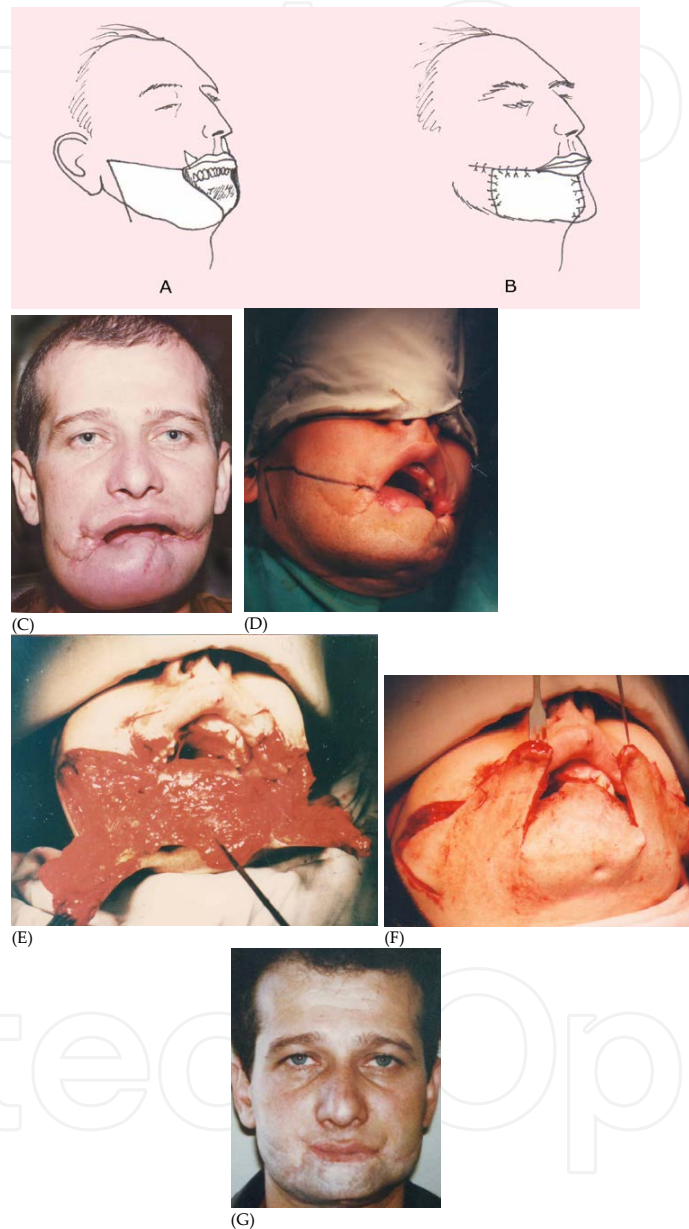
### Lower lip defects

Small-to-moderate sized defects of the lower lip were treated similarly. Lateral rotation or Abbe flaps, Z or V-Y plasties, were used (Figure 6).



**Figure 6.** (A) Medial defect of the lower lip causing unsightly retraction. (B) Correction by lateral advancement flaps and V-Y plasty. (C) A patient with a gunshot wound defect of the chin, lower lip, and labiomental fold. (D) View of the patient after treatment of maxillomandibular fractures, iliac bone grafting, advancement flaps, V-Y, and Z-plasties.

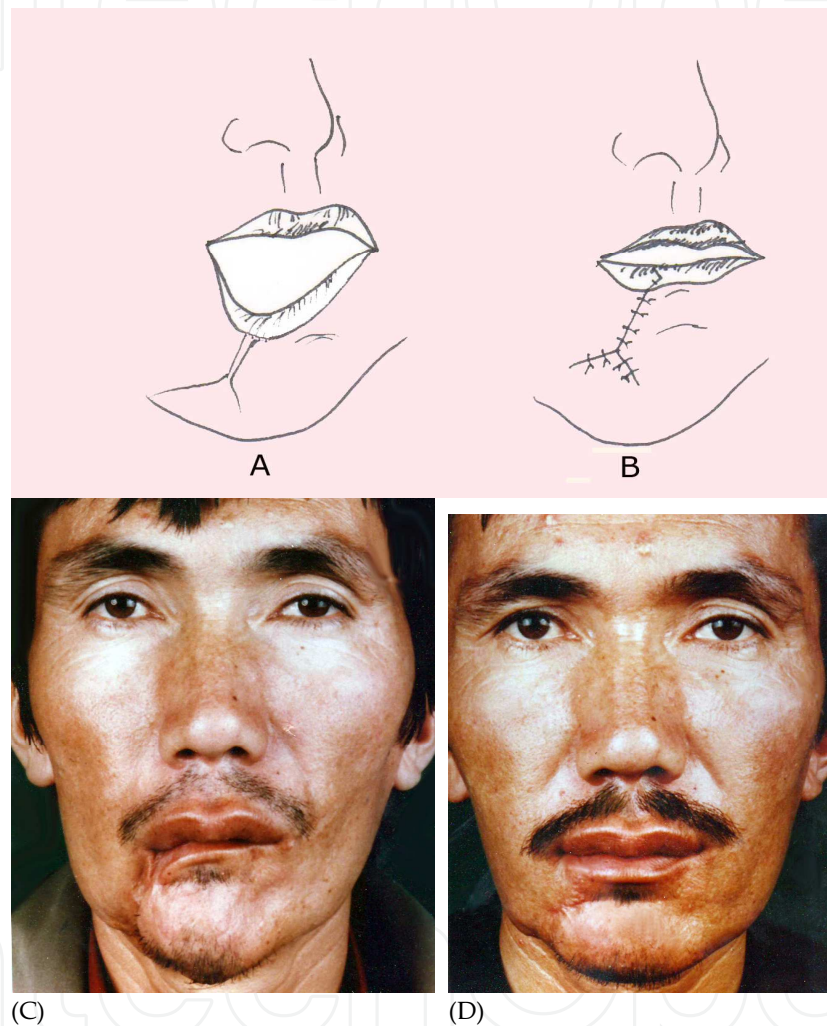
In cases of complete loss of the lower lip and labiomental soft tissues, we combined bilateral Dieffenbach flaps with double Abbe flaps of the upper lip, and a cervical advancement flap, which proved relatively functional and effective in restoring lip competence and lip seal (Figure 7).



**Figure 7.** (A) Total defect of the lower lip and mentolabial tissues. (B) Treatment by Dieffenbach flaps, advancement of the full-thickness bilateral cheek flaps, and double Abbe flaps. (C) A similar defect in a gunshot patient with previously reconstructed hard tissues and soft tissue closure. The total loss of the lower lip and mentolabial tissues caused constant, intolerable, salivary drooling. The mandible was reconstructed primarily by fixing the fragmented bone segments to a reconstruction plate in the first operation, (same patient whose radiographs are shown in Figure 1 ). (D) Outline of the Dieffenbach flap used to reconstruct the lower lip. (E) Flap mobilization with double Abbe flaps outlined. (F) Flaps made passive for advancement. (G) 6-month postoperative photograph of the patient, showing restoration of lip competence.

### Superficial deformities of the lips

Superficial deformities or residual defects which often occur with contraction of linear scars can distort the contour of the lip vermilion or cause notching. These were effectively treated by scar excision, re-creation of the defect, tissue rearrangement combined with supporting flaps, and Z- or V-Y plasty procedures, which proved useful when tissue lengthening was required (Figure 8).



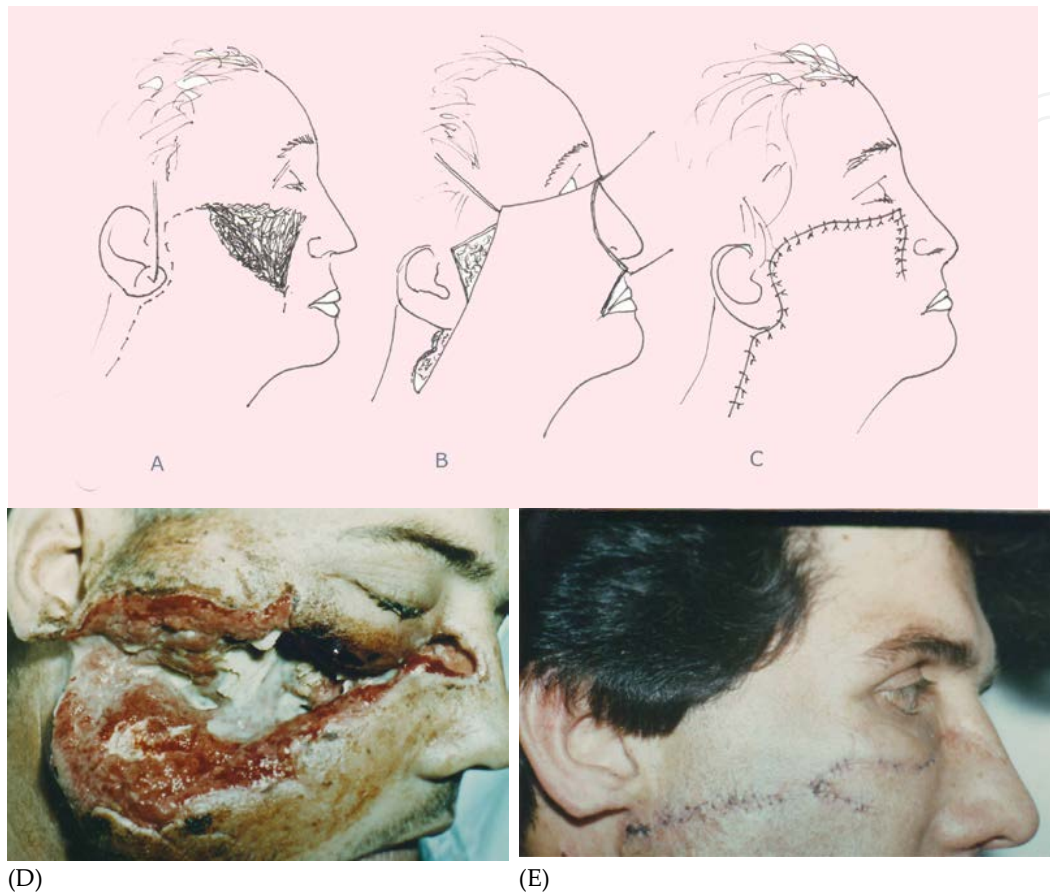
**Figure 8.** (A) Scarring and distortion of a lower lip defect. (B) Correction by scar excision, recreation of the defect, full-thickness lateral flap advancement, and V-Y and Z-plasty. (C) Gunshot patient with a similar contracture deformity. (D) After treatment. The right hemimandible was reconstructed using iliac bone marrow graft in a titanium mesh tray prior to this procedure.

#### 7.1.2.2. Midface and cheek reconstruction

For reconstruction in cases with defects of the cheeks, zygomatic, and midfacial areas, the lateral cheek advancement or rotation flap was used. Transfer of tissue was based on the laxity found in the preauricular tissues, the lower face, and the neck. The larger the defect, the more



extensive the flap preparation. The deep surface of the flap was anchored to the soft tissue, and sometimes included the periosteum over the malar area, to help prevent traction on the eyelid (Figure 9).

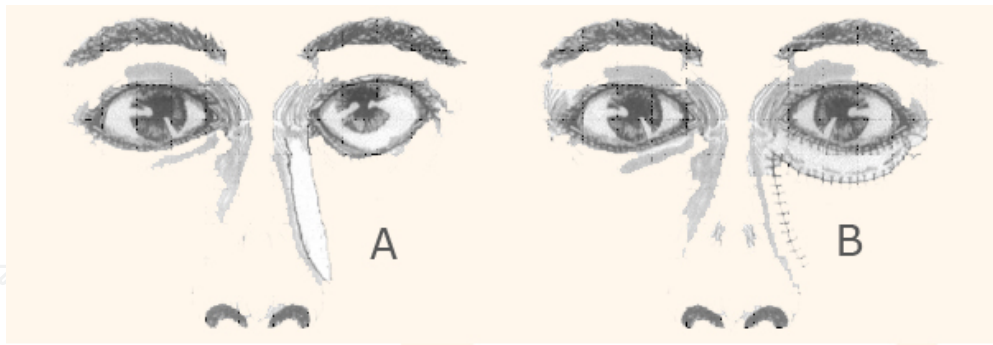


**Figure 9.** (A) Outline of a cervicofacial cheek flap for an avulsion defect. (B) Flap mobilization. (C) Reconstruction. (D) A patient with an extensive, deep avulsion defect of the right cheek and zygomatic area due to a high-velocity shrapnel. (E) View of the patient 1 week after the second surgical stage, note the previous scars of the cervicofacial-zygomatofacial cheek advancement flap and primary closure in the preauricular area are still slightly visible.

This procedure was sometimes combined with a superiorly based nasolabial flap when ectropion was eminent. Smaller defects of the cheeks were treated with local undermining combined with Z-plasties and pedicled fat or subcutaneous supporting flaps to fill the defects and restore the natural prominence of the cheek.

#### 7.1.2.3. Periorbital reconstruction

Reconstruction of defects of the lower eyelid or upper cheek basically employed the versatile nasolabial flap. For defects of this area, the pedicle of this flap was based superiorly, on the angular artery and rotated 90° to close the defect. The tip of the flap was anchored at the corner under the eyelid giving added support to the lower eyelid. This flap was also used to treat lower lid ectropion (Figure 10).



**Figure 10.** (A) Outline of a nasolabial flap for treatment of lower lid sagging and ectropion. (B) Reconstruction.

### 7.1.3. *Hard-tissue injuries*

Hard tissues were usually treated primarily along with closure of the soft-tissue injuries (76%). These procedures varied from debridement only (16%), primary debridement, closed reduction, and fixation (45%), primary debridement, open reduction and wire osteosynthesis (12%), or via primary debridement, open reduction and plate osteosynthesis (3%). When soft-tissue loss precluded primary treatment of hard tissues, or when grafts were needed, these were done secondarily (24%). Secondary graft procedures involved: block grafts (12%), block grafts secured to a reconstruction plate (3%), and cortiocancellous iliac bone placed into titanium mesh trays (9%). All grafts were harvested from the anterior iliac crest and placed transcutaneously. There were no bone graft failures.

### 7.1.4. *Clinical course*

Initial healing of the flaps was uncomplicated in 76% of the patients. However, postoperative discharge from the suture sites was seen in 24% of the patients. This usually resolved within several weeks using daily irrigation and cleansing of the discharge site. None of the soft-tissue flaps sloughed or developed necrosis. Form and function of the regions reconstructed with soft-tissue usually recovered within one year postoperatively. The esthetic results obtained were acceptable in our cases. None required facial nerve grafting, as only the terminal nerve endings were injured in our cases and functional recovery was good.

## 8. Discussion

### 8.1. **Timing treatment**

Ballistic injuries to the face can have minor or often, devastating consequences. The timing, sequence, and appropriate application of surgical procedures and techniques used for reconstruction and rehabilitation of these injuries, have proved to be influential to the final outcome and esthetic result [19]. The staged sequence of treatment dictating the timing of both hard and soft-tissue treatment are dependent to a large extent on surgical judgment and the

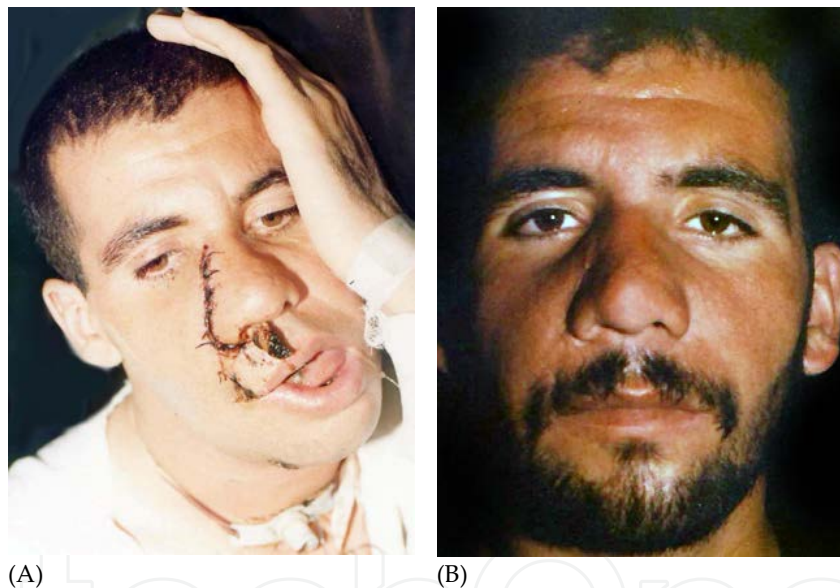


general condition of the patient. The selection of the appropriate surgical technique as well as the timing of surgery is important to prevent infection, wound dehiscence, graft rejection, facial deformity and subsequent revisional operations. Complications prolong hospital stay, postoperative morbidity and increase treatment costs.

## 8.2. Basic surgical stages

Surgical management of maxillofacial ballistic wounds has generally been divided into three stages [19,23,24]:

1. Debridement, fracture stabilization, and primary closure
2. Reconstruction of hard-tissues, provided that the soft-tissue coverage is adequate (Figure 11).
3. Rehabilitation of the oral vestibule, alveolar ridge, and secondary correction of residual deformities.



**Figure 11.** (A) Patient suffering a bullet wound to the face. Note small entry wound below the chin and large exit wound through the face. The patients wounds had been closed and a tracheostomy had been performed prior to transfer. The mandible, maxilla, zygoma and nasal bone were fractured. The wound was re-opened, debrided, arch bars were placed and open reduction was done; then the wound was closed. (B) Patient 6 months postoperatively. No other subsequent surgical treatment was necessary.

Often, stages one and two can be done in the first operation [2,7,19]. Early definitive and comprehensive treatment of the facial injury is the mainstay of treatment when indicated. This results in lower morbidity and better results [2,7,19,23-29]. Local undermining and use of regional soft-tissue advancement rotation flaps for primary closure of maxillofacial soft-tissue defects from projectile injuries have proved beneficial from an esthetic and functional point of view [19]. Leaving defects open results in extensive scarring of the facial tissues complicating subsequent surgical procedures and should be avoided [23,24]. Debridement, cleansing and loose closure of locally transferred tissue is a better alternative. Surprisingly, despite the

contaminated nature of ballistic injuries of the face, entry and exit wounds of the soft-tissues can be closed primarily following careful debridement and extensive irrigation [19,23,24]. Owing to the excellent facial blood supply, primary closure of facial ballistic wounds is the treatment of choice when indications are met [19,23-25]. Underlying compound facial fractures (without extensive comminution) can be reduced, immobilized and fixed in occlusion at the time of primary closure provided that soft tissue coverage is adequate and soft tissue attachments to the bone are preserved [16,19]. In selected patients without severe comminution or infection, osteosynthesis of all free and attached bone fragments using plates in accordance with AO-ASIF can be performed concomitantly with debridement and primary closure. In such cases it is wise to preserve periosteal blood supply and muscle attachments to the attached bony fragments during reduction and fixation. Antibiotic therapy also plays a major role in the prevention of infection of both hard and soft-tissues after primary closure; early and appropriate surgical debridement, copious irrigation, fixation and immobilization of injured hard tissues, detailed wound closure, drainage, and maintenance of clean dressings, nutrition, and circulating fluid volume are equally important [16,19,23]. The hemodynamics of the patient require correction to optimize oxygen carrying capacity influential in wound healing and prevention of infection in victims who have suffered extensive blood loss [14,16,19,23,24].

### 8.3. Revisions

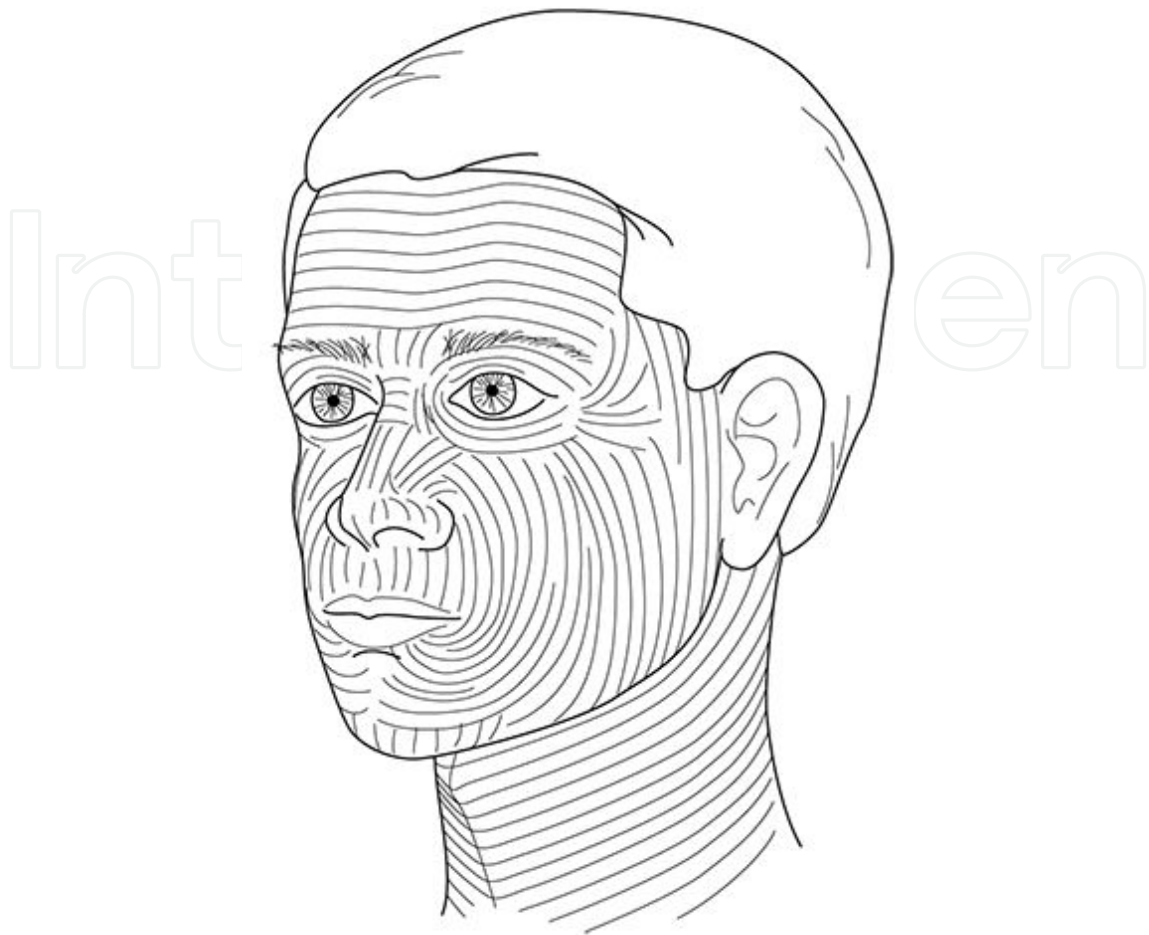
In the next stage when facial soft-tissue injuries are treated electively, previous scars should be excised. In order to treat residual defects, the basic surgical strategy should be to try and rearrange the scars to lie in the natural skin folds (Figure 12).

Such revisions and secondary operations are often necessary and were undertaken in 48% of our patients. This involves operations directed towards rehabilitation and re-establishment of a more normal facial appearance and function which include minor cosmetic procedures and scar revisions. Those most commonly indicated are periorbital, around the alar base, the oral commissures and the vermilion border of the lips. Symmetry in these areas is essential. Many of these operations may be performed under local anesthesia and sedation on outpatients. Masticatory rehabilitation and restoration of occlusion is facilitated with osseointegrated implants. The main problem encountered by the surgeon treating facial soft-tissue injuries in victims remains the lack of adequate suitable tissue to close or reconstruct the defects. In the face, muscle function of the reconstructed facial soft tissues, especially in the lips and perioral regions require composite skin-muscle-mucosal flaps, which become reinnervated and show a high degree of functional recovery yielding acceptable results [15-17,21,26].

### 8.4. Basic flap principles

#### 8.4.1. Patterns

Most local flaps are random pattern flaps with no specific named vascular supply. Examples include rhomboid flaps, V-Y flaps, bilobed flaps and Z-plasty. The length to width ratio of a local flap is very important, and should be approximately 1:1 in most cases to ensure adequate vascular supply to the flap. This ratio is somewhat variable depending on the underlying



**Figure 12.** Langer's lines of the face.

vascularity. For example, flaps in highly vascular areas such as the face can be longer with a narrower base, while a poorly vascularized area such as the lower extremity requires that flap length be equal to flap width. Closure of the donor site for a local flap is usually done in two layers: a layer of absorbable deep dermal fine sutures followed by skin closure with intradermal absorbable or transcutaneous monofilament suture. If the sutures are tied too tightly or left in too long, suture marks will be visible, decreasing the esthetic result. When utilized on the face, sutures should be removed in three to seven days. Local flaps remain erythematous and edematous for many weeks, not taking their final form for three to six months or more, thus any revisional operations should wait [27,28].

#### *8.4.2. Defect size assessment*

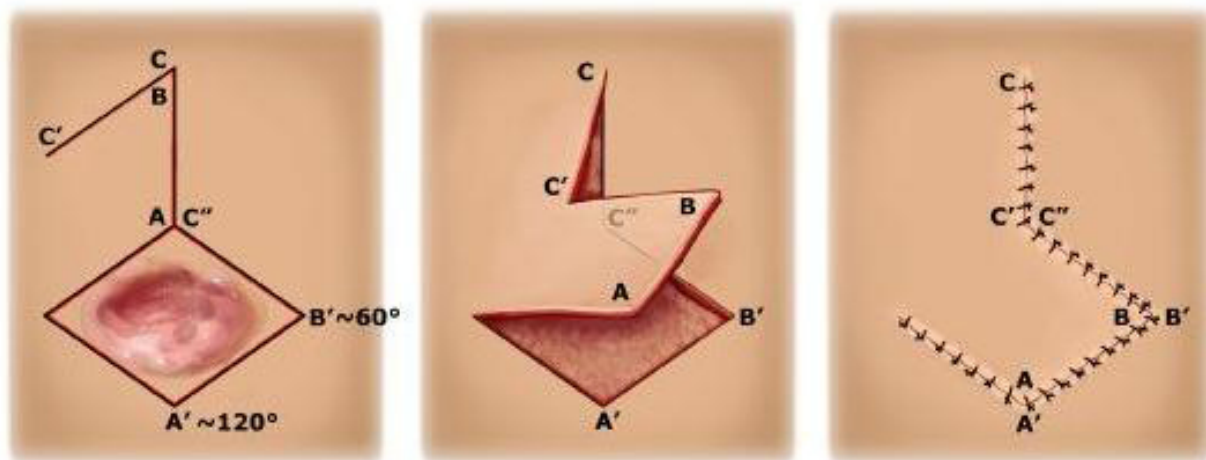
Assessment of defect size is important in planning reconstruction especially in the area of the lips. However, in many cases, assessment of the exact size of the defect can only be done after debridement, approximation of the wound edges and muscles, and when the remaining tissues have been brought into proper position. In patients with scarring, such scar tissue must first

be released. When Abbe flaps are contemplated, it should be noted that the flap pedicle should lie directly opposite the defect. The pedicle is based on the labial artery, located 0.5 cm beneath the mucosal lining of the inner aspect of the lip and must be preserved. In designing this flap; the horizontal dimension of the base of the flap along the vermilion, should be one half of the horizontal defect in the upper lip. In all cases, the vertical dimension of the flap and the defect in the upper lip should be equal. It is advocated that the flap should not exceed 2 cm in width so that the lower (donor) lip does not become too constricted [21,26-28]. Division of the pedicle is usually performed after 2-3 weeks.

A common error when using flaps, is the tendency to inadequately mobilize or extend the flaps. All flaps should be of adequate size to remain in place without tension, otherwise dehiscence, scarring, ectropion or increased scleral show may result. On the whole, we feel that, local flaps in the form of lateral flaps, cheek flaps, nasolabial flaps, rotation advancement flaps alone or in combination with Abbe flaps, tissue rearrangement procedures, supporting flaps, or lengthening procedures such as V-Y or Z plasties, are easier to undertake and have less morbidity for the injured patient when compared with distant flaps.

#### 8.4.3. Benefits of the rhomboid flap

The rhomboid flap is versatile and can be used to cover the bullet entry wound (Figure 13).



**Figure 13.** The rhomboid flap can be used to cover the bullet entry wound.

#### 8.4.4. Benefits of Z-plasty

The primary reasons to perform a Z-plasty are to improve contour, release scar contracture, relieve skin tension, and mobilize tissue for reconstructive surgery.

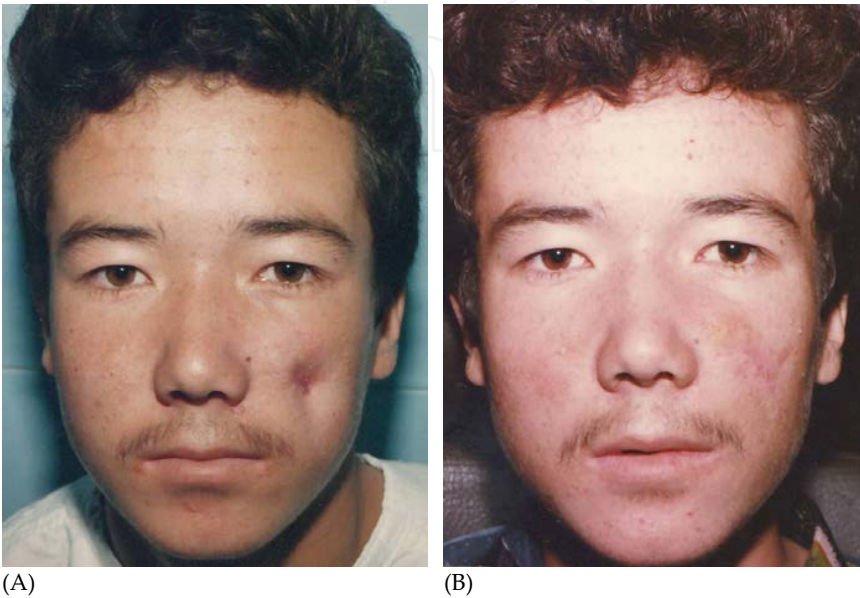Z-plasty has several main tissue effects:

- Redirection of scar - The new scar reorients from the axis of the central limb to a line connecting the tips of the lateral limbs. Z-plasty is used to redirect the scar into "relaxed skin



tension lines" (ie, Langer's lines Figure 12), natural skin folds, or along the border of an esthetic unit (ie, nasolabial fold) to improve cosmetic or functional outcome.

- Lengthening of the scar - Z-plasty lengthens the initial wound or scar. It is used to release contractures and redirect scars (Figure 14).



**Figure 14.** (A) Patient suffering a bullet wound to the left zygoma, maxilla and palate. Treated via dermal flaps and Z-plasty. (B) Patient months postoperatively. The Caldwell procedure plus antrostomy was done simultaneously with the soft tissue repair.

The amount of lengthening is related to the angle between the central and lateral limbs. Larger angles produce the most lengthening, but can be difficult to close because of skin tension. Narrow angles ( $<45^\circ$ ) are easier to close, but produce minimal lengthening and have a higher risk of flap necrosis due to their precarious blood supply.

Central/lateral limb angle	$30^\circ$	$45^\circ$	$60^\circ$	$75^\circ$	$90^\circ$
Theoretical gain in length	25%	50%	75%	100%	120%

The 60 degree Z-plasty (ie, classic Z-plasty) is most commonly used because it provides the optimal balance between lengthening and ease of closure.

- Tissue mobilization - Z-plasty mobilizes adjacent tissue to close skin defects that might otherwise have required a skin graft.

8.4.5. Free flaps

Distant or free flaps are not contraindicated and definitely have their place in the treatment and reconstruction of facial defects, and we have used them effectively in many patients. However, we prefer to consider them secondarily or as a final resort, preserving them for failed

patients or patients requiring extensive reconstruction of both hard and soft tissues of the face not amenable to local flaps, or for patients with scarred, or ischemic tissues unsuitable for the application of local flaps.

Application of local tissue transfer procedures yield acceptable tissue form, texture, and color match, especially when these procedures are used in combination, and tailored to fit the individual defect moreover, application of these procedures is relatively easy and postoperative morbidity is limited, provided the general condition of the patient is stable, the surgical techniques used have good indications and general flap principles (blood supply, length, size, adequate pedicle and mobilization etc.) have been applied. Form and function of the soft-tissue reconstructed regions usually recover within one year postoperatively. The esthetic results obtained are usually favourable. If the terminal branches of the facial nerve are injured they usually recover ( in our cases functional recovery was good).

## Author details

Mohammad Hosein Kalantar Motamedi<sup>1</sup>, Seyed Hossein Mortazavi<sup>2</sup>, Hossein Behnia<sup>2</sup>, Masoud Yaghmaei<sup>2</sup>, Abbas Khodayari<sup>3</sup>, Fahimeh Akhlaghi<sup>3</sup>, Mohammad Ghasem Shams<sup>3</sup> and Rashid Zargar Marandi<sup>4</sup>

1 Professor of Oral and Maxillofacial Surgery, Trauma Research Center, Baqiyatallah University of Medical Sciences, and Attending Surgeon, Azad University of Medical Sciences, Tehran, Iran

2 Professor of Oral and Maxillofacial Surgery, Department of Oral and Maxillofacial Surgery, Taleghani Medical Center, Shahid Beheshti University of Medical Sciences, Tehran, Iran

3 Associate Professor of Oral and Maxillofacial Surgery, Department of Oral and Maxillofacial Surgery, Taleghani Medical Center, Shahid Beheshti University of Medical Sciences, Tehran, Iran

4 Neurosurgeon, Department of Neurosurgery, Baqiyatallah University of Medical Sciences. Tehran, Iran

## References

- [1] Weider, L, Hughes, K, Ciarochi, J, & Dunn, E. Early versus delayed repair of facial fractures in the multiply injured patient. *Am Surg* (1999). , 65, 790-7.
- [2] Motamedi, M. H. Primary treatment of penetrating injuries to the face. *J Oral Maxillofac Surg* (2007). , 65, 1215-8.



- [3] Glapa, M, Kourie, J. F, Doll, D, & Degiannis, E. Early management of gunshot injuries to the face in civilian practice. *World J Surg* (2007). , 31, 2104-10.
- [4] Kincaid, B, & Schmitz, J. P. Tissue injury and healing. *Oral Maxillofac Surg Clin North Am* (2005). , 17, 241-50.
- [5] Ueeck, B. A. Penetrating injuries to the face: Delayed versus primary treatment-considerations for delayed treatment. *J Oral Maxillofac Surg* (2007). , 65, 1209-14.
- [6] Shvyrkov, M. B. Primary surgical treatment of gunshot wounds of facial skeleton. *Stomatologiia (Mosk)* (2001). , 80, 36-40.
- [7] Motamedi, M. H. Primary management of maxillofacial hard and soft tissue gunshot and shrapnel injuries. *J Oral Maxillofac Surg*. (2003). Dec;, 61(12), 1390-8.
- [8] Mclean, J. N, Moore, C. E, & Yellin, S. A. Gunshot wounds to the face-acute management. *Facial Plast Surg* (2005). , 21, 191-8.
- [9] Hollier, L, Grantcharova, E. P, & Kattash, M. Facial gunshot wounds: A 4-year experience. *J Oral Maxillofac Surg* (2001). , 59, 277-83.
- [10] Baig, M. A. Current trends in the management of maxillofacial trauma. *Ann R Australas Coll Dent Surg* (2002). , 16, 123-7.
- [11] Liebllich, S. E, & Topazian, R. G. Infection in the patient with maxillofacial trauma. In: Fonseca RJ, Walker RV, editors. *Oral and maxillofacial trauma*. Philadelphia: Saunders; (1991). , 1157-1159.
- [12] Peleg, M, & Sawatari, Y. Management of gunshot wounds to the mandible. *J Craniofac Surg*. (2010). Jul;, 21(4), 1252-6.
- [13] Vayvada, H, Menderes, A, Yilmaz, M, Mola, F, Kzlkaya, A, & Atabey, A. Management of close-range, high-energy shotgun and rifle wounds to the face. *J Craniofac Surg* (2005). , 16, 794-804.
- [14] Motamedi, M. H, & Behnia, H. Experience with regional flaps in the comprehensive treatment of maxillofacial soft-tissue injuries in warfare victims. *J Craniomaxillofac Surg* (1999). , 27, 256-9.
- [15] Motamedi, M. H, Khatami, S. M, & Tarighi, P. Assessment of severity, causes, and outcomes of hospitalized trauma patients at a major trauma center. *J Trauma*. (2009). Feb;, 66(2), 516-8.
- [16] Motamedi, M. H. Management of firearm injuries to the facial skeleton: Outcomes from early primary intervention. *J Emerg Trauma Shock* (2011). , 4, 212-6.
- [17] Motamedi, M. H, Sagafinia, M, & Famouri-hosseinzadeh, M. Oral and maxillofacial injuries in civilians during training at military garrisons: prevalence and causes. *Oral Surg Oral Med Oral Pathol Oral Radiol Endod*. (2012). jul;114(1):49-51

- [18] Sali Bukhari SG Khan I, Pasha B, Ahmad W. Management of facial gunshot wounds. *J Coll Physicians Surg Pak* (2010). , 20, 382-5.
- [19] Behnia, H. Motamedi MHK: Reconstruction and rehabilitation of short-range, high-velocity gunshot injury to the lower face. *J Cranio Maxillofac Surg* (1997). , 25, 220-4.
- [20] Motamedi, M. H, Hashemi, H. M, Shams, M. G, & Nejad, A. N. Rehabilitation of war-injured patients with implants: analysis of 442 implants placed during a 6-year period. *J Oral Maxillofac Surg*. (1999). Aug;discussion 914-5., 57(8), 907-13.
- [21] Wei-Yung YIH Howerton DW: A regional approach to reconstruction of the upper lip. *J Oral Maxillofac Surg* (1997).
- [22] Taher AA: Management of weapon injuries to the craniofacial skeleton *J Craniofac Surg* 9, 371, (1998).
- [23] Osborne, T. E. Bays RA: Pathophysiology and management of gunshot wounds to the face: In: Fonseca R J, Walker RV (eds.): *Oral and maxillofacial trauma*, Philadelphia: WB Saunders, 672, (1991). , 2
- [24] Berlin, R, Gerlin, L. E, Jenson, B, et al. Local effects of assault rifle bullets in live tissues. *Acta Chir Scand Suppl* (1976).
- [25] Shelton DW: Gunshot wounds In: Peterson LJ, Indresano AT, Marciani RD, Roser SM (eds.): *Principles of oral and maxillofacial surgery*, Philadelphia: JB Lippincott, 596, (1992). , 1
- [26] Converse, J. M. Wood-Smith D: Techniques for the repair of defects of the lips and cheeks: In: Converse JM (ed.): *Reconstructive Plastic Surgery*, Philadelphia: WB Saunders, (1977). , 3, 1547.
- [27] Carray, J. H. Vincent MP: Reconstruction of eyelid deformities: In: Georgiade NG, Georgiade GS, Riefkohl R (eds.): *Essentials of plastic, maxillofacial and reconstructive surgery*. Baltimore, Maryland: Williams and Wilkins, (1987). , 480.
- [28] Jackson IT: *Local flaps in head and neck reconstruction* St Louis: CV Mosby, 189, (1985).
- [29] Kalantar Motamedi MH *Comprehensive Management of Maxillofacial Projectile Injuries at the First Operation; "Picking up the Pieces"*. *Trauma Mon.* (2013). , 17(4), 365-6.

