

We are IntechOpen, the world's leading publisher of Open Access books Built by scientists, for scientists

6,900

Open access books available

186,000

International authors and editors

200M

Downloads

Our authors are among the

154

Countries delivered to

TOP 1%

most cited scientists

12.2%

Contributors from top 500 universities



WEB OF SCIENCE™

Selection of our books indexed in the Book Citation Index
in Web of Science™ Core Collection (BKCI)

Interested in publishing with us?
Contact book.department@intechopen.com

Numbers displayed above are based on latest data collected.
For more information visit www.intechopen.com



Cardiac Trauma

Daniel Eiferman,
R. Nathan Cotterman and
Michael Firstenberg

Additional information is available at the end of the chapter

<http://dx.doi.org/10.5772/55723>

1. Introduction

1.1. History of cardiac trauma

The treatment of trauma to the heart has been written about since 3000 BC and had an inauspicious beginning. Until the late 19th century, the commonly held belief agreed with Boerhaave's sentiments that, "all penetrating cardiac trauma is fatal." Theodore Billroth warned, "The surgeon who should attempt to suture a wound of the heart would lose the respect of his colleagues." Paget believed that "surgery of the heart has probably reached the limits set by nature to all surgery: no new method of discovery can overcome the natural difficulties that attend a wound of the heart." However, reports of successful treatment of cardiac injuries began to surface toward the beginning of the 20th century. Like many surgical advances, times of war brought about new innovations and techniques for treating injuries.

Around the time of World War II, it was recognized that cardiac tamponade could be successfully managed by pericardiocentesis. With the advent of cardiopulmonary bypass by Gibbon in 1953, repair of more complex injuries became possible. This ushered in the modern era of treating injuries to the heart. Diagnosis of cardiac injury and tamponade has also been facilitated by portable ultrasound becoming the standard of care in the evaluation of trauma patients. The focused assessment with sonography for trauma (FAST) scan allows for simple, quick, and non-invasive assessment and recognition of cardiac trauma [1].

Cardiac trauma, especially penetrating injuries to the heart, still carries a very high mortality, but certainly is no longer considered uniformly fatal and attempt at repair is now the standard of care in patients presenting with signs of life upon arrival to the hospital[2, 3].

2. Initial assessment and general assessment

The initial care of the trauma patient with cardiac injuries does not vary from standard Advanced Trauma Life Support (ATLS) protocols. The primary priority is ensuring the patency of the airway and establishing adequate oxygenation and ventilation. This may include tube thoracostomy for drainage of hemothorax from the pleural space to allow re-expansion of the lung. Subsequently, the circulatory system is assessed. Priority is given to establishing intravenous access for the administration of crystalloid and/or blood products. If cardiac tamponade is suspected, this should be confirmed with sonographic confirmation of hemo-pericardium and/or right ventricular collapse during diastole[4]. If tamponade physiology is present, treatment for immediate drainage of the pericardial space should be initiated. This can be accomplished percutaneously by pericardiocentesis or via open pericardial window.

The treatment algorithm for cardiac injured patients branches at this point depending on the mechanism of injury and hemodynamic status. As is the standard in all trauma care, cardiac injuries are categorized as either blunt or penetrating and we will explore their assessment and treatment separately.

3. Penetrating trauma

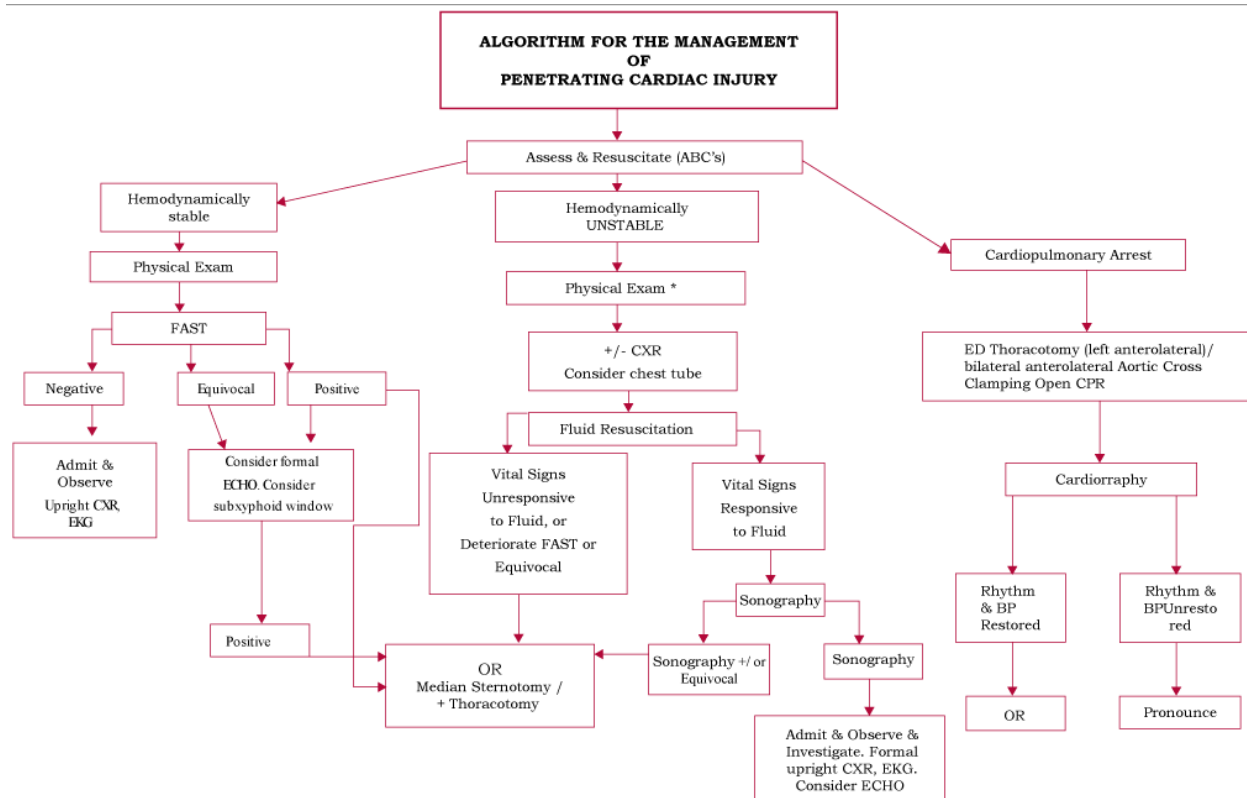
Penetrating trauma to the heart most frequently occur with trauma to the anterior chest, but should also be suspected with wounds to the upper abdomen, chest, back, and neck [5]. Of the patients that do present to the hospital, the majority of the injuries are to the low pressure, anteriorly located right side of the heart (Table 1) [6]. Survival following penetrating trauma is often dependent on the state of the pericardial wound.[7] When the pericardial wound is open and blood is able to flow freely into the pleural space, the patient can often be supported with fluid resuscitation and chest tube thoracostomy. Persistent drainage from the thoracostomy tube should warn of possible cardiac injury and surgical exploration is indicated. Conversely, if the blood is retained in the pericardial space, cardiac tamponade and physiology will ensue if not drained immediately.

Right Atrium	14%	Left Atrium	5%
Right Ventricle	43%	Left Ventricle	33%
Coronary Arteries Involved	3.1-4.4%		

Table 1. Anatomic Location of Penetrating Cardiac Injuries

The protocol for treatment of patients with penetrating cardiac trauma can be further subdivided based upon the patient's vital signs upon presentation to the hospital (Figure 1). Management of the stable patient (systolic blood pressure greater than 90 mm Hg) allows for a more complete evaluation including chest x-ray and echocardiography. Unstable patients

(systolic blood pressure less than 90 mm Hg) are taken directly to the operating room for exploration while patients with loss of vitals during transport or upon presentation to the hospital are treated with Emergency Department thoracotomy.



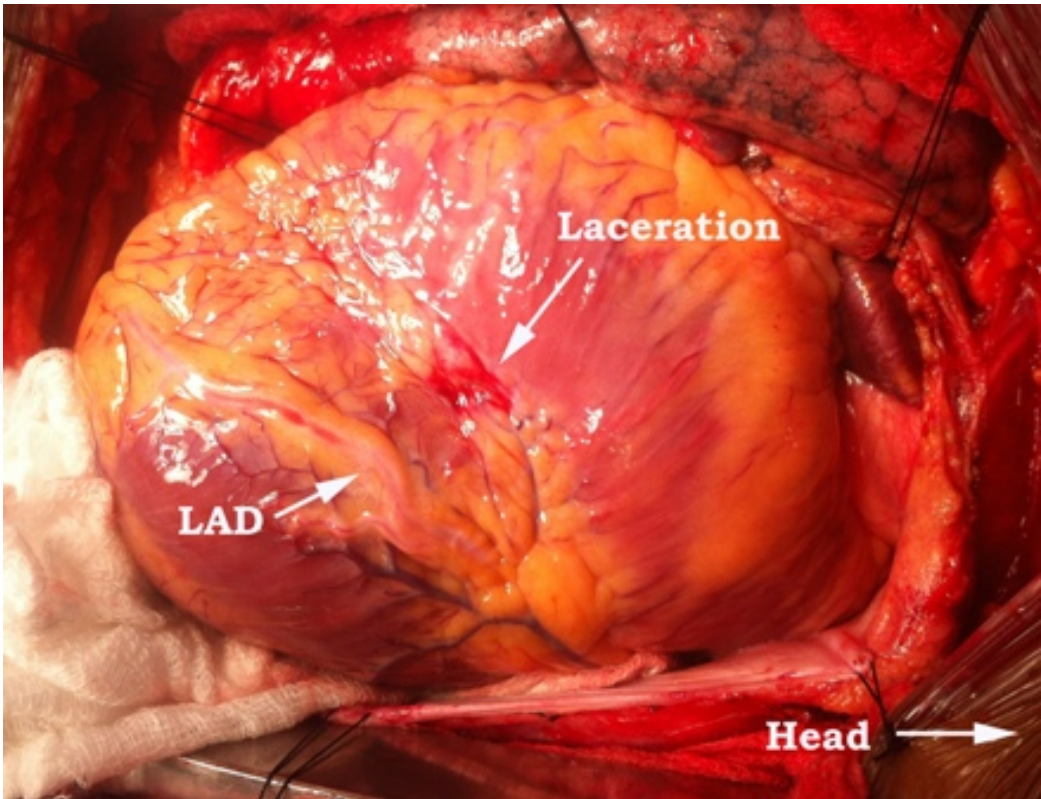
Source: Feliciano DV, Mattox KL, Moore EE: *Trauma*, 6th Edition: <http://www.accesssurgery.com>
Copyright © The McGraw-Hill Companies, Inc. All rights reserved.

Figure 1. Algorithm for the Management of Penetrating Cardiac Injury

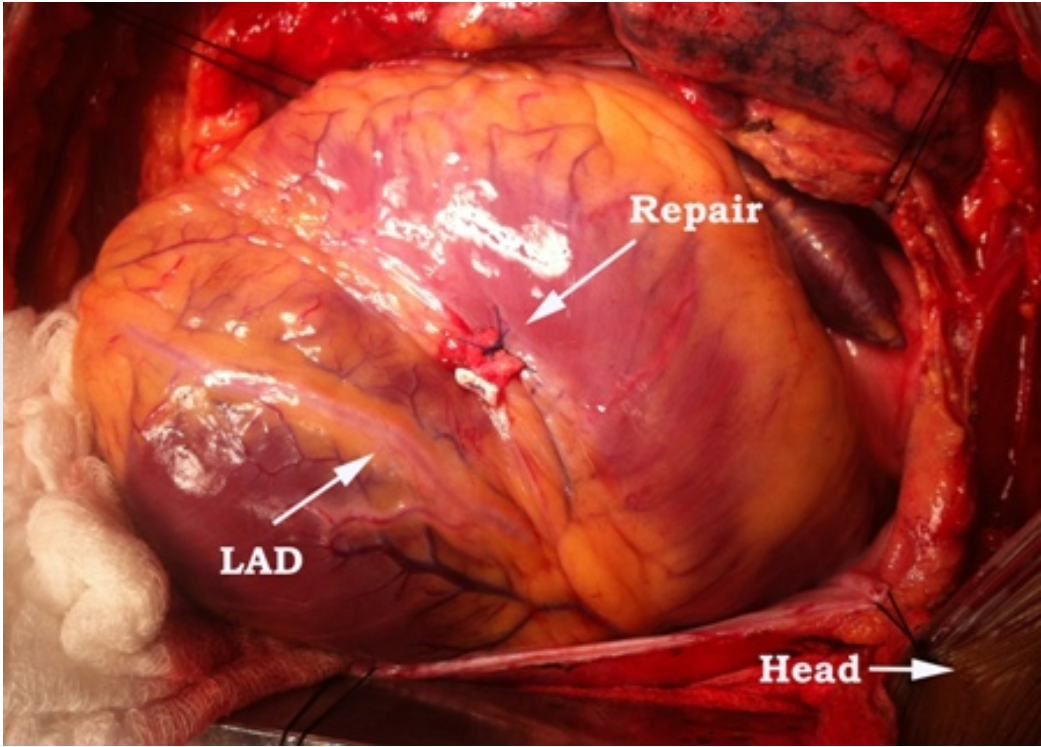
If the diagnosis of penetrating cardiac injury is suspected but not confirmed, a subxyphoid pericardial window should be performed. Surgeons should be prepared to do a median sternotomy if an injury is identified in order to definitely address the wound. Upon opening the pericardial sac, any blood or fluid should be evacuated to allow the heart to properly fill and contract. The surgeon's finger can be used to apply pressure and temporarily control hemorrhage while further exposure is gained. This will also allow for replacement of blood volume and restoration of tissue perfusion.

Repair of the myocardium should be done with interrupted sutures utilizing pledgets and performed in a horizontal mattress fashion [7, 8]. Injuries to small coronary arteries can be treated with simple ligation. Larger coronary arteries require either direct repair or bypass and the operating room should be capable of cardiopulmonary bypass (CPB).[7] Intracardiac injuries require CPB to be definitively addressed.

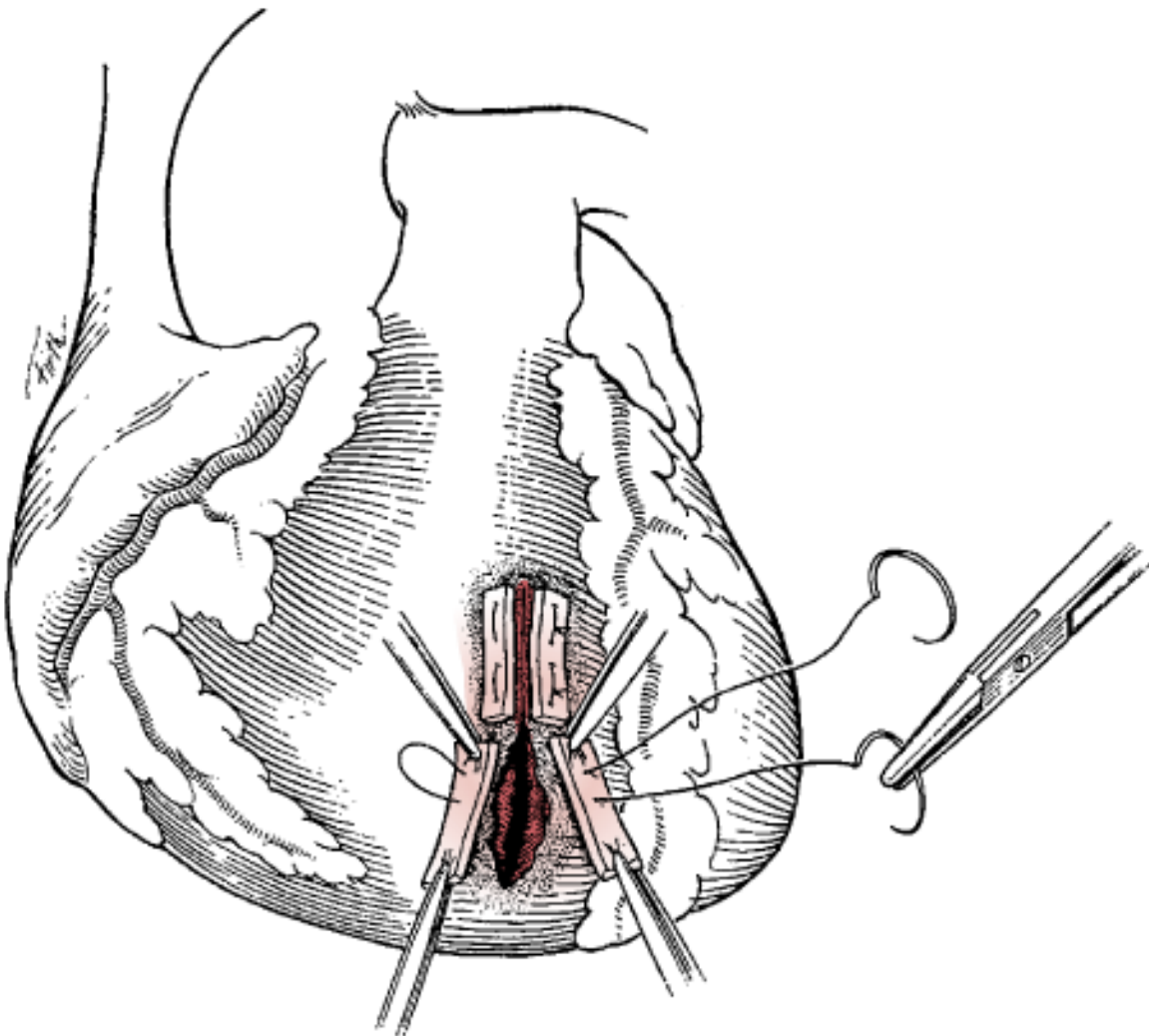
Whatever injury is encountered and method of repair utilized, the operative principles are universal: relieve tamponade, stop the bleeding, and restore circulating volume. [8]



Picture 1. Cardiac Laceration from anterior stab wound



Picture 2. Successful pledgeted repair



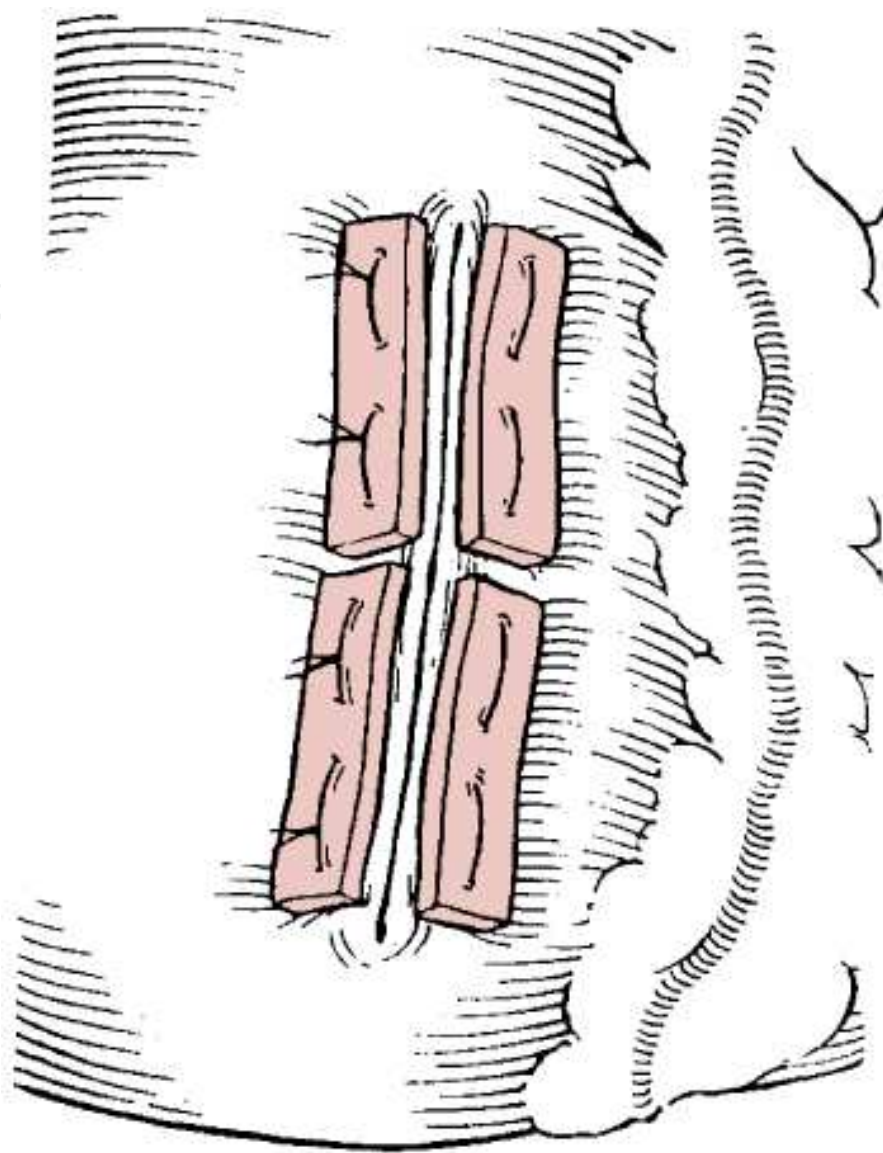
Source: Feliciano DV, Mattox KL, Moore EE: *Trauma*, 6th Edition:
<http://www.accesssurgery.com>

Copyright © The McGraw-Hill Companies, Inc. All rights reserved.

Figure 2. Schematic Depiction of Right Ventricular Repair

3.1. Iatrogenic injuries

Another form of penetrating cardiac injury that has increased in the modern era is iatrogenic injuries. As the fields of interventional and electrophysiology cardiology continue to increase the number of percutaneous procedures performed, there is a concomitant increase in iatrogenic injuries to the heart. Pacemaker and ICD placement, ASD occlusion devices, coronary catheterization, pericardiocentesis, and even central line placement can cause cardiac trauma. Usually the treatment is observational, but sometimes intervention is necessary. Fortunately these are rare complications but the incidence of iatrogenic injury has been reported as high as 6% for certain radiofrequency ablation procedures.[9] Awareness and prompt recognition of an injury are essential to successful treatment.



Source: Feliciano DV, Mattox KL, Moore EE: *Trauma*, 6th Edition: <http://www.accesssurgery.com>

Copyright © The McGraw-Hill Companies, Inc. All rights reserved.

Figure 3. Pledgets are used to reinforce the suture line

3.2. Cardiac fistulas

Although hemorrhage and tamponade are the most common injuries seen in penetrating cardiac trauma, cardiac fistulas are another uncommon yet dramatic complication from cardiac trauma (including iatrogenic injuries). Fistulous connections can occur between coronary arteries, aorta, and directly with the cardiac chambers. Patients, if symptomatic, usually present with congestive heart failure and surgical repair is usually required.[10, 11]. Presentation is variable from acutely after the injury to decades post-injury. Echocardiography and coronary angiography are the cornerstones of diagnosis and necessary to plan surgical repair.

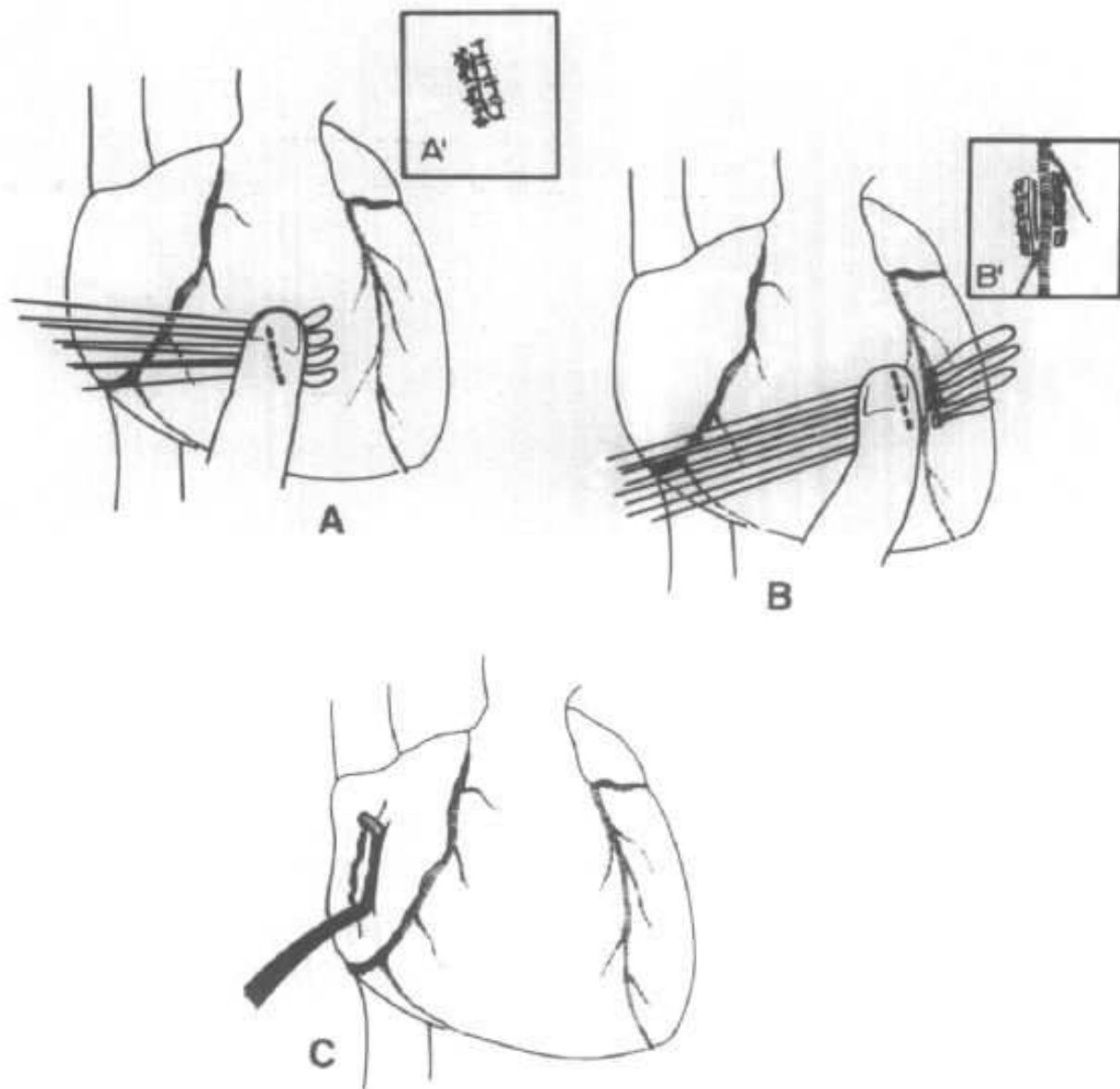
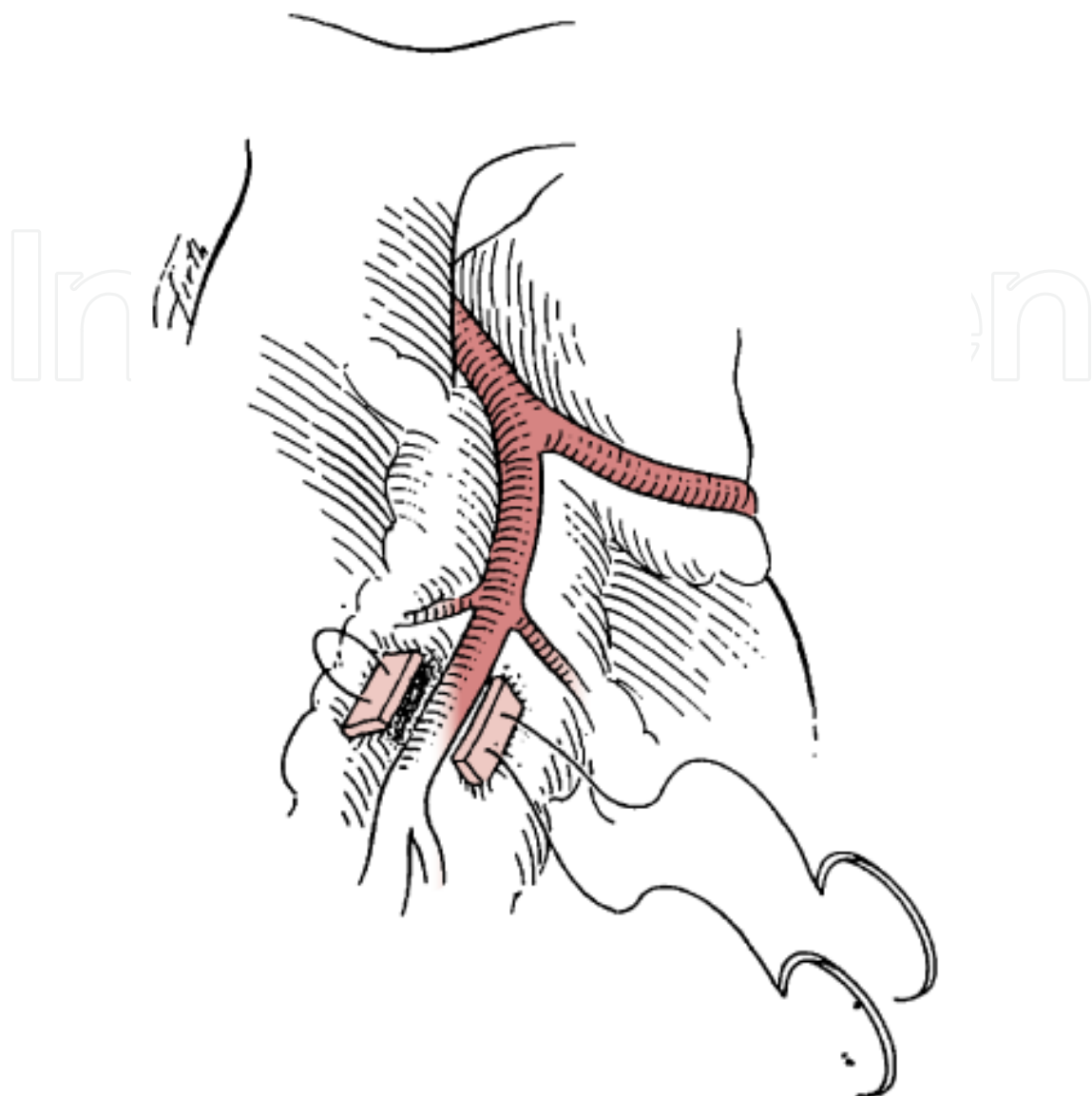


Figure 4. Various maneuvers used to repair penetrating wounds of the heart. Suturing of cardiac wound underneath the wound-occluding finger (A). Wound sutured (A'). Placement of horizontal mattress sutures through the myocardium underneath the cardiac wound-occluding finger and underneath the coronary artery adjacent to the wound (B). Wound sutured (B'). Control of atrial bleeding with a vascular clamp (C). (From Symbas PN: *Cardiothoracic Trauma*. Philadelphia, WB Saunders Co, 1989, p 42. Used by permission.)

4. Blunt injury

4.1. Background (mechanism, incidence, and pathophysiology)

Blunt cardiac injury (BCI) is a spectrum of traumatic heart diseases with severity that can range from myocardial contusion and EKG changes to septal rupture and death. Earlier in the century, cardiac contusion or concussion were terms used to diagnose cardiac changes from blunt thoracic trauma. More recently, BCI is the term used to better incorporate and classify



Source: Feliciano DV, Mattox KL, Moore EE: *Trauma*, 6th Edition: <http://www.accesssurgery.com>

Copyright © The McGraw-Hill Companies, Inc. All rights reserved.

Figure 5.

the myriad of cardiac injuries that result from blunt trauma. BCI is estimated to occur in 20% of motor vehicle collisions and in greater than 75% of thoracic blunt injuries independent of the mechanism. The primary mechanism of injury to the heart is from high-speed motor vehicle collision, but any injury that applies force in the form of kinetic energy to the chest wall and heart can result in a form of BCI. The following mechanisms of injury may result in BCI: direct precordial impact, a crush injury between the sternum and spine, a deceleration injury causing injury from the fixation points of the aorta and vena cava, a hydraulic effect from an intraabdominal injury that sends force to the great vessels and heart, or a crush injury [12].

Since blunt cardiac injury is a spectrum of injuries to the heart, a classification scheme was developed to allow clinicians to categorize the types of injury based on outcomes and treatment options. These categories are as follows: 1) BCI with free wall rupture, 2) BCI with septal rupture, 3) BCI with coronary artery rupture, 4) BCI with cardiac failure, 5) BCI with complex arrhythmias, and 6) BCI with minor ECG or cardiac enzyme abnormalities. The American Association for the Surgery of Trauma (AAST) has also published a cardiac injury scale (Table 2) that may help to codify injury for diagnosis and research. Injuries sustained with blunt cardiac injury (BCI) include contusion, ruptures, septal defects, valvular injuries, and coronary artery injuries. Table 3 lists each of these types and the incidence seen from both autopsy and clinical series. Contusion is the most common type of injury with left atrial chamber rupture being least common. Injuries can often occur concomitantly; approximately 20% of injuries with chamber rupture will have another chamber involved. The right heart is the most commonly injured as it is closest to the sternum which is impacted anteriorly by the steering wheel in motor vehicle collisions. Besides having concomitant cardiac injuries, the force needed to cause a BCI will often cause associated injuries such as chest pain, rib fractures, pulmonary contusions, and solid organ injuries; the most common associated injuries that occur with BCI are listed in Table 5.

4.2. Diagnosis

The best test for diagnosing blunt cardiac injury has been debated for many years. Cardiac enzymes, radionuclide scans, EKG, cardiac ultrasound and continuous monitoring are some of the major methods that have been investigated. Although cardiac enzymes and radionuclide scans have had many supporters these have not shown reliable predictability in diagnosing blunt cardiac injury and have therefore been left out of the Eastern Association for the Surgery of Trauma (EAST) guidelines (figure 6). Cardiac enzymes, specifically serial troponin measurements are mentioned in the suggested BCI algorithm by Schultz and Trunkey 2004 (figure 7) as an adjunct to increase the negative predictive value of the normal EKG when you have a patient who has either a history of cardiac disease or increased age. EKG has emerged as the primary screening tool for blunt cardiac injury. There are no pathognomonic findings; however, the presence of a new arrhythmia is a sign that workup needs to be escalated. If the EKG is negative in a young hemodynamically stable patient without a history of cardiac disease there is no further need for workup [12]. If the EKG is abnormal, and the patient has a history of cardiac disease, increased age or hemodynamic instability then continuous telemetry monitoring for 24-48 hours is recommended. Those with hemodynamic instability require continuous monitoring in a surgical ICU. Any arrhythmia may be detected after BCI including sinus tachycardia, supraventricular arrhythmias, ventricular arrhythmias, any type of heart block, ST-T changes or Q waves [13].

Although, these patients are likely to have had a FAST exam in the emergency room, it is important to figure out who needs a formal echocardiogram. The key indication is hemodynamic instability and a possible diagnosis of blunt cardiac injury. Anyone meeting these criteria requires a formal echocardiogram. There has been debate over whether to use trans-thoracic or transesophageal echocardiography. The recommendations are that the patient

receive the first available study method. If transthoracic echocardiography is used and adequate imaging cannot be obtained, then a transesophageal echocardiogram should be initiated immediately.

Grade	Description of injury	ICD-9	AIS-90
I	Blunt cardiac injury with minor ECG abnormality (nonspecific ST or T wave changes, premature arterial or ventricular contraction or persistent sinus tachycardia)	861.01	3
	Blunt or penetrating pericardial wound with out cardiac injury, cardiac tamponade, or cardiac herniation	861.01	3
II	Blunt cardiac injury with heart block (right or left bundle branch, left anterior fascicular, or atrioventricular) or ischemic changes (ST depression or T wave inversion) without cardiac failure	861.12	3
	Penetrating tangential myocardial wound up to, but not extending through endocardium, without tamponade	861.01	3-4
III	Blunt cardiac injury with sustained (≥ 6 beats/min) or multilocal ventricular contractions	861.01	3-4
	Blunt or penetrating cardiac injury with septal rupture, pulmonary or tricuspid valvular incompetence, papillary muscle dysfunction, or distal coronary arterial occlusion without cardiac failure	861.01	3-4
	Blunt pericardial laceration with cardiac herniation	861.12	3-4
	Blunt cardiac injury with cardiac failure	861.12	3-4
	Penetrating tangential myocardial wound up to, but extending through, endocardium, with tamponade	861.03	3
IV	Blunt or penetrating cardiac injury with septal rupture, pulmonary or tricuspid valvular incompetence, papillary muscle dysfunction, or distal coronary arterial occlusion producing cardiac failure	861.03	3
	Blunt or penetrating cardiac injury with aortic mitral valve incompetence	861.13	3
	Blunt or penetrating cardiac injury of the right ventricle, right atrium, or left atrium	861.03	5
V	Blunt or penetrating cardiac injury with proximal coronary arterial occlusion	861.13	5
	Blunt or penetrating left ventricular perforation		5
	Stellate wound with < 50% tissue loss of the right ventricle, right atrium, or of left atrium		5
VI	Blunt avulsion of the heart		6
	Penetrating wound producing > 50% tissue loss of a chamber		6

*Advance one grade for multiple wounds to a single chamber or multiple chamber involvement.

Table 2. Cardiac Injury Scale

4.3. Management

Since blunt cardiac injury describes a spectrum of disease states, the treatment depends on the actual problem. Arrhythmia can be managed medically with the caveat that anticoagulation needs to be used cautiously in trauma patients. Hemopericardium can be seen with or without

Cardiac Injury	Incidence of injury in autopsy series of patients with BCI	Incidence of injury in clinical series of patients with BCI
Myocardial contusion	60% to 100%	60% to 100%
Chamber Rupture		
Right Ventricle	19% to 32%	17% to 32%
Right Atrium	10% to 15%	8% to 65%
Left Ventricle	5% to 44%	8% to 15%
Left Atrium	1% to 7%	0% to 31%
Atrial Septal Defect	7%	Case reports
Valve Injury in BCI	5%	Case reports
Ventricular Septal Defect	4%	Case reports
Coronary Artery Injury	3%	Case reports

Table 3. BCI Patterns of Injury

Associated Injuries	Incidence of finding in patients with BCI
Chest Pain	18% to 92%
Rib Fracture	18% to 69%
Aortic or great vessel injury	20% to 40%
Hemothorax	7% to 64%
Pulmonary Contusion	6% to 58%
Pneumothorax	7% to 40%
Flail Chest	4% to 38%
Sternal Fracture	0% to 60%
Traumatic Brain Injury	20% to 73%
Extremity Injury	20% to 66%
Abdominal Solid Organ Injury	5% to 43%
Spinal Injury	10% to 20%

Table 4. Injuries Associated with BCI

hypotension or tamponade. If hemopericardium is suspected and the patient is stable a subxiphoid pericardial window can be used to verify the hemopericardium. Once a pericardial window is performed, the surgeon must be prepared to proceed with a median sternotomy. If the patient is hypotensive and tamponade is expected then either a subxiphoid pericardial window or a thoracotomy can be performed. As a rule free wall rupture is more common in the atria than the ventricles and more common on the right than the left. This is thought to be

EAST guidelines

A. Level I

1. An admission EKG should be performed on all patients in who there is suspected BCI.

B. Level II

1. If the admission EKG is abnormal (arrhythmia, ST changes, ischemia, heart block, unexplained ST), the patient should be admitted for continuous EKG monitoring for 24 to 48 hours. Conversely, if the admission EKG is normal, the risk of having a BCI that requires treatment is insignificant, and the pursuit of diagnosis should be terminated.
2. If the patient is hemodynamically unstable, an imaging study (echocardiogram) should be obtained. If an optimal transthoracic echocardiogram cannot be performed, then the patient should have a transesophageal echocardiogram.
3. Nuclear medicine studies add little when compared to echocardiography and, thus, are not useful if an echocardiogram has been performed.

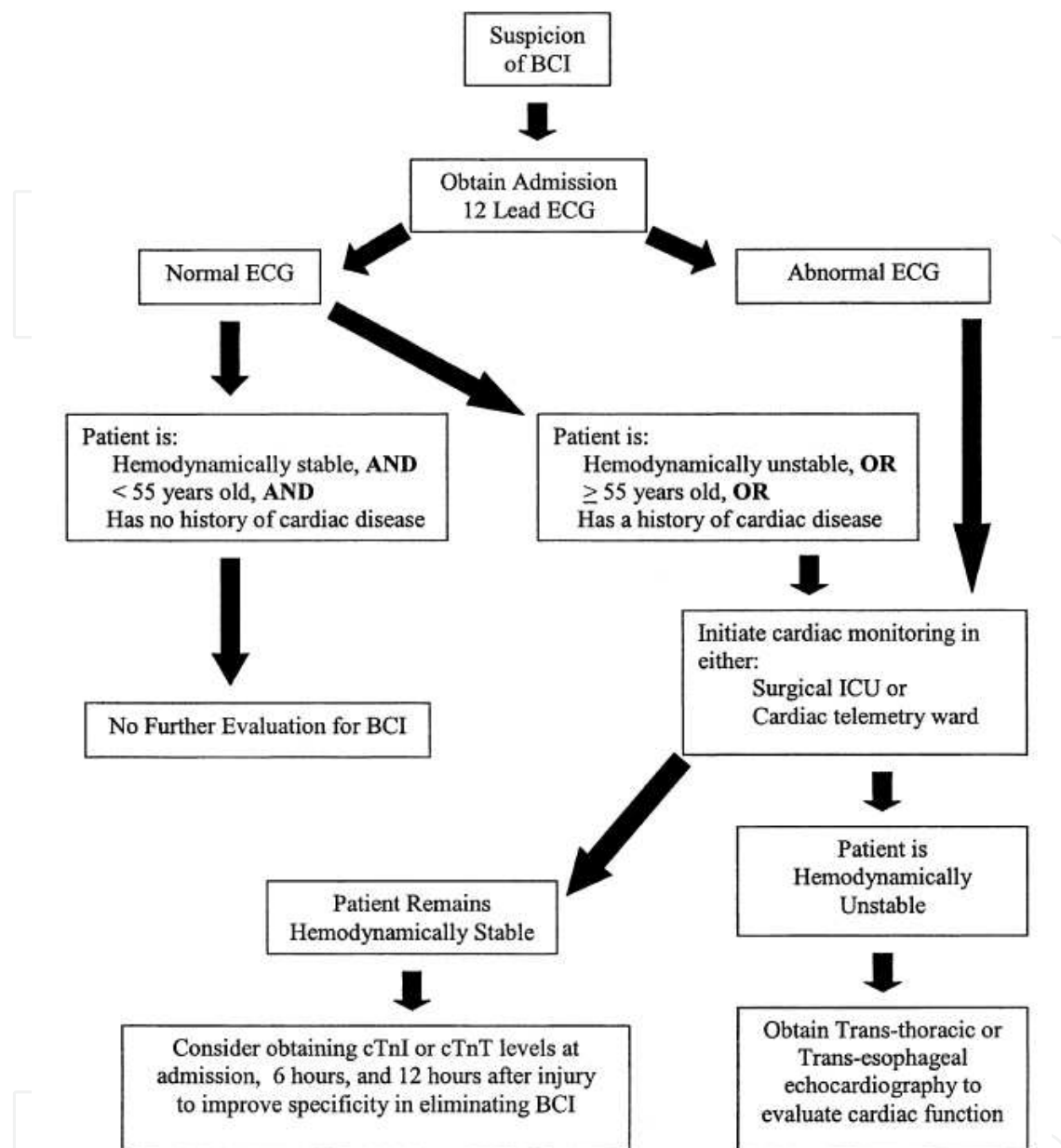
C. Level III

1. Elderly patients with known cardiac disease, unstable patients, and those with an abnormal admission EKG can be safely operated on provided they are appropriately monitored. Consideration should be given to placement of a pulmonary artery catheter in such cases.
2. The presence of a sternal fracture does not predict the presence of BCI and, thus, does not necessarily indicate that monitoring should be performed.
3. Neither creatinine phosphokinase with isoenzyme analysis nor measurement of circulating cardiac troponin T are useful in predicting which patients have or will have complications related to BCI.

Screening of Blunt Cardiac Injury. Pasquale, N K and Clark, J. s.l. : The Eastern Association for the Surgry of Trauma, 1998.

Figure 6. EAST guidelines for Blunt Cardiac Injury

due in part to the position of the heart in the chest. The method of repairing the atria is to grasp each side of the atrial wound, place a vascular clamp across the defect, and sew it closed. The method of repair of the ventricle is to place a finger of the non-dominant hand over the injury occluding the wound and stopping the blood loss. Then pledgeted mattress sutures are placed under the finger in order to approximate the wound without tearing through the injured myocardium. Septal rupture requires the patient to be placed on bypass. Coronary artery injury, valve injury and papillary muscle rupture are all very rare. These entities generally

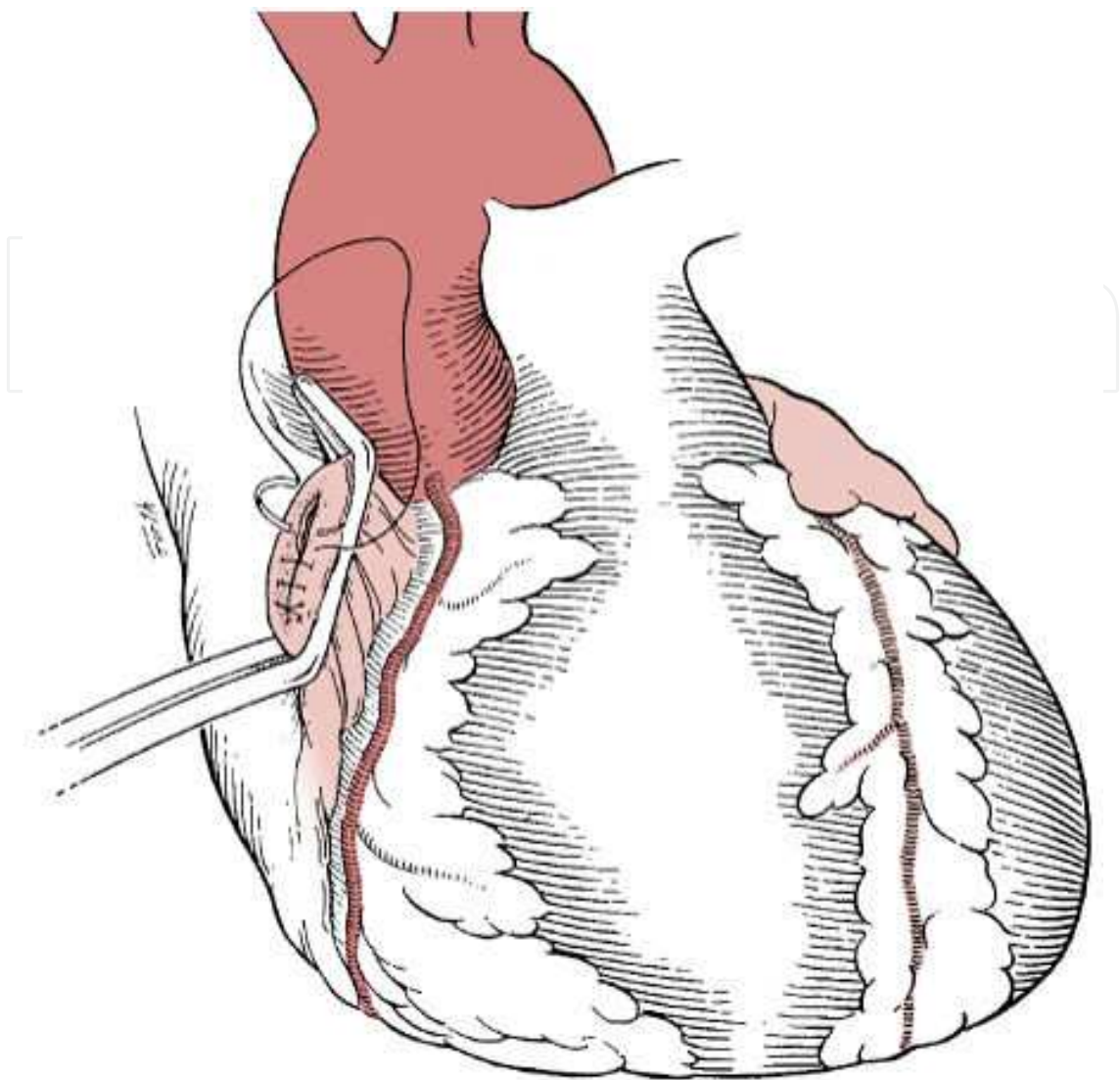


Blunt Cardiac Injury. Schultz JM, Trunkey DD. Critical Care Clin. 20 (2004) 57-70[12]

Figure 7. Algorithm for treatment of suspected BCI

present with clinically significant acute congestive heart failure. Another rare entity is pericardial rupture with cardiac herniation. This requires opening the chest with replacement of the heart in the normal anatomic position and repair of any injured vasculature. Whether you utilize a thoracotomy or sternotomy will depend on the details of the cardiac herniation.

Outcomes of emergency department thoracotomy for blunt trauma are universally poor. The salvage rate of patients with or without vital signs on arrival to the emergency department is 1%-2% [14]. This low survival rate mandates that before an emergency department thoracot-



Source: Feliciano DV, Mattox KL, Moore EE: *Trauma*, 6th Edition:
<http://www.accesssurgery.com>

Copyright © The McGraw-Hill Companies, Inc. All rights reserved.

Figure 8. Schematic Representation of right atrial repair

omy is undertaken both the mechanism of injury and the length or presence of CPR be taken into consideration.

Author details

Daniel Eiferman*, R. Nathan Cotterman and Michael Firstenberg

Ohio State University Medical Center, Department of Surgery, Division of Trauma, Critical Care, and Burn, Columbus, OH, USA

References

- [1] Rozycki, G.S., et al., The role of ultrasound in patients with possible penetrating cardiac wounds: a prospective multicenter study. *J Trauma*, 1999. 46(4): p. 543-51; discussion 551-2.
- [2] Thourani, V.H., et al., Penetrating cardiac trauma at an urban trauma center: a 22-year perspective. *Am Surg*, 1999. 65(9): p. 811-6; discussion 817-8.
- [3] Velmahos, G.C., et al., Penetrating trauma to the heart: a relatively innocent injury. *Surgery*, 1994. 115(6): p. 694-7.
- [4] Plummer, D., et al., Emergency department echocardiography improves outcome in penetrating cardiac injury. *Ann Emerg Med*, 1992. 21(6): p. 709-12.
- [5] Karrel, R., M.A. Shaffer, and J.B. Franaszek, Emergency diagnosis, resuscitation, and treatment of acute penetrating cardiac trauma. *Ann Emerg Med*, 1982. 11(9): p. 504-17.
- [6] Asensio, J.A., et al., Penetrating cardiac injuries: a prospective study of variables predicting outcomes. *J Am Coll Surg*, 1998. 186(1): p. 24-34.
- [7] Symbas, P.N., Cardiothoracic trauma. *Curr Probl Surg*, 1991. 28(11): p. 741-97.
- [8] Evans, J., et al., Principles for the management of penetrating cardiac wounds. *Annals of Surgery*, 1979. 189(6): p. 777-84.
- [9] Kang, N., et al., Penetrating cardiac injury: overcoming the limits set by Nature. *Injury*, 2009. 40(9): p. 919-27.
- [10] Hancock Friesen, C., J.G. Howlett, and D.B. Ross, Traumatic coronary artery fistula management. *Ann Thorac Surg*, 2000. 69(6): p. 1973-82.
- [11] Lowe, J.E., et al., The natural history and recommended management of patients with traumatic coronary artery fistulas. *Ann Thorac Surg*, 1983. 36(3): p. 295-305.
- [12] Schultz, J.M. and D.D. Trunkey, Blunt cardiac injury. *Crit Care Clin*, 2004. 20(1): p. 57-70.
- [13] Sutherland, G.R., et al., Anatomic and cardiopulmonary responses to trauma with associated blunt chest injury. *J Trauma*, 1981. 21(1): p. 1-12.
- [14] Cothren, C.C. and E.E. Moore, Emergency department thoracotomy for the critically injured patient: Objectives, indications, and outcomes. *World J Emerg Surg*, 2006. 1: p. 4.

