

We are IntechOpen, the world's leading publisher of Open Access books Built by scientists, for scientists

6,900

Open access books available

185,000

International authors and editors

200M

Downloads

Our authors are among the

154

Countries delivered to

TOP 1%

most cited scientists

12.2%

Contributors from top 500 universities



WEB OF SCIENCE™

Selection of our books indexed in the Book Citation Index
in Web of Science™ Core Collection (BKCI)

Interested in publishing with us?
Contact book.department@intechopen.com

Numbers displayed above are based on latest data collected.
For more information visit www.intechopen.com



Current Strategies in the Management of Adenocarcinoma of the Rectum

Sergio Huerta and Sean P. Dineen

Additional information is available at the end of the chapter

<http://dx.doi.org/10.5772/55827>

1. Introduction

In 2012, rectal cancer affected 40,290 Americans. Colon and rectal cancer resulted in a mortality of 51,690 individuals during the same year [1]. Patients affected with rectal cancer who have a clinical stage II (T3-T4, NO, MO) or III (Any T, N1-N3, M0) tumor are treated with pre-operative chemoradiation (CRT) followed by surgical intervention 5-10 weeks after the last CRT treatment. An adequate oncologic operation involves removal of the tumor and the entire mesorectum (total mesorectal excision). This has been demonstrated to decrease local recurrence substantially as the lymphatic drainage of the rectum is contained within the investing fascia (mesorectum). Distal rectal tumors involving the anorectal sphincter complex are classically treated with an abdominoperineal resection (APR); whereas, more proximal tumors might be treated with an anterior protosigmoidectomy with a primary colorectal anastomosis (LAR). There has been a substantial shift in the number of APR operations to LAR procedures over the past decade owing to the implementation of new circular stapling devices and the use of neoadjuvant CRT.

2. The rectum

In a Cochrane review of 19 clinical trials assessing preoperative radiotherapy *vs.* surgery alone, the rectum was alternatively defined as below the sacral promontory in three studies, below the pelvic brim in one study, and by the distance from the anal verge in several studies: 12 cm (one study), 13 cm (one study), 14 cm (one study), 15 cm (five studies), and 16 cm (one study) [2]. The hazard ratio for recurrence in patients receiving radiotherapy was less if tumors were located within five to 10 cm from the anal verge, but there was no difference in local recurrence

in patients treated with combination radiotherapy and surgery *vs.* surgery alone in patients that had tumors 10.1 cm from the anal verge [3]. Thus, the benefit of radiotherapy appears to be for more distal tumors (0-10 cm from the anal verge). For the purpose of selecting patient to receive pre-operative CRT, practice guide lines in the United States by the National Cancer Institute (NCI) [4] and the National Comprehensive Cancer Network (NCCN) [5] have defined the rectum to be 12 cm from the anal verge.

3. Indications for neoadjuvant chemoradiation

The addition of preoperative radiation therapy to TME decreases locoregional recurrence from approximately 8% to 2%. The combination of chemotherapy and radiation (CRT) further decreases local recurrence. Chemotherapy also increases the number of patients which achieve a pathologic complete response (pCR), i.e. no detectable tumor after resection. This modality also reduces tumor burden in some patients and might allow a sphincter preserving operation (i.e. LAR) as opposed to an APR, allowing a patient to avoid a permanent colostomy. The rate of pCR is approximately 25% [6;7]. Patients who achieve pCR have better long-term outcomes compared to patients who only have a partial response or no response at all [8]. Current guide lines in the United States [4;5] dictate that patients with stage II (T3-T4) or stage III (any T with positive regional lymph nodes) should be treated with neoadjuvant CRT. Patients with stage I (T1-T2) disease or those with distant metastases (stage IV) generally do not receive neoadjuvant CRT. However, in instances of synchronous liver metastases for which liver resection is planned, neoadjuvant radiation may be considered. These recommendations emanate from the low rate of recurrence (4%) in patients with stage I tumors treated with surgery alone [9]. Further, there is no difference in the rate of locoregional recurrence in patients with stage IV tumors treated with radiotherapy and surgery compared to palliative surgery alone [3]. Similarly, there is no difference in outcomes in patients with distant metastases treated with neoadjuvant radiotherapy and surgery *vs.* palliative surgery alone [3]. Thus, the standard care of practice is to provide neoadjuvant CRT in patients with stage II and III rectal tumors.

4. Clinical staging of rectal cancer

Staging of rectal cancer begins with a thorough history and physical examination. The most common symptom of rectal cancer is bright red blood per rectum. Physical examination of the abdomen is important to identify any evidence of liver disease (ascites) or masses. A lymph node examination is important in any patient suspected of having cancer. Rectal examination will reveal distal tumors and is mandatory in the evaluation of patients with colorectal cancers. In such cases information regarding the size, degree of fixation, distance from the anal sphincters is important. In women, a rectovaginal examination may reveal extent of disease. A full colonoscopy is indicated to identify synchronous lesions (present in approximately 5% of cases). Rigid proctoscopy will define the distance of the lesion from the anus and can be critical in cases where the distance from the anus is not clear.

Because only stage II and III tumors are treated with pre-operative CRT, clinical staging is pivotal in guiding treatment options. There are currently two modalities to assess tumor stage (T stage) in the pre-operative setting: (1) endorectal ultrasound (EUS) and (2) Magnetic Resonance Imaging (MRI). The efficacy of these modalities has been assessed by two meta-analyses [10;11]. One study favors EUS [10] and the other MRI [11]. In the first analysis, 90 studies were included and assessed the accuracy of EUS, MRI, and CT in pre-operatively staging rectal cancer. The results demonstrated that EUS and MRI were similar in terms of sensitivity (Sn) with regards to tumor depth into the muscularis propria (94%). EUS was superior in determining muscularis propria invasion [specificity (Sp) of 86%] compared to MRI (Sp = 69%) and was an overall sensitive strategy (Sn = 90%) for perirectal tumor invasion compared to MRI (Sn = 82%) [10]. A second meta-analysis interrogated 84 studies. This study showed no difference in these modalities in evaluating the nodes (N-staging) [11]. In seven studies, MRI was a superior strategy in evaluating involved circumferential margins [11]. MRI seems to be emerging as a preferred modality for the assessment of rectal cancer staging in the pre-operative setting. However, the use of either of these modalities is largely based on institutional experience. The sensitivity of EUS following CRT is less compared to virgin tissue. Thus, MRI may be a preferred modality to determine response to neoadjuvant CRT.

5. Neoadjuvant chemoradiotherapy

The management of stage II and stage III rectal cancer is a tri-modality approach (Radiotherapy, Chemotherapy and Surgery) and patients are best managed following discussion at a multidisciplinary conference.

5.1. Radiotherapy

Initial studies evaluated the efficacy of radiotherapy without pre-operative chemotherapy. The data has been summarized in two meta-analyses addressing the benefit of preoperative radiation [12;13]. While the data on overall survival was not clear in these analyses, there was a clear decrease in the rate of local recurrence (46% in patients receiving preoperative radiation vs. 53% in the control group). These data established the benefits of preoperative radiotherapy followed by surgery.

5.1.1. Short course vs. long course radiotherapy

In Europe, small fractions of ionizing radiation 5.0 Grey (Gy) X 5.0 (over five days), for a total of 25.0 Gy without chemotherapy, are employed. With this strategy, the Swedish Rectal Cancer Trial found an improved rate of survival at five years with preoperative radiation [14]. In the United States, the typical IR dose is 45.0 to 50.4 Gy given in small doses (1.8 Gy/day) for five to six weeks [5]. In contrast to short course radiotherapy, in the United States, long course radiotherapy is given in combination with neoadjuvant chemotherapy. The interval between completion of radiation and subsequent operation is an area of some debate (see below) but is typically 5-10 weeks.

5.2. Neoadjuvant chemotherapy

Preoperative chemotherapy is generally used as a radiosensitizer. The EORTC group demonstrated that the addition of chemotherapy (5-FU) to the use of preoperative radiation reduced the risk of local recurrence by approximately 50%, from 17.1% to 8.7%. There was not a significant difference in overall survival in this study. Other trials have shown similar improvements in local control. Based on this data, the most established agent used in the preoperative setting in combination with radiation has been 5-fluorouracil (5-FU). The oral form of 5-FU (Capecitabine) is also being widely used in place of 5-FU with similar results [15]. Several chemotherapeutic agents used for the management of colon cancer in the adjuvant setting and for patients with metastases have been evaluated as possible radiosensitizers. These agents include: irinotecan [16], oxaliplatin [17], bevacizumab [18] and cetuximab [18]. With such strategies, there is still a wide response to ionizing radiation and these agents are not in widespread use at this time.

5.3. Pathologic complete response

A pathologic complete response (pCR) occurs in patients who undergo resection of the rectum and no residual tumor is identified. Patients who have a pCR demonstrate superior survival than those without. The EORTC 22921 showed an increased rate of pCR in patients who underwent chemoradiotherapy (13.7%) compared to patients who received radiation therapy alone (5.3%). A European trial inclusive of 762 patients receiving preoperative chemoradiation compared to radiation alone, the pCR rate was 11.4% *vs.* 3.6%, respectively [19]. A recent randomized phase II trial assessing combined chemoradiation for rectal cancer showed 28% of patients achieved a pCR. Further, 78% of patients exhibited tumor down staging [20]. Thus, chemotherapy has an additive effect to radiotherapy and has become the standard of care for patient with stage II/III tumors within 12 cm of the anal verge [5].

In the United States current guidelines recommend pre-operative radiation [50.4 Gy] in 25-28 fractions combination with 5-FU infusional or bolus with leucovorin [425 mg/m²/d] or capecitabine [825 mg/m²]. Neoadjuvant treatment is followed by surgery five to ten weeks later. While some investigators have shown that longer periods between neoadjuvant CRT and surgery might be associated with an increase rate of pCR [21], this approach is still under investigation [22].

6. Surgery

For stage II and III patients treated with CRT, surgical intervention must be planned within five to ten weeks after the last dose of chemoradiation. Although a longer window between neoadjuvant chemoradiation and operative intervention has been associated with higher rates of pCR, this must be assessed in case-to-case basis [21;22].

Transabdominal operations (LAR or APR) are the operations of choice for stage II and stage III rectal cancers. For small tumors with a good histology and for a patient with a prohibitive risk of surgical intervention, a transanal approach might be an alternative approach.

6.1. Transabdominal operations

Two operations are typically performed for rectal cancer. The abdominoperineal resection involves the removal of the distal rectum and perineum with clear tumor radial margins laterally to the pelvic sidewalls. Thus, part of this operation is the creation of a permanent colostomy. A low anterior resection involves the removal of the tumor and the creation of an anastomosis. This might require a temporary loop ileostomy especially in patients that have received neoadjuvant chemoradiation.

6.1.1. Abdominoperineal Resection (APR)

An abdominoperineal resection (Figure 1) necessitates a permanent colostomy, which frequently carries negative perception as a drastic change in quality of life for patients. Although a permanent stoma does necessitate some changes for patients, data is emerging that quality of life following an APR is not significantly less than that following an LAR [23]. This is related to the relatively high rate of complications following LAR, including sexual dysfunction, pain and fecal incontinence. However, an APR is associated with a high rate of perineal wound infections [24]. Furthermore, obtaining clear radial margins is more difficult with an APR compared to an LAR [23;25]. As a result, there is an oncologic advantage in performing an LAR compared to an APR [25]. Thus, in patients with preserved rectal tone, the operation of choice, is an LAR provided tumor associated factors make this possible.

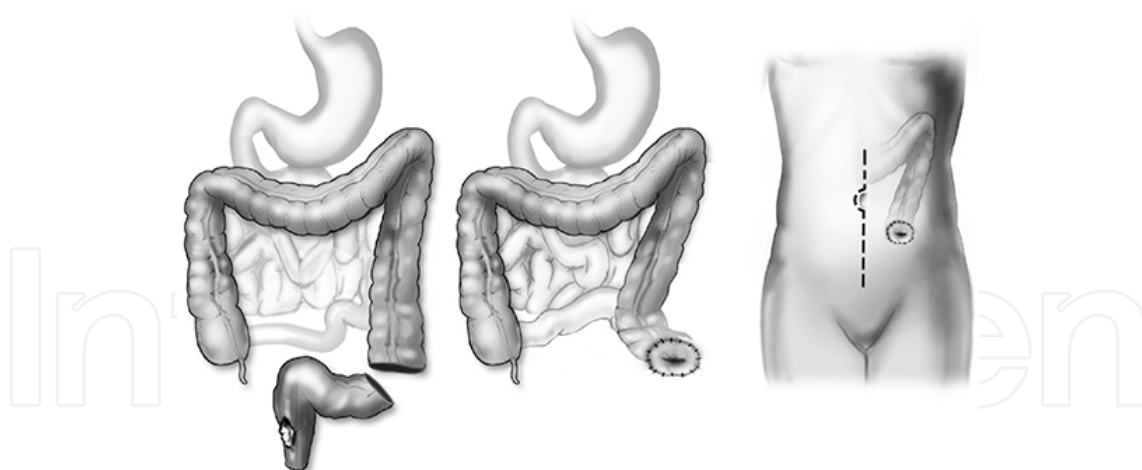


Figure 1. Abdominoperineal Resection (APR). The rectal tumor is removed, a permanent colostomy is created and the anus is obliterated.

6.1.2. Low Anterior Resection (LAR): Total Mesorectal Excision (TME)

An LAR (Figure 2) involves the creation of a primary anastomosis. The area confined within the investing fascia of the rectum and the presacral fascia involves the vascular and lymphatic

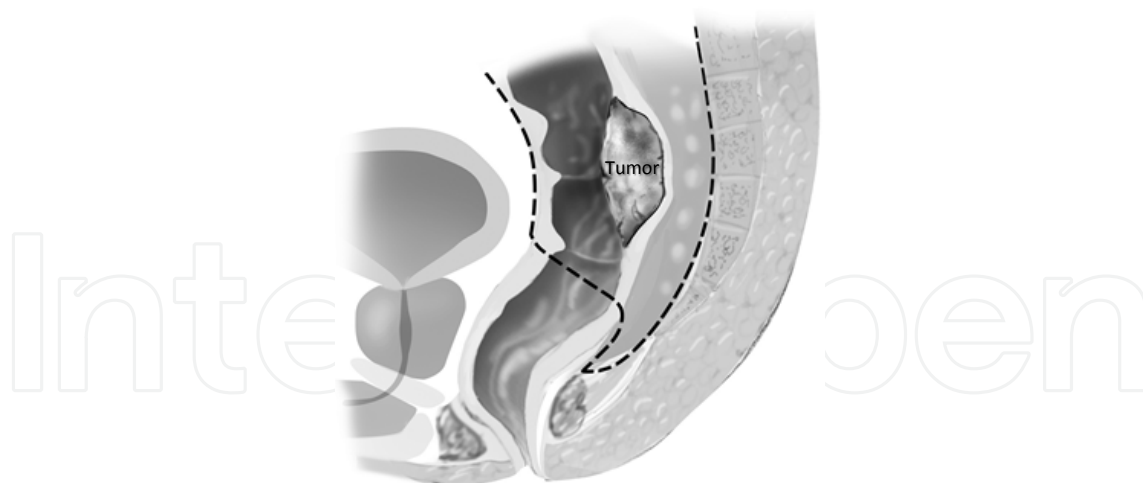


Figure 3. Total Mesorectal Excision (TME). The dotted line represents the line of resection. The tumor is resected and a primary anastomosis is performed

structures of the mid-rectum. An en bloc resection of the rectum that circumscribes these structures is termed a TME (Figure 3). Superiorly, the mesorectum is defined at the level of the sacral promontory or the division of the right and left superior hemorrhoidal arteries. The mesorectum extends distally and reduces posteriorly at the level of the investing fascia of the levators (Waldeyer's Fascia). Prior to the introduction of TME the rate of recurrence for rectal cancer was 25.0%. This rate has been reduced to 5.0% following the introduction of the TME [26].

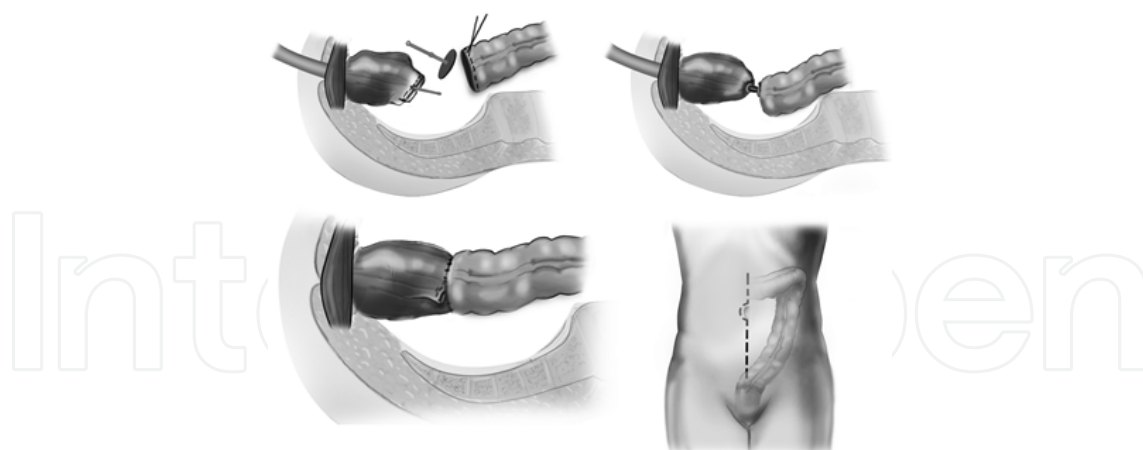


Figure 2. Low Anterior Resection (LAR). The rectum involving the tumor is resected and a primary anastomosis is created with a circular stapling device.

6.1.3. Proximal margin of resection and level of arterial ligation

No studies have interrogated the length required for proximal resection. Because of the continuity with the colon this is not such a concern. NCI guidelines recommend a 5-cm segment

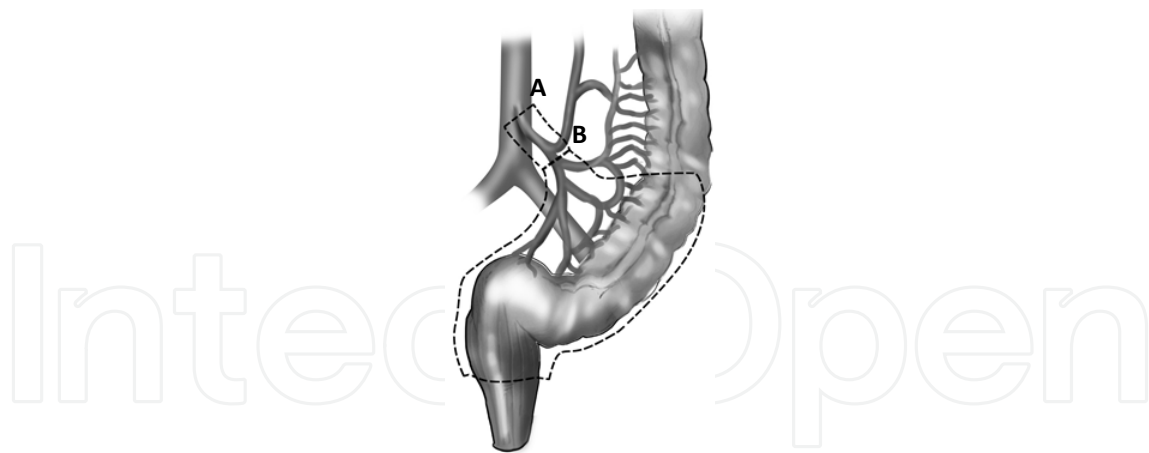


Figure 4. High ligation occurs at the root of the IMA (A). Low ligation occurs at the level of the superior rectal artery (B).

of resection proximal to the tumor [4]. While the inferior mesenteric artery (high ligation) was typically the level of arterial ligation recommended, this practice was associated with a decrease in innervation and perfusion to the anastomosis. The evidence demonstrating that this has a superior oncologic compared to ligation at the level of the superior rectal artery (low ligation) is lacking. Thus, low ligation has become the preferred strategy [27] (Figure 4).

6.2. Laparoscopic surgery for the management of adenocarcinoma of the rectum

Minimally invasive surgery has made laparoscopic resection of rectal cancer possible. However, at this juncture, this procedure remains investigational for the management of rectal cancer [5]. It is currently recommended to include patients in study protocol to continue to address the benefits of the laparoscopic approach in rectal cancer including: oncologic efficacy, complication rates, conversion rates, patient benefit, and cost-effectiveness.

Short term outcomes have not been different in patients treated with the laparoscopic approach compared to the open techniques [28]. Multiple case series reporting laparoscopic TME have documented technical feasibility with satisfactory short term outcomes [29]. While case reports have also reported the ability of a robotic proctectomy [30], these studies need to be replicated in large series compared to the “gold-standard” to determine the general applicability of innovative approaches.

In contrast to colon cancer, where laparoscopy has been compared to the open approach [31-33], for rectal cancer these studies are currently needed. The Conventional Versus Laparoscopic-Assisted Surgery in Colorectal Cancer (CLASICC) trial specifically addressed rectal cancer [32]. In this study, the rate of complications was similar. However, the rate of positive CRM was twice in the laparoscopic approach compared to the open technique (12% *vs.* 6%; $p=0.19$). While this was only a trend and not correlated with an increase in the rate of recurrence, these findings need to be further investigated. Additionally, there was also a trend towards an increase in complications related to male sexual dysfunction (41% *vs.* 23%).

A randomized controlled trial [34] and institutional case series [35;36] indicate that the laparoscopic and the open TME have similar oncologic outcomes. More data on the long term outcomes of the laparoscopic approach will be shed with further analysis of the Colon Cancer Laparoscopic or Open Resection (COLOR) II [37] and the and the American College of Surgeons Oncology Group trial Z6051 is completed.

Thus, the current data suggest that the short-term outcomes of laparoscopic and open surgery are similar. It is crucial to analyze the current data of the available studies carefully as patient selection and the experience of the institution/surgeon are paramount in the current available literature. Long term data regarding oncologic outcome and functional status remain at large, as do data demonstrating patient benefit and cost effectiveness [38].

6.3. Transanal excision

An alternative treatment for early stage rectal cancers is a transanal excision. Candidates for this approach have small (≤ 3 -cm) stage I (T1) tumors located within 8-cm from the anal verge that occupy less than 30% of the circumference of the bowel with good histological features is a transanal removal of the tumor with clear margins. There is a substantial risk for local recurrence with this approach. Local rates of recurrence with the transanal approach *vs.* similarly staged tumors treated with a transabdominal approach is 13.2% *vs.* 2.7%; respectively [39]. Twenty percent of patients with T1 tumors who undergo radical resection are discovered to have lymph node metastases [39]. Patients with rectal cancer treated exclusively by local resection show a rate of local recurrence of 9.7% for T1, 25% for T2, and 38% for T3 cancers [40]. In patients that received systemic chemotherapy after the transanal excision, the local recurrence rate was substantially decreased to: 9.5% for T1, 13.6% for T2, and 13.8% for T3 cancers [40]. This approach is, perhaps, of most benefit in patients with a high operative risk.

7. Adjuvant chemotherapy

Patients with stage II/III rectal cancer should be treated with adjuvant chemotherapy as soon as they are able. Current regimens for this approach extrapolate the experience with colon cancer such that FOLFOX (5-FU/leucovorin, and oxaliplatin) for six months is recommended. 5-FU with or without leucovorin as well as capecitabine with or without oxaliplatin are also alternative options for treatment in the adjuvant setting [5].

8. Pathological analysis of rectal cancer

8.1. Staging

In rectal cancer staging, the prefix “p” refers to pathological staging and “yp” indicates pathological staging after neoadjuvant chemoradiation.

The number of recommended nodes to be retrieved to accurately stage tumors is 12 according to the NCCN guidelines [5]. In patients treated with neoadjuvant therapy, the number of nodes resected during surgery is 3-6 less compared to patients treated with surgery alone [41-43]. Thus, care must be taken by the surgeon to remove all involved nodes and by pathology for a careful analysis of the specimen.

8.2. Pathological Inspection of the tumor

8.2.1. Circumferential Resection Margin (CRM)

The circumferential margin (CRM) is important during pathological assessment of tumors in rectal cancer [44]. The CRM refers to assessment of the non-peritonealized area (bare area) of the rectum created by subperitoneal dissection during surgery. Tumors within 1 mm of the resection margin are defined as having a positive CRM. Additionally discontinuous spread or lymph node involvement within 1mm of the CRM is defined as positive. CRM is a predictor of local recurrence in patients receiving surgery as the only modality of treatment of rectal cancer [25;45]. Patients whose CRM is less than 2 mm have a recurrence rate of 16% compared to 5.8% for patients having a CRM over 2mm. The rate of metastases is also higher in patients with less than 2mm margins vs. greater than 2mm (37.6 vs. 12.7%; respectively) [26]. This observation underscores the importance of radial margins in rectal surgery. Other studies have shown that the CRM is an important predictor of local recurrence, distant metastasis, and overall survival in patients receiving induction CRT compared to patients treated with surgery alone [25]. Thus, pathological evaluation of the resected rectal tumor must include the distance to the tumor to the closest CRM.

8.2.2. Determining response to induction chemotherapy

Pathological tumor response following neoadjuvant therapy is graded from 0 to 3. A grade of 0 indicates complete response without any viable cells; while 3 denotes minimal or no response to treatment. It is important for the pathologist and the surgeon to note the response of CRT after surgery to determine if the current regimens are adequate for the patient population and also to determine the possible aggressiveness of the tumor and plan for adjuvant therapies.

9. Clinical Complete Response (cCR)

Studies continue to accumulate that document the possibility of observing patients who achieve a clinical complete response following neoadjuvant chemoradiation [46;47]. The first study was reported by Habr-Gama's group in 2004 [46]. In this study, 8% of patients considered to have recurrence had a complete pathological response following surgery. Patients with rectal tumors within 0-7 cm from the anal verge received pre-operative radiotherapy (50.4 Gy) and chemotherapy [5-FU (425 mg/m²/d) + folinic acid (20 mg/m²/d)]. Re-staging was performed 8 weeks after treatment and included proctoscopy with rectal biopsies. Complete clinical response was defined by the absence of any abnormalities during proctoscopy. A rectal

scar or a positive biopsy was defined as an incomplete response. These patients did not receive postoperative chemotherapy unless they had recurrent disease. These findings were then reproduced by Maas et al [47].

Maas et al compared patients that achieved a cCR to patients who had a pathological complete response after surgery. Twenty-one subjects were included in the study arm and 20 in the control group. The major differences in these studies include the follow up in Maas vs. Habr-Gama's studies (24.8 *vs.* 57.3 months; respectively). While radiotherapy was similar, Maas used capecitabine rather than 5-FU. Additionally, the definition of cCR was different in these two studies. Habr-Gama used proctoscopy and rectal biopsies while Maas relied on magnetic resonance imaging (MRI), endorectal ultrasound, and biopsies. Finally, all pre-operatively staged III patients received adjuvant chemotherapy consisting of oxaliplatin and capecitabine in Maas study and none in Habr-Gama's.

While there are some differences between the studies by Habr-Gama and Maas, they provide an excellent platform to build on further prospective cohort studies. Further, two other smaller studies have replicated these observations [48;49].

10. Complications

Complications from rectal surgery are typically associated with bladder and sexual dysfunction. A TME has been associated with bladder dysfunction (17.8%), loss of erection (27.7%), and lack of ejaculation (33.9%) [50]. Up to 30% of patients with attempted curative surgical intervention will eventually develop regional (pelvic) recurrence [9]. Treatment failure is largely dependent on the cohort of patients studied and combined to patients who develop metastasis, the rate is substantially high.

11. Conclusions

The management of rectal cancer is in dynamic evolution. Drastic improvements have occurred over the past 20 years. However, the 5-year survival for these patients remains unacceptably high. The tri-modality approach has demonstrated clear advantages. In a small segment of patients (~25%) the tri-modality approach might be reduced to a bimodality treatment avoiding surgery in patients that achieve a clinical complete response. However, this strategy should be undertaken only in the setting of an Institutional Board Review protocol. Efforts to improve local control and survival in rectal cancer are continuing in multiple clinical and preclinical studies. An understanding of specific molecular pathways leading to a response in neoadjuvant modalities will refine the segment of patients who might need an operation sooner compared to patients who might be observed. Ongoing trials on the laparoscopic approach for rectal cancer will shed light into the benefits of this practice.

Author details

Sergio Huerta and Sean P. Dineen

University of Texas Southwestern Medical Center and North Texas VA Health Care System,
USA

References

- [1] Siegel, R, Naishadham, D, & Jemal, A. Cancer statistics, (2012). *CA Cancer J Clin* 2012; , 62(1), 10-29.
- [2] Wong, R. K, & Tandan, V. De SS, Figueredo A. Pre-operative radiotherapy and curative surgery for the management of localized rectal carcinoma. *Cochrane Database Syst Rev* (2007). CD002102.
- [3] Kapiteijn, E, Marijnen, C. A, Nagtegaal, I. D, Putter, H, Steup, W. H, Wiggers, T, et al. Preoperative radiotherapy combined with total mesorectal excision for resectable rectal cancer. *N Engl J Med* (2001). , 345(9), 638-646.
- [4] Nelson, H, Petrelli, N, Carlin, A, Couture, J, Fleshman, J, Guillem, J, et al. Guidelines 2000 for colon and rectal cancer surgery. *J Natl Cancer Inst* (2001). , 93(8), 583-596.
- [5] Engstrom, P. F, Arnoletti, J. P, & Benson, A. B. III, Chen YJ, Choti MA, Cooper HS et al. NCCN Clinical Practice Guidelines in Oncology: rectal cancer. *J Natl Compr Canc Netw* (2009). , 7(8), 838-881.
- [6] Huerta, S. Rectal cancer and importance of chemoradiation in the treatment. *Adv Exp Med Biol* (2010). , 685, 124-133.
- [7] Huerta, S, Hrom, J, Gao, X, Saha, D, Anthony, T, Reinhart, H, et al. Tissue microarray constructs to predict a response to chemoradiation in rectal cancer. *Dig Liver Dis* (2010). , 42(10), 679-684.
- [8] Maas, M, Nelemans, P. J, Valentini, V, Das, P, Rodel, C, Kuo, L. J, et al. Long-term outcome in patients with a pathological complete response after chemoradiation for rectal cancer: a pooled analysis of individual patient data. *Lancet Oncol* (2010). , 11(9), 835-844.
- [9] Rodel, C, & Sauer, R. Radiotherapy and concurrent radiochemotherapy for rectal cancer. *Surg Oncol* (2004).
- [10] Bipat, S, Glas, A. S, Slors, F. J, Zwinderman, A. H, Bossuyt, P. M, & Stoker, J. Rectal cancer: local staging and assessment of lymph node involvement with endoluminal US, CT, and MR imaging--a meta-analysis. *Radiology* (2004). , 232(3), 773-783.
- [11] Lahaye, M. J, Engelen, S. M, Nelemans, P. J, & Beets, G. L. van de Velde CJ, van Engelsehoven JM et al. Imaging for predicting the risk factors--the circumferential resec-

tion margin and nodal disease--of local recurrence in rectal cancer: a meta-analysis. *Semin Ultrasound CT MR* (2005). , 26(4), 259-268.

- [12] Adjuvant radiotherapy for rectal cancer: a systematic overview of 8 patients from 22 randomised trials. *Lancet* (2001). , 358(9290), 1291-1304.
- [13] Camma, C, Giunta, M, Fiorica, F, Pagliaro, L, Craxi, A, & Cottone, M. Preoperative radiotherapy for resectable rectal cancer: A meta-analysis. *JAMA* (2000). , 284(8), 1008-1015.
- [14] Improved survival with preoperative radiotherapy in resectable rectal cancer Swedish Rectal Cancer Trial. *N Engl J Med* (1997). , 336(14), 980-987.
- [15] Patel, P. A. Evolution of 5-fluorouracil-based chemoradiation in the management of rectal cancer. *Anticancer Drugs* (2011). , 22(4), 311-316.
- [16] Illum, H. Irinotecan and radiosensitization in rectal cancer. *Anticancer Drugs* (2011). , 22(4), 324-329.
- [17] Huerta, S, & Hrom, J. Oxaliplatin as a radiosensitizing agent in rectal cancer. *Anticancer Drugs* (2011). , 22(4), 317-323.
- [18] Glynne-jones, R, Mawdsley, S, & Harrison, M. Antiepidermal growth factor receptor radiosensitizers in rectal cancer. *Anticancer Drugs* (2011). , 22(4), 330-340.
- [19] Bosset, J. F, Collette, L, Calais, G, Mineur, L, Maingon, P, Radosevic-jelic, L, et al. Chemotherapy with preoperative radiotherapy in rectal cancer. *N Engl J Med* (2006). , 355(11), 1114-1123.
- [20] Mohiuddin, M, Winter, K, Mitchell, E, Hanna, N, Yuen, A, Nichols, C, et al. Randomized phase II study of neoadjuvant combined-modality chemoradiation for distal rectal cancer: Radiation Therapy Oncology Group Trial 0012. *J Clin Oncol* (2006). , 24(4), 650-655.
- [21] De Campos-lobato, L. F, & Geisler, D. P. da Luz MA, Stocchi L, Dietz D, Kalady MF. Neoadjuvant therapy for rectal cancer: the impact of longer interval between chemoradiation and surgery. *J Gastrointest Surg* (2011). , 15(3), 444-450.
- [22] Huerta, S. Interval between neoadjuvant chemoradiation and surgery for the management of rectal cancer. *J Gastrointest Surg* (2011).
- [23] How, P, Stelzner, S, Branagan, G, Bundy, K, Chandrakumaran, K, Heald, R. J, et al. Comparative quality of life in patients following abdominoperineal excision and low anterior resection for low rectal cancer. *Dis Colon Rectum* (2012). , 55(4), 400-406.
- [24] MacFarlane JK Ryall RD, Heald RJ. Mesorectal excision for rectal cancer. *Lancet* (1993). , 341(8843), 457-460.
- [25] Nagtegaal, I. D, & Quirke, P. What is the role for the circumferential margin in the modern treatment of rectal cancer? *J Clin Oncol* (2008). , 26(2), 303-312.

- [26] Machiels, J. P, Sempoux, C, Scalliet, P, Coche, J. C, Humblet, Y, et al. Phase I/II study of preoperative cetuximab, capecitabine, and external beam radiotherapy in patients with rectal cancer. *Ann Oncol* (2007). , 18(4), 738-744.
- [27] Lange, M. M, & Buunen, M. van de Velde CJ, Lange JF. Level of arterial ligation in rectal cancer surgery: low tie preferred over high tie. A review. *Dis Colon Rectum* (2008). , 51(7), 1139-1145.
- [28] Tjandra, J. J, Chan, M. K, & Yeh, C. H. Laparoscopic- vs. hand-assisted ultralow anterior resection: a prospective study. *Dis Colon Rectum* (2008). , 51(1), 26-31.
- [29] Ng, K. H, Ng, D. C, Cheung, H. Y, Wong, J. C, Yau, K. K, Chung, C. C, et al. Laparoscopic resection for rectal cancers: lessons learned from 579 cases. *Ann Surg* (2009). , 249(1), 82-86.
- [30] Luca, F, Cenciarelli, S, Valvo, M, Pozzi, S, Faso, F. L, Ravizza, D, et al. Full robotic left colon and rectal cancer resection: technique and early outcome. *Ann Surg Oncol* (2009). , 16(5), 1274-1278.
- [31] A comparison of laparoscopically assisted and open colectomy for colon cancer. *N Engl J Med* 2004; 350(20):2050-2059.
- [32] Guillo, P. J, Quirke, P, Thorpe, H, Walker, J, Jayne, D. G, Smith, A. M, et al. Short-term endpoints of conventional versus laparoscopic-assisted surgery in patients with colorectal cancer (MRC CLASICC trial): multicentre, randomised controlled trial. *Lancet* (2005). , 365(9472), 1718-1726.
- [33] Veldkamp, R, Kuhry, E, Hop, W. C, Jeekel, J, Kazemier, G, Bonjer, H. J, et al. Laparoscopic surgery versus open surgery for colon cancer: short-term outcomes of a randomised trial. *Lancet Oncol* (2005). , 6(7), 477-484.
- [34] Lujan, J, Valero, G, Hernandez, Q, Sanchez, A, Frutos, M. D, & Parrilla, P. Randomized clinical trial comparing laparoscopic and open surgery in patients with rectal cancer. *Br J Surg* (2009). , 96(9), 982-989.
- [35] Laurent, C, Leblanc, F, Wutrich, P, Scheffler, M, & Rullier, E. Laparoscopic versus open surgery for rectal cancer: long-term oncologic results. *Ann Surg* (2009). , 250(1), 54-61.
- [36] Milsom, J. W. de OO, Jr., Trencheva KI, Pandey S, Lee SW, Sonoda T. Long-term outcomes of patients undergoing curative laparoscopic surgery for mid and low rectal cancer. *Dis Colon Rectum* (2009). , 52(7), 1215-1222.
- [37] Buunen, M, Bonjer, H. J, Hop, W. C, Haglind, E, Kurlberg, G, Rosenberg, J, et al. COLOR II. A randomized clinical trial comparing laparoscopic and open surgery for rectal cancer. *Dan Med Bull* (2009). , 56(2), 89-91.
- [38] Wagman, L. D. Laparoscopic and open surgery for colorectal cancer: reaching equipoise? *J Clin Oncol* (2007). , 25(21), 2996-2998.

- [39] Nash, G. M, Weiser, M. R, Guillem, J. G, Temple, L. K, Shia, J, Gonen, M, et al. Long-term survival after transanal excision of T1 rectal cancer. *Dis Colon Rectum* (2009). , 52(4), 577-582.
- [40] Sengupta, S, & Tjandra, J. J. Local excision of rectal cancer: what is the evidence? *Dis Colon Rectum* (2001). , 44(9), 1345-1361.
- [41] Baxter, N. N, Morris, A. M, Rothenberger, D. A, & Tepper, J. E. Impact of preoperative radiation for rectal cancer on subsequent lymph node evaluation: a population-based analysis. *Int J Radiat Oncol Biol Phys* (2005). , 61(2), 426-431.
- [42] Tepper, J. E, Connell, O, Niedzwiecki, M. J, Hollis, D, Compton, D, Benson, C, & Iii, A. B. et al. Impact of number of nodes retrieved on outcome in patients with rectal cancer. *J Clin Oncol* (2001). , 19(1), 157-163.
- [43] Wichmann, M. W, Muller, C, Meyer, G, Strauss, T, Hornung, H. M, Lau-werner, U, et al. Effect of preoperative radiochemotherapy on lymph node retrieval after resection of rectal cancer. *Arch Surg* (2002). , 137(2), 206-210.
- [44] Compton, C. C. Key issues in reporting common cancer specimens: problems in pathologic staging of colon cancer. *Arch Pathol Lab Med* (2006). , 130(3), 318-324.
- [45] Nagtegaal, I. D, Marijnen, C. A, Kranenbarg, E. K, Van D, V, & Van Krieken, J. H. Circumferential margin involvement is still an important predictor of local recurrence in rectal carcinoma: not one millimeter but two millimeters is the limit. *Am J Surg Pathol* (2002). , 26(3), 350-357.
- [46] Habr-gama, A, Perez, R. O, Nadalin, W, Sabbaga, J, & Ribeiro, U. Jr., Silva e Sousa AH Jr et al. Operative versus nonoperative treatment for stage 0 distal rectal cancer following chemoradiation therapy: long-term results. *Ann Surg* (2004). , 240(4), 711-717.
- [47] Maas, M, Beets-tan, R. G, Lambregts, D. M, Lammering, G, Nelemans, P. J, Engelen, S. M, et al. Wait-and-see policy for clinical complete responders after chemoradiation for rectal cancer. *J Clin Oncol* (2011). , 29(35), 4633-4640.
- [48] Dalton, R. S, Velineni, R, Osborne, M. E, Thomas, R, Harries, S, Gee, A. S, et al. A single-centre experience of chemoradiotherapy for rectal cancer: is there potential for nonoperative management? *Colorectal Dis* (2012). , 14(5), 567-571.
- [49] Smith, J. D, Ruby, J. A, Goodman, K. A, Saltz, L. B, Guillem, J. G, Weiser, M. R, et al. Nonoperative management of rectal cancer with complete clinical response after neoadjuvant therapy. *Ann Surg* (2012). , 256(6), 965-972.
- [50] Morino, M, Parini, U, Allaix, M. E, Monasterolo, G, Brachet, C. R, & Garrone, C. Male sexual and urinary function after laparoscopic total mesorectal excision. *Surg Endosc* (2009). , 23(6), 1233-1240.