

# We are IntechOpen, the world's leading publisher of Open Access books Built by scientists, for scientists

6,900

Open access books available

185,000

International authors and editors

200M

Downloads

Our authors are among the

154

Countries delivered to

TOP 1%

most cited scientists

12.2%

Contributors from top 500 universities



WEB OF SCIENCE™

Selection of our books indexed in the Book Citation Index  
in Web of Science™ Core Collection (BKCI)

Interested in publishing with us?  
Contact [book.department@intechopen.com](mailto:book.department@intechopen.com)

Numbers displayed above are based on latest data collected.  
For more information visit [www.intechopen.com](http://www.intechopen.com)



---

# **A Review of Radiation Therapy's Role in Early-Stage Breast Cancer and an Introduction to Electronic Brachytherapy**

---

Brent Herron, Alex Herron, Kathryn Howell,  
Daniel Chin and Luann Roads

Additional information is available at the end of the chapter

<http://dx.doi.org/10.5772/55621>

---

## **1. Introduction**

With the exception of skin cancer, breast cancer is the most commonly diagnosed cancer in women in the United States and the most developed European countries [1]. Although breast cancer has been known to be a major cause of mortality in women living in affluent countries, this disease does not discriminate crossing racial, gender, geographic, and economic lines. Encouraging reports indicate there may be a trend toward decreasing breast cancer incidence in countries where there is a decline in hormone replacement therapy [31,6]. Furthermore, it has been reported that breast cancer mortality has fallen in industrialized countries in the last decade [7,36,6]. Reasons for declining mortality may include early detection and better treatment.

Treatment of breast cancer requires a multidisciplinary approach. The surgeon, medical oncologist, radiation oncologist, and pathologist play a role in developing treatment options for the patient. Radiation therapy has a significant part in the treatment of breast cancer, both for noninvasive and invasive cancers.

Breast conserving surgery includes partial mastectomy, lumpectomy, tylectomy, wide local excision, and quadrantectomy. These techniques followed by 5-7 weeks of radiation therapy have been known for over two decades as breast conservation therapy. Initially accepted as a form of breast cancer treatment in Europe, breast conservation therapy is now accepted throughout the world and has gained popularity in the United States since the early 1980s.

With the advancements in computed tomography imaging, simulation, treatment planning and delivery systems, more accurate and homogenous radiation treatment can be delivered. Radiation therapy options following breast conserving surgery include whole breast radiation, accelerated partial breast radiation with external beam treatment or brachytherapy, and hypofractionated whole breast radiation treatment. This chapter includes a review of these techniques and also introduces a relatively new option: electronic brachytherapy as the role of radiation therapy in early breast cancer management has continued to evolve.

## 2. Support of breast conservation treatment

Multiple international trials have demonstrated the efficacy of breast-conserving surgery followed by radiation therapy [16,47,20,21]. Early detection promotions has resulted in patients presenting with even smaller and more favorable tumors than years ago [15]. The improvement of mammographic imaging and screening has led to the increase incidence of patients presenting with noninvasive breast cancer from 5% to 30% [44].

Randomized trials worldwide comparing mastectomy to breast conserving surgery followed by radiation therapy have clearly shown equivalent long-term survival in both groups [20,21, 47,37,38, 9]. The Milan trial was one of the first landmark trials on this subject. From 1973 to 1980, 701 women with Stage 1 breast cancer were randomized to radical mastectomy versus breast conserving surgery with adjuvant whole breast radiation therapy (50 Gy plus a 10 Gy boost). Patients with positive lymph node metastases also received adjuvant chemotherapy. There were no significant differences between the two groups in the development of contralateral breast cancers, distant metastases, or secondary primary cancers. At a median follow-up of 20 years, survival was shown to be equivalent between the two groups.

Other landmark European trials comparing mastectomy and breast conserving surgery included the Institut Gustave-Roussy and the European Organization for Research and Treatment of Cancer (EORTC). The Institut trial randomized women with 2cm or smaller tumors to mastectomy or local excision followed by radiation therapy. 15 year survival rates and local recurrences were statistically similar in this trial as well as the EORTC trial.

In the United States, the National Surgical Adjuvant Breast and Bowel Project (NSABP) initiated the B-04 study in 1971. A total of 2163 women with 4 cm or less breast cancers were randomized to one of three treatment arms: total mastectomy, lumpectomy alone, and lumpectomy plus radiation therapy. Twenty-year follow-up analysis showed no differences in overall survival in the three arms. However, patients who underwent lumpectomy alone had a 39.2% risk of local recurrence versus 14.3% risk of recurrence in the lumpectomy plus radiation arm. Radiation therapy also showed a marginally significant decrease in breast cancer related deaths when compared to the lumpectomy alone arm [20,21].

Fortunately, the outcome for patients treated with breast conserving surgery continues to improve. There have been tremendous advancements in the last decade in surgical techniques, systemic treatment, diagnostic imaging, and radiation therapy delivery

systems. Today, for patients with node negative disease, local recurrence for patients undergoing breast conserving surgery with radiation therapy and systemic chemotherapy has dropped to 0.5% annually [12, 13, 14].

### **3. Patient selection and factors affecting local recurrence**

The American College of Radiology Practice Guidelines and the National Comprehensive Network Practice Guidelines serve as tools for selecting patients as candidates for breast conserving therapy. Most women diagnosed with localized breast cancer are candidates. However, there are contraindications to breast conserving therapy including large tumor size to size of the breast, multicentric breast cancer, diffuse malignant appearing, pregnancy, prior radiation to the chest, persistent positive margins after several re-excisions, pacemaker in radiation portal, and morbid obesity exceeding the radiation therapy table limit. Having a collagen vascular disease, such as active lupus, is a relative contraindication to breast conserving treatment.

At least two-thirds of patients are eligible for breast conserving surgery at diagnosis [6]. Several factors influence local regional recurrence. Obtaining gross negative margins at the time of surgery is no longer considered acceptable. Margins should be microscopically negative and as wide as possible. Most surgeons consider a 2-3mm clear margin as acceptable. The median rates of ipsilateral breast recurrence has been shown to be 2%, 3%, and 6% when margins of clearance were determined clear, 1mm clear, and 2mm clear respectively [41].

The presence or absence of extensive intraductal component (EIC) has traditionally been felt to affect local recurrence. Holland et al. [26] showed that the presence of EIC is associated with breast recurrence. In a series of 214 patients who underwent a mastectomy, 71% of patients with EIC had residual intraductal tumor, whereas only 28% of patients without EIC had residual disease.

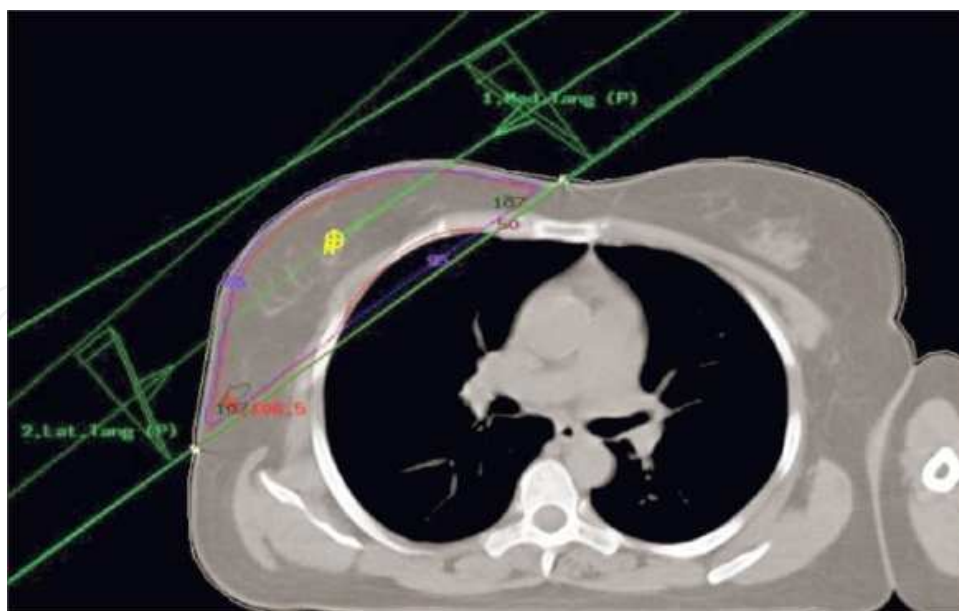
In certain studies, young age, usually 40, 35 or 30 years or less, has been associated with an increase of ipsilateral tumor recurrence following breast conserving surgery. [22,50,34]. However, many of these studies also show young age to correlate with other high risk features such as high grade and the presence of EIC. A boost dose delivered to the surgical cavity following whole breast radiation therapy is particularly significant for younger patients since higher doses tend to correlate with lower recurrences.

### **4. External beam radiation therapy**

External beam radiation therapy typically begins 3 to 6 weeks following surgery unless systemic chemotherapy is given. Treatment planning starts with the simulation process. Breast boards, wing boards, or customized cradles or molds are created or fitted to the individual patient. This allows the patient to be in a reproducible position with each treatment. Patients

are typically placed in the supine position with their torso angled 10-15 degrees. The ipsilateral arm is abducted usually between 100-120 degrees and the shoulder is externally rotated. At this time, radio opaque wires are placed and secured along the surgical scars. The radiation oncologist then defines the treatment field borders to encompass the breast target and regional lymph nodes, if needed. CT simulation is performed. The isocenter can be selected and the daily set-up marks are placed on the patient's skin. 3-dimensional treatment planning is performed. Treatment volumes and critical structures are identified and outlined. Optimal beam arrangements are chosen. The goal is to deliver the prescribed dose to the target with a homogenous distribution, minimizing hot and cold spots, to minimize doses delivered to critical structures, such as lungs and heart, and minimize the volumes of the critical structures within the treatment fields.

For early stage breast cancer, tangential fields that include the most anterior thorax are typically used (Fig 1). These fields can include level I and II lymph node chains. Attention to tangent field borders, especially the cranial and posterior chest wall interface, is important if most of levels I and II axillary nodes are to be included [40]. Radiation therapy to the supraclavicular fossa plus or minus a posterior axillary boost is sometimes offered to patients with undissected nodes, four or more lymph node metastases or to patients with one to three positive nodes. A typical supraclavicular field is a half beam block field matched to the tangents with the beam angled 10-15 degrees away from the cord. A table kick is utilized for the tangential fields to account for the divergence of the beam into the supraclavicular field. The posterior axillary beam supplements dose to the midaxillary plane. Pierce et al. discusses several techniques to treat the internal mammary nodes [36].



**Figure 1.** Depiction of tangential fields used for treatment in external beam radiation therapy.

Four to six MV photon energy is most commonly selected for treating the breast and lymph nodes. Whole breast radiation treatments are administered Monday through Friday, deliver-



ing approximately 50 Gy in 25 to 28 fractions. For the boost treatment, electrons typically are used. The lumpectomy cavity is boosted for another 10-16 Gy at 1.8 to 2 Gy per fraction.

New advances in radiation treatment planning and delivery have led to the development of intensity modulated radiation therapy (IMRT) or forward planning IMRT to treat the breast. The dose to the contralateral breast is reduced with IMRT [10]. By conforming doses along the breast and blocking normal structures with multi-leaf collimators, the normal structures like the lungs or heart for left sided breast cancer treatment also receive reduced doses. The dose to the breast could be more homogenous with concave isodose curves, conforming to the target. Studies have shown that forward planning IMRT when compared to standard radiotherapy, can produce homogenous plans with fewer hot spots [4,25]. This could particularly benefit large-breasted women or those with large breast separation. Whether this translates to better cosmetic outcomes is unknown until these trials mature.

In some elderly patients, particularly those over 70 years of age with early disease who receive adjuvant hormonal therapy, breast conserving surgery alone may be an option. There could be biological differences in the tumors in some elderly women. Additionally, some elderly patients tend to have more transportation, social, and other health-related issues that may affect their ability to receive daily radiation therapy. The Canadian trial [23] and the Cancer and Leukemia Group B (CALGB/Radiation Therapy Oncology Group (RTOG)/Eastern Cooperative Oncology Group (ECOG) trial [28,42,23] both randomized older women with estrogen-receptor-positive early breast cancer following breast-conserving surgery to tamoxifen with or without radiation therapy. Although both trials showed absolute benefits to women receiving radiation therapy, the benefits overall were small.

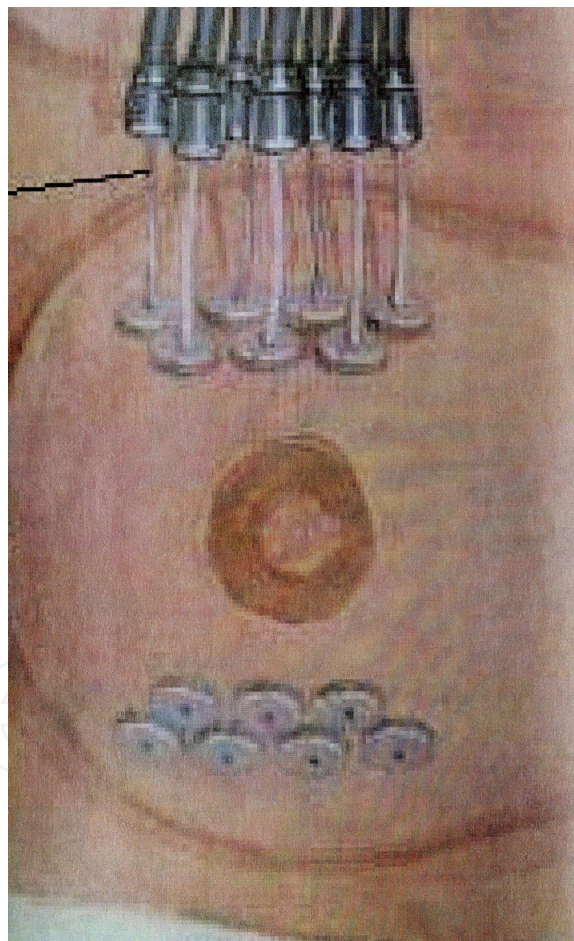## **5. Breast brachytherapy for partial breast irradiation**

The many trials supporting breast-conserving surgery followed by adjuvant radiation therapy have also shown that the risk of recurrence outside the tumor cavity is similar whether or not whole breast radiation was given [20,21,47,27]. This suggests that additional radiation given outside the tumor cavity may not be of additional benefit to patients.

Breast brachytherapy was historically used to treat the lumpectomy cavity as a "boost" following external whole breast radiation therapy. Many centers have now adapted the use of accelerated partial breast irradiation (APBI), either with interstitial needle implants, various applicators (i.e. Mammosite balloon, Contoura multilumen balloon, Savi), or even through the use of 3D conformal external radiation therapy as the sole radiation treatment modality following breast-conserving surgery. By irradiating less volume, higher radiation doses can be given per fraction to the tumor bed. This shortens treatment times significantly, decreasing the patient's travel time when compared to daily whole breast external beam radiation therapy.

Patients are potential candidates for APBI if they have Stage 0, 1, or II tumors, with a single tumor less than 3 cm in maximum dimension. Minimal nodal involvement and clear surgical margins are also required. Typically, partial breast radiation is delivered twice a day, with each treatment separated at least 6 hours apart, for a total of ten fractions.

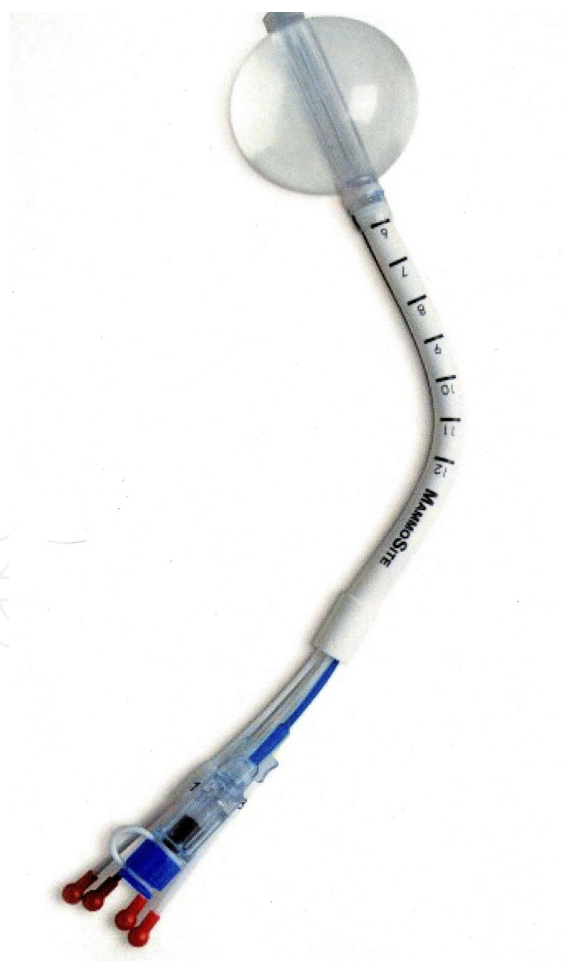
Interstitial breast brachytherapy alone has been successfully used for over 10 years following breast conserving surgery (Fig 2). A trial was started by Vinci et al. in 1993 using brachytherapy as the only radiation treatment modality for patients following breast-conserving surgery [48]. By 2001, 120 patients were enrolled in this trial. Four patients developed local recurrence at a median follow-up of 82 months. During 1997-2000, 100 patients were enrolled in a Radiation Therapy Oncology Group (RTOG), prospective Phase I/II study of breast brachytherapy. Patients were either high-dose or low-dose-rate brachytherapy. For the high-dose-rate group at a median follow-up of 6.14 years; 5-year estimates of ipsilateral breast, regional, and contralateral breast failures were 3%, 5%, and 2% respectively. For patients receiving low-dose-rate brachytherapy at a median follow-up of 6.22 years; 5-year estimates of ipsilateral breast, regional, and contra-lateral breast failures were 6%, 0%, and 6%, respectively. Both groups experienced good cosmesis and local control [3]. Several institutions have shown low recurrences with brachytherapy at 5 and 10 years [2,5]



**Figure 2.** Tube placement for interstitial brachytherapy.

In 2002, the FDA approved Proxima Therapeutics MammoSite® balloon catheter for intracavitary high dose rate breast brachytherapy (Fig 3). Seventy patients were initially enrolled in a prospective multi-center trial evaluating the safety of the MammoSite® balloon catheter.

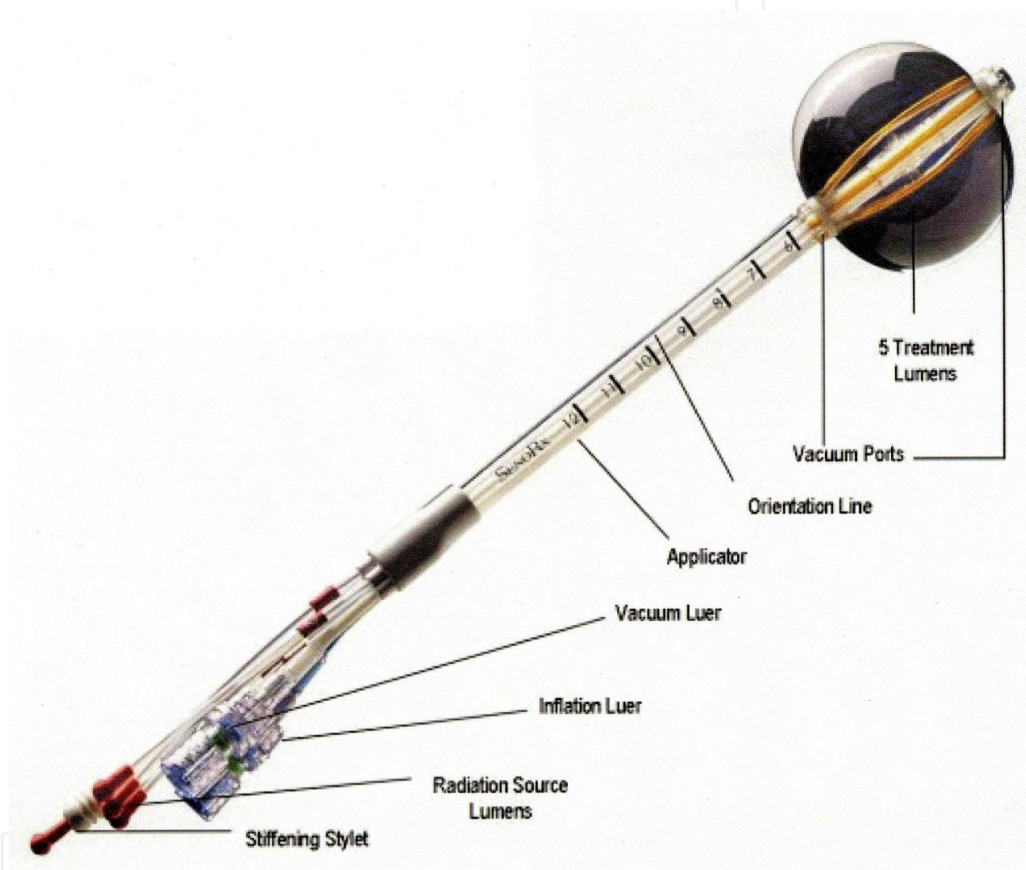
Subsequent evaluation of 43 patients eligible for the therapy revealed only mild to moderate self-limited side effects [30]. Most recently, the American Society of Breast Surgeons reported results from their registry trial involving 1,440 women treated with the MammoSite® catheter following breast-conserving surgery. The 3-year actuarial rates of ipsilateral breast cancer and axillary recurrences were 2.15% and 0.36%, respectively. Cosmetic outcomes were reported to be acceptable and similar to patients treated with other forms of partial breast irradiation [33]. The advantages of the balloon catheter are that it is easier to place in the cavity, placement is more reproducible, and patient comfort is improved. It has become the most widely used device and has the longest track record [43]. The single catheter needs to be temporarily placed in the lumpectomy cavity, as opposed to 10-20 catheters with traditional interstitial implants. However, the balloon needs to "conform" properly to the tumor cavity and optimal dosimetry could be problematic if a large air pocket develops along the periphery of the cavity. The dose distribution is spherical or elliptical depending on the balloon chosen. Balloon-skin spacing should be at least 7 mm. The American Society of Breast Surgeons showed that skin spacing in addition to the use of chemotherapy and breast wound infection were the most important factors of cosmesis at 36 months in their MammoSite® Breast Brachytherapy Registry Trial [24].



**Figure 3.** Hologic Mammosite balloon used for APBI treatments.



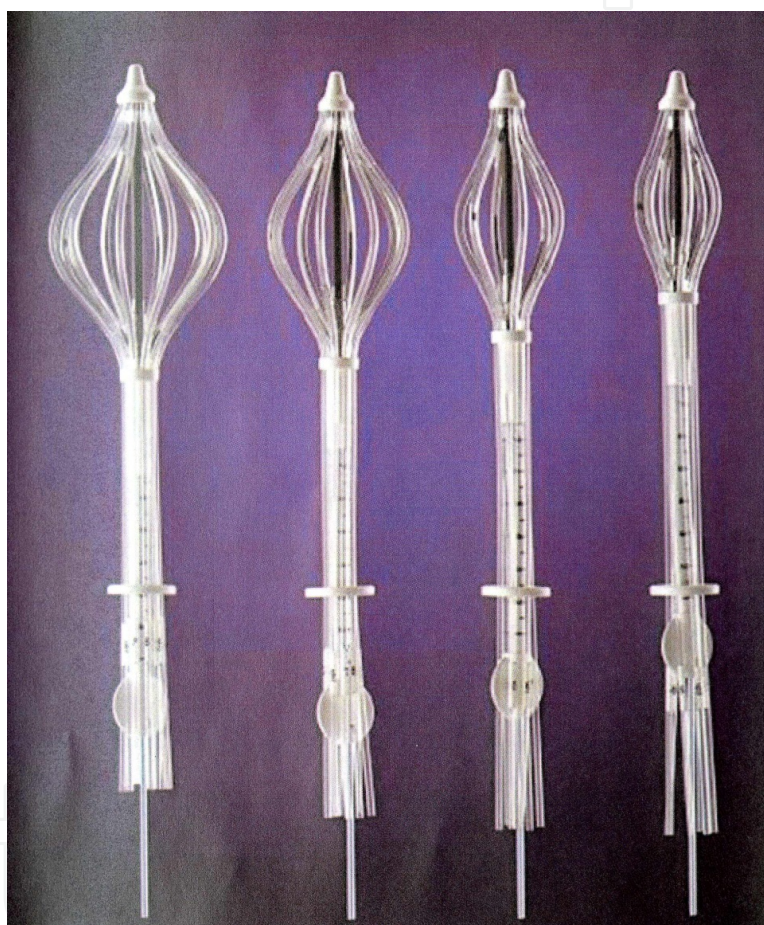Other applicator devices have come onto the market recently, with the advantages of having the potential for improved dosimetry in select patients when compared to the MammoSite applicator. The Contura™ Multi-Lumen Balloon catheter, depicted in Figure 4, allows multiple offset lumens to provide dose shaping opportunities to reduce skin and rib doses [13]. This product may have the advantages of using a balloon type applicator, in which many surgeons and radiation oncologists are familiar and comfortable. Additionally, air and blood around the cavity could be removed with the Contura™ catheter before treatment, potentially reducing air pockets and seroma formation. However, dosimetry is still limited to the confines of a "balloon catheter."



**Figure 4.** Bard Medical Systems Contoura Multi-lumen balloon.

The ClearPath™ multicatheter device is one of the newest brachytherapy devices available. The catheter is placed through a single entry point but without the constraints of having a single radiation source. The use of a multicatheter hybrid can reduce doses to the skin and normal tissues in the breast when compared to a single catheter system [18,19,8]. Both high-dose-rate as well as low-dose continuous release brachytherapy can be delivered. Therefore, facilities without high-rate-rate equipment can now offer brachytherapy. Additionally, patients can get continuous release treatments at home without having to make twice-daily trips to the treatment facility. Strands of I-125 seeds are inserted in the outer catheters. Patients must wear a fully shielded bra if low-dose continuous release treatment is given.

Another recent addition to the brachytherapy options is the SAVI device (Fig 5), a single-entry multicatheter applicator which allows a radiation oncologist to selectively direct radiation through up to eleven catheter channels, allowing more tailored manipulation of the isodose lines. The device is a bundle of expandable catheters around a central lumen. This applicator tries to blend in the advantages of interstitial brachytherapy with a single-entry device. Dose feathering could be done along the skin and chest. Studies have shown the device to give good tumor bed conformance with minimal normal tissue exposure [39]. Patient positioning as well as maintaining a consistent inter-fraction position is important. A potential disadvantage is that removal of the device may be more difficult when compared to the smaller balloon type catheters.

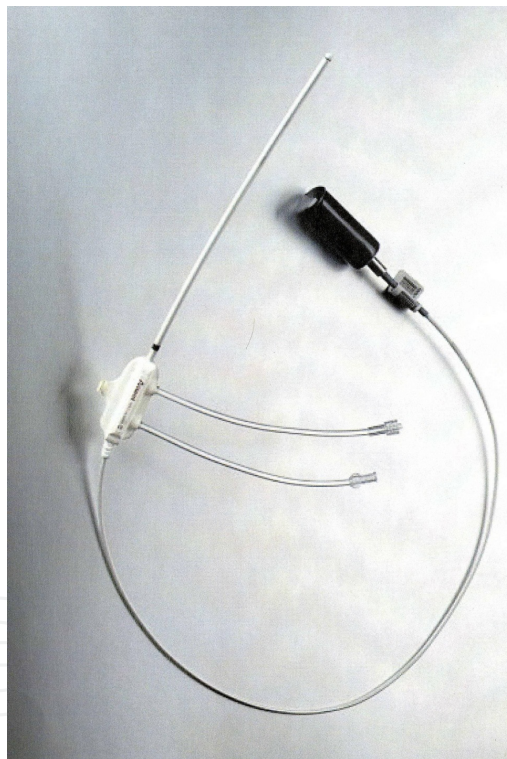


**Figure 5.** Cianna Medical Savi applicators.

Three-dimension (3D) conformal radiation technology has been developed in recent years. This technique of APBI has the advantage of being noninvasive, eliminating an additional procedure, allowing many medical groups that do not perform brachytherapy to offer partial breast radiation therapy. No adverse side effects were seen in 28 patients treated with 3D conformal radiation in a 1999 pilot study [49]. A potential disadvantage is that the breast is not a stationary target and there is the potential for a geographical miss with external radiation therapy to a small target.

## 6. Introduction to electronic brachytherapy

Alternative methods of balloon-based APBI have been explored. A modified form of balloon-based brachytherapy called Xofigo Axxent Electronic Brachytherapy™ (EBX) received FDA clearance for the treatment of breast cancer in January, 2006. This device uses a unique miniaturized x-ray source (Fig 6) and a mobile controller, which generates kilovoltage (kV) x-rays. This approach to APBI requires minimal shielding and thus has the potential to increase the number of settings in which radiation treatments can be offered. In addition, EBX is not limited by rigorous radiation source regulations associated with high dose rate afterloaders used for other methods of APBI, which utilize radioisotope sources. The early results of a clinical trial to evaluate the performance and safety of EBX in the outpatient treatment of early-stage breast cancer patients were presented at the American Society of Clinical Oncology (ASCO) Breast Cancer Symposium. Treatment with EBX was found to be feasible and associated with minimal acute side effects [32].



**Figure 6.** Xofigo Axxent miniature x-ray source.

Investigators have also explored delivering APBI in the operating room immediately after lumpectomy. Intraoperative radiation therapy (IORT) allows the patient to receive all her radiation in a single fraction before she awakens from surgery. Additional potential advantages include delivering the radiation before tumor cells have a chance to proliferate, performing the radiation under direct visualization at the time of surgery, and decreasing healthcare costs. Published results using IORT both as a tumor bed boost in conjunction with



external beam radiation therapy and as a primary treatment in APBI have shown favorable outcomes [45,46,29].

The use of EBX in the operating room is still in its infant stages, but the acceptance of this technique is growing rapidly. The following outlines the steps of an intraoperative procedure:

1. Perform lumpectomy and sentinel node biopsy.
2. Send tumor mass and excision margins for permanent section analysis. Identified sentinel node sent for frozen section evaluation.
3. During surgery, the pathology department reviews the lymph node specimen and informs the treating physicians that the node was uninvolved by cancer.
4. Remove additional breast tissue posterior to the lumpectomy cavity down to the depth of the superficial pectoralis fascia to accommodate a chest wall shield.
5. Place a pliable piece of lead over the chest wall to shield the ribs, lung, and heart, from scatter radiation.
6. Insert a cavity evaluation device into the lumpectomy cavity through a small incision in the lateral breast and inflate with saline.
7. Evaluate the conformity of the cavity evaluation device to the surrounding breast tissue under direct visualization. Determine balloon fill volume to nearest 5cc.
8. Deflate and remove the cavity evaluation device. Based on the fill volume, choose appropriate balloon catheter kit and insert and secure with retention sutures.
9. Verify x-ray source calibration and adjust atlas plan treatment dwell times accordingly. Transfer dwell times to a control USB drive.
10. During machine calibration, perform an intraoperative ultrasound to evaluate that the minimum balloon-to-skin distance is  $>0.6$  cm.
11. Prepare for treatment by placing a sterile drape over the operative field. Add a flexible lead equivalent shield on top of the drape to decrease transmission to the patient and hospital staff.
12. The radiation oncologist connects the x-ray source into the balloon. Provide the radiation treatment.

The treatment prescription is the delivery of 20 Gy to the balloon surface. The treatment is accomplished in 10-25 minutes based on the balloon size, fill volume, and the x-ray source calibration. The duration of the entire procedure including lumpectomy, sentinel lymph node biopsy, balloon catheter placement, radiation therapy, and closing the incisions is approximately two hours.

Long-term data regarding the safety and efficacy of IORT are not available. The TARGIT trial is a phase III prospective, randomized trial comparing single fraction IORT delivered via EBX to conventional whole breast external beam radiation therapy. Sixteen international institu-

tions are enrolling patients in the trial. Eligible patients include patients >35 years of age with T1-T3, N0 tumors eligible for breast conserving therapy. Patients with multi-focal or multi-centric lesions, clinically positive lymph nodes, extensive intraductal component, or invasive lobular cancers are not eligible for enrollment [46].

The results of the TARGIT trial will help determine whether IORT is an equivalent alternative to standard whole breast external beam radiation therapy. If IORT methods, including EBX, are established as a standard treatment option, this may allow increased access to breast conserving therapy, as well as, improved quality of life and decreased medical costs for patients with a diagnosis of early-stage breast cancer.

## 7. Conclusion

Early detection and treatment of breast cancer has significantly improved in recent years. Diagnostic imaging advancements have led to finer and tighter target definition for radiation therapy planning. Treatment delivery systems have changed and continue to change with a movement to shorter and less aggressive therapy. Several treatment options are available for some patients after breast conserving surgery. A 5-7 week course of whole breast external beam therapy now competes with one week of partial breast radiotherapy or a single fraction intraoperative treatment highlighted in this report. As these techniques evolve, focus remains on control, recurrence, and normal tissue response. However, the focus on treatment options also now includes patient schedules, lifestyles as well as the economic impact of the therapy. The multiple risk factors associated with the disease and the variable presentation amongst patients calls out for the need of molecular profiling to assist the oncologist possibly with information on not just who to treat, but how.

## Author details

Brent Herron, Alex Herron\*, Kathryn Howell, Daniel Chin and Luann Roads

\*Address all correspondence to: [medical.physics@hotmail.com](mailto:medical.physics@hotmail.com)

Radiation Oncology, PSL Medical Center, Denver, CO, USA

## References

- [1] American Cancer Society ((2008). Cancer facts and figures. American Cancer Society, Atlanta.



- [2] Antonucci, J, Wallace, M, Goldstein, N, et al. (2009). Differences in patterns of failure in patients treated with accelerated partial breast irradiation versus whole-breast irradiation: a matched-pair analysis with 10-year follow-up. *Int J Radiat Oncol Biol Phys* , 74(2), 447-452.
- [3] Arthur, D, Winter, K, Kuske, R, et al. (2008). A phase II trial of brachytherapy alone after lumpectomy for select breast cancer: tumor control and survival outcomes of RTOG 95-17. *Int J Radiat Oncol Biol Phys* , 72(2), 463-473.
- [4] Bamett, G. C, Wilkinson, J, Moody, A. M, et al. (2009). A randomized controlled trial of forward-planned radiotherapy (IMRT) for early breast cancer: baseline characteristics and dosimetry results. *Radiother Oncol Epub* (ahead of publication)
- [5] Benitez, P, Keisch, M, Vicini, F, et al. (2007). Five year results; the initial clinical trial of Mammosite balloon brachytherapy for partial breast irradiation in early-stage breast cancer. *Am J Surg* , 194(4), 456-462.
- [6] Benson, J. R, Jatoi, I, Keisch, M, et al. (2009). Early breast cancer. *Lancet* , 373, 1463-1479.
- [7] Beral, V, Hermon, C, Reeves, G, et al. (1995). Sudden fall in breast cancer death rates in England and Wales. *Lancet* , 356(8965), 1670-1674.
- [8] Beriwal, S, Coon, D, Kim, H, et al. (2008). Multicatheter hybrid breast brachytherapy: a potential alternative for patients with inadequate skin distance. *Brachytherapy* , 7(4), 301-304.
- [9] Blichert-toft, M, Nielsen, M, Durning, M, et al. (2008). Long-term results of breast conserving surgery vs. mastectomy for early stage breast cancer: 20-year follow-up of the Danish randomized DBCG-82TM protocol. *Acta Oncol* , 47(4), 672-681.
- [10] Borghero, Y. O, Salehpour, M, Mcneese, M. D, et al. (2007). Multileaf field-in-field forward-planned intensity-modulated dose compensation for whole-breast irradiation is associated with reduced contralateral breast dose: a phantom model comparison. *Radiother Oncol* , 82(3), 324-328.
- [11] Brown, S, McLaughlin, M, Pope, K, et al. (2009). Initial radiation experience evaluating early tolerance and toxicities in patients undergoing accelerated partial breast irradiation using the Contura Multi-Lumen Balloon breast brachytherapy catheter. *Brachytherapy* , 8(2), 227-233.
- [12] Buchholz, T. A. (2009). Radiation therapy for early-stage breast cancer after breast-conserving surgery. *N Engl J Med* , 360(1), 63-70.
- [13] Buchholz, T. A, Tucker, S. L, Erwin, J, et al. (2001). Impact of systemic treatment on local control for patients with lymph node-negative breast cancer treated with breast-conservation therapy. *J Clin Oncol* , 19(8), 2240-2246.

- [14] Cabioglu, N, Hunt, K. K, Buchholz, T. A, et al. (2005). Improving local control with breast-conserving therapy: a year single institution experience. *Cancer* 104(1):20-29., 27.
- [15] Cady, B, Stone, M. D, Schuler, J. G, et al. (1996). The new era in breast cancer: invasion, size, and nodal involvement dramatically decreasing as a result of mammographic screening. *Arch Surg* , 131(3), 201-308.
- [16] Clarke, M, Collins, R, Darby, S, et al. (2005). Effects of radiotherapy and of differences in the extent of surgery for earl breast cancer on local recurrence and 15-year survival: an overview of the randomised trials. *Lancet* , 366(9503), 2087-2106.
- [17] Delouche, G, Bachelot, F, Premont, M, et al. (1987). Conservation treatment of early stage breast cancer: long term results and complications. *Int J Oncol Biol Phys* 13(0):29-34.
- [18] Dickler, A. (2009). Xofigo electronic brachytherapy: a new device for delivering brachytherapy to the breast. *Nat Clin Pract Oncol* 6(3): 138-142.
- [19] Dickler, A, Seif, N, Kirk, M, et al. (2009). A dosimetric comparison of MammoSite and ClearPath high-dose-rate brachytherapy devices. *Brachytherapy* , 8(1), 14-18.
- [20] Fisher, B, Anderson, S, Bryant, J, et al. (2002). Twenty-year follow-up of a randomized trial comparing total mastectomy, lumpectomy, and lumpectomy plus irradiation for the treatment of invasive breast cancer. *N Engl J Med* , 347(16), 1233-1241.
- [21] Fisher, B. J, Bryant, J, Dignam, J, et al. (2002). Tamoxifen, radiation therapy, or both for the prevention of ipsilateral breast tumor recurrence after lumpectomy in women with invasive breast cancers of one centimeter or less. *J Clin Oncol* , 20(20), 4141-4149.
- [22] Fowble, B. L, Schultz, D. J, Overmoyer, B, et al. (1994). The influence of young on outcome in early stage breast cancer. *Int J Radiat Oncol Biol Phys* 30(1); 23-33.
- [23] Fyles, A. W, McCreedy, D. R, Manchul, L. A, et al. (2004). Tamoxifen with or without breast irradiation in women 50 years of age or older with early breast cancer. *N Engl J Med* , 351(10), 963-970.
- [24] Goyal, S, Khan, A. J, Vicini, F, et al. (2009). Factors associated with optimal cosmetic results at 36 months in patients treated with accelerated partial breast irradiation (APBI) on the American Society of Breast Surgeons (ASBrS) MammoSite ® Breast Brachytherapy Registry Trial. *Ann Surg Oncol* [Epub ahead of print]
- [25] Harris, J. S, Neill, C. J, & Rosser, P. F. (2008). A comprehensive clinical 3-dimensional dosimetric analysis of forward planned IMRT and conventional wedge planned wedged techniques for intact breast radiotherapy. *Med Dosim* 33(1):62-70.

- [26] Holland, R, Connolly, J. L, Gelman, R, et al. (1990). The presence of extensive intraductal component following a limited excision correlates with prominent residual disease in the remainder of the breast. *J Clin Oncol* , 8(1), 113-118.
- [27] Holli, K, Saaristo, R, Isalo, J, et al. (2001). Lumpectomy with or without postoperative radiotherapy for breast cancer with favorable prognostic features: results of a randomized study. *Br J Cancer* , 84(2), 164-169.
- [28] Hughes, K. S, Schnaper, L. A, Berry, D, et al. (2004). Lumpectomy plus tamoxifen with or without irradiation in women 70 years of age or older with early breast cancer. *N Engl J Med* , 351(10), 971-977.
- [29] Intra, M, Gatti, G, Luini, A, et al. (2002). Surgical technique of intraoperative radiotherapy in conservative treatment of limited stage breast cancer. *Arch Surg* , 137, 737-740.
- [30] Keisch, M, Vicini, F, Kuske, R, et al. (2003). Initial clinical experience with the Mammo Site breast brachytherapy applicator in women with early-stage breast cancer treated with breast-conserving therapy. *Int J Radiat Oncol Biol Phys* 55 (2):289-293.
- [31] Kumle, M. (2008). Declining breast cancer incidence with decreased HRT use. *Lancet* , 372(9639), 608-610.
- [32] Mehta, V. K, Dooley, W, Griem, K. L, et al. (2008). Early experience with an electronic brachytherapy for intracavitary accelerated partial breast irradiation. *Proceedings of the 2008 ASCO Breast Cancer Symposium*.
- [33] Nelson, J, Beitsch, P, Vicini, F, et al. (2009). Four year clinical update from the American Society of Breast Surgeons MammoSite brachytherapy trial. *Am J Surg* , 198(1), 83-91.
- [34] Nixon, A. J, Neuberg, D, Hayes, D. F, et al. (1994). Relationship of patient's age to pathologic features of the tumor and prognosis for patients with stage I or II breast cancer. *J Clin Oncol* , 12(5), 888-894.
- [35] Peto, R, Boreham, J, Clarke, M, et al. (2000). UK and USA breast cancer deaths down 25% in year 2000 at ages years. *Lancet* 355(9217):1822., 29-69.
- [36] Pierce, L. J, Butler, J. B, Martel, M. K, et al. (2002). Postmastectomy radiotherapy of the chest wall: dosimetric comparison of common techniques. *Int J Radiat Oncol Biol Phys* , 52(5), 1220-1230.
- [37] Poggi, M. M, Danforth, D. N, Sciuto, L. C, et al. (2003). Eighteen-year results in the treatment of early breast carcinoma with mastectomy versus breast conservation therapy: the National Cancer Institute Randomized Trial. *Cancer* , 98(4), 697-702.
- [38] Sarrazin, D, Le, M. G, Arriagada, R, et al. (1989). Ten-year results of a randomized trial comparing a conservative treatment to mastectomy in early breast cancer. *Radiother Oncol* , 14(3), 177-184.

- [39] Scanderbeg, J, Yashar, C, Rice, R, et al. (2009). Clinical implementation of a new brachytherapy device for partial breast irradiation. *Radiother Oncol* 90(1):, 36-42.
- [40] Schlembach, P. J, Buchholz, T. A, Ross, M. I, et al. (2001). Relationship of sentinel and axillary level 1 and II lymph nodes to tangential fields used in breast irradiation. *Int J Radiat Oncol Biol Phys* , 51(3), 671-678.
- [41] Singletary, S. E. (2002). Surgical margins in patients with early stage breast cancer treated with breast conservation therapy. *Am J Surg* , 184, 383-393.
- [42] Smith, B. D, Gross, C. P, Smith, G. L, et al. (2006). Effectiveness of radiation therapy for older women with early breast cancer. *J Natl Cancer Inst* , 98(10), 681-690.
- [43] Streeter, O, Vicini, F, Keisch, M, et al. (2003). MammoSite® radiation therapy system. *Breast* , 12(6), 491-496.
- [44] Taghian, A. G, & Powel, S. N. (1999). The role of radiation therapy for primary breast cancer. *Surg Clin North Am* , 79(5), 1091-1115.
- [45] Vaidya, J. S, Walton, L, & Dewar, J. (2006). Single dose targeted intraoperative radiotherapy (TARGIT) for breast cancer can be delivered as a second procedure under local anaesthetic. *World J Surg Oncol* 4:2.
- [46] Vaidya, J. S, Baum, M, Tobias, J. S, et al. (2006). Targeted intraoperative radiotherapy (TARGIT) yields very low recurrence rates when given as a boost. *Int J Radiat Oncol Biol Phys* , 66, 1335-8.
- [47] Veronesi, U, Cascinelli, N, Mariani, L, et al. (2002). Twenty-year follow-up of a randomized study comparing breast-conserving surgery with radical mastectomy for early breast cancer. *N Engl J Med*, 347(16), 1227-1232.
- [48] Vicini, F, Baglan, K, Kestin, L, et al. (2001). Accelerated treatment of breast cancer. *J Clin Oncol* , 19(7), 1993-2001.
- [49] Vicini, F, Remouchamps, V, Wallace, M, et al. (2003). Ongoing clinical experience utilizing 3-D conformal external beam radiotherapy to deliver partial-breast irradiation in patients with early stage breast cancer treated with breast-conserving surgery. *Int J Radiat Oncol Biol Phys* , 57(5), 1247-1253.
- [50] Vicini, F. A, Recht, A, Abner, A, et al. (1992). Recurrence in breast following conservative surgery and radiation therapy for early stage breast cancer. *J Natl Cancer Inst Monogr* (11): 33-39.