

# We are IntechOpen, the world's leading publisher of Open Access books Built by scientists, for scientists

6,900

Open access books available

186,000

International authors and editors

200M

Downloads

Our authors are among the

154

Countries delivered to

TOP 1%

most cited scientists

12.2%

Contributors from top 500 universities



WEB OF SCIENCE™

Selection of our books indexed in the Book Citation Index  
in Web of Science™ Core Collection (BKCI)

Interested in publishing with us?  
Contact [book.department@intechopen.com](mailto:book.department@intechopen.com)

Numbers displayed above are based on latest data collected.  
For more information visit [www.intechopen.com](http://www.intechopen.com)



---

## **Delayed Aneurysm Rupture After EVAR**

---

Guido Regina, Domenico Angiletta,  
Martinella Fullone, Davide Marinazzo,  
Francesco Talarico and Raffaele Pulli

Additional information is available at the end of the chapter

<http://dx.doi.org/10.5772/53415>

---

### **1. Introduction**

Endovascular repair is becoming the milestone of treatment for aneurysmal disease of the abdominal aorta, evolving over time as an attractive alternative to open repair, especially for elderly and high risk patients.

Since the introduction of endovascular aneurysm repair (EVAR) 20 years ago [1] many successful early results have been achieved with this treatment, but mid-term and long-term durability of the endograft devices that have been used remains questionable [2-5].

Endovascular techniques and technical material have improved from the initial devices and have permitted the extension of the treatment to more and more complex anatomies.

However, sustained survival benefits have not been proven because nowadays only mid-term results after EVAR have been reported, and additional procedures were required in many patients.

Late failure of endovascular repair secondary to endoleaks, endotension and sac enlargement, stentgraft migration, tear and fracture or infection continues to be a persistent problem that can result in delayed aneurysm rupture [5-8].

Large cohorts of studies have reported rates of abdominal aortic aneurysm (AAA) rupture after EVAR ranging from 0.5 to 1.2% per patient per year [9-14]. Lifetime risks are even higher because most patients live for several years after the procedure [15].

Therefore, although several randomized trials have shown lower perioperative morbidity and mortality after EVAR compared with open repair [16-19], mid and long-term complica-

tion, most of which represented by endoleaks, are quite frequent after EVAR and the risk of late rupture persists.

Availability of new generation devices, strict patient selection and respect of correct morphological criteria are crucial to obtain good outcomes of EVAR, reducing the risk of postoperative complications, including delayed rupture.

## 2. Materials and methods

In our own series, involving one University Hospital and four Regional Hospitals, between January 2004 and December 2011, a total of 1500 patients underwent endovascular repair of AAA with a variety of commercially available stent grafts.

Emergent aortomonoiliac EVAR and crossover bypass was performed in 90 (5%) patients with ruptured AAA, while the remaining patients received elective EVAR with bifurcated (n=1020, 72.3%) or aortomonoiliac endograft with crossover bypass (n=390, 27.7%).

The mean postoperative follow-up was 30 months (range 6-72). The imaging protocol included angiographic computer tomography (angioTC) performed at intervals of 1, 3, 6, 12 months after the procedure and annually thereafter.

Aneurysm rupture was defined as an extravasation of blood outside the aortic wall, documented at angioCT.

## 3. Results

During the follow-up 22 patients (1.46%) presented with late aneurysm rupture after EVAR. These results are in consonance with the data available in literature [20-24].

There were no statistical differences between patients undergoing emergent or elective EVAR and among patients undergoing bifurcated or aortomonoiliac endografting.

Causes of rupture include endoleaks in 51.3% of cases (35% type I, 15.3% type II, 0% type III and IV), while in 49.7% of cases the cause remained undetermined.

Most of the described AAA ruptures occurred within 1-3 years after endovascular repair. The mean time to rupture from the primary EVAR was 20 months. The mean initial aneurysm diameter was relatively large (62 mm).

All patients arrived alive to treatment. Eight patients had a redo EVAR, while 14 underwent open repair. Three out of 8 patients (37.5%) died after redo EVAR and 6 out of 14 patients (42.8%) treated by open repair died during the operation or in the perioperative period.

The incidence of overall mortality after rupture in this experience was 40.9 %.

## 4. Discussion

Several studies have demonstrated better peri-operative survival for endovascular over open repair of AAA, with fewer complications and a shorter recovery period [16-19].

However there are concerns about durability of endovascular repair at long-term when compared with conventional open treatment. Actually EVAR does not completely eliminate the risk of late aneurysm rupture and requires more frequent reinterventions to maintain the exclusion of the aneurysm, including conversion to open repair.

Success of the endovascular treatment depends on the strict selection of the patients, evaluating specific anatomic characteristics like diameter, lenght and angulation of the aortic neck as well as iliac morphology.

In a 2010 retrospective study involving 1768 patients undergoing EVAR, Metha et al [25] reported an incidence of additional secondary procedures of 19.2% during a mean follow-up period of 34 months (Tab. 1).

Number of patients	1,768
Mean follow-up [SD]	34 Months [30]
Secondary intervention	19.2%
Type II Endoleak	40.1%
Type I/III Endoleak	16.5%
Migration	13.6%
Limb occlusion	7.4%
Other (rupture, device defect, etc.)	8.6%

**Table 1.** Incidence of secondary procedures after EVAR.

In 2010 the results of the DREAM trial showed a reintervention rate of almost 30% within 6 years [26]. The most frequently reported complications include endograft migration, endoleaks, limb occlusion and rupture.

Endoleak is the Achille's heel of the EVAR, revealing associations with both early and late failure of the procedure and is the most common reason for aortic rupture and reinterventions in the follow up of EVAR.

The incidence of all endoleaks is reported in the major trials of recent years as ranging from 15.6% to 19.8% [17-19].

The endoleaks are classified into five types according to the etiology (Tab. 2) [27].

Type	Origin of the leak
I	Inadequate seal at proximal (Ia) or distal (Ib) end of the graft
II	Retrograde flow from the inferior mesenteric artery, lumbar arteries, others collateral vessels of the aneurysm sac
III	Component disconnection (IIIa) or fabric disruption (IIIb)
IV	Graft material porosity
V	Endotension: increase of the pressare without any visibile evidente of blood in the aneurysm sac

**Table 2.** Endoleak classification. From: Moll FL, Powell JT, Fraedrich G, et al. Management of abdominal aortic aneurysms clinical practice guidelines of the European society for vascular surgery. Eur J Vasc Endovasc Surg 2011;41(Suppl 1):S1-S58.

One of the most frequent causes of type I endoleak is represented by the aneurysmatic evolution of the proximal aortic neck. Aortic aneurysmal degeneration can progress over time to involve the segments chosen at the time of surgery as appropriate landing zones for effective sealing. Therefore, late degeneration of the landing zones can lead to endograft migration and type I endoleak with sac enlargement.

Some authors have reported a dilatation of the landing zone after EVAR [28]. Possible explanations could be the continuous outward radial force of the uncovered portion of the endograft, in particular in case of high oversizing, or the forces applied in this region during the implantation of the device.

Type I endoleaks can also occur as a result of stentgraft migration that may originate from unstable proximal sealing, as a consequence of wrong planning involving oversizing underestimation and lack of graft radial force, especially in case of poor quality of proximal aortic neck (i.e. short lenght, severe angulation, high calcification and thrombus load).

Severe angulations and tortuosity of the aorta and the iliac arteries usually can also led to graft migration with possibile type I endoleaks.

Iliac fixation plays an important role in preventing stentgraft migration. Extension of both iliac limbs to the level of the iliac bifurcation seems to minimize the risk of endograft migration, despite suboptimal neck anatomy.

Type III endoleak is caused mainly by a dislocation of two stentgraft components in a modular stentgraft system (IIIa), generally due to a shortening of the overlapping zones during the procedure. Extreme angulation of the neck or iliac segments may also be a contributing factor. Failure relate to modular disjunction is preventable by ensuring an adequate component overlap during the intervention.

Other causes of type III endoleak are due to a device failure as a consequence of a deficit in the graft fabric (type IIIb).

Patients with type I and III endoleaks have been identified as being at gratest risk of aneurysm rupture. Conventional endoleak management consists in prompt repair of type I and III endoleaks.

Type IV endoleak is determined by an excessive porosity of the stentgraft that appears intact. Since these endoleaks may spontaneously seal, their treatment is not recommended.

Type II endoleak is related to retrograde flow via collaterals, mostly lumbar arteries, hypogastric arteries, inferior mesenteric artery. Although type II endoleak is considered benign, this persistent flow could prevent thrombosis of the aneurysm sac, resulting in a potential risk of continued aneurysm expansion and possible rupture.

Many early type II endoleaks are transient and will resolve spontaneously within six months, but a small minority of patients with untreated endoleak type II may suffer from aneurysm rupture. The treatment of type II endoleaks should be considered when it suddenly appears during follow-up or when it persists for more than 6 months without shrinkage of the sac.

Ronsivalle et al [29] have reported the efficacy of the injection of fibrin glue with coils into the aneurysm sac, in addition to the conventional EVAR protocol. The aim of this procedure is to induce clotting of the aneurysm sac, thus reducing the risk of type II endoleaks, potentially leading to late aneurysm rupture.

In our experience, intraoperative intrasac thrombin injection was employed in patients with AAA at high risk of type II endoleaks (absence or modest intraluminal thrombus, presence of inferior mesenteric artery, lumbar arteries, hypogastric or accessory renal arteries). Early results at follow-up showed a reduction of the incidence of type II endoleak, as well as type I endoleak, since clotting of the aneurysm sac presumably provides also stability of the endograft, so preventing migration of the devices.

Although the high incidence of secondary interventions after EVAR decreased significantly in recent years, largely thanks to device improvement, the widespread use of the endovascular treatment often leads surgeons to force the indications to EVAR, even in patients with unfavorable anatomy.

Endografts placed outside device guidelines were associated with higher aneurysm-related mortality, reinterventions, graft-related adverse events, indicating that adherence to such guidelines is a fundamental clinical practice.

## 5. Data from literature

Data from literature about late aneurysm rupture after EVAR and relative mortality were collected. Results are summarized in table 3 and compared with our experience.

The EUROSTAR (European Collaborators on stent-graft techniques for aortic aneurysm repair) registry [4], established in 1996, collected data on the outcome of treatment of patients with infrarenal AAA treated by EVAR, with the purpose to evaluate incidence and risk factors of late rupture, conversion and death. In this large study 2464 patients have been enrolled, with a median follow-up of 12.14 months. Thirteen patients sustained confirmed aneurysm rupture 30 days or more after operation. One rupture occurred in the periopera-

Study (year)	N. late rupture (%)	Overall mortality (%)	N. patients undergoing surgery	Mortality after surgery
Harris (2000) [4]	13/ 2464 (0.52)	8/13 (61.5)	11/13 (84.6)	6/11 (54.54)
Bernhard (2002) [30]	7/3946 (0.17)	4/7 (57)	6/7 (85.7)	3/6 (50)
Hobo (2008) [20]	(1.7) (4.5) (*)	(4.5) (7.4) (*)	NR	NR
Szmidt (2007) [21]	3/445 (0.67)	0	0	0
Wyss (2010) [22]	22/848 (2.59)	15/22 (68.18)	8/22 (36.36)	1/8 (12.5)
Koole (2011) [23]	26/6337 (0.41)	NR (62)	NR	NR
Metha (2011) [24]	27/1768 (1.52)	4/27 (14.81)	26/27 (96.3)	3/26 (11.5)
Our experience (2011)	22/1500 (1.46)	9/22 (40.9)	22/22 (100)	9/22 (40.9)

(\*) presence of concomitant iliac aneurysm

N.R. not reported

**Table 3.** Incidence and mortality of delayed aneurysm rupture after EVAR.

tive period (within 30 days). Only those patients with clear signs of rupture (derived from the findings at operation, CT images or autopsy results) were included in the study. Patients who died suddenly before a precise diagnosis could be confirmed (10 patients) were not included. Details of the patients with proved rupture are shown in table 4.

Peak incidence of rupture occurred 18 months after the intervention (range 0-24 months). The annual cumulative rate of rupture approximated to 1% per year (1.4% in the first year, 0.6% in the second year). Twelve patients (85.7%) underwent emergency open surgery, five of whom (41.6%) survived. There were no survivors between the two patients who were not subject to an emergency operation. The overall death rate of late (> 30 days) aneurysm rupture after EVAR was 69.2% (9/13) of the patients.

Proximal type I endoleak, midgraft (type III) endoleak, migration and postoperative kinking of the endograft were proved to be relevant risk factors for rupture. Type II endoleak, distal type I endoleak, endograft stenosis and thrombosis were present but statistically not significant (table 5).

Persistent endoleak as indicator of failure of the treatment was based on the assumption that the endoleak itself was the cause of the continued expansion and the eventual rupture of the aneurysm sac after EVAR.

Nevertheless, at last three of 10 patients who died suddenly of unknown causes had an aneurysm of a maximum diameter greater than six centimeters before their death. Although there may have been cardiac malfunction or other postoperative causes, rupture was likely to account for some of these 10 deaths.



Serial no.	Time since operation (mo)	Intervention on rupture	Device	Outcome (at 30 d)
1	18	Conversion	Vanguard*	Death
2	24	Conversion	Vanguard*	Death
3	3	Conversion	AneuRx	Death
4	12	Conversion	Stentor*	Survived
5	18	Conversion	Stentor*	Survived
6	6	Conversion	Vanguard*	Death
7	18	Conversion	Vanguard*	Survived
8	18	Nil	Vanguard*	Death
9	6	Conversion	Vanguard*	Survived
10	24	Conversion	Vanguard*	Death
11	3	Nil	Talent	Death
12	18	Conversion	Vanguard*	Death
13	24	Conversion	Vanguard*	Survived
14†	0	Conversion	Talent	Death

\*Discontinued model devices.

†One rupture within 30 days of endovascular repair

From: Harris PL, Vallabhaneni SR, Desgranges P, et al. Incidence and risk factors of late rupture, conversion, and death after endovascular repair of infrarenal aortic aneurysms: the EUROSTAR experience. European collaborators on stent/graft techniques for aortic aneurysm repair. *J VascSurg* 2000;32:739-49

**Table 4.** Details of patients with a proved rupture of the treated aneurysm.

Moreover, EUROSTAR experience demonstrates that the overall death rate of 64.3% (9/14) for AAA rupture after EVAR is not inferior than the usual expectation of mortality after ruptured AAA repair, as previously reported [31].

The analysis of risk factors for late rupture in the EUROSTAR study confirms the importance of proximal fixation site endoleak, while distal endoleaks seem to have a more benign impact, possibly because of the lower pressure or endotension in the aneurysm sac. Moreover, results of this study seem to confirm that type II endoleak is less important as regard to aneurysm rupture, most of them resolving spontaneously. However, prudence is mandatory because of uncertainty regarding the accuracy of diagnosis of these endoleaks. Kinking of the endovascular devices could also be responsible of the sac rupture as well as stent migration.

Even if the death rate associated with all operations for conversion repair in the EUROSTAR experience was 24.4%, surgeons must realized that the risk of delayed rupture is greater than the risk of conversion.

In 2008 an outcome analysis of EUROSTAR experience compared results following EVAR in patients affected by AAA with (group II) and without (group I) concomitant iliac artery



Adverse factor	Free from rupture and adverse factor (n)	Rupture with adverse factor (n)	Rupture free from adverse factor (n)	Adverse factor free from rupture (n)	P value	Relative hazard ratio (95% CI)
Proximal type I endoleak	2250	3	10	62	.0001	7.59 (2.09-27.62)
Midgraft (type III) endoleak	2224	5	8	88	.0001	8.95 (2.92-27.52)
Stent-graft migration	2248	3	10	64	.0001	4.53 (1.24-16.66)
Kinked endograft	2216	3	10	96	.0001	3.13 (1.40-11.49)
Type II endoleak*	2106	2	11	206	.415*	
Distal type I endoleak*	2177	1	12	135	.776*	
Endograft stenosis*	2275	0	13	37	.646*	
Thrombosed endograft*	2235	0	13	77	.503*	

\*Statistically not significant.

From: Harris PL, Vallabhaneni SR, Desgranges P, et al. Incidence and risk factors of late rupture, conversion, and death after endovascular repair of infrarenal aortic aneurysms: the EUROSTAR experience. European collaborators on stent/graft techniques for aortic aneurysm repair. J VascSurg 2000;32:739-49

**Table 5.** Risk factors for late rupture and their incidence after endovascular repair.

aneurysm [26]. Mortality rates was obtained from the Registry database for the period from October 1996 to November 2006. Group II included more patients classified as ASA III-IV, who were considered more frequently unfit for open surgery, with larger-diameter aneurysms and infrarenal necks, an increased incidence of internal iliac artery occlusion and greater angulation of the aortic neck and iliac artery (Tab. 3).

The 5-year cumulative incidence of distal type I endoleak was higher in group II (9.1%) than in group I (4.3%) as well as the 5-year cumulative incidence of aneurysm rupture (4.5% in group II versus 1.7% in group I;  $p = 0.042$ ) (Fig. 1).

Nevertheless, between the two study groups was not found an aneurysm-related mortality rate significantly different (4.5% in group I and 7.4% in group II). However, this rate could be underestimated because the cause of death was unknown or undefined in a significant number of patients.

In this study distal type I endoleaks was strongly associated ( $p < 0.0001$ ) with the presence of concomitant iliac aneurysms. The greater incidence of these endoleaks appears to be due to a more difficult achievement of an adequate distal seal and fixation of the endograft in the external iliac artery, which is frequently tortuous, angulated or diseased in this area. Distal type I endoleak is probably the cause of the higher incidence of aneurysm rupture observed in these patients.

In 2007 Szmidt et al [21] presented their experience with 445 patients undergoing EVAR between 1998 and 2006. The authors reported three (0.67%) late aneurysm ruptures. In all cases the cause was type I endoleak, due to graft migration in two cases and aneurysm lengthening in the remaining case. All the patients received open aneurysmectomy without any major complications.

	Group I (n=6286)	Group II (n=1268)	p*
<i>Mesasurements</i>			
Infrarenal neck diameter, mm	24.1 +/- 3.3	24.5+/-3.4	<0.001
Infrarenal neck length, mm	26.8+/-11.5	27.7+/-12.6	NS
Maximum aneurysm diameter, mm	60.7+/-10.4	62.3+/-11.2	<0.0001
Common iliac artery, mm	14.8+/-4.7	25.9+/-13.2	<0.0001
<i>Occlusion</i>			
Common or external iliac artery	109 (1.7%)	23 (1.8%)	NS
Hypogastric artery	329 (5.2%)	144 (11.4%)	<0.0001
<i>Angulation</i>			
Aortic neck	1529 (24.3%)	390 (30.8%)	<0.0001
Aneurysm	776 (11.7%)	160 (10.9%)	NS
Iliac artery	2632 (41.9%)	612 (48.3%)	<0.0001

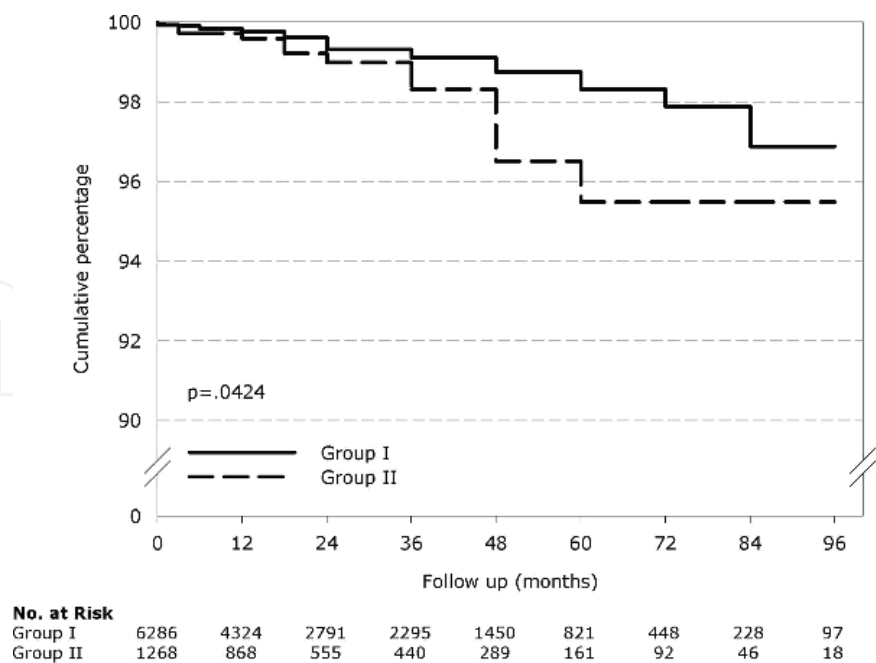
Continuous data are presented as means +/- standard deviation; categorical data are given as counts (percentages).

NS: not significant.

\* Univariate analysis.

From: Hobo R, Sybrandt JE, Harris P, Buth J. Endovascular repair of abdominal aortic aneurysms with concomitant iliac artery aneurysm. Outcome analysis of the EUROSTAR experience. *J Endovasc Ther.* 2008;15:12-22

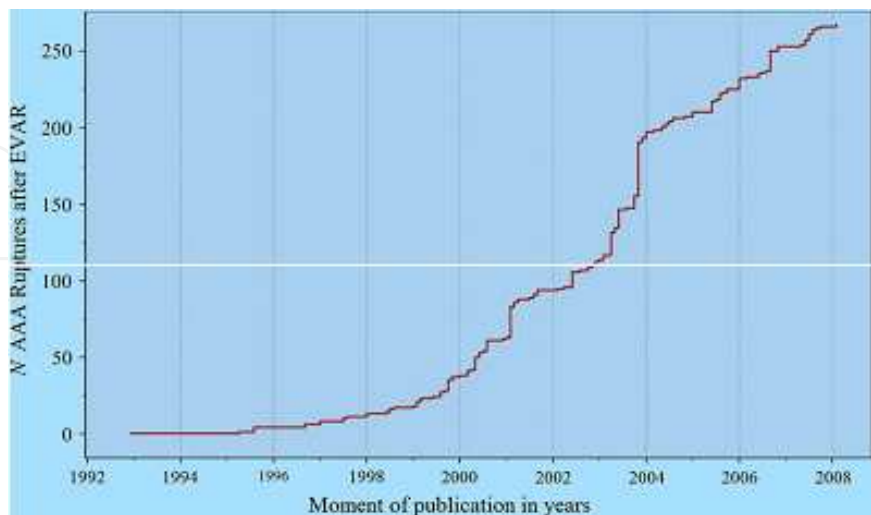
**Table 6.** Aneurysm anatomy of 7554 AAA patients undergoing Endovascular Aneurysm Repair.



**Figure 1.** Freedom from aneurysm rupture. From: Hobo R, Sybrandy JE, Harris P, Buth J. Endovascular repair of abdominal aortic aneurysms with concomitant iliac artery aneurysm. Outcome analysis of the EUROSTAR experience. *J Endovasc Ther.* 2008;15:12-22

However, the late rupture rate in this series is probably underestimated because of a limited follow-up period (mean 30 months) and the dropout of a considerable number of patients.

In a review published in 2009, Schlosser et al [32] identified 270 patients with AAA rupture after EVAR, most of whom occurred within 2-3 years after the operation (Fig. 2).



**Figure 2.** Patients with AAA rupture after aneurysm repair by publication date. From: Schlösser FJV, Gusberg RJ, Dardik A, Lin PH, Verhagen HJM, Moll FL and Muhs BE. Aneurysm rupture after EVAR: can the ultimate failure be predicted? *Eur J VascEndovascSurg* 37(1):15-22 (2009).

The main cause of rupture was reported for 235 of the 270 patients. Endoleaks were reported in 160 patients (57 type IA, 31 type IB, 23 type II, 26 type III, 0 type IV, 9 endotension, 14 not specified), graft migration in 41, graft disconnection in 11 and infection in 6.

Late ruptures occurred in 164 patients. The mean time interval between the initial procedure and subsequent AAA rupture was 24 +/- 18 months (range 2-96, median 20). 155 out of 202 reported moments of rupture occurred within 27 months after EVAR and their incidence considerably reduced thereafter.

The mean time interval did not differ between men and women in 71 patients in which information about gender and time interval was available. Mean initial AAA diameter was relatively large (65mm).

In 82 patients information about both moments of rupture and AAA diameter was available. Patients with an initial AAA diameter above the mean (> 65mm) had a shorter time interval between EVAR and AAA rupture than patients with smaller-diameters AAA, although this difference was not significant.

The course of AAA diameter during follow-up was described in 101 patients. Growth of the AAA sac occurred in 36, any changes in 39 and shrinkage in 26 patients.

In 41 patients no abnormalities requiring reintervention were found during the follow-up: in 35 no abnormalities (absence of endoleak, stent fractures, migration, graft angulation, insecure fixation, signs of inflammation and sac enlargement) were found at all. In another 6 patients only a small type II endoleak was found and the AAA diameter was stable.

Fifty-six of all patients presented an endoleak during the most recent follow up visits before the rupture occur, 6 of whom were small type II endoleaks without sac enlargement. Other abnormal findings included wire fractures, graft migration or severe graft angulation in 11, insecure fixation in 5, AAA sac inflammation in 1, while AAA rupture itself was diagnosed during a regular follow-up visit in 5 patients.

160 patients underwent open conversion and 26 sustained a redo-EVAR. In 24 patients no repair was performed at all and for 60 no data were available.

AAA ruptures were fatal in about half of the patients (119 out of 231) for whom data about mortality were reported. In patient undergone to endovascular or open repair the results were slightly better: a fatal course occurred in 62 of 138 patients that underwent open conversion and in 7 of 26 patients that were subjected to a redo endovascular ruptured AAA repair.

This study has however some limitations. Because data collection was obtained from the existing literature, informations about many variables could not been available for all patients (e.g. data about neck diameters at the time of EVAR and time of rupture, year of repair, etc.). Another disadvantage is that the determination of the cause of aneurysm rupture was based on the description reported by the authors of the selected articles. Because different authors may have used different criteria to establish causes of rupture, this process may have been relatively subjected. Moreover, in 24 of 270 patients, no pre-

cise description about diagnostic examinations was provided and no fatal course was described. Theoretically there may have been a possibility that any of these 24 patients had a “symptomatic” AAA instead of a ruptured AAA.

Another disadvantage concerns the limited follow-up period of a significant number of patients, that may partially explain the relatively high number of AAA ruptures in the first 2-3 years after EVAR reported in this study. Indeed, ruptures after 3 years may be underrepresented due to movement of patients to other institutions or due to mortality.

It is interesting to note that a strong association between larger-diameter aneurysm and increased risk of rupture after EVAR has been described by the EUROSTAR registry, Lifeline registry and AneuRx trial [9-15, 33-38].

Increased rupture risk in patients with persistent type II endoleak was reported by Johns et al [39]. Female gender seems to be associated with an increased risk of rupture too [12,13].

Because relatively many ruptures occur between the follow up visits at one and two years after EVAR, an additional follow-up after 18 months may possibly reduce the AAA rupture rate. This may be especially important for patients with early rupture, such as patients with larger AAA diameters, endoleaks or graft migration.

Data from the EVAR trials [16, 40] were analyzed by Wyss et al [22] in order to assess factors associated with AAA rupture after EVAR or open repair. There were no ruptures in the 594 patients undergoing open aneurysmectomy, during a follow-up with average duration of 5.3 years. On the other hand, out of a total of 848 elective EVARs, 27 ruptures occurred during an average follow-up period of 4.8 years (25 in EVAR trial 1 and 2 in EVAR trial 2), with a rate of rupture of 0.8 and 0.2 per 100 patients per year, respectively.

The ruptures were divided into three groups. Group A contains 5 (18.5%) ruptures that occurred in the perioperative period (within 30 days). Group B included 5 (18.5%) patients who sustained rupture more than 30 days after the intervention, without prior complication or signs of failed endovascular treatment. Four of the 5 patients died within 30 days of the rupture. One patient sustained the rupture at home on day 32 and no post-procedural imaging was performed before discharge. Three patients underwent a normal follow-up CT scan within 2 months before rupture, all showing sac shrinkage with any abnormal findings. Another patient showed sac shrinkage and no complications during the first 2 years but he missed the three years follow-up scan. Thus, even if a pre-discharge scan had been proposed as part of the EVAR trial protocol, three ruptures remained unexplained, despite optimal protocol had been followed.

Group C included 17 (63%) patients with late ruptures with prior complications. Eleven of these patients died within 30 days of the rupture. Sac enlargement had been observed in 15 of 17 patients, with documented endoleaks in 12 of these 15 patients. In the remaining 2 patients, without sac expansion, one sustained graft migration and one presented an endoleak of undetermined origin. Three cases had a type II endoleak as previously described complications. All these patients presented concomitant sac enlargement before rupture. Twelve patients with a prior complication underwent a secondary intervention before rupture.

Surgical repair was performed in 12 out of 27 patients who experienced aneurysm rupture, with an overall surviving rate of 75%. Seven patients (4 in group A and 3 in group C) underwent open repair, 5 of whom survived more than 30 days, while endovascular treatment was performed in 5 patients (1 in group B and 4 in group C), 4 of whom survived more than 30 days. The remaining 15 patients died before aneurysm repair could be attempted.

In this study there was a significant association between rupture and previous detection of complications (type I endoleak, type II endoleak with sac expansion, type III endoleak with migration or kinking of the endograft) and no significant difference in rupture rate between the different kinds of endoprosthesis employed (Cook Zenith, Medtronic Talent, Gore Excluder, others). A risk of rupture doubling for each centimeter increase of top neck diameter was suspected. The analysis also suggested that age was an influential factor, with a risk of rupture increasing with age.

Bernhard et al [30] showed their experience with aneurysm rupture after deployment of Guidant/EVT endograft and reviewed previously reported cases with others devices. The authors collected 47 cases of ruptured AAA after EVAR from 1993 to 2000, seven of whom occurred after the use of Guidant/EVT devices. Causes of rupture are listed in table 7.

Type and source of endoleak	No. of patients
Type I endoleak	27
Proximal attachment	12†
Distal attachment	14
Aorta	10†
Iliac	4
Site not reported	1
Type II endoleak	2
Type III endoleak	11
Modular disconnection	5 (2‡)
Stent erosion through fabric	1
Details not reported	5
Leak present, source not reported	4

†Three patients met criteria for endotension (AAA enlargement in absence of detectable endoleak before AAA rupture). One had proximal leak shown at surgery. Another was classified as proximal leak on basis of known migration at proximal neck; however, no post rupture CT scan, surgery, or autopsy was found to verify this presumption. A third had initial increase in AAA diameter that remained stable until rupture from distal aortic endoleak. Endoleak was recognized in retrospect.

‡Associated fabric tear in Dacron graft wall and disruption of sutures attaching it to metal frame.

From: Bernhard VM, Mitchell RS, Matsumura JS, Brewster DC, Decker M, Lamparello P, Raithel D, Collin J. Ruptured abdominal aortic aneurysm after endovascular repair. *J VascSurg* 2002;35:1155-62.

**Table 7.** Causes of rupture (n = 44 of 47 patients; cause not reported in three patients).



Mortality rate in these cases was 57% (4/7) overall and 50% for surgical repair (3/6). In the 40 additional ruptures related to other devices, for a total of 47, the overall mortality rate for the combined series was 50%, with an operative mortality rate of 41%.

Ruptures after implantation of Guidant/EVT occurred in patients with tube grafts and all were a consequence of a type I endoleak developed at the distal aortic attachment site. Five occurred in 93 patients followed for a mean of 41.8 months and treated with first-generation tube graft, which were prone to develop attachment mechanism fractures. The remaining two ruptures occurred in the subgroup of 166 patients who received second-generation tube endografts.

No ruptures were reported in patients who received bifurcated or unilateral iliac devices, over a mean follow-up of 37.5 months.

Factors contributing to endoleak and postoperative rupture are reported in table 8.

Contributing factors	No. of patients with contributing factors
Loss of endograft integrity	16
Endograft migration	10
Severe angulation of proximal aortic neck	6
Dilatation of distal aortic neck after implant	5
Patient refused intervention for endoleak	5
Delayed or discontinued follow-up	4*
Surgical conversion delayed	4
Poor patient selection	3
Wide distal neck lined with clot	2
Iliac artery attachment site too wide	1
Short proximal aortic neck	2
Error in deployment technique	2
Stiff graft body design	2
Proximal neck thrombus	1
Short distal aortic neck	1
Low graft implantation	1
AAA shrinkage	1
Total	63

\*Two patients did not have CT scan for 11 months, although this delay was within prescribed time frame of investigational protocol.

Multiple contributing factors were reported in several patients; two in seven patients, three in seven patients, and five in two patients.

From: Bernhard VM, Mitchell RS, Matsumura JS, Brewster DC, Decker M, Lamparello P, Raithel D, Collin J. Ruptured abdominal aortic aneurysm after endovascular repair. *J Vasc Surg* 2002;35:1155-62.

**Table 8.** Factors contributing to endoleak and postoperative rupture (information reported for 34 of 47 patients).



In this investigation 9 out of 19 patients in which pre-rupture imaging was available suffered aneurysm rupture despite the absence of aneurysm enlargement. However most of these patients showed other abnormalities that could underlie a rupture.

Authors conclude that (1) the use of tube endografts should be restricted to the rare cases with ideal anatomy, no other alternatives and at high risk for open repair; (2) primary endoleaks have a tendency to early rupture, which entails the need to their treatment without delay; (3) prevention could be possible in some patients if there had been application of strict anatomic criteria for exclusion and rigorous adherence to prestabilted follow-up protocol; (4) outcomes of delayed aneurysm rupture after EVAR are similar to those expected for patients without prior endografts.

A study evaluating the AAA annual rupture risk in patients without detectable endoleak after EVAR (endotension) has been published in 2011 by Koole et al [23]. The basis for this analysis was 6337 patients who were enrolled prospectively in the EUROSTAR database between 1996 and 2006. Perioperative mortality rate of conversion to open AAA repair in these patients was also assessed.

In this study aneurysm enlargement was defined as a diameter increase  $\geq 8$  mm relative to the preoperative diameter measurements. Patients were divided into three groups depending on the degree of shrinkage or enlargement of the aneurysm sac. Group A included patients with  $> 8$  mm aneurysm shrinkage, group B consisted of patients with  $\leq 8$  mm shrinkage to  $\leq 8$  mm enlargement and group C presented an aneurysm enlargement of  $> 8$  mm. Ruptures occurred in 26 patients: 3/691 (0.4%) patients in group A, 14/5307 (0.32%) patients in group B and 9/339 (2.6%) patients in group C. The median interval to aneurysm rupture after EVAR was 48 months and the mortality rate from rupture was 62%.

The annual rate of rupture in group C was  $< 1\%$  in the first 4 years but increased to 7.5% up to 13.6% in the years thereafter (table 9), thus suggesting the need for conversion. The mortality rate of elective conversions to open repair was 6.0%. A significant higher conversion rate was observed in group C, compared with group A and B.

Year of FU	Combined FU <sup>a</sup> (years)	Ruptures (n)	Annual rupture rate (%)
1	264	0	0
2	206	1	0.5
3	149	0	0
4	102	0	0
5	67	5	7.5
6	37	0	0
7	22 3	1	3.6

FU, Follow-up; <sup>a</sup>Combined FU years were calculated for each interval.

From: Koole D, Moll FL, Buth J et al. Annual rupture risk of abdominal aortic aneurysm enlargement without detectable endoleak after endovascular abdominal aortic repair. *J VascSurg* 2011Dec;54(6):1614-22.

**Table 9.** An overview of the different annual rupture risks in group C.

The authors confirmed the role of aneurysm enlargement without detectable endoleak as an independent factor for conversion. Conventional CT angiography visualizing low-flow endoleaks with a blood-pool contrast agent, dynamic electrocardiographically gated CT angiography or MR angiography are suggested to possibly improve the sensitivity for detecting endoleaks [41-42], thus potentially resulting in a decreased mortality risk from rupture.

Interestingly in this study a large number of patients were lost to follow-up (50% in group A and B; 30% in group C). Consequently, a higher number of ruptures and a higher mortality could be imaginable.

In 2011 Metha et al [24] evaluated the frequency, etiology and outcomes of delayed AAA rupture following EVAR with the aim to establish treatment options that facilitated an improvement in survival. Over a mean follow-up of 29 months (range 14-111 months), 27 (1.5%) out of 1768 patients undergoing elective or emergent EVAR sustained delayed AAA rupture and required repair by either open surgical conversion or a redo endovascular treatment. Twenty (74%) patients were lost to follow-up, 17 (63%) patients had type I endoleak with stentgraft migration, 3 (11%) had type I endoleak without stent graft migration, 5 (19%) had type II endoleak and two (7%) experienced aneurysm rupture for undetermined causes. In 15 (55%) patients open surgical repair via retroperitoneal approach was performed, with partial (8 patients, 53%) or complete (7 patients, 47%) stentgraft explantation and aortoiliac reconstruction; 11 (41%) patients underwent a redo-EVAR and one (4%) patient refused treatment and died. Supraceliac aortic clamping was required in three (20%) patients, while supraceliac occlusion balloon was required in two (18%) patients during EVAR. There were three (11%) postoperative deaths: two after open conversion and one following EVAR.

Similar mortality rate are reported by other authors [43-45] despite the use of different techniques (midline vs retroperitoneal approach; supraceliac vs infrarenal vs aortic balloon clamping; complete or partial removal of the graft).

Interesting to note, in 2011 Venermo et al [46] reported that EVAR may reduce the risk of rupture and aneurysm-related mortality despite the presence of persisting proximal type I endoleak, compared to untreated AAA of similar size (11% vs 52%). However this study has some limitations, as it is retrospective, has small cohorts and the two groups are different not having being studied over the same time period or in the same geographic location. Moreover the EVAR group is likely to have received better medical treatment, with tighter blood pressure control and possible use of statins.

Age and sex are also different in this study while having an important impact on EVAR outcome. Suitability for EVAR was found to be associated with a lower rupture rate in unoperated aneurysms [47]. Therefore, knowing the aortic anatomy in the patients not undergoing EVAR would have been interesting.

## 6. Conclusion

In conclusion: the rupture risk for all EVAR patients is thought to be in the order of 0.5 to 1.2 per 100 patients per years [28,37] and it increases with age. Reasonably this is an underesti-

mated rupture rate as many patients are lost to follow-up and almost a few could have died because of aneurysm rupture.

Moreover, no precise description of the performed diagnostic examinations is provided and no fatal course is described in several publications; consequently, there may have been the possibility that many patients had a “symptomatic” AAA, instead of a ruptured one.

Relatively many ruptures occur between the follow up visits at 1 and 2 years after EVAR. An additional follow-up after 18 months may possibly reduce the AAA rupture rate. However, it is important to note that rupture can occur even for unknown reasons, despite an optimal protocol was followed.

The lesson learned when any major complication is found is that the underlying problem needs to be corrected whenever possible. Particularly, we agree with Chuter’s recommendation to treat primary type I endoleaks without delay [48].

Conversion to open repair should be seriously considered, particularly if the complication is not resolved and the patient is fit enough for this intervention.

However, the risk of this approach will need to be evaluated prospectively, as there is a high risk of rupture if patients are left untreated and an uncertain mortality risk by conversion to open repair [4-7,49-52].

Better stentgraft durability and longevity is also required to further reduce this serious complication. Prospective long-term evaluation of specific devices will also be necessary to determine the reliability of endograft exclusion, as well increasing using of statins as protective factors to prevent rupture [47]. Endovascular repair outside manufacturer’s instructions for use is associated with an unacceptable risk of proximal type I endoleak, aneurysm-related and all-causes mortality. Actually tube grafts should be limited to patients with ideal anatomy. In all other cases open surgery or use of fenestrated EVAR in short necks should be encouraged.

We strongly agree with Veith that until solution of these problems are found, EVAR will remain an imperfect long-term treatment with mortality rate for conversion in the setting of rupture remaining very high [53].

## Author details

Guido Regina<sup>1,4</sup>, Domenico Angiletta<sup>1,4</sup>, Martinella Fullone<sup>1,4</sup>, Davide Marinazzo<sup>1,4</sup>,  
Francesco Talarico<sup>2,3</sup> and Raffaele Pulli<sup>2</sup>

1 Department of Vascular Surgery, University of Bari, Italy

2 Department of Vascular Surgery, University of Florence, Italy

3 Department of Vascular Surgery, Palermo, Italy

4 VASA-MG (Vascular-endovascular Surgery Association of Magna Graecia), Italy

## References

- [1] Parodi JC, Palmaz JC, Barone HD. Transfemoral intraluminal graft implantation for abdominal aortic aneurysms. *Ann VascSurg* 1991;5: 491-9.
- [2] Zarins CK, White RA, Fogarty TJ. Aneurysm rupture after endovascular repair using the AneuRx stent graft. *J VascSurg* 2000;31:960-70.
- [3] Holzbein TJ, Kretschmer G, Thurnher S, et al. Midterm durability of abdominal aortic aneurysm endograft repair: a word of caution. *J VascSurg* 2001;33(2 Pt 2):46-54.
- [4] Harris PL, Vallabhaneni SR, Desgranges P, et al. Incidence and risk factors of late rupture, conversion, and death after endovascular repair of infrarenal aortic aneurysms: the EUROSTAR experience. European collaborators on stent/graft techniques for aortic aneurysm repair. *J VascSurg* 2000;32:739-49.
- [5] Ohki T, Veith FJ, Shaw P, et al. Increasing incidence of mid and long-term complications after endovascular graft repair of AAAs: a note of caution based on a 9-year experience. *Ann Surg* 2001;234:323-34.
- [6] Brewster DC, Cronenwett JL, Hallett JW Jr, Johnston KW, Krupski WC, Matsumura JS. Joint Council of the American Association for Vascular Surgery and Society for Vascular Surgery. Guidelines for the treatment of abdominal aortic aneurysms. Report of a subcommittee of the Joint Council of the American Association for Vascular Surgery and Society for Vascular Surgery. *J VascSurg* 2003;37:1106-17.
- [7] Brewster DC, Jones JE, Chung TK, Lamuraglia GM, Kwolek CJ, Watkins MT, et al. Long-term outcomes after endovascular abdominal aortic aneurysm repair: the first decade. *Ann Surg* 2006;244:426-38.
- [8] Hinnen JW, Koning OHJ, van Bockel JH, Hamming JF. Aneurysm sac pressure after EVAR: the role of endoleak. *Eur J VascEndovascSurg* 2007;34:432-41.
- [9] Schermerhorn ML, O'Malley AJ, Jhaveri A, Cotterill P, Pomposelli F, Landon BE. Endovascular vs. open repair of abdominal aortic aneurysm in the Medicare population. *N Engl J Med* 2008;358:464e74.
- [10] Konig GG, Vallabhneni SR, Van Marrewijk CJ, Leurs LJ, Laheij RJ, Buth J. Procedure-related mortality of endovascular abdominal aortic aneurysm repair using revised reporting standards. *Rev Bras Cir Cardiovasc* 2007;22:7e13.
- [11] Leurs LJ, Buth J, Laheij RJ. Long-term results of endovascular abdominal aortic aneurysm treatment with the first generation of commercially available stent grafts. *Arch Surg* 2007;142: 33e41.
- [12] Franks SC, Sutton AJ, Bown MJ, Sayers RD. Systematic review and meta-analysis of 12 years of endovascular abdominal aortic aneurysm repair. *Eur J VascEndovascSurg* 2007;33:154e71.

- [13] Sicard GA, Zwolak RM, Sidawy AN, White RA, Siami FS. Endovascular abdominal aortic aneurysm repair: long-term outcome measures in patients at high-risk for open surgery. *J VascSurg* 2006;44:229e36.
- [14] Zarins CK. The US AneuRx Clinical Trial: 6-year clinical update 2002. *J VascSurg* 2003;37:904e8.
- [15] Schermerhorn ML, Finlayson SR, Fillinger MF, Buth J, van Marrewijk C, Cronenwett JL. Life expectancy after endovascular versus open abdominal aortic aneurysm repair: results of a decision analysis model on the basis of data from EUROSTAR. *J VascSurg* 2002;36:1112e20.
- [16] Greenhalgh RM, Brown LC, Powell JT, et al; United Kingdom EVAR Trial Investigators. Endovascular versus open repair of abdominal aortic aneurysm. *N Engl J Med*. 2010;362(20):1863-71.
- [17] Prinssen M, Buskens E, Blankensteijn JD. The Dutch Randomized Endovascular Aneurysm Management (DREAM) trial. Background, design and methods. *J Cardiovasc Surg* 2002; 43(3):379-84.
- [18] Paraskevas KI, Mikhailidis DP, Veith FJ. Endovascular versus open repair of abdominal aortic aneurysms: interpreting the landmark United Kingdom EVAR-1 results. *J Endovasc Ther* 2010; 17(5):599-601.
- [19] Leurs LJ, Buth J, Harris PL, Blankensteijn JD. Impact of study design on outcome after endovascular abdominal aneurysm repair. A comparison between the randomized controlled DREAM-trial and the observational EUROSTAR-registry. *Eur J Vasc Endovasc Surg* 2007;33(2):172-6
- [20] Hobo R, Sybrandt JE, Harris P, Buth J. Endovascular repair of abdominal aortic aneurysms with concomitant iliac artery aneurysm. Outcome analysis of the EUROSTAR experience. *J Endovasc Ther*. 2008;15:12-22.
- [21] Szmids J, Galazka Z, Rowinski O, Nazarewski S, Jakimowicz T, Pietrasik K, Grygiel K, Chudzinski W. Late aneurysm rupture after endovascular abdominal aneurysm repair. *Interact Cardiovasc Thorac Surg*. 2007 Aug;6(4):490-4.
- [22] Wyss TR, Brown LC, Powell JT, Greenhalgh RM. Rate and predictability of graft rupture after endovascular and open abdominal aortic aneurysm repair: data from the EVAR Trias. *Ann Surg* 2010;252(5):805-12.
- [23] Koole D, Moll FL, Buth J et al. Annual rupture risk of abdominal aortic aneurysm enlargement without detectable endoleak after endovascular abdominal aortic repair. *J VascSurg* 2011Dec;54(6):1614-22.
- [24] Metha M, Paty PS, Roddy SP et al. Treatment options for delayed AAA rupture following endovascular repair. *J VascSurg* 2011Jan;53(1):14-20.



- [25] Mehta M, Sternbach Y, Taggert JB, Kreienberg PB, Roddy SP, Paty PS, Ozsvath KJ, Darling RC 3rd. Long-term outcomes of secondary procedures after endovascular aneurysm repair. *J Vasc Surg*. 2010 Dec;52(6):1442-9
- [26] De Bruin JL, Baas AF, Buth J, Prinssen M, Verhoeven EL, Cuypers PW, et al. DREAM study Group. Long-term outcome of open or endovascular repair of abdominal aortic aneurysm. *N Engl J Med* 2010;362:1881-9
- [27] Moll FL, Powell JT, Fraedrich G, et al. Management of abdominal aortic aneurysms clinical practice guidelines of the European society for vascular surgery. *Eur J Vasc Endovasc Surg* 2011;41(Suppl 1):S1-S58.
- [28] Conner MS 3rd, Sternbergh WC 3rd, Carter G, Tonnessen BH, Yoselevitz M, Money SR. Secondary procedures after endovascular aortic aneurysm repair. *J Vasc Surg* Nov 2002; 36(5):992-6
- [29] Ronsivalle S, Faresin F, Franz F, Rettore C, Zanchetta M and Olivieri A. Aneurysm Sac "Thrombization" and Stabilization in EVAR: A Technique to Reduce the Risk of Type II Endoleak. *J Endovasc Ther*. 2010; 17:4, 517-24.
- [30] Bernhard VM, Mitchell S, Matsumura JS, Brewster DC, Decker M, Lamparello P, Raithel D, Collin J. Ruptured abdominal aortic aneurysm after endovascular repair. *J Vasc Surg* 2002; 35:1155-62.
- [31] Kantonen I, Lepäntalo M, Brommels M, Luther M, Salenius J-P, Ylönen K. Mortality in ruptured abdominal aortic aneurysms. The Finnvasc Study Group. *Eur J VascEndovascSurg* 1999;17:208-12.
- [32] Schlösser FJV, Gusberg RJ, Dardik A, Lin PH, Verhagen HJM, Moll FL and Muhs BE. Aneurysm rupture after EVAR: can the ultimate failure be predicted? *Eur J VascEndovascSurg* 2009;37(1):15-22.
- [33] Acosta S, Ogren M, Bengtsson H, Bergqvist D, Lindblad B, Zdanowski Z. Increasing incidence of ruptured abdominal aortic aneurysm: a population-based study. *J VascSurg* 2006;44:237e43.
- [34] Wilmink AB, Hubbard CS, Day NE, Quick CR. The incidence of small abdominal aortic aneurysms and the change in normal infrarenal aortic diameter: implications for screening. *Eur J VascEndovascSurg* 2001;21:165e70.
- [35] Fransen GA, Vallabhaneni SrSR, Van Marrewijk CJ, Laheij RJ, Harris PL, Buth J. Rupture of infra-renal aortic aneurysm after endovascular repair: a series from EUROSTAR registry. *Eur J VascEndovascSurg* 2003;26:487e93.
- [36] Zarins CK, Crabtree T, Bloch DA, Arko FR, Ouriel K, White RA. Endovascular aneurysm repair at 5 years: does aneurysm diameter predict outcome? *J VascSurg* 2006;44:920e9.
- [37] Lifeline registry of EVAR publications committee. Lifeline registry of endovascular aneurysm repair: long-term primary outcome measures. *J VascSurg* 2005;42:1e10.

- [38] Peppelenbosch N, Buth J, Harris PL, van Marrewijk C, Fransen G. Diameter of abdominal aortic aneurysm and outcome of endovascular aneurysm repair: does size matter? A report from EUROSTAR. *J VascSurg* 2004;39:288e97.
- [39] Jones JE, Atkins MD, Brewster DC, Chung TK, Kwolek CJ, LaMuraglia GM, et al. Persistent type 2 endoleak after endovascular repair of abdominal aortic aneurysm is associated with adverse late outcomes. *J VascSurg* 2007;46:1e8.
- [40] Greenhalgh RM, Brown LC, Powell JT, et al; United Kingdom EVAR Trial Investigators. Endovascular repair of aortic aneurysm in patients physically ineligible for open repair. *N Eng J Med*. 2010;362(20):1872-80.
- [41] Cornelissen SA, Prokop M, Verhagen HJ, Adriaensen ME, Moll FL, Bartels LW. Detection of occult endoleaks after endovascular treatment of abdominal aortic aneurysm using magnetic resonance imaging with a blood pool contrast agent: preliminary observations. *Invest Radiol* 2010;45:548-53.
- [42] Cornelissen SA, Verhagen HJ, Prokop M, Moll FL, Bartels LW. Visualizing type IV endoleak using magnetic resonance imaging with a blood pool contrast agent. *J VascSurg* 2008;47:861-4.
- [43] Kelso RL, Lyden SP, Butler B, Greenberg RK, Eagleton MJ, Clair DG. Late conversion of aortic stent grafts. *J VascSurg* 2009;49:589-95.
- [44] Coppi, G., Gennai, S. & Saitta, G. Treatment of ruptured abdominal aortic aneurysm after endovascular abdominal aortic repair: A comparison with patients without prior treatment. *J VascSurg* 2009;49(3):582-8.
- [45] Lyden SP, McNamara JM, Sternbach Y et al. Technical considerations for late removal of aortic endografts. *J VascSurg* 2002;36:674-8.
- [46] Venermo MA, Arko III FR, Salenius JP, Saarinen JP, Zvaigzne A, Zarins CK. EVAR May Reduce the Risk of Aneurysm Rupture Despite Persisting Type Ia Endoleaks. *J EndovascTher*. Oct 2011.18(5): 676-682.
- [47] Powell JT, Brown LC, Greenhalgh RM, et al. The rupture rate of large abdominal aortic aneurysms: is this modified by anatomical suitability for endovascular repair? *Ann Surg*. 2008;247: 173-179.
- [48] Chuter TAM, Risberg B, Hopkinson BR, Wendt G, Scott AP, Walker PJ, et al. Clinical experience with a bifurcated endovascular graft for abdominal aortic aneurysm repair. *J Vasc Surg*. 1996;24:655-666.
- [49] Millon A, Deelchand A, Feugier P, et al. Conversion to open repair after endovascular aneurysm repair: causes and results. A French Multicentric Study. *Eur J VascEndovasc Surg*. 2009;38(4):429-434.
- [50] Pitoulas GA, Schulte S, Donas KP, et al. Secondary endovascular and conversion procedures for failed endovascular abdominal aortic aneurysm repair: can we still be optimistic? *Vascular* 2009;17(1):15-22.



- [51] *Dick F, Greenhalgh RM. Three-dimensional imaging for EVAR: importance of precise neck length and angulation. In: Greenhalgh RM, ed. Vascular and Endovascular Controversies Update. London, UK: BIBA Publishing; 2009: 189–195.*
- [52] *Brown LC, Greenhalgh RM, Powell JT, et al. Use of baseline factors to predict complications and re-interventions after endovascular aneurysm repair for abdominal aortic aneurysm. Br J Surg. 2010;97(8):1207–1217.*
- [53] *Veith FJ, Baum RA, Ohki T, Amor M, Adiseshiah M, et al. Nature and significance of endoleaks and endotension: Summary of opinions expressed at an international conference. J Vasc Surg 2002;35(5):1029-35.*