

We are IntechOpen, the world's leading publisher of Open Access books Built by scientists, for scientists

6,900

Open access books available

186,000

International authors and editors

200M

Downloads

Our authors are among the

154

Countries delivered to

TOP 1%

most cited scientists

12.2%

Contributors from top 500 universities



WEB OF SCIENCE™

Selection of our books indexed in the Book Citation Index
in Web of Science™ Core Collection (BKCI)

Interested in publishing with us?
Contact book.department@intechopen.com

Numbers displayed above are based on latest data collected.
For more information visit www.intechopen.com



Infective Conjunctivitis – Its Pathogenesis, Management and Complications

Adnaan Haq, Haseebullah Wardak and
Narbeh Kraskian

Additional information is available at the end of the chapter

<http://dx.doi.org/10.5772/52462>

1. Introduction

The aims of this chapter are to briefly discuss infective conjunctivitis, its subtypes and its treatment. Other forms of conjunctivitis will also be considered and discussed in this chapter, namely, neonatal conjunctivitis, conjunctivitis in the immunocompromised. A comprehensive assessment of the various treatments of conjunctivitis will also be discussed.

Conjunctivitis is a term broadly used to describe an inflammation of the conjunctiva. Conjunctivitis may be split into four main aspects; bacterial, viral, allergic and irritant. Infective conjunctivitis, namely bacterial and viral will be discussed in this chapter in details.

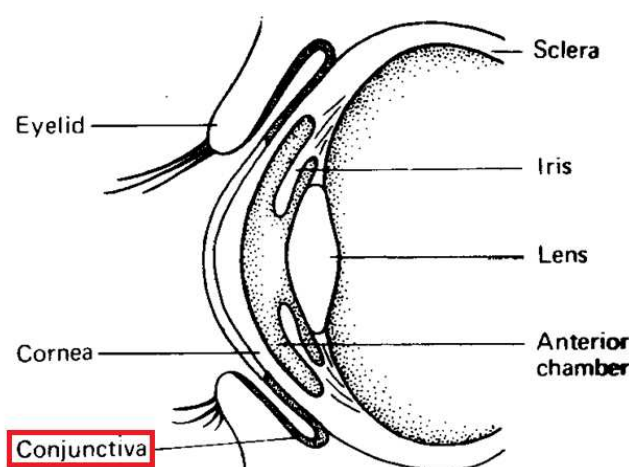


Figure 1. The conjunctiva in relation to the orbit and its structures

1.1. Anatomy of the conjunctiva

The conjunctiva is the fine mucous membrane which covers and joins the anterior surface of the eyeball to the posterior surface of eyelid. This translucent membrane lines the white part of the eye starting at the edge of the cornea (limbus) and runs behind the eye to cover the anterior part of the sclera. It then flows, loops forward, and forms the inside surface of the eyelids. At the medial canthus the conjunctiva fold thickens, which is called the semilunar fold.

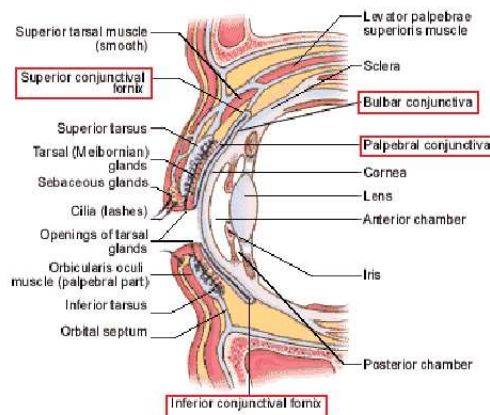


Figure 2. The different parts of the conjunctiva and its relation to other orbit anatomy

The conjunctiva is subdivided into three parts depending on location: palpebral conjunctiva, bulbar conjunctiva and conjunctival fornix. Histologically the conjunctiva is divided into three layers. From superficial to deep these are epithelial, adenoid and fibrous. These conjunctival layers contain a wide range of structures that includes glands, melanocytes, langerhans cells, mast cells and lymphoid tissue.

The arterial blood supply to conjunctiva is made up of branches of ophthalmic artery, the anterior and posterior conjunctival arteries. These are branches of anterior ciliary arteries and palpebral arcades respectively. The venous drainage follows the arteries. Posterior conjunctival veins drain the veins of the lid and anterior conjunctival veins drain anterior ciliary vein to ophthalmic vein.

The lymphatic drainage of the conjunctiva depends on the region of the conjunctiva. Lymphatics in palpebral region drain into the lymphatics of eyelids. In bulbar conjunctiva, lymphatics from lateral side drain into the superficial preauricular lymph nodes & lymphatics from medial side drain to deep sub maxillary nodes.

The first division of the trigeminal provides nerve supply to the conjunctiva.

1.2. Allergic and irritant conjunctivitis

Before discussing the major contents of the chapter, it is necessary to briefly discuss allergic and irritant conjunctivitis.

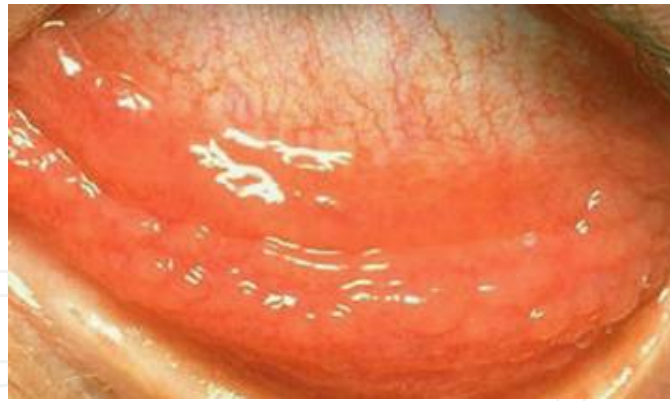

Figure 3. Allergic conjunctivitis- look for follicles and papillae which are characteristic of allergic conjunctivitis

Allergic conjunctivitis is seen in two acute disorders; seasonal allergic conjunctivitis (which is prevalent in the summer months) and perennial allergic conjunctivitis (which presents intermittently) and three chronic disorders, vernal keratoconjunctivitis, atopic keratoconjunctivitis and giant papillary conjunctivitis. Allergic conjunctivitis is considered to be a type I hypersensitivity reaction. Its treatment is largely supportive, although in severe cases, topical corticosteroids may be of some benefit 1.

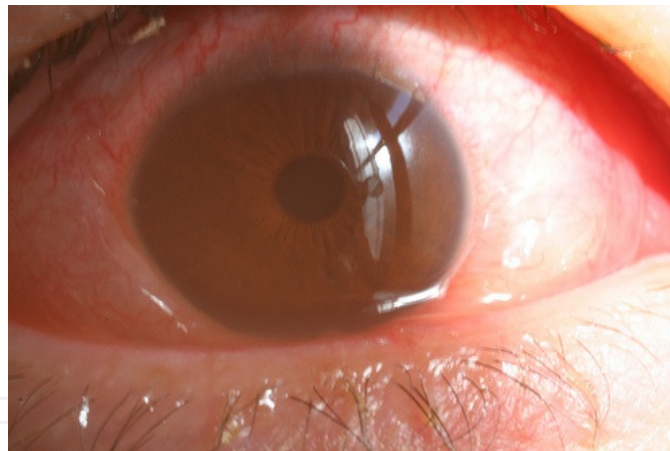

Figure 4. Irritant conjunctivitis- generalised redness around the eye and constant tearing are typical features

Irritant conjunctivitis is a form of conjunctivitis that is often brought on by an external source. The source, considered an 'irritant', directly affects the conjunctiva, causing an inflammatory response. Not all causes of irritant conjunctivitis are external however. Causes of irritant conjunctivitis are vast, though some of the more common causes are hair products (e.g. shampoos), smoke or fumes, chlorinated water used in swimming pools. A common non-external source is trapped eyelashes, which continually irritate the conjunctiva. Treatment of irritant conjunctivitis is thorough cleansing of the eye and removing the irritant.

2. Infectious conjunctivitis

Infective conjunctivitis can be caused by several bacterial and viral pathogens. Infective conjunctivitis can be further differentiated into acute infective conjunctivitis, defined as inflammation of the conjunctiva due to infection that does not last longer than 3 weeks, and chronic conjunctivitis, inflammation of the conjunctiva that lasts longer than 3 weeks.

In the developed world, acute infectious conjunctivitis is a common presentation in the primary care setting, accounting for up to 2% of consultations with the general practitioner [2]. Many general practitioners find it difficult to differentiate between bacterial and viral conjunctivitis. The uncertainty of the pathogenic cause of acute conjunctivitis has led to the routine practice of prescribing a broad spectrum antibiotic topically even though the pathogen has not been proved to be bacterial in nature. In the UK, approximately 3.4 million topical antibiotic prescriptions are issued every year, at a cost to the NHS of over £4.7 million [3].

A diagnosis of conjunctivitis is usually made on the basis of a clinical history and examination by the clinician. Other investigations of conjunctivitis, such as swabs and cultures of the conjunctiva are rarely performed as it often delays treatment and has very little prognostic benefit, as conjunctivitis is often a self limiting illness and the antibiotics currently used have a good spectrum of pathogen coverage. Swabs and cultures are mainly used in research purposes.

It is vital that a correct diagnosis is made to early to identify the cause and start treatment promptly. It is also essential to rule out more serious causes and medical emergencies that would require hospital admission. Such cases would include bacterial keratitis, acute closed angle glaucoma, corneal abrasions and others.

2.1. Bacterial conjunctivitis

Bacterial conjunctivitis is a relatively common infection and affects all people, although a higher incidence is seen in infants, school children and the elderly. Bacterial conjunctivitis has a higher prevalence in children, where a recent study by Rose et al identified 67% of 326 children as having a bacterial cause [4]. Although its incidence is continuing to decrease in developing nations, periodic rises in incidence are seen during the monsoon seasons in many countries such as Bangladesh, and thus, bacterial conjunctivitis is the most common cause of infective conjunctivitis in developing nations.

2.1.1. Types of bacterial conjunctivitis and pathogenic causes of bacterial conjunctivitis

Bacterial conjunctivitis can be broadly split into three major categories; hyperacute bacterial conjunctivitis, acute conjunctivitis and chronic conjunctivitis.

- Hyperacute bacterial conjunctivitis is commonly seen in patients affected with *N. Gonorrhoea*. The onset is often rapid with an exaggerated form of conjunctival injection, chemosis and copious purulent discharge. Prompt treatment is essential to prevent complications.

- Acute bacterial conjunctivitis is the most commonly seen bacterial conjunctivitis and often presents with a typical presentation, time course and prognosis. In a study done by Weiss et al, the most common pathogens in acute bacterial conjunctivitis were *Staphylococcus aureus*, *Haemophilus influenzae*, *streptococcus pneumoniae*, and *Moraxella catarrhalis*, whereas in an older study done by Gigilotti et al, *Chlamydia trachomatis* was also commonly found in infected patients [5, 6].
- Chronic bacterial conjunctivitis, ie, red eye with purulent discharge persisting for longer than a few weeks, is generally caused by *Chlamydia trachomatis* or is associated with a nidus for infection such as in dacryocystitis [7].

In certain bacterial conjunctivitis, it is essential to identify a pathogen. As mentioned, most causes of conjunctivitis are diagnosed and treated on a clinical exam basis, but in patients who are particularly susceptible such as neonates or immunodeficient patients, a microbiological diagnosis must be made to exclude harmful pathogens such as *N.gonorrhoeae*, *Listeria monocytogenes*, *Corynebacterium diphtheriae* and certain members of the *Haemophilus* group. These pathogens contain proteolytic enzymes which may cause long term damage to the parenchyma of the conjunctiva.

2.1.2. Signs and symptoms of bacterial conjunctivitis

Although the symptoms of bacterial conjunctivitis are varied and quite vast, there are a number of key symptoms which differentiate it from other eye infections. Thick purulent discharge is seen as the major symptom that affects sufferers of bacterial conjunctivitis, compared to the watery discharge seen in viral conjunctivitis. This leads to 'glue eye' which is often the term used to describe difficulty opening the eye due to thick sticky secretions. A study done in 2004 in the Netherlands confirmed that 'early morning glue eye' was a positive predictor of bacterial conjunctivitis amongst 184 patients presenting with 'glue eye', itch or a past history of conjunctivitis [8].

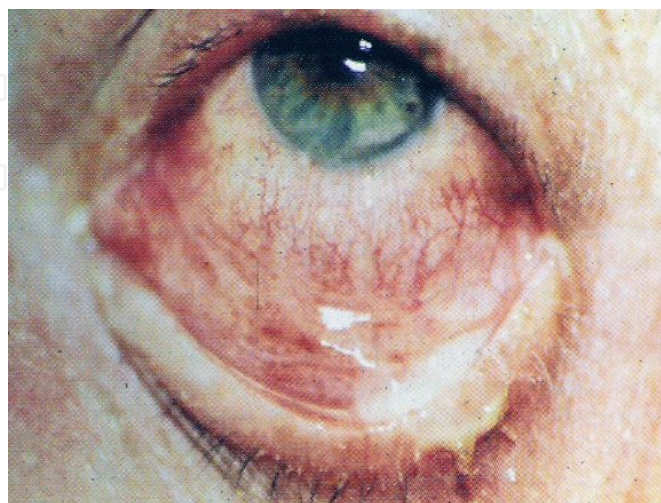

Figure 5. Mucopurulent discharge seen in bacterial conjunctivitis

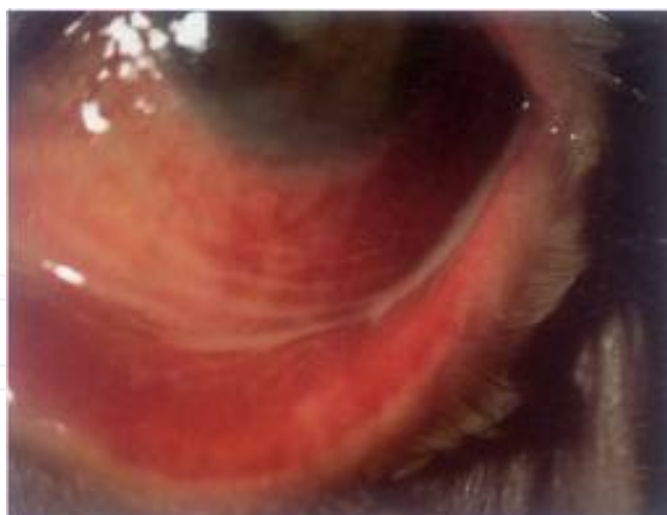


Figure 6. Injection of the conjunctiva and chemosis are two common symptoms and are demonstrated here

Other symptoms which are commonly seen in bacterial conjunctivitis is a 'foreign body' sensation, injection of the conjunctiva, chemosis (conjunctival oedema), itching, erythema of the eyelid skin and some patients also experience a slight burning or stinging sensation. In studies done by Carr et al and Wall et al almost all patients presented with injection of the conjunctiva, up to 90% of patients with bacterial conjunctivitis presented with itching and a foreign body sensation and up to 50% of patients presented with a burning or stinging sensation [9, 10]. Erythema of the eyelid was seen in 85% of patients.

2.1.3. Complications of bacterial conjunctivitis

Bacterial keratitis is a well known but rare complication of bacterial conjunctivitis [11]. People at particularly high risk of developing keratitis often have corneal epithelial defects or disease and patients who have particularly dry eyes are seen to be at an increased risk.

2.1.4. Treatment of bacterial conjunctivitis

Bacterial conjunctivitis is commonly treated empirically with broad-spectrum antibiotics. Broad-spectrum antibiotics that have good efficacy against both gram-negative and gram-positive are necessary as a diverse range of pathogens can be the cause of infections. A Cochrane systematic review found that acute bacterial conjunctivitis is often a self-limiting condition, 65% (95% confidence interval of 59% to 70%) patients treated with placebo showed significant improvement occurring by the second to fifth day of infection [12]. Patients treated with topical antibiotics were shown to have improved clinical outcome, especially when treated early (days 2 to 5) with relative risk = 1.24, 95% confidence interval = 1.05 to 1.45. Patients treated late (days 7 to 10) had reduced clinical benefit with relative risk = 1.11, 95% confidence interval = 1.02 to 1.21. Microbiological remission was also improved with treatment, early (days 2 to 5) showing relative risk = 1.77, 95% confidence interval = 1.23 to 2.54 and late (days 7 to 10) relative risk = 1.56, 95% confidence interval = 1.17 to 2.09.

An open, randomized and controlled study by Everitt et al investigated 307 adults and children with suspected infective conjunctivitis using three different treatment methods: no treatment, delayed topical treatment and immediate topical chloramphenicol treatment [13]. The varying treatments did not affect the severity of symptoms experienced within the first three days of infection. However, patients with moderate symptoms who were treated immediately with topical chloramphenicol had a reduced duration of symptoms with an average of 3.3 days whilst patients that received no treatment had 4.9 days duration.

Rietveld et al carried out a double-blind randomized and placebo controlled study in a primary care setting. The efficacy of fusidic acid gel was compared to a placebo gel in 163 adult patients presenting with a red eye and mucopurulent discharge [14]. After 7 days the treatments were evaluated with clinical cure being found in 62% of patients on fusidic acid gel and 59% of patients on placebo gel. The study found that the severity of symptoms and the duration of symptoms were not significantly different in either group. In conclusion, with the limited evidence the authors produced, they did not support the current practice of prescribing empirical antibiotics.

The majority of doctors actively treat uncomplicated acute bacterial conjunctivitis with empirical topical antibiotics at diagnosis. There are several other options available including: delaying treatment for 5 days and begin treatment if no sign of improvement and to treat patients who have clinical features associated with a bacterial cause. Studies comparing the effectiveness of different antibiotics recommended for use in suspected bacterial conjunctivitis have shown similar levels of effectiveness. Therefore, it is important to consider local bacterial resistance and cost-effectiveness of the antibiotics being prescribed [15]. All antibiotic courses should be taken for 7-10 days. Compliance with the length of time the antibiotics are prescribed for is particularly important to help prevent resistance developing.

The first line treatment in mild to moderate bacterial conjunctivitis is either Trimethoprim-Polymyxin B (Polytrim) solution, Erythromycin 0.5% ointment, or Azithromycin drops. Alternatives to these antibiotics are bacitracin ointment and sulfacetamide drops. In moderate to severe infections, or antibiotic-resistant infections and in immunocompromised patients, fluoroquinolones are recommended. These include: ofloxacin, ciprofloxacin, levofloxacin, moxifloxacin and gatifloxacin. Chlamydial conjunctivitis requires oral antibiotics alongside a topical antibiotic to treat the systemic infection alongside the ophthalmic manifestation. The oral antibiotic options include Azithromycin, doxycycline, or erythromycin. These are given in combination with Azithromycin or erythromycin drops for 2 to 3 weeks [16]. In addition, patients should be advised to take several precautions to help prevent spread of infection. Patients should wash their hands regularly and thoroughly, especially after touching any infected secretions. Furthermore, patients should avoid sharing towels, pillows, or utensils.

Studies have shown that treatment with topical antibiotics shortens the duration of disease, prevents spread of infection, reduces the rate of recurrence, and decreases the risk of complications that affect vision [17]. However, there has been controversy in recent years over the use of empirical antibiotics and its role in an evidently self-limiting disease with the clinical outcome being only marginally favourable to taking no antibiotics. There has been increasing antibiotic resistance especially among the older class of antibiotics that have been

used extensively such as chloramphenicol, sulphonamides, polymyxins, bacitracin, aminoglycosides and early generation fluoroquinolones. The efficacy of these drugs has reduced to a combination of resistance and narrow spectrum of activity [18, 19]. The newer generation of fluoroquinolones, such as gatifloxacin and moxifloxacin, have a greater range of activity and efficacy against common pathogens of the eye [20]. Specifically, they have better *in vitro* efficacy over the older generation fluoroquinolones against gram positive pathogens. However, the efficacy was not greater with *Haemophilus influenza* isolates [21]. The Ocular Tracking Resistance in the U.S. Today (TRUST) initiative annually monitors the *in vitro* susceptibility of common ocular pathogens; *Staphylococcus aureus*, *Streptococcus pneumoniae*, and *Haemophilus influenzae*. Between 2000 and 2005 there was a 12.1% increase in the incidence of methicillin-resistant *Staphylococcus aureus* (MRSA). Moreover, greater than 80% of the MRSA strains were also resistant to fluoroquinolones [22, 23].

2.1.5. Prognosis of bacterial conjunctivitis

The prognosis of bacterial conjunctivitis is normally very good with the correct and prompt treatment of the infection. In many cases, spontaneous remission, without a cure, is seen. In a study done by Sheikh and Hurwitz et al, spontaneous cure occurred in 60% of patients within 1-2 weeks [24]. However, with prompt antibiotic treatment, the treatment time is significantly reduced.

2.2. Viral conjunctivitis

Viral conjunctivitis is a common infection amongst the Western population, and is often associated with other infections around the body. Due to the contiguity with the respiratory tract anatomy, viral upper respiratory tract infections are a common cause of secondary viral conjunctivitis.

Most cases of viral conjunctivitis are mild. Days 3-5 of infection are often the worst, but the infection will usually clear up in 7-14 days without treatment and without any long-term consequences. In some cases, viral conjunctivitis can take 2-3 weeks or more to clear up, especially if complications arise.

2.2.1. Pathogens causing viral conjunctivitis

Much unlike bacterial conjunctivitis, there are many pathogens associated with viral conjunctivitis, although the majority of cases of viral conjunctivitis are encompassed by a few common pathogens. The specific viruses are much dependant on the geographical area in the world. In a study done in the Far East countries of Japan, Korea and Taiwan the most common pathogens isolated from 1105 cases were *adenovirus 8* and *enterovirus 70*. Other viruses also identified were *adenoviruses 19* and *37* [25]. Similarly, the causes of viral conjunctivitis in the Western countries are mainly *adenoviruses*, though *adenovirus 13* seems to be the dominant strain in these countries.

Other rarer causes of viral conjunctivitis include *herpes simplex virus*, *herpes zoster virus* and the *measles virus*. Although less commonly seen, it is essential to identify *herpes* and *measles*

viruses early to ensure prompt treatment, to prevent any long term complications associated with these viruses.

A recent study also showed outbreaks of the *avian influenza* viruses in patients, although this may possibly be linked to the recent outbreaks of the virus in humans.

2.2.2. Signs and symptoms of viral conjunctivitis

As with bacterial conjunctivitis, a diagnosis of viral conjunctivitis is often made by the general practitioner on the basis of a history and examination. However, due to the overlap in symptoms between viral and bacterial conjunctivitis, it is often difficult to ascertain viral from bacterial conjunctivitis.

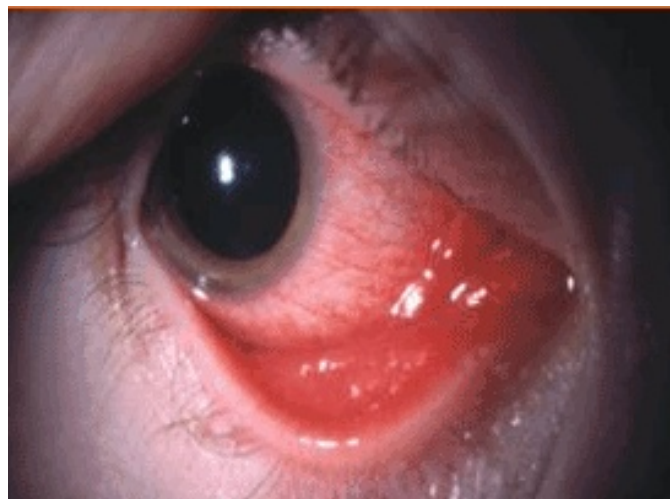

Figure 7. Classical 'pink' eye associated with conjunctival injection seen in viral conjunctivitis

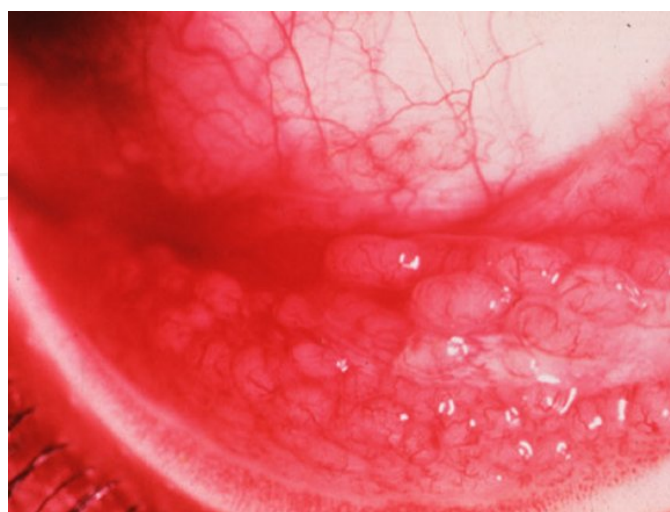


Figure 8. Classical follicles seen in the conjunctiva in a patient suffering from herpetic conjunctivitis

The key symptom of viral conjunctivitis is ‘pink eye’. This shows a fine, diffuse pinkness of the conjunctiva, which is often easily mistaken for the ciliary injection of iritis. Other symptoms associated with viral conjunctivitis include discharge which is often clear and watery. This is often the most discernible difference between bacterial and viral conjunctivitis.

A history of itchy eyes is also suggestive of viral conjunctivitis, although it is a symptom also associated with irritant and allergic conjunctivitis. Rarer symptoms associated with simple *adenovirus* viral conjunctivitis include foreign body sensation, ocular discomfort, excessive tearing and sticky eyelids which are worse in the morning.

Herpes simplex conjunctivitis is usually unilateral. Symptoms include a red eye, photophobia, eye pain and mucoid discharge. There may be periorbital vesicles, and a conjunctival branching (dendritic) pattern of fluorescein staining makes the diagnosis.

Below is a table summarising the key differences between adenoviral and herpetic viral conjunctivitis.

Adenoviral	Herpetic
Watery discharge bilaterally	Usually unilateral watery discharge
Hyperaemia	Diffuse hyperaemia
Petechial hemorrhages	Vesicular eruptions on eyelid
Punctate keratitis	Follicles
Preauricular and/or submandibular lymphadenopathy	Occasional preauricular lymphadenopathy
Serous, mucoid, or mucopurulent discharge	Serous mucoid discharge
Associated with pharyngitis	Major complication of dendritic epithelial keratitis

Table 1. A summary of the differences of adenoviral and herpetic viral conjunctivitis

Herpes zoster Ophthalmicus is shingles of the ophthalmic branch of the trigeminal nerve, which innervates the cornea and the tip of the nose. It begins with unilateral neuralgia, followed by a vesicular rash in the distribution of nerve. Once spread to the eye, it may lead to an extremely painful conjunctivitis and may take several days to settle.

2.2.3. *Complications of viral conjunctivitis*

There are many recognised complications of viral conjunctivitis. In many cases, it may be associated with inflammation of the cornea, known as keratoconjunctivitis. There is also an increase in likelihood of a superimposed bacterial infection. Other rare complications associated with viral conjunctivitis include blepharitis, entropion and in very rare cases, scarring of the eyelid.

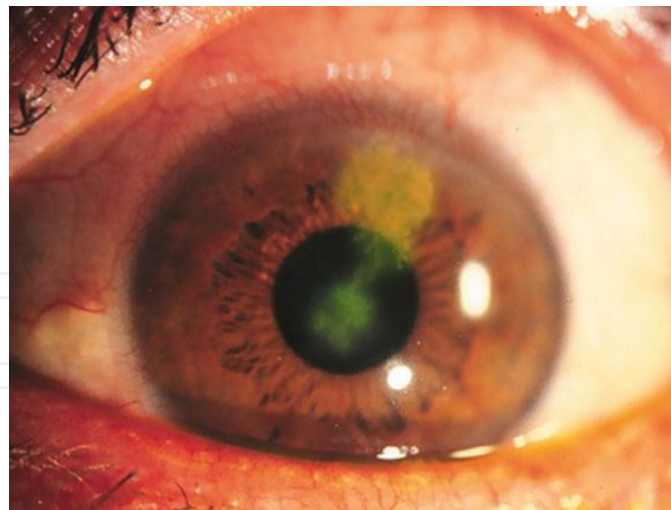


Figure 9. Herpes simplex keratitis, demonstrated here via fluorescein staining

The most serious complication of viral conjunctivitis is *herpes simplex* keratitis, a corneal ulcer, which can ultimately lead to blindness. This is an extremely rare side effect of viral conjunctivitis and requires immediate transfer to hospital and review by the ophthalmologists.

2.2.4. Treatment of viral conjunctivitis

Viral conjunctivitis is a self-limiting disease that usually resolves within two weeks of onset of symptoms and does not require treatment with antiviral medication. There is no evidence supporting the use of anti-viral medication and their efficacy has not been proven. However, as a highly contagious disease, there is a need to make infected patients aware of good hygiene practices to prevent further spread. Viral conjunctivitis is transmitted through direct contact, therefore, hands should be thoroughly washed regularly, and infected patients should not share pillows, towels and other utensils [26]. The highly contagious nature of viral conjunctivitis, especially adenovirus, makes it necessary for infected patients to avoid going to work or school for 5 days to 2 weeks. Contagiousness of adenovirus conjunctivitis has been shown to be reduced in an *in vitro* study using the topical anti-viral agent povidone-iodine. Povidone-iodine at a concentration of 1:10 (0.8%) is particularly effective against free adenovirus, eradicating all of them within 10 minutes with little cytotoxicity [27]. In addition, patients with contact lenses should avoid using them until the conjunctivitis resolves and last dose of any treatment having been taken over 24 hours ago [28]. Treatment for viral conjunctivitis is supportive, involving cold compresses, ocular decongestants, and artificial tears for symptomatic relief. In patients with high susceptibility of contracting bacterial infections an antibiotic may be given to prevent a bacterial superinfection occurring. If a pseudomembrane or corneal subepithelial infiltrates develop then a topical corticosteroid may be given alongside the other non-pharmacological treatments outlined earlier. Immediate referral to an ophthalmologist should be considered in patients with a pseudomembrane or corneal subepithelial infiltrate. Immediate referral is necessary in patients with hyperacute conjunctivitis or those who have corneal involvement including ulceration and herpetic keratitis.

2.2.5. Prognosis of viral conjunctivitis

Viral conjunctivitis is extremely contagious and remains so for 14 days, which also is often how long the symptoms remain.

The prognosis is very good for viral conjunctivitis. It resolves completely within 2 weeks of the 'pink eye' onset and there are rarely any long term complications or problems associated with viral conjunctivitis [29].

3. Conjunctivitis in the immunocompromised

Conjunctivitis in the immunocompromised is something that is often overlooked by the general practitioner. However, it is essential to properly investigate conjunctivitis in immunodeficient patients as they are more likely to suffer from long term complications such as dendritic ulcers and corneal damage.

3.1. Epidemiology and conjunctival microvascular disease associated with HIV

Up to 75% of HIV infected patients have suffered from conjunctivitis. Most will exhibit microvascular changes of the conjunctiva, often the inferior perilimbal bulbar conjunctiva. These changes are often seen as capillary dilations, short irregular vessels and a granular appearance of blood column within the vessels.

In some cases, there have been reports of direct infiltration of the vascular endothelial cells of the conjunctiva being infiltrated by the HIV virus, which causes a deposition of immune complexes within the conjunctiva, causing conjunctivitis.

3.2. Infections causing conjunctivitis in the immunocompromised

Most conjunctivitis reports in the immunocompromised, especially HIV, have shown *staphylococci* to be the main infective agent, with *coagulase negative staphylococci* (mostly *staphylococcal epidermidis* the majority) accounting for most of the cases. The major other normal flora organism which cause infection in immunocompromised patients include *cornyobacterium pseudo/diphthericum* (found in the nasopharynx) and certain members of the *Haemophilus* group. Isolated cases of *neisseriameningitidis* and the *measles* virus have also been found in immunocompromised patients, although no study has yet shown a direct link between these two organisms and conjunctivitis in the immunocompromised.

Opportunistic infections may also cause conjunctivitis. Below are common pathogens that have been identified as opportunistic infections causing conjunctivitis:

- Microsporidial keratoconjunctivitis- Reports of microsporidial keratoconjunctivitis in AIDS patients have been noted. This infection is caused by an intracellular protozoan parasite of the phylum *Microspora*. Patients affected with Microsporidial keratoconjunctivitis experience similar symptoms as with any other bacterial infection, but the symptoms of

photophobia and extreme redness are also present. There may also be bilateral conjunctival hyperaemia with diffuse coarse white infiltrates, conjunctival hypertrophy and erosions of the corneal epithelium [30].

Microsporidial keratoconjunctivitis should not be overlooked in HIV patients because it rarely responds to conventional topical antivirals or antibacterials. In some cases, antiprotozoal medication has also been reported as ineffective. A recent study found that Fumagillin (Fumidin B) is the treatment with most positive outcome in HIV patients with Microsporidial keratoconjunctivitis [31].

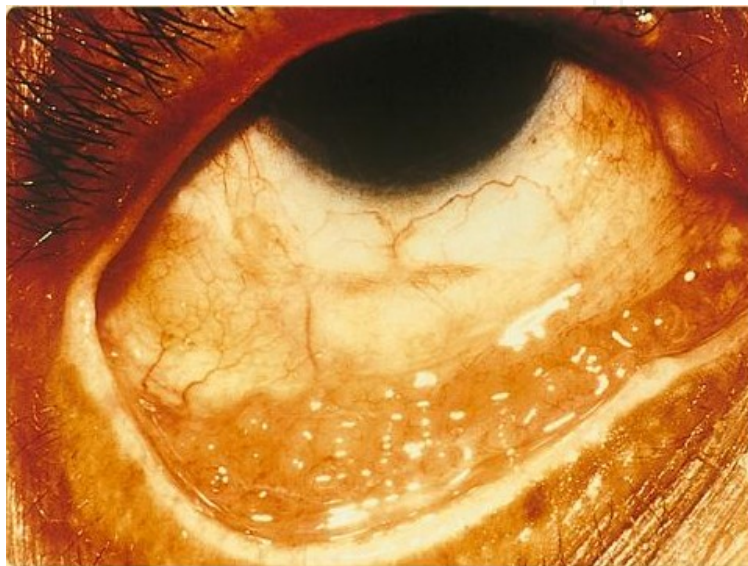

Figure 10. Conjunctivitis in a patient suffering from AIDS

- Molluscum contagiosum-Although rarely affecting the conjunctiva even in immunocompromised individuals, molluscum contagiosum has been noted to primarily affect the conjunctiva and also cause secondary conjunctival inflammation during infection. In one case report, a nodule of molluscum contagiosum was noted on the bulbar conjunctiva on a 34 year old man with AIDS [32]. However, in most cases of patients in an immunocompromised state with molluscum contagiosum, the conjunctiva is secondarily affected, causing an associated follicular conjunctivitis [33].

Treatment of primarily conjunctival infection of molluscum contagiosum is via cryotherapy and/or surgery, although this has shown to provide only limited long term correction in HIV patients.

- Fungal infections- Fungal infections affecting the conjunctiva are rare. In immunocompromised patients, the cornea is often affected, causing a keratitis to develop. This can however, cause a secondary conjunctivitis. Studies have shown that *Cryptococcus* and *Candida albicans* are the most common pathogens affecting the cornea and conjunctiva in immunocompromised patients.

Fortunately, the treatment is very effective for fungal infections. Although hospital admission is required in patients affected with keratitis, topical amphotericin B or natamycin, subconjunctival miconazole and oral ketoconazole are proven effective antifungals.

4. Neonatal conjunctivitis

Neonatal conjunctivitis also known as ophthalmia neonatorum is inflammation of the conjunctiva occurring in the first month of life. This condition is caused by a number of different pathogens. These include bacteria, viruses and chemical agents. In recent times prophylaxis has led to decreased morbidity in the developed world. However, it is still a significant cause of ocular morbidity, blindness and even death in the developing world.

4.1. Epidemiology of neonatal conjunctivitis

The incidence of ophthalmia neonatorum is dependent on many different factors. The main risk factor for ophthalmia neonatorum of infective origin is the presence of a sexually transmitted disease in the mother. The organism usually infects the neonate through direct contact as it passes through the birth canal. Therefore, incidence is high in areas with high rates of sexually transmitted disease [34]. Prolonged rupture of membranes at the time of delivery is also thought to increase the risk of infection. It is also dependent on socioeconomic factors; incidence varies in highly developed countries with good prenatal care compared to the developing parts of the world [35]. The offending pathogens vary geographically due to the differences in the prevalence of maternal infection and the use of prophylaxis. In US and Europe the incidence has been reported 1-2% depending on the socioeconomic character of the area. However in other parts of the world the incidence is reported to be as high as 17%. In recent studies in Pakistan the incidence has been 17% and in Kenya as high 23% [36, 37].

There has been a sharp decrease in the incidence of ophthalmia neonatorum in the past few decades in the developed countries due to many reasons. In 1800s, prophylaxis (silver nitrate) for ophthalmia neonatorum in the developed countries was used for the first time. Since then there has been gradual decrease in incidence. Better prenatal care has also led to detection and treatment of sexually transmitted diseases hence reduction in the risk of transmission to new-borns during birth.

4.2. Aetiology of neonatal conjunctivitis

Ophthalmia neonatorum can be broadly divided into two types, septic and aseptic. The aseptic type (chemical conjunctivitis) is generally secondary to the instillation of silver nitrate drops for ocular prophylaxis. Septic neonatal conjunctivitis is mainly caused by bacterial and viral infections. Causes include [38]:

From maternal genital tract:

- Bacterial
 - *Neisseria gonorrhoeae*
 - *Chlamydia trachomatis*
 - Group B beta-haemolytic streptococci
- Viral
 - Herpes Simplex Virus (HSV)

From cross infection:

- *Staphylococcus aureus*
- Coliforms
- *Pseudomonas aeruginosa*

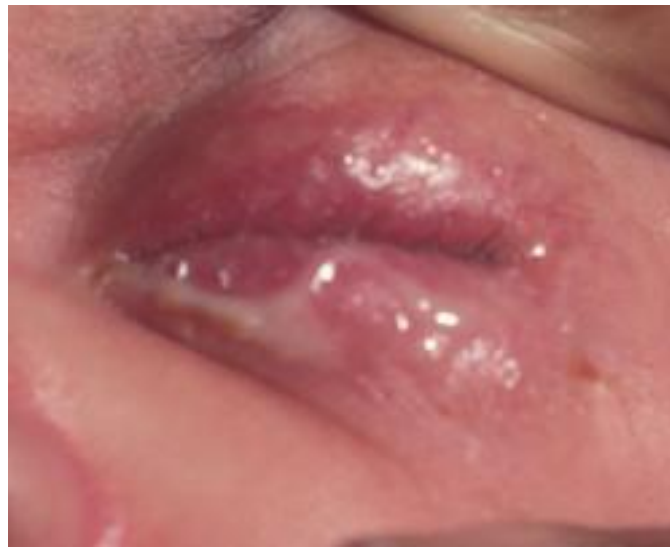

Figure 11. A neonate suffering from gonococcal conjunctivitis

Neisseria gonorrhoeae - Congenital gonorrhoea infection is acquired intrapartum and it leads to ophthalmia neonatorum. *Gonococcal* ophthalmia neonatorum presents with a severe conjunctivitis and keratitis usually in the first 48 hours of life but it can be delayed up to 3 weeks. It is frequently bilateral. If untreated, it can lead to blindness. Systemic infection can cause meningitis, arthritis and sepsis.

Chlamydia trachomatis - Also known as trachoma-inclusion conjunctivitis or TRIC. This is usually a benign, self-limiting, suppurative conjunctivitis due to *Chlamydia trachomatis* - serotypes D-K. Onset occurs around 1 week of age. Onset maybe earlier with premature rupture of membranes. It is characterised by mild swelling, hyperaemia and minimal to moderate discharge.

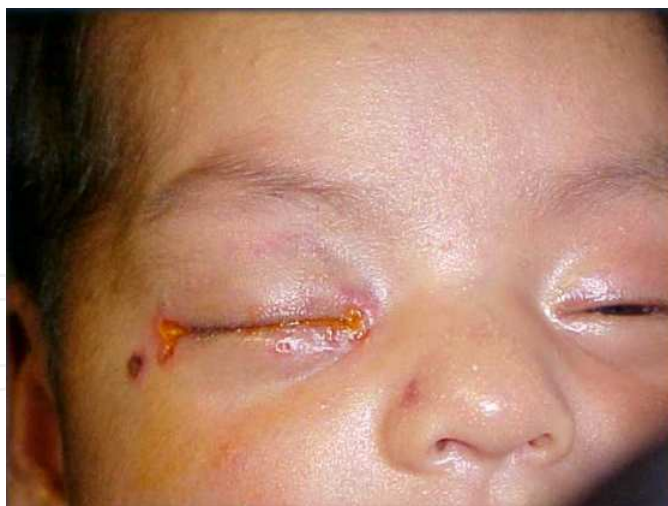

Figure 12. Typical presentation of a neonate suffering from herpetic conjunctivitis

Other bacteria -These bacteria make up 30-50% of all cases of neonatal conjunctivitis. The most commonly identified gram-positive organisms include *Staphylococcus aureus*, *Streptococcus pneumoniae*, *Streptococcus viridans*, and *Staphylococcus epidermidis*. Gram-negative organisms, such as *Escherichia coli*, *Klebsiella pneumoniae*, *Serratia marcescens*, and *Proteus*, *Enterobacter*, and *Pseudomonas species*, also have been implicated.

Herpes Simplex- Herpes simplex virus (HSV) can cause neonatal keratoconjunctivitis. This is a rarer form of ophthalmia neonatorum presenting in the second week of life and can be associated with a generalized herpes simplex infection.

Chemical Conjunctivitis- Classically, the most common cause of neonatal conjunctivitis is due to use of post-delivery use of ophthalmic silver nitrate used in the prophylaxis of ocular *Gonococcal* infections. There is a mild irritation, tearing and redness in a baby who has been administered prophylactic silver nitrate (used for the prevention of gonorrhoeal infection) within the preceding 24-48 hours. The incidence of chemical conjunctivitis in the United States has significantly decreased since replacement of silver nitrate with erythromycin ointment.

4.3. Presentation of neonatal conjunctivitis

Babies present with unilateral or bilateral purulent, mucopurulent or mucoid discharge from the eyes within the first month of life. Injected conjunctiva and lid swelling may also be present. There may be associated systemic infection.

- Bacterial conjunctivitis - often have a longer incubation period than for the other infective causes. Presenting with a sub-acute onset between the 4th and 28th day of life. Depending on the pathogen, there may be a mixed picture of a red eye with lid swelling and a varying amount of purulent discharge. Specific types of bacterial infection:

- *Chlamydial* infection - 5 to 14 days after birth (some report up to 28 days after birth): unilateral/bilateral watery discharge which becomes copious and purulent later on. There may be associated preseptal cellulitis and, less commonly, rhinitis, otitis and pneumonitis.
- *Gonorrhoeal* infection - typically 1-5 days after birth but may occur later: hyper-acute conjunctival injection and chemosis, lid oedema and severe purulent discharge. There may be associated corneal ulceration and perforation.
- Viral conjunctivitis
- The onset is acute usually 1-14 days after birth: unilateral/bilateral serosanguinous discharge \pm vesicular skin lesions. Uncommonly it can also lead to systemic infection.

4.4. Differential diagnosis of neonatal conjunctivitis

Every other potential cause of red eye needs to be excluded. The differentials include [39]:

- Dacryocystitis
- Congenital glaucoma
- Nasolacrimal duct obstruction
- Preseptal/Orbital cellulitis
- Congenital glaucoma
- Infectious keratitis

4.5. Investigations

A definitive diagnosis of the cause of ophthalmia neonatorum is dependent on laboratory identification of the offending organism. The speed of progression of some of the causative agents makes it imperative to do a test which can identify the cause as soon as possible. Some of the laboratory tests that can be performed are as follows [40]:

- Culture on chocolate agar for *N gonorrhoeae*. Due to the rapid progression of *N gonorrhoea* conjunctivitis, it makes it imperative to perform smears, as it may be possible to identify gram-negative diplococci and initiate proper treatment within hours.
- Conjunctival scraping with Gram stain and Giemsa stain for *chlamydia*. Conjunctival specimens for *chlamydia* testing must include conjunctival epithelial cells because *C. trachomatis* is an obligate intracellular organism and exudates are not adequate for testing. Other non-culture methods such as direct fluorescent antibody testing, enzyme immunoassays and nucleic acid testing (NAT) may allow early detection of *Chlamydia* within hours rather than several days, as required for culture methods.
- Culture on blood agar for other strains of bacteria. For other viral aetiology direct cultures of the HSV vesicles can be performed. Alternatively direct antibody testing or PCR can be done. If symptoms worsen or symptoms recur after treatment cultures may have to be repeated.

4.6. Management of neonatal conjunctivitis

Prophylaxis- In 1881 for the first time silver nitrate was used as prophylactic treatment to reduce the incidence of ophthalmia neonatorum. Silver nitrate is specifically more effective against gonorrhoeal conjunctivitis. It inactivates gonococci by agglutination. It is not effective against Chlamydial conjunctivitis. However silver nitrate use also led to mild conjunctival inflammation, tearing and redness which typically resolved within 48 hours. Chemical conjunctivitis is a self-limiting condition, therefore no treatment is required. However preservative artificial tears have been used in some cases.

In recent times povidone-iodine drops are used as prophylaxis instead of silver nitrate [41]. These are shown to be more effective against *gonococcal* and *chlamydial* conjunctivitis and also less toxic. In US, erythromycin is being used as alternative to silver nitrate and povidone-iodine [42]. This is also well tolerated and effective against TRIC and gonococci agents.

Treatment -Treatment of neonatal conjunctivitis should initially be based on the history, clinical presentation and results of smears. This can later be adjusted when laboratory results become available then specific therapy can be instituted.

The risk of transmission of chlamydial, gonococcal, herpetic, and streptococcal pathogens to the foetus during the birth process should be considered. If necessary, cervical cultures should be performed and managed appropriately. To confirm the presence of a sexually transmitted disease in the neonate, examine and treat the mother and her sexual partner. If necessary, therapy can be modified when the results of culture and sensitivity are known.

Bacterial conjunctivitis- Chlamydial conjunctivitis is treated with fourteen day course of twice daily oral erythromycin(50 mg/kg/d divided qid) [43, 44]. Systemic therapy is important in Chlamydia conjunctivitis, due to the high incidence of extra-ocular infection in neonates. It has shown to eliminate Chlamydial infection in 80-100% of patients. Topical erythromycin can be used as adjunct with the oral therapy. If there is failure to respond to this course the fourteen day course can be repeated before seeking alternative antibiotics [45].

Gonococcal conjunctivitis may be treated with intramuscular or intravenous ceftriaxone 50 mg/kg/day or as a single dose treatment of 125mg [46]. Alternatively, cefotaxime 100mg can be given intramuscularly or 25 mg/kg given either intramuscularly or intravenously every 12 hours for 7 days [47].

Neonates with conjunctivitis caused by herpetic simplex virus should be treated with systemic acyclovir to reduce the chance of a systemic infection [48]. An effective dose is 60 mg/kg/day IV divided. The recommended minimal duration is 14 days, but a course as long as 21 days may be required. Infants with neonatal HSV keratitis should receive a topical ophthalmic drug, most commonly 1% trifluridine drops or 3% vidarabine ointment.

4.7. Complications of neonatal conjunctivitis

Complications of neonatal conjunctivitis vary. There are two main types of complications, ocular and systemic complications. These can be prevented with prompt diagnosis and

treatment. Ocular complications include pseudomembrane formation, peripheral pannus formation, thickened palpebral conjunctiva, corneal oedema, corneal opacification, corneal perforation, staphyloma, endophthalmitis, loss of eye, and blindness [49].

Systemic complications of chlamydia conjunctivitis include pneumonitis, otitis, and pharyngeal and rectal colonization. Pneumonia has been reported in 10-20% of infants with chlamydial conjunctivitis. Complications of gonococcal conjunctivitis and subsequent systemic involvement include arthritis, meningitis, anorectal infection, septicaemia, and death.

Ophthalmia neonatorum is a preventable cause of childhood blindness and with prompt diagnosis, treatment and efforts on all levels, this can be eradicated.

5. Prevention of conjunctivitis

Infective conjunctivitis is a condition which affects people of all ages. Its spread is something that can be effectively controlled via good personal hygiene and adequate education. Once an individual is affected, rapid measures must be taken to ensure that the spread is limited.

Good personal hygiene is primarily achieved via effective hand washing and eye care. Where an outbreak of the highly contagious viral conjunctivitis has occurred, stringent measures to control the spread must be undertaken immediately. Simple measures such as removal of possible contaminated materials (hand cloth, towels and face cloths) are very effective in reducing spread.

For specialist cases of conjunctivitis, i.e. neonatal conjunctivitis and conjunctivitis in the immunocompromised, immediate action must be undertaken to ensure no long term complications and quick recovery. Should there be any delay in treatment, the potential for long term damage, and even blindness, is very high. Prevention of such conditions can be attained by immediate and frequent treatment via hospital admissions, prophylactic medication and good eye hygiene.

6. Conclusion

Conjunctivitis can be a very irritating and frustrating condition to suffer from. Not only does it have profound social implications, it can also affect education and finances if social exclusion is required. General practitioners must remain vigilant when diagnosing viral from bacterial conjunctivitis and try to ensure that patient education of the condition is at an optimum level to prevent spread. Special care must also be taken into consideration in neonatal conjunctivitis and conjunctivitis in the immunocompromised.

Although conjunctivitis is mostly a mild condition, GPs must also be aware of other more serious conditions and be able to differentiate mild conditions from more serious underlying and emergency conditions. This is only achieved via being able to create a list of differentials from a thorough patient history, examination and referral to an ophthalmologist if required.

Author details

Adnaan Haq, Haseebullah Wardak and Narbeh Kraskian

St. George's University of London, UK

References

- [1] Santa JO, Mark BA. Allergic conjunctivitis: Update on pathophysiology and prospects for future treatment. *The Journal of Allergy and Clinical Immunology*. 2004; 115: 118-122.
- [2] Sheikh A, Hurwitz B. Topical antibiotics for acute bacterial conjunctivitis: a systematic review. *Br J Gen Pract*. 2001; 51:473-7.
- [3] Department of Health, Prescription cost analysis data. Leeds: Department of Health, 1998.
- [4] Rose PW, Harnden A, Brueggemann AB, Perera R, Sheikh A, Crook D, Mant D. Chloramphenicol treatment for acute infective conjunctivitis in children in primary care: a randomised double-blind placebo-controlled study. *Lancet*. 2005; 366: 37-43.
- [5] Weiss A, Brinser JH, Nazar-Stewart V. Acute conjunctivitis in childhood. *J Pediatr*. 1993; 122: 10-14.
- [6] Gigliotti F, Williams WT, Hayden FG, Hendley JO. Etiology of acute conjunctivitis in children. *J Pediatr*. 1981; 98: 531-536.
- [7] Tarabishy BA, Jeng HB. Bacterial conjunctivitis: A review for internists. *Cleveland Clinic Journal of Medicine*. 2008; 75: 508-512.
- [8] Genees en hulpmiddelen Informatie Project. Annual report prescription data. Collegevoorzorg verzekeringen, Amstelveen, 2001.
- [9] Carr WD. Comparison of Fucithalmic® (fusidic acid viscous eye drops 1%) and Chloromycetin Redidrops® (chloramphenicol eye drops 0. 5%) in the treatment of acute bacterial conjunctivitis. *J Clin Res*. 1998; 1: 403-411.
- [10] Wall AR, Sinclair N, Adenis JP. Comparison of Fucithalmic® (fusidic acid viscous eye drops 1%) and Noroxin (norfloxacin ophthalmic solution 0. 3%) in the treatment of acute bacterial conjunctivitis. *J Drug Assess*. 1998; 1: 549-558.
- [11] Schiebel N: Use of antibiotics in patients with acute bacterial conjunctivitis. *Ann Emerg Med*. 2003; 41: 407-409.
- [12] Sheikh A, Hurwitz B. Topical antibiotics for acute bacterial conjunctivitis: Cochrane systematic review and meta-analysis update. *British Journal of General Practice*. 2005; 55: 962-964.

- [13] Everitt HA, Little PS, Smith PW. A randomised controlled trial of management strategies for acute infective conjunctivitis in general practice. *BMJ*. 2006; 333: 321.
- [14] Rietveld RP, Bindels PJE, Sloos JH, van Weert HCPM. The treatment of acute infectious conjunctivitis with fusidic acid: a randomised controlled trial. *Br J Gen Pract*. 2005; 55: 924–930.
- [15] Cronau H, Kankanala RR, Mauger T. Diagnosis and management of red eye in primary care. *Am Fam Physician*. 2010; 81: 137-44.
- [16] Anon. Acute Conjunctivitis. Best Medical Practice, *BMJ* [serial online]. Available from: <http://bestpractice.bmj.com/best-practice/monograph/68/treatment/details.html>
- [17] Sheikh A, Hurwitz B. Topical antibiotics for acute bacterial conjunctivitis: Cochrane systematic review and meta-analysis update. *British Journal of General Practice*. 2005; 55: 962-964
- [18] Fraunfelder FW. Corneal toxicity from topical ocular and systemic medications. *Cornea*. 2006; 25: 1133-8
- [19] Schlech BA, Blondeau J. Future of ophthalmic anti-infective therapy and the role of moxifloxacin ophthalmic solution 0. 5% (VIGAMOX) . *SurvOphthalmol*. 2005; 50: 64-7.
- [20] Kowalski RP, Dhaliwal DK, Karenchak LM, Romanowski EG, Mah FS, Ritterband DC, Gordon YJ. Gatifloxacin and moxifloxacin: an in vitro susceptibility comparison to levofloxacin, ciprofloxacin, and ofloxacin using bacterial keratitis isolates. *Am J Ophthalmol*. 2003; 136: 500-5.
- [21] Kowalski RP, Yates KA, Romanowski EG, Karenchak LM, Mah FS, Gordon YJ. An ophthalmologist's guide to understanding antibiotic susceptibility and minimum inhibitory concentration data. *Ophthalmology*. 2005; 112: 1987.
- [22] Asbell PA, Colby KA, Deng S, McDonnell P, Meisler DM, Raizman MB, Sheppard JD Jr, Sahm DF. Ocular TRUST: nationwide antimicrobial susceptibility patterns in ocular isolates. *Am J Ophthalmol*. 2008; 145: 951-958.
- [23] Asbell PA, Sahm DF, Shaw M, Draghi DC, Brown NP. Increasing prevalence of methicillin resistance in serious ocular infections caused by *Staphylococcus aureus* in the United States: 2000 to 2005. *J Cataract Refract Surg*. 2008; 34: 814-8
- [24] Sheikh A & Hurwitz B: Topical antibiotics for acute bacterial conjunctivitis: a systematic review. *Br J General Prac*. 2001; 51: 473–477.
- [25] Ishii K, Nakazono N, Fujinaga K, Fujii S, Kato M, Ohtusaka H, Aoki K, Chen CW, Lin CC, Sheu MM, Lin KH, Oum BS, Lee SH, Chun CH, Yoshii T, Yamazaki S. Comparative Studies on Aetiology and Epidemiology of Viral Conjunctivitis in Three Countries of East Asia—Japan, Taiwan and South Korea. *International Journal of Epidemiology*. 1986; 16: 98-103.

- [26] Donahue, S. P. , Khoury, J. M. , Kowalski, R. P. (1996) Common ocular infections: a prescriber's guide. *Drugs*. 52 (4) , pp. 528-529.
- [27] Monnerat, N. , Bossart, W. , Thiel, M. A. (2006) Povidone-iodine for treatment of adenoviral conjunctivitis: an in vitro study. *Klinische Monatsblätter für Augenheilkunde*. 223 (5) , pp. 349-52.
- [28] Cronau, H. , Kankanala, R. R. , Mauger, T. (2010) Diagnosis and management of red eye in primary care. *American Academy of Family Physicians*. 81(2) , pp. 137-44.
- [29] Schueler, S. J. , Beckett, J. H. , Gettings, D. S. (2008) Viral Conjunctivitis: Outlook. Available: [http://www. freemd. com/viral-conjunctivitis/outlook. htm](http://www.freemd.com/viral-conjunctivitis/outlook.htm). Last accessed 8th August 2012.
- [30] Chronister, C. L. (1996) Review of External Ocular Disease Associated with AIDS and HIV infection. *American Academy of Optometry*. 73 (4) , pp. 225-230.
- [31] Diesenhouse, M. C. , Wilson, L. A. , Corrent, G. F. , Visvesvara, G. C. (1993) Treatment of Microsporidial keratoconjunctivitis with topical fumagillin. *American Journal of Ophthalmology*. 115 (1) , pp. 293-298.
- [32] Charles, N. C. , Freidberg, D. N. (1992) Molluscum Contagiosum in AIDS. *Ophthalmology (Rochester)* . 99 (7) , pp. 1123-1126.
- [33] Kohn, S. R. (1987) Molluscum Contagiosum in patients with AIDS. *American Medical Association: Archives of Ophthalmology*. 105 (4) , p. 458.
- [34] Schryver, A. D. , Meheus, A. (1990) Epidemiology of sexually transmitted diseases: the global picture. *Bulletin of the World Health Organization*. 68(5) , pp. 639-654.
- [35] Verma, M. , Chaatwal, J. , Varughese, P. (1994) Neonatal Conjunctivitis: A Profile. *Indian Paediatrics*. 31(11) , pp. 1357-61.
- [36] Jamal, L. , Khan, M. (2010) Ophthalmianeonatorum. *Journal of College Physicians and Surgeons Pakistan*. 20(9) , pp. 595-8.
- [37] Laga, M. , Plummer, F. A. , Nzanze, H. , Namaara, W. , Brunham, R. C. , Ndinya-Achola, J. O. , Maitha, G. , Ronald, A. R. , D'Costa, L. J. , Bhullar, V. B. , Fransen, L. , Piot, P. , (1986) Epidemiology of Ophthalmia Neonatorum in Kenya. *The Lancet*. 328(8516) , pp. 1145-1149.
- [38] Enzenauer R. W. , (2011) Neonatal Conjunctivitis. Available at: [http://emedicine. medscape. com/article/1192190-overview](http://emedicine.medscape.com/article/1192190-overview)(Accessed: 5th August 2012) .
- [39] Scott, O. , (2011) OphthalmiaNeonatorum Available at: [http://www. patient. co. uk/ doctor/Ophthalmia-Neonatorum. htm](http://www.patient.co.uk/doctor/Ophthalmia-Neonatorum.htm)(Accessed 5th August 2012) .
- [40] Gregory, S. , Cantor, L. , Louis, B. , Weiss, J. S. , (2011) Paediatric Ophthalmology and Strabismus. In *The American Academy of Ophthalmology, ed, Basic and clinical science course*. 1st edn. Singapore: American Academy of Ophthalmology, pp. 186-188.

- [41] Sherwin, J. , Isenberg, A. P. T. , Leonard, A. P. T. , Wood, M. , (1995) A Controlled Trial of Povidone–Iodine as Prophylaxis against Ophthalmia Neonatorum. *The New England Journal of Medicine*. 332 (9) , pp. 562-566.
- [42] Darling, E. , McDonald, H. , (2010) A meta-analysis of the efficacy of ocular prophylactic agents used for the prevention of gonococcal and chlamydial ophthalmia neonatorum. *Journal of Midwifery and Women's Health*. 55(4) , pp. 319-27.
- [43] Heggie, A. D. , Jaffe, A. C. , Stuart, L. A. , Thombre, P. S. , Sorensen, R. U. (1985) Topical Sulfacetamide vs Oral Erythromycin for Neonatal Chlamydial Conjunctivitis. *American Journal of diseases of children*. 139(6) , pp. 564-566.
- [44] Zar H. J. , (2005) Neonatal Chlamydial Infections: Prevention and Treatment. *Pediatric Drugs*. 7(2) , pp. 103-110.
- [45] Stenberg, K. , Mardhip, A. , (1991) Treatment of chlamydial conjunctivitis in newborns and adults with erythromycin and roxithromycin. *Journal of Antimicrobial Chemotherapy*. 28(2) , pp. 301-307.
- [46] Laga, M. , Naamara, W. , Brunham, R. C. , D'Costa, L. , Nsanze, H. , Piot, P. , Kunitomo, D. , Ndinya-Achola, J. , Slaney, L. , Ronald, A. R. , Plummer, F. A. (1986) Single-Dose Therapy of Gonococcal Ophthalmia Neonatorum with Ceftriaxone. *The New England Journal of Medicine*. 315(22) , pp. 1382-1385.
- [47] Pierce, J. M. , Ward, M. E. , Seal, D. V. (1982) Ophthalmia neonatorum in the 1980s: incidence, aetiology and treatment. *British Journal of Ophthalmology*. 66 (11) , pp. 728-731.
- [48] Whitley, R. , (2004) Neonatal herpes simplex virus infection. *Current Opinion in Infectious Diseases*. 17(3) , pp. 243-246.
- [49] Gogate, P. , Gilbert, C. , Zin, A. (2011) Severe Visual Impairment and Blindness in Infants: Causes and Opportunities for Control. *Middle East African Journal of Ophthalmology*. 18(2) , pp. 109-114.

