

We are IntechOpen, the world's leading publisher of Open Access books Built by scientists, for scientists

6,900

Open access books available

186,000

International authors and editors

200M

Downloads

Our authors are among the

154

Countries delivered to

TOP 1%

most cited scientists

12.2%

Contributors from top 500 universities



WEB OF SCIENCE™

Selection of our books indexed in the Book Citation Index
in Web of Science™ Core Collection (BKCI)

Interested in publishing with us?
Contact book.department@intechopen.com

Numbers displayed above are based on latest data collected.
For more information visit www.intechopen.com



Management of CMV-Associated Diseases in Immunocompromised Patients

A.L. Corona-Nakamura and
M.J. Arias-Merino

Additional information is available at the end of the chapter

<http://dx.doi.org/10.5772/56141>

1. Introduction

Among the great advances that have been achieved in infectious diseases has been on the management of cytomegalovirus (CMV) infection and disease.

This chapter describe an overview of the clinical manifestations of CMV diseases that are in immunocompromised patients, including patients with human immunodeficiency virus infection / Acquired Immunodeficiency Syndrome (HIV / AIDS), organ transplant recipients, bone marrow transplant recipients, and individuals receiving immunosuppressive therapy or chemotherapeutic agents. We also present the conditions for the development of CMV disease in these patients.

In the overall population, the seroprevalence of CMV (IgG) is 30 to 100%. CMV disease is a major cause of death in bone marrow and organ transplant recipients and persons with AIDS. In adult patients with cancer and leukemia (except T cell leukemia) who have not undergone transplantation, the frequency of CMV disease is lower than 3%, but mortality can reach 82% [1-5].

The direct clinical effects of CMV are CMV viral syndrome and end-organ diseases. The indirect effects include superinfections caused by bacteria (eg: *Listeria* or *Pseudomonas*), fungi (eg: *Aspergillus*, *Pneumocystis jiroveci*, *Cryptococcus*) or other viruses (herpes zoster, Epstein Barr virus) [6].

2. Terminology

CMV Infection is defined as the detection of the CMV virus by antibodies in blood or the detection of this virus by polymerase chain reaction (PCR), or antigens in any body fluid or tissue specimen, but the infected patient not show any clinical symptoms caused by the virus [2,4,7].

CMV Disease is the presence of CMV infection, evident as:

CMV Syndrome, a clinical condition characterized by fever $\geq 101^{\circ}\text{F}$ ($\geq 38.3^{\circ}\text{C}$) at least twice within 7 days, muscle pain, leukopenia $\leq 3500/\mu\text{l}$, neutropenia $\leq 1,500/\mu\text{l}$, atypical lymphocytosis $\geq 5\%$ and/or thrombocytopenia $< 100,000/\mu\text{l}$ [7] or...

CMV Disease with Organ and Tissue involvement. Clinical presentations [3,4,6] include pneumonitis, gastrointestinal disease (e.g., gastritis, colitis, esophageal ulcers), hepatitis, pancreatitis, nephritis, cystitis, myocarditis, retinitis, central nervous system disease (e.g., meningitis, polyradiculitis, encephalitis, transverse myelitis, Guillain-Barré Syndrome, peripheral neuropathy), thrombocytopenia, hemolytic anemia, adrenalitis, disseminated disease [2].

Primary infection is defined as the detection of CMV infection in an individual previously found to be CMV seronegative. In the case transplanted patients, when the recipient with CMV seronegative (IgG and IgM) receives blood products or a graft from a donor CMV seropositive IgG (D+/R-). The appearance of de novo specific antibodies in a seronegative patient may also be acceptable for the diagnosis of CMV [2,7].

Secondary (Reactivation) infection occurs with the reactivation of endogenous latent CMV, in a CMV seropositive patient, who has (cancer, chronic lymphocytic leukemia, solid organ transplantation, or bone marrow transplantation) with diminished immunity after immunosuppressive therapy or a patient with HIV. The recipient before transplantation is seropositive for CMV (IgG) and the donor is seronegative to CMV (IgG and IgM) (D-/R+) [2,4,8,9]. Reactivation or reinfection again initiates an IgM response. The IgG appears within a few weeks of the IgM rise (4).

Superinfection can occur when the recipient receives a graft or blood products from a donor who is CMV seropositive with different strain of CMV (D+/R+) [2].

Preemptive therapy consists on to monitor weekly by CMV blood PCR to immunocompromised patients and if the test becomes positive, they will be treated with antiviral, irrespective of clinical symptoms. This type of therapy is used in patients with solid organ transplant (specifically with serotypes D+/R+, D-/R+ and D-/R-), hemopoietic stem cell transplantation, and patient with chronic lymphocytic leukemia who received alemtuzumab, each group of patients has specific guidelines for this type of therapy. Following a study in which CMV DNA was found in 83% of liver transplant recipients at a mean of 13 days before the onset of symptomatic CMV infection, it has become apparent that the preemptive therapy decreases the morbidity and mortality of CMV infection [2].

Prophylactic therapy involves administration of oral valganciclovir or intravenous ganciclovir at-risk patients, such as patients with CMV IgG serostatus negative (D+/R-) or when the recipients need anti-rejection therapy, such as anti-thymocyte globulin (ATG) or anti-lymphocyte globulins (ALGs) [2].

3. The role of immunosuppression

3.1. CMV disease in transplantation recipients

3.1.1. Hemopoietic Stem Cell Transplantation (HSCT)

CMV infections may be more frequently caused by reactivation of the virus in the recipient rather than a primary infection. Approximately 30% of seronegative recipients with seropositive stem cell donors (D+/R-) develop primary CMV infection, whereas reactivation occurs in about 80% who were seropositive before transplantation [8,10].

According the guidelines by Tomblyn *et al* 2009, HSCT recipients at risk for post transplant CMV disease (all CMV-seropositive HSCT recipients, and all CMV-seronegative recipients with a CMV seropositive donor) should have a CMV disease prevention program from the time of transplantation until at least 100 days after HSCT, using prophylaxis or preemptive treatment for allogeneic recipients.

A preemptive strategy against CMV replication (<100 days post-HSCT):

1. To all allogeneic HSCT recipients with evidence of CMV infection for CMV DNA, and this strategy is preferred over prophylaxis therapy for D+/R-. Administer induction doses: Valganciclovir 900 mg twice daily or ganciclovir I.V. 5mg/kg every 12 hours for 7-14 days. Maintenance doses: for another 3-4 weeks until the test is negative or resolution of symptoms.
2. CMV seropositive autologous HSCT recipients with high risk for CMV replication or disease, for example patients who had total body irradiation, and patients who have received alemtuzumab within 6 months prior to HSCT. Administer induction doses: Valganciclovir 900 mg twice daily or ganciclovir I.V. 5mg/kg every 12 hours for 7 days. Maintenance doses: for another 3-4 weeks until the test is negative or resolution of symptoms. Note: Continue screening for CMV reactivation and re-treat if screening tests become positive after discontinuation of therapy [11].

Preemptive therapy > 100 days post-HSCT for:

1. Allogeneic HSCT recipients.
2. All patients receiving steroids for graft-versus-host disease (GVHD), steroid use, low CD4 counts <50/mm³, and use of grafts from CMV-seronegative donors in CMV-seropositive recipients.

Administer induction doses: Valganciclovir 900 mg twice daily or ganciclovir I.V. 5mg/kg every 12 hours for 7-14 days.

Maintenance doses: for another 3-4 weeks until the test is negative or resolution of symptoms [11].

Prophylactic therapy can be recommended for all allogeneic recipients (from engraftment to 100 days after HSCT), this therapy is not recommended for seropositive autologous recipients, except the patient is at high risk as recipients unrelated, patient with human leucocyte antigen (HLA) system-mismatched or in patients who used the alemtuzumab and are candidates for HSCT. The induction: valganciclovir 450 mg twice daily for 5-7 days. Maintenance: Daily until day 100 after HSCT [8,11,12].

Before the introduction of specific prophylaxis, the risk of CMV disease was reported to be up to 58% in of the allogeneic stem cell transplant seropositive recipients, the clinical presentation more likely was pneumonia with mortality to 94 % [2,7,8,13]. The incidence of CMV pneumonia after autologous bone marrow transplantation and peripheral blood SCT ranges from 1% to 6% [8,14].

Gastrointestinal disease is the most common disease, after CMV pneumonia, which can escape blood-based surveillance by PCR in approximately 25 % of patients. There is presently no consensus on how to use molecular methods to diagnose CMV gastrointestinal and pneumonia disease because there are no data on what level of CMV DNA in bronchoalveolar lavage (BAL) fluid or tissue that correlates best with CMV disease. The gastrointestinal disease is treated with antiviral alone. The treatment of CMV pneumonia includes the antiviral and intravenous immunoglobulin. CMV retinitis and encephalitis are rare complications [8,12].

3.1.2. Late CMV disease in HSCT patients

Late CMV disease (after 100 days) occurs in 15% to 20% of seropositive allograft recipients, and it occurs between months 4 and 12 after HSCT, with a mortality rate of 46%. Risk factors for late CMV disease include CMV infection during the first 3 months after transplantation, chronic graft-versus-host disease (GVHD), CD4 counts less 50 per mm³, and undetectable CMV-specific T-cell immunity [8,12].

3.1.3. Solid Organ Transplant (SOT)

CMV infection is most common during the first 3 to 12 weeks after transplantation, this is because in this period is more intense immunosuppression to prevent rejection [2].

There is a high risk of CMV disease when a seronegative receptor receives an organ from a seropositive individual [Donor+/Recipient- (D+/R-)]. Up to 85% of SOT recipients with CMV D+/R- serologic status develop primary CMV disease, with the prophylactic therapy reducing CMV disease to 22% [2].

Other high risk factors are biologic agents used for induction therapy or rejection treatment. These include T lymphocyte (OKT3) monoclonal antibody, ATG, ALGs, or high doses of corticosteroids [2,7].

There is an Intermediate risk of CMV disease with D+/R+ or D-/R+ combinations and a low risk when the donor and recipient are CMV seronegative [2,7].

In kidney transplant patients, 8-18 % will have CMV infection. The clinical presentations may be asymptomatic, fever or affect the transplanted organ, as a glomerulopathy or nephritis [2,7,15].

Amongst liver transplant patients, 29% present CMV infection manifesting as CMV hepatitis [2,6].

Amongst heart transplant patients, 25% present with CMV infection manifesting as myocarditis [2,7]. Of the patients transplanted kidney-pancreas, 50% will present CMV infection usually affecting the transplanted pancreas [2,7].

22% of patients with transplanted small bowel will have CMV infection affecting the transplanted bowel [2,7].

Around 39% of patients with heart-lung transplants can be expected to have CMV infection, usually affecting the lung causing pneumonitis [2,7].

3.1.4. Late CMV disease in solid organ transplanted patients

Antiviral prophylaxis is highly effective in preventing CMV disease in transplanted recipients, particularly in D+/R- patients. However, late-onset CMV disease may occur after 100 days or several years after transplantation, coinciding with discontinuation of antiviral prophylaxis. Among kidney and kidney-pancreas transplant recipients, late-onset CMV disease was documented in 47% of D+/R- patients, 12% of D+/R+ patients, 7% of D-/R+ patients, and 4% of D-/R- patients [16]. One study reported that up to 27% of high-risk (CMV D+/R-) liver and kidney transplantation recipients who received oral ganciclovir prophylaxis for 3 months developed late-onset CMV disease after the completion of antiviral prophylaxis. CMV retinitis and CMV colitis tend to be later manifestations of disease or a clinical presentation atypical [2,16].

In a systematic review, CMV disease occurred in 2.6% and 9.9% of SOT recipients receiving valganciclovir as preemptive therapy and prophylaxis, respectively. In patients receiving valganciclovir prophylaxis, the incidence of early-onset (≤ 90 days posttransplant) CMV disease was 0.8% and 1.2% in all patients (D+/R+, D-/R+) and D+/R- patients, respectively. In the prophylactic group, the incidence of late-onset (>90 days posttransplant) CMV disease rose up to 8.9 % and 17.7 % in all patients and D+/R-, respectively. Ninety-two percent of the patients with CMV disease in the prophylactic group were late-onset disease. No patients developed late-onset CMV disease in preemptive group. Late-onset CMV disease is a complication observed uniquely with valganciclovir prophylaxis, particularly in D+/R- patients, but not with preemptive therapy [17].

The rejection rate was 10.8% in SOT recipients who receiving preemptive therapy. The overall rejection was 17.6% in the prophylactic studies. Fifteen patients (3.9%) of 380 patients in preemptive group had graft loss. In prophylactic studies the graft loss rate was 2.5%. The patients who receiving preemptive therapy, 28.5% developed opportunistic infections. In

contrast, prophylactic studies reported the proportion of patients with opportunistic infections was 7.8%. The mortality was 8.2% from four preemptive studies, and 4.4% in prophylactic studies [17].

3.1.5. Recurrent CMV disease

Recurrent CMV disease may occur in up to 25% of SOTR (2). Predictive factors include the type of organ transplant, CMV DNA in plasma at day 21, negative CMV IgG serostatus D+/R- at start of treatment and therapy for acute rejection (18). The rate of recurrent CMV disease for lung transplant recipients was 38.5%, for kidney 14.6%, for heart 11.8%, and for liver transplant recipients was 0%. The yearly risk of recurrent CMV disease was 24.4% for patients with persistent CMV DNAemia in plasma at day 21 versus 8.8% for those eradicated at day 21 [18].

CMV recurrence may be related to incomplete suppression of viral replication or the duration of treatment (often 2-4 weeks) may have been insufficient. Some authors suggest treatment for 3 months for pneumonitis, retinitis and gastrointestinal CMV disease. Plasma levels of CMV DNA should influence the therapy duration [2]. Weekly monitoring until eradication is recommended [18].

3.2. CMV disease in patients with HIV/AIDS

CMV infection was one of the most important opportunistic infection in HIV-infected patients before the introduction of the highly active antiretroviral therapy. Approximately 40% of HIV-infected patients with advanced disease suffered from one of several manifestations of CMV infection during their life. Colitis is the second most common presentation of CMV disease after CMV retinitis (4). It is related to the degree of T-cell impairment, being most common in patients with CD4⁺ T-cell counts below 50-100 cells/ μ l [3,19].

3.3. CMV disease in patients with rheumatic diseases

The incidence of CMV in rheumatic patients was 50% for systemic lupus erythematosus (SLE), 10% for dermatomyositis, 8.8% for microscopic polyangitis, and less than 5% for rheumatoid arthritis, rheumatoid vasculitis, Behcet's disease, Chung-Strauss syndrome. The mortality rates CMV disease were 20-75% rheumatological disease depending on the type. The fever was the most common symptom, respiratory symptoms were the second most common, followed by gastrointestinal symptoms. Visual disturbance was observed in one patient [20].

CMV infection was most common among patients under strong immunosuppressive therapy (eg: 500-1000 mg pulsed methylprednisolone per day, 60-100 mg oral prednisolone, or intravenous or oral cyclophosphamide within a year before CMV diagnosis [19]. The effect of corticosteroid involves derangement of T lymphocyte and monocyte/macrophage functions, and blockade of the production of cytokines such as TNF- α . Cyclophosphamide suppresses lymphocyte proliferation and function which increasing the risk of CMV reactivation and replication [1,20-22].

3.4. CMV disease in patients with haematological malignancies and solid tumours

CMV disease is potentiated by drugs that cause profound cell-mediated immunosuppression, such as fludarabine (which depresses CD4 T-lymphocytes), high-dose cyclophosphamide, high-dose of steroids and granulocyte transfusions from donors who have CMV disease, and with the use of metotrexate, cyclosporine, alemtuzumab (anti-CD52 MoAb) and rituximab (anti-CD20 MoAb). The mortality rate among the patients with leukemia, myelodysplastic syndrome or lymphoma was 82%, and the 63% of the fatal cases was due to, relapse of leukemia, refractory leukemia, or that these patients were in accelerated or blast phase [1,23].

In 2001, serious CMV disease, (primarily pneumonia) was found at autopsy in 17%-75% of patients dying with T cell leukemia. Mortality was higher among patients who had lymphopenia [1].

3.4.1. Guidelines on the management of CMV reactivation in patients with chronic lymphocytic leukemia treated with alemtuzumab

Chronic lymphocytic leukemia (CLL) is a disease of progressive with an accumulation of clonal B lymphocytes in peripheral blood, marrow, and lymphoid organs. This is generally incurable, except the patients who receive an allogeneic cell transplant, and it is the most common form of adult leukemia in Western countries. Patients with CLL have impaired humoral and cellular immunity [24-26]. Current treatments for patients with CLL include monoclonal antibodies (eg. rituximab and alemtuzumab) among others [9,27].

Alemtuzumab is a recombinant humanized, anti-CD52 monoclonal antibody with significant activity in CLL, including fludarabine-refractory disease. CD52 is a glycoprotein of unknown function that is expressed on the surfaces of normal and malignant B and T lymphocytes. Binding of alemtuzumab to CD52 on lymphocytes induces complement-dependent cytotoxicity, antibody-dependent cell-mediated cytotoxicity (which results in a rapid and profound reduction of lymphocytes, and this produces viral replication and reactivation CMV) and direct cytotoxicity (likely apoptotic cell death) [9,24,25,27-29].

Viral infections often are presented at the third week after the initiation of alemtuzumab, which coincides with the nadir in T-cell numbers. The CMV reactivation is the most common opportunistic infection observed in alemtuzumab-treated patients and it is observed at the beginning of the 4 - 6 weeks of alemtuzumab [30]. O'Brien *et al* estimated the incidence of CMV reactivation ranges from 4 to 30 %. This incidence typically refers to symptomatic CMV infection [9,24,28,31,32]. CMV pneumonitis was reported 0.8 %, and CMV-related death 0.2 %. CMV reactivation which frequently presents as fever of unknown origin or respiratory symptoms [9,24,28,31,33].

Updated management guidelines for using alemtuzumab in CLL.

Among the recommendations on the use of alemtuzumab in the patient with CLL, is monitoring for opportunistic infections, such as CMV reactivation, these management guidelines are referred by Osterborg A *et al*, 2009, and O'Brien *et al* 2006 for monitoring and treating of CMV reactivation, such as:

1. Baseline CMV serology prior to therapy of the patient
2. If the fever unresponsive to antibacterial agents and test not available should be presumed to be CMV reactivation and the alemtuzumab should discontinue and antiviral therapy should start [9,24,25,27,28,31]
3. Monitoring CMV reactivation by weekly PCR during therapy, and every 2 weeks for 6 weeks after alemtuzumab discontinuation [34-36].

If the CMV PCR two consecutive positive results obtained 1 week apart, it should start preemptive therapy with intravenous ganciclovir or oral valganciclovir or when CMV reactivation becomes symptomatic or viremia increase, alemtuzumab therapy should be interrupted and anti-CMV therapy to be started (Figure 1) [9,24,25,28].

The antiviral is administrated 900 mg twice daily for 21 days, or continue with the maintenance dose 900 mg twice daily until the CMV PCR is negative or until you have 2 consecutive negative results [9,24,25,28].

The pre-emptive treatment prevents the occurrence of potentially life-threatening infectious diseases, and the initiation of anti-CMV treatment avoids the interruption of alemtuzumab [31].

Another modality is the anti-CMV prophylaxis in CLL patients receiving alemtuzumab, is with valganciclovir 450 mg twice daily. The prophylaxis is administrated entire duration of Alemtuzumab therapy and until 2 months after end the therapy and the frequency of CMV PCR is every 2 weeks. The valganciclovir prophylaxis may be used in patients with elevated risk for CMV reactivation [9, 28]. Patients on prophylactic valganciclovir had a lower rate of CMV activation compared with valacyclovir (3% vs 24%) among patients being treated with an alemtuzumab-based regimen [26,32]

3.5. CMV infection in patients with inflammatory bowel disease

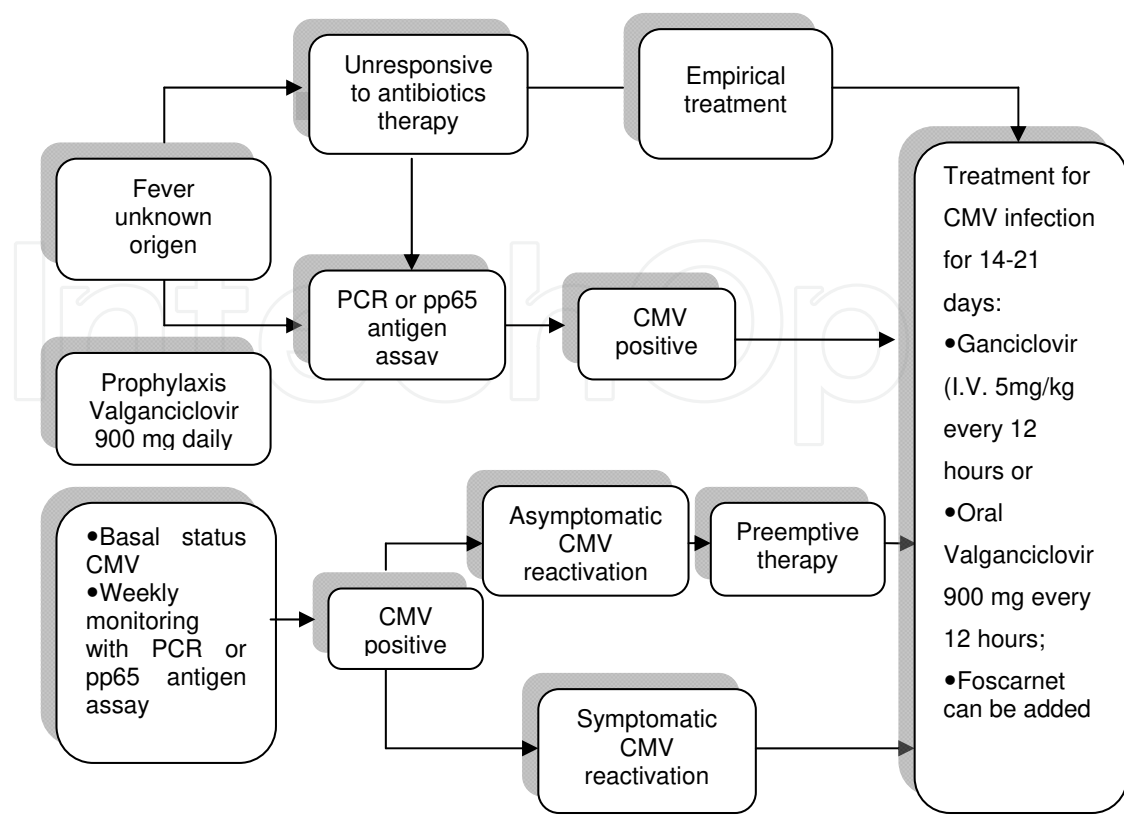
CMV disease is seen in patients under treatment with azathioprine alone or with 5-aminosalicylic acid, steroids, and/or infliximab, or 6-mercaptopurine, or leukocytapheresis. Crohn disease (CD) was underlying disease in 77% of cases possibly because immunosuppression is more common in CD compared to Ulcerative colitis (UC) [6].

4. Clinical presentations of CMV disease

4.1. CMV Pneumonia (CMVp)

“CMVp” is defined as the occurrence of clinical and radiographic evidence of pneumonia, in association with the isolation of CMV in BAL, or lung-tissue specimens or with the identification of CMV in lung tissue by histopathology, immunohistochemistry or PCR [1].

CMVp represents a major cause of morbidity and mortality in highly immunosuppressed patients, the clinical presentation resembles *Pneumocystis jiroveci* pneumonia (PCP), the



PCR, polymerase chain reaction; IV, via intravenous.

Figure 1. Guidelines on the Management in Cytomegalovirus Monitoring for Patients with Chronic Lymphocytic Leukemia Treated with Alemtuzumab

presence of extrapulmonary CMV disease could suggest the diagnosis of CMV pneumonia [37]. The symptoms are fever, nonproductive cough, dyspnea, or worsening dyspnea that progresses to hypoxemia, and necessitates assisted mechanical ventilation [6]. It can include extrapulmonary CMV disease (gastrointestinal or retinitis) [37]. The signs can include normal breath sounds at auscultation or basal crepitations [6].

On chest radiograph the infiltrates are usually bilateral and may be interstitial and diffuse (figure 2), or nodular, or alveolar and occasionally small pleural effusions [37]. The most common manifestations of CMVp on conventional radiographs are parenchymal consolidation and multiple nodules measuring less 5 mm in diameter [38].

In patients having AIDS, the most frequent finding was dense consolidation and mass-like opacities. The most frequent computed tomography (CT) pattern in immunocompromised patients without AIDS was ground-glass opacities which were bilateral patchy, diffuse distribution. Other findings included poorly-defined small nodules and consolidation. Interlobular septal thickening and pleural effusion [38,39].

Coinfections were other potentially life-threatening infections that occurred within 90 days of the episode of CMVp. These can contribute to death in patients with fatal CMVp [23].

HSCT and lung transplant recipients who develop CMVp or infection have an increased risk for subsequent invasive aspergillosis [23].

In allogeneic bone marrow transplant recipients, the incidence of CMVp is 20-35% and the mortality is up to 50% [40]. IV ganciclovir is given concurrently with immune serum globulin or hyperimmune globulin. In autologous bone marrow transplant recipients, the incidence of CMVp is 2% [9,23]. The mortality rate from CMVp in patients with HSCT was 100% [23].

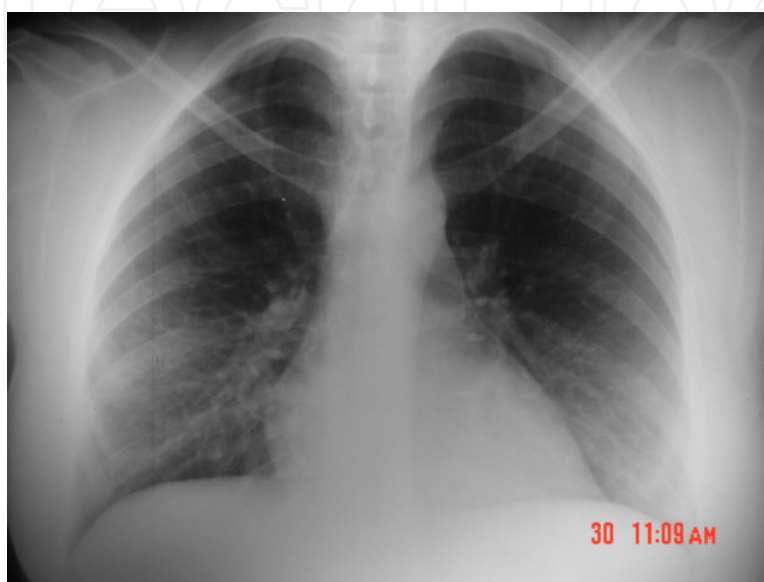


Figure 2. Bilateral interstitial pneumonia caused by CMV in a renal transplant recipient

In solid organ transplantation, the incidence of CMVp is 17 to 90 % [23].

In adults with leukemia, the frequency of CMVp was 0.4%, 2.2%, 2.3%, and 2.5% in patients with myelodysplastic syndrome, acute myelogenous leukemia (AML), chronic myelogenous leukemia (CML), and acute lymphocytic leukemia (ALL) respectively and 8.8% and 11% in patients with chronic lymphocytic leukemia (CLL) and lymphoblastic lymphoma. The median duration of time from the diagnosis of leukemia to the occurrence of CMVp ranged from 6 months and 9 months in patients with AML and ALL, respectively, to 25 months and 54 months in patients with CML, and CLL respectively [1,23].

The CMVp among patients with leukemia, lymphoma and myelodysplastic syndrome, the mortality rate was 57%, and the death occurred 15 (2-36) days after onset of illness. Among patients treated before the occurrence of respiratory failure, the mortality rate was 48%. When therapy was initiated after the occurrence of respiratory failure that required mechanical ventilation, the mortality rate was 57-100 % [1,23].

Chemaly *et al.* [23] observed that, the incidence of CMVp among adults with lymphoma was 0.6-1.2%. In the 92% of the patients, chemotherapy had been administered to the patients within 6 months before the onset of CMVp. Essentially, these patients with lymphoma were treated with rituximab or alemtuzumab [23].

A study of cancer patients receiving chemotherapy placed the incidence of CMVp below 3%, in patients with head and neck cancers, nasopharyngeal cancer (NPC), hypopharyngeal cancer (HPC), lung cancer, lymphoma and rectal cancer. The chemotherapy regimen used was cisplatin, 5-FU, fluorouracil, leucovorin and etoposide. As the incidence is low, prophylactic therapy was not recommended [5].

Cascio *et al.* [6] reported that the 85% of patients with inflammatory bowel disease who developed CMVp were on treatment with thiopurines (azathioprine and 6-mercaptopurine) when they developed CMVp. The mean length of treatment with azathioprine before the appearance of respiratory symptoms was 19 months, with 6-mercaptopurine was 18 months, infliximab was 10 days to 3 weeks, and cyclosporine was 3 days. These patients had hematological findings such as pancytopenia, lymphopenia, neutropenia, leucopenia, severe anemia, hemophagocytic lymphohistiocytosis or thrombocytopenia. Symptoms lasted from 2 days to 1 month [6,23].

4.2. CMV gastrointestinal (GI) diseases

Symptoms range from low-grade fever, weight loss, anorexia, abdominal pain, and bloody diarrhea to a fulminant colitis. In HIV patients can have present esophageal ulcer, esophagitis, gastritis, duodenitis, jejunal and ileal perforation, peritonitis secondary, odynophagia, and bowel obstruction. GI CMV disease is estimated to affect about 20% of adults with AIDS, and it can be involved all parts of the gastrointestinal tract, but the colon and esophagus are the most common sites [4, 41]. CMV infection of the endothelial cells and ensuing vasculitis may play a role in the development of thrombosis, local ischemia and ulceration of the gastrointestinal mucosa [41].

4.2.1. CMV colitis

Refers to the presence of the virus in the colon in sites of inflamed tissue. Within patients with severe ulcerative colitis (UC), CMV disease may occur more commonly in patients over age 55, and in patients treated with steroids. Steroids produce suppression of CMV-specific T-cell function. Infliximab has not been associated with an increased risk of CMV in patients with inflammatory bowel disease (IBD) [4].

The prevalence of CMV colitis in resected IBD specimens ranged from 0 to 22% [39], the prevalence assessed using CMV DNA in colon biopsy was 81% in UC patients, and 66% prevalence in Crohn's disease patients [3]. Domenech *et al.*, showed a prevalence of colonic CMV of 32% in patients with steroid-refractory UC [10].

CMV colitis has occurred primarily in patients with pre-existing UC, with documented disease for as long as 20-30 years [3]. Another theory was that CMV was an innocent bystander in IBD colitis. This may reflect infection with nonpathogenic genotypes. The challenge is differentiating the innocent bystanders from the pathogenic strains, so most patients are treated with antivirals, as the possible cost of delaying antiviral therapy is colectomy or even death. Refractory IBD colitis have been associated with CMV inclusions bodies, and these patients have a colectomy rate of 62% and a mortality rate of 44% [3].

CMV reactivation exacerbates disease severity in those with active intestinal inflammation. Patients with IBD have impaired NK cell activity and defects in mucosal immunity, which may enhance susceptibility to CMV reactivation). Patients described as “steroid-refractory” show CMV detectable by immunohistochemistry (IHC) in 20%-40% of both endoscopic biopsies and colectomy specimens. CMV DNA was detectable in the colon of up to 60% of patients in the same study [4].

CMV colitis is rare in patients with Crohn’s disease or mild-moderate ulcerative colitis. In patients with severe and/or steroid-refractory ulcerative colitis, the possibility of a concurrent CMV infection causing or worsening the colitis is considered, especially when patients are on immunosuppressive medications. Local reactivation of CMV can be detected in actively inflamed colonic tissue in about 30% of cases [3].

CMV has tropism for dysplastic colonic tissue (adenomas and adenocarcinomas) and may play a significant role in cancer progression. The association of CMV infection with dysplasia progression in IBD patients increases the risk of developing colorectal cancer [3].

The diagnosis includes:

Endoscopic findings comprise patchy erythema, exudates, microerosions, edematous mucosa, or deep ulcers and pseudotumor [42]. These findings can be very difficult to distinguish from severe IBD colitis [39]. CMV colitis may exclusively affect the right colon in up to 30% of cases [3].

CMV antigenemia is being supplanted by leukocyte CMV PCR. A “cut off” level of viremia for distinguishing infection from disease is required for CMV colitis in patients with IBD [4]. Higher CMV viral loads correlate with symptomatic disease [3]. Most studies in patients with IBD have reported a correlation between identification of CMV by PCR in blood, and colonic detection in tissue by hematoxylin and eosin (H&E) or IHC [3,4]. IHC improves histological sensitivity. It uses monoclonal antibodies, identifying infected cells in the colon. Sensibility ranges 78%-93% [4]. PCR of colonic tissue can be used to detect viral DNA [5]. The GI disease can occur even if there is no detection of CMV in the blood [10].

The European Crohn’s and Colitis Organization guidelines (2009) [4]: its authors recommend the use of tissue PCR or IHC in investigating for CMV in cases of IBD.

Guidelines from the American College of Gastroenterology, and the European Crohn’s & Colitis Organization (ECCO) recommend treatment with antivirals when CMV is detected by blood PCR or IHC on colonic biopsies, which must be performed in all patients with severe colitis refractory to immunosuppressive therapy. They do not recommend colonic PCR because they give false positive results. Likewise, they recommend the discontinuation of immunosuppressive agents only in cases of severe systemic CMV disease[4].

Treatment with antiviral therapy has allowed some patients with severe colitis to avoid colectomy despite poor response to conventional IBD therapies. CMV colitis is usually treated with ganciclovir, foscarnet, valganciclovir, or cidofovir. The recommended dosage is for at least 3-6 weeks. The “response rate” in patients with steroid-refractory disease who have reactivation of CMV is 72% (range 50%-100%) (figure 3) [3, 4].

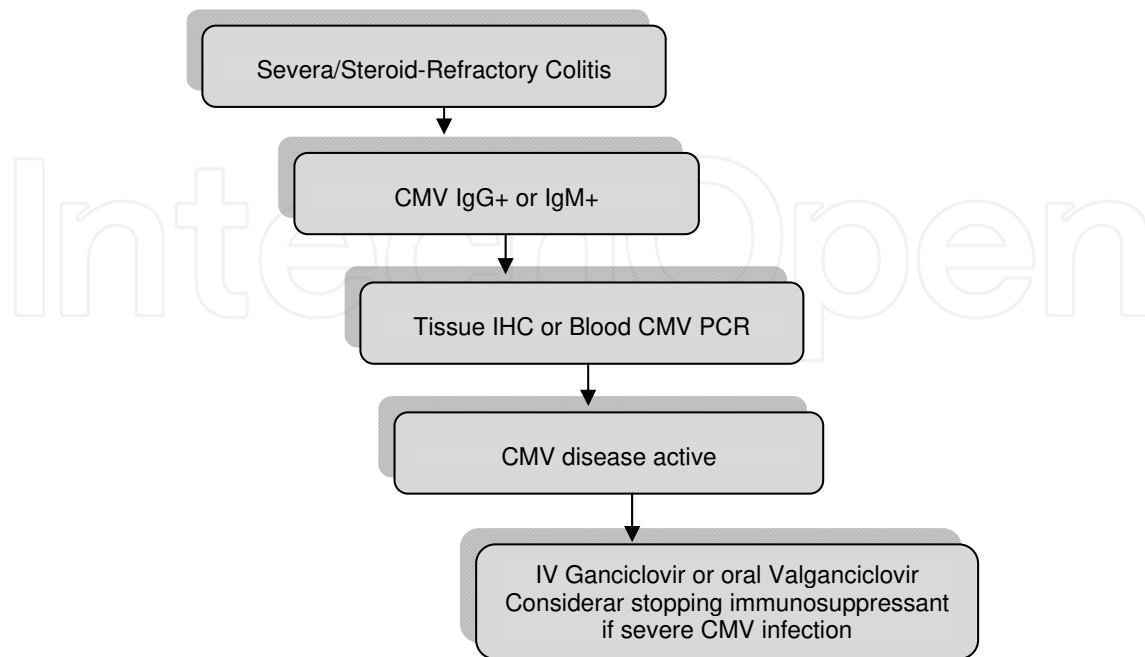


Figure 3. Algorithm for management of suspected CMV colitis in patients with IBD [4]

In patients having AIDS, relapse of CMV gastrointestinal disease in AIDS patients can occur between 9 weeks and 1 year after initial antiviral [3].

4.2.2. CMV hepatitis

Is defined by findings such as fever, vomiting, with hepatomegaly with hepatalgia, and atypical lymphocytosis may be approximately 50%, elevated bilirubin and/or enzyme levels, and detection of CMV by histopathologic analysis within the liver tissue is needed [13,42].

4.2.3. CMV pancreatitis

Requires the detection of CMV infection by immunohistochemical analysis together with the identification in a pancreatic biopsy. Detection of CMV by PCR alone is insufficient for diagnosis of CMV pancreatitis because it can imply the presence of transient viremia [42].

4.3. CMV retinitis

Retinitis can appear more than 6 months after solid organ transplantation, mainly heart transplant recipients. The patients can be asymptomatic, or they may experience blurring of vision, scotomata, or decreased visual acuity. Fundoscopy often reveals the diagnosis [2]. In HIV-infected patients, retinitis is the single most common manifestation of CMV disease, accounting for 85% of all cases. In developing countries, CMV retinitis is still the most frequent cause of visual loss in HIV-infected patients. Accordingly, the incidence of CMV retinitis,

which is the most common CMV disease among HIV patients, decreased from 17.1/100 patient years to 5.6/100 patient-years [2, 43].

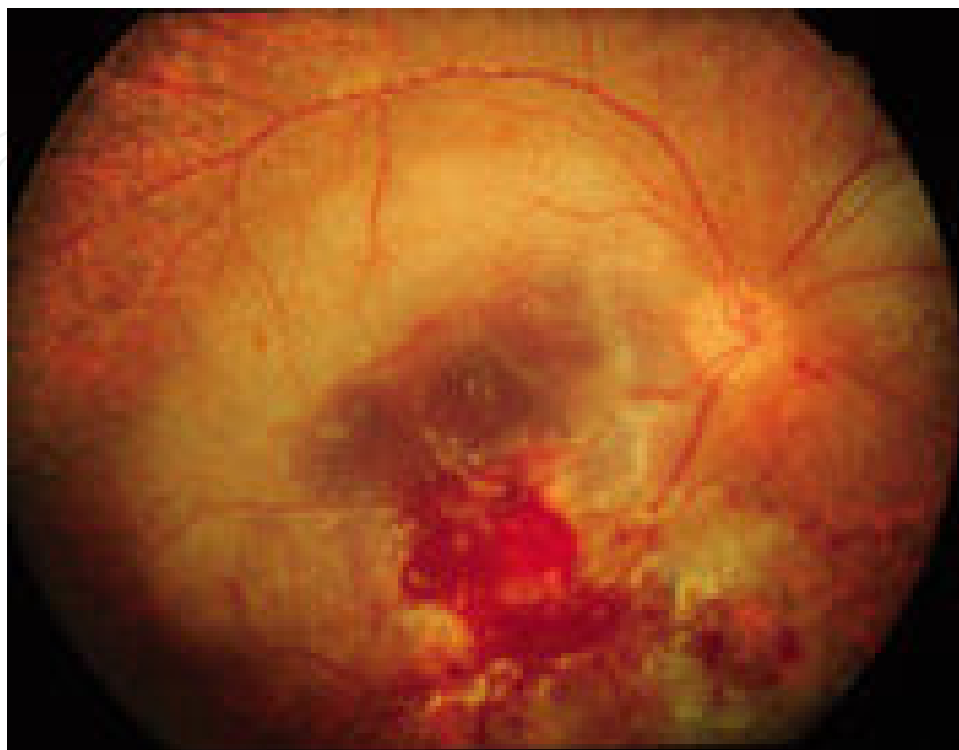

Figure 4. Reference [43]

CMV retinitis in a patient with AIDS appears as an arcuate zone of retinitis with extensive haemorrhages and optic disk swelling (figure 4) [43].

4.4. CMV neurological diseases

4.4.1. CMV Guillain–Barré Syndrome (GBS)

GBS has become the most frequent cause of acute flaccid paralysis in Western countries, following the near-elimination of poliomyelitis. The current annual incidence is estimated to be 0.75–2 cases/100 000 population. Infectious agents have been suggested as possible triggers of GBS, as some form of respiratory or gastrointestinal infection precedes nearly two-thirds of GBS cases. Infection with CMV is the most common antecedent virus infection, as identified by the presence of IgM antibodies in 10–15% of patients at the onset of GBS. However, antiviral therapy is currently not recommended in cases of GBS, since the disease is considered to be post infectious. Recently, the presence of CMV DNA has been demonstrated in almost one-third of serum and cerebrospinal fluid samples from GBS patients who were positive for CMV-specific antibodies at the onset of the neurological disease [43]

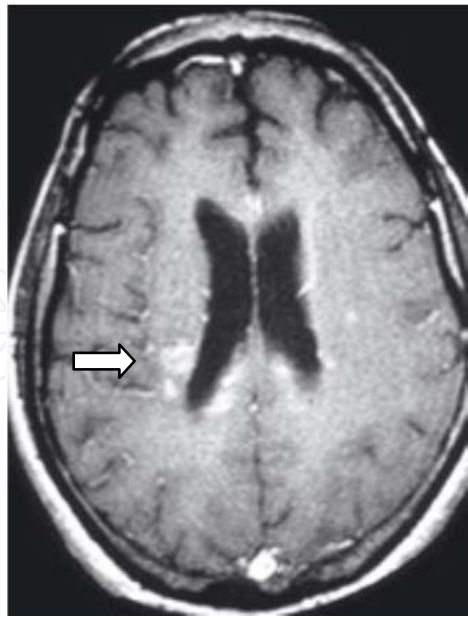

Figure 5. Reference [43]

4.4.2. *CMV ventriculoencephalitis*

This occurs rarely. It presents with changes in mental function. Multiple small, peri-ventricular lesions of the brain are detected following brain magnetic resonance imaging (arrow) (figure 5) [2,43].

4.5. CMV genitourinary diseases

4.5.1. *CMV Nephritis*

It can be defined by the detection of CMV infection by immunohistochemical analysis together with the identification of histological features of CMV infection in a kidney biopsy. Detection of CMV by PCR alone is insufficient for this diagnosis [42].

4.5.2. *CMV Cystitis*

This CMV disease is defined by detection of CMV by immunohistochemical together with identification of conventional histological features of CMV in a bladder biopsy obtained from patient with symptoms of cystitis [42].

4.6. CMV myocarditis

This occurs most frequently in heart transplant recipients. This infection is defined by the detection of CMV infection by immunohistochemical analysis together with the identification of conventional histological features of CMV infection in a heart biopsy specimen and CMV

PCR. Detection of CMV by PCR alone is insufficient for the diagnosis of CMV myocarditis [42]. There is an association between CMV and left ventricular dysfunction [2].

4.7. CMV vasculopathy

The CMV vasculopathy is considered to be an inflammatory disease. CMV and others organisms such as *Chlamydia pneumoniae*, Epstein Barr virus, herpes simplex virus-1, *Mycoplasma pneumoniae* and *Helicobacter pylori* are implicated, but evidence is strongest with CMV and *Chlamydia pneumoniae*. There is a correlation between CMV seropositivity and the presence of atherosclerosis, restenosis following and coronary angioplasty and transplant vascular sclerosis. CMV antigens and nucleic acids have been detected in atherosclerotic lesions in the different layers of the human aorta. Patients suffering from acute myocardial infarction have been found to develop CMV antigenaemia, reflecting either a primary infection or reactivation of a latent infection [44].

CMV infects cells in vessels on endothelial cells, smooth muscle cells and macrophages contribute to the slow progression and aggravation of atherosclerosis. The virus may also contribute to coronary thrombosis [44].

4.8. CMV associated Hemophagocytic Syndrome (HPS)

CMV hemophagocytic syndrome, also referred as macrophage activation syndrome (MAS) or haemophagocytic lymphohistiocytosis (HLH), is a reactive disorder, characterized by generalized histiocytic proliferation, with marked hemophagocytosis. This syndrome was first described by Risdull et al in 1979 in transplant patients [45]. There are two forms of HPS, familial erythrocytic lymphohistiocytosis and the secondary or reactive HPS [34,46,47].

Reactive or secondary HPS may develop during systemic infections, immunodeficiencies or malignancies. Infection-associated hemophagocytic syndrome (IAHS) is observed with viral infections (CMV, Epstein Barr virus, human herpes virus 8, human herpes virus 6, Parvovirus B19 or BK polyoma virus), bacterial infections (*Escherichia coli* and *Mycobacterium*), fungal infection (*Histoplasma*, *Pneumocystis*, and *Penicillium marneffei*), parasitic infections (toxoplasmosis, leishmaniasis or babesiosis). HPS may also develop as a complication of malignancies such as T-cell lymphomas and metastatic carcinomas. Secondary HPS to inflammatory/autoimmune disorders, including systemic lupus erythematosus, rheumatoid arthritis and Still's disease, or due anticonvulsants such as phenytoin and carbamazepine [34,45,46].

Cytomegalovirus has been associated with haemophagocytic syndrome in healthy patients, patients with inflammatory bowel diseases, rheumatological diseases, and transplant recipients [45,47].

The pathophysiology of HPS is not completely understood there is an activation of lymphohistiocytic tissue secondary to hypercytokinemia derived from the activation of T lymphocytes and activated macrophages, causing fever, shock, and organ dysfunction [48,49].

The HLH (Henter, 2004), (Emmenegger, 2005) diagnostic criteria are shown in Table 1,

The most typical signs of HPS are fever $\geq 38.3^{\circ}\text{C}$) and splenomegaly associated with pancytopenia (affecting ≥ 2 cell lineages in peripheral blood), hepatic enzyme abnormalities, hypertriglyceridemia or hypofibrinogenemia are common features of HPS. The diagnostic sensitivity of hypertriglyceridemia, hypofibrinogenemia and splenomegaly may be about 50%, but the diagnostic sensitivity of low NK cell activity and soluble CD25 levels approaches 100%. The histopathologic features are not pathognomonic. The most prominent feature is proliferation of histiocytes and hemophagocytosis in bone marrow, spleen, or lymph nodes, with no evidence of malignancy [34,45,48,49].

-
1. Fever: $\geq 101^{\circ}\text{F}$ ($\geq 38.3^{\circ}\text{C}$) for more than a week
 2. Splenomegaly: about 3 cm below the costal arch
 3. Absence of malignancy
 4. Cytopenia of ≥ 2 cell lines
Hemoglobin ≤ 9 g/dl, or platelets count $< 100,000/\mu\text{l}$, or neutrophil count $< 1,000/\mu\text{l}$
 5. Hypertriglyceridemia: Fasting triglycerides ≥ 265 mg/dl (> 3 mmol/l)
 6. Hypofibrinogenemia: < 1.5 g/l
 7. Serum ferritin > 500 $\mu\text{g/l}$
 8. Hemophagocytosis demonstrated in bone marrow, spleen, or lymph node
 9. Low or absent NK cell activity) $\geq 2,400$ U/ml
 10. Soluble CD25 (soluble interleukin-2 receptor) $\geq 2,400$ U/ml
-

Table 1. HLH-2004 Diagnostic criteria, References [48,49]

Therapy includes corticosteroids, cyclosporine, withdrawal of the immunosuppressant treatment, intravenous immunoglobulins (0.4g/ kg /day for 5 days) and antiviral treatment. The mortality rates are 30-40 % [45]. The hemophagocytic syndrome should be considered if a patient has fever of unknown origin, pancytopenia and multiorgan dysfunction [45,48,49].

Author details

A.L. Corona-Nakamura and M.J. Arias-Merino

From the Infectious Disease Department Specialities Hospital, West Medical Center, Instituto Mexicano del Seguro Social, Guadalajara, Jalisco, México

References

- [1] Nguyen Q, Estey E, Radd I, Rolston K, Kantarjian H, Jacobson K, et al. Cytomegalovirus Pneumonia in Adults with Leukemia: An Emerging Problem. *CID* 2001; 32: 539-45.

- [2] Paya CV, Razonable RR. Cytomegalovirus Infection after Solid Organ Transplantation. In: Bowden RA, Ljungman P, Paya CV, eds. *Transplant Infections*. 2nd ed. Philadelphia: Lippincott-Raven Publishers; 2003.p. 298-325.
- [3] Kandiel A, Lashner B. Cytomegalovirus Colitis Complicating Inflammatory Bowel Disease. *Am J Gastroenterol* 2006; 101: 2857-2865.
- [4] Lawlor G, and Moss AC. Clinical Review. Cytomegalovirus in Inflammatory Bowel Disease: Pathogen or Innocent Bystander? *Inflamm Bowel Dis* 2010; 16: 1620-1627.
- [5] Kuo CP, Wu CL, Ho HT, Chen CG, Liu SI and Lu YT. Detection of cytomegalovirus reactivation in cancer patients receiving chemotherapy. *Clin Microbiol Infect* 2008; 14:221-227.
- [6] Cascio A, Laria C, Ruggeri P, Fries W. Cytomegalovirus pneumonia in patients with inflammatory bowel disease: a systematic review. *Int J Infect Dis* 16 (2012) e474-e479.
- [7] Cytomegalovirus Prophylaxis following Solid Organ Transplants Guideline Team, Cincinnati Children's Hospital Medical Center: Evidence-based care guideline for CMV Prophylaxis following Solid Organ Transplant. Guideline 17, pages 1-16, July 6, 2007. www.cincinnatichildrens.org/svc/alpha/health-policy/ev-based/CMV-Transplant.htm.
- [8] Boeckh MJ, Ljungman P. Cytomegalovirus Infection after Hemopoietic Stem Cell Transplantation. In: Bowden RA, Ljungman P, Paya CV, eds. *Transplant Infections*. 2nd ed. Philadelphia: Lippincott-Raven Publishers; 2003.p. 277-397.
- [9] O'Brien SM, Keating MJ, Mocarski ES. Updated Guidelines on the Management of Cytomegalovirus Reactivation in Patients with Chronic Lymphocytic Leukemia Treated with Alemtuzumab. *Clin Lymphoma Myelom* 2006; 7 (2): 125-130.
- [10] Domenech E, Vega R, Ojanguren I, et al. Cytomegalovirus in Inflammatory Bowel Disease: Time for another look? *Gastroenterology* 2009; 137:1163-1175.
- [11] Tomblyn M., Chiller T, Einsele H, Gress R, Sepkowitz K, Storek J, et al. Guidelines for Preventing Infectious Complications among Hematopoietic Cell Transplantation Recipients: A Global Perspective. *Biol Blood Marrow Tr* 2009; 15:1143-1148.
- [12] Boeckh M. Complications, Diagnosis, Management, and Prevention of CMV Infections: Current and Future. *Hematology* 2011; 305-309.
- [13] Crumpacker C. S, Zhang JL. Citomegalovirus. In: Mandell GL, Bennett JE, Dolin R, eds. *Enfermedades Infecciosas. Principios y Práctica*. 7ma. Ed. Barcelona, España: Elsevier; 2012.p.1983-2000.
- [14] Kim EA, Lee KS, Primack SL, Yoon HK, Byun HS, Kim TS, et al. Viral Pneumonias in Adults: Radiologic and Pathologic Findings. *Radiographics* 2002; 22: S137-S149.

- [15] Corona Nakamura AL, Monteón Ramos FJ, Troyo Sanroman R, Arias Merino MJ, Anaya Prado R. Incidence and predictive factors for cytomegalovirus infection in renal transplant recipients. *Transplant Proc* 2009; 41:2412–5.
- [16] Kotton CN, and Fishman JA. Disease of the month. Viral Infection in the Renal Transplant Recipient. *J Am Soc Nephrol* 2005; 16, 1758-1774.
- [17] Sun H-Y, Wagener MM and Singh N. Prevention of Posttransplant Cytomegalovirus Disease and Related Outcomes with Valganciclovir: A Systematic Review. *Am J Transplant* 2008, 8: 2111-2118.
- [18] Asberg A, Humar A, Jardine AG, Rollag H, Pescovitz MD, Mouas H, *et al.* Long-Term Outcomes of CMV Disease Treatment with Valganciclovir Versus IV Ganciclovir in Solid Organ Transplant Recipients. *Am J Transplant* 2009; 9: 1205-1213.
- [19] Tamm M. The Lung in the Immunocompromised Patient. Thematic Review Series. *Respiration* 1999; 66: 199-207.
- [20] Takizawa Y, Inokuma S, Tanaka Y, Saito K, Atsumi T, Hirakata M, *et al.* Clinical characteristics of cytomegalovirus infection in rheumatic diseases: multicentre survey in a large patient population. *Rheumatology* 2008; 47:1373-1378.
- [21] Aries PM, Ullrich S, Gross WL. A case of destructive Wegener's granulomatosis complicated by cytomegalovirus infection. *Nature Clinical Practice Rheumatology* 2006; 2: 511-515.
- [22] Wade JC. Viral Infection in Patients with Hematological Malignancies. *Am Soc Hematol* 2006; 368-373.
- [23] Chemaly RF, Torres HA, Hachem RY, Nogueras GM, Aguilera EA, Younes A, *et al.* Cytomegalovirus Pneumonia in Patients with Lymphoma. *Cancer* 2005; 104 (6): 1213-1220.
- [24] Desai S, PharmD, and Pinilla-Ibarz J. Front-Line Therapy for Chronic Lymphocytic Leukemia. *Cancer Control* 2012; 19 (1): 26-36.
- [25] Thursky KA, Worth LJ, Seymour JF, Prince HM, and Slavin MA. Spectrum of infection, risk and recommendations for prophylaxis and screening among patients with lymphoproliferative disorders treated with alemtuzumab. *Brit J Haematol* 2005; 132: 3-12.
- [26] Badoux XC, Keating MJ, Wang X, O'Brien SM, Ferrajoli A, Fadert S, *et al.* Cyclophosphamide, fludarabine, alemtuzumab, and rituximab as salvage therapy for heavily pretreated patients with chronic lymphocytic leukemia. *Blood* 2011; 118 (8): 2085-2092.
- [27] Elter T, Hallek M, and Montillo M. Alemtuzumab: What Is the Secret to Safe Therapy?. *Clin Advan Hematol Oncol* 2011; 9 (5): 364-372.

- [28] Österborg A, Foá R, Bezares RF, Dearden C, Dyer MJS, Geisler C, Lin TS, *et al.* Review. Management guidelines for the use of alemtuzumab in chronic lymphocytic leukemia. *Leukemia* 2009; 23:1980-1988.
- [29] Cortelezzi A, Gritti G, Laurenti L, Cuneo A., Ciolli S, Di Renzo N, *et al.* An Italian retrospective study on the routine clinical use of low-dose alemtuzumab in relapsed/refractory chronic lymphocytic leukemia patients. *Brit J Haematol* 2011; 156:481-489.
- [30] Petersen CC, Nederby L, Roug AS, Skovbo A, Peterslund NA, Hokland P, *et al.* Increased Expression of CD69 on T Cells as an Early Immune Marker for Human Cytomegalovirus Reactivation in Chronic Lymphocytic Leukemia Patients. *Viral Immunol* 2011; 24 (2):165-169.
- [31] Cavallo R. The Laboratory of clinical virology in monitoring patients undergoing monoclonal antibody therapy. *Clin Microbiol Infect* 2011; 17: 1781-1785.
- [32] O'Brien S, Ravandi F, Riehl T, Wierda W, Huang X, Tarrand J, *et al.* Valganciclovir prevents cytomegalovirus reactivation in patients receiving alemtuzumab-based therapy. *Blood* 2008; 111(4): 1816-1819.
- [33] Kaufman M, Rai KR. Review. Alemtuzumab in the up-front setting. *Therapeutics and Clinical Risk Management* 2008; 4 (2):459-464.
- [34] Fisman DN. Synopsis. Hemophagocytic Syndromes and Infection. *Emerg Infect Dis* 2000; 6 (6): 601-608.
- [35] Montillo M, Tedeschi A, Petrizzi VB, Ricci F, Crugnola M, Spriano M, *et al.* An open – label, pilot study of fludarabine, cyclophosphamide, and alemtuzumab in relapsed/refractory patients with B-cell chronic lymphocytic leukemia. *Blood* 2011; 118(15): 4079-4085.
- [36] Elter T, Gercheva-Kyuchukova L, Pylypenko H, Robak T, Jaksic B, Rekhtman G, *et al.* Fludarabine plus alemtuzumab versus fludarabine alone in patients with previously treated chronic lymphocytic leukemia: a randomised phase 3 trial. www.thelancet.com/oncology 2011; 12:1204-1213.
- [37] Salomon N, Gomez T, Perlman DC, Laya L, Eber C, and Mildvan D. Clinical features and outcome of HIV-related cytomegalovirus Pneumonia. *AIDS* 1997, 11:319-324.
- [38] Ayyappan AP, Thomas R, Kurian S, Christopher DJ, and Cherian R. Multiple cavitating masses in an immunocompromised host with rheumatoid arthritis-related interstitial lung disease: an unusual expression of cytomegalovirus pneumonitis. *Brit J Radiol* 2006, 79: e174-e-176.
- [39] Moon JH, Kim EA, Lee KS, Kim TS, Jung KJ, and Song JH. Cytomegalovirus Pneumonia High-Resolution CT Findings in Ten Non-AIDS Immunocompromised Patients. *Korean J Radiol* 2000; 1: 73-78.
- [40] Vogel MN, Brodoefel H, Hierl T, Beck R, Bethge WA, Claussen CD *et al.* Differences and similarities of cytomegalovirus and pneumocystis Pneumonia in HIV-negative

immunocompromised patients- thin section CT morphology in the early phase of the disease. *Brit J Radiol* 2007; 80:516-523.

- [41] Ukarapol N, Chartapisak W, Lertprasertsuk N, Wongsawasdi L, Kattipattanapong V, Singhavejsakul J *et al.* Cytomegalovirus-Associated Manifestations Involving the Digestive Tract in Children With Human Immunodeficiency Virus Infection. *J Pediatr Gastroenterol Nutr* 2002; 35: 669-673.
- [42] Ljungman P, Griffiths P, Paya C. Definitions of Cytomegalovirus Infection and Disease in Transplant Recipients. *CID* 2002; 34 (15):1094-1097.
- [43] Steininger C. Clinical relevance of cytomegalovirus infection in patients with disorders of the immune system. *Clin Microbiol Infec* 2007; 13: 953–963.
- [44] Soderberg-Naucler C. Does cytomegalovirus play a causative role in the development of various inflammatory diseases and cancer? *J Int Med* 2006; 219-246.
- [45] Oloomi Z, Moayeri H. Cytomegalovirus Infection-Associated Hemophagocytic Syndrome. *Arch Iranian Med* 2006; 9 (3): 284-287.
- [46] Palazzi DL, McClain KL, and Kaplan SL. Major Article. Hemophagocytic Syndrome in Children: An Important Diagnostic Consideration in Fever of Unknown Origin. *CID* 2003; 36: 306-12.
- [47] Ponticelli C, and Della Casa Alberighi O. Editorial Reviews. Haemophagocytic syndrome- a life-threatening complication of renal transplantation. *Nephrol Dial Transpl* 2009; 24: 2623-2627.
- [48] Raschke RA, and Garcia-Orr R. Original Research. Critical Care. Hemophagocytic Lymphohistiocytosis. A Potentially Underrecognized Association With Systemic Inflammatory Response Syndrome, Severe Sepsis, and Septic Shock in Adults. *Chest* 2011; 140 (4): 933-938.
- [49] Núñez Bacarreza JJ, Montiel López L, and Núñez del Prado Alcoreza JR. Elsevier Doyma. Medicina Intensiva. Síndrome hemofagocítico asociado a infección viral por citomegalovirus. *Med Intensiva* 2011; 35 (3): 189-192.

