

We are IntechOpen, the world's leading publisher of Open Access books Built by scientists, for scientists

6,900

Open access books available

185,000

International authors and editors

200M

Downloads

Our authors are among the

154

Countries delivered to

TOP 1%

most cited scientists

12.2%

Contributors from top 500 universities



WEB OF SCIENCE™

Selection of our books indexed in the Book Citation Index
in Web of Science™ Core Collection (BKCI)

Interested in publishing with us?
Contact book.department@intechopen.com

Numbers displayed above are based on latest data collected.
For more information visit www.intechopen.com



Surgical Treatment for Diffuse Coronary Artery Diseases

Cheng-Xiong Gu, Yang Yu and Chuan Wang

Additional information is available at the end of the chapter

<http://dx.doi.org/10.5772/54416>

1. Introduction

Currently coronary artery bypass grafting (CABG) is the most commonly used procedure for revascularization of coronary heart disease. However it may not be suitable for the patients with diffuse coronary artery lesions, for which endarterectomy is a way but it's not feasible to thin coronary artery without inner lumen or to the immature plaque. In this case, it may be a proper therapeutic option to achieve coronary revascularization by retrograde perfusion via cardiac venous system, namely retrograde coronary venous bypass grafting (CVBG). [1] Saphenous veins could be used to realize arterialization for great or middle cardiac vein by separate or sequential bypass grafting. But it would cause myocardial hemorrhage, edema and even heart failure due to excessive perfusion by high pressure [2]. However, internal mammary artery (IMA), as one kind of muscular artery materials, can enlarge or contract its lumen to adjust the blood flow with strong adaptability [3]. Off-pump coronary artery bypass surgery (OPCAB) has been widely applied as a less invasive method of myocardial revascularization in recent years. It could avoid the systemic inflammatory effects caused by cardiopulmonary bypass (CPB). OPCAB has more merits such as low mortality, low morbidity, and reduced costs, especially in high risk patients [4]. Therefore, sequential bypass of bilateral IMA combined with arterialization for middle cardiac vein were carried out during OPCAB for patients with diffuse lesions existing in right coronary artery.

2. Definition & anatomy

Diffuse CAD was defined as: length of significant stenoses ≥ 20 mm; multiple significant stenoses ($\geq 70\%$ narrowing) in the same artery separated by segments of apparently normal (but probably diseased) vessel; and significant narrowing involving the whole length of the coronary artery [5] (Figure 1). Provided a mature plaque is successfully endarterectomized through

the true arterial lumen (Figure 2), patients with a long diffuse lesion can be treated very efficiently. But sometimes long, severe diffuse coronary artery stenosis isn't recommended for surgical treatment because of its low patency and more postoperative complications [6]. (Figure 3)

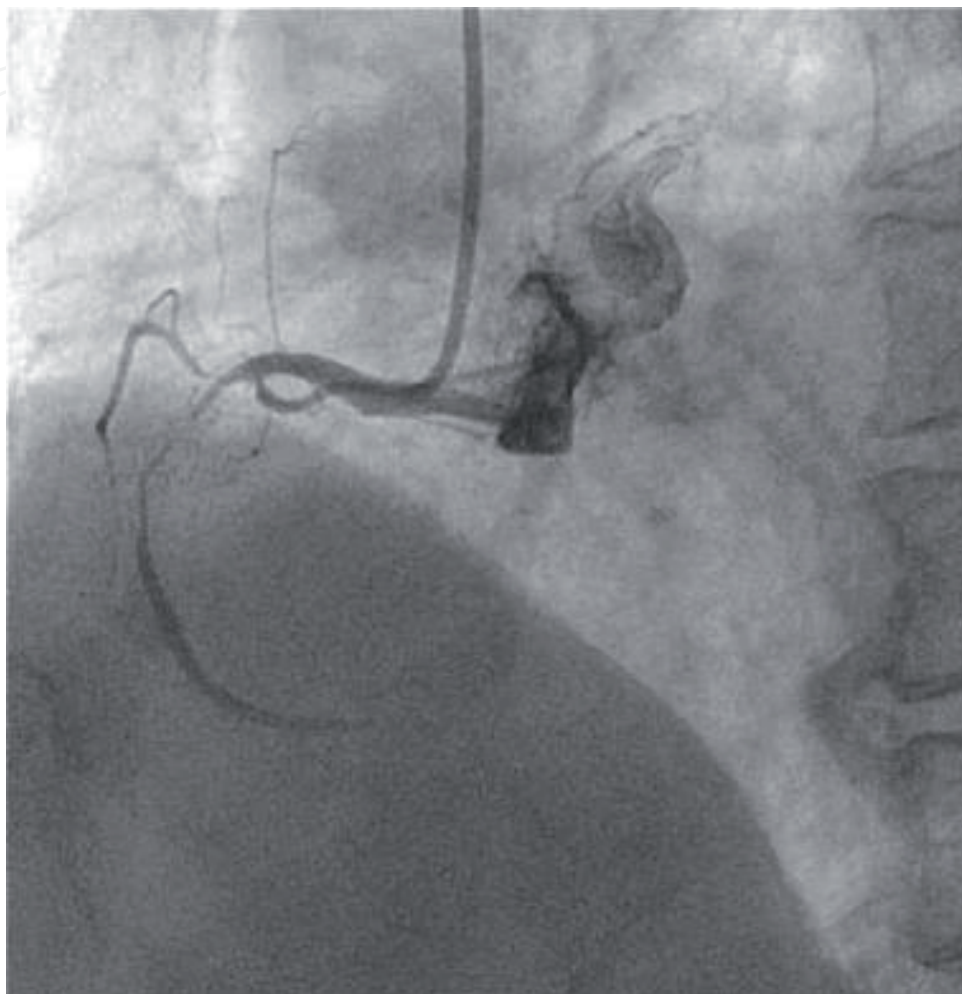


Figure 1. Diffuse CAD of the right coronary artery

3. History

The idea that the mammalian myocardium could be nourished by means of a flow of blood from the coronary venous system, acting as an alternative myocardial perfusion way because it would not be affected by atherosclerosis, was proposed by Pratt in 1898 [7]. However, few clinical trials and long-term outcome data have been presented and clinical use of venous arterialization has rarely been reported. Further experiments were made in 1943, in which the coronary sinus in a canine model was arterialized by using an autologous carotid artery as a conduit between the dogs descending aorta and the coronary sinus. In 1948, Beck and colleagues first carried out globally retroperfusion by CVBG through coronary sinus[8]. These

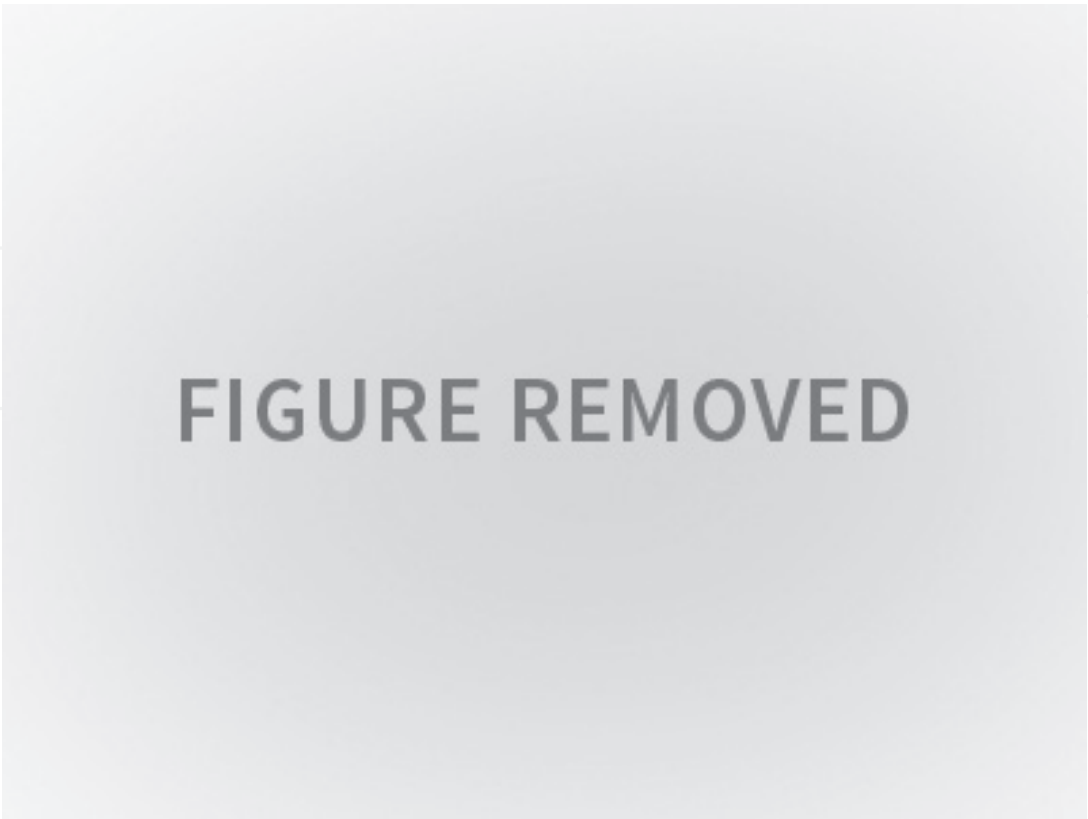

Figure 2. Mature plaque in the blocked coronary artery
(Notice: the figure is removed at the request of the copyright holder [2016-06-21])

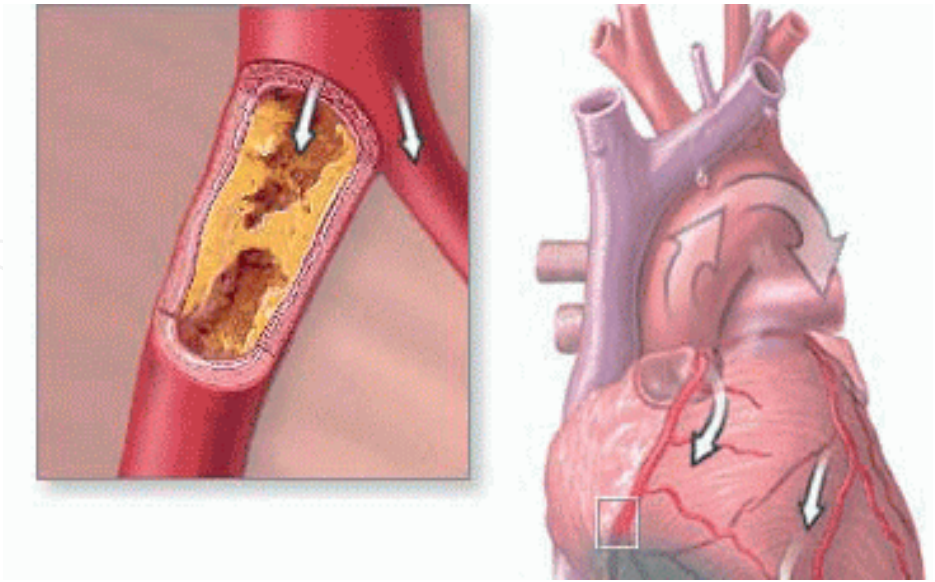


Figure 3. Diffuse coronary artery with immature plaque

findings led them to state that there are communications between the venous and arterial sides of the circulation which, in the dead specimen, allowed blood flow in a retrograde direction. The Beck II procedure afterwards consisted of a free vein graft from the aorta to the coronary sinus, with a second operation 2 to 3 weeks later to ligate the coronary sinus, which reported remarkable success in attempts to revascularize the heart. The effectiveness of reversing flow in the coronary venous system had been debated and this operation was gradually abandoned because of related mortality of 26.1% and development of CABG. However, CABG was soon discovered to have its own limitations, particularly in patients with diffuse atherosclerotic lesion and tiny coronary arteries. Arterialization of coronary veins therefore regained its appeal. Arealis and colleagues brought forth selective CVBG in 1973 which was made only for part of ischemic myocardium, while normal reflux was kept for the rest myocardial veins. Great cardiac vein parallel to LAD and middle cardiac vein parallel to PDA were selected as goal vessels. Eventually an ample report of CVBG animal trial was published by Dr. Hochberg in 1979 which indicated CVBG's advantages, such as perfusion all layers of the myocardium, especially the subendocardium – the crucial layer of myocardial muscle[2]. However, this mechanism had been studied at the experimental level because its relatively high clinical mortality and was only theoretic until CVBG technique developed in the recent years.

4. Preclinical study and animal trials

Historically, most studies of revascularization have been based on and reported according to angiographic criteria. Some patients with significant arteriosclerosis of the heart are not amenable to revascularization of a coronary artery because they have a combination of microangiopathy and significant macroangiopathy. Therefore cardiac surgeons developed the technical approach of venous revascularization. Several systematic reviews have been conducted in an attempt to define the exact role of animal models as platforms for future human therapy [9-12]. We investigated the benefit of arterialization of a cardiac vein under these circumstances in some animal models [13] which indicate retrograde venous revascularization is possible and improves cardiac function in a state of acute ischemia so we could find its way into practical use in coronary heart surgery. In experimental studies in a variety of animals and in human clinical studies, retroperfusion of the coronary sinus has been used to improve myocardial perfusion and postischemic systolic and diastolic function in many surgical procedures. In addition, animal trials, mostly involving sheep, dogs and pigs showed that arterialization of cardiac veins decreases infarct size as well[11,14]. These animal models are likely to be useful for pre-clinical evaluation of the functional effects of surgical therapy.

5. Surgical option – CVBG versus traditional CABG

There is no doubt that for patients with surgical triple-vessel coronary disease and a severely diseased left main artery, CABG appears to be preferable [15]. Despite constant advances in surgical and interventional therapy of coronary artery disease, there remains a group of

patients who are not amenable to these traditional treatment strategies. Many patients being referred for CABG nowadays have far advanced CAD, which is often diffuse and exhibits poor vessel runoff. The idea of myocardial revascularization by means of grafting the coronary venous system is more than a century old; in cases of diffuse coronary artery disease, this may represent a valid therapeutic option [16].

The lack of suitable targets vessels remains a challenge for aortocoronary bypass grafting in diffuse coronary heart disease. Although this figure approximates 20% to 50% frequency reported in many series [17], our study represents a highly selective group with diffuse coronary disease in which CABG was not feasible with or without an endarterectomy.

5.1. Data analysis

From March 2004 to August 2010, patients with diffuse right coronary lesions were studied retrospectively and divided into two groups (Table1). Informed consent and ethical review committee approval were obtained. Group 1 included seventeen patients who underwent selective CVBG during OPCAB while group 2 included twenty-one patients without right coronary artery surgical therapy. Group 1 included eleven male cases (64.7%), the mean age was (46.1 ± 6.2) years, seven hypertension cases (41.2%) and ten diabetes mellitus (58.8%) cases were involved. The case number of cardiac function from II–IV grade was eight, eight, and one respectively. Left ventricular ejection fraction (LVEF) was 0.52 ± 0.09 and left ventricular end diastolic diameter (LVEDD) was (52.7 ± 5.1) mm. Group 2 included fourteen male cases (66.7%), the mean age was (45.9 ± 5.7) years, nine hypertension cases (42.9%) and eleven diabetes mellitus (52.4%) cases were involved. The case number of cardiac function from II–IV level was twelve, seven, two respectively. LVEF was 0.52 ± 0.11 and LVEDD was (51.9 ± 5.2) mm. There was no significant difference between the two groups ($P > 0.05$). All the patients had angina pectoris symptom before operation. It was indicated by electrocardiogram that all the cases with old myocardial infarction had obvious ST-T changes. Coronary angiography showed that seven cases had double-vessel lesions and ten cases had triple-vessel lesions in group 1; nine cases had double-vessel lesions and twelve cases had triple-vessel lesions in group 2. Right coronary artery of all the patients took on diffuse lesions with vascular diameter < 1 mm and length > 20 mm. It was shown by vascular ultrasound examination that blood flow in bilateral mammary artery was smooth and vascular diameter > 2 mm; and left subclavian artery was not narrow.

OPCAB was performed with an average of 3.6 grafts per patient, group 1 being (3.3 ± 1.1) grafts and group 2 being (2.2 ± 1.6) grafts respectively. These patients discharged eight to fourteen days after the operation. Determination of blood flow was made for eleven cases in group 1 and thirteen cases in group 2 which were (81.47 ± 32.65) ml/min and (76.82 ± 28.36) ml/min in trunk of IMA, (32.52 ± 18.82) ml/min and (28.12 ± 16.71) ml/min in trunk of left IMA, (39.63 ± 19.02) ml/min and (35.92 ± 18.34) ml/min in trunk of right IMA. The both groups had no death. Tracheal cannula was pulled out on the date of operation or one day after operation. Low-dose positive inotropic drugs were used as assistance for four cases postoperatively. All the patients had no brain complication and no infection of sternum and mediastinum.

	Group 1 N=17	Group 2 N=21
Gender (M/F)	11/6	14/7
Age (years)	46.1±6.2	45.9±5.7
Hypertension (yes/no)	7/10	9/12
Diabetes mellitus (yes/no)	10/7	11/10
LVEF	0.52±0.09	0.52±0.11
LVEDD (mm)	52.7±5.1	51.9±5.2
Coronary angiography		
Double-vessel lesions	7	9
Triple-vessel lesions	10	12

LVEF: Left ventricular ejection fraction; *LVEDD*, left ventricular end diastolic diameter.

Table 1. Characteristics of patients

5.2. Surgical procedure

5.2.1. General surgical procedure

In group 1, standard median sternotomy incision was applied for the exposure of the heart under general anesthesia. Bilateral IMAs were harvested as longer as possible and usually cut proximally at the starting position from subclavian artery and distally on the level of Xiphoid. Surrounding tissues of IMA were desected and removed so as to ensure enough length of IMA (generally 18–25 cm). The free right IMA was anastomosed with left IMA to form a bifurcation as “Y” type. The anastomotic position on the LIMA should be determined according to its length and the distance from the bypass grafting anastomosis between LIMA and LAD or diagonal. The position was usually selected at the location of 3–4 cm proximal to the first anastomotic site of left IMA, and 8-0 prolene suture was utilized in end-to-side anastomosis between two mammary arteries. Subsequently, CABG was carried out on beating heart. Left IMA was anastomosed to left anterior descending artery (LAD) and then right IMA was sequentially anastomosed with diagonal branch and circumflex artery (obtuse marginal and posterior branch of the left ventricle). Then the end of middle cardiac vein proximal to heart was blocked with 6-0 prolene suture so that blood can not reflow to coronary sinus in normal way. Finally, end-to-side anastomosis between middle cardiac vein parallel to right coronary post descending artery (PDA) and right IMA was performed with 8-0 prolene suture. When all the vessels were anastomosed and blood circulation was stable, blood flow of grafting vessels was determined by Transonic H1311 flowmeter (Transonic Systems, Inc., Ithaca, NY, USA). Incision was carefully washed before closing chest. In group 2, no branch of the right coronary artery was bypass grafted.

5.2.2. Unique surgical procedure – Blood flow limitation

Venous arterialization occurs when a vein segment is transposed as a bypass graft into the arterial circulation, and atherosclerosis is a common feature of autogenous vein bypass grafts resulting in their long-term failure [18-20]. Arterial pressure-induced distension is thought to play a major role in the wall thickening of vein grafts, which may in turn favor atherosclerotic complications [21,22]. Reduction of the wall distension by perfusion pressure reduction using blood flow limitation protected the vein grafts from atherosclerosis, possibly as a result of the decrease in wall thickening that occurred in response to arterialization [23,24].

Saphenous vein was commonly used to complete CVBG. After harvesting, meticulous care should be taken to avoid distention of the vein graft. An infusion pressure of no more than 100 mmHg is recommended for minimal endothelial damage [25]. In our previous study and emerged that ischemia and infarction of myocardium would happen if the blood flow in grafting vessel was less than 50 ml/min. The blood was delivered into the cardiac veins by the native arterial pressure. However when intravascular pressure reached 60 mm Hg (1 mmHg = 0.133 kPa) or higher, the risk of complications would increase such as myocardial edema and even intramural hemorrhage and so on [26]. In this case, we used to ligate the vein graft to 1.5 to 2 mm in diameter with two interrupted silk lines to control blood flow (Figure 4). It has been reported that infarct size can be reduced by which arterial blood is delivered retrogradely to the ischemic myocardium through the cardiac veins [27].

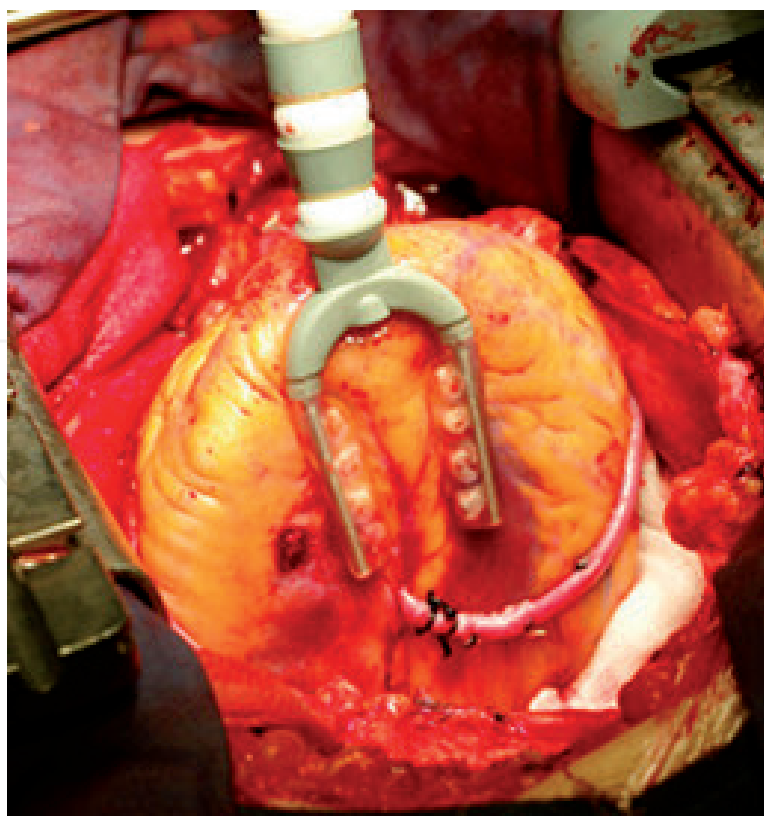


Figure 4. Flow-limited CVBG

5.3. Follow up

Three months after discharge, all the patients in group 1 had no preoperative symptom. Myocardial ischemia was not found by electrocardiogram in group 1. Postoperative angina was found in eight cases of group 2 and electrocardiogram showed inferior wall myocardial ischemia. There was significant difference between the two groups ($P < 0.05$). Cardiac function was improved to class I ($P < 0.001$), LVEF was increased to 0.60 ± 0.08 ($P < 0.001$) in group 1 and 0.56 ± 0.10 ($P < 0.001$) in group 2 which showed no preoperative differences and the postoperative LVEF of group 1 was superior to group 2 while there was no significant difference between these two groups. LVEDD decreased to (48.1 ± 3.4) mm ($P < 0.001$) in group 1 and (47.2 ± 3.5) mm ($P < 0.001$) in group 2. Patients underwent physical examination and echocardiography in our outpatient clinic periodically after discharge. These data were compared with the patients' preoperative variables. Several examination of myocardial nuclide imaging, coronary angiography (41 months postop.) and CT scanning (5 years postop.) were carried out (Figure 5).

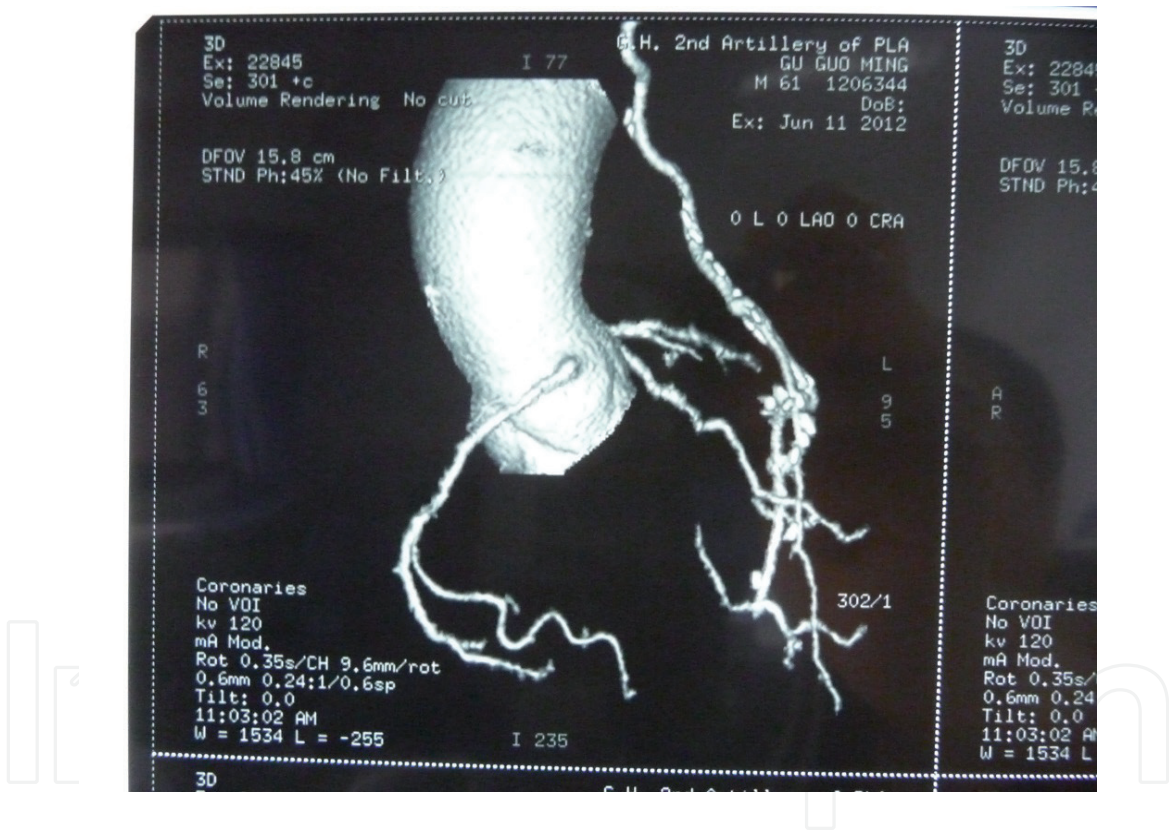


Figure 5. follow-up CT scanning data of CVBG.

6. Conclusion

In the past few decades, there was an increase in the number of patients with coronary heart disease who were not eligible for standard procedures including CABG and percutaneous coronary angioplasty, and diffuse coronary atherosclerosis occupies 12%–30% of patients

requiring further intervention [28]. Clinical trials investigating treatment with angiogenesis factors and gene therapy have been initiated, and new devices for creating cardiac arteriovenous fistulas percutaneously have also been introduced [29-32]. Whereas injection of growth factors require an adequate arterial inflow, which is not often existent in the hearts of these “no option patients”. New catheter devices to create a fistula between a coronary artery and the accompanying vein or, as performed in animal experiments, a coronary vein and the left ventricle, are difficult to handle, and hold all the risks of catheterization of a severely altered vessel [33]. Before that, small numbers of reports of the clinical application had published, so no remarkable conclusions can be yet drawn [34-37]. As the efficiency of these new methods awaits the evaluation of long-term trials, we think that some patients might benefit from the revival of an “old” procedure that is retrograde venous revascularization. In both short and long-term experiments, effective selected area perfusion had been achieved.

Despite the successful and widespread application of these revascularization procedures, a large number of patients are not good candidates for either angioplasty or surgery. These “no-option” patients frequently have diffuse coronary disease without a discrete target for angioplasty, stenting, or surgical bypass [33]. In clinical application, we draw some experiences as follows. Blood flow of IMA is important to ensure perfusion of myocardium after bypass grafting which can be determined by preoperative vascular ultrasound examination and intraoperative testing. It is also important to make sure the diameter of each anastomotic incision 1.5 times as that of IMA in order to keep adequate blood flow. For the patients with coronary vessel less than 1.5 mm in diameter, it is necessary to use 8-0 prolene suture in case of anastomotic stricture. Attention should be focused on not damaging the posterior wall of middle cardiac vein while opening it, because the vascular wall of coronary vein is obviously thinner than that of coronary artery. The graft should be fixed to myocardium on both sides because IMA and middle cardiac vein are prone to twist due to different thickness of vascular wall. It is valuable to observe the difference of color on both segments of middle cardiac vein in the ligation. If red and dark are distinctive, it is indicated the ligation is definite. Otherwise it is possible that there is some residue blood flow [38]. It is useful to measure blood flow of each graft with flowmeter after anastomosis in order to keep vessel grafting patent.

CVBG surgery is indicated for both the relief of symptoms and the improvement of life expectancy in patients suffering from diffuse coronary heart disease [39-41]. We believe the selective CVBG should be considered in cases of coronary artery disease not amenable to traditional revascularization strategies [42-45]. Indications of selective CVBG include the patients with tenuous right coronary artery or diffuse lesions. It is possibly fit for the patients who need reoperation of CABG as well [46-48]. A substantial improvement in the long-term prognosis may be expected with more precise anastomosis.

Author details

Cheng-Xiong Gu, Yang Yu and Chuan Wang

6 Department of Cardiac Surgery, Beijing An Zhen Hospital, Capital Medical University, Beijing, China

References

- [1] YU Yang, YAN Xiao-lei, Gu cheng-xiong, et al. Off-pump sequential bilateral internal mammary artery grafting combined with selective arterialization of the coronary venous system. *Chinese Medical Journal* 2011;124(19):3017-3021
- [2] Hochberg MS, Roberts WC, Morrow AG, Austen WG.. Selective arterialization of the coronary venous system. Encouraging long-term flow evaluation utilizing radioactive microspheres. *J Thorac Cardiovasc Surg* 1979; 77: 1-12.
- [3] Rankin JS, Tuttle RH, Wechsler AS, Teichmann TL, Glower DD, Califf RM. Techniques and benefits of multiple internal mammary artery bypass at 20 years of follow-up. *Ann Thorac Surg* 2007; 83: 1008-1014.
- [4] Guru V, Glasgow KW, Froles SE, Austin PC, Teoh K, Tu JV. The real-world outcomes of off-pump coronary artery bypass surgery in a public health care system. *Can J Cardiol* 2007;23: 281-286.
- [5] Di Sciascio G, Patti G, Nasso G, Manzoli A, D'Ambrosio A, Abbate A. Early and longterm results of stenting of diffuse coronary artery disease. *Am J Cardiol* 2000;86:1166-70.
- [6] Jeffrey H. Shuhaiber, Alexander N. Evans, Malek G. Massad, Alexander S. Geha et al. Mechanisms and future directions for prevention of vein graft failure in coronary bypass surgery. *European Journal of Cardio-thoracic Surgery* 22 (2002) 387-396.
- [7] Pratt FH. The circulation through the veins of Thebesius. *J Boston Soc Med Sci* 1897; 1: 29-34.
- [8] Beck CS, Stanton E, Batiuchok W. Revascularization of the heart by graft or systemic artery into the coronary sinus. *JAMA* 1948; 137: 436-442.
- [9] R.W. Eckstein, George Smith, Morton Eleff and James Demming. The Effect of Arterialization of the Coronary Sinus in Dogs on Mortality Following Acute Coronary Occlusion. *Circulation* 1952;6:16-20
- [10] Mark S. Hochberg, and W. Gerald Austen, Selective Retrograde Coronary Venous Perfusion, *Ann Thorac Surg* 1980;29:578-588
- [11] Peter Boekstegers, Wolfgang Peter, Georges Von Degenfeld, et al. Preservation of Regional Myocardial Function and Myocardial Oxygen Tension During Acute Ischemia in Pigs: Comparison of selective Synchronized Suction and Retroinfusion of Coronary Veins to Synchronized Coronary Venous Retroperfusion. *J Awn Coll Cardiol* 1994, 23 :45'9-69.
- [12] Stephanie Kwei, George Stavrakis, Masaya Takahas, et al. Early Adaptive Responses of the Vascular Wall during Venous Arterialization in Mice. *American Journal of Pathology*, Vol. 164, No. 1, January 2004.

- [13] Michaela Elisabeth Resetar, Cris Ullmann, Petra Broeske et al. Selective arterialization of a cardiac vein in a model of cardiac microangiopathy and macroangiopathy in sheep. *The Journal of Thoracic and Cardiovascular Surgery*. May 2007
- [14] J. Kevin Drury, Shigeru Yamazaki, Michael C. Fishbein, et al. Synchronized Diastolic Coronary Venous Retroperfusion: Results of a Preclinical Safety and Efficacy Study, *J Am Coll Cardiol* 1985;6:328-35
- [15] Donald E. Gregg and David C. Sabiston, JR. Current Research and Problems of the Coronary Circulation. *Circulation* 1956;13:916-927.
- [16] J. Rafael Sadaba, FRCS, and Unnikrishnan R. Nair, FRCS. Selective Arterialization of the Coronary Venous System. *Ann Thorac Surg* 2004;78:1458–60
- [17] Richard S. Hahn, Maurice Kim, Revascularization of the Heart Histologic Changes after Arterialization of the Coronary Sinus. *Circulation* 1952;5:810-815.
- [18] Glen R. Rhodes, Donald C. Syracuse, and Charles L. McIntosh. Evaluation of Regional Myocardial Nutrient Perfusion Following Selective Retrograde Arterialization of the Coronary Vein. *The Annals of Thoracic Surgery* Vol 25 No 4 April 1978.
- [19] Raymond C. Truex and Martin J. Schwartz, Venous System of the Myocardium with Special Reference to the Conduction System. *Circulation* 1951;4:881-889
- [20] A Zalewski, S Goldberg, S Slysh and PR Maroko, Myocardial protection via coronary sinus interventions: superior effects of arterialization compared with intermittent occlusion. *Circulation* 1985;71:1215-1223.
- [21] J. Rafael Sadaba, FRCS, and Unnikrishnan R. Nair, FRCS, Selective Arterialization of the Coronary Venous System, *Ann Thorac Surg* 2004;78:1458–60.
- [22] Jean Batellier, Michel Wassef, Regine Merval, Micheline Duriez, and Alain Tedgui. Protection From Atherosclerosis in Vein Grafts by a Rigid External Support. *Arteriosclerosis and Thrombosis* Vol 13, No 3 March 1993.
- [23] Stephanie Kwei, George Stavrakis, Masaya Takahas, George Taylor, et al. Early Adaptive Responses of the Vascular Wall during Venous Arterialization in Mice. *AJP* January 2004, Vol. 164, No. 1
- [24] Adcock Jr OT, Adcock GL, Wheeler JR, et al. Optimal techniques for harvesting and preparation of reversed autogenous vein grafts for use as arterial substitutes: a review. *Surgery* 1984;96(5):886–894.
- [25] Malte Meesmann, Hrayr S. Karagueuzian, Takeshi, et al. Selective Perfusion of Ischemic Myocardium During Coronary Venous Retroinjection: A Study of the Causative Role of Venoarterial and Venoventricular Pressure Gradients, *J Am Coll Cardiol* 1987;10:887-97.

- [26] Andrew Zalewski, Sheldon Goldberg, Sonya Slysh, et al. Myocardial protection via coronary sinus interventions: superior effects of arterialization compared with intermittent occlusion. *Circulation* 71, No. 6, 1215-1223, 1985.
- [27] Sherif E. Moustafa, Kenton Zehr, Martina Mookadam, et al. Anomalous interarterial left coronary artery: An evidence based systematic overview. *International Journal of Cardiology* 126 (2008) 13–20.
- [28] Nabil Dib, Edward. Diethrich, Ann Campbell, Amir Gahremanpour, et al. A percutaneous swine model of myocardial infarction. *Journal of Pharmacological and Toxicological Methods* 53 (2006) 256– 263.
- [29] Emerson. Perin, Guilherme. Silva, Yi Zheng, Human Hepatocyte Growth Factor (VM202) Gene Therapy via Transendocardial Injection in a Pig Model of Chronic Myocardial Ischemia. *Journal of Cardiac Failure* Vol. 17 No. 7 July 2011.
- [30] Nabil Dib, Edward. Diethrich, Ann Campbell, Amir Gahremanpour, et al. A percutaneous swine model of myocardial infarction, / *Journal of Pharmacological and Toxicological Methods* 53 (2006) 256– 263.
- [31] ML Marcus, WM Chilian, H Kanatsuka, KC Dellsperger, CL Eastham and KG Lamping, Understanding the coronary circulation through studies at the microvascular level, *Circulation* 1990;82;1-7.
- [32] Stephen N. Oesterle, Nicolaus Reifart, Eugen Hauptmann, et al. Percutaneous In Situ Coronary Venous Arterialization Report of the First Human Catheter-Based Coronary Artery Bypass. *Circulation* 2001;103;2539-2543
- [33] GM Hutchins, A Kessler-Hanna and GW Moore, Development of the coronary arteries in the embryonic human heart, *Circulation* 1988;77;1250-1257.
- [34] Kurt Wallner, Chen Li, Michael C. Fishbein, Arterialization of Human Vein Grafts Is Associated With Tenascin-C Expression, *Journal of the American College of Cardiology* Vol. 34, No. 3, 1999.
- [35] Alexander Kulik, Michael A. Borger and Hugh E. Scully, Aortovenous bypass graft to the posterior left ventricle in absence of an identifiable coronary artery, *Ann Thorac Surg* 2004;78:313-314
- [36] Anke M. Smits¹, Jos F.M. Smits, Ischemic heart disease: models of myocardial hypertrophy and infarction. *Drug Discovery Today: Disease Models*, Vol. 1. No. 3 2004.
- [37] Harold L. Lazar, Coronary sinus retroperfusion: Can forward progress still be achieved by using a backward technique? *The Journal of Thoracic and Cardiovascular Surgery*. Volume 127, Number 6, June 2004.
- [38] Karl Mischke, Christian Knackstedt, Georg Mühlenbruch, Thomas Schimpf, et al. Imaging of the coronary venous system: Retrograde coronary sinus angiography ver-

sus venous phase coronary angiograms. *International Journal of Cardiology* 119 (2007) 339–343.

- [39] Tomoko Tani, Kazuaki Tanabe, Minako Tani, Fumie Ono, et al. Quantitative assessment of harmonic power doppler myocardial perfusion imaging with intravenous levovist in patients with myocardial infarction: comparison with myocardial viability evaluated by coronary flow reserve and coronary flow pattern of infarct-related artery. *Cardiovascular Ultrasound* 2005, 3:22.
- [40] Michaela Elisabeth Resetar, Cris Ullmann, Petra Broeske, et al. Selective arterialization of a cardiac vein in a model of cardiac microangiopathy and macroangiopathy in sheep. *The Journal of Thoracic and Cardiovascular Surgery*, Volume 133, Number 5, May 2007.
- [41] Egemen Tuzun, Eddie Oliveira, Cuneyt Narin, Hassan Khalil, et al. Correlation of Ischemic Area and Coronary Flow With Ameroid Size in a Porcine Model. *Journal of Surgical Research* Vol. 164, NO. 1, NOVEMBER 2010, 164, 38–42 (2010)
- [42] Aaron M. Abarbanell, Jeremy L. Herrmann, Brent R. Weil, et al. RESEARCH REVIEW Animal Models of Myocardial and Vascular Injury, *Journal of surgical research: VOL. 162, NO. 2, aug 2010*, 239–249.
- [43] Masanori Fujita, Yuji Morimoto, Masayuki Ishihara, Masafumi Shimizu, et al. A New Rabbit Model of Myocardial Infarction without Endotracheal Intubation. *Journal of Surgical Research: Vol. 116, No. 1, January 2004*, 124–128 116.
- [44] Nabil Dib, Edward B. Diethrich, Ann Campbell, Amir Gahremanpour, et al. A percutaneous swine model of myocardial infarction, *Journal of Pharmacological and Toxicological Methods* 53 (2006) 256– 263.
- [45] Alexander Kulik, Michael A. Borger, and Hugh E. Scully, Aortovenous Bypass Graft to the Posterior Left Ventricle in Absence of an Identifiable Coronary Artery. *Ann Thorac Surg* 2004;78:314–6
- [46] E. Marc Jolicœur, MSc, Christopher. Granger, Timothy. et al. Clinical and research issues regarding chronic advanced coronary artery disease: Part I: Contemporary and emerging therapies. *American Heart Journal* Volume 155, Number 3. March 2008.
- [47] Armando Pérez de Prado, Carlos Cuellas-Ramón, Marta Regueiro-Purriños, J. Manuel Gonzalo-Orden, et al. Closed-chest experimental porcine model of acute myocardial infarction–reperfusion. *Journal of Pharmacological and Toxicological Methods*. 60 (2009) 301–306.
- [48] Yasuhiro Shudo, Shigeru Miyagawa, Satsuki Fukushima, Atsuhiko Saito, et al. Novel regenerative therapy using cell-sheet covered with omentum flap delivers a huge number of cells in a porcine myocardial infarction model. *The Journal of Thoracic and Cardiovascular Surgery* c Volume 142, Number 5 November 2011.

