

We are IntechOpen, the world's leading publisher of Open Access books Built by scientists, for scientists

6,900

Open access books available

186,000

International authors and editors

200M

Downloads

Our authors are among the

154

Countries delivered to

TOP 1%

most cited scientists

12.2%

Contributors from top 500 universities



WEB OF SCIENCE™

Selection of our books indexed in the Book Citation Index
in Web of Science™ Core Collection (BKCI)

Interested in publishing with us?
Contact book.department@intechopen.com

Numbers displayed above are based on latest data collected.
For more information visit www.intechopen.com



A Noninvasive Alternative to Coronary Angiography: Myocardial Contrast Echocardiography Following Strain Map as a Gate Way to Myocardial Contrast Echocardiography Map

Ri-ichiro Kakiyara

Additional information is available at the end of the chapter

<http://dx.doi.org/10.5772/45953>

1. Introduction

[Background] Segmental left ventricular (LV) wall systolic dysfunction has been considered a significant sign of coronary artery disease (CAD) for many years. However, it is well known that many heart diseases besides CAD cause abnormal LV wall motion. Therefore, it is essential to verify that segmental LV wall systolic dysfunction is due to myocardial ischemia. Although coronary angiography is typically used to determine the clinical significance of CAD, it is also possible to visualize areas of ischemic myocardium noninvasively by echocardiography using microbubble contrast agents. Perfluorobutane microbubbles, consisting of a hydrogenated egg-phosphatidylserine shell encapsulating perfluorobutane gas, offers the advantage of resistance to destruction by ultrasound, thus enabling repeated scans per injection.

[Methods] We used phase-inversion harmonic ultrasonography to assess the ability of perfluorobutane microbubbles to detect ischemic myocardial areas due to coronary artery stenosis in 66 patients who had undergone coronary angiography (CAG). Abnormal LV wall motion was detected by longitudinal strain before CAG. Pre and post-injection images were evaluated from late-diastolic points along the time-intensity curve.

[Results] The injection of perfluorobutane microbubbles caused a significant change in intensity in the left ventricular wall in the AP and SAX views in segments perfused by normal coronary arteries ($p < 0.0001$), but not in segments perfused by arteries with significant ($\geq 75\%$) stenosis. Receiver operating characteristic curve analysis showed that an intensity dif-

ference ≤ 6.3 dB in the AP view could detect $\geq 75\%$ stenosis with a sensitivity of 98%, specificity of 94% and accuracy of 97%. An intensity difference ≤ 5.1 dB in the SAX view could detect $\geq 75\%$ stenosis with a sensitivity of 97%, specificity of 96% and accuracy of 97%.

[Conclusions] These data indicate that when optimal signal intensity difference parameters have been accurately defined, perfluorobutane microbubbles can be used safely for highly sensitive, specific and accurate visualization of ischemic myocardial areas due to coronary artery stenosis.

2. Background

The ability to prevent, diagnosis and treat cardiac disease has improved over the last two decades due to the remarkable and seemingly exponential advances in imaging technology [1,2,3,4]. Ironically, the surprising increases in computing power and software design now at the physician's disposal have been greatly enhanced by the advent of a relatively uncomplicated and a readily-synthesized molecule, the microbubble. Perfluorobutane microbubbles consist of a macromolecular shell encapsulating a high molecular weight gas [5] and are typically 1 to 10 μ in diameter. Their small size allows them to be introduced safely into the circulatory system where they enhance ultrasonic wave scattering by blood, thereby providing higher contrast to ultrasound images of the left ventricular myocardial wall. Ultrascanners operating at frequencies < 15 MHz oscillate the microbubbles, which results in increased echo contrast. The vibrating microbubbles also emit harmonic signals that can preferentially enhance the signal-to-noise ratio. In addition to their diagnostic advantages, microbubbles also avoid the use of radiation and are generally more economical to use. Microbubble ultrasound technology has been used to image other organs besides the heart (liver, pancreas, breast and kidney, in particular), and can be used to target drug-delivery vehicles to different organs [6]. Basic biomedical researchers are also benefitting from microbubble reagents for delivering macromolecules, such as plasmid DNAs, into cells [7].

Two microbubble contrast agents for cardiac echocardiography, OPTISONTM and DefinityTM, are approved for use in the United States, SonoVueTM is approved in Europe and China, and Levovist in Japan. But OPTISONTM and DefinityTM are used for opacification of the left ventricular cavity and endocardial border definition only. Levovist is used for myocardial contrast echocardiography (MCE). Safety problems occurred initially with each agent, but continuing clinical studies overwhelmingly indicated their efficacy and safety [8,9]. More recently, contrast-enhanced ultrasound (CEUS) has been found safe for pediatric use in subjects as young as two years old [10]. Furthermore, at the recent *16th European Symposium on Ultrasound Contrast Imaging in Rotterdam*, Porter (USA) presented highly compelling evidence that CEUS improved the prediction of patient outcomes when compared with nuclear imaging or non-contrast ultrasound. He also pointed out that contrast imaging avoids subjecting patients to the ionizing radiation inherent in nuclear techniques and suggested that there was significant underutilization of CEUS.

Because of these findings and our own clinical experience, we have persisted in our studies on perfluorobutane microbubbles for coronary artery disease. However, at the present time, this contrast agent has only been approved for hepatic diseases in Japan [11]. Here, we report our experience with the use of perfluorobutane microbubbles to perform MCE in 66 patients who had undergone coronary angiography. Our data showed that perfluorobutane microbubbles markedly and stably enhance visualization of ischemic myocardial areas due to significant coronary artery stenosis and provided superior images compared with Levovist™, but with the caveat that imaging parameters require careful optimization.

3. Materials and Methods

3.1. Patients

Sixty-six patients with a history of coronary angiography (CAG) within the last three months were enrolled in this study, and informed consent was obtained. The study was approved by the clinic's ethics committee. All procedures were performed in accordance with The Code of Ethics of the World Medical Association (Declaration of Helsinki) for experiments involving humans. The following aspects of the consent form were explained to the patients: 1) the advantages, benefits, risks and possible side effects of the procedure to them specifically as well as to patients with coronary artery disease in general, 2) the cost of the procedure according to the regulations of the National Health Service, 3) the approximate time of the procedure, and 4) the clinic staff and specialists that would be present during the procedure. In addition, the approval of the ethics committee required that the procedure be performed by a special team that included the following personnel: Dr. R. Kakiyama since he was in charge of the study, the nurses and echocardiographers who had experience with MCE, at least one specialist in the use of Sonazoid™ from Daiichi Sankyo Co. Ltd, and a mechanical engineer and a technical specialist to operate the Vivid 7 Ultrasound System. All 24 patients enrolled had $\geq 75\%$ significant coronary artery stenosis (significant stenosis). Among them, single vessel disease was present in 11 patients, double vessel disease in 9 and triple vessel disease in 4. No subject had a history of previous myocardial infarction. The following patient data were obtained: age, 69.9 ± 11.4 y/o; body weight, 60.5 ± 12.1 kg; body surface area, 1.61 ± 0.43 m²; blood pressure, 128.6 ± 15.3 / 67.7 ± 9.9 mmHg; heart rate, 65.3 ± 9.0 beats/min; LVEF (by angiography), $60.5 \pm 4.3\%$; LDL-cholesterol, 125.6 ± 38.1 mg/dl; and triglyceride, 193.1 ± 134.1 mg/dl. Six patients were treated for diabetes mellitus by oral medication and their average HbA1c was $6.3 \pm 1.5\%$.

3.2. Instrumentation

Phase-inversion harmonic ultrasonography was performed using the Vivid 7 Dimension digital ultrasound system, Version 7.0.3 (General Electric Healthcare, Inc., U.S.A.), and a 1.5/4.0 MHz active-matrix array (AMA) probe. The images were analyzed offline using EchoPAC PC Version 108.1.4. Phase inversion harmonic sonography is two phase-inverted but otherwise identical sonographic pulses are transmitted. Summing the returning echoes

in a buffer cancels most of the fundamental and odd harmonic echoes and effectively amplifies the second harmonic. [12]

3.3. The first step

A longitudinal peak systolic strain map (LPSSM) has high diagnostic reliability to detect segmental left ventricular wall abnormalities. [13,14] Thus, an LPSSM was created on any patient with coronary artery disease (CAD) risk factors. When the LPSSM showed abnormal left ventricular segmental wall systolic function, myocardial contrast echocardiography (MCE) was done using Sonazoid™ to confirm whether the dysfunction was due to myocardial ischemia.

3.4. The second step

Materials: Sonazoid™ was obtained from Daiichi Sankyo Co. Ltd. (Tokyo, Japan).




Figure 1. Magnified reconstituted Sonazoid solution. A macromolecular shell is encapsulated by a high molecular weight gas. The microbubbles are very weak and are destroyed easily by usual physical pressure and MI (mechanical index). Sonazoid reconstituted in saline for injection of 2.5mL: Volume concentration: 6.9 μ L MB/mL Particle size: 2.3~2.9 μ m (median diameter) Involving gas: Perflubutane (C₄F₁₀) Membrane element: Hydrogenated egg phosphatidyl serine (sodium) pH: 5.7~7.0 Osmotic pressure ratio: 0.9~1.1

Any remaining Sonazoid should be stored at room temperature and used within 2 hours.

Because Sonazoid™ microbubbles are susceptible to destruction by physical pressure, 2.5 ml were injected over at least 20 sec, not less than the systemic circulation time under the stress of low dose ATP (0.15 mg/kg/min of Adenosine 5- Triphosphate Disodium) Figure 1, Figure 2, Figure 3, Figure 4.

Measurements: The echocardiographer was blinded to the results of CAG in the patients enrolled. Three apex approach (AP) views and one parasternal short axis (SAX) view were recorded per injection. The instrument settings were as follows: mechanical index (MI), 0.4-0.6 for the AP and 0.22 for the SAX views; frame rate, 21.2; and frequency, 1.5/3.0 MHz. These were selected based on the recommendations of the specialist from Daiichi Sankyo Co. Ltd who had experience with liver imaging. The MI was very low so as not to destroy the microbubbles but high enough to vibrate them. This vibration energy is necessary to create ultrasonic cardiac images. The images taken were clear and of sufficient quality to be analyzed at

these settings. The images were acquired from the time-intensity curve in late diastole just before the P wave. Intensity differences before and after Sonazoid™ injection were measured at the same site. The intensity data were automatically shown on the upper right part of the screen. We examined 3 AP views (APLAX: mid-anterior septum & mid-posterior segment; AP2ch: mid-anterior and mid-inferior segment; AP4ch: mid lateral and mid-septal segments) and mid-papillary muscle level SAX views (mid-anterior, mid-lateral, mid-posterior, mid-inferior, mid-septal a mid-anterior septal segments). The segments in the 3 AP views that were perfused by coronary arteries with significant stenosis were designated as Group A and the segments in the SAX views were designated as Group B. The segments in the AP views that were perfused by normal or coronary arteries without significant stenosis were designated as Group C and the segments in the SAX views were designated as Group D. We compared the intensities of all four groups before and after Sonazoidinjection using a paired t-test.

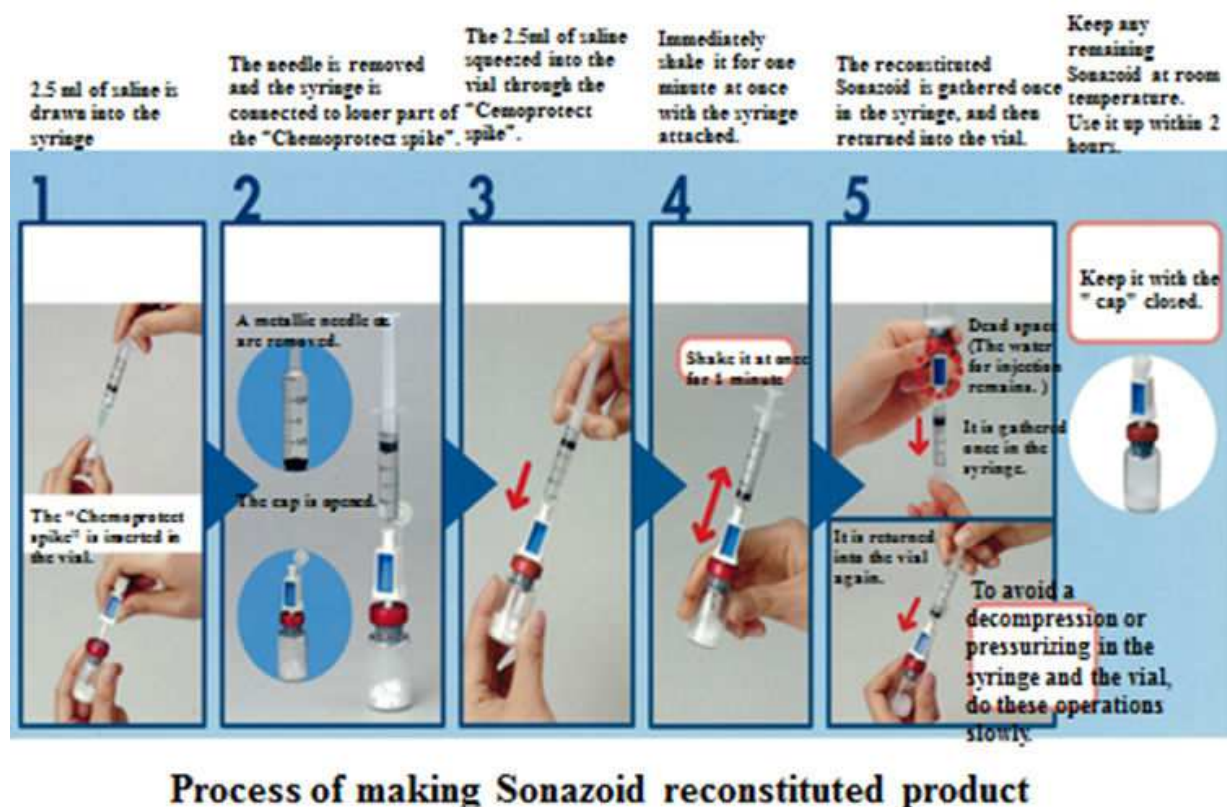


Figure 2. Process of making the Sonazoid reconstituted product. The "Chemoprotect spike" is inserted in the vial to keep the pressure in the vial unchanged. Then, 2.5 ml of saline is drawn into the syringe. Then the needle is removed and the syringe is connected to the luer part of the "Chemoprotect spike". Then, 2.5 ml of saline is squeezed into the vial through the "Chemoprotect spike". The solution is shaken for one minute with the syringe attached. The reconstituted Sonazoid is gathered once in the syringe, and then returned into the vial. To avoid decompression or pressurization in the syringe and vial, these procedures should be performed slowly.

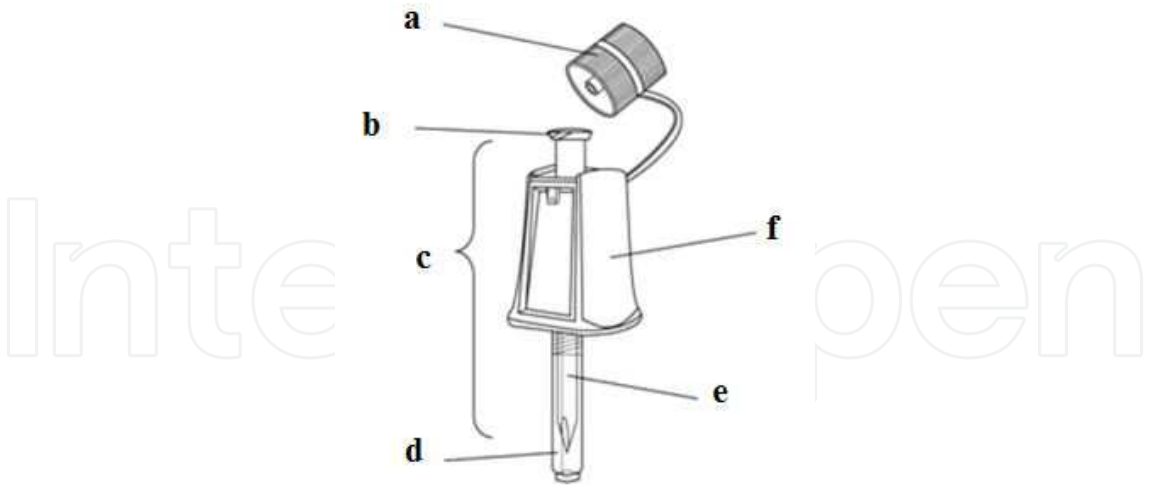


Figure 3. Chemoprotect Spike. This reconstituted Sonazoid production adjustment device consists of a main body, a luer portion, filter housing, spike part, built in liquid filter for drug solution filtration, and an air filter for ventilation. a : Cap, b : Luer portion, c : Spike (Main body), d : Protective cap, e : Protective cap, f : Filter housing, Fluid filter, Air filter

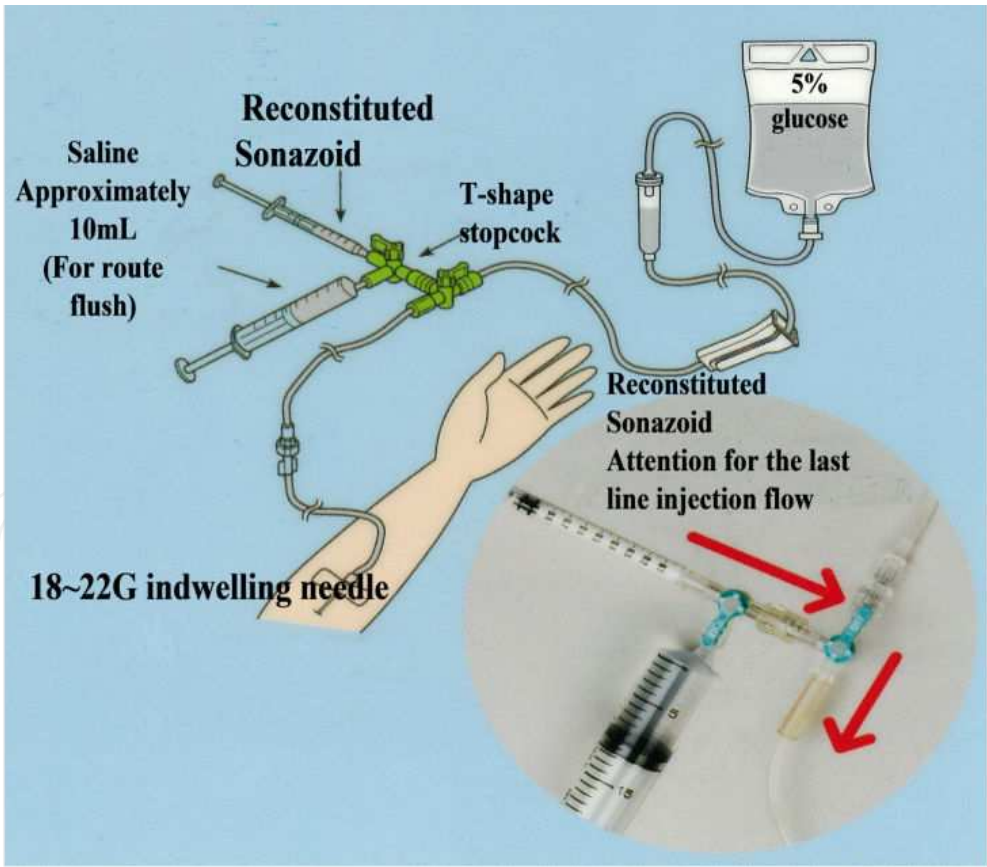


Figure 4. Method and route of injection of reconstituted Sonazoid. Sonazoid (2.5 ml) was injected slowly over 20 seconds. After finishing the injection of Sonazoid, saline (approximately 10 ml) was injected to flush the delivery route

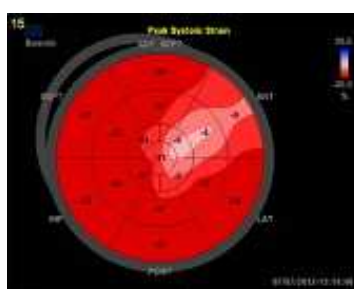


Figure 5. Longitudinal peak systolic strain map. This shows abnormal LV wall motion area, does not show ischemic area. Therefore coronary artery disease is not diagnosis by this map.

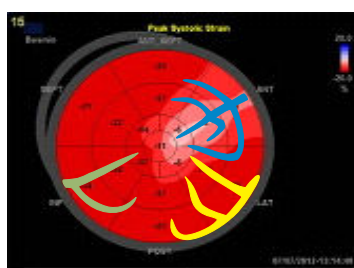


Figure 6. The picture of coronary arteries is superimposed on the strain map. By this method the relation between coronary arteries and the area of abnormal LV wall motion is confirmed.

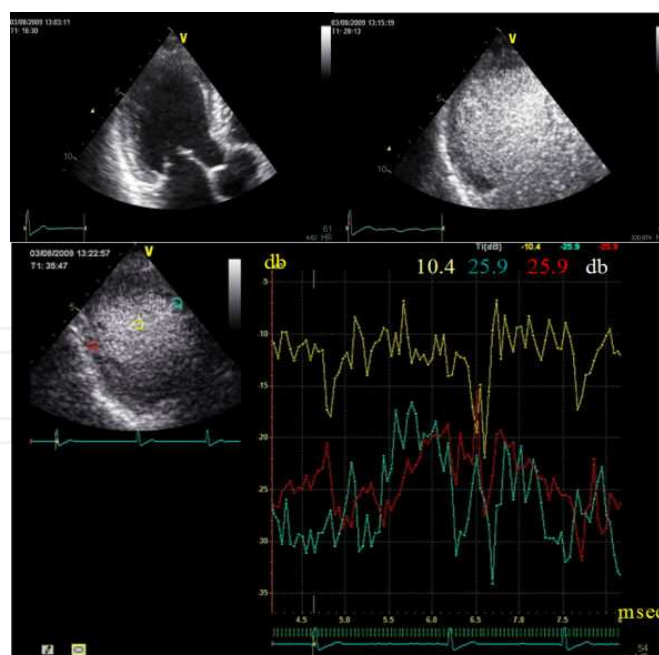


Figure 7. Sonazoid myocardial contrast echocardiography, APLAX views. The patient #7 (see Figure 3 for CAG images) was examined before and after Sonazoid injection. The instrument was set to MI = 0.4. APLAX views before (A) and after (B) Sonazoid. Intensity curves (C). Yellow, LV cavity; red, posterior wall (LCX area); and blue, interventricular septum (LAD #6 area)

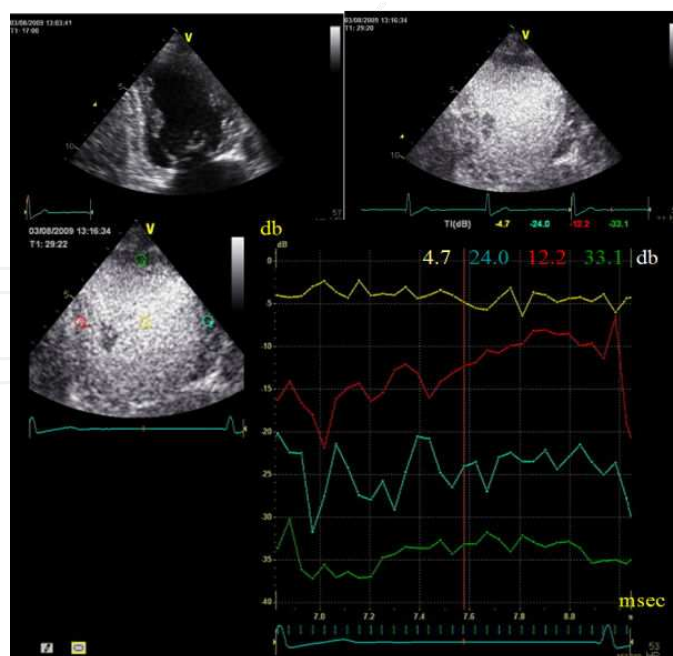


Figure 8. Sonazoid myocardial contrast echocardiography, AP 2-chamber views. The instrument was set to MI = 0.4. AP 2-chamber views before (A) and after (B) Sonazoid injection. Time-intensity curves (C). Yellow, LV cavity; red, inferior wall (RCA area); and blue, anterior wall (LAD area).

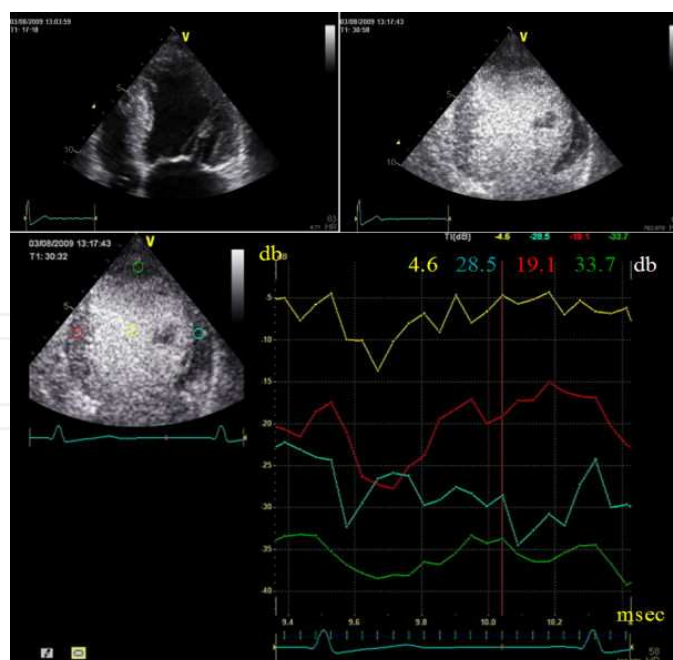


Figure 9. Sonazoid myocardial contrast echocardiography, AP 4-chamber views. The instrument was set to MI = 0.4. AP 4-chamber views before (A) and after (B) Sonazoid injection. Time-intensity curves (C). Yellow, LV cavity; red, inter-ventricular septum (LAD #6 area); blue, lateral wall and apex (LAD #7 area).

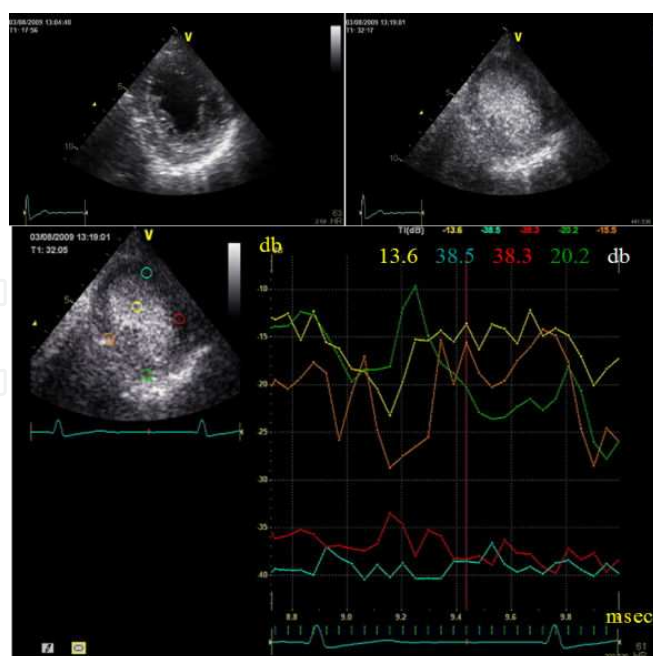


Figure 10. Sonazoid myocardial contrast echocardiography, SAX- pm views. The instrument was set to MI = 0.22. SAXpm views before (A) and after (B, C) Sonazoid injection. Time-intensity curves (D). Yellow, LV cavity; blue, anterior wall; red, lateral wall (both are LAD #7 area); orange, posterior wall; green, inferior wall.

None of the patients experienced adverse affects of this procedure. Each of the 66 patients enrolled in the study had undergone CAG and was diagnosed with significant coronary artery stenosis. Patients were divided into four groups as described above, and myocardial segments perfused by the stenotic and normal vasculatures were examined by ultrasonography before and after Sonazoid administration. The data for one patient (#7) are presented in Figures 5 through Figure 10. Ultrasound images taken before and after Sonazoid administration are shown in 6 Figures, which represent the strain maps and APLAX, AP2ch, AP4ch and SAX-papillary muscle (pm) views, respectively. Figure 5 and Figure 6 show the longitudinal peak systolic strain map and Figure 6 which is superimposed coronary arteries on the map strongly implies this patient experienced no adverse affect and had LAD single vessel disease. Figure 11 shows an angiogram of the left and right coronary arteries. In the left panel, the angiogram (left coronary artery) clearly reveals left anterior descending coronary artery stenosis obstructing 75% of the vessel's normal diameter. Stenotic regions are indicated by the arrows. In contrast, no involvement of the right coronary artery could be discerned.

The data from 100 myocardial segments (16 patients) perfused by normal coronary arteries and from 283 myocardial segments (50 patients) perfused by stenotic coronary arteries in 66 patients with coronary artery disease were grouped into A, B, C and D as designated above and are summarized in Tables 1 and Table 2. Specifically, the intensity difference between A-pre-injection (A-pre) and A-post-injection (A-post) was 1.3 ± 3.5 dB; the intensity difference between B-pre and B-post was 0.9 ± 3.3 dB. The intensity differences in groups A and B were not significant. For C-pre and C-post, the intensities were -33.4 ± 5.1 dB and -22.3 ± 6.8

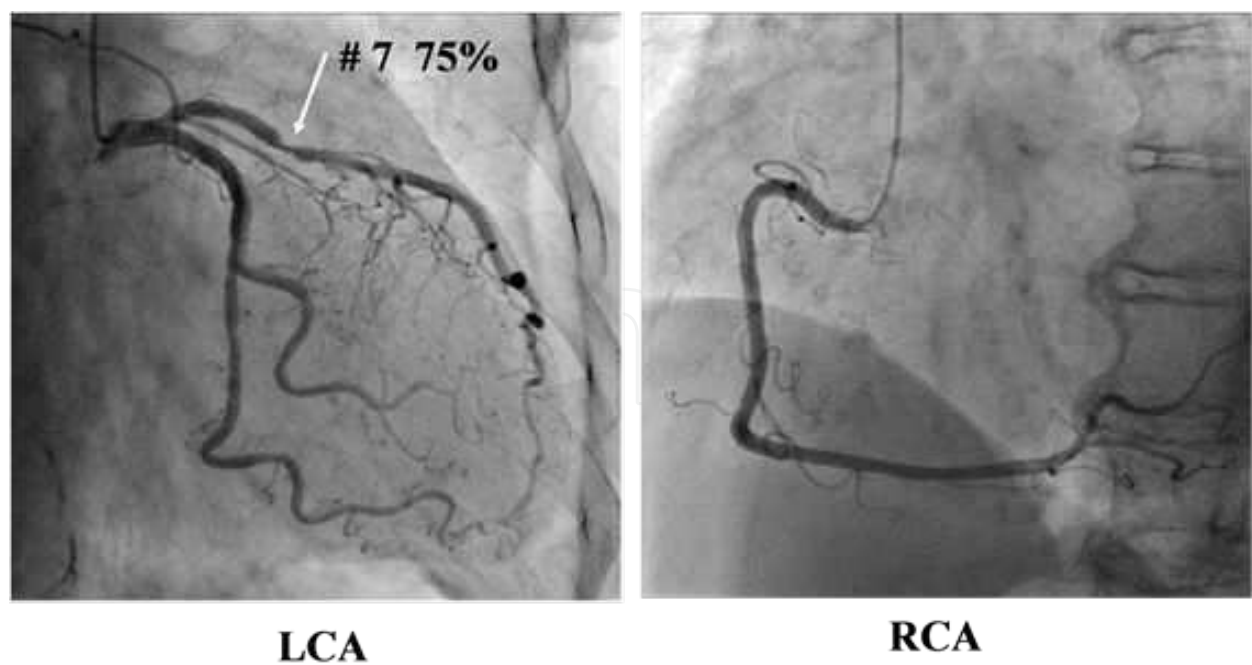


Figure 11. Coronary artery angiography. Left: left coronary artery. Left anterior descending artery had 75% stenosis at #7. Right: Right coronary artery was normal.

dB, respectively; and D-pre and D-post were -36.2 ± 4.8 dB and -22.6 ± 10.7 dB, respectively. The intensity differences in groups C (14.1 ± 5.8 dB) and D (11.5 ± 4.3 dB) were both significant ($p < 0.001$). By ROC (receiver operating characteristic curve) analysis, intensity differences ≤ 6.3 dB in the AP views could detect $\geq 75\%$ stenosis with a sensitivity of 98%, specificity of 94% and accuracy of 97%. An intensity difference ≤ 5.1 dB in the SAX view could detect $\geq 75\%$ stenosis with a sensitivity of 97%, specificity of 96% and accuracy of 97%. These data indicate the sensitivity, specificity and diagnostic accuracy of MCE using Sonazoid to detect $\geq 75\%$ stenosis.

Stenotic Groups	
Group/View	Intensity difference
A/AP	1.3 ± 3.5 dB (N.S.)
B/SAX	0.9 ± 3.3 dB (N.S.)
Normal Groups	
Group/View	Intensity difference
C/AP	14.1 ± 5.8 dB ($P < .001$)
D/SAX	11.5 ± 4.3 dB ($P < .001$)

Table 1. Intensity differences before and after Sonazoid administration. A-pre-injection (A-pre) and –post-injection (A-post): 1.3 ± 3.5 dB. B-pre and B-post: 0.9 ± 3.3 dB. The intensity differences for each pair were not significantly different. C-pre and C-post: -33.4 ± 5.1 dB and -22.3 ± 6.8 dB; D-pre and D-post: -36.2 ± 4.8 dB and -22.6 ± 10.7 dB. The differences between C (14.1 ± 5.8 dB) and D (11.5 ± 4.3 dB) were judged significant ($P < 0.001$)

View	Sensitivity	Specificity	Accuracy
AP ($\Delta \leq 6.3$ dB)	0.98	0.94	0.97
SAXpm ($\Delta \leq 5.1$ dB)	0.97	0.96	0.97

Table 2. Sonazoid's detection parameters for coronary artery stenosis. The optimal dB cut-off vales were selected that gave the highest sensitivity and specificity. By ROC, intensity differences ≤ 6.3 dB in AP views detects $\geq 75\%$ stenosis with a sensitivity: 0.98, specificity: 0.94, accuracy: 0.97. In the SAX view an intensity difference ≤ 5.1 dB detects $\geq 75\%$ stenosis with a sensitivity: 0.97, specificity: 0.96, accuracy: 0.97.

The intraobserver reproducibility was determined by imaging the same patients after a four-week interval and then calculating Cohen's kappa ($\kappa = 0.76$, $p < 0.001$). To obtain the four-week interval and then calculating Cohen's kappa ($\kappa = 0.76$, $p < 0.001$). To obtain the interobserver reproducibility, the same images were evaluated by another echocardiographer who was employed at a different medical institute and had no knowledge of the protocol. The interobserver reproducibility was excellent ($\kappa = 0.98$, $p < 0.001$). These two results indicate that the reproducibly of Sonazoid MCE is sufficient for the use of this agent in the clinical setting.

4. Discussion

Remarkable progress has been made over the last decade in medical imaging of the heart and other organs. However, there is still an enormous worldwide mortality and morbidity from coronary artery disease. A major hurdle in overcoming this situation is the inability to make a definite diagnosis of coronary artery stenosis or to screen coronary artery disease easily and inexpensively. Although myocardial ischemia it thought to start from 75% stenosis, patients usually have no symptoms with normal daily activities. When the stenosis is $\geq 90\%$, patients may become symptomatic with normal daily activities. Presently, CAG is only one diagnostic method, but it is invasive and expensive. Routine preventative cardiac imaging that would be safe (no ionizing radiation or allergenic contrast dyes), highly sensitive, specific and economical would obviously help mitigate this ongoing public health burden.

Echocardiography is one of the areas in which the most exciting advances have been made, and it is especially attractive because it is becoming progressively more miniaturized and can be used in a typical office setting rather than a dedicated imaging center. Current modalities include real-time three-dimensional echocardiography, speckle tracking, contrast echocardiography, intracardiac echocardiography and hand-held echocardiography.

Here, we show that Sonazoid can be successfully used in a local clinical setting and this contrast agent allows the accurate detection of coronary artery stenosis $\geq 75\%$. This may be accounted for by Sonazoid's resistance to acoustic pressure and its long half-life compared to other microbubble-based contrast agents [15]. Our patients did not experience adverse effects during or after the procedure. This is likely due to Sonazoid's intrinsic nontoxicity, but

also by the rapid metabolism of microbubbles via the respiratory system. We compared our results with those of other studies [16, 17] and found similar accuracy for the detection of significant ($\geq 75\%$) coronary artery stenosis. Thus, our data argue for continued investigations into its suitability for MCE and ultimate approval for this purpose, especially in view of the limited number of microbubble-based contrast agents now available to cardiologists. In future studies, it will be of great interest to determine whether Sonazoid is capable of detecting less significant degrees of stenosis.

5. Limitations

The limitations of this method are the same as the limitations of echocardiography. It is difficult to obtain good B-mode images in patients with a thick subcutaneous fatty layer or emphysematous lung. The reliability of MCE to detect ischemia is clearly dependent on the quality of the B-mode images. Another limitation is the process of making Sonazoid™ since the solution is somewhat complex compared with Levovist™. In addition, the detection of ischemic myocardial areas requires the ability to make and read time-intensity graphs. However, we learned to overcome these limitations after four or five subjects.

6. Conclusions

This study showed that Sonazoid™ has good clinical utility and better diagnostic accuracy to detect significant coronary artery stenosis than other contrast agents. This is because the concentration of Sonazoid™ in circulating blood is more stable, and the agent has a longer half-life than other contrast agents.

Comparisons between myocardial regions of affected and normal arteries in these patients before and after Sonazoid™ administration under low-dose ATP stress showed that MCE could detect $\geq 75\%$ stenosis with a sensitivity of 97%, specificity of 96% and accuracy of 97%. An important factor in achieving these results was the optimization of the MI settings. We believe that these data, taken together with patients not experiencing adverse effects during or after the procedure, provide a compelling argument for extending these studies, with the ultimate goal of providing cardiologists a powerful new tool for routine echocardiography.

The ability of this MCE method to identify various degrees of coronary artery stenosis needs to be confirmed in larger, randomized trials. Although conventional echocardiography cannot detect the extent of myocardial tissue ischemia due to coronary artery stenosis, it can detect LV wall systolic dysfunction due to myocardial ischemia by strain mapping. By applying these two methods, we could develop a new and more accurate diagnostic method. The creation of an MCE map along with a strain map might be used to directly diagnose the severity of coronary artery stenosis and extent of the ischemic myocardial area.

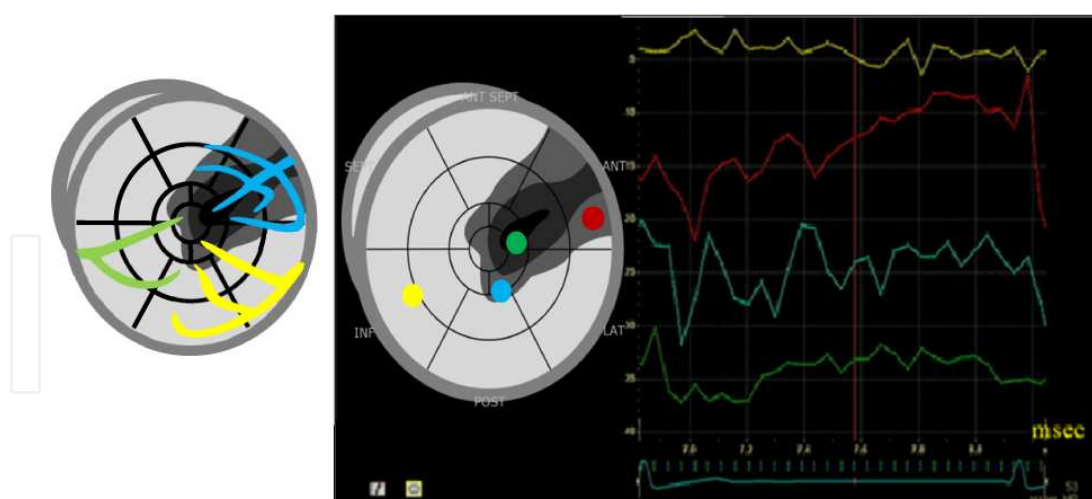


Figure 12. The image of myocardial contrast echocardiography map (MCE Map: left) and the time-intensity curve of the MCE of the patient by MCE MAP.

The extent of the ischemic myocardial area surely play a more leading and important role as an index more than the severity of coronary artery stenosis to decide the indication of coronary artery intervention.

Acknowledgements

The authors heartedly express our thanks to Mr. Yoshio Oonishi (Daiichi Sankyo Co. Ltd, Tokyo, Japan) who kindly provided us with Figures 1, 2, 3 and 4, and also to Mr Kenichiro Morinaga and Mr. Eiji Aoki (SEIKOTEC Co.,Ltd.) who helped me by drawing coronary arteries on strain maps (<http://seikotec.com/>). In addition I deeply appreciate Mr. Hisashi Koumyou's personal advice to edit this thesis.

Author details

Ri-ichiro Kakiyara

Address all correspondence to: ri-ichiro.k@adagio.ocn.ne.jp

Department of Cardiology, Private Kakiyara Clinic, Toyohashi, Japan

References

- [1] Chelliah RK, Senior R. Contrast echocardiography: an update. *Curr Cardiol Rep.* 2009; 11(3) 216-224.

- [2] Platts D, West C, Boga T, Hamilton-Craig C, Burstow D. Direct visualization of septal perforator coronary arterial blood flow during perflutren microsphere contrast echocardiography. *Eur J Echocardiogr.* 2009;10(6) 808-810.
- [3] Cheng AS, Pegg TJ, Karamitsos TD, Searle N, Jerosch-Herold M, Choudhury RP, Banning AP, Neubauer S, Robson MD, Selvanayagam JB. Cardiovascular magnetic resonance perfusion imaging at 3-tesla for the detection of coronary artery disease: a comparison with 1.5-tesla. *J Am Coll Cardiol.* 2007; 49(25) 2440-2449.
- [4] Schwarz F, Ruzsics B, Schoepf UJ, Bastarrika G, Chiaramida SA, Abro JA, Brothers RL, Vogt S, Schmidt B, Costello P, Zwerner PL. Dual-energy CT of the heart--principles and protocols. *Eur J Radiol.* 2008;68(3) 423-433.
- [5] Schutt EG, Klein DH, Mattrey RM, Riess JG. Injectable microbubbles as contrast agents for diagnostic ultrasound imaging: the key role of perfluorochemicals. *Angew Chem Int Ed Engl.* 2003;42(28) 3218-3235.
- [6] Klibanov AL. Microbubble contrast agents: targeted ultrasound imaging and ultrasound-assisted drug-delivery applications. *Invest Radiol.* 2006;41(3) 354-362.
- [7] Hernot S, Klibanov AL. Microbubbles in ultrasound-triggered drug and gene delivery. *Adv Drug Deliv Rev.* 2008;60(10) 1153-1166.
- [8] Dijkmans PA, Juffermans LJ, van Dijk J, Musters RJ, Spreeuwenberg, Kamp O. Safety and feasibility of real time adenosine myocardial contrast echocardiography with emphasis on induction of arrhythmias: a study in healthy volunteers and patients with stable coronary artery disease. *Echocardiography.* 2009;26(7) 807-814.
- [9] Abdelmoneim SS, Bernier M, Scott CG, Dhoble A, Ness SA, Hagen ME, et al. Safety of contrast agent use during stress echocardiography: a 4-year experience from a single-center cohort study of 26,774 patients. *JACC Cardiovasc Imaging.* 2009 Sep;2(9): 1048-1056.
- [10] McMahon CJ, Ayres NA, Bezold LI, Lewin MB, Alonzo M, Altman CA, et al. Safety and efficacy of intravenous contrast imaging in pediatric echocardiography. *Pediatr Cardiol.* 2005 26(4) 413-417.
- [11] Moriyasu F, Itoh K. Efficacy of perflubutane microbubble-enhanced ultrasound in the characterization and detection of focal liver lesions: phase 3 multicenter clinical trial. *Am J Roentgenology.* 2009;193(1) 86-95.
- [12] Stanton J. Rosenthal, Paul H. Jones, Louis H. Wetzel Phase Inversion Tissue Harmonic Sonographic Imaging: A Clinical Utility Study. *Am J Roentgenology.* 2001; 176(6) 1393-1398.
- [13] Reisner SA, Lysyansky P, Agmon Y, Mutlak D, Lessick J, Friedman Z. Global longitudinal strain: a novel index of left ventricular systolic function : *J Am Soc Echocardiogr.* 2004 June; 17(6) 630-633.
- [14] Shimoni S, Gendelman G, Ayzenberg O, Smirin N, Lysyansky P, Edri O, Deutsch L, Caspi A, Friedman Z. Differential Effects of Coronary Artery Stenosis on Myocardial

Function: The Value of Myocardial Strain Analysis for the Detection of Coronary Artery Disease : J Am Soc Echocardiogr. 2011; 24(7) 748-757.

- [15] Sontum PC. Physicochemical characteristics of Sonazoid, a new contrast agent for ultrasound imaging. *Ultrasound Med Biol.* 2008;34(5) 824-833.
- [16] I Jucquois, P Nihoyannopoulos, A D'Hondt, V Roelants, A Robert, J Melin, D Glass, and J Vanoverschelde. Comparison of myocardial contrast echocardiography with NC100100 and 99mTc sestamibi SPECT for detection of resting myocardial perfusion abnormalities in patients with previous myocardial infarction. *Heart.* 2000; 83(5) 518–524.
- [17] Binder T, Assayag P, Baer F, Flachskampf F, Kamp O, Nienaber C, Nihoyannopoulos P, Piérard L, Steg G, Vanoverschelde JL, Van der Wouw P, Meland N, Marelli C, Lindvall K. NC100100, a new echo contrast agent for the assessment of myocardial perfusion--safety and comparison with technetium-99m sestamibi single-photon emission computed tomography in a randomized multicenter study. *Clin Cardiol.* 1999;22(4) 273-282.

IntechOpen

