

# We are IntechOpen, the world's leading publisher of Open Access books Built by scientists, for scientists

6,900

Open access books available

185,000

International authors and editors

200M

Downloads

Our authors are among the

154

Countries delivered to

TOP 1%

most cited scientists

12.2%

Contributors from top 500 universities



WEB OF SCIENCE™

Selection of our books indexed in the Book Citation Index  
in Web of Science™ Core Collection (BKCI)

Interested in publishing with us?  
Contact [book.department@intechopen.com](mailto:book.department@intechopen.com)

Numbers displayed above are based on latest data collected.  
For more information visit [www.intechopen.com](http://www.intechopen.com)



---

# **Endoscopic Management of Oesophageal and Gastric Varices**

---

Neil Rajoriya and David A. Gorard

Additional information is available at the end of the chapter

<http://dx.doi.org/10.5772/52524>

---

## **1. Introduction**

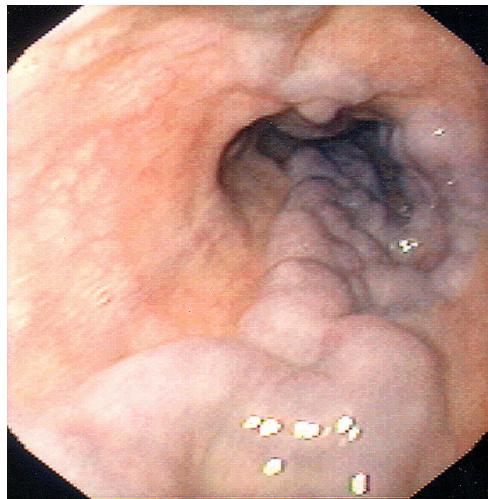
Chronic liver disease of any aetiology can result in portal hypertension. Portal hypertension leads to the formation of porto-systemic collaterals including gastro-oesophageal varices. The development of portal hypertension can also herald the development of other complications of liver cirrhosis such as ascites formation, hepatic encephalopathy and when varices occur, their bleeding. However it should be noted that portal hypertension also occurs in non-cirrhotic conditions, such as: Budd-Chiari, myeloproliferative diseases and extra-hepatic portal vein obstruction.

Variceal haemorrhage is a serious life-threatening complication of portal hypertension, with overall mortality rates historically reported as 30-50% [1]. Although mortality can be up to 40% at 6 weeks, it can be up to 70% at 1 year [2]. With the generally improved management of the critically ill cirrhotic patient, together with vasoactive therapy and new endoscopic techniques for managing variceal haemorrhage, overall mortality has reduced, with one centre in Europe showing a reduction from 42% in 1980 to 14% in 2000 [3]. The treatment of gastric varices has also evolved over recent years with the introduction of adhesive compounds such as N-butyl-2-cyanoacrylate and thrombin, and the increased use of Transjugular Intrahepatic Portosystemic Shunts (TIPS) in variceal bleeding and early in rebleeding. New self-expanding oesophageal stents have been developed for oesophageal haemorrhage in the ever expanding endoscopic armamentarium against variceal bleeding. Earlier emergency access to endoscopy performed by skilled endoscopists has coincided with the decline in use of tamponade equipment such as Sengstaken-Blake-more tubes, and the virtual extinction of emergency surgical procedures of oesophageal transection or porto-caval shunt formation.

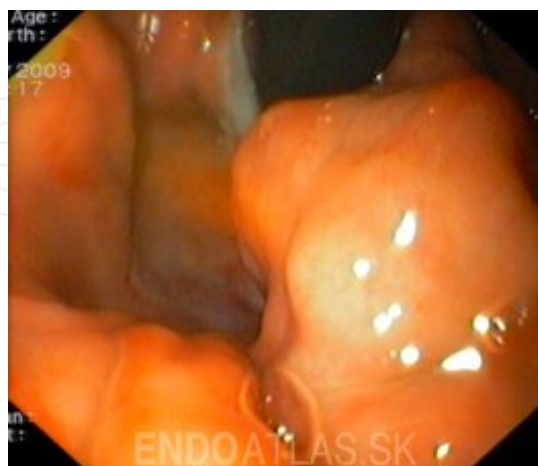This chapter addresses the aetiology and pathogenesis of oesophageal and gastric varices, the strategy of primary prophylaxis against variceal bleeding, and reviews the medical and endoscopic treatment of variceal haemorrhage and rebleeding thereafter.

## 2. Portal hypertension and the development of varices

Portal hypertension is a key factor in the development of oesophageal or gastric varices. The endoscopic appearances of oesophageal and gastric varices can be seen in Figures 1 and 2 respectively.



**Figure 1.** Quiescent column of oesophageal varices



**Figure 2.** Gastric varix seen on retroflexion of the endoscope in fundus of the stomach with the classical "hanging grapes" appearance (courtesy of Dr Branislav Kunčák, University of Trnava and Nové Zámky Hospital, Nové Zámky, Slovakia at [www.Endoatlas.sk](http://www.Endoatlas.sk))

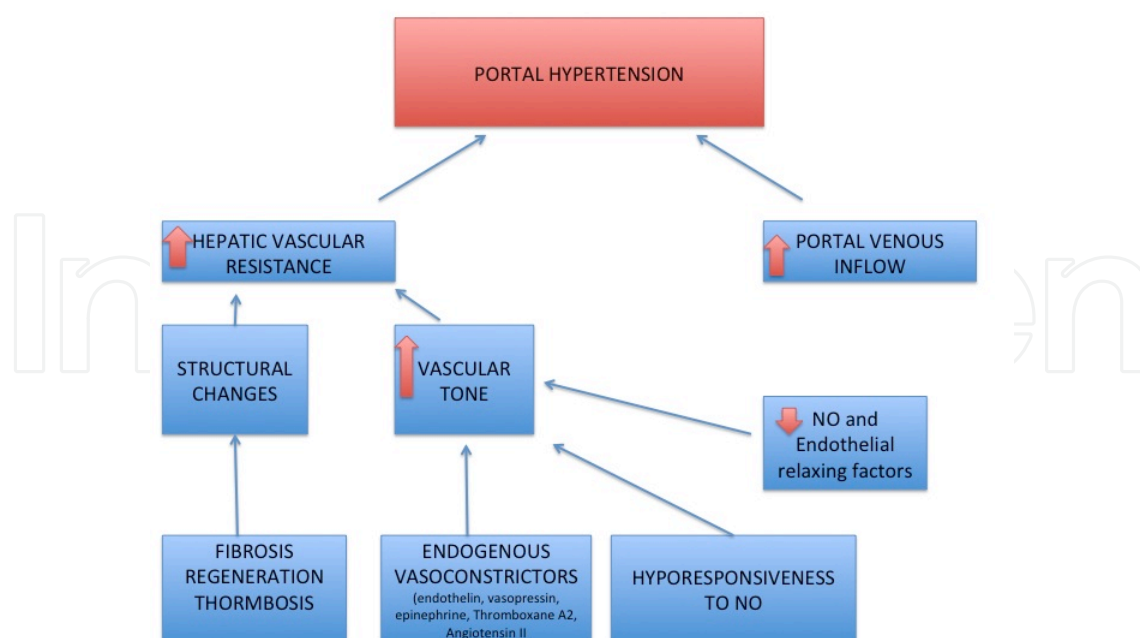
The portal pressure is the pressure in the portal vein and portal vein tributaries. Normal portal pressure is 1-5 mmHg. When the portal pressure gradient (difference in pressure between the pressure in the portal vein and hepatic vein) exceeds 10-12mmHg, varices will form. The causes of portal hypertension categorised by anatomical site are summarised in Table 1.

SITE	CAUSES
PRE-HEPATIC	Portal vein/ splenic vein thrombosis Extrinsic compression of portal vein Portal vein congenital abnormalities (stenosis)
INTRA-HEPATIC	Any cause of cirrhosis (alcoholic, metabolic, viral, biliary, autoimmune) Acute alcoholic hepatitis Veno-occlusive disease Hepatocellular carcinoma Chronic active hepatitis Acute fatty liver of pregnancy Amyloidosis Chronic Hypervitaminosis A Polycystic disease Nodular regenerative hyperplasia Granulomatous liver diseases (TB, sarcoidosis, schistosomiasis)
POST-HEPATIC	Tricuspid valve disease / severe right heart failure Constrictive pericarditis Inferior vena cava thrombosis/ congenital malformations Hepatic vein thrombosis (Budd Chiari)

**Table 1.** Causes of portal hypertension related to site of increased resistance to portal blood flow

Irrespective of the site of resistance to portal blood flow, there are different mediators involved in the development of portal hypertension as outlined in Figure 3.

Portal hypertension can develop from structural changes within the liver, altering the architecture and thus leading to distortion of the blood flow through the liver. This results in increased vascular resistance. Such structural changes are the main cause for increased intrahepatic vascular resistance. Nodule generation, sinusoidal capillarization (development of a basal membrane around the sinusoid in the Space of Disse and fibrous tissue accumulation), sinusoidal collapse and hepatocyte enlargement all lead to shrinking and narrowing of the sinusoid unit leading to increased intrahepatic vascular resistance. Once these pathological changes occur, they can be an irreversible / fixed component of the development of portal hypertension. Depending on the aetiology and thus treatment of disease, degrees of fibrosis can in some cases be partially reversed.



**Figure 3.** Overview of the mechanisms in the development of portal hypertension. (NO = nitric oxide)

Activated hepatic stellate cells (HSCs) are key mediators in the production of peri-sinusoidal hepatic fibrous tissue and the laying down of extracellular matrix [4]. Such deposition of fibrous tissue around the sinusoids can be the initial event in sinusoidal capillarization [5]—whereby extracellular matrix is deposited in the Space of Disse, and furthermore this can result in sinusoidal endothelial cells producing less nitric oxide (NO), which activates HSCs further. Any underlying liver disease promoting a fibrosis architecture of the liver can lead to portal hypertension [6]. As the fibrosis persists and progresses, liver cirrhosis can ensue.

The development of portal hypertension leading to collateral formation and varices relies not only on structural changes within the liver, but also on increased vascular tone within the liver. The alterations in vascular tone are dynamic changes. The HSCs are activated and can constrict as fibrosis and cirrhosis develop leading to a further vasoconstriction at the sinusoidal level. The mechanisms by which this occurs are multifactorial but include a change of HSC from a quiescent phenotype to a myofibroblast-like phenotype [6], which has greater contractile properties, and an up-regulation of calcium-channel receptors that mediate constriction [6, 7]. In addition to the activation of HSCs, there is an increase in mediators of vasoconstriction including Thromboxane A<sub>2</sub>, Angiotensin II, RhoA, endothelin, and eicosanoid, which have been shown at experimental level to increase intravascular intrahepatic tone [8–11]. The increase in vasoconstrictors is coupled with a reduction of vasodilators such as homocysteine and NO, with the latter being a key mediator in portal circulation vasodilatation [12] and in the formation of collateral vessels [13,14]. The production of NO is promoted by vascular endothelial growth factor, which also promotes porto-collateral vessel formation [15].

Vasodilatation of the arterial splanchnic vessels is an important factor in the development of portal hypertension. Chronic vasodilatation leads to increased blood flow to the porto-ve-

nous system and development of porto-systemic collateral formation and varices [16]. Increased portal pressure is the most important risk factor for the development of varices [2]. Varices develop once a hepatic venous pressure gradient (HVPG), a surrogate marker for sinusoidal portal hypertension, exceeds 10-12mm Hg [17]. Lowering the portal pressure is a key target in the prevention of variceal formation, in the prevention of variceal bleeding, and in the management of acutely bleeding varices [18]. One other major feature in portal hypertension is the development of the hyperdynamic circulatory syndrome, which is associated with the development of varices [16]. This is characterised by a decreased mean arterial pressure, increased cardiac output and decreased systemic vascular resistance. The hyperdynamic circulation again is a target for drug therapies including beta-blockers to reduce portal hypertension, with the main driver for the vasodilatation and subsequent hyperdynamic circulation being NO [16].

### 3. Growth, classification and location of varices

Once portal hypertension ensues, there is development of porto-systemic collateral formation in an attempt to decompress the rising portal pressure. Two basic mechanisms lead to: (1) neo-angiogenesis and (2) dilatation of pre-existing embryonic channels between the portal and systemic circulations [19, 20]. Gastro-oesophageal varices develop as part of cephalad collaterals formed after dilatation of the left gastric (coronary) vein and the short gastric veins. Once established, varices can remain indolent or grow in size, and also cause life-threatening haemorrhage. When the portal pressure is above 10 mmHg, the median time for the development of varices is 4 years [21] while some studies show a *de novo* formation rate of 4-6% per year [22, 23].

Variceal size is a predictor of haemorrhage, as predicted by La Place's law, whereby wall tension increases with variceal radius and transmural variceal pressure. The mean risk of haemorrhage from larger varices (>5mm) is 30% at 2 years, compared to 10% from small varices at 2 years [24,25]. Risk factors for the dilatation of varices include: an increase in portal pressure [26], alcohol consumption [27], circadian rhythm [28], prandial blood flow bursts [29] and also Child-Pugh class at baseline and its deterioration during follow-up [30, 31]. The rate of yearly increase in size of varices varies from a range of 8% to 31% [32, 33]. The two main locations of varices that may rupture are the lower oesophagus and the stomach.

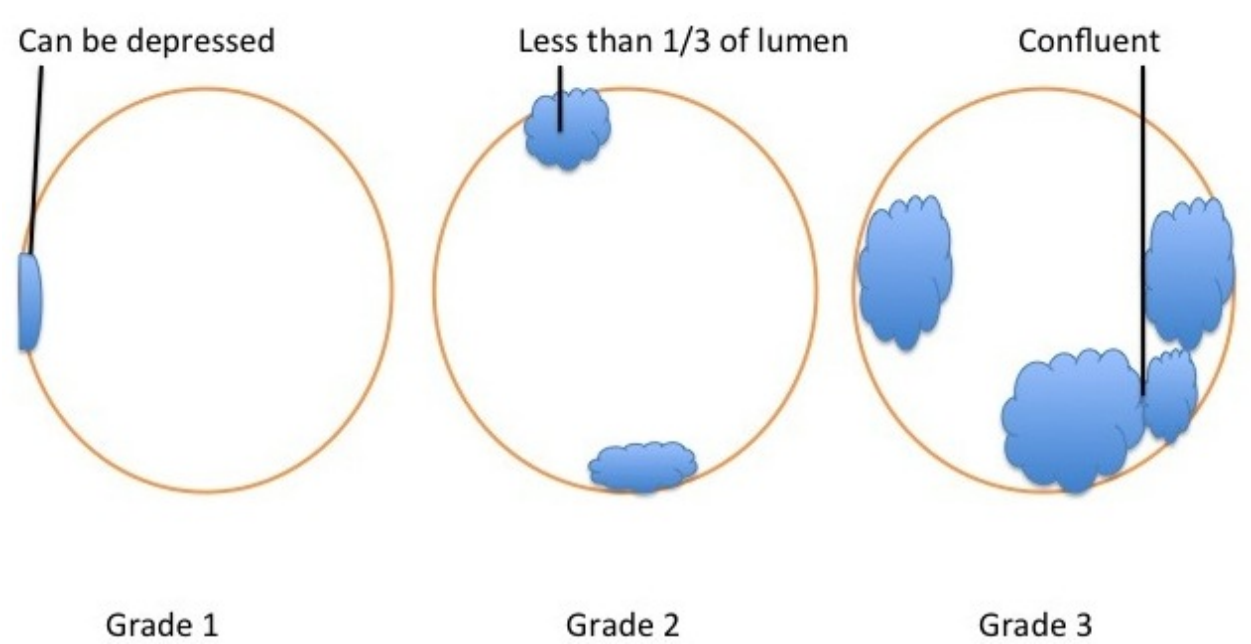
#### 3.1. Oesophageal varices

Oesophageal varices are long columns of dilated veins (Figure 1), usually occurring within the lower third of the oesophagus, immediately above the gastro-oesophageal junction (GOJ). Oesophageal varices can be graded endoscopically according to size [34] (Table 2/ Figure 4), while the American Association for the Study of Liver Diseases (AASLD) recommends the classification into small and large oesophageal varices based on a cut-off of 5mm [35].



GRADE OF OESOPHAGEAL VARIX	DESCRIPTION
1 (small)	Small straight varices
2 (medium)	Enlarged tortuous varices occupying less than one third of the lumen
3 (large)	Large coil-shaped varices occupying more than one third of the lumen

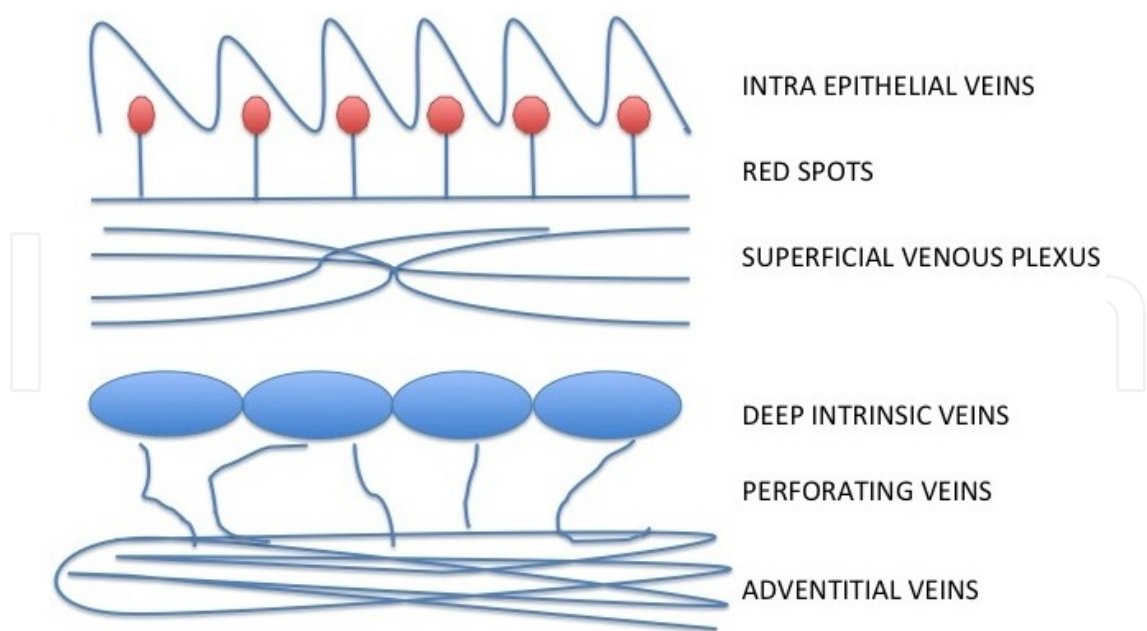
**Table 2.** Grading of oesophageal varices according to Italian liver cirrhosis project. (Reference 34)



**Figure 4.** Grading of oesophageal varices endoscopically (adapted from reference 24)

The major blood supply to oesophageal varices is from the left gastric vein. There are 4 layers of veins in the oesophagus (Figure 5). The intra-epithelial veins are the most superficial veins and correlate with the red spots seen at time of endoscopy. These red spots have been shown to be predictive of variceal rupture (along with variceal size and Child-Pugh class [25]). Deeper to these veins is the superficial venous plexus, which then drains into deeper intrinsic veins. These in turn are then connected via perforating veins to the deepest adventitia plexus. It is the main trunks of the deep adventitia plexus that large oesophageal varices arise from.

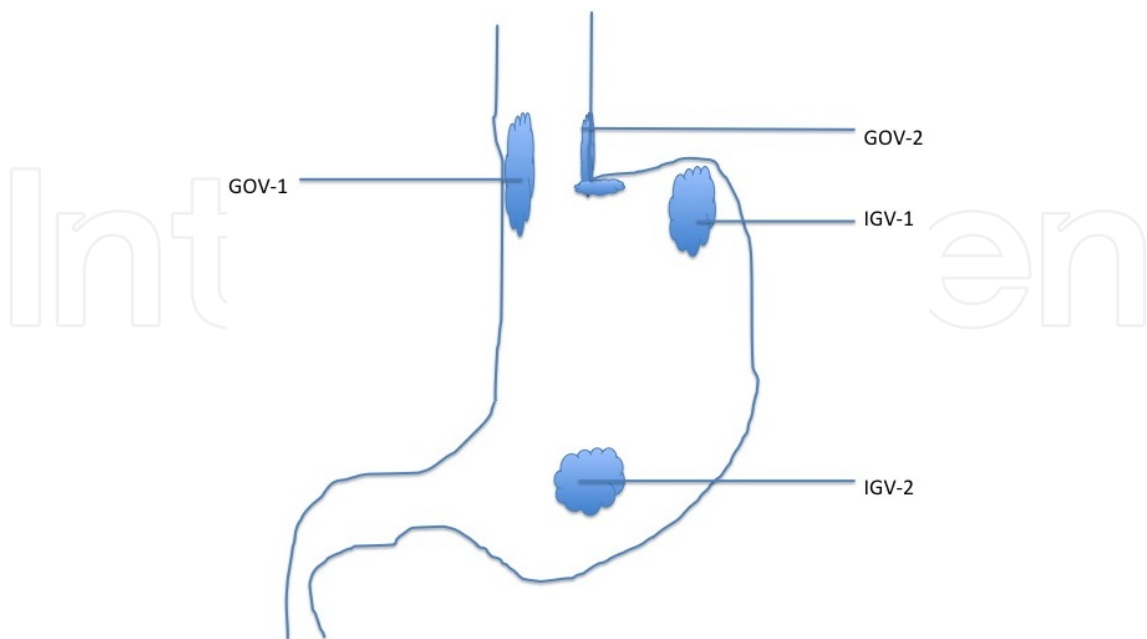
An area of common oesophageal variceal rupture is at the GOJ - the palisade zone – an area of venous tributaries between the gastric zones and perforating zone (in the oesophagus). This area is a watershed between the azygous and portal blood flow systems, where venous flow is bidirectional with turbulent flow – which may explain frequent rupture [36] – and thus why when banding, oesophageal bands should be applied as close to the GOJ as possible.



**Figure 5.** The anatomy of veins within the oesophagus from which oesophageal varices arise.

**3.2. Gastric varices**

Gastric varices are supplied by the short gastric veins, draining into the deep intrinsic veins of the lower oesophagus, and can be classified according to site by the Sarin classification of gastric varices [37] (Figure 6 / Table 3).



**Figure 6.** Sarin classification of gastric varices (adapted from reference 37)



Gastric varices account for 10-30% of variceal haemorrhage and can occur in up to 20% of patients with portal hypertension [17, 38]. Management of bleeding gastric varices differs from that of the more common situation of bleeding oesophageal varices (see later in chapter).

SARIN TYPE OF GASTRIC VARIX	DESCRIPTION/LOCATION
Gastro-Oesophageal Varices -1 (GOV-1)	Continuation from oesophageal varices and extend on lesser curve
Gastro-Oesophageal Varices -2 (GOV-2)	Extend along lesser curve and more tortuous than GOV-1
Isolated Gastric Varices-1 (IGV-1)	Occur in absence of oesophageal varices, and occur in the fundus, and are tortuous and complex
Isolated Gastric Varices-2 (IGV-2)	Occur in absence of oesophageal varices, in the body, antrum or pylorus

**Table 3.** Sarin classification of gastric varices (adapted from reference 37).

**4. Prevention of 1<sup>st</sup> variceal haemorrhage – Primary prophylaxis**

Since patients with cirrhosis may have portal hypertension and varices, there is a rationale for screening of such patients to identify those with varices who might benefit from primary prophylaxis against variceal haemorrhage. Thus those patients who have a diagnosis of cirrhosis either clinically, biochemically or on liver biopsy, should be offered Oesopho-Gastro-Duodenoscopy (OGD) looking for gastro-oesophageal varices [39]. When cirrhosis is diagnosed, any factors causing the continuing insult to the liver must be addressed – such as treatment of the underlying condition (e.g. viral /autoimmune or ongoing alcohol intake in alcoholic liver disease). In those cirrhotic patients who do not have varices diagnosed on initial endoscopy, a follow up endoscopy has been recommended after 2-3 years [40] particularly if hepatic synthetic function worsens (i.e. worsening in Child-Pugh status). Primary prophylaxis aims to prevent variceal haemorrhage in patients who have varices but who have not had a previous bleeding episode. Strategies used in primary prophylaxis can be broadly divided into pharmacological and endoscopic therapies.

**4.1. Pharmacological therapies as primary prophylaxis**

Drug therapies are used to prevent variceal bleeding, and if well tolerated by patients can be effective. Isosorbide mononitrate (ISMN) is a potent vasodilator used in ischaemic heart disease and reduces vascular tone. There are theoretical reasons why ISMN should help to prevent variceal bleeding. In randomised control trials ISMN has been shown to reduce HVPG by 7.5% [41,42], and to augment the splanchnic vasoconstrictive effects of the non-selective beta-blocker propranolol [42]. It has been used when there are contra-indications to, or intolerance of beta-blocker drugs in patients with varices. However a double-blind randomised controlled trial in patients intolerant of beta-blockers, compared ISMN with placebo and found that ISMN was ineffective at preventing a first variceal bleed [43].

Non-selective beta-blockers are the mainstay of treatment in the prevention of variceal bleeding once varices have been identified. Non-selective beta-blockers not only block beta-1 receptors, reducing cardiac output and thus portal blood flow, but also block the adrenergic dilatory tone in the mesenteric arterioles, resulting in unopposed alpha-adrenergic vasoconstriction and a decrease in portal blood flow [44]. Nadolol or propranolol can reduce HVPG measurements by up to 10% [45,46] and are effective in reducing variceal bleeding rates and mortality when compared to placebo [47,48]. Their roles have been firmly established in guidelines [2,35] with the choice between them dependent on institutional practice. Carvedilol is a potent non-selective beta-blocker, with weak vasodilating effects due to alpha-1-blockade [49]. This leads to a reduction in hepatic vascular tone and hepatic resistance [50]. Carvedilol has been shown in multiple studies to reduce portal pressure and HVPG significantly more than propranolol [51-54], but its role in primary prophylaxis is not yet been established [2]. Once beta-blocker therapy has been instituted, patients with varices who are compliant with their medication do not require further endoscopy unless bleeding occurs. However some US centres prefer to repeat endoscopy annually in varices patients on beta-blockers and consider changing to a programme of endoscopic variceal band ligation (EVBL) if the varices increase in size. This latter strategy, however, is non-evidence based.

Side-effects of beta-blockers include bronchoconstriction, heart failure and impotence, and these can often limit a patient's tolerability of the drug. The safety of beta-blockers in cirrhotic patients with refractory ascites has also been questioned in a prospective study of 151 patients in such a cohort [55]. The 1-year probability of survival was significantly lower in patients who received propranolol [19% (95% CI = 9%-29%)] versus those who did not [64% (95% CI = 52%-76%),  $p < 0.0001$ ]. Further studies in this area are required as this initial study was not a randomised controlled trial. It has been postulated that beta-blockers are only beneficial during a set time window in the progression of cirrhosis with portal hypertension [56]. There may be no benefit in early cirrhosis when there is less risk of bacterial translocation, no increase in sympathetic nervous system activity and when the cardiac compensatory reserve remains intact. However as cirrhosis progresses with increasing bacterial translocation and increased sympathetic nervous system activity, there is an increased risk of variceal haemorrhage, and beta-blockers become beneficial in not only reducing variceal bleeding but also reducing bacterial translocation. The window then closes in advanced cirrhosis as beta-blockers exert a negative impact on cardiac compensatory reserve.

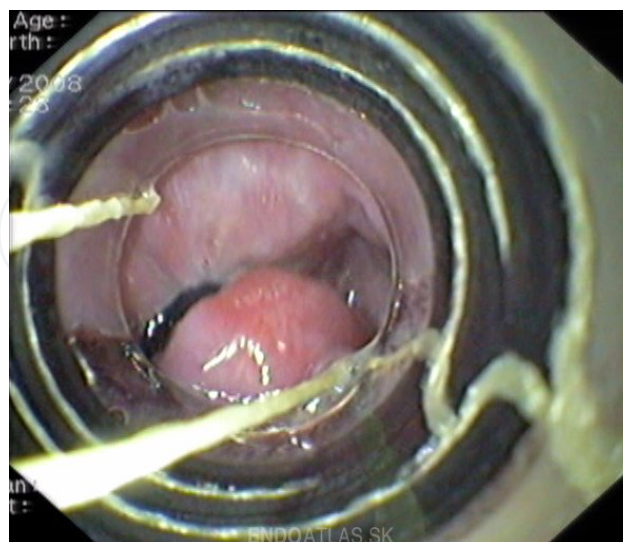
#### **4.2. Endoscopic therapies as primary prophylaxis**

Endoscopic treatments can be used to obliterate/thrombose oesophageal varices. Injection sclerotherapy involves the injection of a sclerosant (usually ethanolamine) via a needle-catheter directly into a varix to thrombose it. Although intuitively the obliteration of varices before they have a chance to bleed would seem to be a logical strategy, injection sclerotherapy is not without complication. In fact when sclerotherapy for primary prophylaxis against variceal bleeding was formally studied in a randomised trial, patients with varices randomised to sclerotherapy had a higher mortality than patients with varices in the control arm [57]. Consequently injection sclerotherapy should not be used as primary prophylaxis against

variceal bleeding. Injection sclerotherapy for oesophageal varices has largely been superseded by EVBL in the past 2 decades. EVBL is an alternative to non-selective beta-blockers, in those intolerant to the medication or for those often with medium or large varices (Figure 7). EVBL should be performed by an endoscopist who has expertise in variceal band ligation to minimise complications in day-case endoscopy patients.

EVBL can be used to treat acutely or recently bleeding oesophageal varices, or can be performed electively to obliterate varices and thus prevent bleeding or rebleeding. Once a diagnostic OGD has been performed and has identified oesophageal varices, the most distal level of variceal location is noted, and the endoscope removed. A single-use, multiband ligator incorporating up to 10 bands, is then loaded onto the endoscope. A cap fitting over the endoscope's tip holds the mounted bands, and is connected through the accessory port of a standard endoscope, with the firing handle mounted close to the endoscope's operating wheels. Once the ligator has been loaded onto the endoscope, the oesophagus is re-intubated. The ligator's cap may make intubation and subsequent endoscopic views a little more difficult.

The first varix to be banded should be the largest one with stigmata of recent/active haemorrhage, or if quiescent then the most distal varix just above the GOJ, since varices at/just above the GOJ are those most likely to bleed. Furthermore, if a proximal varix is banded first, it may be difficult to then pass the endoscope beyond it without dislodging the band. Suction is applied, aspirating the varix into the cap, until the varix is completely sucked up (as seen by a red-out on the screen). Operating the firing handle releases a band onto the varix neck, and release of suction allows the banded varix to be viewed (Figure 7). Thereafter, additional variceal banding can be continued in a cranial direction. Complications of EVBL include band-induced ulceration (which may present as a re-bleed requiring urgent endoscopy), transient dysphagia or chest pain, and rarely oesophageal stricturing.



**Figure 7.** Endoscopic variceal band ligation of oesophageal varices (courtesy of Dr Branislav Kunčák, 2nd Dept. of Internal Medicine, Faculty of Health and Social Work, University of Trnava and Nové Zámky Hospital, Nové Zámky, Slovakia. at [www.Endoatlas.sk](http://www.Endoatlas.sk))

The role of EVBL in patients with medium or large varices has been studied in several trials, and has also been compared to beta-blockers. Meta-analyses show that for primary prophylaxis, both beta-blockade and EVBL have similar efficacy and mortality [53, 58-63]. Guidelines currently do not recommend combination therapies with both EVBL and non-selective beta-blockers [2,35,40]. Local factors including availability of endoscopic procedures, and technicians able to perform EVBL may influence choices between beta-blockade and EVBL as primary prophylaxis. The cost of endoscopy with EVBL is higher than the cost of beta-blocker medication, particularly since banding programmes require follow-up endoscopies to ensure variceal eradication (with up to 22% recurrence post-EVBL reported in one study [59]). Guidelines recommend EVBL every 1-2 weeks after initial OGD until the varices are obliterated, and then 6-12 monthly check endoscopies [35].

Current Baveno V guidelines on portal hypertension [2] recommend primary prophylaxis with non-selective beta-blockers for patients with small oesophageal varices and red wale marks or Child C cirrhotic patients. These guidelines also suggest that patients with small oesophageal varices but without signs of increased risk of haemorrhage or Child C cirrhosis could be considered for treatment with non-selective beta-blockers, although further studies are necessary. Patients with medium or large oesophageal varices can be treated with either beta-blockers or EVBL. Current American Association for the Study of Liver Diseases (AASLD) guidelines [35] similarly recommend prophylaxis with non-selective beta-blockers for patients with compensated cirrhosis and small oesophageal varices with or without features of likely increased haemorrhage risk. The AASLD guidelines also recommend non-selective beta-blockers or EVBL for those with medium or large varices.

For gastric varices, injection of N-Butyl-2-Cyanoacrylate glue has been studied in the primary prophylaxis setting. This long-chain cyanoacrylate glue polymerises and solidifies within seconds following contact with aqueous media such as blood within a varix. This leads to obliteration of the varix from which the cast extrudes after 2-4 weeks. Mixing the cyanoacrylate with the oily agent Lipiodol delays polymerisation. The glue treatment was compared with beta-blockers or no therapy in a randomised controlled trial [64], with significantly reduced probabilities of bleeding in patients treated with glue compared to beta-blockers or no therapy (13% v 28% and 45% respectively). However the use of the glue for gastric varices has complications (see later in chapter in "Endoscopic treatment of acute gastric variceal haemorrhage" section) and its role in primary prophylaxis against gastric variceal bleeding has not yet been established [2]. Although there is a paucity of data from prophylactic studies on gastric variceal bleeding, there is current consensus that using beta-blockers to reduce portal pressure is appropriate in this setting [2].

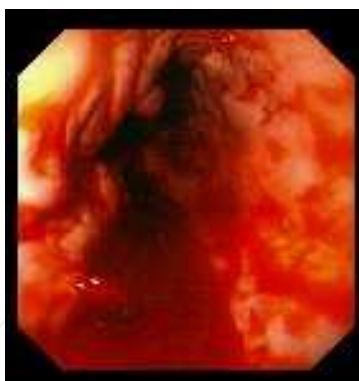## 5. General management strategies in acute variceal haemorrhage

Variceal haemorrhage is a life-threatening emergency with a mortality of 20-40% at 6-weeks (65). Factors predictive of death within 6 weeks of index bleeding in patients with cirrhosis include: site of bleed is varices (instead of other pathology), level of bilirubin, underlying alco-



holic liver disease, presence of encephalopathy or coagulopathy and the need for balloon tamponade [2,40,65]. If haematemesis or melena occurs in patients known to have cirrhosis or stigmata of chronic liver disease, variceal bleeding should be considered. AASLD guidelines recommend such patients should be managed in an intensive care setting [35]. Tracheal intubation should be considered if the patient has a reduced Glasgow Coma Scores (GCS) or signs of hepatic encephalopathy, since these increase the risk of aspiration. Furthermore, subsequent endoscopy to diagnose and treat the bleeding point is safer in an intubated patient. General measures include wide-bore venous access or central venous access, and fluid resuscitation with either colloid or blood products. Blood resuscitation to maintain a haemoglobin level of approximately 8g/dl has been recommended [40], as experimental studies have shown the total restoration of all lost blood may raise portal pressure higher than that of baseline [66], with subsequent higher rates of re-bleeding and mortality [67]. There must however be adequate arterial pressure to maintain renal perfusion (and prevent acute kidney injury and the development of hepato-renal syndrome). Clotting and platelet deficiencies should be corrected.

Bacterial infections are common in cirrhotic patients, and antibiotics have been shown to reduce bacterial infections, recurrent bleeding and mortality in patients bleeding from oesophageal varices [68,69]. Broad-spectrum antibiotic prophylaxis is recommended [35]. Local antibiotic policy and a patient's nil-by-mouth status are important influences, but the antibiotic used should be either an oral quinolone, or else a 3<sup>rd</sup> generation intravenous cephalosporin in patients who have advanced cirrhosis, or previously received quinolone prophylaxis, or live in areas of high quinolone resistance [2].



**Figure 8.** Bleeding oesophageal varices (courtesy of ELLA-CS, Hradec Kralove, Czech Republic)

The use of vasoactive drugs to lower portal pressure is paramount in the initial management of variceal bleeding. Such drugs should be given prior to endoscopy if the source of upper gastrointestinal bleeding is suspected to be varices [2, 70]. Vasopressin and terlipressin cause constriction of the splanchnic arterioles, thus leading to increased resistance to inflow of blood to the gut. This leads to a lowering of portal venous pressure. Side effects however include myocardial ischaemia and these vasoconstrictors are contraindicated in peripheral vascular disease. Vasopressin has been shown to achieve haemostasis in 60-80% of patients, but has limited effects on reducing early rebleeding and does not improve survival from active variceal hae-

morrhage [71]. Vasopressin has largely been superseded by terlipressin in countries where it is available (not the USA). Terlipressin (triglycyl-lysine vasopressin) is a synthetic analogue of vasopressin administered at an initial dose of 2mg, then 1mg intravenously every four hours. Meta-analysis shows that terlipressin reduces all-cause mortality when compared to placebo [71, 72] and it should be instituted early and continued for up to 5 days, as this is the period during which rebleeding is common. When compared to somatostatin analogues such as octreotide, the haemodynamic effects of terlipressin on portal pressure are more sustained [73], suggesting terlipressin may have a more prolonged benefit in bleeding varices.

Somatostatin and somatostatin analogues (e.g. the long-acting analogue octreotide) act by increasing splanchnic arterial resistance, and inhibit vasoactive peptides such as glucagon. Octreotide is used as first-line vasoactive therapy in the USA (where terlipressin is unavailable). It is given intravenously as a 50 microgram bolus followed by a continuous infusion of 50 micrograms per hour. Octreotide causes a transient reduction in portal pressure and azygous blood flow lasting up to only 5 minutes despite continuous infusion [74]. However additional effects are via inhibition of glucagon and other peptides that increase post-prandial mesenteric blood flow [75]. The mesenteric blood flow increases in variceal bleeding due to the high protein gut loading from the intraluminal blood [76], and octreotide can reduce the hormone-induced changes for up to 38 hours [77]. Somatostatin has fewer side effects than terlipressin (0% vs. 10%) and a higher relative risk (1.62) for achieving initial control of bleeding, but no survival benefit [78]. Thus vasoactive drugs are part of the initial therapy in variceal haemorrhage and one of these drugs should be continued for 2- 5 days [2].

Prior to endoscopy a tamponading balloon such as the Sengstaken-Blakemore tube or Minnesota tube can be considered, but the advent of 24-hour endoscopy services, vasoactive drugs and TIPS has largely obviated the need for this intervention. Balloon tamponade should be only be used in massive haemorrhage as a bridge to endoscopy [2]. Complications of tube insertion include upper airway obstruction, inadvertent tracheal intubation, lower oesophagus ulceration and even oesophageal rupture if the gastric balloon is wrongly inflated in the oesophagus.

## **6. Endoscopic treatment of acute oesophageal variceal haemorrhage**

OGD is the investigation of choice in the diagnosis of variceal bleeding, and it offers endoscopic therapeutic capability at the time. After general measures covered earlier in the chapter have been instituted in a patient with variceal bleeding, an urgent OGD should be carried out within 12 hours of presentation [2]. Some experts recommend tracheal intubation prior to OGD in all patients suspected of having variceal bleeding, to prevent aspiration of blood into the airway. Endoscopic therapy for bleeding varices largely depends on the type of varix that is bleeding – oesophageal or gastric. The mainstays of endoscopic therapy for bleeding oesophageal varices include injection sclerotherapy and EVBL.

Endoscopic sclerotherapy for oesophageal varices has mainly been performed using the sclerosant ethanolamine. Cyanoacrylate glue and thrombin have also been used. Sclerotherapy is done using a catheter with a retractable needle introduced through the endoscope's operating channel. Under endoscopic vision, the sclerosant is directly injected into the



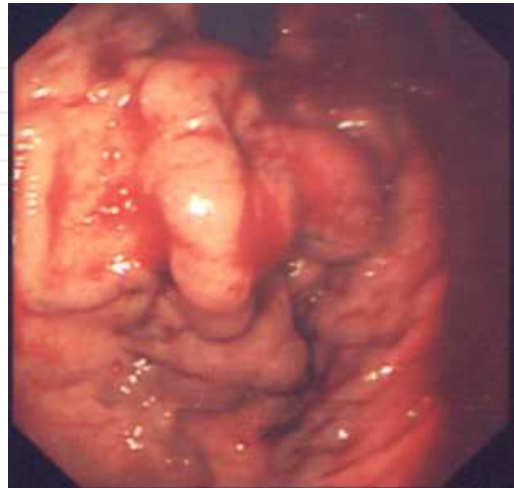bleeding oesophageal varix. Local complications can include bleeding, stricture formation, ulceration, oesophagitis, mediastinitis and oesophageal perforation.

Sclerotherapy controls active bleeding from oesophageal varices in 62-100% of patients and is more effective than treatment with placebo, vasoactive therapy or balloon tamponade [40]. A meta-analysis of 5 studies (Laine L, personal communication in Baveno IV consensus statements [40]) of 251 patients comparing sclerotherapy with sham sclerotherapy, balloon tamponade and/or vasopressive therapies showed significant benefits of sclerotherapy in terms of initial haemostasis, in patient re-bleeding (OR=0.36, 0.21-0.62) and mortality (OR=0.57, 0.33-0.98) [79-83]. A meta-analysis suggested that sclerotherapy was the "gold standard" in acute variceal bleeding [84]. Despite the efficacy of endoscopic sclerotherapy for actively bleeding oesophageal varices, endoscopic therapy has switched to EVBL. In part this switch may have been extrapolated from the negative outcomes when sclerotherapy was used as primary prophylaxis against variceal bleeding[57], but subsequent comparative trials detailed below have pointed to a superiority of EVBL.

EVBL has evolved as the recommended standard of treatment for bleeding oesophageal varices (Baveno IV guidelines) [40], and sclerotherapy is only recommended if ligation is technically difficult. In a meta-analysis of 10 randomized controlled trials comparing EVBL with sclerotherapy, there was an almost significant benefit of EVBL in achieving initial haemostasis compared to sclerotherapy (pooled relative risk of 0.53 with CI 0.28-1.01) [85]. In one of the studies in the meta-analysis, HVPG increased significantly immediately after both EVBL and sclerotherapy, but the HVPG remained elevated for the duration of the study (5 days) in the sclerotherapy group while returning to baseline levels by 48 hours after EVBL group [86]. Another meta-analysis however found no difference in initial haemostasis rates between sclerotherapy and EVBL (RR 1.1, 95% CI: 0.4-2.9) [87], but the actively bleeding patients represented a small subset from larger trials, and were thus not truly from pure randomized controlled trials in this population [40]. EVBL is associated with fewer adverse effects than sclerotherapy. By consensus, EVBL is the preferred form of endoscopic therapy for acute oesophageal variceal bleeding, although sclerotherapy is recommended in patients in whom EVBL is not technically feasible.

Combination therapies of vasoactive drugs and direct endoscopic therapies have been studied, with dual therapy conferring the potential benefits of pharmacological reduction in portal pressure together with the direct local haemostating effects of either sclerotherapy or EVBL. Combination is now recommended as a standard of care in oesophageal variceal bleeding [2,40]. The combined effect of initial haemostasis was initially difficult to assess due to heterogeneity of trials and definitions of immediate haemostasis. A meta-analysis of 4 trials including 559 patients, concluded that combined therapy was associated with a higher rate of initial haemostasis than endoscopic therapy alone (88% v 76%, RR: 1.12, 95% CI: 1.02-1.23) [88]. Five-day haemostasis rates were studied in the Baveno IV consensus statements [40]. Pooling of results of 939 patients demonstrated that combination therapy achieved greater haemostasis rates than endoscopic therapy alone (77% v 58%, RR: 1.28, 95% CI: 1.18-1.39) with a number needed to treat of 5 (95% CI 4-8) [89-96]. However no significant differences were found in 5-day or 42-day mortality when combined vasoactive drug and endoscopic therapy was compared to endoscopic therapy alone in 2 meta-analyses [88, 89].

Two pooled randomized controlled trial results of combination therapy versus pharmacological therapy alone showed combination therapy improved control of bleeding (RR: 3.1, 95% CI: 1.2-8.3) but with no influence on mortality [88, 89].



**Figure 9.** A bleeding gastric varix seen on retroflexion of the gastroscope (courtesy of Dr Adrian Stanley, Glasgow Royal Infirmary, 2006)



**Figure 10.** Self-expanding oesophageal metallic stent (courtesy of ELLA-CS, Hradec Kralove, Czech Republic)

More recently self-expanding oesophageal metallic stents have been developed and used in oesophageal variceal bleeds. They have been developed from their role in oesophageal malignancy, and act by applying direct tamponading pressure to the distal oesophageal mucosa and any associated varices. Stents were used in a pilot study in 20 patients who failed to achieve haemostasis with pharmacological or endoscopic techniques [92]. Immediate haemostasis was achieved in 100% of these patients. Such stents seem a promising option in the situation of refractory oesophageal haemorrhage, but further evaluation is needed.

Radiological therapies have been used in acute oesophageal variceal bleeding, with TIPS the most commonly studied and available radiological modality. TIPS involves the placement of a needle catheter via the transjugular route into the hepatic vein, and wedging it there under fluoroscopic guidance. The needle is then advanced through the liver parenchyma to the intrahepatic portion of the portal vein, creating a “side-to-side” anastomotic shunt. A stent is then positioned across the liver, connecting the portal vein and hepatic veins, and allowing blood to flow normally from the portal vein through the liver with a drop in the portal pressure. TIPS was initially used as therapy for uncontrolled bleeding and achieved control of bleeding in 90-95% of patients and a 4-week survival of 50-60% [93]. Early TIPS placement has been shown to have beneficial effect in patients with a HVPG > 20mmHg presenting with a variceal bleed [94]. TIPS reduced treatment failures, hospital stay and 1-year mortality. Other studies have confirmed the role of TIPS in variceal bleeding which cannot be controlled by endoscopy or vasoactive drugs [95-97]. Complications of TIPS include haemorrhage, infection, intravascular haemolysis and worsening of hepatic encephalopathy [95-97].

## 7. Endoscopic treatment of acute gastric variceal haemorrhage

Although less common than oesophageal variceal bleeding, gastric variceal haemorrhage is often torrential with an associated high mortality (Figure 9). Re-bleeding is also common with reported figures of up to 43-89% after a gastric variceal bleed [37, 98-101]. Gastric varices can occur alone or in combination with oesophageal varices. They are often large and located deep in the submucosa, making EVBL or injection therapy more difficult than that for oesophageal varices. Gastric varices can remain quiescent and predicting which gastric varix is likely to bleed can be difficult. Factors that are associated with a high risk of gastric variceal bleeding include: red colour sign, large varices, or a rapid increase in size [102-104].

Therapeutic options for bleeding gastric varices include injection sclerotherapy, banding, TIPS and other radiological interventions. Endoscopic sclerotherapy was first applied in the treatment of a bleeding gastric varix in 1984 [105] and results in endothelial damage with subsequent sclerosis of the varix. Variceal obliteration rates of 71.6% (mean follow up 24.2 +/-22.9 months) in gastric variceal bleeds treated with sclerotherapy have been reported [101], but there are often high re-bleeding rates of 60-90% following sclerotherapy for gastric varices [106, 107].

There are limited data on EVBL in the management of gastric variceal bleeding. EVBL can be useful for varices extending from the oesophagus along the proximal lesser curve (Sarin

GOV-1), but it is problematic for other types of gastric varices. High rates of gastric variceal recurrence following EVBL may be due to a more superficial effect compared with obturation therapy [108]. This, together with the technical difficulty of banding in a retroflexed endoscope position has meant EVBL for gastric varices has largely been superseded by obturation therapies using cyanoacrylate and thrombin injection.

Cyanoacrylate injection is effective for bleeding gastric varices, yet remains unapproved in the USA. Injection of cyanoacrylate is not without complications including endoscope damage due to blockage of the injection channel, detachment of the injection needle into a varix, cerebral embolism, pulmonary embolism, splenic infarcts, mediastinitis and local abscesses. Although most reports of this therapy for gastric varices have limited follow-up, immediate haemostasis rates of 92-100% have been reported with variable re-bleeding rates [108-113]. Cyanoacrylate glue has been compared with ethanol injection in a randomised study with the former showing faster rates of variceal obliteration with a smaller injection volume, improved efficacy in control of acute gastric oesophageal variceal bleeding and reduced need for rescue surgery [114]. Another randomised study concluded that the obliteration of gastric varices using EVBL was more difficult and less effective than cyanoacrylate glue injection [115]. Early haemostasis rates were 87% with cyanoacrylate and 45% with EVBL, and re-bleeding rates were 31% and 54% respectively. Cyanoacrylate injection is also superior to beta-blockers in preventing gastric variceal re-bleeding [116]. When 77 patients who had bled from gastric varices were assigned to either beta-blockers or cyanoacrylate, those whose varices were injected with cyanoacrylate had lower rebleeding rates (15% v 55%), and lower mortality (3% v 25%) [116]. The addition of beta-blockers to cyanoacrylate therapy for secondary prevention after a cyanoacrylate-treated index bleed, does not confer any additional benefit [117].

Thrombin is another obturation therapy advocated for acutely bleeding gastric varices in some United Kingdom centres. It converts fibrinogen to a fibrin clot and causes platelet aggregation [118]. There have been small case-series of its use with haemostasis rates between 70-100% using bovine thrombin [119-122]. However there was concern that this material of bovine origin might present a potential risk of prion transmission. Short-term small studies of human-derived thrombin have demonstrated initial haemostasis rates of 100% but a high mortality from re-bleeding [123-125].

Interventional radiological procedures for the treatment of gastric varices include TIPS [126-128] and Balloon-occluded Retrograde Transvenous Obliteration (BRTO) [127-129] as salvage or rescue therapy when obturation therapy fails. BRTO is an interventional radiological technique used mostly in Far East Asia for gastric variceal bleeding. The gastro-renal shunts often seen in such patients can be occluded with sclerosant via a balloon catheter approach via the left renal vein [129]. BRTO may become an alternative to TIPS in patients with active gastric variceal bleeding in whom a gastorenal shunt is present [130].

Current Baveno V guidelines [2] suggest early TIPS within 72 hours (ideally < 24 hours) in patients at high risk of treatment failure (Child-Pugh class C < 14 points or Child-Pugh class B with active bleeding) after initial pharmacology and endoscopic therapy in patients with variceal bleeding. This recommendation is derived from the pivotal study from Barcelona in which 63 cirrhotic patients with variceal bleeding were treated with vasoactive drugs and



endoscopic therapy and then randomised to treatment with a TIPS within 72 hours (“early-TIPS”) or else continuation of vasoactive drugs for 3 to 5 days followed by non-selective beta-blockers and long-term EVBL with insertion of a TIPS only if required as a rescue therapy [132]. Rebleeding or failure to control bleeding occurred in only 1 of the “early-TIPS” patients and in 14 of the vasoactive drug/EVBL group ( $p < 0.001$ ). Overall mortality was lower in the “early-TIPS” group (12 patients versus 4,  $p = 0.01$ ) with 1-year survival 61% in the vasoactive drug/EVBL group versus 86% in the “early-TIPS” group ( $p < 0.001$ ).

## 8. Prevention of rebleeding (secondary prophylaxis)

The improvement in survival from index variceal bleeds using the therapies discussed has focussed attention on prevention of rebleeding. 60-80% of patients who bleed from varices will rebleed if not treated [18, 40, 133, 134], and the risk of rebleeding is greatest in the first 10 days (131, 132), during which 50% of those who are going to rebleed, do so. The risk of rebleeding gradually falls over the first month when an additional 10% rebleed [133, 134]; the risk after the first six weeks then plateaus out. Despite the advent of endoscopic therapies and early pharmacological therapies, rebleeding rates are still higher early on, with factors predictive of early rebleeding /treatment failure at 5 days including: active bleeding at index endoscopy, severity of liver disease (Child-Pugh class), severity of bleed, and severity of portal hypertension [132, 135]. HVPG is one of the best predictors of identifying those who will re-bleed. After an index variceal bleed, a reduction of HVPG to less than 12mm Hg or by at least 20%, reduces the risk of rebleeding from 46-65% to 0.13% [136]. HVPG measurement is usually limited to specialist centres.

Strategies to prevent rebleeding historically included surgical portocaval shunts, but currently involve pharmacological and endoscopic therapies. Pharmacological therapies include non-selective beta-blockers, and endoscopic therapies include sclerotherapy or EVBL. Beta-blockers significantly reduce rebleeding rates and improve survival at 2 years when compared to placebo [24, 137]. Factors associated with a risk of rebleeding in patients treated with beta-blockers included a lack of compliance or a lack of reduction of heart rate [138]. Injection sclerotherapy reduces the risk of rebleeding from 65% to 35% but does not appear to reduce overall mortality and is associated with complications such as oesophageal ulceration [40]. When sclerotherapy was compared with beta-blockers there was less rebleeding in the sclerotherapy group, but significantly more side effects and no impact on mortality [136, 139]. EVBL has been shown to be superior to sclerotherapy in reducing the risk of rebleeding to a greater level with fewer side effects [87]. The combination of EVBL and sclerotherapy was no more effective than EVBL alone [140]. A combination of beta-blocker therapy with either EVBL or sclerotherapy has been found to reduce all bleeding, rebleeding from varices and variceal recurrence but not mortality, when compared to any single modality of therapy [141]. TIPS has been studied in early rebleeding with excellent results as mentioned previously in the chapter [132].

In summary, current Baveno V guidelines [2] suggest secondary prophylaxis should start on day 6 of the index bleed. A combination of beta-blocker therapy and EVBL is recommended

over either treatment alone as there are lower re-bleed rates with combination therapy. In patients who are unwilling to have EVBL, beta-blockers with ISMN is recommended [2]. In patients intolerant of beta-blockers, EVBL alone is recommended. In patients who re-bleed despite endoscopic and pharmacological therapies, TIPS is recommended. Transplantation should be considered in those who are appropriate candidates.

## 9. Conclusions

Variceal haemorrhage remains a life-threatening emergency, and a cause of decompensation of patients with portal hypertension or cirrhosis. Prevention of the development of portal hypertension where possible remains key in halting the development of oesophageal or gastric varices. However when portal hypertension has developed, it is important to identify those at risk of varices and enter them into a screening programme. Those found to have varices should be offered primary prophylaxis if required. Once a varix bleeds, urgent specialist care is required to potentially save life. In addition to fluid and blood resuscitation to stabilise conditions before endoscopy, vasoactive medications to reduced portal pressure and antibiotics should be administered. At urgent endoscopy performed by an experienced endoscopist, EVBL is the preferred endoscopic technique to achieve haemostasis in oesophageal variceal haemorrhage, and injection of cyanoacrylate glue is the preferred endoscopic technique to achieve haemostasis in gastric variceal haemorrhage. If endoscopic therapy is difficult, or does not halt the bleeding then TIPS can be performed, although self-expanding tamponading stents may be useful in refractory oesophageal variceal bleeding and BRTO may be useful in refractory gastric variceal bleeding. Survivors of variceal bleeding should receive secondary prophylaxis with beta-blocker medication, together with EVBL in the case of oesophageal varices.

## Acknowledgements

The authors would like to acknowledge those permitting the reprint of images in the chapter: Dr Adrian Stanley, Consultant Gastroenterologist, Glasgow Royal Infirmary, Scotland; the company ELLA-CS, Hradec Kralove, Czech Republic; and Dr Branislav Kunčák, 2nd Dept. of Internal Medicine, Faculty of Health and Social Work, University of Trnava and Nové Zámky Hospital, Nové Zámky, Slovakia.

## Author details

Neil Rajoriya and David A. Gorard

Department of Gastroenterology, Wycombe Hospital, High Wycombe, Buckinghamshire, UK



## References

- [1] D'Amico G, Pagliaro L, Bosch J. The treatment of portal hypertension: a meta-analytic review. *Hepatology* 1995;22(1):332-54
- [2] De Franchis R. Baveno V consensus faculty. Revising consensus in portal hypertension: report of the Baveno V consensus workshop on methodology of diagnosis and therapy in portal hypertension. *J Hepatol* 2010;53(4): 762-768
- [3] Carbonell N, Pauwels A, Serfaty L, et al. Improved survival after variceal bleeding in patients with cirrhosis over the past 2 decades. *Hepatology* 2004;40(3):652-659
- [4] Pinzani M, Failli P, Ruocco C, Casini A, Milani S, Baldi E, Giotti A, et al. Fat storing cells as liver-specific pericytes. Spatial dynamics of agonist-stimulated intracellular calcium transients. *J Clin Invest* 1992;90(2):642-646
- [5] Deleve LD, Wang X, Guo Y. Sinusoidal endothelial cells prevent rat stellate cell activation and promote reversion to quiescence. *Hepatology* 2008;48(3):920-30
- [6] Freidman SL. Mechanisms of hepatic fibrogenesis. *Gastroenterology* 2008;134:1655-1669
- [7] Bataller R, Gasull X, Gines P, et al. In vitro and in vivo activation of rat hepatic stellate cells results in de novo expression of L-type voltage operated calcium channels. *Hepatology* 2001;33(4):956-962
- [8] Bataller R, Sancho-Bru P, Gines P, et al. Activated human hepatic stellate cells express the renin-angiotensin system and synthesize angiotensin II. *Gastroenterology* 2003;125(1):117-125
- [9] Rockey D. The cellular pathogenesis of portal hypertension: stellate cell contractility, endothelin and nitric oxide. *Hepatology* 1997;25:2-5
- [10] Zhou Q, Hennenberg M, Trebicka J, Jochem K, Leiffield L, Biecker E, Saurbruch T, et al. Intrahepatic upregulation of RhoA and Rho-kinase signalling contributes to increased hepatic vascular resistance in rats with secondary biliary cirrhosis. *Gut* 2006;55(9):1296-1305
- [11] Gracia-Sancho, Lavina B, Rodriguez-Vilarrupla A, et al. Enhanced vasoconstrictor prostanoid production by sinusoidal endothelial cells increases portal perfusion pressure in cirrhotic rat livers. *J Hepatol* 2007;47(2):220-227
- [12] Lee CH, Loureiro-Silva MR, Abraldes JG, et al.. Decreased intrahepatic response to alpha(1)-adrenergic agonists in lipopolysaccharide-treated rats is located in the sinusoidal area and depends on Kupffer cell function. *J Gastroenterol Hepatol* 2007;22(6):893-900
- [13] Carmeliet P. Mechanisms of angiogenesis and arteriogenesis. *Nat Med* 2000;6(4): 389-395

- [14] Fukumura D, Yuan F, Endo M, Jain RK. Role of nitric oxide in tumour microcirculation. Blood flow, vascular permeability, and leucocyte-endothelial interactions. *Am J Pathol* 1997;150(2):713-725
- [15] Fernandez M, Vizzutti F, Garcia-Pagan JC, Rodes J, Bosch J. Anti-VEGF receptor-2 monoclonal antibody prevents porto-systemic collateral vessel formation in portal hypertensive mice. *Gastroenterology* 2004;126(3):886-894
- [16] Wiest R, Groszmann RJ. Nitric oxide and portal hypertension: its role in the regulation of intrahepatic and splanchnic vascular resistance. *Semin Liver Dis* 1999;19(4):411-426
- [17] Garcia-Tsao G, Groszmann RJ, Fisher RL, et al. Portal pressure, presence of gastro-oesophageal varices and variceal bleeding. *Hepatology* 1985;5(3):419-24
- [18] D'Amico G. The role of vasoactive drugs in the treatment of oesophageal varices. *Expert opinion pharmacother* 2004;5(2):349-360
- [19] Noda T. Angioarchitectural study of oesophageal varices (with special reference to variceal rupture). *Virchows Archiv A* 1984;404:381-392
- [20] Vianna A. Anatomy of the portal venous system in portal hypertension. In: McIntyre N, Benhamou JP, Birhcer J, Rizzetto M, Rodes J (eds). *Oxford textbook of clinical hepatology*, Oxford University press, Oxford 1991; 393-399
- [21] Groszmann RJ, Garcia-Tsao G, Bosch J, et al. Multicentre randomised placebo controlled trial of non-selective beta-blockers in the prevention of the complications of portal hypertension: final results and identification of predictive factor. *AASLD, Boston, Hepatology* 2003;38(4) (suppl 1):206A
- [22] Primignani M, Albe R, Preatoni P, et al. "De-novo" development of esophageal varices in patients with a recent histological diagnosis of liver cirrhosis. *Gastroenterology* 1998;114:A1234
- [23] Polio J, Groszmann RJ. Hemodynamic factors involved in the development and rupture of esophageal varices: a pathophysiological approach to treatment. *Semin Liv Dis* 1986;6:318-331
- [24] D'Amico G, Pagliaro L, Bosch J. Pharmacological treatment of portal hypertension: An evidence-based approach. *Semin Liv Diseases* 1999;19(4):475-505
- [25] The North Italian Endoscopic Club for the Study and Treatment of Esophageal Varices. Predictors of the first variceal haemorrhage in patients with cirrhosis of the liver and esophageal varices. *N Engl Med J* 1988;13:983-989
- [26] Dell'Era A, Bosch J. review article: the relevance of portal pressure and other risk factors in acute gastro-oesophageal variceal bleeding. *Aliment Pharmacol Ther* 2000; 20 (suppl 3): 8-15, discussion 16

- [27] Luca A, Garcia-Pagan JC, Bosch J, et al. Effects of ethanol consumption on hepatic haemodynamics in patients with alcoholic cirrhosis. *Gastroenterology* 1997;112(4):1284-1289
- [28] Garcia-Pagan JC, Feu F, Castells A, et al. Circadian variations of portal pressure and variceal haemorrhage in patients with cirrhosis. *Hepatology* 1994;16(3):595-601
- [29] Lee SS, Hadengue A, Moreau R, et al. Postprandial hemodynamic responses in patients with cirrhosis. *Hepatology* 1988;8(3):647-651
- [30] Cales P, Desmorat H, Vinel JP, et al. Incidence of large oesophageal varices in patients with cirrhosis: application to prophylaxis of first bleeding. *Gut* 1990;31:1298-1302
- [31] Merli M, Nicolini G, Angeloni S, et al. Incidence and natural history of small esophageal varices in cirrhotic patients. *J Hepatol* 2003;38:266-278
- [32] Merkel C, Marin R, Angeli P, et al. A placebo-controlled trial of nadolol in the prophylaxis of growth of small esophageal varices in cirrhosis. *Gastroenterology* 2004;127(2):476-84
- [33] Zoli M, Merkel C, Magalotti C, et al. Natural history of cirrhotic patients with small esophageal varices: a prospective study. *Am J Gastroenterol* 2000;95(2):503-508
- [34] Italian liver cirrhosis project. Reliability of endoscopy in the assessment of variceal features. *J Hepatol* 1987;4:93-98
- [35] Garcia-Tsao G, Sanyal AJ, Grace ND, Carey W. Prevention and management of gastroesophageal varices and variceal hemorrhage in cirrhosis. *Hepatology*. 2007;46(3):922-38.
- [36] McCormack TT, Rose JD, Smith PM, Johnson AG. Perforating veins and blood flow in oesophageal varices. *Lancet* 1983; 2: 1442-1444
- [37] Sarin SK, Lahoti D, Saxena SP, Murthy NS, Makwana UK. Prevalence, classification and natural history of gastric varices: a long-term follow-up study in 568 portal hypertension patients. *Hepatology* 1992;16 (6):1343-1349.
- [38] Feu F, Garcia-Pagan JC, Bosch J, et al. Relation between portal pressure response to pharmacotherapy and risk of recurrent variceal haemorrhage in patients with cirrhosis. *Lancet* 1995;346:1056-9
- [39] Bosch J, Berzigotti A, Garcia-Pagan JC, Abraldes JG. The management of portal hypertension: Rational basis, available treatments and future options. *J Hepatol* 2008;S68-92
- [40] de Franchis R. Evolving consensus in portal hypertension report of the Baveno IV consensus workshop on methodology and therapy in portal hypertension. *J Hepatol* 2005;43:167-176

- [41] Navasa M, Chesta J, Bosch J, Rodes J. Reduction of portal pressure by isosorbide-5-mononitrate in patients with cirrhosis. Effects on splanchnic and systemic hemodynamics and liver function. *Gastroenterology* 1989;96(4):1110-1118
- [42] Garcia-Pagan JC, Navasa M, Bosch J, et al. Enhancement of portal pressure reduction by the association of isosorbide-5-mononitrate to propranolol administration in patients with cirrhosis. *Hepatology* 1990;11(2):230-238
- [43] Garcia-Pagan JC, Villanueva C, Vila MC et al. Isosorbide mononitrate in the prevention of first bleed in patients who cannot receive beta-blockers. *Gastroenterology* 2001;121(4):908-914
- [44] Sanyal AJ, Shiffman ML. The pharmacological treatment of portal hypertension. *Annu Rev Gastrointest Pharmacol* 1996;242
- [45] Bosch J, Masti R, Kravetz D, et al. Effects of propranolol on azygous venous blood flow and hepatic and systemic hemodynamics in cirrhosis. *Hepatology* 1984;4(6):1200-1205
- [46] Garcia-Tsao G, Grace ND, Groszmann RJ, et al. Short-term effects of propranolol on portal venous pressure. *Hepatology* 1986;6(1):101-106
- [47] Cheng JW, Zhu L, Gu MJ, Song ZM. Meta-analysis of propranolol effects on gastrointestinal haemorrhage in cirrhotic patients. *World J Gastroenterol* 2003;9(8):1836-1839
- [48] Hayes PC, Davis JM, Lewis JA, Bouchier IA. Meta-analysis of value of propranolol in prevention of variceal haemorrhage. *Lancet* 1990;336:153-156
- [49] Bartsch W, Sponer G, Strein K, Muller-Beckman B, von Mollendorf E, Abshagen U. Pharmacologie und klinische pharmakologie des neuen vasodilatorischen beta-rezeptoren blockers. *BMJ* 1982;32:5714
- [50] Bosch J. Carvedilol for portal hypertension in patients with cirrhosis. *Hepatology* 2010;51(6):2214
- [51] Forrest EH, Bouchier IA, Hayes PC. Acute haemodynamic changes after oral carvedilol, a vasodilating beta-blocker, in patients with cirrhosis. *J Hepatol* 1996;25(6):909-915
- [52] Stanley AJ, Therapondos G, Helmey A, Hayes PC. Haemodynamic effects of acute and chronic administration of low dose carvedilol in patients with cirrhosis. *J Hepatol* 1999;30(3):479-484
- [53] Tripathi D, Ferguson JW, Kochar N, et al. Randomised controlled trial of carvedilol versus variceal band ligation for the prevention of first variceal bleed. *Hepatology* 2009;50(3):825-833
- [54] Tripathi D, Therapondos G, Lui HF, Stanley AJ, Hayes PC et al. Haemodynamic effects of acute and chronic administration of low-dose carvedilol, a vasodilating beta-blocker, in patients with cirrhosis and portal hypertension. *Aliment Pharmacol Ther* 2002;16(3):373-80

- [55] Serste T, Melot C, Francoz C, et al. Deleterious effects of beta-blockers on survival in patients with cirrhosis and refractory ascites. *Hepatology* 2010;52(3):1017-22
- [56] Krag A, Wiest R, Albillos A, Gluud LL. The window hypothesis: haemodynamic and non-haemodynamic effects of  $\beta$ -blockers improve survival of patients with cirrhosis during a window in the disease. *Gut*. 2012;61(7):967-9.
- [57] The Veterans Affairs Cooperative Variceal Sclerotherapy Group. Prophylactic Sclerotherapy for Esophageal Varices in Men with Alcoholic Liver Disease — A Randomized, Single-Blind, Multicenter Clinical Trial.. *N Engl J Med* 1991; 324:1779-1784
- [58] Lay CS, Tsai YT, Teg CY, et al. Endoscopic variceal ligation in prophylaxis of first variceal bleeding in cirrhotic patients with high-risk esophageal varices. *Hepatology* 1997;25(6):1346-1350
- [59] Sarin SK, Lamba GS, Kumar M, et al. Comparison of endoscopic ligation and propranolol for the primary prevention of variceal bleeding. *N Engl Med* 1999;340(13): 988-993
- [60] Lui HF, Stanley AJ, Forrest EH, et al. Primary prophylaxis of variceal haemorrhage: a randomised controlled trial comparing band ligation, propranolol, and isosorbide mononitrate. *Gastroenterology* 2002;123(3):735-744
- [61] Imperiale TF, Chalasani N. A meta-analysis of endoscopic variceal ligation for primary prophylaxis of esophageal variceal bleeding. *Hepatology* 2001;33(4):802-807
- [62] Khuroo MS, Khuroo NS, Farahat KL, et al. Meta-analysis: endoscopic variceal ligation for primary prophylaxis of oesophageal variceal bleeding. *Aliment Pharmacol Ther* 2005;21(4):347-361
- [63] Gluud LL, Klingenberg S, Nikolova D, Gluud C. Banding ligation versus Beta-blockers as primary prophylaxis in esophageal varices: a systematic review of randomised trials. *Am J Gastroenterol* 2007;102(12):2842-2848
- [64] Mishra SR, Sharma BC, Kumar A, Sarin SK. Primary prophylaxis of gastric variceal bleeding comparing cyanoacrylate injections and beta-blockers: a randomised controlled trial. *J Hepatol* 2011;54(6):1161-1167
- [65] Chalasani N, Kahi C, Francois F, et al. Improved patient survival after acute variceal bleeding: a multicentre cohort study. *Am J Gastroenterol* 2003;98(3):653-9
- [66] Kravetz D, Sikuler E, Groszmann RJ. Splanchnic and systemic hemodynamics in portal hypertensive rats during hemorrhage and blood volume restitution. *Gastroenterology* 1986;90(5 Part 1):1232-1240
- [67] Castaneda B, Morales J, Lionetti R, et al. Effects of blood volume restitution following a portal hypertensive-related bleeding in anesthetized cirrhotic rats. *Hepatology* 2001;33(4):821-825.



- [68] Hou MC, Lin HC, Liu TT, et al. Antibiotic prophylaxis after endoscopic therapy prevents rebleeding in acute variceal haemorrhage: a randomised controlled trial. *Hepatology* 2004;39(3):746-53
- [69] Soares-Weiser K, Brezis M, Tur-Kaspa R, et al. Antibiotic prophylaxis of bacterial infections in cirrhotic inpatients: a meta-analysis of randomised controlled trials. *Scand J Gastroenterol* 2003;38(2):193-200
- [70] Burroughs AK, Planas S, Svoboda P. Optimising care of upper gastrointestinal bleeding in cirrhotic patients. *Scand J Gastroenterol* 1998;226:14-24
- [71] Ianno G, Doust J, Rockey DC. Terlipressin for acute esophageal variceal haemorrhage. *Cochrane Database Syst Rev*. 2003;(1):CD002147
- [72] Gotzsche PC, Hrobjartsson A. Somatostatin analogues for acute bleeding oesophageal varices. *Cochrane Database Syst Rev* 2008;3:CD000193
- [73] Baik SK, Jeong PH, Ji SW, et al. Acute hemodynamic effects of octreotide and terlipressin in patients with cirrhosis: a randomized comparison. *Am J Gastroenterol* 2005;100(3):631-5
- [74] Escorsell A, Bandi JC, Andreu V, et al. Desensitisation to the effects of octreotide in cirrhotic patients with portal hypertension. *Gastroenterology* 2001;120(1):161-169
- [75] Spahr L, Giostra E, Frossard JL, et al. A 3-month course of long-acting repeatable octreotide (sandostatin LR) improves portal hypertension in patients with cirrhosis: a randomized controlled study. *Am J Gastroenterol* 2007;102(7):1397-1405
- [76] Chen J, Grozsmann RJ. Blood in the gastric lumen increases splanchnic portal flow and portal pressure in portal-hypertensive rats. *Gastroenterology* 1986;111:1103-
- [77] Ludwig D, Schadel S, Bruning A, Schiefer B, Stange EF, et al. 48-hour hemodynamic effects of octreotide on postprandial splanchnic hyperemia in patients with liver cirrhosis and portal hypertension: double-blind, placebo-controlled study. *Dig Dis Sci* 2000;45(5):1019-1027
- [78] Imperiale TF, Teran JC, McCullough AJ. A meta-analysis of somatostatin versus vasopressin in the management of acute esophageal variceal haemorrhage. *Gastroenterology* 1995;109(4):1289-1294
- [79] Hartigan PM, Gebhard RL, Gregory PB. Sclerotherapy for actively bleeding esophageal varices in male alcoholics with cirrhosis. Veterans Affairs Cooperative Variceal Sclerotherapy Group. *Gastrointest Endoscop* 1997;46(1):1-7
- [80] Piquet KJ, Flessner H. Endoscopic sclerosis and esophageal balloon tamponade in acute haemorrhage from esophagogastric varices: a prospective controlled randomized trial. *Hepatology* 1985; 5(4): 580-583
- [81] Westaby D, Hayes PC, Gibson AE, Polson RJ, Williams R. Controlled clinical trial of injection sclerotherapy for active variceal bleeding. *Hepatology* 1989;9(2):272-277



- [82] Larson AW, Cohen H, Zweiban B, et al. Acute esophageal variceal sclerotherapy. Results of a prospective randomized controlled trial. *JAMA* 1986;255(4):497-500
- [83] Moreto M, Zaballa M, Bernal A, et al. A randomized trial of tamponade or sclerotherapy as immediate treatment for bleeding esophageal varices. *Surg Gynecol Obstet* 1988;167(4):331-334
- [84] Traintos CK, Goulis J, Patch D, et al. An evaluation of emergency sclerotherapy of varices in randomized trials: looking the needle in the eye. *Endoscopy* 2006;38(8):797-807
- [85] Garcia-Pagan JC, Bosch J. Endoscopic band ligation in the treatment of portal hypertension. *Nat.Clin Pract.Gastroenterol Hepatol* 2005;2(11):526-535.
- [86] Avgerinos A, Armonis A, Stefanidis G, et al. Sustained rise of portal pressure after sclerotherapy, but not band ligation, in acute variceal bleeding in cirrhosis. *Hepatology* 2004;39(6):1623-1630.
- [87] Laine L, Cook D. Endoscopic ligation compared to sclerotherapy for treatment of esophageal variceal bleeding. A meta-analysis. *Ann Inter Med* 1995;123(4):280-287
- [88] Banares R, Albillos A, Rincon D, et al. Endoscopic treatment versus endoscopic plus pharmacologic treatment for acute variceal bleeding: a meta-analysis. *Hepatology* 2002;35(3):609-615
- [89] D'Amico G, Criscuoli V, Fili D, Mocciaro D, F, Pagliaro L. Meta-analysis of trials for variceal bleeding. *Hepatology* 2002;36(4 Pt 1):1023-1024
- [90] Novella MT, Villanueva C, Ortiz J, et al. Octreotide vs sclerotherapy and octreotide for acute variceal bleeding. A pilot study. *Hepatology* 1996;24(suppl): 207A
- [91] Villanueva C, Ortiz J, Sabat M, et al. Octreotide in acute bleeding esophageal varices: a prospective randomized trial. *Hepatology* 1999;30(2):384-389
- [92] Hubmann R, Bodlaj G, Czompo M, Benko L, Pichler P, et al. The use of self-expanding metal stents to treat acute esophageal variceal bleeding. *Endoscopy* 2006; 38: 896-901
- [93] Teres J, Planas R, Panes J, et al. Vasopressin/nitroglycerine infusion vs esophageal tamponade in the treatment of acute variceal bleeding: a randomized controlled trial. *Hepatology* 1990;11(6):964-968
- [94] Monescillo A, Martinez-Lagares F, Ruiz-Del-Arbol L, et al. Influence of portal hypertension and its early decompression by TIPS placement on the outcome of variceal bleeding. *Hepatology* 2004;40:793-801
- [95] Burroughs AK, Triantos CK. Predicting failure to control bleeding, and mortality in acute variceal bleeding. *J Hepatology* 2008;48(2):185-188

- [96] Sanyal A, Freedman Am, Luketic VA, et al. Transjugular intrahepatic portosystemic shunts for patients with active variceal hemorrhage unresponsive to sclerotherapy. *Gastroenterology* 1996;111(1): 138-146
- [97] Chau TN, Patch D, Chan YW, et al. "Salvage" transjugular intrahepatic portosystemic shunts: gastric fundal compared with esophageal variceal bleeding. *Gastroenterology* 1998;114(5):981-987
- [98] Trudeau W, Prindville T. Endoscopic injection sclerosis in bleeding gastric varices. *Gastrointest Endosc* 1986;32(4):264-268
- [99] Thakeb F, Salem SA, Abdallah M, el Batanouny M. Endoscopic diagnosis of gastric varices. *Endoscopy* 1994;26(3):287-291.
- [100] Bretagne JF, Dudicourt JC, Morisot D, et al. Is endoscopic variceal sclerotherapy effective for the treatment of gastric varices.(abstr) *Dig Dis Sci* 1986;31:505S
- [101] Sarin SK. Long term follow up gastric variceal sclerotherapy: an eleven-year experience. *Gastrointest Endosc* 1997;46(1):8-14
- [102] Ogawa K, Ishikawa S, Naritaka Y, et al. Clinical evaluation of endoscopic injection sclerotherapy using N-Butyl-2-Cyanoacrylate for gastric variceal bleeding. *J Gastroenterol Hepatol* 1999; 14(3):245-50
- [103] Hirota S, Matsumoto S, Tomita, Sako M, Kono M.. Retrograde transvenous obliteration of gastric varices. *Radiology* 1999 ;211(2) :349-356
- [104] Kim T, Shijo H, Kokawa H, et al. Risk factors for hemorrhage from gastric fundal varices. *Hepatology* 1997 ;25(2) :307-312
- [105] Gotlib JP, Zimmerman P. Une nouvelle technique de traitement endoscopique des varices oesophagiennes: l'obliteration. *Endosc Dig* 1984;7:10-12
- [106] Sarin SK, Sachdev G, Nanda R, Misra SP Broor SI. Endoscopic Sclerotherapy in the treatment of gastric varices. *Br J Surg* 1988;75(8):747-750
- [107] Jalan R, Hayes PC. UK Guidelines on the management of variceal haemorrhage in cirrhotic patients. British Society of Gastroenterology. *Gut* 2000;46 (Suppl. 3-4):III1-III5
- [108] Lee MS, Shim CS. Is endoscopic ligation therapy with large detachable snare and elastic bands really safe and effective? Response. *Gastrointest Endosc* 2003;57:439-440
- [109] Billi P, Milandri GL, Borioni D, Fabbri C, Baroncini D, Cennamo V, et al. Endoscopic treatment of gastric varices with N-butyl-2-cyanoacrylate: a long term follow up (abstract). *Gastrointest Endosc* 1998; 47:AB26
- [110] Huang YH, Yeh HZ, Chen GH, et al. Endoscopic treatment of bleeding gastric varices by N-butyl-2-cyanoacrylate (Histoacryl) injection: long term efficacy and safety. *Gastrointest Endosc* 2000;52:160-7

- [111] Seewald S, Naga M, Onar S, et al. Standardised injection technique and regimen minimises complication and ensures safety of N-Butyl-2-Cyanoacrylate injection for the treatment of Gastric Fundal Varices. *GastroIntest Endosc* 2005; 61 (5): AB91-372
- [112] Iwase H, Maeda O, Shinida M, et al. Endoscopic ablation with cyanoacrylate glue for isolated gastric variceal bleeding. *Gastrointest Endosc* 2001; 53(6):585-596
- [113] Rajoriya N, Forrest EH, Gray J, et al. Long-term follow-up of endoscopic Histoacryl glue injection for the management of gastric variceal bleeding. *QJM*. 2011 Jan;104(1): 41-47.
- [114] Sarin SK, Jain AK, Jain M, Gupta R. A randomised controlled trial of cyanoacrylate versus alcohol injection in patients with isolated fundic varices. *Am J Gastroenterol* 2002;97(4):1010-1015
- [115] Lo GH, Lai KH, Cheng JS, Chen MH, Chiang HT. A prospective, randomised trial of butyl cyanoacrylate injection versus band ligation in the management of bleeding gastric varices. *Hepatology* 2001;33(5):1060-1064
- [116] Mishra SR, Chander Sharma B, Kumar A, Sarin SK. Endoscopic cyanoacrylate injection versus beta-blocker for secondary prophylaxis of gastric variceal bleed: a randomised controlled trial. *Gut* 2010;59(6):729-735
- [117] Hung HH, Chang CJ, Hou MC, et al. Efficacy on non-selective B-Blockers as adjunct to endoscopic prophylactic treatment for gastric variceal bleeding: A randomized controlled trial. *J Hepatol* 2012;56(5):1025-1032
- [118] Tripathi D, Ferguson JW, Therapondos G, Pleveris JN, Hayes PC. Review article: recent advances in the management of bleeding gastric varices. *Aliment Pharmacol Therap* 2006;24(1):1-17
- [119] Kitano S, Hashizume M, Yamaga H, et al. Human thrombin plus 5 per cent ethanolamine oleate injected to sclerose oesophageal varices: a prospective randomized trial. *Br J Surg* 1989; 76(7): 715–718.
- [120] Przemioslo RT, McNair A, Williams R. Thrombin is effective in arresting bleeding from gastric variceal hemorrhage. *Dig Dis Sci* 1999; 44(4): 778–781.
- [121] Snobl J, Van Buuren HR, Van Blankenstein M. Endoscopic injection using thrombin: an effective and safe method for controlling oesophagogastric variceal bleeding. *Gastroenterology* 1992;102: A891 (abstract).
- [122] Williams SG, Peters RA, Westaby D. Thrombin – an effective treatment for gastric variceal haemorrhage. *Gut* 1994; 35(9): 1287–1289.
- [123] Heneghan MA, Byrne A, Harrison PM. An open pilot study of the effects of a human fibrin glue for endoscopic treatment of patients with acute bleeding from gastric varices. *Gastrointest Endosc* 2002; 56(3): 422–426.
- [124] Datta D, Vlavianos P, Alisa A, Westaby D. Use of fibrin glue (beriplast) in the management of bleeding gastric varices. *Endoscopy* 2003; 35(8): 675–678.

- [125] Yang WL, Tripathi D, Therapondos G, Todd A, Hayes PC. Endoscopic use of human thrombin in bleeding gastric varices. *Am J Gastroenterol* 2002; 97(6): 1381–1385.
- [126] Albillos A, Ruiz Del Arbol L, “Salvage” transjugular intrahepatic portosystemic shunt: gastric fundal compared with esophageal variceal bleeding. *Gastrointest Endosc* 1999;50(2):294–295.
- [127] Stanley AJ, Jalan R, Ireland HM, et al. A comparison between gastric and oesophageal variceal haemorrhage treated with transjugular intrahepatic portosystemic stent shunt (TIPSS). *Aliment Pharmacol Ther* 1997;11(1):171–176.
- [128] Barange K, Peron JM, Imani K, et al. Transjugular intrahepatic portosystemic shunt in the treatment of refractory bleeding from ruptured gastric varices. *Hepatology* 1999;30(5):1139–1143.
- [129] Kiyosue H. Mori H. Matsumoto S. Yamada Y. Hori Y. Okino Y. Transcatheter obliteration of gastric varices. Part 1. Anatomic classification. *Radiographics*. 2003;23(4): 911-920
- [130] Choi YH. Yoon CJ. Park JH. Chung JW. Kwon JW. Choi GM. Balloon-occluded retrograde transvenous obliteration for gastric variceal bleeding: its feasibility compared with transjugular intrahepatic portosystemic shunt. *Korean Journal of Radiology*. 2003;4(2):109-116,
- [131] Matsumoto A, Haramoto N, Nomura T, Hongou Y, Arisaka Y, Morikawa H, Hirata I, Katsu K. Balloon-occluded retrograde transvenous obliteration of high risk gastric varices. *Am Journal of Gastroenterol*; 94(3):643-649
- [132] Garcia-Pagan JC, Caca K, Bureau C, et al. Early use of TIPS in patients with cirrhosis and variceal bleeding. *N Engl J Med* 2010;362(25):2370-2379.
- [133] Graham DY, Smith JL. The course of patients with variceal hemorrhage. *Gastroenterology* 1981;80(4):800-809
- [134] D’Amico G, de Franchis R.. Upper digestive bleeding in cirrhosis. Post-therapeutic outcome and prognostic indicators. *Hepatology* 2003;38(3):599-612
- [135] Bambha K, Kim WR, Pedersen R, et al. Predictors of early rebleeding and mortality after acute variceal hemorrhage in patients with cirrhosis. *Gut* 2008;57(6):814-820
- [136] Bosch J, Garcia-Pagan JC. Prevention of variceal rebleeding. *Lancet* 2003; 361:952-954
- [137] Bernard B, Lebrech D, Mathurin P, Opolon P, Poynard T. Beta-adrenergic antagonists in the prevention of gastrointestinal rebleeding in patients with cirrhosis: a meta-analysis. *Hepatology* 1997;25(1):63-70
- [138] Poynard T, Lebrech D, Hillon P, et al. Propanolol for the prevention of recurrent gastrointestinal bleeding in patients with cirrhosis: a prospective study of factors associated with rebleeding. *Hepatology* 1987;7(3):447-451

- [139] Bernard B, Lebre C, Mathurin P, Opolon P, Poynard T. Propranolol and sclerotherapy in the prevention of gastrointestinal rebleeding in patients with cirrhosis. *J Hepatol* 1997;26(2):312-324
- [140] Karsan H, Morton SC, Shekelle PG, et al. Combination of endoscopic band ligation and sclerotherapy compared with endoscopic band ligation alone for the secondary prophylaxis of esophageal variceal haemorrhage: A meta-analysis. *Dig Dis Sci* 2005;50(2):399-406
- [141] Gonzalez R, Zamora J, Gomez-Camero J, et al. Meta-analysis: Combination endoscopic and drug therapy to prevent variceal rebleeding in cirrhosis. *Ann Intern Med* 2008;149(2):109-22