

We are IntechOpen, the world's leading publisher of Open Access books Built by scientists, for scientists

6,900

Open access books available

186,000

International authors and editors

200M

Downloads

Our authors are among the

154

Countries delivered to

TOP 1%

most cited scientists

12.2%

Contributors from top 500 universities



WEB OF SCIENCE™

Selection of our books indexed in the Book Citation Index
in Web of Science™ Core Collection (BKCI)

Interested in publishing with us?
Contact book.department@intechopen.com

Numbers displayed above are based on latest data collected.
For more information visit www.intechopen.com



Optical Coherence Tomography (OCT): A New Imaging Tool During Carotid Artery Stenting

Shinichi Yoshimura, Masanori Kawasaki,
Kiyofumi Yamada, Arihiro Hattori,
Kazuhiko Nishigaki, Shinya Minatoguchi and
Toru Iwama

Additional information is available at the end of the chapter

<http://dx.doi.org/10.5772/53962>

1. Introduction

One of the mechanisms underlying acute stroke is the disruption of atherosclerotic plaques in major cerebral vessels, including the carotid arteries. However, visualizing precise arterial wall changes is sometimes difficult using conventional imaging techniques such as angiography, magnetic resonance imaging (MRI) or duplex ultrasonography. In particular, intraluminal thrombus is difficult to detect clearly during catheter interventions such as carotid artery stenting (CAS), even with utilization of intravascular ultrasonography (IVUS) [1,2]. When visualization of the carotid wall changes is possible during CAS, especially before and after angioplasty and stenting, it then becomes possible to select appropriate devices and methods of angioplasty and cerebral protection based on better anatomical information.

Intravascular optical coherence tomography (OCT) has recently been proposed as a high-resolution imaging tool for plaque characterization in the coronary arteries. OCT is a non-contact, light-based imaging method utilizing newly developed fiber-optic technology (Fig. 1). The typical OCT image has an axial resolution of 10 μm , approximately 10 times higher than that of any other clinically available diagnostic imaging modality such as IVUS with a resolution of 80 μm [3]. Therefore, despite the need for removing blood from the field of view, in vivo application of OCT has been reported useful in the coronary arteries [4-7]. For example, Jang IK et al reported that intracoronary OCT identified most architectural features detected by IVUS and provided additional detailed structural information [4]. Kawasaki M et al claimed that OCT had the best potential for tissue characterization of coronary plaques, within the

penetration depth of OCT, in a comparative study with IVUS [7]. Based on these results, we speculated that intravascular OCT would also be useful for the other vessels. Our use of OCT for human carotid arteries was approved by our institutional review board (No. 21-108), and recently registered on the Internet (University Hospital Medical Information Network: UMIN 000002808).

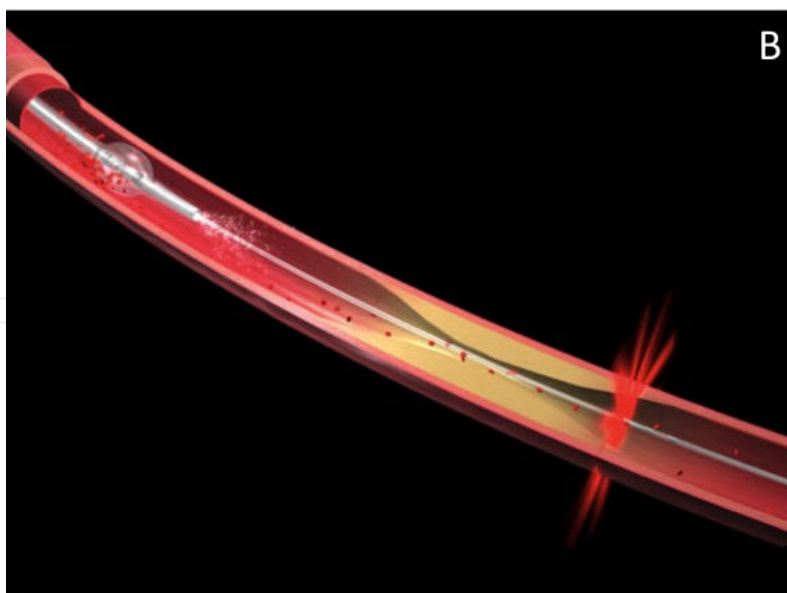


Figure 1. Images of an optical coherence tomography (OCT) system and an imagewire. This is the first generation of OCT analyzer (M2 OCT Imaging system, LightLab Imaging, Inc., Westford, Massachusetts, A), which was used for our clinical studies. An imagewire is schematically demonstrated to show its scanning capabilities during the target artery occlusion using an occlusion balloon (B).

2. First application of OCT for the human carotid artery

Our group first applied intravascular OCT in a patient with a large thrombus in the carotid artery [8]. An 83-year old male admitted due to motor weakness of the left hand. Diffusion weighted MRI showed multiple high intensity spots in the territory of the right middle cerebral artery, and magnetic resonance angiography (MRA) revealed significant stenosis at the origin of the right internal carotid artery (Fig. 2A). Because of an apparent change in plaque shape on the angiogram just before CAS (Fig. 2B), further examinations such as IVUS and OCT were performed. After IVUS examination (Fig. 2D), both the common carotid and external carotid arteries were occluded by an occlusion balloon system prepared for CAS. Then, the stenotic site was imaged by OCT (M2 OCT Imaging system, LightLab Imaging, Inc., Westford, Massachusetts) from the distal section at 1mm/sec using a built-in pull-back system with continuous injection of saline through the guiding catheter to remove blood from the field of view. Intraluminal thrombus was clearly demonstrated by OCT (Fig. 2C), and carotid endarterectomy was performed instead of stenting to avoid distal migration of the thrombus during the revascularization procedure. The carotid artery specimen obtained by endarterectomy showed a soft plaque with a large intraluminal thrombus, which correlated with OCT findings performed preoperatively (Fig. 2E,F). This was the first report of a clinical application of the OCT in the carotid artery, and the intraluminal thrombus detected by OCT was successfully confirmed by histological analysis of the surgical specimen.

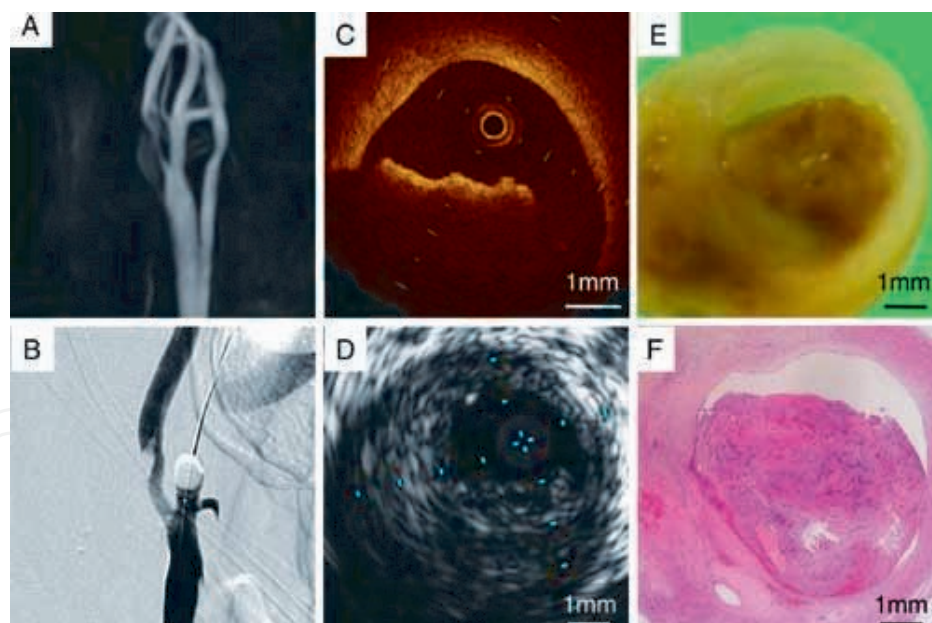


Figure 2. An intraluminal thrombus in the carotid artery demonstrated by OCT and confirmed by pathological analysis. A: initial magnetic resonance angiography revealed severe stenosis of the internal carotid artery (ICA) and high-intensity plaque. B: the carotid angiogram showed ICA stenosis and enlargement of an intraluminal protrusion in the ICA. C: cross sections by OCT demonstrated an intraluminal thrombus with shadowing in the ICA. D: cross sections by intravascular ultrasonography showed only eccentric and low-echoic plaque in the ICA. E: macroscopic view of a surgical specimen showing an intraluminal thrombus formed at the ruptured site of the plaque. F: pathological analysis with hematoxylin-eosin staining confirmed soft plaque with intraplaque hemorrhage and an intraluminal red thrombus, which correlated with OCT findings. This study was reported previously [8].

It has been reported that neither angiography nor IVUS can reliably demonstrate the presence of a thrombus [1]. In this patient, a thrombus in the carotid artery was clearly demonstrated by preoperative OCT. Due to the size of thrombus the information provided by OCT which altered therapy, possible embolism and its consequences of hemiparesis or speech disturbance was averted.

Kume et al reported that OCT could differentiate between red and white coronary arterial thrombi by post mortem, ex vivo experiments [9]. Meng et al reported on the feasibility of OCT for the detection of in vivo acute thrombosis in the carotid artery using an animal model [10]. They also reported an excellent correlation between OCT images and histology regarding thrombus length and location. OCT images of red thrombi are characterized as highly backscattered protrusions with signal-free shadowing. A red thrombus consists mainly of red blood cells, causing scatter and attenuation of OCT signal intensity from the inner surface of the thrombus to the vessel wall. In our patient, the protruded mass in the ICA (Fig. 2B) was diagnosed as a red thrombus by OCT (Fig. 2C) because of signal attenuation behind the mass, and pathologically confirmed thereafter (Fig. 2E,F).

3. Comparison of OCT with IVUS during stenting

Next, this group applied OCT for the carotid artery during stenting as a clinical study. In this study, we evaluated the ability of OCT to visualize structures of the carotid artery wall when compared with IVUS. We reported typical images of this preliminary OCT application to human carotid arteries during CAS [11]. OCT was performed on 20 plaques of 17 patients

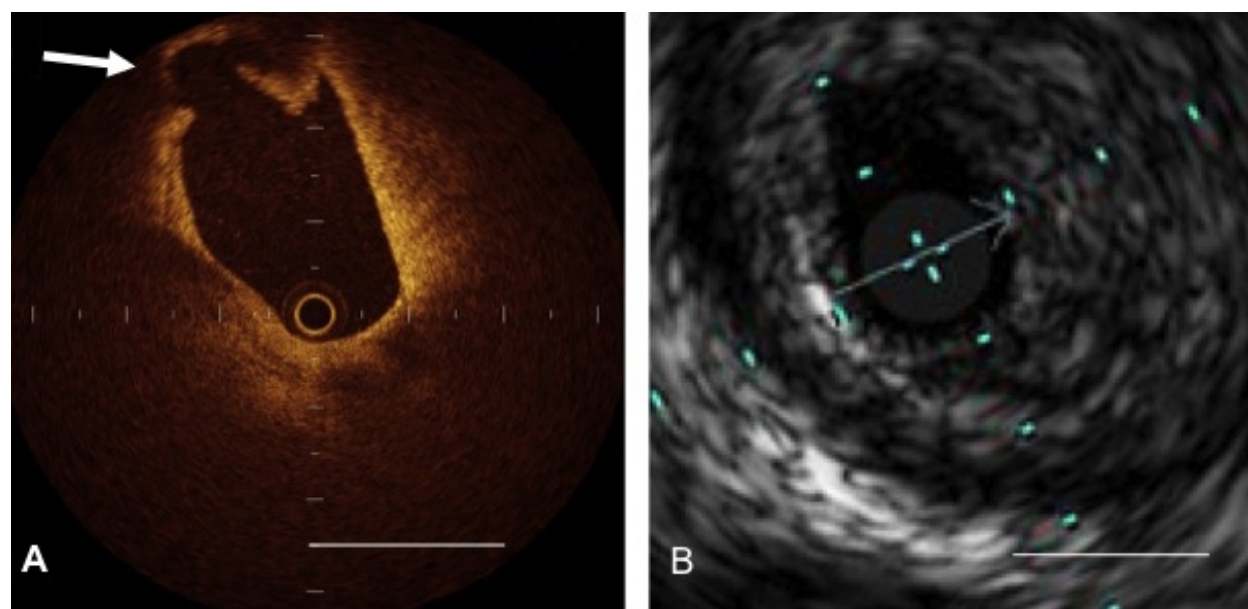


Figure 3. Representative images of carotid plaque with fibrous cap disruption from a symptomatic patient with right ICA stenosis prior to carotid artery stenting (CAS). A: an image from OCT shows fibrous cap disruption as a discontinuous fibrous cap and cavity formation (arrow). B: IVUS was not able to detect the fibrous cap disruption. The bar in both A and B equals 2 mm. This study was reported previously [11].

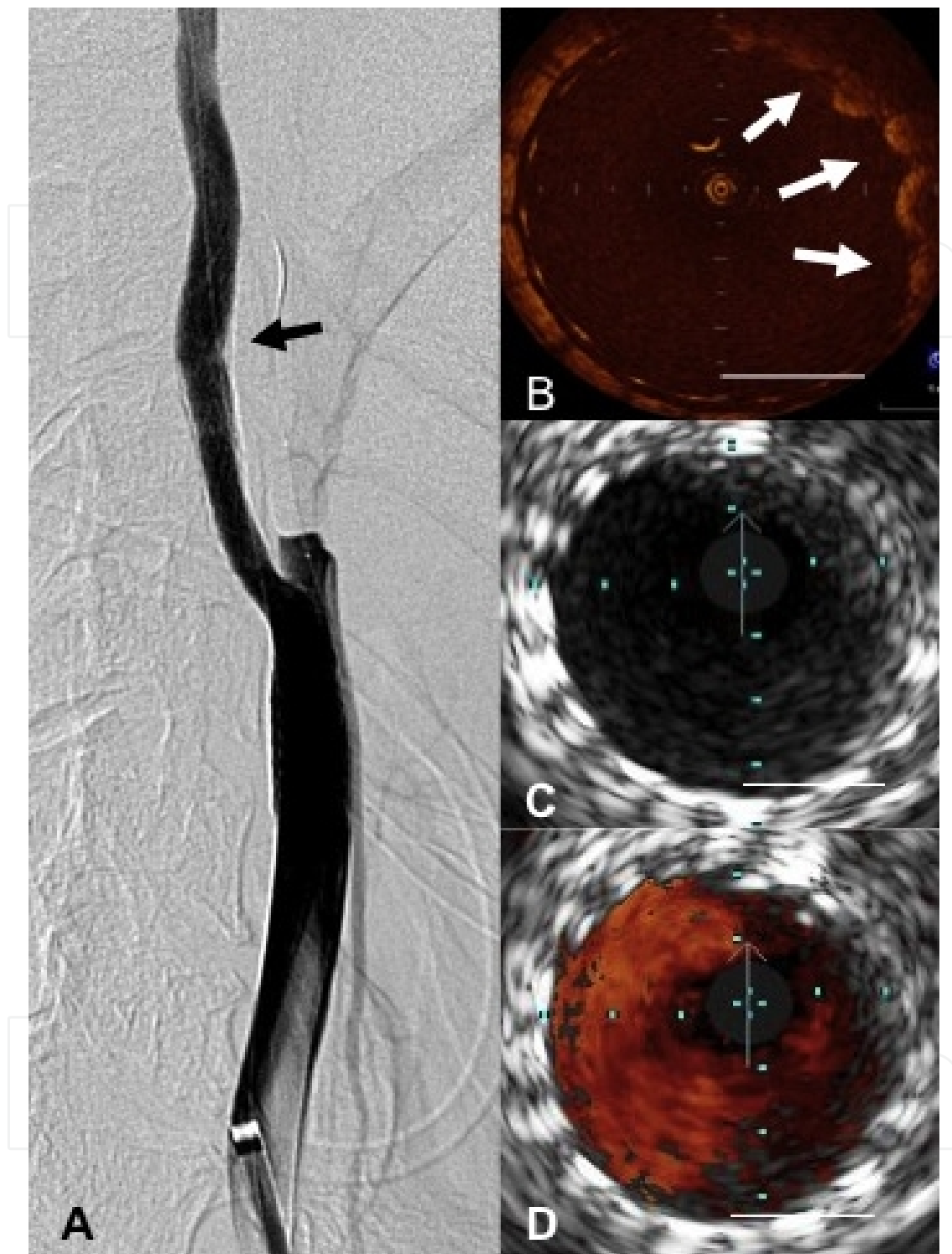


Figure 4. Tissue Protrusion. Representative images of carotid plaque protrusion in a symptomatic patient with left ICA stenosis after carotid artery stenting (CAS). Plaque protrusion is considered to be one source for the embolic complication after CAS. Plaque protrusion from stent struts just after stent deployment was clearly demonstrated by OCT, but was overlooked by IVUS. A: Carotid angiogram demonstrating the plaque protrusion after stent placement (arrow). B: OCT demonstrates tissue protrusion from spaces between stent struts (white arrows). C, D: IVUS with and without ChromaFlo (Eagle Eye Gold, Volcano Therapeutics, Rancho Cordova, California) was unable to see plaque protrusions. The bar in B, C, and D equals 2 mm. This study was reported previously [11].

during CAS, under a proximal cerebral protection method. In addition to intraluminal thrombus, fibrous cap disruption (Fig. 3) and plaque protrusion after stenting (Fig. 4) were easily detected by OCT. There were no technical or neurological complications in this series. OCT could best visualize the lateral side of lumen pathology (intraluminal thrombus or fibrous cap disruption) with a high resolution of 10 μ m, whereas IVUS, MRI, or computed tomography allowed assessment of the entire arterial wall, albeit with lesser resolution. OCT and IVUS thus complement each other and may aid in discriminating plaques that are eligible for CAS.

4. Differences between symptomatic and asymptomatic plaques by OCT

Another study to evaluate the ability of OCT to visualize carotid artery plaques as compared to that of IVUS in asymptomatic and symptomatic patients was performed ¹². In this study, OCT was used for 34 plaques (17 symptomatic, 17 asymptomatic) in 30 patients during CAS under a proximal cerebral protection method. OCT was performed before balloon angioplasty and after stent placement. IVUS was performed after OCT. Among pre-stenting findings, intraluminal thrombus and neovascularization were significantly more frequently detected by OCT than by VH-IVUS ($p<0.001$). Ulceration also tended to be more frequently detected by OCT than by IVUS, but the difference was not significant (Table 1). Conversely, calcification was less frequently detected by OCT than by IVUS ($p<0.001$; Table 1). No difference in the detection of the lipid rich necrotic core was seen between OCT and IVUS (Table 1).

	OCT	VH-IVUS	p-value
Pre-stenting (n = 34)			
Thrombus, n (%)	15 (44.1)	1 (2.9)	<0.001
Neovascularization, n (%)	13 (38.2)	0 (0)	<0.001
Ulceration, n (%)	3 (8.8)	0 (0)	0.24
Calcification, n (%)	13 (38.2)	34 (100)*	<0.001
Lipid, n (%)	28 (82.4)	30 (88.2)**	0.73
Post-stenting (n = 34)			
Plaque protrusion, n (%)	6 (17.6)	0 (0)	0.032

*: shown as 'dense calcified', **: shown as 'fibrofatty and/or necrotic core' on VH-IVUS

Table 1. Comparison of OCT and VH-IVUS findings

OCT detected differences between symptomatic and asymptomatic carotid plaques (Table 2): intraluminal thrombus was more frequently observed in symptomatic plaques (76.5%) than in asymptomatic plaques (11.8%; $p<0.001$); and, neovascularization was also more often observed in symptomatic plaques (58.8%) than in asymptomatic plaques (17.6%; $p=0.03$). In contrast, no significant differences were seen in the incidence of other findings such as

calcification, lipid-rich necrotic core, ulceration, and plaque protrusion after stent placement between groups. *Interobserver* and *intraobserver* variability with OCT diagnosis was excellent for thrombus, ulceration, neovascularization, and lipid pool.

	Symptomatic	Asymptomatic	p-value
	(n=17)	(n=17)	
Male, n (%)	14 (82.4)	15 (88.2)	" />0.99
Age, yr	72 ± 10	68 ± 10	0.19
Degree of stenosis, %	84 ± 12	79 ± 7	0.26
OCT findings			
Thrombus	13 (76.5)	2 (11.8)	<0.001
Neovascularization	10 (58.8)	3 (17.6)	0.03
Ulceration	3 (17.6)	0 (0)	0.23
Calcification	7 (41.2)	6 (35.3)	" />0.99
Lipid-rich component	16 (94.1)	12 (70.6)	0.17
Plaque protrusion	4 (23.5)	2 (11.8)	0.66

Table 2. OCT findings of symptomatic and asymptomatic lesions

5. Limitations and recent advances of the OCT system

The major limitations of OCT are interference by blood flow and the degree of tissue penetration. To obtain a bloodless field of view, a proximal protection method which uses occlusion balloons for the common and external carotid arteries is required for the application of OCT in the cervical carotid artery [8, 11, 12]. The scanning length of OCT was 3.25 to 3.4 mm in normal saline. Therefore, in the carotid artery, plaque components located on the far side of the luminal surface were sometimes not visualized by OCT due to its limited penetration depth. Recently, a new frequency domain OCT system was developed. This new system does not need occlusion of the target artery due to faster scanning (Table 3). Setacci et al. document the benefits of this new OCT system utilizing a non-occlusive technique in the carotid artery [13]. In their report, the new system not only safely eliminated the need to occlude the carotid artery, but also acquired good quality images and informative details before and after stenting. Notably, the new OCT catheter can visualize arteries up to 10 mm in diameter, encompassing the entire carotid artery. Thus, this new system seems to overcome the imitations of the previous iteration, allowing OCT to be applied safely, easily, and efficiently in the carotid artery. Future studies are expected to investigate the relationship between carotid plaques and stents with regard to stent design and plaque composition.

	New version (C7)	Previous version (M2)
Axial Resolution	12 - 15 μ m	15 - 20 μ m
Beam Width	20 – 40 μ m	20 – 40 μ m
Frame Rate	100 frames/s	15 frames/s
Pullback Speed	20 mm/s	2 mm/s
Max. Scan Dia.	10 mm	6.8 mm
Tissue Penetration	1.0 - 2.0 mm	1.0 - 2.0 mm
Lines per Frame	500	200
Lateral Resolution (3mm Artery)	19 μ m	39 μ m

Table 3. Comparison of new and previous version of OCT

6. Conclusions

Optical coherence tomography (OCT) is a useful tool in the assessment of intraluminal thrombus before interventional procedure. Also, its excellent resolution may detect plaque protrusions after carotid artery stenting alerting to possible complications. Further studies with a new system utilizing a non-occlusive technique are expected to investigate the clinical applicability of OCT to characterize carotid plaque components and intraluminal changes during CAS.

Acknowledgements

We have no financial or other relations that could lead to a conflict of interest.

Author details

Shinichi Yoshimura^{1*}, Masanori Kawasaki², Kiyofumi Yamada², Arihiro Hattori², Kazuhiko Nishigaki², Shinya Minatoguchi¹ and Toru Iwama¹

*Address all correspondence to: shinichiyoshimura@hotmail.com

¹ Department of Neurosurgery, and Regeneration & Advanced Medical Science, Graduate School of Medicine, Gifu University, Gifu, Japan

² Department of Radiology, University of Washington, Seattle, USA

References

- [1] Timaran, C. H, Rosero, E. B, Martinez, A. E, et al. Atherosclerotic plaque composition assessed by virtual histology intravascular ultrasound and cerebral embolization after carotid stenting. *J Vasc Surg* (2010). , 52, 1188-94.
- [2] Hishikawa, T, Iihara, K, Ishibashi-ueda, H, et al. Virtual histology-intravascular ultrasound in assessment of carotid plaques: ex vivo study. *Neurosurgery* (2009). , 65, 146-52.
- [3] Mintz, G. S, Nissen, S. E, Anderson, W. D, et al. American College of Cardiology clinical expert consensus document on standards for acquisition, measurement and reporting of intravascular ultrasound studies (IVUS). A report of the American College of Cardiology task force on clinical expert consensus documents developed in collaboration with the European society of cardiology endorsed by the society of cardiac angiography and interventions. *J Am Coll Cardiol* (2001). , 37, 1478-92.
- [4] Jang, I. K, Bouma, B. E, Kang, D. H, et al. Visualization of coronary atherosclerotic plaques in patients using optical coherence tomography: comparison with intravascular ultrasound. *J Am Coll Cardiol* (2002). , 39, 604-9.
- [5] Yabushita, H, Bouma, B. E, Houser, S. L, et al. Characterization of human atherosclerosis by optical coherence tomography. *Circulation* (2002). , 106, 1640-5.
- [6] Jang, I. K, & Tearney, G. J. MacNeill B, et al. In vivo characterization of coronary atherosclerotic plaque by use of optical coherence tomography. *Circulation* (2005). , 111, 1551-5.
- [7] Kawasaki, M, Bouma, B. E, Bressner, J, et al. Diagnostic accuracy of optical coherence tomography and integrated backscatter intravascular ultrasound images for tissue characterization of human coronary plaques. *J Am Coll Cardiol* (2006). , 48, 81-8.
- [8] Yoshimura, S, Kawasaki, M, Yamada, K, et al. Demonstration of intraluminal thrombus in the carotid artery by optical coherence tomography. *Neurosurgery* (2010). Suppl Operative):onsE305.
- [9] Kume, T, Akasaka, T, Kawamoto, T, et al. Assessment of coronary arterial thrombus by optical coherence tomography. *Am J Cardiol* (2006). , 97, 1713-7.
- [10] Meng, L, Lv, B, Zhang, S, & Yv, B. In vivo optical coherence tomography of experimental thrombosis in a rabbit carotid model. *Heart* (2008). , 94, 777-80.
- [11] Yoshimura, S, Kawasaki, M, Yamada, K, et al. OCT of human carotid arterial plaques. *JACC Cardiovasc Imaging* (2011). , 4, 432-6.
- [12] Yoshimura, S, Kawasaki, M, Yamada, K, et al. Visualization of internal carotid artery atherosclerotic plaques in symptomatic and asymptomatic patients: a comparison of optical coherence tomography and intravascular ultrasound. *AJNR Am J Neuroradiol* (2012). , 33, 308-13.

- [13] Setacci, C, De Donato, G, Setacci, F, et al. Safety and feasibility of intravascular optical coherence tomography using a nonocclusive technique to evaluate carotid plaques before and after stent deployment. *J Endovasc Ther* (2012). , 19, 303-11.
- [14] Yoshimura, S. Intravascular optical coherence tomography: a new, more detailed view of the carotid arteries. *J Endovasc Ther* (2012). , 19, 314-5.

IntechOpen

IntechOpen