

We are IntechOpen, the world's leading publisher of Open Access books Built by scientists, for scientists

6,900

Open access books available

186,000

International authors and editors

200M

Downloads

Our authors are among the

154

Countries delivered to

TOP 1%

most cited scientists

12.2%

Contributors from top 500 universities



WEB OF SCIENCE™

Selection of our books indexed in the Book Citation Index
in Web of Science™ Core Collection (BKCI)

Interested in publishing with us?
Contact book.department@intechopen.com

Numbers displayed above are based on latest data collected.
For more information visit www.intechopen.com



Classification and Clinical Features of AMD

Petr Kolar

Additional information is available at the end of the chapter

<http://dx.doi.org/10.5772/53762>

1. Introduction

Disease was first time described as “Symmetrical central choroido-retinal disease occurring in senile persons” in 1874 by Hutchinson. About 25 years ago, the term “age-related maculopathy” was accepted and end stage of disease was acknowledged as age-related macular degeneration [1]. AMD is leading cause of blindness worldwide in older patient population. The highest risk of developing of AMD is in the population older than 65 years. With ageing of population in many countries, more than 20 % might have the disease [2]. Advanced forms of AMD are associated with visual progressive impairment. Visual acuity of this subjects decreases to practical blindness. This has big socioeconomic impact.

AMD is progressive chronic disease that is located in central retinal area (macula lutea – yellow spot) [2]. Most visual lost is identified in late stages of AMD. There are 2 categories: wet AMD and geographic atrophy. In wet AMD choroidal neovascularization breaks through neuroretina. Leaking vessels, hemorrhages and lipid deposits lead to scarring process in macular area. All retinal structures including photoreceptors are destroyed. In geographic atrophy occur progressive atrophy of retinal pigment epithelium and secondary photoreceptors. To the end of 20th century was AMD practically untreatable. However, new pharmaceuticals based on suppression of vascular endothelial growth factor (VEGF) have completely changed the treatment of the disease [2]. Nearly 95 % of patients can be prevented from visual lost, and nearly 40 % of them improve vision [2].

2. Epidemiology, risk factors, and natural history

Prevalence and incidence

In last 30 years were published many epidemiological studies on AMD. In a meta-analysis of population-based studies in white people aged 40 years and older, the prevalence of early

age-related macular degeneration was estimated to be 6.8% and late age-related macular degeneration 1.5%[3].

Results from the Baltimore Eye Study reported epidemiological data from other ethnic groups. Late AMD was nine to ten times more prevalent in white participants than in black ones [4]. Age-specific prevalence of late age-related macular degeneration in Asians is largely similar to that in white people [5].

In Asia population have often disease specific features. Many of them have polypoidal dilatation of the choroidal vasculature. Polypoidal choroidal vasculopathy can account for 50% of wet AMD cases in Asians, but only 8-13% in white people [5].

Another variant of AMD is retinal angiomatous proliferation (RAP), which accounts for 12-15% of neovascular age-related macular degeneration [6]. RAP usually not responds to standard management of wet AMD.

There are few incidence studies on AMD. The US Beaver Dam Eye Study in the USA reported a 14.3% 15-year cumulative incidence for early AMD and 3.1% for late AMD in adults aged 43-86 years [7].

3. Risk factors of AMD

The major risk factor for AMD is older age. More than 10% of people older than 80 years have late AMD. Female sex has been inconsistently reported as a risk factor as well [3].

The major systemic risk factors include cigarette smoking [8]. Cigarette smoking in particular is a strong and consistent risk factor for AMD. Smoking 20 cigarettes a day increases the risk of double. Obesity is further systemic risk factor. This is connected with systemic risks of obesity. These patients are more likely to have hypertension and diabetes mellitus, which are another risk factors [9,10]. People with AMD are also at increased risk of stroke [11].

Ocular risk factors for age-related macular degeneration include darker iris pigmentation, previous cataract surgery, and hyperopic refraction. A meta-analysis suggested previous cataract surgery was a strong risk factor for age-related macular degeneration, but this association was not shown in a randomized clinical trial [12].

Table 1 summarizes the risk factors for age-related macular degeneration.

4. Genetic factors

Last ten years several genes have been associated to have role in pathogenesis of AMD [2].

AMD is disease that is tightly connected with inflammatory reaction. Inflammatory and immunologic processes play major role in its pathogenesis. For this reason was identified complement factor H gene (CFH). Other confirmed genes in the complement pathway include

C2, CFB, C3 and CFI.29-31. On the basis of large genome-wide association studies, HDL cholesterol pathway genes have been implicated, including LIPC and CETP, and possibly ABCA1 and LPL.32-34 APOE in the LDL pathway might also be related to AMD [13]. The collagen matrix pathway genes COL10A1 and COL8A1 and the extracellular matrix pathway gene TIMP3 have also been linked to age-related macular degeneration [14]. Finally, genes in the angiogenesis pathway (VEGFA) have also been associated with age-related macular degeneration in a meta-analysis of two AMD genome-wide association studies [14].

Older age, female sex
Cigarette smoking
Obesity, Hypertension, Diabetes mellitus
Low dietary intake of vitamins A, C, and E, and zinc
Low dietary intake of lutein and omega-3 fatty acids
Unhealthy lifestyle related to cardiovascular risk factors

Table 1. Risk factors for age-related macular degeneration (adapted from [2])

Genes modifying several biological pathways are in AMD. Complement and immune processes, HDL cholesterol, and mechanisms involving collagen, extra-cellular matrix, and angiogenesis pathways are associated with the onset, progression, and bilateral involvement of AMD [2]. But it should be noted that genetic susceptibility can be modified by environmental factors. Genetic variations can also influence differential responses to treatments for age-related macular degeneration, an emerging research area [2].

Table 2 summarizes major genes associated with onset and progression of AMD

5. Clinical manifestations of the process of natural retinal aging

Aging is a physiological process involving all body organs and tissues. This process also affects the eye. It is a physiological process. That is not a manifestation of any disease. Each body cell has a planned life cycle from its inception to apoptosis (cell death). Body tissue in which there is no restoration of extinct mitotic cells (nerve tissue, retina), have a high incidence of manifestations of aging especially after the 75th year of life.

Clinical manifestation of retinal aging is mainly visible as a foveal reflex loss. Its background is in the loss of cells from the inner retinal layers around the foveola and extending of foveal avascular zone [15]. In macular zone are usually present small hard drusen, which are not yet a manifestation of AMD [16]. In macula also occur tigers like irregularities in pigmentation. Visual acuity remains on a physiological level unlike of subjects affected by AMD. Doppler velocimetry demonstrates decrease of blood flow to the macular area [17]. Further is detectable reduction of perifoveolar arterioles and venules together with enlargement of foveal avascular zone [18] and reduction of retinal ganglion cells amount [19].

Also can be diagnosed decrease of other visual functions in connection with the process of aging. There are especially adaptation to darkness, contrast sensitivity, color vision and ability of stereopsis [20].

CFH (complement factor H; chr 1)
ABCA4 (ATP-binding cassette transporter; chr 1)
COL8A1 (collagen type 8 alpha 1 subunit; chr 3)
CF1 (complement factor 1; chr 4)
VEGFA (vascular endothelial growth factor A; chr 6)
FRK/COL10A1 (fyn-related kinase/alpha chain of type X collagen; chr 6)
CFB (complement factor B [properdin]; chr 6)
C2 (complement component 2; chr 6)
ARMS2/HTRA1 (HtrA-serinepeptidase1; chr 10)
LIPC (hepatic lipase; chr 15)
CETP (cholesterylester transfer protein; chr 16)
APOE (apolipoprotein E; chr 19)
C3 (complement component 3; chr 19)
TIMP3 (tissue inhibitor of metalloproteinase 3; chr 22)
TNFRSF10A (tumor necrosis factor receptor superfamily 10a; chr 8)

Table 2. Summery of genes studied according to their impact on AMD (adapted from [2])

6. Classification and clinical features of age-related macular degeneration

Age-related macular degeneration can be divided into 2 categories: dry form (non-exudative) and wet form (exudative). The dry form is very prevalent and affects about 85 to 90 % of patients. The wet form occurs in the remaining 10 to 15 %. Impairment of central visual acuity is much higher in wet form of AMD than in dry form. Wet form is responsible for 85 % of severe vision loss.

6.1. Dry form of AMD

The dry form of AMD occurs independently on the choroidal neovascular membrane (CNV). It is associated with chorioretinal atrophy with no obvious defects in Bruch's membrane. Clinical studies show a decrease in chorioretinal blood flow [21]. Chorioretinal atrophy leads to subsequent degeneration of the retinal pigment epithelium cells (RPE). It is associated with involution of photoreceptors in the affected area [22]. The dry form of AMD includes atrophy of the outer part of hematoretinal barrier (HRB) without appreciable leakage. It seems that the barrier function is maintained and the area of atrophy remains dry.

Both forms of AMD are presented with painless loss of central vision. Individuals with dry AMD will typically complain of blurred vision as well as difficulty seeing fine details clearly. In the advanced stages, atrophic macular areas often coalesce, creating central scotoma, or blind spots, in the central visual field. This central visual loss compromises an individual's ability to perform basic tasks such as recognizing faces, reading signs, and other activities of daily living. Individuals with wet AMD will commonly present with visual distortion in which straight lines appear deformed. A hallmark of conversion from dry to wet AMD is a sudden and profound loss or distortion of central vision. These visual changes occur as a result of the acute degenerative changes occurring in the macula - most notably, subretinal and intraretinal hemorrhages from choroidal neovascular membrane. Individuals will typically have preserved peripheral vision in both processes [23].

6.2. Dry AMD

Dry AMD, the more common variety of the AMD, results from degeneration of outer retinal cells (RPE cells) with subsequent profound retinal dysfunction (damage of photoreceptors and retinal neurons).

The dry form of the disease is usually asymptomatic. Progression to the wet form may be indicated by sudden, severe vision loss or new onset of visual distortion (metamorphopsia).

The dry form of the disease is characterized by macular drusen, however alterations in RPE are visible. Intermediate to severe cases of the dry form are characterized by larger drusen and geographic atrophy of RPE layer. This can cause severe vision loss [24].

Regular examinations are important to determine whether patients may benefit from certain interventions. For patients over age 55 with no risk factors, a comprehensive eye exam every one to two years is recommended. Patients with early-stage disease or a family history of the condition may require closer follow-up. Those with an intermediate or advanced case of the dry form of the disease should be advised to take a particular combination multivitamin recommended in the Age-Related Eye Disease Study. These supplements reduce the risk of progression to the wet form of the disease by 25%. However, patients with early-stage disease may not benefit from such supplementation. Smoking cessation is associated with a substantial reduction in the risk of progression to late-stage disease [24].

Self-monitoring with an Amsler grid (available online at www.macula.org/amsler-grid) is critical and can help detect disease progression as early as possible. New onset of visual dis-

tortion noted on an Amsler grid, or any other sudden change in vision, may indicate progression from dry to the wet form of AMD. In some cases, timely treatment can reduce the risk of permanent loss of vision [24].

Patients who describe a sudden change in vision should be referred for urgent ophthalmic evaluation [24].

Drusen

In early dry AMD, various lipid and protein-rich extracellular deposits accumulate under the RPE [25]. Clinically, deposits of AMD are classified on fundoscopic features of morphology and size.

Drusen are a marker of age-related macular degeneration (AMD). Lesions similar to drusen, both in histology and their clinical appearance, are also seen in choroidal tumours, chronic inflammatory and degenerative conditions of the eye. Drusen are yellowish-white deposits of extracellular material located between the retinal pigment epithelium (RPE) and the inner collagenous zone of Bruch's membrane. They are the result of ageing. Drusen seen in these varied conditions have a similar clinical and histological appearance [26].

As seen through the ophthalmoscope, drusen are dots ranging in color from white to yellow, sometimes with a crystalline, glittering aspect. The origin of drusen has remained unresolved for more than a century. Moreover, there is no agreement as to whether drusen in the absence of other ocular abnormalities always point to early age-related macular degeneration [1].

Inside Bruch's membrane we can differentiate several biochemical and anatomical changes with aging, including collagenous thickening, calcification, and lipid infiltration, in the absence of apparent retinal dysfunction. The accumulation of specific deposits under the RPE is the hallmark histopathological feature of eyes with early AMD, when visual function is still not irreversibly impaired. Histopathological examination defines three main types of sub-RPE deposits on the basis of location, thickness, and content: basal laminar deposits (BLamD), basal linear deposits (BLinD), and nodular drusen. BLamD is seen as amorphous material of intermediate electron density between the plasma membrane and the basement membrane of the RPE, often containing banded structures (wide-spaced collagen), patches of electron-dense fibrillar or granular material, and occasionally, membranous debris [27]. They are distributed throughout the retina, including the periphery as well as the macula, underlying not only cones but rods as well. BLinD are diffuse, amorphous accumulations within the inner collagenous zone of BrM, external to RPE basement membrane, with similar content variations [Green]. BLinD are characterized by coated and non-coated vesicles as well as some membranous and empty profiles [28]. Biochemically, deposits contain phospholipids, triglycerides, cholesterol, cholesterol esters, unsaturated fatty acids, peroxidized lipids, and apolipoproteins [29].

In contrast to BLamD and BLinD, nodular drusen are discrete, dome-shaped deposits within the inner collagenous zone of BrM (i.e., external to the RPE basal lamina). Due to their location, nodular drusen are often contiguous with BLinD, and can be difficult to distinguish

from BLinD without electron microscopy [25]. Differences between BLamD and BLinD are seen on Figure 1.

A key factor influencing the classification of drusen is their size and shape. Simple aids, the widest diameter of venous branches at the edge of the disc, which has a dimension of 125 microns, determine the size of drusen.

Drusen are classified according to their appearance and size in the two basic categories:

1. Hard drusen

Their size is smaller than 63 microns. Ophthalmoscopic examination shows us small and well-demarcated yellow deposits (Figure 2.). This type of drusen is associated with very low risk of progression to late forms of AMD. However the occurrence of more than 8 hard drusen is associated with an increased risk of occurrence soft drusen.

2. Soft drusen: their size is greater than 63 microns are not sharply defined; often coalesce (Figure 3.). They are associated with higher risk of developing of wet AMD. If they affect foveal region they are often associated with the occurrence of metamorphopsia on Amsler grid. Over time, soft drusen can confluent and form irregular detachment of the RPE.

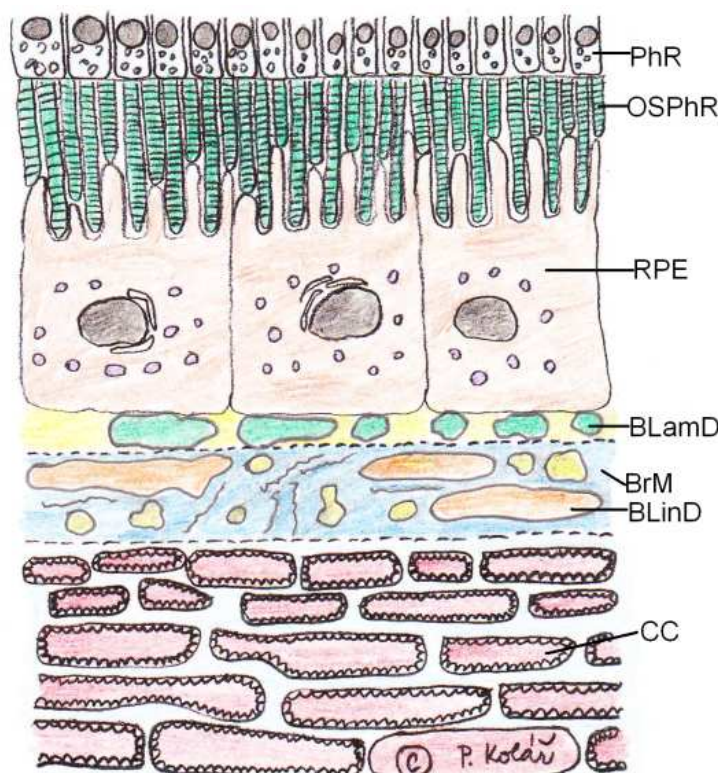


Figure 1. Schema of drusen in AMD. Legend: PhR – Photoreceptor, OSPhR – Outer Segment of Photoreceptor, RPE – Retinal Pigment Epithelium, BLamD – Basal Laminar Deposits, BLinD – Basal Linear Deposits, BrM – Bruch's Membrane, CC – Choriocapillaris

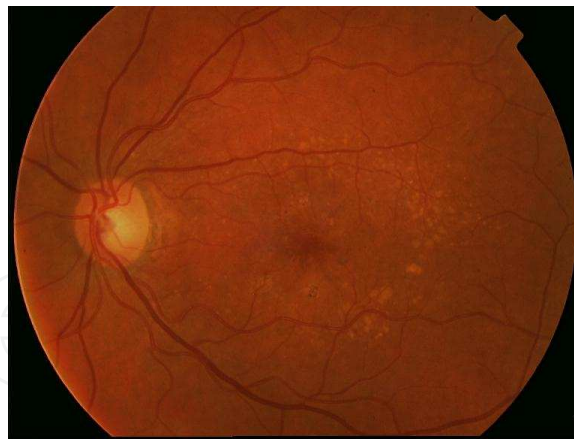


Figure 2. Hard drusen in macular region

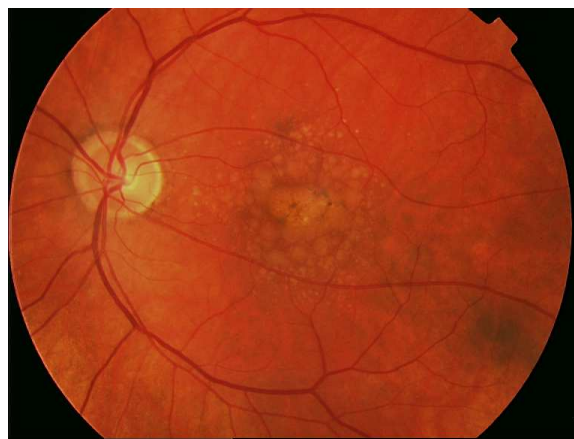


Figure 3. Soft drusen in macular region

Occurrence of drusen, however, is not a static phenomenon. Their presence is characterized by dynamic changes. Hard drusen can grow and change to soft drusen. Soft drusen can grow and coalesce into large confluent bodies. This leads to detachment of the RPE. Another change that can be seen is calcification. Inside drusen are visible cholesterol crystals. Drusen with advancing age usually increased in their amount. Presence of soft drusen in both eyes is an important risk factor in the development of advanced forms of AMD (geographic atrophy of the RPE and CNV). Hard drusen are, however, frequently associated with the occurrence of dry AMD [30].

Changes in retinal pigment epithelium

Irregularities in the RPE are associated with all stages of AMD. Focal hyperpigmentation arises from changes at the level of the RPE. We can differentiate hyperpigmentation or RPE cells, proliferation or migration of RPE cells into the subretinal space (Figure 4.). Focal hyperpigmentation is commonly associated with chorioretinal anastomosis.

Focal hypopigmentation is associated with areas of drusen, which leads to thinning of the RPE cells layer and reduction of melanin content. Low melanin content is associated with a high risk of transition to the wet form of AMD.

Geographic atrophy of RPE cells

Geographic atrophy (GA) of RPE is end-stage dry AMD. GA is characterized by well-circumscribed area of RPE atrophy, which allows good visualization of the choroid and in end stage of disease sclera (Figure 5., Figure 6.). The term geographic atrophy is not accurate name for this stage, because it is not only RPE atrophy, but also choriocapilaris and retinal atrophy. These three layers are inseparably joined together. The atrophy of one of them leads to irreversible atrophy of the other twos. GA can occurs either as a primary form of AMD, or followed by a secondary form after absorption of soft drusen, after flattening of RPE detachment, or as a consequence of CNV regression, or rupture of the RPE. GA of RPE is causing severe loss of visual acuity in 20% of AMD patients. The remaining 80% of the severe losses of visual acuity in AMD is caused by CNV.

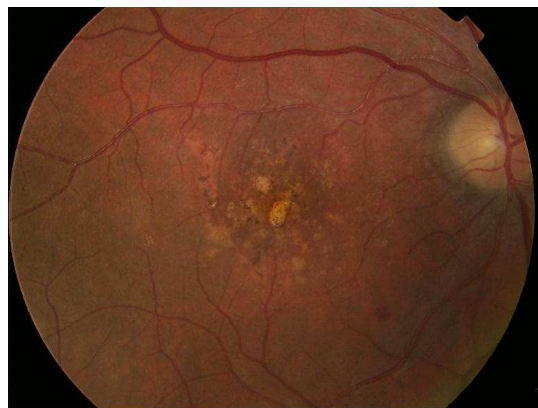


Figure 4. Hyperpigmentation and proliferation of RPE cells

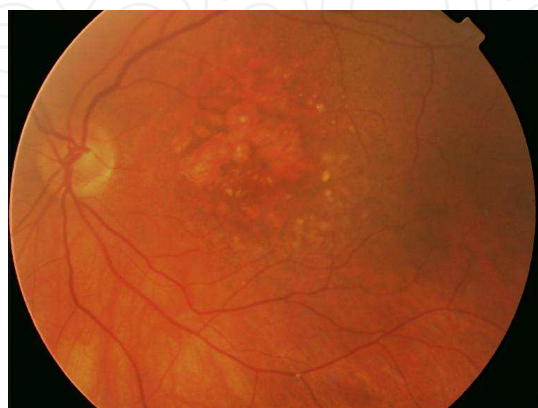

Figure 5. Geographic atrophy of RPE (color image)

Patients with primary GA are on average older than patients with wet AMD. Based on these circumstances, it has been suggested that the GA process occurs as reaction to changes in Bruch's membrane in those eyes, which are not developed wet form of AMD.

Patients with GA RPE have problems with near vision in particular, even if it is retained subfoveal RPE central area. These problems are caused by paracentral scotomas, abnormal ability to adapt to the darkness that reduces visual acuity under dimmed lighting, and the deterioration of contrast sensitivity [31]. Magnifying aids paradoxically don't bring a large profit because it carries the magnified image into the paracentral absolute scotomas. The patient's vision during the day varies depending on the ability to find a central area functioning retina within the zone of GA [32].

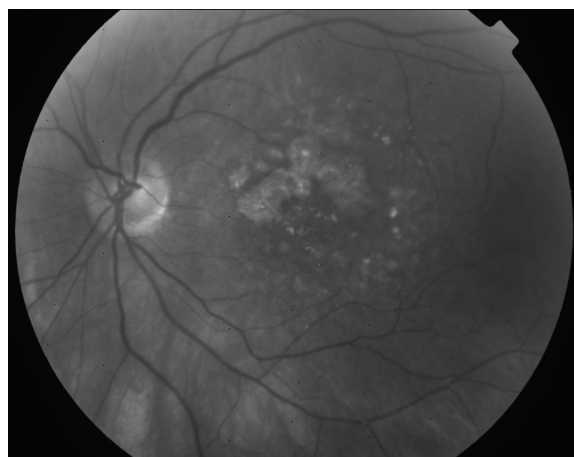


Figure 6. Geographic atrophy of RPE (red free image)

Long-term prognosis of visual acuity in GA is individual. It depends mainly on the location of the first location of GA. Interval from the developing of first spot to the GA with legal blindness is about 9 years [33]. The average rate of progress of GA is about 139 microns per year. Affected eyes have 8 % annual risk of a decline of visual acuity value from 20/50 to 20/100 [34].

GA RPE occurs bilaterally. The second eye is affected by in about 50%. Area of GA in the second eye is around 20 % smaller. With the development of GA in one eye decreases the risk of CNV in both eyes (i.e. wet AMD) [31].

Research that is based on the RPE injury hypothesis postulate that the pathogenesis and progression of dry macular degeneration is characterized by three distinct stages:

1. Initial RPE oxidant injury causes extrusion of cell membrane debris together with decreased activity of matrix metalloproteinases (MMPs), under the RPE as BLamD.
2. RPE cells are subsequently stimulated to increase synthesis of MMPs and other molecules responsible for extracellular matrix removal affecting both RPE basement membrane and BrM [35]. This process leads to progression of BLamD into BLinD and drusen

by admixture of blebs into BrM, followed by the formation of new basement membrane under the RPE to trap these deposits within BrM [36].

3. Macrophages are recruited to sites of RPE injury and deposit formation. Macrophage recruitment may be beneficial or harmful depending upon their activation status at the time of recruitment [37]. Nonactivated or scavenging macrophages may remove deposits without further injury. Activated or reparative macrophages, through the release of inflammatory mediators, growth factors, or other substances, may promote complications and progression to the late forms of the disease [37].

6.3. Wet form of AMD

Wet AMD occurs less commonly but is far more aggressive when compared with dry AMD. Wet AMD results from the development of neovascularization, or new blood vessel growth, beneath the retina. These abnormal blood vessels may break into the retinal cell layers. The leakage of fluid and proteins from these vessels causes scar formation throughout the macula, which ultimately results in deterioration of central vision. Wet AMD tends to be far more severe than dry AMD.

The wet form of AMD is characterized by occurrence of RPE detachment, choroidal neovascular membrane (CNV), subretinal hemorrhage in the macula. The terminal stage of wet AMD is disciform scar (Figure 7.).

In the last decade, the wet form of AMD allocated an additional 2 clinical units: angiomatose retinal proliferation (RAP) and polypoidal choroidal vasculopathy (PCV) (see below).

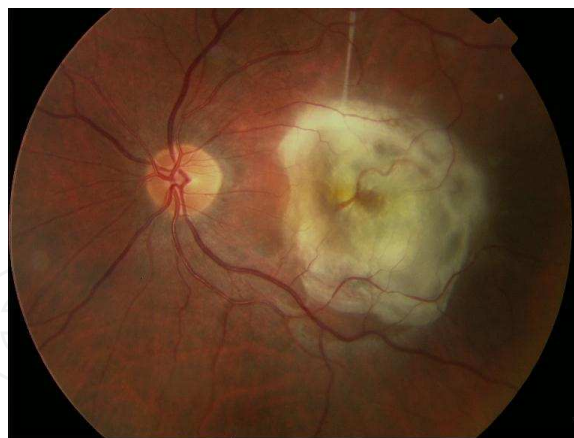


Figure 7. Disciform scar

Retinal pigment epithelium detachment

Their prognosis isn't good if central part of fovea is affected. [38]. RPE detachment is generally characterized by elevation of RPE layer from the Bruch's membrane. RPE detachment is divided into 4 categories.

1. Drusen RPE detachment (Figure 8.)

Drusen RPE detachment is formed in the later stages of multiple connecting soft drusen, which elevate the RPE layer from Bruch's membrane. Drusen RPE detachment is a high risk due to the development of CNV [38]. On the fluorescein angiography (FA) we can see in early phase hyperfluorescence of soft drusen, which isn't widening until the late stages.

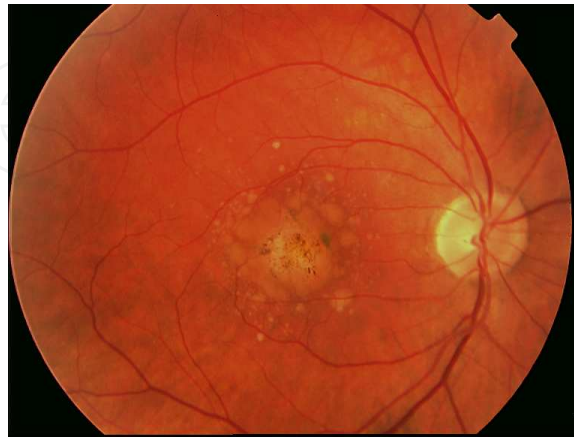


Figure 8. Drusen RPE detachment

2. Serous RPE detachment (Figure 9., Figure 10.)

Serous RPE detachment is roughly bounded elevation of the RPE cells, containing serous fluid that is usually clear, but may be turbid. On the FA we see early hyperfluorescence, which is sharply bounded, but not noticeable leakage.

3. Hemorrhagic RPE detachment (Figure 11.)

4. Fibrovascular RPE detachment (Figure 12.)

Hemorrhagic and vascularized RPE detachments are very close, because both contain the CNV. They differ from each other in principle, only the extent of bleeding, which in hemorrhagic RPE detachment greater. Angiographic picture of hemorrhagic RPE detachment is different from the vascularized because hemoglobin overlaps fluorescence, and the extent of CNV is not completely well defined. In unclear cases are possible to use indocyanine green angiography (ICGA), which can display the vascular structure of the retina and choroid despite hemoglobin.

The clinical course of RPE detachment may be as follows:

1. Persistent RPE detachment

Persistent RPE detachment can be stabilized without the presence of CNV. Over time, may be slowly progressing in its size [38].

2. Flattened RPE detachment

Flattening of the RPE detachment is uncommon and when it occurs, usually develops in the affected area geographic atrophy of the RPE [39].

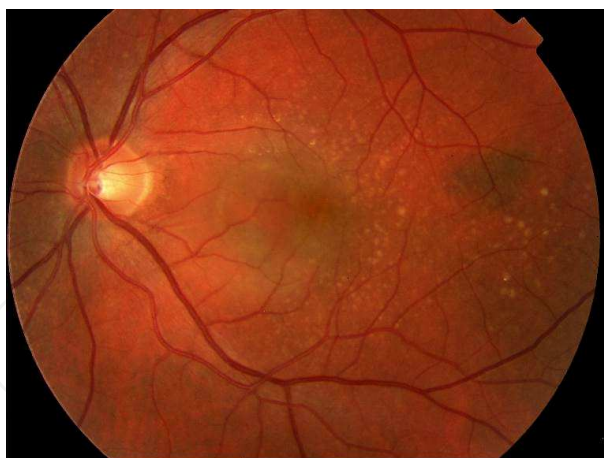


Figure 9. Serous RPE detachment

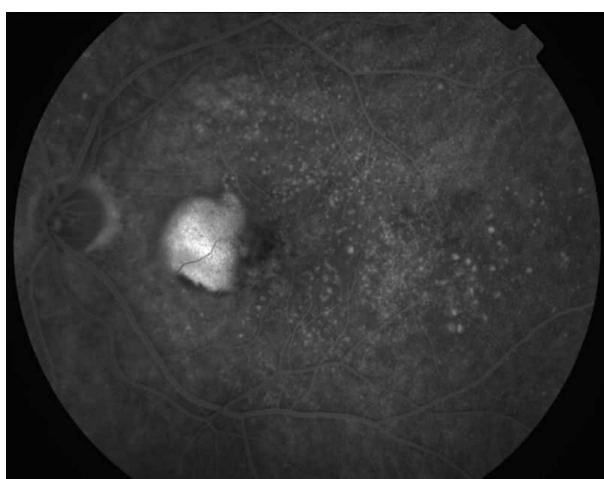


Figure 10. Serous RPE detachment on fluorescein angiography

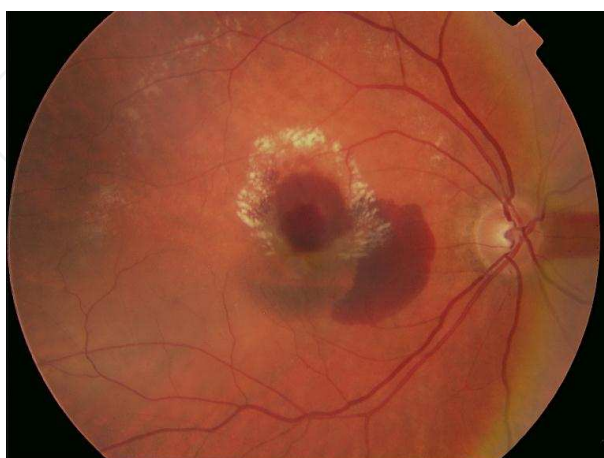


Figure 11. Hemorrhagic RPE detachment

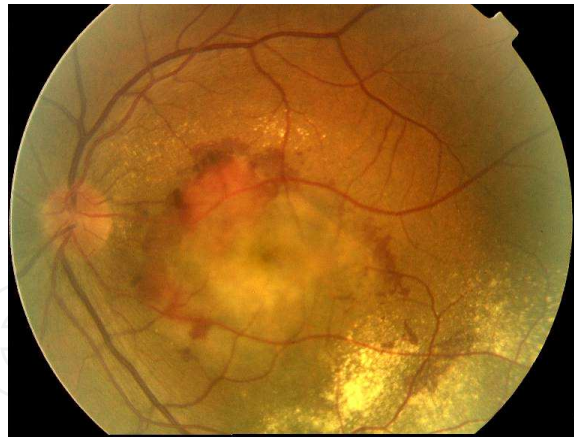

Figure 12. Fibrovascular RPE detachment

3. Rupture of RPE

RPE rupture is very unfavorable state accompanying the process of development of RPE detachment [40]. It occurs mostly at the edge of detachment at the transition attached and detached RPE. The RPE constricts away from location of rupture to the center of the detachment. If it is affected subfoveal area, there is detected a rapid decrease in visual acuity. In this case, the photoreceptors had lost contact with the RPE cells, and there is an absolute central scotoma. In the course of rupture usually occurs subretinal bleeding. Less frequently develops CNV, which is very aggressive and rapidly progresses to the disciform scar [40].

4. Development of CNV

But the most common complication of RPE detachment is the appearance of CNV. Increasing age is the basic risk factor of development of CNV in subjects with RPE detachment. CNV formation is rare in patients under 56 years of age, occurs in 29 % of those aged 56-75 years and affects 62.5 % of subjects in the group over 75 years. Another study showed that elderly patients have a larger RPE detachment with more fluid than younger and more often develop CNV [41].

Choroidal neovascular membrane

CNV occurs when occurs the rupture of Bruch's membrane. Newly formed blood vessels from choroid grow first into the space under the RPE and later under the subretinal space. Size of edema of neuroretina is a sign of CNV activity. Attempt to unify the classification of CNV has become a necessity. Based on this was defined by the term classic and occult CNV.

A typical picture of CNV includes subretinally localized grayish lesion, which can vary in size, location and thickness. If the membrane has a classic character, the lesion is usually well defined and its edges are lined with subretinal hemorrhages (Figure 13.).

On the FA it can be seen from early stages well-demarcated lesion that not increase in it size to the late stages of FA (Figure 14., Figure 15.).

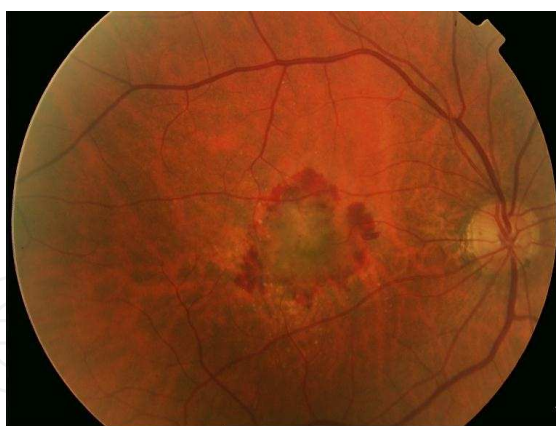

Figure 13. Classic CNV

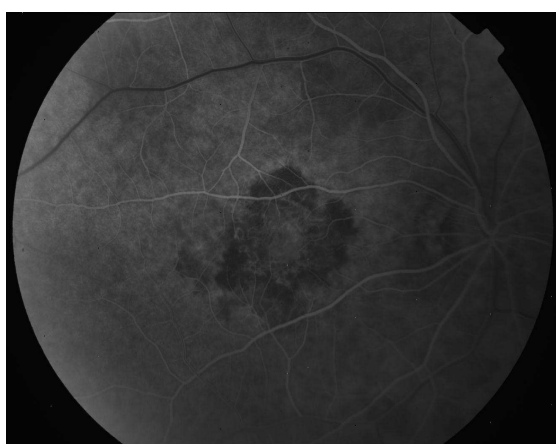

Figure 14. Early stage of classic CNV on FA, well-demarcated lesion with block of fluorescence on its border due to subretinal hemorrhage

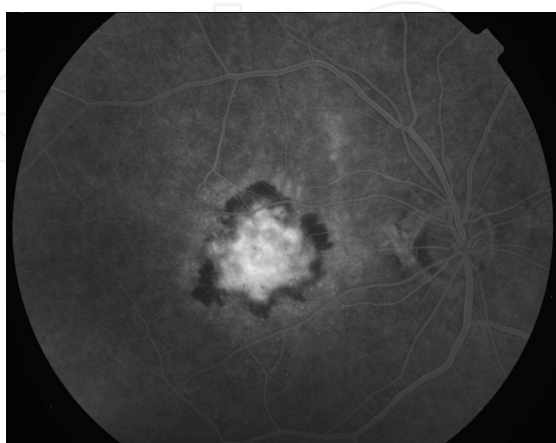


Figure 15. Late stage of classic CNV on FA, well-demarcated lesion that not increase in its size from early stage

The size of occult membranes is most evident at biomicroscopy. Changes are visible at the level of the RPE (movement of RPE cells, RPE detachment). There may occur subretinal hemorrhages. Oedema of neuroretina is noticeable (Figure 16.).

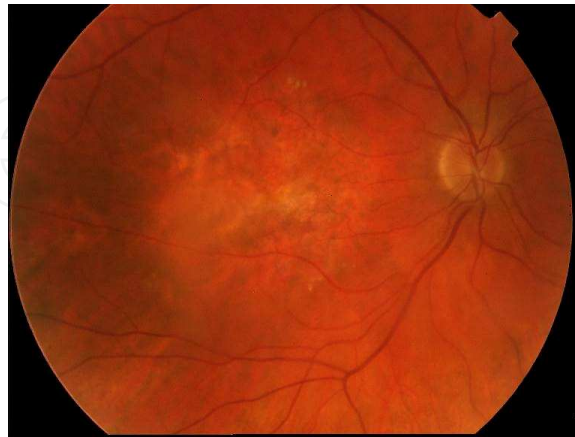

Figure 16. Occult CNV

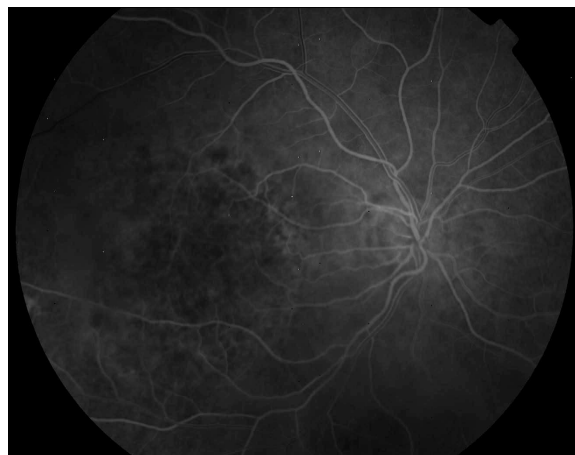

Figure 17. Early stage of occult CNV on FA, lesion is not clearly visible, leakage is very low and not well demarcated

Location of CNV in respect to the position of RPE

This classification is put into clinical practice for the first time in late 1960 by Gass [42].

Based on the findings on fluorescein angiography (FA) distinguishes two basic types of CNV: classic and occult.

Occult CNV (according to Gass classification type I) is characterized by the development of the neovascular complex and RPE choriocapillaris. CNV complex is characteristic for the beginning stages of wet AMD (Figures 16-18.).

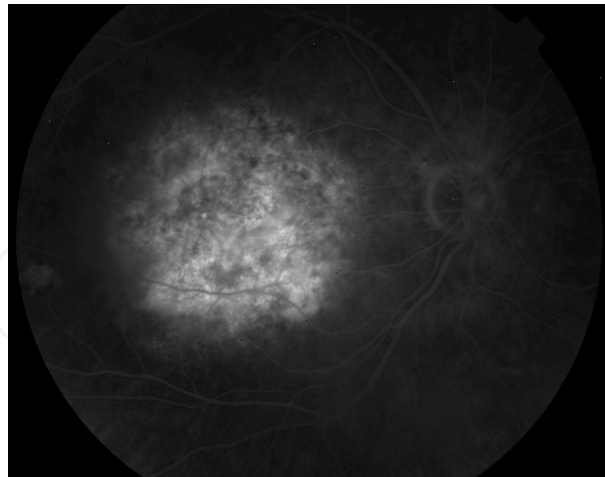


Figure 18. Late stage of occult CNV on FA, CNV size increases when compare to the early stage

Classic CNV (according to Gass classification type II) causes the spread of CNV complex in the space between the RPE and neuroretina. We can say that the classic CNV arises from occult CNV to a breach of continuity Bruch's membrane (Figures 13-15.).

Classification of CNV according to the center of the fovea

Entire CNV complex localization in respect to the center of the fovea plays a crucial role in deciding on the method of subsequent therapy. Localization is possible only by using of high-quality FA.

Depending on the position of CNV according to the fovea center we can diagnose 3 forms of CNV. The most common form is subfoveal localization, which has a CNV complex located beneath the center of the fovea. Another form is juxtafoveal localization. In this case, the CNV complex is located at a distance of 1 to 199 microns from the center of the fovea. The least frequent localization is extrafoveal location. Distance from the center of CNV complex fovea is larger than 200 microns.

Special clinical units within the wet form of AMD

In the last decades passed classification of wet AMD further development. There were created 2 new clinical entities distinguished from the model of classic and occult CNV: retinal angiomatous proliferation (RAP) and polypoidal choroidal vasculopathy (PCV).

Retinal Angiomatous Proliferation (RAP)

Yannuzzi created this term in order to describe the basic characteristics of clinical entity, in which the formation of neovascularization begins within retina [43].

RAP represents about 10 – 15 % of newly diagnosed cases of wet AMD [44]. It occurs more frequently in elderly patients [43]. Most commonly occurs in Caucasians, in contrast to PCV, which is more common in pigmented races [45].

The disease is divided into 3 clinical stages

Stage I – intraretinal neovascularization: New RAP lesions develop typically outside the foveal avascular zone, i.e. extrafoveal. The course is initially asymptomatic. Intraretinal neovascularization (IRN) begins in the deep capillary plexus outside the center of the fovea. During development, the most typically spread in the vertical direction, i.e. between the external and the internal limiting membrane. IRN that is spreading sideways is not typical in initial stages. Biomicroscopically can be observed capillary dilation with a large network of nourishing blood vessels and intraretinal haemorrhages. Haemorrhages are usually very discreet compared to subretinal hemorrhages accompanying classic and occult CNV and especially PCV [45].

Stage II - subretinal neovascularization: This stage is diagnosed if the complex of IRN moves between photoreceptors and RPE. This area develops detachment of neuroretina with corresponding edema. Intraretinal haemorrhages are more noticeable than in stage I. If the lesion extends into the subretinal space, there can be diagnosed small subretinal haemorrhage. At this stage, there is often retino-retinal anastomosis, which has afferent arteriole and efferent venule. Serous RPE detachment can be diagnosed if is IRN connected with subretinal CNV.

Stage III - CNV: In stage III is diagnosed already typical CNV combined with vascularized RPE detachment. During the development of CNV is then in subretinal space formed chorioretinal anastomosis like clear communication between the retinal bloodstream and the choriocapilaris. CNV is predominantly perfused by the vascular system of the choroid. In the end stage is then evident disciform scar.

Pathophysiological mechanism of RAP development is not explained in detail till now. It is assumed the proportion of VEGF produced by RPE cells [46]. Thus neovascularization begins intraretinally and later subretinally. Secondarily creates RPE detachment with the occult CNV [47]. Reduction of Bruch membrane permeability for VEGF may signify increases its intraretinal concentration. This situation is main cause of intraretinal neovascularization [48]. Another theory shows that the oxidative stress leads to migration of RPE cells, both subretinally and intraretinally. This leads to the production of VEGF and stimulation of neovascularization in an atypical location [49].

Diagnostic

Basic diagnostic modality is beside biomicroscopy FA examination. In stage I leakage occurs at the region intraretinal neovascularization. In this area is also biomicroscopically demonstrated edema with accumulation of vascular loops and leakage of dye on FA. RAP can at this stage be erroneously mistaken for another microangiopathy, such as incipient diabetic maculopathy. RAP stage II and I may be misdiagnosed as classic CNV. In stage III we can see on FA finding very close to vascularized RPE detachment. It is therefore often diagnosed as occult CNV [43].

ICGA usually brings enough light to the uncertain cases. In stage I is observed focal hyperfluorescence in retinal circulation, which has the character of IRN [44]. There can often be diagnosed retino-retinal anastomosis. In stage II IRN is visible inside and under the retina.

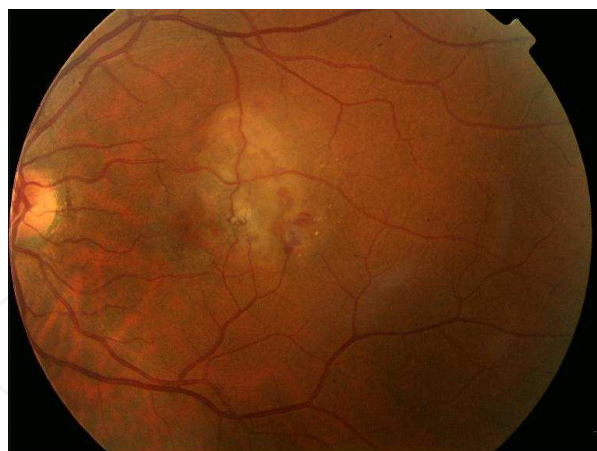


Figure 19. Stage III of RAP. Temporally in macula is chorioretinal anastomosis.

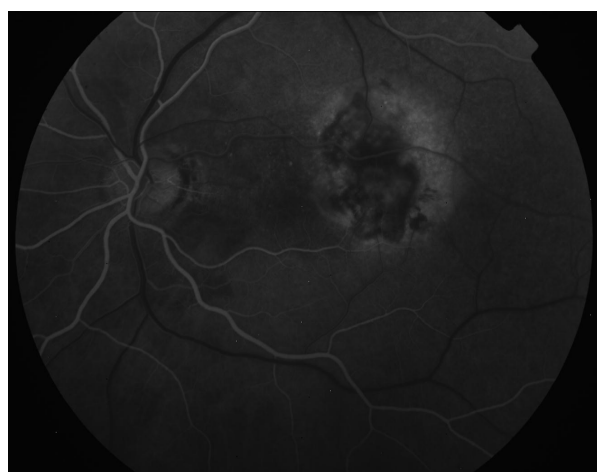

Figure 20. Stage III of RAP on FA, early phase

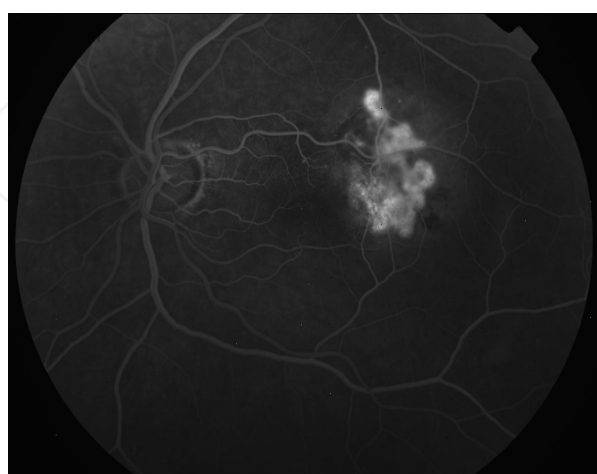

Figure 21. Stage III of RAP on FA, late phase, leakage dye from CNV is visible

For location of IRN have to be used pseudo stereo view to state the position of neovascularization in the vertical axis. Hot spot for RAP must be distinguished from another hot spots, e.g. inside the choroid. In stage III is visible, a connection of choroidal and retinal neovascularization (Figure 19.-21.). This creates a complex neovascularization, which has the character of vascularized RPE detachment. In some cases, we trace chorioretinal anastomosis.

Polypoidal Choroidal Vasculopathy (PCV)

This clinical entity has been in detail described and classified by Yannuzzi in 1990 as a peculiar hemorrhagic disorder of the macula, characterized by recurrent sub-retinal and sub-retinal pigment epithelium bleeding in middle aged black women [50]. Pathogenesis of the disease is not completely understood. The primary pathological changes that occur are sac-like extension of choroidal vessels, which are sacculated polypoidal nature. Clinically it is manifested by multiple hemorrhagic PCV and serous RPE detachment accompanied by retinal edema [50]. PCV is a special type of CNV in wet AMD [45].

PCV usually occurs in pigmented races between 50 - 65 years of age. Originally it was thought that the disease affected only black women. According to published data, the disease occurs in men, the ratio of affected women compared to men is 4,7:1 [51]. Prevalence varies between 4-10% in subjects with newly diagnosed wet AMD.

For the basic clinical picture of PCV is characterized by the absence drusen accompanied by haemorrhagic or serous RPE detachment. Other symptoms are: minimal signs of scarring, vitreous hemorrhage, and signs of intraocular inflammation. The disease usually occurs bilaterally [50], although it is described one-side occurrence [52]. The main factor contributing to the development of PCV seems to be the long-term chronic hypoxia by RPE detachment together with destructive effect of hard exudates.

Vascular structure PCV is located in choroid. Distinguish by size we have small, medium and large PCVs. PCV lesions reach a larger size if there are affected larger choroid vessels. When are affected medium choroid vessels, the lesions are smaller. Their diagnosis is more difficult because they don't have a characteristic image like a larger lesions [50].

PCV is located mostly around the optic disc. Some works but also show localization in the central periphery or in the central macular area [53]. PVC may be present as a single lesion, or may be multiple. Topographically are lesions localized to the area under the Bruch's membrane. The results of these studies are documented on OCT [54].

Natural course of the disease

PCV has the character of a chronic disease that manifests by serosanguinolent RPE detachment often near the optic nerve. Disease comes in multiple relapses, and patients have maintained good visual acuity for long time. Chronic RPE detachment usually results to the creation scarring plaque beneath the RPE, which is hardly distinguishable from classical disciform scar that develops as a terminal stage of the wet form of AMD. Polyps can have very specific progress. They occlude often spontaneously, and after some time are again perfused. If are polyps located in the central subfoveal area in the terminal stage of the disease can

occur RPE atrophy and chronic cystoid retinal changes. Rarely may arise massive subretinal and intravitreal hemorrhage, which is usually fatal and final visual acuity is poor [55].

Diagnostic

Blood vessels occurring with PCV have a characteristic shape. Form a bag-like aneurysms, RPE over them has a characteristic red-orange color (Figure 22., Figure 23.).

In contrast, blood vessels in other types of CNV are made from very small vascular knitting and are usually gray-green color. The thickness of the choroid is smaller in other types of CNVs. In PCV is choroid thicker.

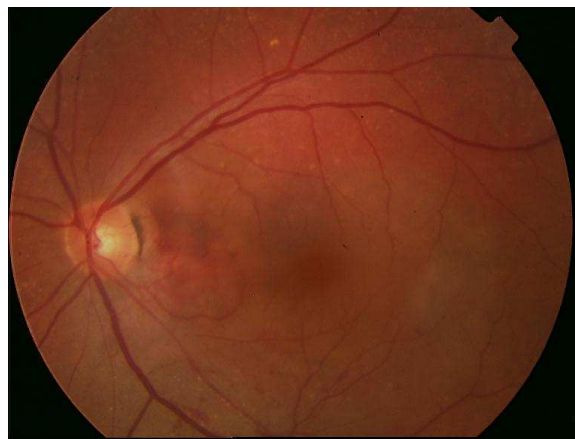


Figure 22. PCV in maculopapilar bundle, color image

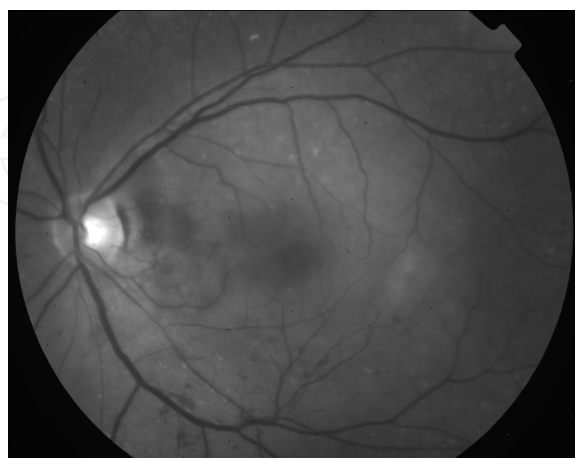


Figure 23. PCV in maculopapilar bundle, red free image

FA may in some cases provide a diagnosis of PCV (Figure 24., Figure 25.).

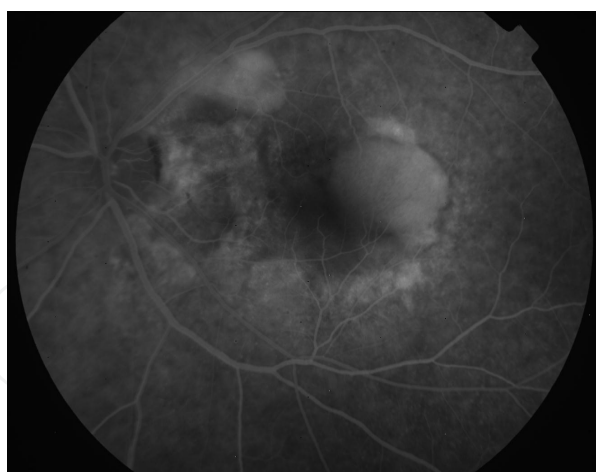

Figure 24. PCV in middle phase of FA, leakage from polyps is visible, in temporal part of macula is detected RPE detachment

However, the basic diagnostic modality is in the diagnosis of PVC ICGA. Only on ICGA can be diagnosed bag-like extension of choroidal vessels [56]. In the early phase of ICGA fill up large PCV vessel before filling of retinal vessels. Neighborhood of PCV lesions remains hypofluorescent. Late stage of ICGA shows choroidal polyps. They are closely associated with large chorioidal vessels (Figure 26., Figure 27.).

In the initial phase of the angiogram polyps are usually smaller than in the late phase. This corresponds to the red-orange lesions, which are detectable by biomicroscopy. In the late stage, there is a reverse phenomenon. Center of the lesion becomes hypofluorescent and around the polyp occurs hyperfluorescence. At a very late stage angiogram can occur wash-out of dye. This phenomenon is only seen in the lesions without leaking; leaking lesions remain hyperfluorescent [56].

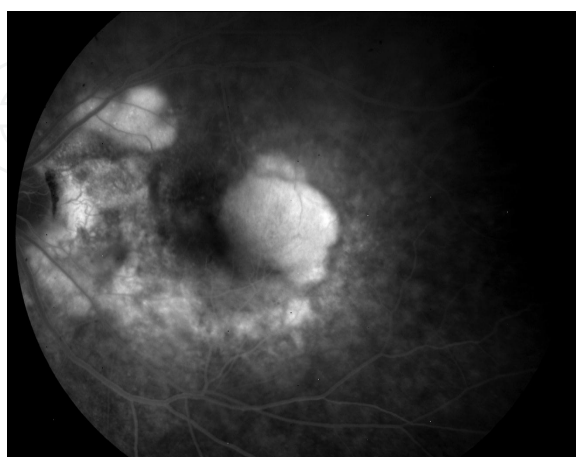


Figure 25. PCV in late phase of FA, leakage from polyps is visible, 2 RPE detachments are located on temporal upper vascular arcade and in temporal part of macula

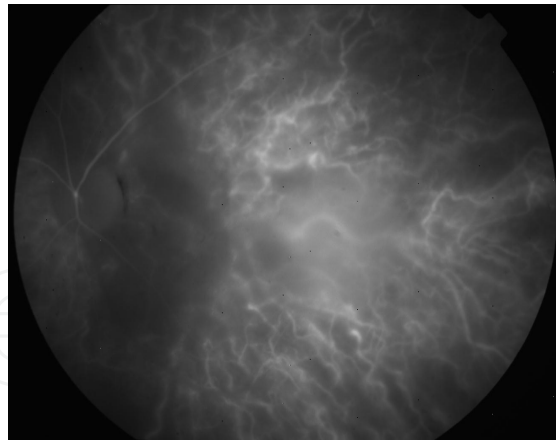


Figure 26. PVC, early stage on ICGA

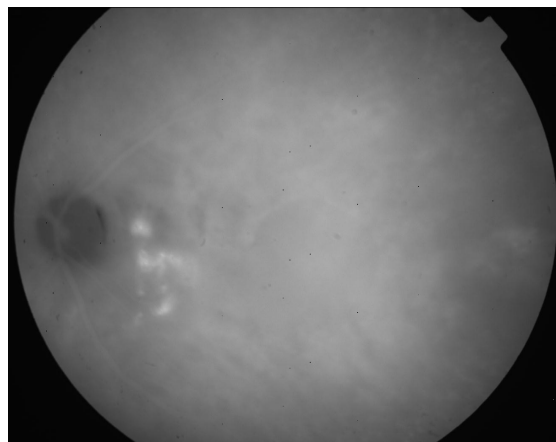


Figure 27. PCV, late stage on ICGA, polyps are visible near the optic disc

OCT examination demonstrates elevation of RPE layer, which corresponds to the red-orange lesions detected during biomicroscopic examination. PCV is manifested against serous RPE ablation by greater prominence of RPE layer [54].

Differential diagnosis

Differential diagnosis distinguishes PCV from other vascular abnormalities, inflammatory conditions of the retina and choroid, other types of CNV and choroidal tumors. Improved diagnostic methods and clarifying the pathophysiological mechanisms lead to the correct diagnosis of PCV more often than before.

In diagnostic help both FA and ICGA. CNV in PCV leaks already at an early phase, so as CNV different origin. In the late stage, the lesion on the basis of PVC may have washed out the dye [56]. If a bag-like aneurysms leak, in their neighborhood is evident late dye leakage (Figure 26., Figure 27.).

CNV on the basis of PVC, rarely undergo to fibrose unlike other types of CNV in AMD. RPE detachment associated with PCV almost doesn't fibrose, whereas RPE detachment associated with occult CNV fibrose very often and has a very poor prognosis [50].

Author details

Petr Kolar

Address all correspondence to: pe-kolar@seznam.cz

Department of Ophthalmology, University Hospital Brno and Masaryk University Brno, Czech Republic

References

- [1] De Jong P T V M. Age-related Macular Degeneration. *The New England Journal of Medicine*. 2006; 355(14), 1474-85.
- [2] Lim L S, Mitchell P, Seddon J M, Johanna M et al. Ophthalmology 1: Age-related Macular Degeneration. *Lancet*. 2012; 379, 1728-1738.
- [3] Smith W, Assink J, Klein R, et al. Risk factors for age-related macular degeneration: Pooled findings from three continents. *Ophthalmology*. 2001; 108, 697-704.
- [4] Friedman D S, Katz J, Bressler N M, Rahmani B, Tielsch J M. Racial differences in the prevalence of age-related macular degeneration: the Baltimore Eye Survey. *Ophthalmology*. 1999; 106, 1049-55.
- [5] Laude A, Cackett P D, Vithana E N, et al. Polypoidal choroidal vasculopathy and neovascular age-related macular degeneration: same or different disease? *Prog Retin Eye Res*. 2010; 29 19-29.
- [6] Gupta B, Jyothi S, Sivaprasad S. Current treatment options for retinal angiomatous proliferans (RAP). *Br J Ophthalmol*. 2010; 94, 672-77.
- [7] Klein R, Klein B E, Knudtson M D, Meuer S M, Swift M, Gangnon R E. Fifteen-year cumulative incidence of age-related macular degeneration: the Beaver Dam Eye Study. *Ophthalmology*. 2007; 114, 253-62.
- [8] Seddon J M, Willett W C, Speizer F E, Hankinson S E. A prospective study of cigarette smoking and age-related macular degeneration in women. *JAMA*. 1996; 276, 1141-46.
- [9] Seddon J M, Cote J, Davis N, Rosner B. Progression of age-related macular degeneration: association with body mass index, waist circumference, and waist-hip ratio. *Arch Ophthalmol*, 2003; 121, 785-92.

- [10] Chakravarthy U, Wong TY, Fletcher A, et al. Clinical risk factors for age-related macular degeneration: a systematic review and meta-analysis. *BMC Ophthalmol.* 2010; 10, 31.
- [11] Snow KK, Seddon JM. Do age-related macular degeneration and cardiovascular disease share common antecedents? *Ophthalmic Epidemiol.* 1999; 6, 125-43.
- [12] Chew E Y, Sperduto R D, Milton R C, et al. Risk of advanced age-related macular degeneration after cataract surgery in the Age-Related Eye Disease Study: AREDS report 25. *Ophthalmology.* 2009; 116, 297-303.
- [13] McKay G J, Patterson C C, Chakravarthy U, et al. Evidence of association of APOE with age-related macular degeneration- a pooled analysis of 15 studies. *Hum Mutat.* 2011; 32, 1407-16.
- [14] Yu Y, Bhangale TR, Fagerness J, et al. Common variants near FRK/ COL10A1 and VEGFA are associated with advanced age-related macular degeneration. *Hum Mol Genet.* 2011; 20, 3699-709.
- [15] Laatikainen L, Karinkari J. Capillary-free area of the fovea with advancing age. *Invest Ophthalmol Vis Sci.* 1977; 161, 1154-1157.
- [16] Klein R, Klein B E K, Linton K L P. Prevalence of age-related maculopathy: the Beaver Dam Eye Study. *Ophthalmology.* 1992; 99, 933-943.
- [17] Groh M J M, Michelson G, Langhans M J, et al. Influence of age on retinal and optic nerve head blood circulation. *Ophthalmology.* 1996; 103, 529-534.
- [18] Ibrahim Y W M, Bots M L, Mulder P G H, et al. Number of perifoveolar vessels in aging, hypertension, and atherosclerosis: the Rotterdam Study. *Invest Ophthalmol Vis Sci.* 1998; 39, 1049-53.
- [19] Gao H, Hollyfield J G. Aging of the human retina: differential loss of neurons and retinal pigment epithelial cells. *Invest Ophthalmol Vis Sci.* 1992; 33, 1-17.
- [20] Sanberg M A, Gaudio, A R. Slow photostress recovery and disease severity in age-related macular degeneration. *Retina.* 1995; 15, 407-412.
- [21] Grunwald J E, Hariprasad S M, Dupont J, et al. Foveolar choroidal blood flow in age-related macular degeneration. *Invest Ophthalmol Vis Sci.* 1998; 39, 385-390.
- [22] Curcio C A, Saunders P L, Younger P W, et al. Peripapillary chorioretinal atrophy: Bruch's membrane changes and photoreceptor loss. *Ophthalmology.* 2000; 107, 334-343.
- [23] Hazin R, Freeman P, David M D, Kahook M Y. Age- Related Macular Degeneration: A Guide for the Primary Care Physician. *Journal of the National Medical Association.* 2009; 101, 134-138.
- [24] Noble J, Chaudhary V. Age-related Macular Degeneration. *Canadian Medical Association Journal.* 2010; 16, 1759.

- [25] Mettu P S, Wielgus A R, Ong S S, Cousins S W. Retinal pigment epithelium response to oxidant injury in the pathogenesis of early age-related macular degeneration. *Molecular Aspects of Medicine*. 2012; 33, 376-398.
- [26] D'Souza Y, Jones C J P, Bonshek R. Glycoproteins of drusen and drusen-like lesions. *J Mol Hist*. 2008; 39, 77-86.
- [27] Kliffen M, van der Schaft T L, Mooy C M, de Jong P T. Morphologic changes in age-related maculopathy. *Microscopy Research and Technique*. 1997; 36 (2), 106-122.
- [28] Green, W R. Histopathology of age-related macular degeneration. *Molecular vision*. 1999; 5, 27.
- [29] Penfold P L, Madigan M C, Gillies M C, Provis J M. Immunological and aetiological aspects of macular degeneration. *Progress in Retinal and Eye Research*. 2001; 20 (3), 385-414.
- [30] Fine S L, Berger J W, Maguire M G, et al. Age related macular degeneration. *N Engl J Med*. 2000; 342, 483-492.
- [31] Sunness J S, Rubin G S, Applegate C A, et al. Visual function abnormalities and prognosis in eyes with age-related geographic atrophy of the macula and the good visual acuity. *Ophthalmology*. 1997; 104, 1677-1691.
- [32] Sunness J S, Gonzales-Baron J, Applegate C A, et al. Enlargement of atrophy and visual acuity loss in the geographic atrophy form of age-related macular degeneration. *Ophthalmology*. 1999; 106, 1768-1779.
- [33] Maguire P, Vine A K. Geographic atrophy of retinal pigment epithelium. *Am J Ophthalmol*. 1986; 102, 621-625.
- [34] Schatz H, McDonald H R. Atrophic macular degeneration: rate of spread of geographic atrophy and visual loss. *Ophthalmology*. 1989; 96, 1541-1551.
- [35] Strunnikova N, Zhang C, Teichberg D, Cousins S W, Baffi J, Becker K G, Csaky K G. Survival of retinal pigment epithelium after exposure to prolonged oxidative injury: a detailed gene expression and cellular analysis. *Investigative Ophthalmology and Visual Science*. 2004; 45 (10), 3767-3777.
- [36] Espinosa-Heidmann D G, Suner I J, Catanuto P, Hernandez E P, Marin-Castano M E, Cousins S W. Cigarette smoke-related oxidants and the development of sub-RPE deposits in an experimental animal model of dry AMD. *Investigative Ophthalmology and Visual Science*. 2006; 47 (2), 729-737.
- [37] Cousins S W, Espinosa-Heidmann D G, Csaky K G. Monocyte activation in patients with age-related macular degeneration: a biomarker of risk for choroidal neovascularization? *Archives of Ophthalmology*. 2004; 122 (7), 1013-1018.
- [38] Casswell A G, Kohen D, Bird, A C. Retinal pigment epithelial detachment in the elderly: classification and outcome. *Br J Ophthalmol*. 1985; 69, p. 379-403.

- [39] Blair C J. Geographic atrophy of retinal pigment epithelium. *Arch Ophthalmol*. 1975; 93. 19-25.
- [40] Green S N, Yarian D. Acute tear of the retinal pigment epithelium. *Retina*. 1983; 3, 16-20.
- [41] Yannuzzi L A, Gitter K A, Schatz H. Detachment of the retinal pigment epithelium. In: *The Macula: A Comprehensive Text and Atlas*. Baltimore: Williams and Wilkins; 1979, 166-179.
- [42] Gass J D M. Pathogenesis of disciform detachment of neuroepithelium III. Senile disciform macular degeneration. *Am J Ophthalmol*. 1967; 63, 617-644.
- [43] Yannuzzi L A, Negrao S, Iida T et al. Retinal angiomatous proliferation in the age-related macular degeneration. *Retina*. 2001; 21, 416-434.
- [44] Lafaut B A, Aisenbrey S, Broecke C V, et al. Clinicopathological correlation of deep retinal vascular anomalous complex in age-related macular degeneration. *Br J Ophthalmol*. 2000; 84, p. 1268-1274.
- [45] Yannuzzi L A, Wong D W K, Sforzolino B S, et al. Polypoidal choroidal vasculopathy and neovascularized age-related macular degeneration. *Arch Ophthalmol*. 1999; 117, 1503- 1510.
- [46] Wells J A, Murthy R, Chibber R, et al. Levels of vascular endothelial growth factor are elevated in the vitreous in patients with subretinal neovascularization. *Br J Ophthalmol*. 1996; 363-366.
- [47] Tobe T, Okamoto N, Vinore M A, et al. Evolution of neovascularization in mice with overexpression of vascular endothelial growth factor in photoreceptor. *Invest Ophthalmol Vis Sci*. 1998; 39, p. 180-188.
- [48] Khiffen M, Sharma H S, Moory C M, et al. Increased expression of angiogenic growth factors in age-related maculopathy. *Br J Ophthalmol*. 1997; 81, 1154-1162.
- [49] Tamai K, Spaide R F, Ellis E A, et al. Lipid hydroperoxide-stimulated subretinal choroidal neovascularization in the rabbit. *Exp Eye Res*. 2002; 74, 301-308.
- [50] Yannuzzi L A, Sorenson J, Spaide R F, et al. Idiopathic polypoidal choroidal vasculopathy. *Retina*. 1990; 10, 1-8.
- [51] Uayma M, Wada M, Nagai Y, et al. Polypoidal choroidal vasculopathy: natural history. *Am J Ophthalmol*. 2002; 133, 639-648.
- [52] Iida T, Yannuzzi L A, Freund K B, et al. Retinal angiopathy and polypoidal choroidal vasculopathy. *Retina*. 2002; 22, 455-463.
- [53] Yannuzzi L A, Nogueira F B, Spaide R F, et al. Idiopathic polypoidal choroidal vasculopathy: a peripheral lesions. *Arch Ophthalmol*. 1998; 116, p. 382-383.

- [54] Iijima H, Iida T, Imai M, et al. Optical coherence tomography of orange-red subretinal lesions in eyes with idiopathic polypoidal vasculopathy. *Am J Ophthalmol*. 2000; 129, 105- 111.
- [55] Yang S S, Fu A D, McDonald H R, et al. Massive spontaneous choroidal hemorrhage. *Retina*. 2003; 23, 139-144.
- [56] Spaide R F, Yannuzzi L A, Slakter J S, et al. Indocyanine green videoangiography of idiopathic polypoidal choroidal vasculopathy. *Retina*. 1995; 15, 100-110.